

























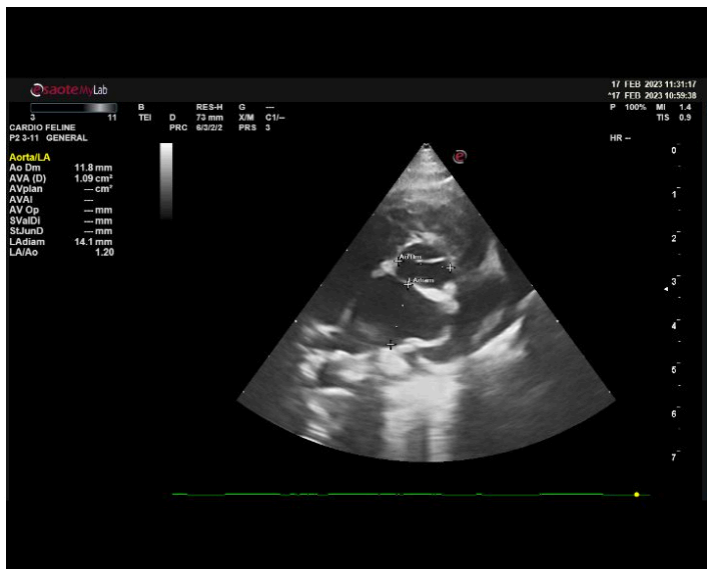
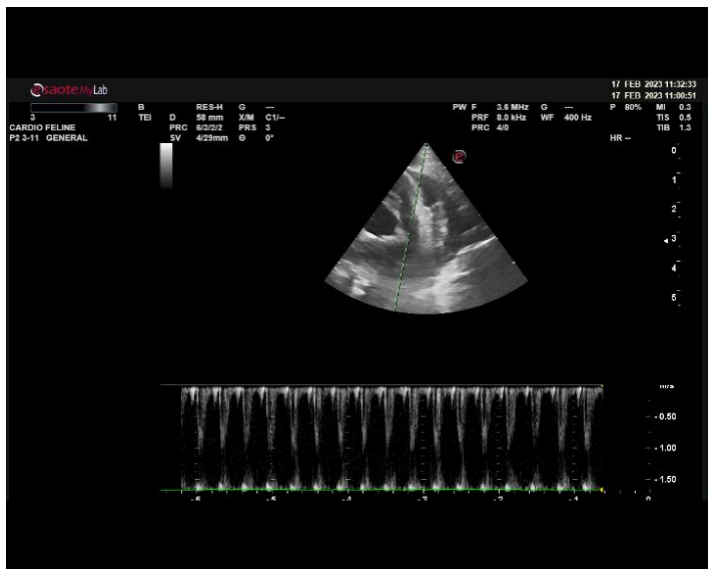
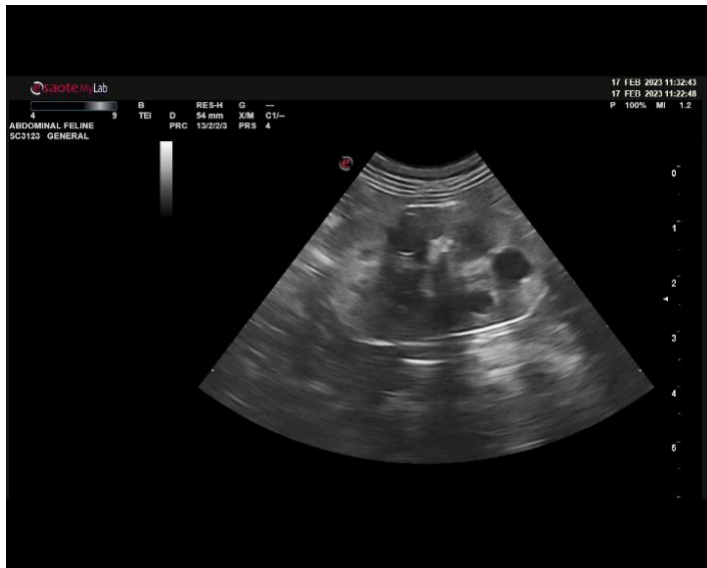

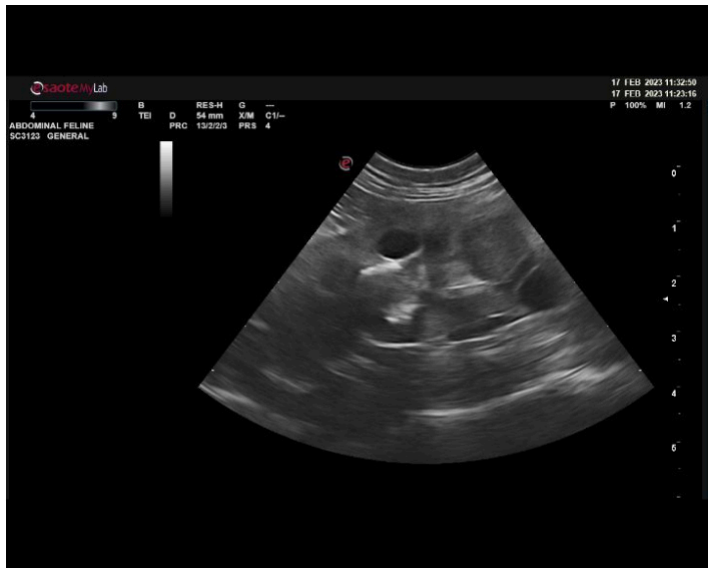
三分类血常规 (含血涂片)

检查项目	结果值	单位	参考范围	结果	备注
WBC (白细胞数目)	7.0	10 ³ /uL	5.5~19.5		--
Lymph# (淋巴细胞数目)	2.9	10 ³ /uL	0.8~7		--
MON# (单核细胞数目)	0.3	10 ³ /uL	0~1.9		--
Gran# (粒细胞数目)	3.8	10 ³ /uL	2.1~15		--
Lymph% (淋巴细胞百分比)	42.1	%	12~45		--
Mon% (单核细胞百分比)	4.5	%	2~9		--
Gran% (粒细胞百分比)	53.4	%	35~85		--
RBC (红细胞数目)	11.28 ↑	10 ¹² /L	4.6~10		--
HGB (血红蛋白浓度)	158 ↑	g/L	93~153		--
HCT (红细胞压积)	41.6	%	28~49		--
MCV (平均红细胞体积)	36.9 ↓	fL	39~52		--
MCH (平均血红蛋白量)	14	pg	13~21		--

MCH (平均血红蛋白量)	14	pg	13~21		--
MCHC (平均红细胞血红蛋白浓度)	379	g/L	300~380		--
RDW (红细胞分布宽度)	15.4	%	14~18		--
PLT (血小板数目)	250	10 ⁹ /L	100~514		--
MPV (平均血小板体积)	7.6	fL	5~11.8		--
PDW (血小板分布宽度)	15.1				--
PCT (血小板压积)	0.190	%			--
Eos% (嗜酸性粒细胞百分比)	3.6	%			--
单核细胞镜检		%	0~4		--
淋巴细胞镜检		%	20~55		--
叶状中性粒细胞镜检		%	35~75		--
杆状中性粒细胞镜检		%	0~3		--
嗜酸性粒细胞镜检		%	2~12		--
嗜碱性粒细胞镜检		%			--
其他细胞镜检		%			--

检查影像



检查所见

DOCTOR NOTES

TRANSLATED FROM CHINESE

Multiple cysts in the liver.

Kidney stones, polycystic kidney: Pericardial effusion, suspected
longitudinal hernia: Not selling sound and shadow

The chyme in the stomach, the distal end is not visible, and the pyloric outflow tract has no obvious abnormality; the small intestine is empty, and the wall layer is acceptable, and a continuous moderate echo interface can be seen in the colon, accompanied by 4.

The spleen capsule is basically smooth, and the parenchymal echo is basically uniform Anechoic liquid dark area, no obvious dilatation of extrahepatic bile duct; incomplete shape of diaphragm

The capsule of the liver is smooth, with multiple cystic dark areas in the parenchyma, irregular in shape, and clear veins; the gallbladder is basically filled, and the echo of the gallbladder wall is slightly enhanced.

The contours of both kidneys are not smooth, the corticomedullary boundary is acceptable, the blood flow signal in the medulla is abundant, and hyperechoic light clusters with acoustic shadows can be seen on both sides; multiple cystic dark areas can be seen in the renal parenchyma, the largest The diameter of the ureter is about 8.8mm; there is no dilation of the ureter

The bladder is basically filled, and there is an echo-free liquid dark area in the cavity, and there is no expansion of the proximal urethra 2.M-type: IVSD=5.2LVPWD=5.2mmHR=192 There were no obvious abnormalities in the interventricular septum and left ventricular free wall. There were no obvious abnormalities in the structures and valves of the chambers. LA/AO= 14.1/11.8=1.20 Scanning cat in lateral position: 4.6kg 1. B-mode: heart structure deviation|

NOW

胸部 侧位 (1)

1608102

辛巴

微 苏格兰斯利猫

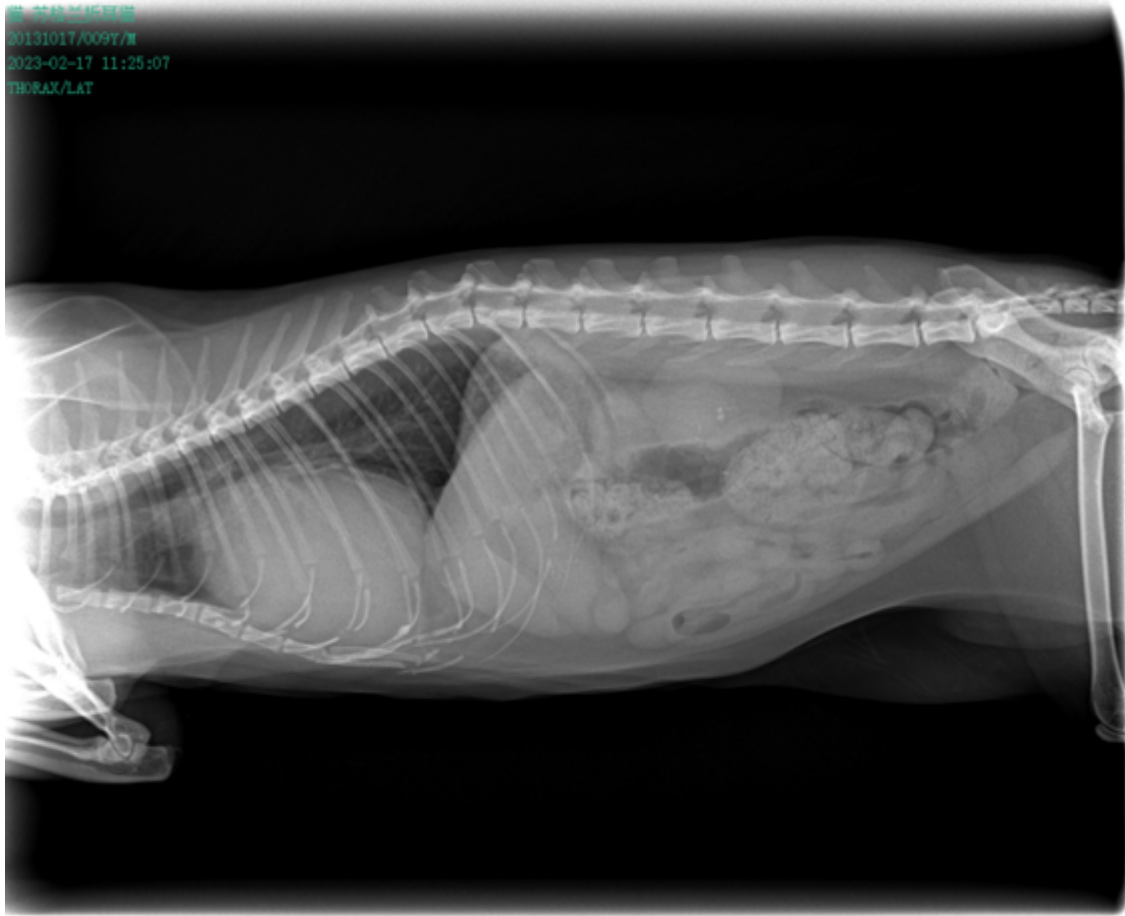20131017/009Y/M

2023-02-17 11:25:07

THORAX/LAT

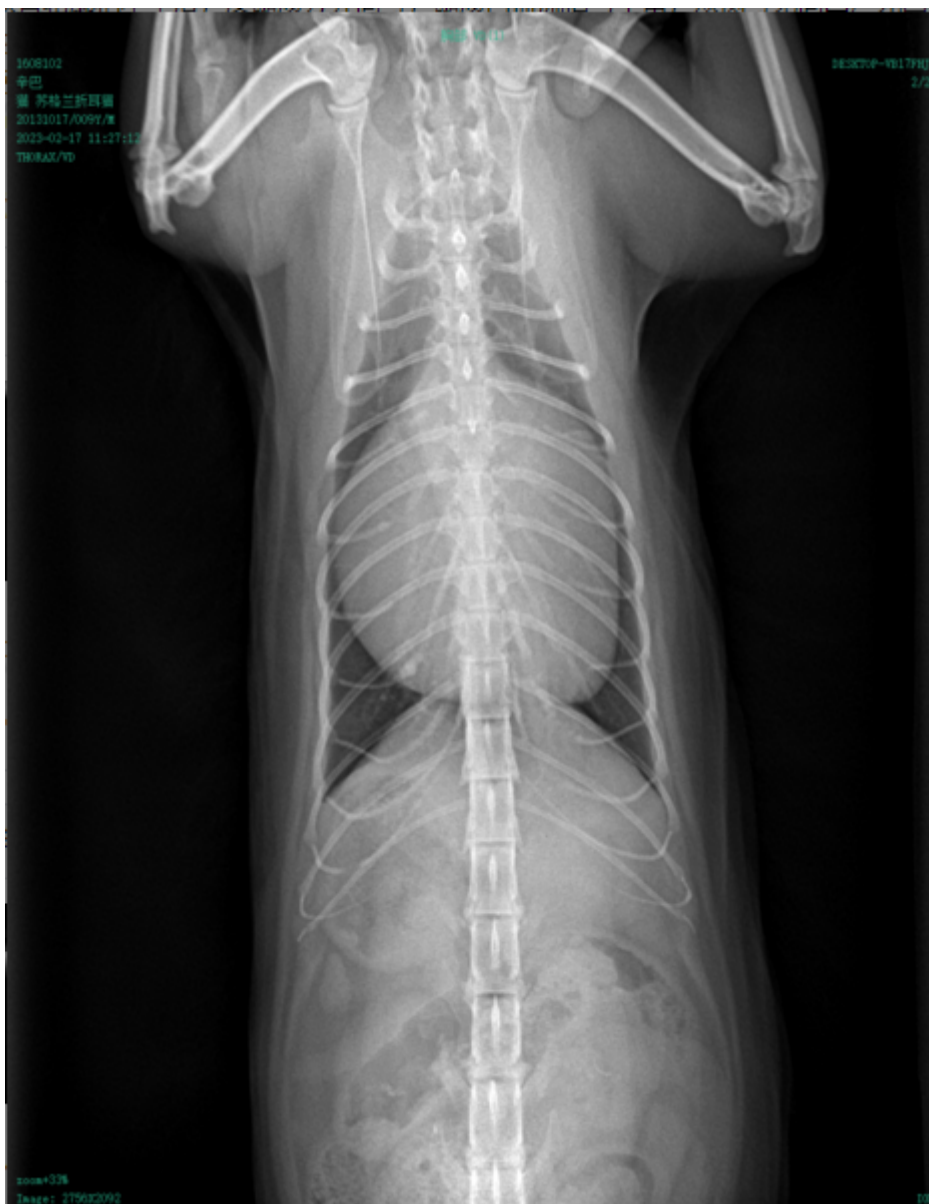DESKTOP-VB17FHJ

1/1



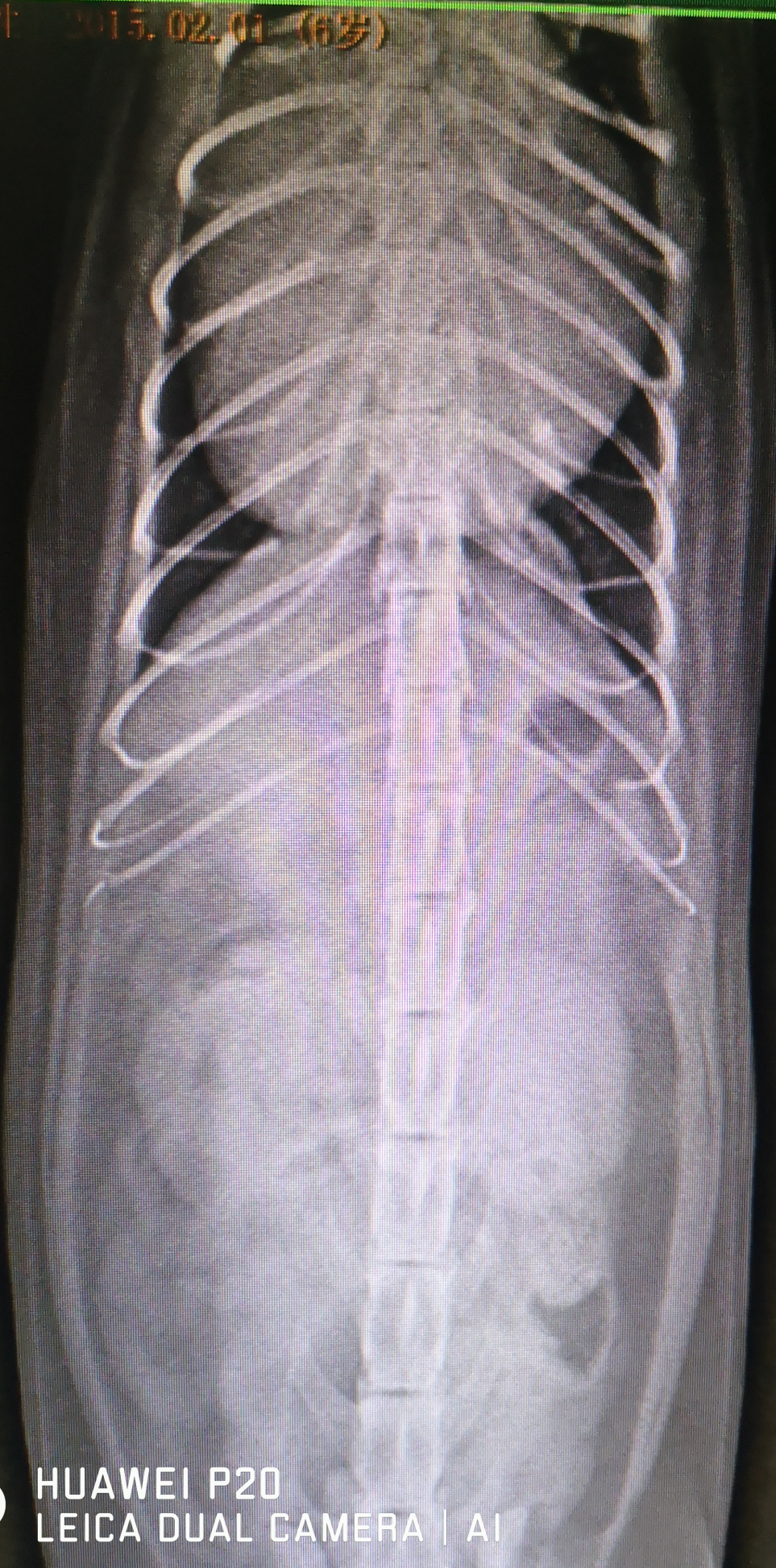
**RIBS BONES BROKEN BUT WE HAVEN'T
SEEN HIM BREAKING IT. WE WORRY
IF ITS A CANCER THAT EATS THE BONE**

NOW



3 YEARS AGO

张 X | 男性 | 2015.02.01 (6岁)



HUAWEI P20
LEICA DUAL CAMERA | AI

3 YEARS AGO

