

Common Features of Esophageal Diseases

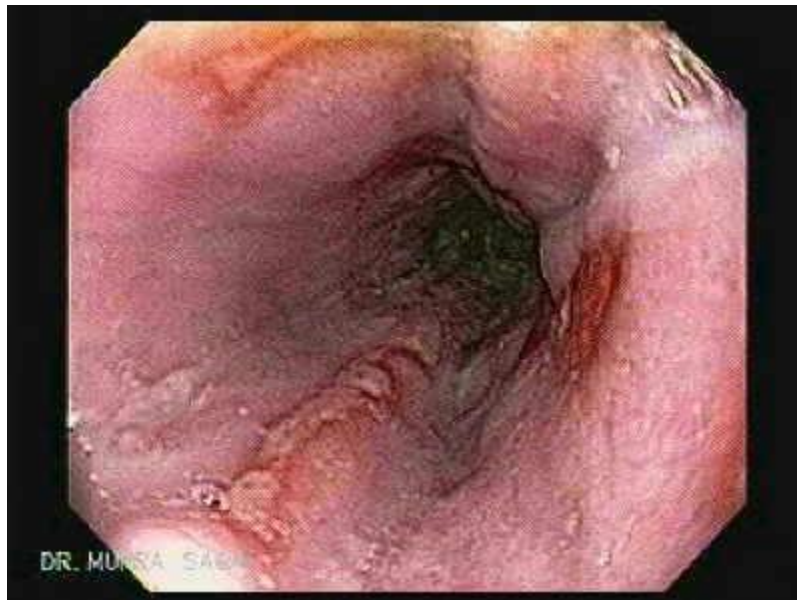★ Common Complications:

1- **Esophagitis** → ulcerations

2- **Bleeding** : usually not severe leading to occult blood in stool ,
melaena & haematemesis.

3- **Respiratory complications.**

3- **Carcinoma** of oesophagus



Esophagitis and esophageal ulceration

★ Common clinical picture :

1- **Dysphagia** : is the main symptom of esophageal diseases .

2- **Odynophagia** (painful dysphagia due to esophagitis)

3- **Regurgitation** which should be differentiated from vomiting.

Disorders of esophagus

Vomiting	Regurgitation
<ul style="list-style-type: none"> ▪ Prodromal nausea & salivation 	<ul style="list-style-type: none"> ▪ No
<ul style="list-style-type: none"> ▪ Retching is common . 	<ul style="list-style-type: none"> ▪ No
<ul style="list-style-type: none"> ▪ Reflex , active, antiperistalsis . 	<ul style="list-style-type: none"> ▪ Passive return of esophageal or gastric contents (reflux esophagitis is a type of regurgitation) .
<ul style="list-style-type: none"> ▪ Occur at any time 	<ul style="list-style-type: none"> ▪ Occur at any time specially on lying flat , bending or leaning forewords and more by night . It is relieved by sitting or standing
<ul style="list-style-type: none"> ▪ Abdominal contractions . 	<ul style="list-style-type: none"> ▪ No
<ul style="list-style-type: none"> ▪ Gastric and intestinal digested contents . 	<ul style="list-style-type: none"> ▪ Usually esophageal undigested contents or gastric contents .
<ul style="list-style-type: none"> ▪ May contain bile 	<ul style="list-style-type: none"> ▪ No
<ul style="list-style-type: none"> ▪ May contain coffee blood or fresh red blood (if massive bleeding) 	<ul style="list-style-type: none"> ▪ May contain mild red blood .
<ul style="list-style-type: none"> ▪ Contents may be acidic or alkaline 	<ul style="list-style-type: none"> ▪ Contents usually alkaline but may be acidic.
<ul style="list-style-type: none"> ▪ No esophageal distension. 	<ul style="list-style-type: none"> ▪ Esophageal distension may be present

4- Halitosis : Bad odour of the breath due to esophagitis & fermentation of retained fluid in the esophagus .

Disorders of esophagus



5- Sever continuous *retrosternal pain due to oesophogitis* .

6- Picture of complications in neglected cases (mention) eg.
pulmonary symptoms as cough , wheezes , pneumonia etc.....

★ **Common investigations :**

- 1- Blood picture : usually show anemia .
- 2- Plain x-ray chest may show pulmonary complications .
- 3- Barium swallow .
- 4- Upper GIT endoscopy .

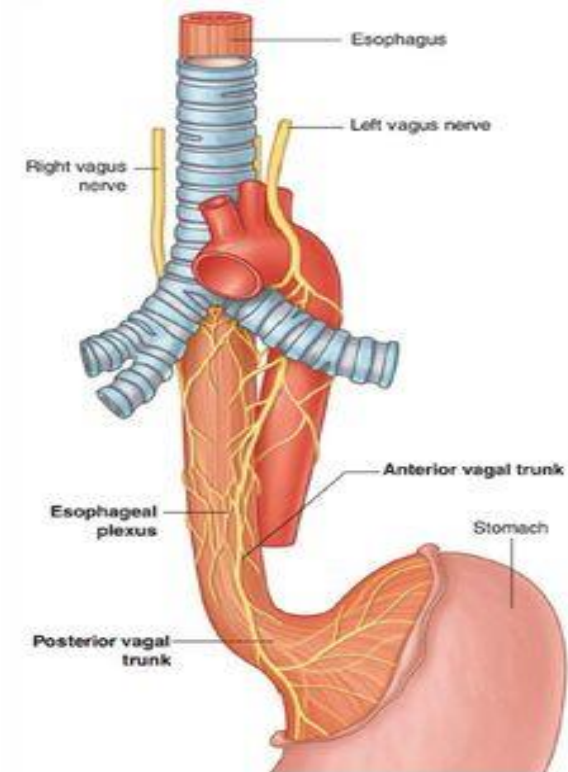


Fig. 3.92 Esophageal plexus.

Disorders of esophagus

