



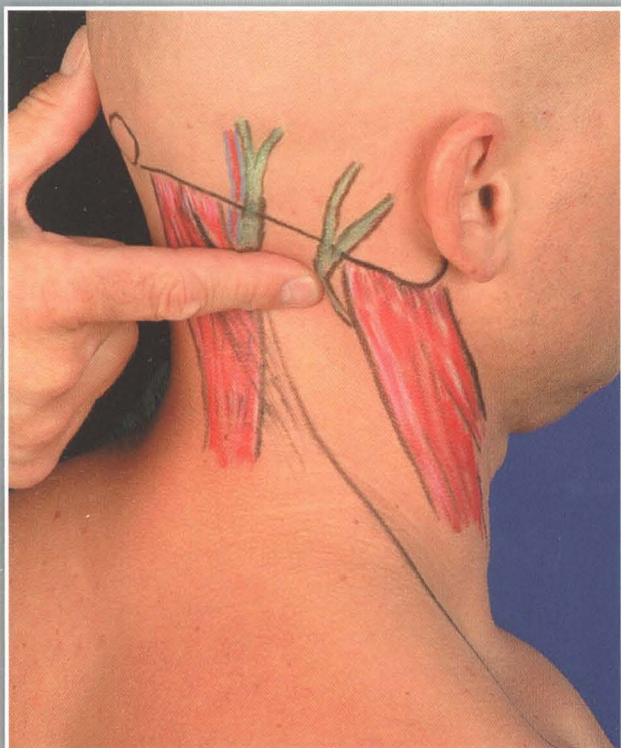
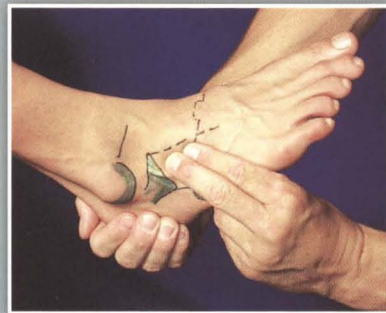
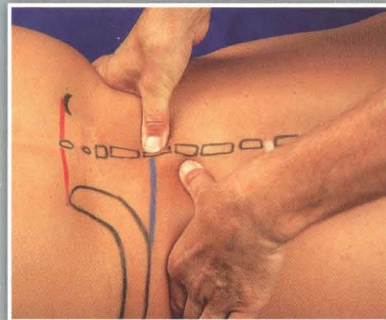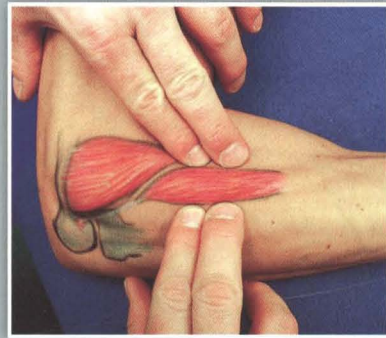
Complementary
Medicine

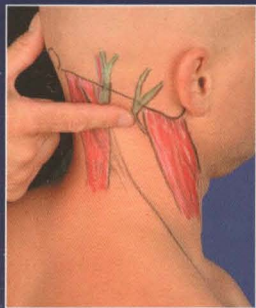
Palpation Techniques

Surface Anatomy for Physical Therapists

Bernhard Reichert

With the collaboration of
Wolfgang Stelzenmueller





Visual guide to hands-on palpation techniques and in vivo anatomy

This lavishly illustrated guide to palpation techniques provides readers with a solid understanding of topographic anatomy using clear, step-by-step descriptions that teach how to first identify, then distinguish between, the various body structures.

Full-color photographs feature models with detailed drawings of muscles, bones, and tendons on their skin, indicating exactly where and how to palpate. Complementary color drawings show the functional significance of each anatomic region.

Features:

- In-depth coverage of the entire body—upper extremities, lower extremities, and the head and trunk—all in one comprehensive volume
- Over 850 full-color photographs and illustrations enhance the text, making it especially useful for the visual learner
- Easy-to-reference text boxes contain tips and tricks, including advice on finger placement, pressure application levels, and more
- Study questions at the end of each chapter aid readers in self-assessment and review of the material

Palpation Techniques: Surface Anatomy for Physical Therapists will enable students and practitioners of physical therapy or osteopathy to develop their anatomic knowledge and optimize patient care.

Bernhard Reichert, M, PT, MT, BSC PT, is Massage Therapist and Physical Therapist, VPT Academy, Fellbach, Germany.

An award-winning international medical and scientific publisher, Thieme has demonstrated its commitment to the highest standard of quality in the state-of-the-art content and presentation of all of its products. Thieme's trademark blue and silver covers have become synonymous with excellence in publishing.

ISBN 978-3-13-146341-8



9 783131 463418

www.thieme.com

THIS PAGE INTENTIONALLY
LEFT BLANK

Palpation Techniques

Surface Anatomy for Physical Therapists

Bernhard Reichert, M, PT, MT, BSC PT

Massage Therapist, Physical Therapist
VPT Academy
Fellbach, Germany

With the collaboration of

Wolfgang Stelzenmueller

Dreieich, Germany

861 illustrations

Thieme
Stuttgart · New York

Library of Congress Cataloging-in-Publication Data

Reichert, Bernhard, 1959-

[Anatomie in vivo. English]

Palpation techniques : surface anatomy for physical therapists / Bernhard Reichert, with contributions by Wolfgang Stelzenmueller.

p. : cm.

ISBN 978-3-13-146341-8 (alk. paper)

1. Palpation 2. Anatomy, Surgical and topographical. I. Stelzenmueller, Wolfgang. II. Title.

[DNLM: 1. Palpation. 2. Body Regions--anatomy & histology. 3. Physical Therapy Modalities. WB 275]

RC76.5.R4513 2010

611'.9--dc22

2010033219

This book is an authorized and revised, merged translation of Volume 1 (2nd ed) and Volume 2 of the German edition published and copyrighted 2005 and 2007 by Georg Thieme Verlag, Stuttgart, Germany. Title of the German edition: Anatomie in vivo (Vol 1: palpieren und verstehen im Bereich der Extremitäten; Vol 2: palpieren und verstehen im Bereich Rumpf und Kopf).

Translator: Michelle Hertrich, Nettetal, Germany

Illustrator: Martin Hoffmann, Thalfingen, Germany

Photos: Oskar Vogl; Benjamin Stollenberg; authors



We wish to thank the leading manufacturer of anatomical teaching aids, 3B Scientific, for their kind support.

Please also see page 398–399 or

www.3bscientific.com.

© 2011 Georg Thieme Verlag,
Rüdigerstrasse 14, 70469 Stuttgart, Germany
<http://www.thieme.de>
Thieme New York, 333 Seventh Avenue,
New York, NY 10001, USA
<http://www.thieme.com>

Cover design: Thieme Publishing Group
Typesetting by Hagedorn Kommunikation, Viernheim,
Germany
Printed in Germany by Offizin Andersen Nexö, Zwenkau

ISBN 978-3-13-146341-8

1 2 3 4 5 6

Important note: Medicine is an ever-changing science undergoing continual development. Research and clinical experience are continually expanding our knowledge, in particular our knowledge of proper treatment and drug therapy. Insofar as this book mentions any dosage or application, readers may rest assured that the authors, editors, and publishers have made every effort to ensure that such references are in accordance with **the state of knowledge at the time of production of the book.**

Nevertheless, this does not involve, imply, or express any guarantee or responsibility on the part of the publishers in respect to any dosage instructions and forms of applications stated in the book. **Every user is requested to examine carefully** the manufacturers' leaflets accompanying each drug and to check, if necessary in consultation with a physician or specialist, whether the dosage schedules mentioned therein or the contraindications stated by the manufacturers differ from the statements made in the present book. Such examination is particularly important with drugs that are either rarely used or have been newly released on the market. Every dosage schedule or every form of application used is entirely at the user's own risk and responsibility. The authors and publishers request every user to report to the publishers any discrepancies or inaccuracies noticed. If errors in this work are found after publication, errata will be posted at www.thieme.com on the product description page.

Some of the product names, patents, and registered designs referred to in this book are in fact registered trademarks or proprietary names even though specific reference to this fact is not always made in the text. Therefore, the appearance of a name without designation as proprietary is not to be construed as a representation by the publisher that it is in the public domain.

This book, including all parts thereof, is legally protected by copyright. Any use, exploitation, or commercialization outside the narrow limits set by copyright legislation, without the publisher's consent, is illegal and liable to prosecution. This applies in particular to photostat reproduction, copying, mimeographing, preparation of microfilms, and electronic data processing and storage.

Foreword to the English Edition

The clinical practice community has been left wanting for a textbook dedicated to the precise execution of in-vivo anatomical examination, and this excellent text emerges in a timely fashion. Healthcare professionals have witnessed an escalation in the need for relevant clinical examinations and the use of manual therapeutic interventions, both of which rely on a thorough understanding and execution of precision in-vivo surface anatomy skills. Because surgical exposure may not be readily available, the clinician must rely on nonsurgical measures for identifying relevant anatomical structures. Thus, surface anatomy skillsets become indispensable for localizing structures and landmarks. This text can serve as a roadmap for locating relevant structures with exactitude. The clear means by which this text instructs the clinician in tactile localization will compliment essential knowledge in structural and functional anatomy.

The authors have organized the approach to identifying structures by both layer and region. This process of organization can guide the clinician to visualizing a particular structure's relative depth and relationship to surrounding structures. Moreover, the text is complete, offering a thorough and methodical approach to all major musculoskeletal areas of the human body. This will assist the clinician in developing a musculoskeletal surface anatomy approach to the *entire* human, allowing for identification of patterns, similarities, and differences between structures in the different regions. Finally, the clinician is cued on how the information can be directly applied to clinical examination, which bridges the gap between knowledge and implementation. When used in accompaniment to a thorough, systematic clinical examination, precise structural localization can help to confirm a

suspicion of that structure's involvement in the patient's condition.

Surface anatomy is essentially manual in nature. Thus, this text can serve as a segue for accurate localization of structures involved in a manual therapeutic intervention. Moreover, because a patient's response to manual therapeutic interventions could be influenced by a clinician's confidence in technique execution, the clinician's thorough knowledge of structural architecture that is accompanied by accurate tactile localization could serve to enhance the patient's response to treatment.

The knowledge and skills gained from this text can provide a foundation for increased clinical confidence, as it can reduce the clinician's guesswork when navigating to a particular structure. The authors offer practical guidance for enhancing the clinician's success with an in-vivo surface anatomy experience. So not only are clinicians instructed on what skills to utilize, they are additionally guided on how to best implement them. This text can join the top ranks of a clinician's library and serve as a bridge between foundational science, clinical knowledge, and practical skills. With these features in mind, the text can support an individual's development and progress as a master manual clinician.

*Phillip S. Sizer Jr., PT, PhD, OCS, FAAOMPT
Professor and Program Director,
ScD Program in Physical Therapy
Director, Clinical Musculoskeletal Research Laboratory,
Center for Rehabilitation Research
School of Allied Health Sciences, Texas Tech University
Health Sciences Center
Lubbock, TX, USA*

Foreword to the German Edition

Our understanding of the anatomy and biomechanics of the musculoskeletal system has increased manifold in recent decades. The enormous expansion of new scientific knowledge certainly represents the general trend in medicine. Perhaps this is also the main reason why today's medical students receive less and less information in more and more specialties. The medical study period is simply too short to keep up with the "explosion" of new medical information and too short to be able to properly and thoroughly absorb all this information during the basic medical training. This unfortunately results in medical universities worldwide paying too little attention to the study of the complicated musculoskeletal system. In the past, students studied the anatomy of the musculoskeletal system over a period of three years. In many faculties, the same material is now being covered in just three weeks! It is no exaggeration to say that the study of anatomy plays an increasingly smaller role in medical studies.

In order to examine and treat our patients' musculoskeletal problems effectively, we must be able to answer at least two fundamental questions: *where* does the pain come *from* (i.e., which part of the body is diseased or injured?) and *what has triggered* the pain? We have to possess detailed knowledge in topographical anatomy to answer the first question when diagnosing. However, this alone is not enough. It is also necessary to be able to apply this knowledge to the benefit of our patients. This requires deep insight into in vivo anatomy (anatomy on living subjects). Do we pay enough attention to our patients as living beings capable of feeling when we apply our structural anatomical knowledge? Are we able to combine **receptive touch** with our knowledge of anatomy to such an extent that we can answer our patient's specific questions and provide clarity about the circumstances surrounding their pain?

It is of great importance that the clinician recognizes and understands what the patient reports about their pain so that the patient feels their complaints are being acknowledged in a discerning manner. Although this is often not always possible, the application of in vivo anatomy can assist us in making the right decisions, even in cases of generalized and sensitized pain.

Perhaps the first rule of medicine should be "to recognize the patient as an individual": the clinician must interpret the patient's physiological symptoms and complaints as being unique and personal.

Expert knowledge of in vivo anatomy plays a central role when we want to differentiate between structures and identify at which level and in which layer the pain is the strongest. It is only then that we can address the second question: *why* is the patient suffering?

To give an example: in cases of lumbo-pelvic pain, it is important to find out whether pain is coming from (*from where*) the gluteus maximus (large muscle of the buttocks), the multifidus muscle (multiply divided muscle in the back), the gluteus medius (middle muscle of the buttocks), or the long posterior ligament of the sacroiliac joint. These structures are located close to each other when the area around the posterior superior iliac spine is being palpated. It is only after structures have been differentiated in detail and the most painful structures have been identified that we can begin to search for the source of this specific pain.

As author of one of the first detailed books on in vivo anatomy in the musculoskeletal system, I am glad to see that a real evolution has been set into motion in this field of knowledge. This book not only represents a large step in the right direction compared with the first edition; most importantly, it also presents in great detail the alternatives available to expand our knowledge of the "anatomy on the living body" to the benefit of our patients.

It is my sincere hope that this book will be accepted as an important tool for answering the questions of *from where* and *why* and contribute to the better care of our patients for not only students and clinicians in the fields of physical therapy, osteopathy, and manual therapy, but also for medical students and physicians. This book is exceptionally well-suited for deepening our understanding of human anatomy. Knowledge of in vitro anatomy (anatomy outside the living organism) can only be applied if we combine it effectively with **hands-on in vivo touch**. This requires extensive practice, intuition, and "**listening touch**." An improvement in skills on living subjects will undoubtedly bring about improvements in diagnosis and clinical practice and hence contribute to better patient care.

*Prof. Dr. Andry Vleeming, PhD, PT
Chairman, World Congress on Low Back and Pelvic Pain
Founder of the Spine and Joint Centre
Rotterdam, The Netherlands*

Preface

The aim of this book is to make the introduction to in vivo anatomy (anatomy on living subjects) easier and to help standardize palpatory techniques.

I am very pleased with how well this English edition has turned out. The original German version of the book invoked an interest for palpation in many of its European readers. I hope the same holds true for readers of the English edition.

Palpation is learnt by palpating. It cannot be learnt by reading. It is for this reason that this book claims to be an easy-to-understand guide to the independent study of in vivo anatomy.

We achieve this by starting on the surface before moving deeper, layer by layer, toward the more deeply situated structures. The interest in neighboring structures in the musculoskeletal system understandably grows as we become more specialized and improve our knowledge in biomechanics and pathology. When this happens, I am under the impression that we “forget” during palpation to view the skin as a signal organ and the muscles as stabilizers and mobilizers. Including the skin and muscles was therefore of particular concern to me.

The level of difficulty gradually increases in the book. The basic features of palpation are practiced at the start and the specific tests and complicated maneuvers are found at the end. This book is therefore suitable for different target audiences. The beginner can start with the easy material and gradually work through to the more difficult

subject matter. The experienced therapist or physician has a reference book to selectively search for specific structures. Teachers involved in therapist training can extract several aspects to round off classes in assessment or anatomy.

Cross-references are continually used to link the individual sections and improve navigation between the chapters. In the end, the connection between theory and practice should be successful. Quite a large section of the book involves information on assessment and treatment to clarify how important in vivo anatomy is. The study questions at the end of each chapter should help readers to consciously reflect on certain topics. This book contains only a selection of the palpable structures of interest for the clinical practice. I would be happy to receive suggestions from readers to strengthen and also broaden the repertoire of techniques. I also hope that this book will instigate a discussion on the standardization of anatomy in vivo. With this in mind, the palpatory techniques demonstrated in this book should only be seen as an attempt to standardize both technical procedures and the criteria used to evaluate palpatory results.

The language has been selected so that the facts are presented as accurately as possible while still being easy to read.

Bernhard Reichert

Acknowledgements

I have collected quite a lot of knowledge and skills from previous publications (Hoppenfeld, Winkel, and Vleeming) in this volume in addition to suggestions, tips, and knowledge gained in my long involvement with anatomy and manual therapy.

This book would never have come into being without a large number of people, whom I would like to thank. First of all, I would like to thank the team at Thieme responsible for the original German edition of this book. The professionalism of the publisher can also be judged by the quality of the editor and the graphic artist. Martin Hoffmann's graphics captivate with their preciseness and three-dimensional brilliance. He was able to find a good way to demonstrate precise anatomical details while still highlighting particular relationships.

The Thieme Publishers team responsible for the completion of this English edition was just as professional. This book has been able to reach the English-speaking public thanks to the initiative of Angelika-M. Findgott. Anne Lamparter coordinated the team at all stages of the publishing process and helped and supported me innumerable times.

My next thanks go to the photographers Benjamin Stollenberg and Oskar Vogl, whose enthusiasm and expertise made the photo shoots pleasant and effective.

I would also like to sincerely thank Mr. Wolfgang Stelzenmueller for his chapter on the palpation of the skull and the jaw. His extensive specialist knowledge and amazing illustrations enhance this book tremendously.

Thank you to Sabine Reichel, who advised me in the details of the anatomy of the skull, and Christiane Pauling, who saw me through the correct procedure for the respiratory therapy techniques. All of the colleagues in the

VPT's (Verband Physikalische Therapie—Physical Therapy Association) manual therapy group, starting with Omer Matthijs, Didi van Paridon-Edauw, and Sabine Reichel, are responsible for my continuing professional development. Notes in the text regarding personal correspondence from the IAOM group (International Academy of Orthopedic Medicine) reflect the IAOM group's knowledge gained from years of literature studies and clinical experience.

A further great role model is Professor Andry Vleeming. I was permitted to observe his lectures and courses over many years. Professor Vleeming and his study group at the Spine and Joint Centers in Rotterdam, the Netherlands, are responsible for the enthusiasm associated with linking topographical, functional, pathologically oriented, and palpatory anatomy.

A great deal of thanks goes to my model Andreas Hofacker for the good teamwork and friendship. He understood how to prepare his amazing body perfectly for the photo shoots. His cheerful nature and his excellent specialist knowledge have contributed to the successful photographs.

The biggest thanks go to my family. I tested their patience more than once with my many hours of writing spread over approximately three years. My wife, Ulrike, and my children, Yvonne and Svenja, have followed the development of this book with their patience and love. My wife is also my biggest and most important critic: "You have to get to the point quickly and accurately." I hope that I have done it well.

Bernhard Reichert

The Author



Bernhard Reichert was born in 1959 in Düsseldorf, Germany. After completing secondary school, he gained his first professional qualifications, became self-employed, and later relocated to Schwieberdingen in the German district of Ludwigsburg with his family.

Education

- Massage and balneotherapy certification
- Physical therapy certification and Bachelor of Science in Physiotherapy
- Business administration in educational management
- Currently studying for his Master of Science in Physiotherapy

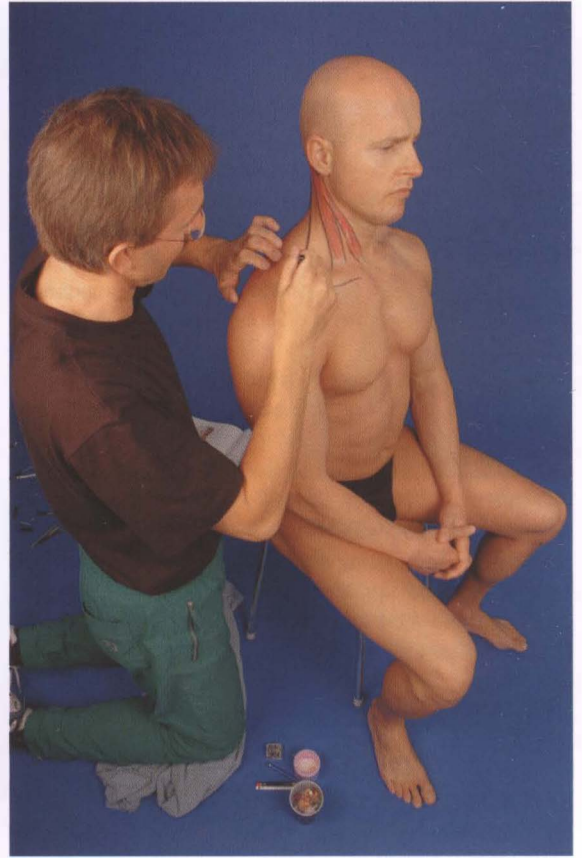
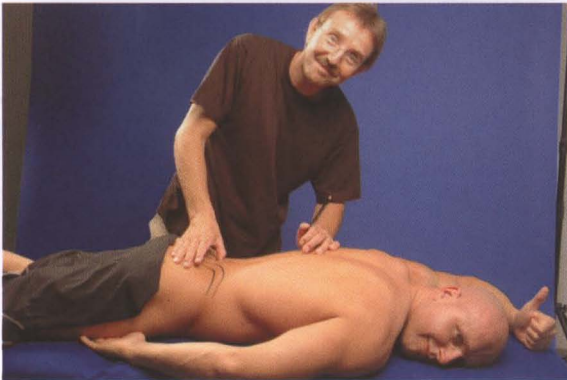
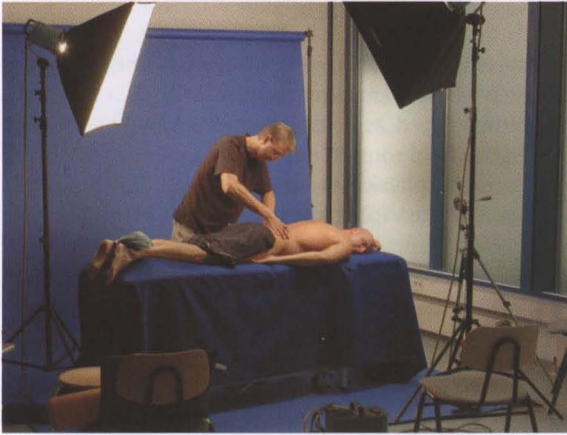
Continuing Education (Selection)

- Manual therapy
- Orthopedic medicine (Cyriax)
- PNF
- Sports physical therapy, medical rehabilitation
- Mobilization of neural structures
- Anatomy on specimens

Professional Experience

- Self-employed in his own massage, balneotherapy, and electrotherapy practice from 1984–95
- Self-employed as consultant and owner of the firm “PhysioTrain consult” since 1996
- Teacher of physical therapy and head of the massage course at the VPT Academy Fellbach, Germany
- Course instructor for anatomy and manual therapy
- Lecturer at congresses and symposiums; author of several articles, book reviews, and reference books
- Certified manual therapy instructor
- Lecturer at the International Academy of Orthopedic Medicine (IAOM Europe)
- Freelance lecturer in scientific methodology, Dresden International University, Germany

Work Behind the Scenes



Contents

1 Basic Principles	3	Required Basic Anatomical and Biomechanical Knowledge	19
Why Do Clinicians Need In Vivo Anatomy?	3	General Orientation—Posterior	20
What Is Understood by In Vivo Anatomy in this Book?	3	Summary of the Palpatory Process	20
Where Can In Vivo Anatomy Be Used?	3	Starting Position	21
Component in the Assessment of a Joint or Section of the Spine	3	Topographical Position of the Scapula	21
Orientation before the Application of Special Assessment and Treatment Techniques	4	Medial Border of the Scapula	21
Basis for the Local Treatment of Tendons, Bursae, etc.	4	Local Palpation—Posterior	21
Clinical Relevance	4	Summary of the Palpatory Process	22
Characteristics of Palpation	4	Starting Position	22
When Is In Vivo Anatomy Applied?	5	Inferior Angle of the Scapula	22
Prerequisites	5	Medial Border of the Scapula	23
Anatomical Background	5	Superior Angle of the Scapula	23
Precise Palpation as a Process	5	Spine of the Scapula—Inferior Edge	23
Define Objectives	5	Acromial Angle	24
Preparation	5	Acromion	24
Localization	6	Spine of the Scapula—Superior Edge	25
The Reliable Result	6	Supraspinatus—Muscle Belly	26
Experience	6	Infraspinatus—Tendon and Insertion	27
Central Aspects of the Procedure	6	Local Palpation—Lateral	28
Pressure Applied during Palpation	6	Summary of the Palpatory Process	29
Palpatory Techniques	7	Lateral Edge of the Acromion	29
Palpating the Skin	7	Acromial Spine	29
Palpating Bony Edges	7	AC Joint—Anterior Approach	30
Palpating Bony Prominences	8	AC Joint—Posterior Approach	30
Palpating Muscle Bellies	8	Acromioclavicular Joint	31
Palpating the Edge of Muscles	9	Tips for Assessment and Treatment	33
Palpating Tendons	10	General Orientation—Anterior	34
Palpating Ligaments	10	Starting Position	34
Palpating Capsules	11	Supraclavicular and Infraclavicular Fossa	34
Palpating Bursae	11	Local Palpation—Anterior	35
Palpating Neural Structures	12	Summary of the Palpatory Process	35
Palpating Blood Vessels (Arteries)	13	Starting Position	35
Palpation Aids	13	Sternocleidomastoid	35
Guiding Structures	13	Medial End of the Clavicle	35
Connecting Lines	14	Sternoclavicular Joint Space	36
Supporting Measures for Confirming a Palpation	14	Infraclavicular Fossa	36
Marking Structures	15	Coracoid Process	36
Starting Positions for Practice (Practice SPs)	15	Tips for Assessment and Treatment	37
Study Questions	16	Local Palpation—Anterolateral	37
2 Shoulder Complex	19	Summary of the Palpatory Process	37
Significance and Function of the Shoulder Region	19	Starting Position	37
Common Applications for Treatment in this Region	19	Borders of the Coracoid Process	38
		Subscapularis Tendon	39
		Lesser Tubercle of the Humerus	39
		Intertubercular Sulcus and the Greater Tubercle of the Humerus	40
		Glenoid Cavity	41
		Supraspinatus—Insertion	42
		Study Questions	44

3 Elbow Complex	47	General Orientation on the Posterior Humerus	65
Significance and Function of the Elbow Complex ..	47	Summary of the Palpatory Process	66
Common Application for Treatment in this Region	47	Starting Position	66
Required Basic Anatomical and Biomechanical Knowledge	47	Palpating Warmth and Swelling	66
General Orientation—Anterior	49	The Relationship between the Three Bony Elevations	66
Boundaries of the Cubital Fossa	49	Tips for Assessment and Treatment	67
Local Palpation—Anterior	49	Study Questions	68
Summary of the Palpatory Process	49		
Starting Position	50	4 Hand	71
Humerus—Medial Shaft	50	Significance and Function of the Hand	71
Muscle Belly and Tendons of Biceps Brachii	51	Causes of the Diversity of Functions in the Hand	71
Neurovascular Bundle	51	Common Applications for Treatment in this Region	72
Pronator Teres	52	Common Pathological Conditions in the Hand	72
Brachioradialis	53	Required Basic Anatomical and Biomechanical Knowledge	73
Proximal Radioulnar Joint	53	Axial Divisions of the Skeleton of the Hand into Columns and their Clinical Significance	73
Tips for Assessment and Treatment	53	Triangular and Fibrocartilage Complex	74
Local Palpation—Medial	54	Construction of the Carpal Tunnel	74
Summary of the Palpatory Process	54	Extensor Tendons and Their Compartments	75
Starting Position	54	General Orientation—Dorsal	76
Humerus—Medial Border	54	Summary of the Palpatory Process	76
Ulnar Nerve	54	Starting Position	77
Groove for the Ulnar Nerve and the Cubital Tunnel ..	55	Proximal Boundary of the Carpus (Radiocarpal Joint Line)	77
Medial Intermuscular Septum of the Arm	55	Alignment of the Radiocarpal Joint Space	78
Medial Supracondylar Ridge and Medial Epicondyle of the Humerus	55	Distal Boundary of the Carpus (Carpometacarpal Joint Line)	78
Sites of Insertion at the Medial Epicondyle (Common Head, Pronator Teres)	56	Tips for Assessment and Treatment	79
Differentiation in the Presence of Epicondylitis	57	Local Palpation of the Dorsal Soft Tissues	79
Quick Orientation on the Forearm	58	Summary of the Palpatory Process	80
Tips for Assessment and Treatment	59	Starting Position	80
Local Palpation—Lateral	59	Radial Fossa (Anatomical Snuffbox)	80
Summary of the Palpatory Process	59	Extensor Tendons and Their Compartments	80
Starting Position	59	Radial Nerve, Cephalic Vein, and Radial Artery	82
Localization of the Most Important Osseous Structures	59	Tips for Assessment and Treatment	83
Humerus—Lateral Border	60	Local Palpation of the Dorsal Aspect of the Carpal Bones	84
Lateral Intermuscular Septum	60	Summary of the Palpatory Process	84
Lateral Supracondylar Ridge	60	Starting Position	84
Lateral Epicondyle and the Lateral Condyle of the Humerus	60	Carpal Bones in the Radial Column	85
Humeroradial Joint Space and Muscle Belly of the Anconeus	61	Bones in the Anatomical Snuffbox	85
Head and Neck of the Radius	61	Tips for Assessment and Treatment	86
Locating the Muscles and Their Insertions	62	Carpal Bones in the Central Column	87
Localization of the Lateral Insertion Tendinopathies	62	Boundary between the Lunate and Scaphoid	88
Brachioradialis and the Radial Nerve	62	Tips for Assessment and Treatment	88
Extensor Carpi Radialis Longus	63	Carpal Bones in the Ulnar Column	88
Extensor Carpi Radialis Brevis	63	Tips for Assessment and Treatment	90
Extensor Digitorum	64	General Orientation—Palmar	90
Extensor Carpi Ulnaris	64	Summary of the Palpatory Process	90
Tips for Assessment and Treatment—Local Palpatory Techniques for Type II Tennis Elbow	65	Starting Position	90
		Edge of the Radius	91

Local Palpation of the Palmar Soft Tissues 91

Summary of the Palpatory Process 91

Starting Position 92

Flexor Carpi Radialis and Tubercle of Scaphoid 92

Radial Artery 92

Flexor Pollicis Longus 92

Summary of all Radial Structures 93

Palmaris Longus 93

Flexor Digitorum Superficialis 93

Flexor Carpi Ulnaris and Pisiform 93

Ulnar Artery and Nerve 93

Summary of All Ulnar Structures 94

Tips for Assessment and Treatment 94

Local Palpation of the Palmar Aspect of the

Carpal Bones 94

Summary of the Palpatory Process 94

Starting Position 95

Pisiform 95

Hook of Hamate 96

Scaphoid 96

Trapezium 97

Transverse Carpal Ligament and the Carpal Tunnel 97

Median Nerve, Position 98

Tips for Assessment and Treatment 98

Study Questions 100

5 Hip and Groin Region 103

Significance and Function of the Hip and

Groin Region 103

Common Applications for Treatment in this

Region 103

Common Pathological Conditions in the Hip 103

Required Basic Anatomical and Biomechanical

Knowledge 103

Bone Anatomy 104

Femoral Neck Anteversion Angle 104

Relevant Anterior Soft Tissues 105

Relevant Posterior Soft Tissues 106

Local Palpation—Posterior 106

Summary of the Palpatory Process 106

Starting Position 106

Greater Trochanter 106

Femoral Neck Anteversion Angle, Measurement 107

Ischial Tuberosity 108

Hamstrings 108

Tips for Assessment and Treatment 109

Local Palpation—Anterior 109

Summary of the Palpatory Process 110

Starting Position 110

Lateral Femoral Triangle 110

Sartorius 110

Tensor Fasciae Latae 111

Rectus Femoris 112

Medial Femoral Triangle 113

Sartorius 113

Adductor Longus 113

Inguinal Ligament 113

Iliopsoas, Iliopectineal Bursa 114

Femoral Nerve, Artery, and Vein 114

Proximal Insertion of the Pectineus 115

Proximal Insertion of the Adductor Longus 115

Gracilis 116

Tips for Assessment and Treatment 116

Study Questions 117

6 Knee Joint 121

Significance and Function of the Knee Joint 121

Common Applications for Treatment in this

Region 122

A Selection of Possible Symptoms 122

Common Assessment and Treatment Techniques 122

Required Basic Anatomical and Biomechanical

Knowledge 122

Construction of the Femorotibial Joint 122

Construction of the Patellofemoral Joint 123

Palpating Edema and Increase in Temperature 123

Summary of the Palpatory Process 123

Starting Position 124

Large Effusion 124

Medium-sized Effusion 124

Minimal Effusion 124

Palpating an Increase in Temperature 125

Local Palpation—Anterior 125

Summary of the Palpatory Process 125

Starting Position 125

Base of the Patella 127

Edges of the Patella 127

Apex of the Patella 127

Patellar Ligament, Differentiation 128

Tibial Tuberosity 128

Tips for Assessment and Treatment 129

Local Palpation—Medial 130

Summary of the Palpatory Process 130

Starting Position 130

Boundaries of the Joint Space 131

Medial Epicondyle of the Femur 132

Adductor Tubercle and the Tendon of Adductor
Magnus 132

Saphenous Nerve 133

Medial Collateral Ligament 133

Pes Anserinus Muscle Group 135

Tips for Assessment and Treatment 135

Local Palpation—Lateral 137

Summary of the Palpatory Process 137

Starting Position 138

Boundaries of the Joint Space 138

Iliotibial Tract 139

Gerdy Tubercle 140

Lateral Epicondyle of the Femur 141

Head of the Fibula 141

Lateral Collateral Ligament 141

Biceps Femoris 142

Common Peroneal Nerve	142	Palpation of the Posterior Foot	175
Tips for Assessment and Treatment	143	Summary of the Palpatory Process	175
Local Palpation—Posterior	144	Starting Position	175
Summary of the Palpatory Process	144	Borders of the Achilles Tendon	175
Starting Position	144	Insertion of the Triceps Surae	176
Neural Structures in the Popliteal Fossa	145	Palpation of the Tendon	177
Biceps Femoris	146	Study Questions	179
Pes Anserinus Muscle Group	146		
Tips for Assessment and Treatment	147	8 Soft Tissues	183
Study Questions	148	Significance and Function of Soft Tissues	183
		Common Applications for Treatment	183
7 Foot	151	Required Basic Anatomical and Biomechanical Knowledge	183
Significance and Function of the Foot	151	Summary of the Palpatory Process	184
Function	151	Extent of the Palpation	184
Special Characteristics of the Bony Construction	151	Criteria for Palpation	184
Special Biomechanical Characteristics	151	Method and Techniques of the Palpatory Process	185
Common Symptoms in the Foot	152	Starting Position	186
Required Basic Anatomical and Biomechanical Knowledge	152	Difficult and Alternative Starting Positions	186
Palpating the Medial Border of the Foot	154	Neutral Starting Position: Sitting	187
Summary of the Palpatory Process	154	Neutral Starting Position: Side-lying	187
Starting Position	154	Palpation Techniques	187
Medial Malleolus	154	Palpating the Surface of the Skin	188
Sustentaculum Tali	155	Palpating the Quality of the Skin (Turgor)	188
Neck of the Talus	155	Palpating the Consistency of Muscle (Assessment of Muscle Tension)	189
Posterior Process of the Talus (Medial Tubercle)	156	Tips for Assessment and Treatment	191
Tendon of Tibialis Posterior	156	Differentiating between Tissues	191
Navicular Tuberosity	157	Interpreting the Findings of Skin Surface Palpation	192
Position of the Medial Ligaments	157	Interpreting the Skin Consistency (Turgor) Palpation Findings	192
Tendon of the Flexor Digitorum Longus	158	Interpreting the Muscle Consistency (Tension) Palpation Findings	192
Tendon of the Flexor Hallucis Longus	158	Examples of Treatment	193
Tibial Artery and Tibial Nerve	158	Lumbar Functional Massage in the Prone Position	193
Tendon of the Tibialis Anterior	159	Lumbar Functional Massage in Side-lying	194
Joint Spaces on the Medial Border of the Foot	159	Functional Massage of the Trapezius in Side-lying	196
Tips for Assessment and Treatment	161	Functional Massage of the Trapezius in the Supine Position	198
Palpating the Lateral Border of the Foot	162	Study Questions	199
Summary of the Palpatory Process	163		
Starting Position	163	9 Posterior Pelvis	203
Lateral Malleolus	163	Significance and Function of the Pelvic Region	203
Peroneal Trochlea	163	Common Applications for Treatment in this Region	203
Base of the Fifth Metatarsal	164	Required Basic Anatomical and Biomechanical Knowledge	205
Peroneus Longus and Brevis	164	Gender-based Differences	206
Calcaneocuboid Joint	165	Coxal Bone	207
Fourth/fifth Metatarsal—Cuboid Joint Space	166	Sacrum	207
Dimensions of the Cuboid	167	The Pelvic Ligaments	209
Position of the Lateral Ligaments	167	The Sacroiliac Joint	210
Anterior Tibiofibular Ligament	168	Sacroiliac Joint Biomechanics	211
Tips for Assessment and Treatment	169	Ligament Dynamization in the Sacroiliac Joint	212
Palpating the Dorsum of the Foot	170		
Summary of the Palpatory Process	170		
Starting Position	170		
Joint Space of the Ankle	170		
Neck and Head of the Talus	171		
Blood Vessels on the Dorsum of the Foot	172		
Neural Structures on the Dorsum of the Foot	172		
Tips for Assessment and Treatment	173		

Summary of the Palpatory Process 213

Palpatory Techniques for Quick Orientation on the Bones 214

Starting Position 214

Iliac Crests 214

Greater Trochanter 215

Sacrum 216

Ischial Tuberosity 217

Palpatory Procedure for Quick Orientation on the Muscles 217

Starting Position 217

Gluteus Maximus 217

Gluteus Medius 220

Iliotibial Tract 220

Local Palpation Techniques 221

Summary of the Palpatory Procedure 221

Starting Position 221

Ilium—Iliac Crest 221

Ilium—Posterior Superior Iliac Spine 222

Sacrum—S2 Spinous Process 224

Sacrum—Median Sacral Crest 225

Sacrum—Insertion of the Multifidus 225

Sacrum—Sacral Hiatus 226

Sacrum—Sacrococcygeal Transition 226

Sacrum—Inferolateral Angles of the Sacrum 227

Sacrotuberous Ligament 228

Long Posterior Sacroiliac Ligament 228

Orienting Projections 229

Posterior Inferior Iliac Spine 229

Sacroiliac Joint Projection 229

Piriformis 230

Sciatic Nerve and the Gluteals 231

Local Palpation of the Pelvic-Trochanter Region 233

Region of the Greater Trochanter and Ischial Tuberosity 233

Trochanteric Bursa 233

Measuring the Femoral Neck Anteversion Angle 234

Insertions on the Trochanter 234

Width of the Gap between the Pelvis and the Greater Trochanter 235

Ischial Tuberosity and Sciatic Bursa 236

Palpating Muscle Activity in the Pelvic Floor Muscles 236

Tips for Assessment and Treatment 237

Study Questions 238

10 Lumbar Spine 241

Significance and Function of the Lumbar Spine 241

Supporting the Weight of the Body 241

Spatial Alignment of the Upper Body 241

The Importance of Stability for Standing and Lifting 241

Movement in the Trunk 241

Development of Energy Needed for Locomotion 242

Junction between the Rigid and Mobile Vertebral Column 242

Common Applications for Treatment in this Region 242

Required Basic Anatomical and Biomechanical Knowledge 243

Anatomical Definitions 243

Shape of the Inferior Lumbar Vertebrae and Intervertebral Disks 244

Detailed Anatomy of Bony Structures 245

Detailed Anatomy of the Ligaments 248

Detailed Anatomy of the Muscles 252

Basic Biomechanical Principles 256

Summary of the Palpatory Process 258

Starting Position 258

Difficult and Alternative Starting Positions 259

Palpation Techniques 259

Orienting Projections 259

Local Bony Palpation 260

Tips for Assessment and Treatment 264

Test for Rotation (Transverse Vertebral Pressure) 264

Posteroanterior Segmental Joint Play 265

Palpation during Flexion and Extension Movements 266

Anteroposterior Segmental Joint Play 266

Local Segmental Mobility Using Coupled Movements 267

Training the Multifidus 268

Study Questions 269

11 Thoracic Spine and Thoracic Cage 273

Significance and Function of the Thoracic Region 273

Protective Function 273

Supportive Function 273

Junction between the Cervical and Lumbar Spines 273

Respiration 273

How Does this Affect Palpation? 274

Common Applications for Treatment in this Region 274

Required Basic Anatomical and Biomechanical Knowledge 275

Functional Divisions in the Thoracic Spine 275

Anatomical Characteristics of the Thoracic Spine 276

Thorax 278

Thoracic Back Muscles 282

Summary of the Palpatory Process 284

Starting Position 284

Difficult and Alternative Starting Positions 284

Posterior Palpation Techniques 284

Cervicothoracic Junction in the Sitting Starting Position 285

Cervicothoracic Junction in the Prone Starting Position 292

Posterior Palpation in the Prone Starting Position 294

Tips for Assessment and Treatment 297

Anterior Palpation Techniques	302	Anterior Palpation Techniques	361
Anterior Palpation in the Sitting Starting Position . .	302	Anatomy	362
Anterior Palpation in the Supine Starting Position .	304	Hyoid Bone—Lamina C3	362
Thoracic Palpation in the Side-lying Starting Position	306	Thyroid Cartilage (Indentation)—Lamina C4	363
Tips for Assessment and Treatment	306	Thyroid Cartilage (Lateral Surfaces)— Lamina C5	363
Study Questions	313	Cricoid Cartilage—Lamina C6	363
12 Cervical Spine	317	Carotid Tubercle	364
Significance and Function of the Cervical Spine . . .	317	Jugular Notch—T2 Spinous Process	365
Common Applications for Treatment in this Region	317	Study Questions	366
Required Basic Anatomical and Biomechanical Knowledge	318	13 Head and Jaw	369
Sections of the Cervical Spine	318	<i>Wolfgang Stelzenmueller</i>	
Anatomy of the Lower Cervical Spine	318	Introduction	369
Lower Cervical Spine Biomechanics	320	Significance and Function of the Temporomandibular Joint	369
Anatomy of the Occiput and the Upper Cervical Spine	322	Common Applications for Treatment in this Region	369
Ligaments of the Cervical Spine	324	Required Basic Anatomical and Biomechanical Knowledge	369
Biomechanics of the Upper Cervical Spine	326	Anatomy of the Bony Skull	370
Posterior Muscles	327	Dividing the Head into Regions	370
Anterior and Lateral Muscles	329	Overview of the Frontal Aspect of the Viscerocranium	370
Nerves and Blood Vessels	331	Palpation of the Bony Skull	370
Summary of the Palpatory Process	332	Frontal Aspect of the Viscerocranium	370
Starting Position	332	Lateral Aspect of the Skull	371
Difficult and Alternative Starting Positions	334	The Jaw—Temporomandibular Joints	371
Posterior Palpation Techniques	334	Required Basic Knowledge of Topography and Morphology	372
Occiput	334	Biomechanics of the Temporomandibular Joint	372
Suboccipital Fossa and Ligamentum Nuchae	335	Assessing Deviations from the Mid-line during Mouth Opening	373
C2 Spinous Process	337	Palpating the Temporomandibular Joints	374
Spinous Processes of the Lower Cervical Spine	338	Summary of the Palpatory Process	374
Facet Joints	339	Assessment of the Clicking Phenomenon during Active Mouth Opening	375
Muscles, Suboccipital Nerves, and Blood Vessels . .	342	Palpatory Examination of the Jaw Muscles	375
Tips for Assessment and Treatment	346	Summary of the Palpatory Process	375
Test for the Alar Ligaments	347	Masseter	376
Identifying the Level of Chronically Irritated Intervertebral Disks	349	Medial Pterygoid Muscle	377
Functional Massage	349	Lateral Pterygoid Muscle	378
Lateral Palpation Techniques	350	Temporalis	380
Angle of the Mandible	351	Anterior and Posterior Bellies of the Digastric	382
C1 Transverse Process	352	Study Questions	385
C2 and C3 Transverse Processes	353	Bibliography	387
Boundaries of the Posterior Triangle of the Neck . .	353	Index	391
Occipital Triangle of the Neck	357		
Supraclavicular Triangle of the Neck	358		
Tips for Assessment	360		

An anatomical model of a human head and neck, shown in profile. Two hands are positioned to palpate the face and neck. One hand is on the forehead, and the other is on the neck. The model is white and set against a light green background.

1 Basic Principles

Why Do Clinicians Need In Vivo Anatomy? ... 3

What Is Understood by In Vivo Anatomy in this Book? ... 3

Where Can In Vivo Anatomy Be Used? ... 3

Clinical Relevance ... 4

Characteristics of Palpation ... 4

When Is In Vivo Anatomy Applied? ... 5

Prerequisites ... 5

Palpatory Techniques ... 7

Palpation Aids ... 13

Study Questions ... 16

THIS PAGE INTENTIONALLY
LEFT BLANK

1 Basic Principles

“You must be relaxed to have a good tactile sense.”
(A. Vleeming, Berlin, 2003)

Why Do Clinicians Need In Vivo Anatomy?

The need to locate anatomical features on living subjects for the purpose of assessment and treatment has existed since the beginning of professional training for massage therapists, physical therapists, and physicians.

In medical and health care training programs, information on the position, appearance, and function of musculoskeletal structures is mostly communicated verbally with the support of two-dimensional illustrations.

Due to the enormous flood of information, students of anatomy quickly find study material dry and abstract. Adept didactic training demonstrates the functional importance of a specific structure within a kinematic complex or a complicated motion sequence. Using a large number of illustrations, it also conveys an approximate three-dimensional idea of that structure.

This, however, exhausts the normal amount of material and time available in health care training.

Students are often unable to recognize anatomical features on specimens, for example, when they visit a pathological institute during basic professional training or continuing education courses. It is likewise rare that theoretical knowledge is successfully transferred onto living bodies.

In vivo anatomy (anatomy on living subjects) becomes a part of professional training that is mentioned in passing; a coincidence during the assessment and treatment of patients; the object of troublesome self-learning; and the content of expensive continuing education courses.

Therefore, it is highly likely that important anatomical features cannot be located; thus the error rate in local treatment is inevitably very high. This is something that neither physicians nor therapists can really afford.

What Is Understood by In Vivo Anatomy in this Book?

This book deals with both clinically relevant structures in the musculoskeletal system and accessible conductive pathways (blood vessels and peripheral nerves). It uses precise palpation to systematically transfer topographical anatomical knowledge onto living bodies. Therapists should be provided with a logical system to locate relevant structures quickly and reliably. This “toolbox” of techniques not only includes the actual palpation; it also

gives therapists hints on what to expect when searching for a structure and the difficulties they may encounter.

This is not about reinventing palpatory techniques, but about the clarification of procedures and the detailed documentation of techniques in words and pictures. The substantial number of illustrations allows therapists to monitor their execution of the technique. The descriptions allow even visually impaired clinicians to reliably locate each structure after hearing the text.

Other authors who have dealt with in vivo anatomy incorporate:

- Surface topography (dividing the body into different regions).
- Anthropometric methods (e.g., measurements of length and circumference).
- General and local observation of regions of the body and structures.

These aspects have been deliberately left out of this book, and readers should understand the term “in vivo anatomy” as a system used for palpation only.

Where Can In Vivo Anatomy Be Used?

The precise palpation of structures in the musculoskeletal system is used in three important areas:

- As a component in the assessment of a joint or section of the spine.
- For orientation before the application of special assessment and treatment techniques (e.g., tests of joint play, palpation of blood vessels).
- As the basis for local treatment of tendons, bursae, etc. (e.g., electrotherapy or manual transverse friction).

Component in the Assessment of a Joint or Section of the Spine

The established procedure used by massage therapists and physical therapists to assess the joints or the spine involves the following routine components:

1. General observation.
2. Subjective assessment—subjective symptoms.
3. Local observation.
4. Palpating for warmth and swelling before the assessment of function.
5. Assessment of function—objective symptoms (active and passive movements, and movements against resistance).

6. Palpation following the assessment of function (increase in temperature, swelling, **detailed palpation**).
7. If required, additional tests such as the assessment of muscle function, tests of joint play, the measurement of circumference, tests of stability, additional provocative tests, differentiation tests, etc.

One of the aims of assessment is to identify the affected structure by applying a specific test to provoke the patient's current symptoms. The accuracy of tests and the interpretation of their findings are quite refined nowadays; nevertheless, it is not always possible to differentiate a painful tendon from a group of synergetic muscles, for example.

Often, the possible causes of pain in a structure are spread over only a few centimeters. For example, in one muscle, the cause could be localized at the site of insertion, the tendon, or the junction between the muscle and the tendon. Only provocative precise palpation is of help in these cases.

Orientation before the Application of Special Assessment and Treatment Techniques

Certain assessment and treatment techniques require therapists to first orient themselves on local structures. For example, initial palpation is required to assist the test of joint play at the articulation formed by the talus and the navicular bone. Accurate palpation locates the joint space, indicating the position of the articulating surfaces and the direction of the glide to be used in the test. Manual therapy tests of joint play obtain the required reliability only when palpation is used for orientation.

Basis for the Local Treatment of Tendons, Bursae, etc.

Disorders of the musculoskeletal soft tissue usually appear in very localized areas. Only large traumas or inflammation spread over larger areas. Physical therapy interventions for the treatment of soft-tissue conditions also include local, thermic, electrotherapeutic, and mechanical interventions. Local application of these treatments can only be effective if applied precisely to the affected structure.

Accurate localization of an affected site is ensured only through the experienced and reliable use of palpatory techniques.

Clinical Relevance

In vivo anatomy, in the form of precise palpation (**Fig. 1.1**), is an important mainstay for local assessment and treatment. The therapeutic content is clarified in several parts of the book:

- The introduction to each chapter covers the pathological conditions frequently observed in the area of the specific joint.
- In several parts of the text, it is pointed out that the palpatory techniques used to search for a structure are simultaneously the techniques used for treatment.
- Each chapter discussing a joint region concludes with details and illustrations of manual treatment in that region. This mostly involves Cyriax transverse frictions or manual therapy tests of joint play.

Characteristics of Palpation

A focal point of in vivo anatomy is the allocation of a structure to a specific segment, that is, the identification of a structure's exact level and position. The palpatory process begins with the normal topography of structures and transfers this knowledge onto the situation seen in the living body.

The anatomical images used for training and further education are often drawings demonstrating an idealistic norm. These drawings breach a basic principle of anatomy: variation (Aland and Kippers, 2005). The concept of the anatomical norm cannot be standardized. Rather, it has to include inter-individual (between two people) and intra-individual (left–right) variations in position and shape. Old anatomy books teach us about possible variations in certain topographical and morphological properties, something that modern anatomy books often lack. For example, the classic anatomy book by Lanz and Wachsmuth *Praktische Anatomie* (2004a), describes the percentage of the population who have differently shaped or nonexistent structures; for example in 5%–20% of the population the lumbar spine does not possess a fifth lumbar vertebra (depending on which anatomical study is cited). Töndury (1968, in Lanz and Wachsmuth 2004a, p. 23) wrote about the abundance of variation in all spinal section boundaries: “Only approximately 40% of all people have their boundaries [of the sections of the spine] in the normal location.”

What should we do when our confidence in topographical orientation—the knowledge gained from our training—disappears when coming across a variation? First of all, it is important to keep an open mind and be prepared to accept anatomical anomalies when palpating. Experience in palpating and faith in anatomical facts found in every individual take on an even greater significance. Certain structures remain constant in position and shape and

can be identified without a large degree of variation: for example, the iliac crests, the scapula, the sternum, and the 1st–10th ribs.

In comparison, other structures are formed differently between individuals: for example, the spinous process, 11th and 12th ribs, and the external occipital protuberance. Experience is necessary to recognize these variations.

The less confident you are using concrete structural details for orientation, the more helpful technical tricks, guiding structures, or drawings become in confirming that the correct structure has been palpated.

Whatever the case may be, you should not give up if you are unable to palpate a structure immediately and with confidence.

When Is In Vivo Anatomy Applied?

The precise palpation of structures is used in physical therapy assessment and treatment of, for example, the vertebral column segments:

- Physical therapy assessment:
 - defining the area to be treated.
 - confirming the presumed location.
 - examining the consistency of skin and muscles.
 - the provocation of local segmental parts (e.g., facet joint).
 - the assessment of segmental mobility.
 - examining the temporomandibular joint.
- Basic principles of regional or local treatment:
 - regional treatment: Swedish massage, functional massage, connective tissue massage, electrotherapy, hydrotherapy, heat therapy, balneotherapy, and manual therapy techniques.
 - local treatment: segmental oscillations for pain relief, local segmental manual therapeutic mobilization techniques to maintain or improve mobility, cross-frictions according to Cyriax, and colon massage.

Prerequisites

Anatomical Background

“You cannot feel what you do not know.”

This simple phrase illustrates the necessity of a solid background in topographical and morphological anatomy for local palpation. It does not make sense to look for a specific transverse process if you are unable to visualize its

shape, position, and spatial relationship to its surroundings.

It is a difficult task to always recall the exact anatomy of a clinically relevant structure. A lot of time and motivation are needed in dealing with this considerable amount of material.

For this reason, two short theoretical sections can be found at the start of each topic:

- The functional importance of each region and its individual parts. This acts as an introduction to the respective topic and refers to current knowledge about the fascinating interplay between individual parts.
- Required topographical knowledge before starting. It is extremely useful to recall topographical relationships again before searching for specific structures. Important anatomical details required for palpation are therefore mentioned in the text and figures.

Precise Palpation as a Process

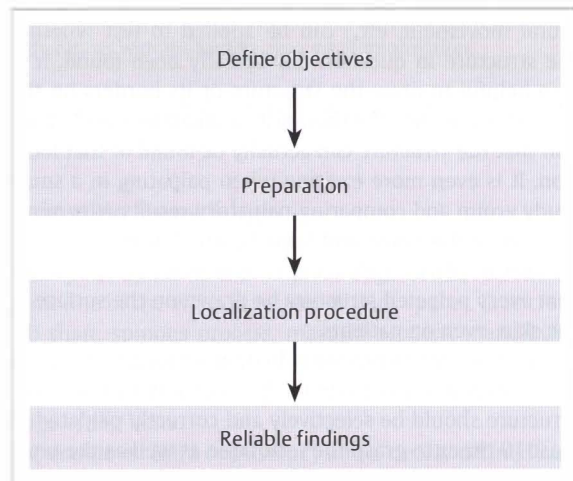


Fig. 1.1 General palpatory procedure.

Define Objectives

The objective of precise palpation of detailed structures is to obtain local orientation for assessment and treatment based on the reasons described above.

Preparation

Preparation involves the study partner/patient and the therapist adopting a certain starting position (SP). If the therapist does not have experience in applying in vivo anatomy, it is recommended that the SP described in the text be strictly observed. Once the therapist has gained a little more experience in locating a particular structure,

other more difficult SPs should be adopted for further practice.

Localization

Therapists should start with the areas they know best. The description of the palpatory process generally starts with the palpation of known and easy-to-reach bony structures (e.g., sacrum, occiput) and muscles (erector spinae, semispinalis). More difficult details can then be “conquered.”

Precise palpation always requires the appropriate technique. There is a specific technique especially suited to each structure.

The Reliable Result

Certain measures (tensing specific muscles, passive vertebral movement, etc.) can be applied to test whether the structure in question has actually been found. It is also helpful to draw the structure or its borders on the skin. This compels the therapist to document and establish that the structure can actually be found at that location. It is even more exciting when palpating in a small study group and comparing palpatory results. Vleeming, founder of the Spine and Joint Centre, Rotterdam and a pioneer in precise palpation, recommends in his courses that every palpated structure be drawn on the surface of the skin, even on patients.

Every author on precise palpation writes about the necessity of practical experience. It is my estimate that every structure should be selectively and correctly palpated at least 10 times to grasp the technique as well as the position and form of the structure.

Experience

Experience is ultimately the deciding factor in obtaining the necessary confidence.

Experience is first demonstrated in the quick and reliable localization of the sought structure in any SP.

There is also another reason why clinicians need to gain experience in precise palpation. Most of the anatomical illustrations available during basic professional training and continuing education courses are in the form of drawings and are therefore a virtual copy of an ideal, that of the assumed average. In this way, these illustrations violate a fundamental rule of anatomy—variation. Even the concept of the anatomical norm cannot be uniform. Instead, it must include variations in position and shape.

Certain structures are quite constant in their position and shape and can therefore be located without much variation in their anatomy. Other structures are subject to large degrees of variation. Therapists need experience to be able to recognize variations in anatomy.

*Empirical formula for in vivo anatomy:
Topography × Technique × Experience*

Central Aspects of the Procedure

Three essential features characterize the palpatory process:

- The application of the appropriate palpatory technique.
- The expected consistency of tissue.
- Differentiating the resistance felt in palpated structures.

The necessity of topographical and morphological knowledge and experience in precise palpation has already been mentioned.

Each structure requires a certain palpatory technique, and it is necessary to have an idea about what the structure should “feel” like. Before palpating, it is also important to know exactly what type of resistance the palpating finger will encounter when it exerts pressure or slides over the sought structure.

For example, the exact location of a bony edge is found by palpating at a right-angle to the edge being sought. The structure is expected to have a hard consistency. The position and shape of a structure can be correctly found amongst the surrounding tissue when the therapist is able to differentiate between the different types of consistencies found in the different tissues.

Soft, elastic tissue is examined slowly to perceive the elasticity.

Hard tissue is examined with a quick movement to feel the hardness.

These principles are also recommended when assessing the end-feel using angular tests (passive functional tests) and translation tests (joint play tests).

Pressure Applied during Palpation

On the whole, only gentle pressure is applied during palpation.

In general, the amount of pressure applied should be as much as necessary and as little as possible.

It is definitely wrong to insist that palpation is always conducted with minimal pressure. The amount of pressure applied depends on the following:

- The expected **consistency of the targeted structure**. For example, if you are searching for a bony edge or prominence, it is correct to assume that it will feel hard when direct pressure is applied to it. In this case, the palpation tends to be performed with more intensity so that the hard tissue response can be felt. Soft tissue is detected using less pressure. It is impossible to perceive its resilience if too much pressure is applied.
- The firmness and thickness of the more superficial tissue. Deeply located bony landmarks covered by a strong muscular layer or a layer of fat cannot be reached by palpating lightly.

A skilled therapist is able to locate the structure in question and the expected tissue consistency by using the appropriate technique and the appropriate amount of pressure during palpation.

Palpatory Techniques

Palpating the Skin

Example: Posterior trunk.

Technique:

- Skin quality: the palm of the hand strokes the skin.
- Skin temperature: the back of the hand strokes the skin.
- Skin consistency: displacement test, skin lifting test, skin rolling.

Expectations:

- Skin quality: smooth, pliable skin. Light hair growth is sometimes present.
- Skin temperature: uniform body temperature.
- Skin consistency: soft and very elastic. The skin becomes firmer when more tension is placed on it.

Commentary: The skin qualities described above represent the ideal situation for young patients. Needless to say, age-related changes to the skin should not be immediately classified as pathological.

The skin's consistency is determined by the balance of fluid in the skin. Elasticity tests are used to assess the consistency of skin and include the displacement test, lifting test (Fig. 1.2), and skin rolling. All three tests should provide identical results. The same amount of elasticity, sensitivity, and changes in these parameters should be found. If this is not the case, techniques should be reassessed or patients questioned again. These tests place different tensile stresses on the skin. The displacement test can be used to find a sensitive or significantly inflamed region; small

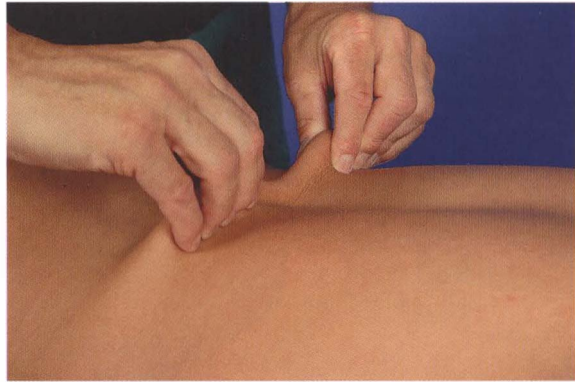


Fig. 1.2 Assessing the skin consistency with the lifting test.

changes in consistency can be detected especially well using skin rolling with a large amount of stretch.

Tip: Experienced therapists need only use one of these tests when working with patients. The choice of test depends on the sensitivity of tissues. In principle, skin rolling provides therapists with the largest amount of information.

The examination of skin consistency does not provide therapists with information on changes in muscle tension.

Palpating Bony Edges

Examples: Spine of the scapula, edge of the acromion, joint line of the wrist, a variety of joint spaces. Iliac crest, rib shaft, spinous process, mastoid process, mandibular arch.

Technique: The fingertip palpates perpendicular to the edge of the bone.

Expectations: Hard consistency and a clearly defined border.

Commentary: This technique enables therapists to accurately locate the outer boundaries of a bone. The palpating finger must always be positioned perpendicular to the edge of the structure (Fig. 1.3). All other techniques are less reliable.

Tip: To feel the hard consistency and clearly palpate the bony edge, therapists should palpate the soft tissue first and then gradually move toward the presumed location of the bony edge.

It becomes increasingly difficult to locate bony contours when superficial tissue is tense. Muscles tense up when patients are positioned in unsupported sitting. Tension increases in all soft tissue when the SP alters the normal curvature of the spine, and tissue is stretched, for example, when padding is placed under the abdomen in the prone position or when sitting patients place their arms in front of them on a treatment table.

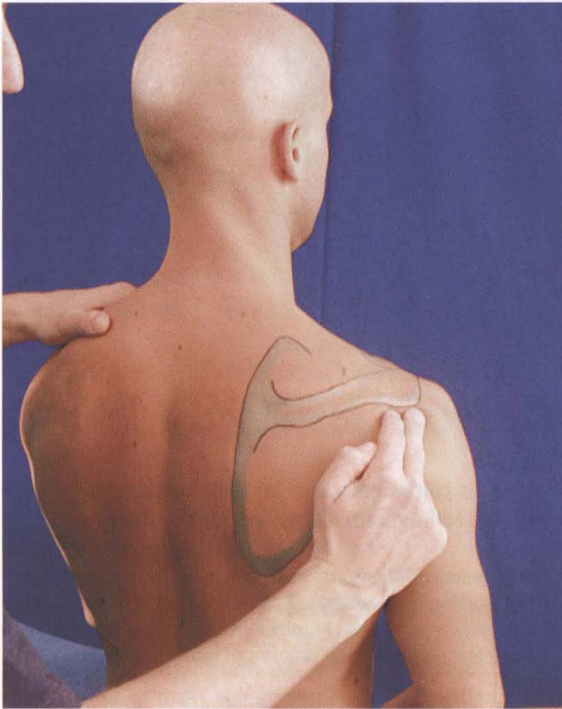


Fig. 1.3 Palpating the edge of bone, demonstrated here on the acromial angle.

Arthritic swelling and bone deformations alter the structure's expected consistency and contours.

Palpating Bony Prominences

Examples: Medial epicondyle of the humerus, Lister tubercle, anterior superior iliac spine, tibial tuberosity, Gerdy tubercle. Posterior superior iliac spine, external occipital protuberance, sacral spinous processes.

Technique: Circular palpation using the finger pads and a minimal amount of pressure.

Expectations: The bony prominence protrudes from the surrounding bone. The structure itself feels hard when direct pressure is applied to it.

Commentary: On the extremities, tubercles, tuberosities, etc. are clearly elevated in comparison to their surroundings and can be clearly differentiated from other tissues with this technique. In most cases, the pelvic spines can be differentiated from their surroundings by their distinctly protruding form. Boundaries cannot always be felt so easily. Their shape is palpated using flattened fingers (**Fig. 1.4**). Too much pressure makes it difficult to feel differences in shape and position, decreasing the chance of success. Direct pressure is only applied to the structure to confirm that bone is being palpated.

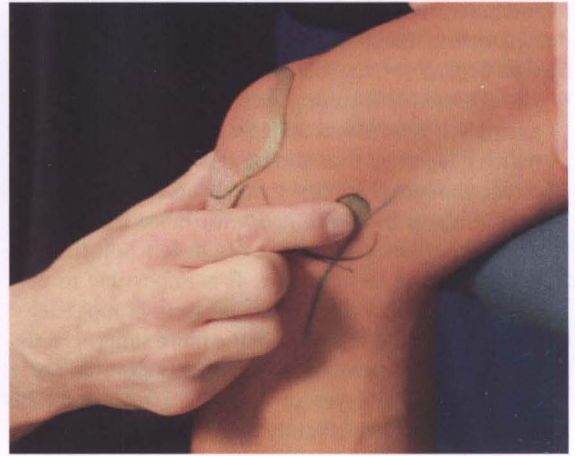

Fig. 1.4 Locating the medial epicondyle.

Tip: The shape of bony prominences can be visualized by looking at their morphology. However, variations are expected to be encountered quite often (see, e.g., external occipital prominence). This can be a distinct protrusion or very flat.

Palpating Muscle Bellies

Examples: Infraspinatus, deltoid, erector spinae, semispinalis capitis, gluteal muscles (**Fig. 1.5**).

Technique: Slow palpation. The finger pads (possibly using more than one to create a larger area of contact) are positioned perpendicular to the muscle fibers most of the time. Minimal pressure is applied.

Expectations: Soft consistency. Tissue yields slightly to pressure. Deeper structures can frequently be palpated.

Commentary: The muscles are palpated using one or several finger pads. Pressure should target the muscle directly. The tissue's soft, elastic consistency can only be felt by proceeding slowly.

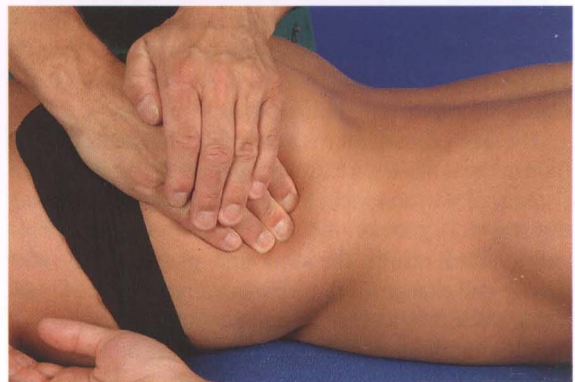

Fig. 1.5 Palpating muscle bellies, demonstrated here on the small gluteal muscles.

Tip: Tissue consistency is directly dependent on the strength or tension in the fascia enveloping the muscle or the section of the trunk or extremities.

Thickness of the Fasciae

Fasciae can be very soft on the anterior and lateral sides of the trunk, in the neck, along the throat, in the medial forearm, the calf, or the medial aspect of the thigh, for example. Muscles yield easily to the pressure of precise palpation here and have an especially soft, elastic consistency. In contrast, extremely hard fasciae feel significantly firmer during palpation, even when the active muscle tension is normal. Typical examples of this are the thoracolumbar fascia superficial to the lumbar erector spinae and the rectus sheath. Therapists may easily conclude that muscles are tense when increased resistance is felt in the tissues. Once they are aware of the qualities fasciae possess, however, they will have correct expectations regarding the consistency of muscle tissue.

Tension in the Fasciae

The consistency of muscle and skin is also influenced largely by the length of tissues. An approximated muscle (where the ends of the muscle are found close to each other) generally feels softer than the resting tension felt in a stretched muscle.

Approximation or lengthening occurs *in the limbs* due to the angular position of joints. It is very difficult to palpate local quadriceps induration when the knee is bent at 90°.

Positioning can influence muscle length *in the trunk* considerably. The changes to palpation become obvious when the lumbar and thoracic trunk extensors in the sitting SP are palpated and this is compared with palpation in the prone position. Even when resting the upper body on a treatment table and other supportive surfaces, muscles are stretched by the flexion/kyphosis of the lumbar spine in a sitting position and by the forward bend of the body. Tissue feels significantly firmer when pressure is applied. Therapists may interpret this as a pathological increase in muscle tension. The amount of tension in the back muscles is also altered when the therapist places padding underneath the abdomen in the prone position, lowers the head end of the treatment table, and elevates the arms. It is not always possible to avoid approximating or stretching muscles during the positioning or skillful examination of patients while keeping symptoms to a minimum. It is important that the therapist takes this into account when looking at the expected consistency of the muscles to be palpated and does not reach the wrong conclusion when interpreting results.

The following exercises should clarify how differences in fascial tension can affect the interpretation of palpatory results on the posterior aspect of the body:

- **Exercise 1:** The gluteal region is palpated, starting at the sacrum and moving systematically in a lateral direction. A hardened area is frequently palpated between the greater trochanter and the iliac crests. The iliotibial tract is located here (thickening of the fascia in the buttocks and the thigh), running from the iliac crest toward the greater trochanter and the lateral thigh. The therapist changes the hip joint's SP by moving it into more abduction or adduction and attempts to feel how the tract changes under direct palpation (different consistencies due to the muscle being stretched or approximated).
- **Exercise 2:** Firm fascia already restricts direct pressure from being applied to the lumbar trunk extensors. The patient's pelvis is moved toward or away from the therapist. This causes lumbar lateral flexion. The therapist palpates the trunk extensors and attempts to find out how their consistency changes (↔ different consistencies due to the muscle being stretched or approximated). Lumbar tension is also increased when patients raise their arms over their heads.

Palpating the Edge of Muscles

Examples: Sartorius, adductor longus, semispinalis capitis, erector spinae, sternocleidomastoid.

Technique: A muscle edge is usually palpated with the muscle slightly tensed. The palpating fingers can be positioned using all possible variations (fingertips, finger pads, sides of the fingers) and should be placed against the edge of the muscle as best possible (Fig. 1.6). Once the edge of the muscle has been located, it is steadily followed so that the course and the length of the muscle can be perceived.

Expectation: When tensed, the edge of the muscle has a firm consistency and a uniform, smooth contour. Large and small gaps differentiate the edges of the muscle from neighboring muscles.

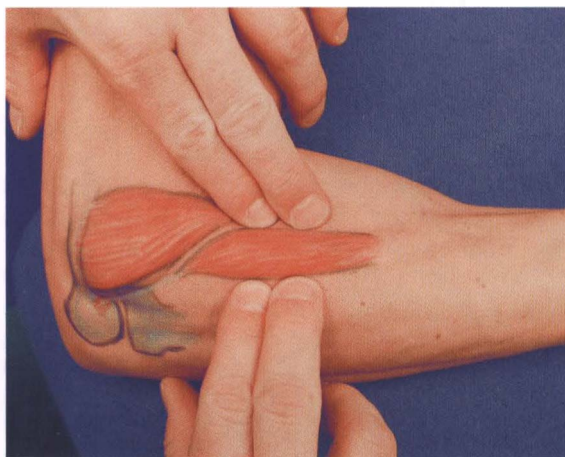


Fig. 1.6 Palpating the edges of muscles, demonstrated here on the extensor carpi radialis brevis.

Commentary: Many neighboring muscles and borders cannot be differentiated from one another or identified without selective activation of the muscle. Well-trained muscles with low fat content as well as muscles with pathologically increased tension are exceptions and project themselves out of their surroundings.

Tip: A muscle and its edges can be quickly identified in difficult situations by alternating muscular tension. The patient is instructed how to quickly alternate between tensing and relaxing the muscle. Reciprocal inhibition is sometimes an option to help “turn off” neighboring muscles. Occasionally, the edges of the muscles can be followed along the further course of the muscle to the insertion into bone.

Palpating Tendons

Examples: Tendons in the extensor compartments of the wrist, flexors of the wrist and fingers, biceps brachii tendon, ankle plantar flexors and toe flexors, hamstring tendons (Fig. 1.7). The trunk muscles rarely attach onto the bone via a tendon. A “fleshy” insertion is more common. Limb muscles near the trunk are more likely to have insertions that feel like tendons when palpated, for example, the communal head of the hamstrings.

Technique: The choice of technique depends on how difficult it is to find the target tissue and the aim of palpation:

- Tendon that is difficult to locate: Place the finger pads flatly and directly onto the point where you suspect the tendon to be, then alternately tense and relax the muscle.
- Tendon that is easy to locate: Place the tip of the finger alongside the edge of the tendon. Tense the muscle when necessary.
- For pain provocation: Administer transverse friction massage using the finger pads, applying firm pressure on the presumably affected site.

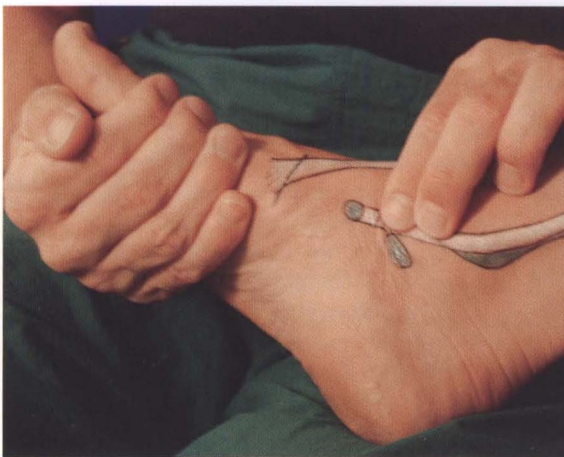


Fig. 1.7 Palpating tendons, demonstrated here on the tibialis posterior tendon.

Expectation: Firm consistency and, when the muscle is tensed, very firm consistency. A tendon remains somewhat elastic when direct pressure is applied to it, even when under a large amount of tension. In most cases, the tendon is a rounded structure with a clearly defined contour.

Commentary: Tendons and their insertions belong to the soft tissue structures in the musculoskeletal system that most frequently present with local lesions. It is therefore imperative to familiarize oneself with the different techniques used for this taut connective tissue.

Tip: The treating finger should not slip off from the tendon while Cyriax transverse frictions are being applied to the tendon for treatment or pain provocation. The tendon remains stable by positioning the muscle in a stretched position and placing the tendon under tension.

Palpating Ligaments

Examples: Medial collateral ligament or the patellar ligament at the knee joint (Fig. 1.8), talofibular ligament at the ankle. With very few exceptions the precise palpation of spinal ligaments is rarely possible. The pelvic ligamental structures, e.g., the sacrotuberous ligament (Fig. 1.8), as well as the supraspinosus and the nuchal ligaments, are the only ligaments on the trunk that can be palpated well.

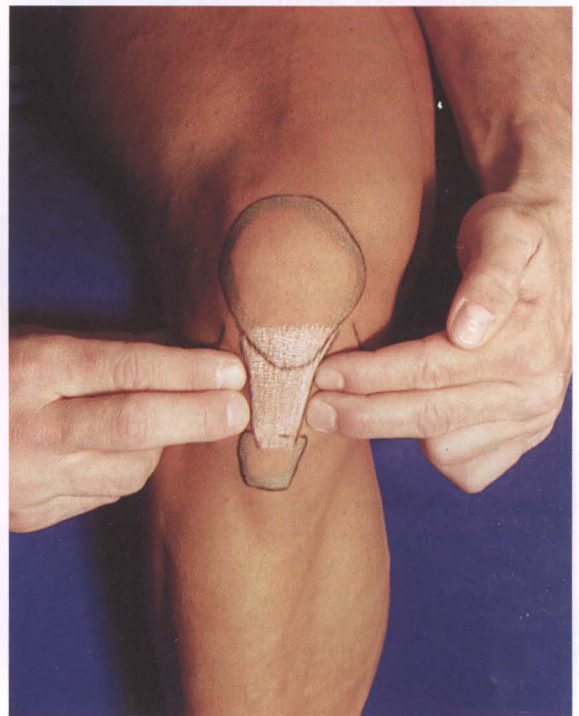


Fig. 1.8 Palpating ligaments, demonstrated here with the patellar ligament.

Technique:

- Ligament that is easy to locate: The tip of the finger is positioned on the edge of the ligament, for example, sacrotuberous ligament.
- Ligament that is difficult to locate: Initially place the ligament under tension and use direct pressure to palpate the firm, elastic consistency, for example, nuchal ligament.
- For pain provocation: Administer transverse friction using the finger pads, applying firm direct pressure onto the ligament, for example, supraspinous ligament.

Expectation: Firm consistency. Very firm consistency when stretched. A ligament remains somewhat elastic, even when placed under a large amount of tension.

Commentary: It is important to be able to accurately visualize the anatomy. You should be familiar with the course of the ligament and, when possible, find its bony attachments.

Ligaments providing capsular reinforcement are another type of taut connective tissue. In contrast to tendons, most ligaments cannot be easily differentiated from either those capsules without ligamentary reinforcement or from other tissues. When ligaments belong to the fibrous layer of joint capsules, they only rarely show clear edges. Exceptions to this rule include the patellar ligament and the lateral collateral ligament of the knee joint. In the other cases, therapists must be familiar with the course of the ligament and locate its fixed points on the bones. In the upper cervical area, the local ligaments are examined via their bony partners and their biomechanical relationship (see “Test for the Alar Ligaments” section in Chapter 12, p. 347).

Tip: If therapists wish to administer provoking or therapeutic transverse frictions to a ligament, the corresponding structure must be stable and should not be allowed to slide away from underneath the finger. The joint is therefore positioned so that the ligament is taut. When patients have only recently overstretched or partially ruptured ligaments, repositioning is done with the necessary amount of care, that is, slowly and without aggravating pain. Muscle contraction usually does not help to make the ligament stable enough for palpation.

Palpating Capsules

Examples: Test for large effusions in the knee joint, effusions at the elbow joint (Fig. 1.9). Cervical facet joints.

Technique: The palpation is performed at a slow pace with the entire surface of the finger pads palpating directly over the capsule. The finger pads move repeatedly over the capsule, applying minimal pressure.

Expectation: A very soft consistency and a fluctuation of synovial fluid inside the swollen capsule is to be expected. At times, a somewhat softer consistency is to be expected with arthritis in comparison to unaffected capsules.

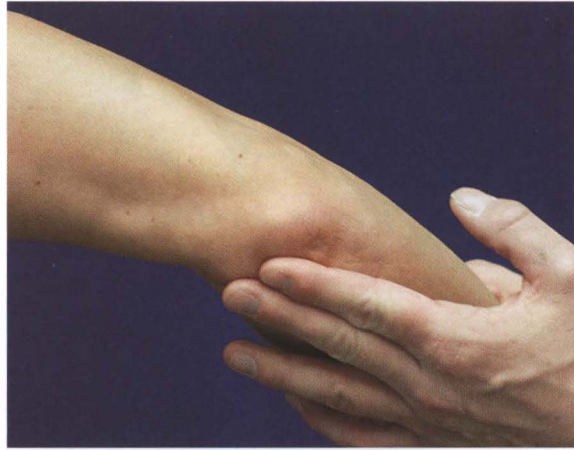

Fig. 1.9 Palpating the capsule of the elbow joint.

Commentary: The joint capsule is palpated to search for lesions in a damaged ligament providing capsular reinforcement and to confirm the presence of capsular swelling.

As previously mentioned, a flat, slow technique is used when a soft consistency is to be expected. The palpatory findings, that is, the identification of swelling, must match the results of observation at a local level. Palpation for an increase in temperature is also usually positive. The sacroiliac joints, the lumbar and thoracic facet joints, and the atlanto-occipital joints cannot be directly reached using palpation. It is not customary to palpate for warmth or swelling as there is too much soft tissue overlying these joints. The focus is the provocation of pain using palpation to locate the level of the cervical facet joints. The result of this palpation, that is, the discovery of sensitivity to pressure and possible associated swelling, must be accompanied by a functional assessment (end-of-range combined movement).

Tip: The palpation of capsular swelling in the knee joint is performed in three graded steps. Topographical knowledge and good spatial visualization abilities are of great advantage.

Palpating Bursae

Examples: Olecranon bursa, sciatic bursa, trochanteric bursa.

Technique: The palpation is performed at a slow pace with the entire surface of the finger pads palpating directly over the bursa. The palpatory movements are repeated several times, applying minimal pressure.

Expectation: Normally, a bursa cannot be perceived as an independent structure as it consists of two capsulelike layers on top of each other. A bursa that is not inflamed is also not sensitive to pressure.

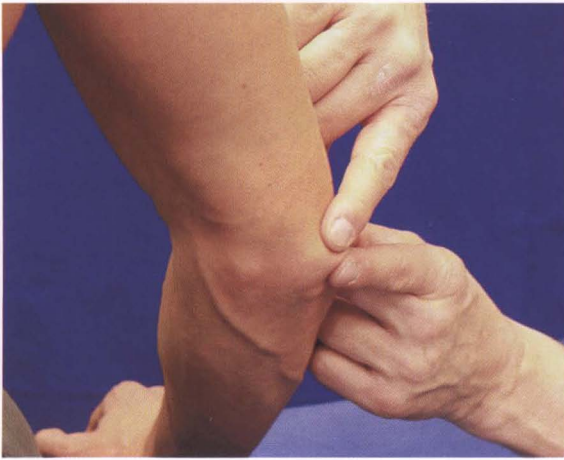

Fig. 1.10 Palpating bursae, demonstrated here with the olecranon bursa.

When a bursitis is present, it is expected that the bursa will have a soft consistency and that the fluid in the inflamed bursa fluctuates with the repeated palpation.

Commentary: Irritated bursae at the trunk can only be palpated in the pelvic/hip region and on the spinous processes. On the extremities this is possible in all prominent bony parts, for example, the olecranon. If the patient indicates local pain, this is a reason for searching for fluctuating fluid in a bursa. This presents when the bursa is compressed during the assessment used for orientation. In the case of a trochanteric bursitis, active resisted abduction and passive adduction of the hip joint are painful.

Tip: The fluctuation of fluid can be felt well when two finger pads are used for the palpation and pressure is alternately applied using one finger and then the other (**Fig. 1.10**). Muscular or tendonous structures located superficial to the affected bursa (iliotibial tract over the trochanteric bursa) should not be tensed or stretched during the palpation. The consistency naturally changes when palpating through these tissues. They may lose the softness, and fluctuations can no longer be palpated. In this case, the technique serves only to provoke pain in the suspected bursitis.

Palpating Neural Structures

Examples: Median nerve, ulnar nerve, tibial nerve, common peroneal nerve, sciatic nerve, brachial plexus.

Technique: The fingertips palpate at a right-angle to the pathway of the sought neural structure (**Fig. 1.11**). It is possible to slide over the nerve if the nerve is placed under tension beforehand. This is similar to plucking a tightened guitar string. Do not use too little pressure and do not proceed too slowly.

Expectation: The nerve feels very firm and has an elastic consistency when the nerve has been placed under ten-

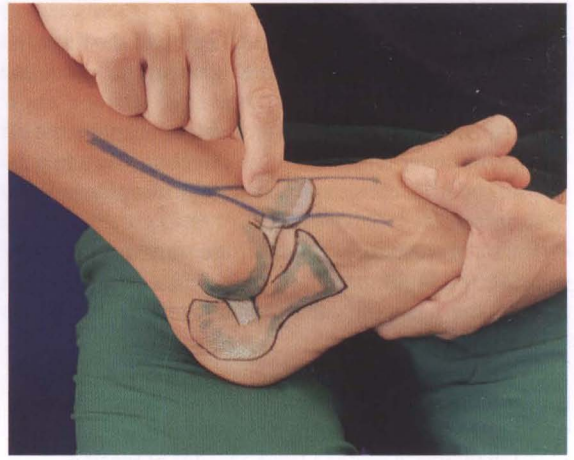


Fig. 1.11 Palpating neural structures, demonstrated here on the superficial peroneal nerve.

sion beforehand and direct pressure is applied to the nerve.

Commentary:

- The number of peripheral nerve compressions identified during patient assessment is increasing. These conditions sometimes give the impression that a lesion is present in a muscle or tendon. For example, irritation of the ulnar nerve imitates a “golfer’s elbow,” while irritation of the radial nerve appears to be an inflammation of the synovial sheath in the first extensor tendon compartment. In addition to further indications, good palpatory differentiation is very useful.
- Peripheral nerves occasionally accompany or cross over tendons and ligaments. Futile and unpleasant irritation of a peripheral nerve may result from the application of therapeutic transverse friction to the nerve that actually aims to relieve pain in an affected tendon or ligament. For this reason, local palpation is again helpful in gaining clear orientation.
- The compression and tension of neural structures plays a significant role when examining patients with spinal symptoms. The results indicate the type and severity of damage.

Tips:

- In most cases, it is not possible to palpate and locate neural structures without initially placing the neural structures under tension.
- The important peripheral nerves for the upper and lower limbs are especially thick near the trunk.
- Nerves can tolerate direct pressure and short-term adjustments in their pathway quite well. Extreme caution is not necessary. The nerves have to be stretched past their physiological boundaries, undergo repeated frictioning, or experience long-lasting pressure before they show signs of intolerance. Sensitive people report a “pins and needles” sensation when the preliminary tension on a nerve is uncomfortable.

- Once therapists have experienced the typical “plucking” of a nerve, they will be able to recognize this feeling in every other nerve. It is not comparable to any other palpatory findings.
- Lines can often be used as an aid to make the location of a neural structure clear (e.g., sciatic nerve at the pelvis).

Palpating Blood Vessels (Arteries)

Example: Brachial artery, femoral artery, anterior tibial artery (Fig. 1.12), occipital artery.

Technique: A finger pad is placed flat and with very little pressure over the presumed position of the artery.

Expectation: The different consistencies are not being addressed here and pain is not being provoked as a test. Instead, the palpation of arteries involves feeling how the artery “knocks” on the finger pad. This can only be achieved when the applied pressure is minimal. The finger pad receptors are unable to discriminate between the pulsation and the consistency of the surrounding tissues when too much pressure is applied. Excessive pressure can also compress small arteries, making it more difficult to feel the pulse.

Commentary: When assessing patients of internal medicine through palpation, knowledge of the position and course of blood vessels is used to evaluate the peripheral arterial supply to the arm and leg using palpation. This

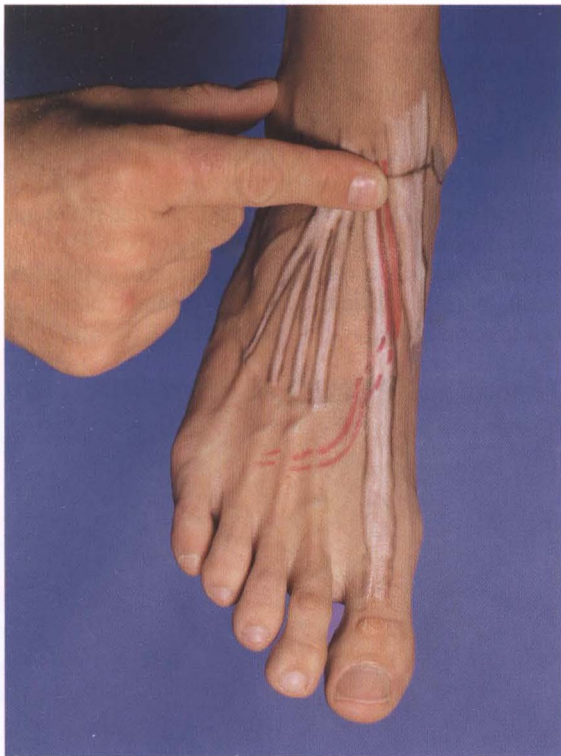


Fig. 1.12 Palpating arteries, demonstrated here on the anterior tibial artery.

knowledge is not as important for the physical therapy assessment of the trunk as it is for the assessment of the limbs. Arteries are rarely palpable on the trunk wall. They can only be clearly felt on the posterior side of the head, along the throat, and in the face.

Nevertheless, compression of neural structures and blood vessels in the trunk should be avoided when applying manual techniques. For this reason, it is important to be able to recognize the palpable blood vessels and their location.

Tip: When palpating arteries of the extremities, the superficial tissue should be as relaxed as possible. Therefore, the patient is instructed to relax as much as possible. The joint is positioned at an angle that relieves tension in the surrounding soft tissue. The brachial artery on the medial aspect of the upper arm is thus palpated with the elbow slightly flexed. If it is difficult to find the pulse of a blood vessel, the area of contact can be increased by using one or two extra finger pads. Therapists should take their time when palpating as the pulse cannot be felt immediately.

Palpation Aids

It is occasionally necessary to use aids when trying to locate a certain structure.

Guiding Structures

It is sometimes extremely difficult or even impossible to find the exact location of an anatomical structure using direct palpation. In these cases, other anatomical structures are used that guide the palpating finger to the point being sought. Guiding structures can be tendons that make the position of a structure clearer. The edge of muscles or certain bony points (reference points or landmarks) can also be used for orientation.

Examples:

- The tendon of the sternocleidomastoid guides the palpating finger to the sternoclavicular (SC) joint space.
- The tendon of the palmaris longus reveals the position of the median nerve in the forearm.
- The scaphoid can be found in the anatomical snuffbox. The snuffbox is formed by two tendons.
- The distal radioulnar joint space lies immediately beneath the tendon of the extensor digiti minimi.
- The tip of the patella is always found at the same level as the joint space of the knee.
- The common peroneal nerve is found in the popliteal fossa, running parallel to the biceps femoris, approximately 1 cm away from it.
- The 12th rib and the T12 transverse process are found at the same level as the T11 spinous process (Fig. 1.13).

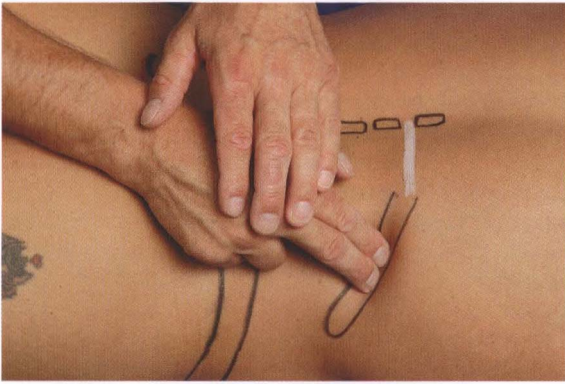


Fig. 1.13 Guiding structures—the 12th rib guides us to the T11 spinous process.

- The sternocleidomastoid muscle can be used to guide the palpation to the mastoid process.

Connecting Lines

It is also possible to use a line connecting two bony landmarks for safe orientation without having to directly palpate. In particular, this aid is used when the anatomical characteristics associated with the connecting line display little variation.

Examples:

- The palpatory differentiation of individual carpal bones using direct palpation is difficult or, in some cases, even impossible. Connecting lines are of great assistance. For example, the therapist can assume that the joint space between the scaphoid and lunate is halfway along the line connecting the head of the ulna and the Lister tubercle on the posterior aspect. Initially, this still appears to be quite complicated. However, if the therapist is able to accurately find these bony landmarks, it is easy to use the connective line.

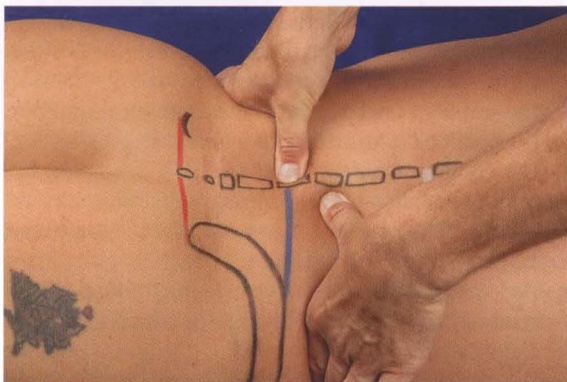


Fig. 1.14 Lines connecting the pelvis and the lumbar spine.

- The line connecting the two posterior superior iliac spines is found at the same level as the S2 spinous process (**Fig. 1.14**).
- The sciatic nerve is found halfway along the line connecting the ischial tuberosity and the tip of the greater trochanter.

It is sometimes necessary to enlist the help of guiding structures and spatial relationships to locate the structure in question.

Supporting Measures for Confirming a Palpation

Several measures can be used to confirm the location of a structure when the clinician is not sure what structure is being palpated:

- The successful palpation of a cervical facet joint gap is best confirmed by passively moving one side of the joint.
- The successful palpation of an intervertebral space is best confirmed by passively moving one of the vertebrae involved (see **Fig. 1.15**).
- The insertions of a muscle belly into a bone or the edge of a muscle can be palpated by tensing the muscle in several short repetitions.
- If a therapist feels they are palpating a peripheral nerve, they can position the joints differently in order to place the nerve under tension or to relax it.
- Palpable ligaments (e.g., medial collateral ligament at the knee joint) can be tightened using a wide-range movement to allow the change in consistency to be felt.

These measures are used to change the feel of the tissue, indicating exactly where the structure is to be found. It is, however, the aim of routine palpation to find structures without these aids. Some measures cannot be used on patients, for example confirming the location of an intervertebral space if a painful vertebral segment cannot be moved without aggravating symptoms.

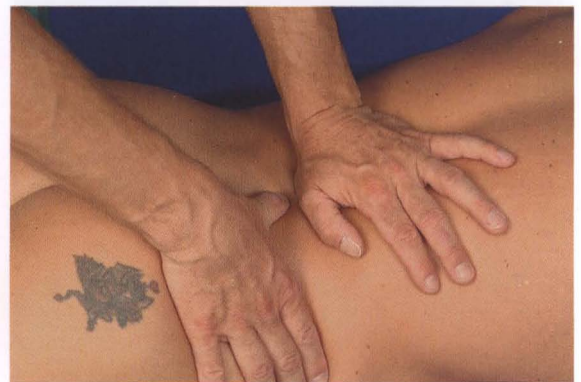

Fig. 1.15 Moving the more superiorly located vertebra to confirm the localization of an interspinal space.

Marking Structures

Marking anatomical structures is not imperative and therefore tends to be rarely done on patients. However, marking the position or course of a structure when practicing can be very helpful. Drawing clarifies the location of different anatomical shapes and develops spatial orientation abilities.

A drawing can also ensure that a third person can examine the findings and check whether they are correct. Drawing a structure is a moment of truth.

In this book, the structures found during palpation are marked on the skin. Bony borders, edges of muscles and tendons, etc. are illustrated exactly where they have been felt. This helps to visualize where the specific structure can be found.

Marking an anatomical structure on the skin means placing a palpated three-dimensional structure onto an almost two-dimensional surface. Hence a drawing always appears more extensive and wider than the palpated structure actually is. A drawing is more reliable in demonstrating the actual size of a structure when the structure is more superficial.

Starting Positions for Practice (Practice SPs)

Generally it is necessary to practice palpatory techniques on a study partner in appropriate SPs. It is permissible to use SPs that do not always correspond to the clinical situation when practicing.

The application of the recommended techniques is described later in this book. Once the techniques can be confidently performed in the practice SPs, the study partner should be placed in more difficult positions that mirror clinical practice and an attempt made to relocate the structure. Fast, confident location of structures in any SP is a sign of experience.

Study Questions

1. Name several examples from your area of experience where *in vivo* anatomy plays a decisive role.
2. Describe how you proceed when you are unsure whether you have found the exact location of a structure you are looking for.
3. Explain why it is helpful to start palpating in an area with which you are familiar.
4. Why is it so important to have experience in *in vivo* anatomy?
5. Which three central aspects are important when palpating?
6. Why should you apply firm pressure when searching for a structure?
7. What type of consistency do you expect skin to have when examining it?
8. What is the best technique for correctly locating the edge of a bone?
9. What types of structures are best found by palpating in a circular manner with the entire surface of the finger pads?
10. What role does the thickness and the preliminary tension of fascia play when palpating a muscle belly?
11. There is a supporting measure you can use to increase your confidence in correctly palpating the edges of muscles. What is this?
12. Where can ligaments be palpated on the trunk?
13. In which part of the vertebral column can the facet joint capsules be reached?
14. Why is it not dangerous to place direct pressure on neural structures for a short amount of time?
15. What do you expect to find when you successfully palpate an artery?
16. What are guiding structures in *in vivo* anatomy?
17. What is the purpose of the connecting lines that are drawn on the skin?
18. What is the advantage of drawing the position of palpated structures on the skin?
19. Why does it make sense to first use simple SPs when you are new to the palpatory process?



2 Shoulder Complex

- Significance and Function of the Shoulder Region ... 19**
- Common Applications for Treatment in this Region ... 19**
- Required Basic Anatomical and Biomechanical Knowledge ... 19**
- General Orientation—Posterior ... 20**
- Local Palpation—Posterior ... 21**
- Local Palpation—Lateral ... 28**
- General Orientation—Anterior ... 34**
- Local Palpation—Anterior ... 35**
- Local Palpation—Anterolateral ... 37**
- Study Questions ... 44**

THIS PAGE INTENTIONALLY
LEFT BLANK

2 Shoulder Complex

Significance and Function of the Shoulder Region

This section examines biomechanical and functional factors in the shoulder complex.

The shoulder complex is one of the largest movement complexes in the musculoskeletal system. It includes:

- The shoulder joint (glenohumeral or GH joint).
- The bony parts and joints in the shoulder girdle.
- The cervicothoracic junction and the superior costal joints.
- The muscles, vessels, and nerves supplying this area.

The arm must be able to move over the largest range of motion. The **most important principle of function** of the shoulder complex is to provide a mobile and stable base for the arm movements. Apart from the mechanics of locomotion, end range elevation of the shoulder is the most complex movement of the body.

The **intricate interplay** between the individual components of the shoulder complex allows a variety of dysfunctions. The cause of restricted shoulder elevation can be found in every single mobile articulation in the cervicobrachial region.

A comparatively **large number of causes** for shoulder/arm pain exists. Pain may be referred or projected from the cervical spine and the thoracic outlet, or may be due to several other possible causes ranging from arthritis to lesions in the soft tissue.

When presented with a “shoulder patient,” therapists are often compelled to thoroughly assess all components of the shoulder complex and frequently find it quite difficult to interpret results.

Common Applications for Treatment in this Region

Techniques used in this region that require knowledge of palpation include:

- Joint play tests and manual therapy techniques (e.g., glenohumeral, acromioclavicular, and sternoclavicular).
- Local cross-frictions according to Cyriax, for example, at the site of insertion for the rotator cuff muscles.
- Local application of electrotherapy and thermotherapy on the muscles and articular structures.

Required Basic Anatomical and Biomechanical Knowledge

Therapists should be familiar with the location and form of the articular structures in all “shoulder joints,” as well as the location, course, and attachments of clinically important muscles, for example, the supraspinatus. Good spatial sense is of advantage as the clinically important

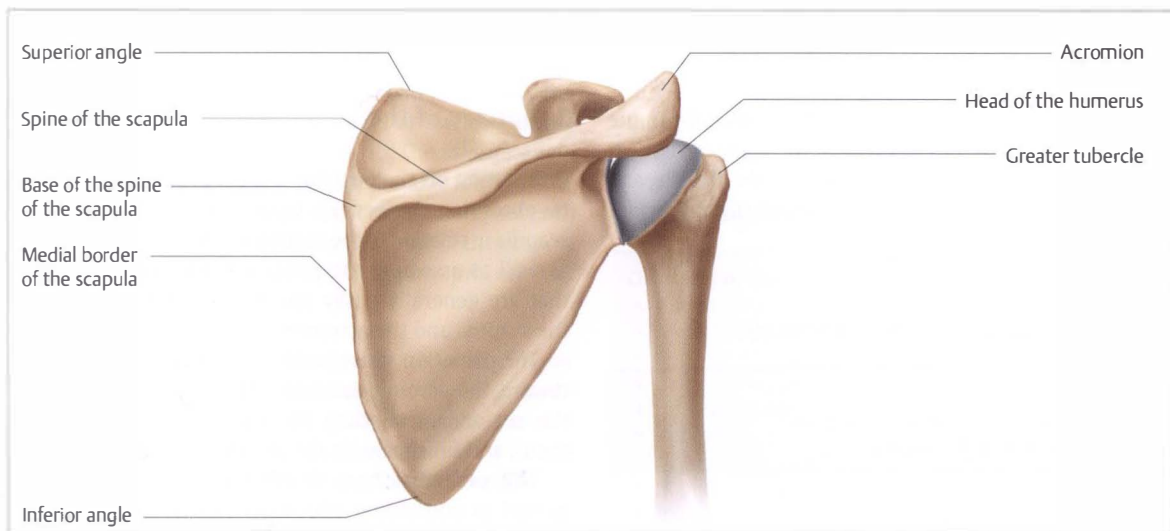


Fig. 2.1 Overview of the topography on the posterior aspect.

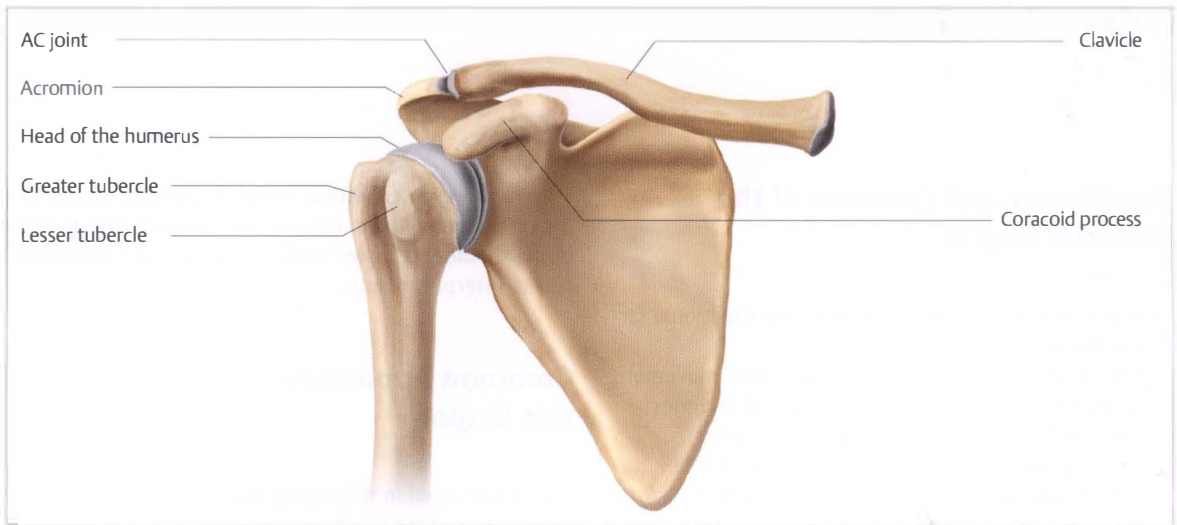


Fig. 2.2 Overview of the topography on the anterior aspect.

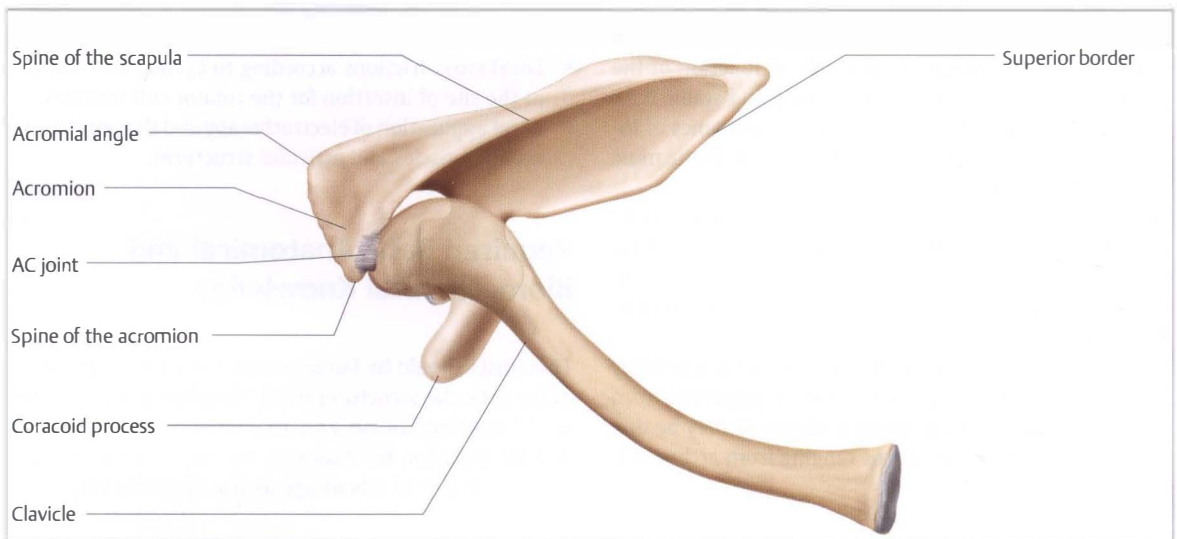


Fig. 2.3 Overview of the topography on the superior aspect.

structures are found close to each other, especially in the GH joint. Knowledge of the shape of the spine of the scapula and the acromion, the dimensions of the clavicle, and the position of the joint spaces is especially important (Figs. 2.1, 2.2, 2.3).

General Orientation—Posterior

Overview

- Topographical position of the scapula.
- Medial border of the scapula.

Summary of the Palpatory Process

Orientation on the posterior aspect of this region begins by observing the general topographical position of the scapula in relation to the vertebral column and the thorax, as well as assessing the position of the bony landmarks that are generally easily recognizable (inferior angle of the scapula and the acromion).

The palpation starts posteriorly on the scapula, moves toward the acromioclavicular (AC) joint, then addresses the region surrounding the sternoclavicular joint (SC joint), and finishes with the anterolateral aspect.

This order has been developed from the experience gained in continuing education courses and is recommended simply for educational purposes. Therapists can naturally start palpating at any point they wish.

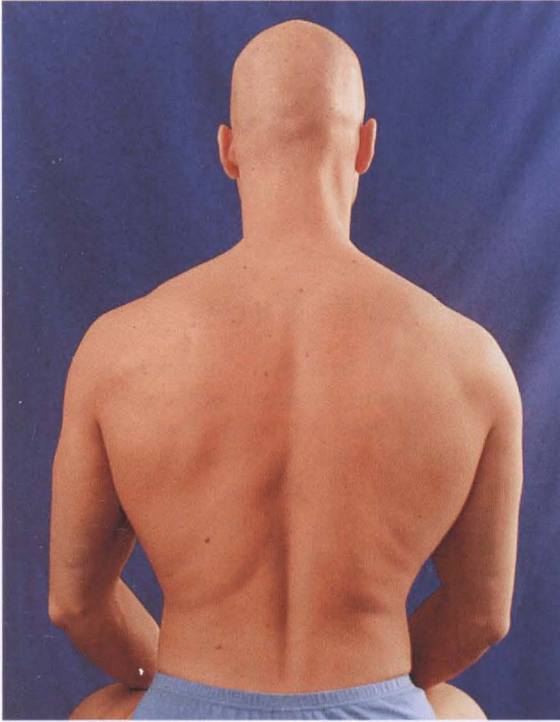


Fig. 2.4 SP for the palpation of the posterior aspect.

Starting Position

When the important structures in the shoulder girdle are being located in detail, a practice starting position (SP) is taken: upright-sitting on a stool or a treatment table with the arms hanging loosely by the sides. In this SP, all components of the shoulder complex are usually found in a neutral position and all structures can be reached with ease (Fig. 2.4).

Topographical Position of the Scapula

According to Winkel (2004) and Kapandji (2006), the superior angle of the scapula is found at the level of the T1 spinous process and the second rib. The inferior angle of the scapula can be clearly palpated and is found at the same level as the T7 spinous process and the seventh rib. The triangular-shaped base of the spine of the scapula can be located at the level of the T3 spinous process (Fig. 2.5).

The correlations described above are very constant, but only apply when the shoulder is relaxed and a sitting or upright SP is used. If the patient changes position, for example, into side-lying, they are no longer reliable as the position of the scapula has changed (e.g., there is more elevation or abduction).

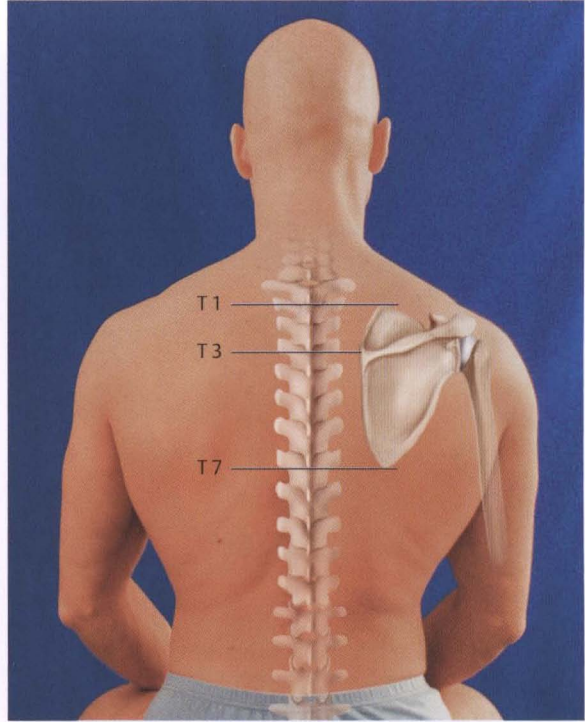


Fig. 2.5 Position of the scapula in relation to the spine.

Medial Border of the Scapula

When the shoulder joint rotates medially, the scapula follows and the medial border of the scapula moves away from the thoracic wall (Fig. 2.6). This assists movement of the arm and is normal. It should not be considered pathological. Only the timing and the range of motion allow the therapist to draw conclusions on the ability of the shoulder joint to medially rotate.

The medial border of the scapula is usually only visible when weakness in the rhomboids and serratus anterior results in insufficient thoracic stabilization of the scapula. Considerable weakness or paralysis in these muscles causes winging of the scapula and is also known as scapula alata (Fig. 2.7).

Local Palpation—Posterior

Overview of the Structures to be Palpated

- Inferior angle of the scapula.
- Medial border of the scapula.
- Superior angle of the scapula.
- Spine of the scapula—inferior edge.
- Acromial angle.
- Acromion.
- Spine of the scapula—superior edge.
- Supraspinatus—muscle belly.
- Infraspinatus—tendon and insertion.

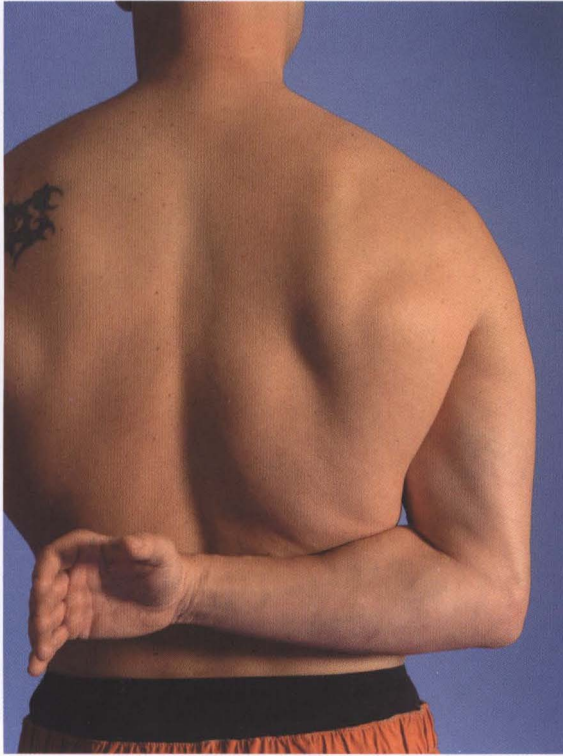


Fig. 2.6 Movement of the scapula with medial rotation of the arm.

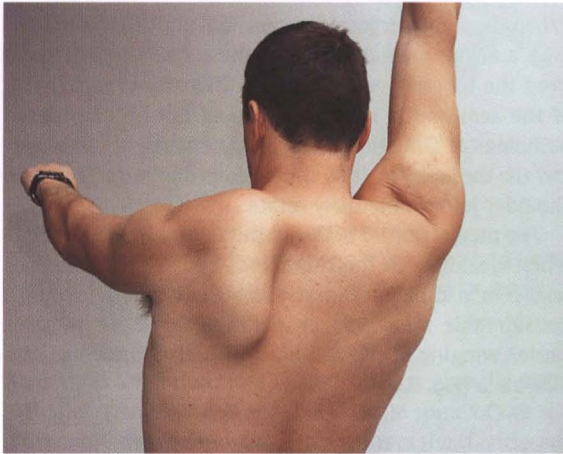


Fig. 2.7 Patient with a lesion of the long thoracic nerve and paresis of the left serratus anterior.

Summary of the Palpatory Process

Following completion of the introductory orientation on the posterior aspect of the shoulder, several important bony structures will first be located. The palpation starts medially, over the spine of the scapula toward the lateral region of the shoulder. The different sections of the acromion are of special interest here and guide the therapist to

two structures of great clinical importance: the supraspinatus and infraspinatus.

Starting Position

The patient's SP is identical to that used in the previous section.

Inferior Angle of the Scapula

The inferior angle of the scapula is an important reference point when assessing movement of the scapula. Therapists use this structure for orientation when they are assessing the range of scapular motion during abduction and lateral rotation of the shoulder.

Technique

To assess rotation of the scapula, the therapist first palpates the inferior angle of the scapula in its resting position (Fig. 2.8). The patient is then instructed to raise the arm. With regard to scapular movement, it is of no significance whether this is done through flexion or abduction. Once the arm has been raised as far as possible, the therapist palpates the position of the angle again and assesses the range of motion (Fig. 2.9). This is also compared

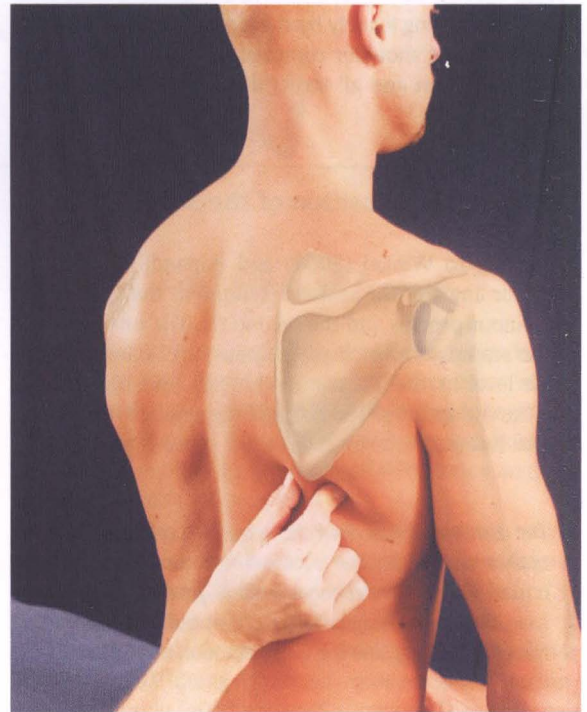


Fig. 2.8 Position of the inferior angle of the scapula at rest.

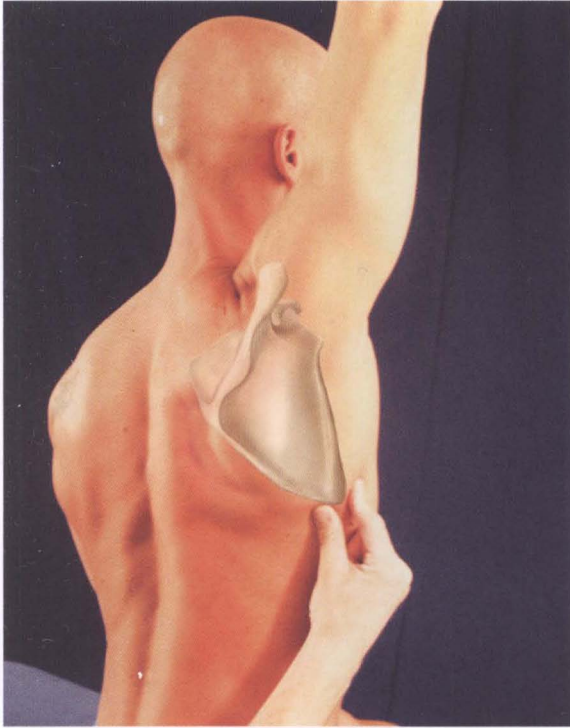


Fig. 2.9 Position of the inferior angle of the scapula in maximal arm elevation.

with the other side. It is more difficult to locate the inferior angle when the latissimus dorsi is well developed.

Range of motion is not the sole interesting aspect when analyzing movement of the scapula. Asymmetrical or even jerky movements of the inferior angle as it moves to assist elevation of the arm indicate poor coordination and a possible weakness of the serratus anterior. If the scapula does not sufficiently assist arm elevation, range of motion will be reduced and chronic subacromial/subdeltoid bursitis may also result.

Medial Border of the Scapula

The medial border of the scapula is located using a perpendicular technique and palpated from inferior to superior. This is the first opportunity for students to consciously use this technique and to differentiate between the soft and elastic consistency of the muscles and the hard resistance of the edge of bone.

Technique

The palpating fingertips come from a medial position and push against the border (Fig. 2.10). It is easy to locate the inferior part of the border as relatively few muscles are found here that impede access. It becomes more difficult to palpate more superiorly.

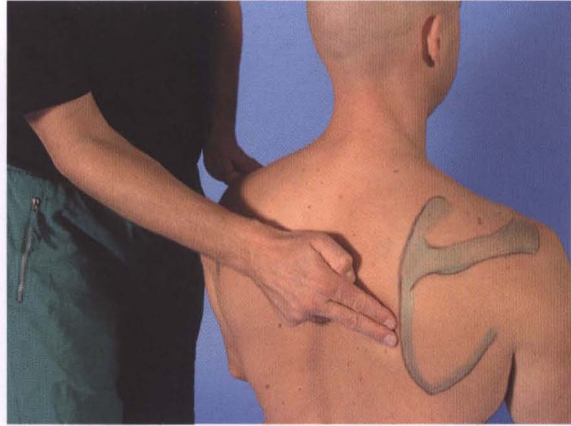


Fig. 2.10 Palpation of the medial border of the scapula.

Tip: If circumstances make it difficult to locate the border, it can help to ease the shoulder into medial rotation so that the medial border of the scapula wings out (see also Fig. 2.6). However, the aim of this palpatory exercise is to be able to find the edge of bone in any shoulder and with different tissue conditions.

Superior Angle of the Scapula

The superior angle of the scapula is found at the level of the second rib and is often expected more superior.

Technique

One hand palpates from a superior position. The finger is placed over the posterior border of the muscle belly of the descending part of the trapezius superior to the medial border of the scapula.

Tip: It is very difficult to palpate the superior angle of the scapula. The trapezius and the inserting levator scapulae are often very tense, making it difficult for the therapist to differentiate between muscle tension and the superior angle. The therapist can avoid this problem by passively elevating the shoulder girdle. This can be done in any SP. The therapist elevates the shoulder girdle by pushing along the axis of the hanging arm. The superior angle of the scapula then pushes against the palpating finger (Fig. 2.11).

Spine of the Scapula—Inferior Edge

The spine of the scapula is another important bony reference point when palpating the posterior aspect. It is a reliable starting point for lateral palpation and when accessing the bellies of clinically conspicuous muscles (supraspinatus and infraspinatus). The spine of the scapula points toward the opening of the socket of the shoulder joint

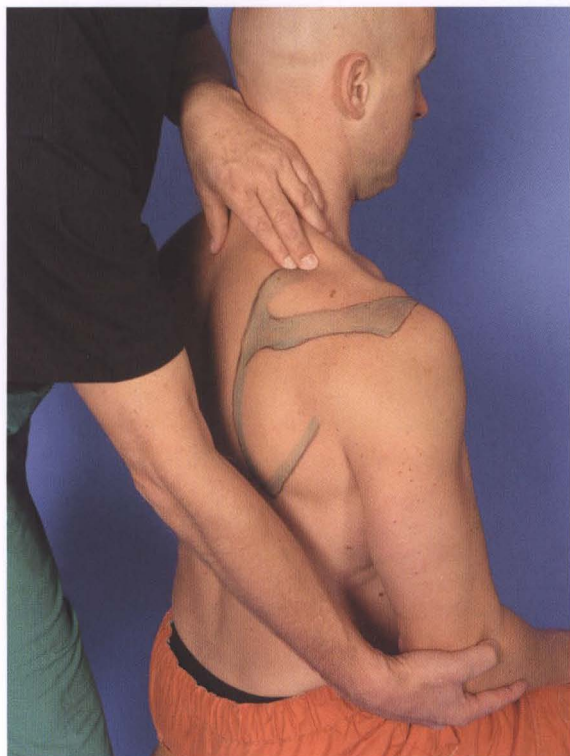


Fig. 2.11 Palpation of the superior angle of the scapula.

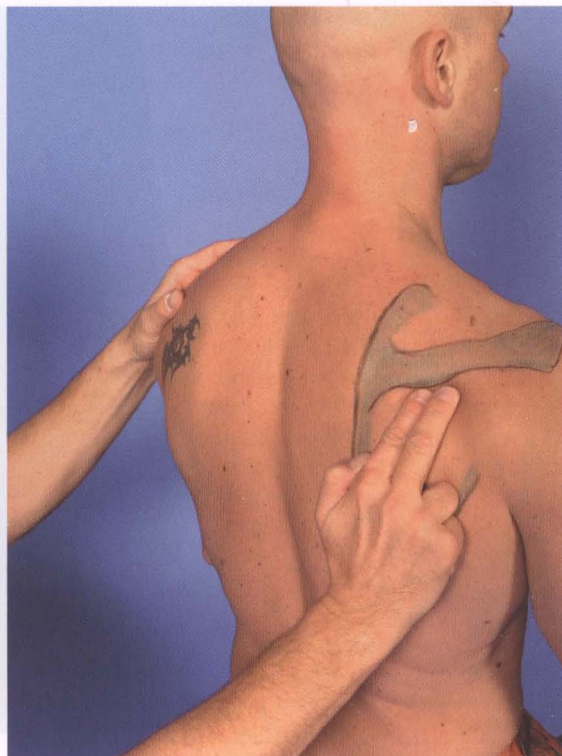


Fig. 2.12 Palpation of the inferior edge of the spine of the scapula.

(glenoid cavity) and is the direction for manual therapeutic traction at the GH joint. Manual therapists should therefore first determine the direction of traction by palpating the spine of the scapula before applying traction to the joint. This is possible in any SP.

Technique

The inferior and superior edges of the spine of the scapula are palpated using the perpendicular technique with which we are already familiar. The supraspinatus and infraspinatus are often quite tense, which makes locating the spine of the scapula more difficult than on the medial border of the scapula.

The inferior edge is palpated from medial to lateral. The spine of the scapula has a rolling, undulating shape that has developed as a result of the pull of muscular attachments, for example, the ascending part of the trapezius.

To locate the inferior edge exactly, the therapist uses the finger pads to push against the elastic resistance of the skin and muscles and moves the palpating fingers in a superior direction until the finger pads encounter hard resistance (Fig. 2.12).

The muscle belly of the infraspinatus is found underneath the spine of the scapula.

Acromial Angle

Technique

When the arm is hanging down, the acromial angle is the prominent structure on the lateral end of the inferior edge of the spine of the scapula. The spine of the scapula becomes the acromion at this point (Fig. 2.13).

Acromion

The acromion is also an important reference point. The height of the acromion in the resting position can indicate the presence of an “elevated shoulder.” During arm elevation, the acromion is also used for orientation to assess the range and speed of shoulder girdle elevation and, when observed from the side, retraction (Fig. 2.14).

Tip: The lateral edge of the acromion is generally aligned anteriorly, medially, and slightly superiorly. The shape and dimensions of the acromion vary greatly among individuals and must be palpated precisely. This will be described later in the text.

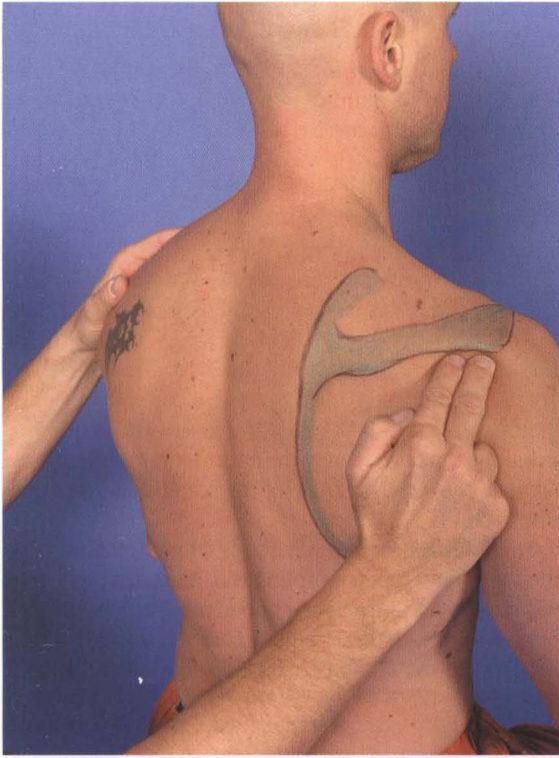


Fig. 2.13 Palpation of the acromial angle.

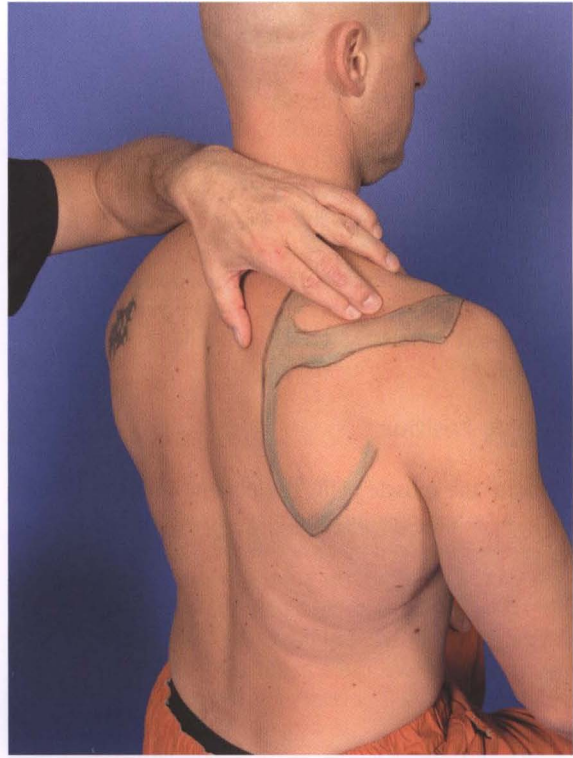


Fig. 2.15 Palpation of the superior edge of the spine of the scapula.

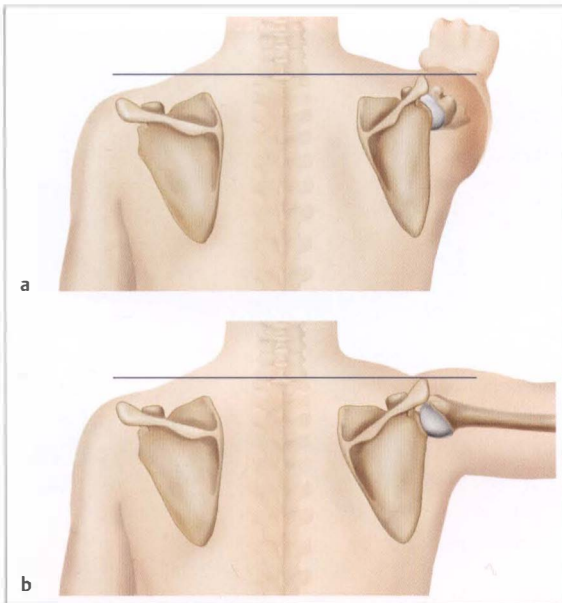


Fig. 2.14 Movement of the acromion during shoulder flexion and abduction.

Spine of the Scapula—Superior Edge

In the next stage of the palpation, the superior edge of the spine of the scapula is followed from medial to lateral until it meets up with the posterior edge of the clavicle. The therapist will discover that the spine of the scapula is significantly thicker than imagined. When the edges are projected and drawn onto the skin, they are almost parallel to each other, appear very broad, and are 2–3 cm apart.

Technique

This palpation uses the same technique described in the palpation of the inferior edge (Fig. 2.15).

The spine of the scapula can be followed from its base to the acromion. The palpation finishes laterally when the fingertips encounter another hard structure. This is the posterior edge of the clavicle. Both of these bony edges (superior edge of the spine of the scapula and the posterior border of the clavicle) taper in toward each other and connect, forming the “posterior V” (see p. 30).

Supraspinatus—Muscle Belly

The muscle belly of the supraspinatus is found in its bony depression between the superior edge of the spine of the scapula and the descending part of the trapezius. The muscle belly and sometimes muscle–tendon junction can be palpated between the superior angle of the scapula and the “posterior V.”

This shoulder muscle is of great functional and clinical importance. It can be symptomatic in the muscle belly and at the insertion into the greater tubercle.

Starting Position

To locate the muscle belly, the patient does not have to adopt a certain position and may remain sitting upright. The shoulder should be easily accessible from the side.

The muscle belly of the supraspinatus is found deep in the supraspinous fossa and only the slender superficial section of the muscle can be reached directly. The therapist must therefore use a technique that can be applied to tight spaces but is nevertheless intense enough to reach the affected area.

Transverse frictions are used for palpation. This technique is used during the assessment to confirm that this structure is symptomatic. It is also used with other techniques to treat tendinitis or tendinosis at the muscle–tendon junction or injuries to the muscle belly.

Technique

The suitable technique here is to come from the side, positioning the middle finger parallel to the muscle fibers and applying pressure. The index finger is placed over the middle finger as support (Fig. 2.16). Transverse frictions are conducted by pronating the forearm and applying pressure from posterior to anterior (Fig. 2.17). This technique can be used over the entire length of the muscle between the superior angle of the scapula and the “posterior V.”

The muscle becomes tendinous laterally. Its insertion into the greater tubercle is of clinical interest, but is not accessible when the arm is positioned in neutral as it is then found underneath the acromion. Location of this tendon is discussed in the section “Local Palpation—Anterolateral” below, page 42.

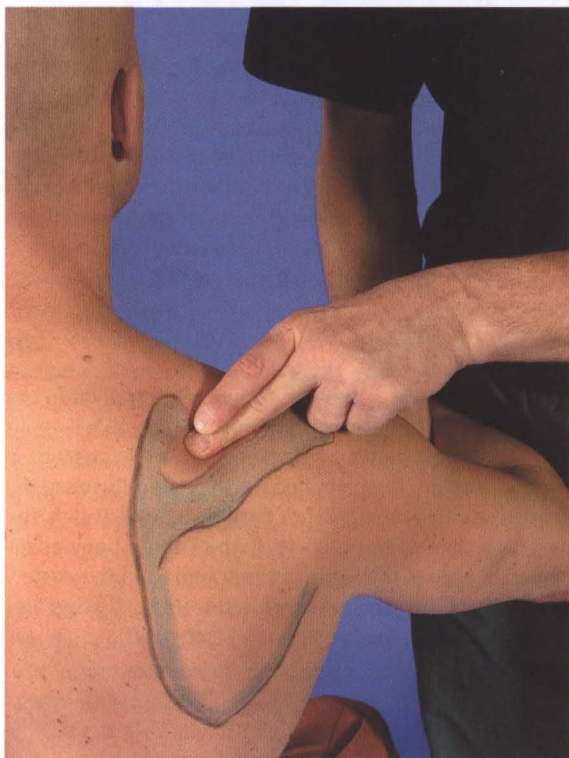


Fig. 2.16 Transverse friction at the muscle belly of the supraspinatus, phase 1.

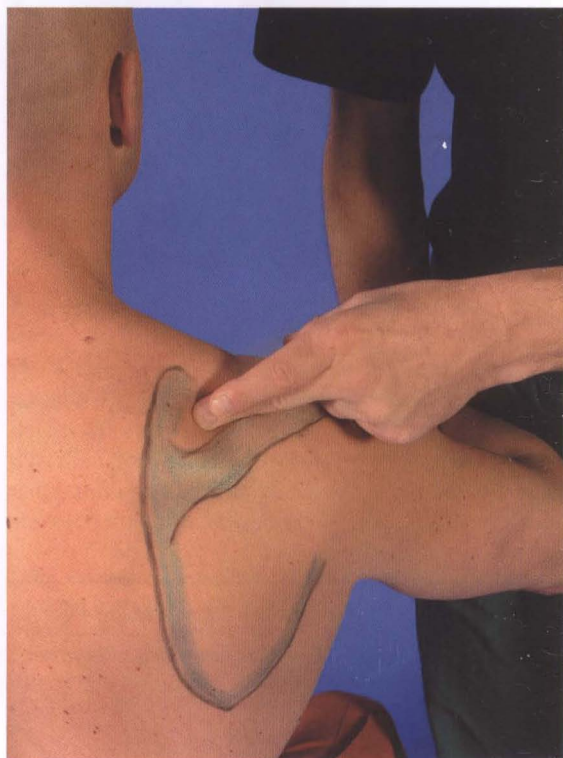


Fig. 2.17 Transverse friction at the muscle belly of the supraspinatus, phase 2.

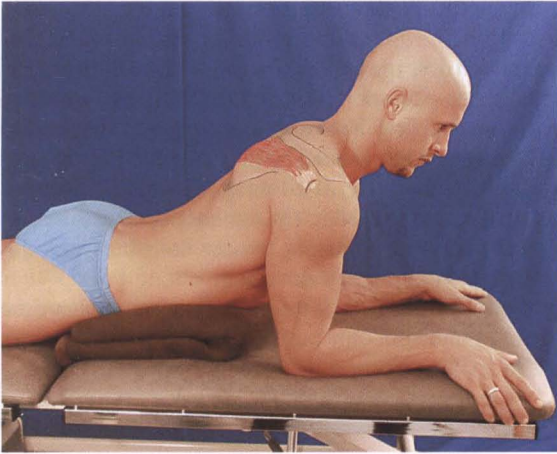


Fig. 2.18 SP—palpation of the infraspinatus.

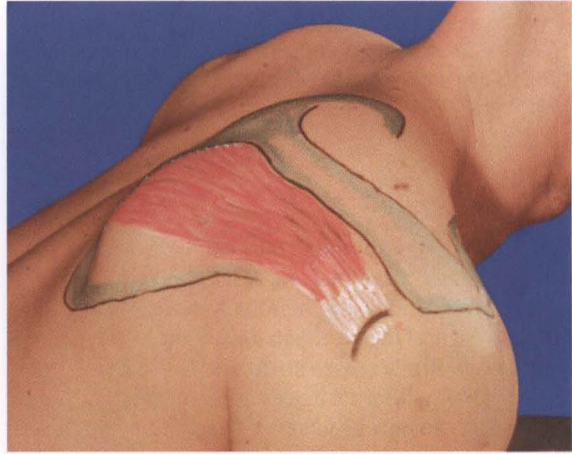


Fig. 2.19 Position of the infraspinatus.

Infraspinatus—Tendon and Insertion

Starting Position

The patient must be placed in a more complex position so that the therapist can reach the infraspinatus tendon and its site of insertion. The patient lies prone with the side to be palpated close to the edge of the treatment table (Fig. 2.18).

The patient supports themselves on the forearms and padding is placed underneath the abdomen to prevent an uncomfortable hyperlordosis. This SP results in approximately 80° flexion at the shoulder joint.

The joint is additionally placed in slight adduction (elbows about one hand-width away from the edge of the table) and lateral rotation (the hand holds onto the side of the table).

Flexion causes the otherwise inaccessible section of the greater tubercle to rotate posteriorly out from underneath the acromion.

Adduction places the infraspinatus tendon under tension and gives the tendon a firmer consistency.

This is advantageous when the tendon is being differentiated from the surrounding structures using palpation. When this technique is used for treatment, the tendon remains underneath the finger applying cross-frictions and does not slide out from underneath the finger (Fig. 2.19).

Alternative Starting Positions

The usual SP can cause discomfort in the cervical and lumbar spines despite padding in the abdominal area. Many massage therapists and physical therapists use other positions to avoid this problem:

- The patient lies flat on the stomach (not supporting themselves on the forearms). The affected arm hangs down over the side of the treatment table and the forearm rests on a stool (Fig. 2.20). The therapist then at-

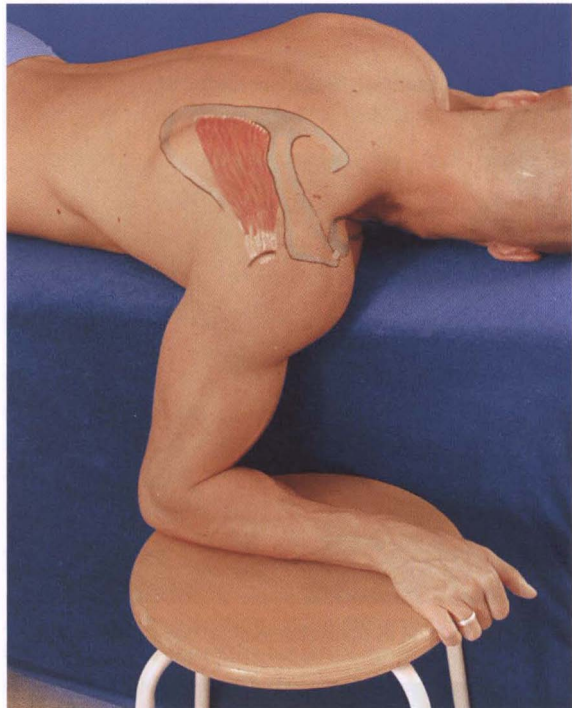


Fig. 2.20 Alternative SP

tempts to place the GH joint in slight adduction and lateral rotation again.

- The patient sits on a stool at the head end of the table. The head end of the treatment table is lowered and the arm is placed in the position described above, resting on the head end of the table (without figure).

Tip: All alternative positions are more comfortable for patients but are not particularly conducive for the localization of the tendon and the site of insertion. They have the drawback that insufficient axial pressure is applied to the humerus to tighten up the tendon. The tendon feels less firm underneath

the palpating finger and it is more difficult to differentiate it from the surrounding tissue and its insertion into the bone. The tendon gives way under the pressure applied during transverse friction.

Technique

The palpation starts at the already familiar posterior angle of the acromion (acromial angle, see Fig. 2.13). The wide infraspinatus tendon can be found approximately 2 cm from the angle of the acromion toward the axilla. The tendon is a flat, firmly tensed structure that reacts to transverse friction with a firm yet elastic form of resistance. The tendon can now be followed laterally toward the humerus until a hard structure is felt. The teno-osseous junction is found here, the insertion of the infraspinatus.

Method 1

Two different methods of transverse friction exist that can generally be applied to provoke pain or to treat.

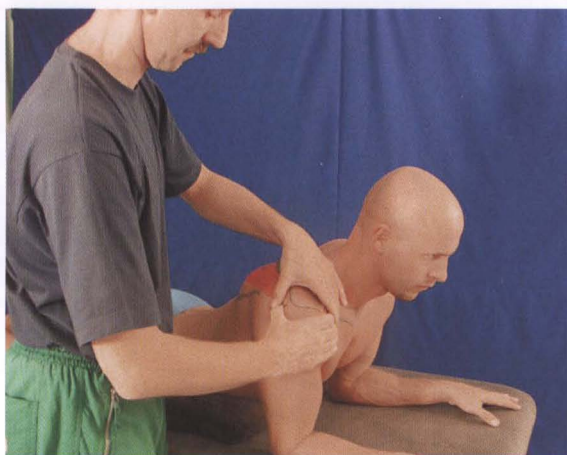


Fig. 2.21 Palpation as transverse friction: first method.

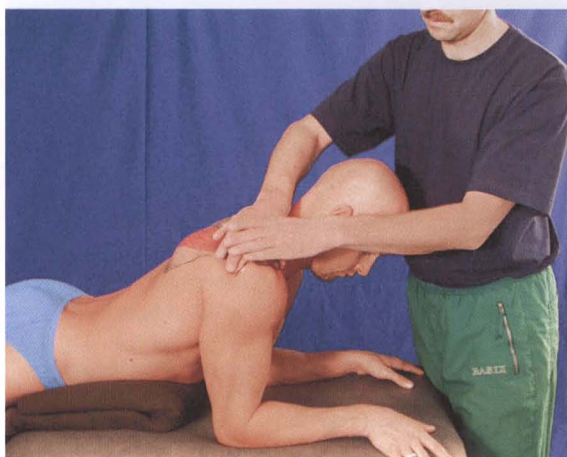


Fig. 2.22 Palpation as transverse friction: second method.

In the first method, the therapist stands on the side to be treated. The thumbs are positioned on top of each other and placed over the tendon. The fingers hold onto the coracoid process anteriorly (Fig. 2.21). The thumbs maintain skin contact, apply almost no pressure, and move inferiorly along the line formed by the axilla and the acromial angle. Pressure is increased once the thumbs are positioned deep in the tissues. The thumbs maintain this pressure and move back up along the line. Both forearms supinate slightly during this movement.

If the insertion is to be treated, the thumb applying the friction should not only push deep into the tissue; it also has to apply pressure laterally onto the humerus.

Method 2

As an alternative, the therapist may stand in front of the patient. The thumbs are now used to stabilize the hands and rest on the coracoid process (Fig. 2.22).

The index fingers are used for friction and are placed on top of each other over the tendon. Once again, no pressure is applied when moving down the above-described line. The palpatory or therapeutically effective part of the technique is conducted when pressure is applied during the upward movement (Fig. 2.23).

The main movement here is extension of the wrist. This method is less strenuous and is preferable over techniques that involve finger flexion.

Local Palpation—Lateral

Overview of the Structures to be Palpated

- Lateral edge of the acromion.
- Acromial spine.
- AC joint—anterior approach.
- AC joint—posterior approach.
- AC joint capsule.

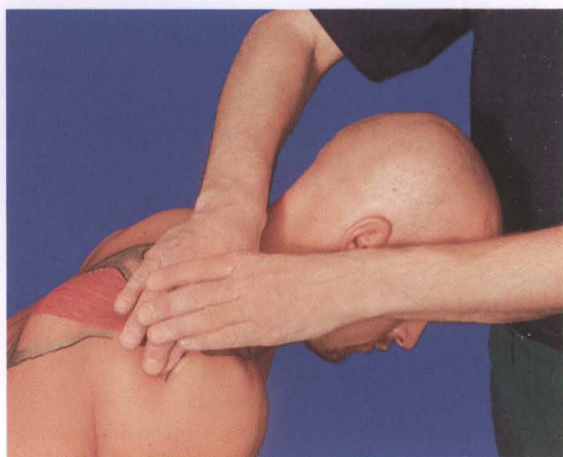


Fig. 2.23 Second method—detailed view.

Summary of the Palpatory Process

This region also contains important bony reference points that guide therapists to a variety of clinically pathological structures. The AC joint is the focus of palpation and the anterior and posterior access to this structure will be elucidated. The exact position of the AC joint is ascertained by palpating the capsule and depiction of the joint's position. This in turn increases confidence in locating the AC joint, as well as the diagnosis and treatment of problems in this region.

Starting Position

The patient sits on a chair or a treatment table with the shoulder girdle relaxed. The lateral region of the shoulder should be easily accessible. This SP is initially used when practicing palpation. Several assessment and treatment techniques require patients to be positioned in supine, side-lying, or prone position. Therapists should therefore also be able to correctly locate important structures in these SPs as well.

Advanced Starting Positions

The patient is not always in a sitting position when the source of shoulder girdle pain is being localized or when the AC joint is being treated. Therefore, it is recommended that the palpation be repeated in other SPs. This knowledge is of advantage when applying manual therapy treatment techniques that require therapists to locate the small joint space in unusual SPs and sometimes even without visual control.

With a little practice, it is not difficult to locate the AC joint space in the sitting position described above. Once therapists feel confident using this technique, other SPs can be chosen and the palpation repeated:

- Palpation of the AC joint in side-lying position.
- Palpation of the AC joint in supine position.

In both cases, palpation is conducted with a relaxed shoulder in full elevation. Arm elevation dramatically changes the joint space alignment. While the joint space has a posterior–anterior alignment when the shoulder is relaxed, concomitant rotation of the scapula during arm elevation changes its alignment so that it points more toward the point of the chin.

The lateral palpation is continued when therapists are familiar with the general and special orientation of anterior structures.

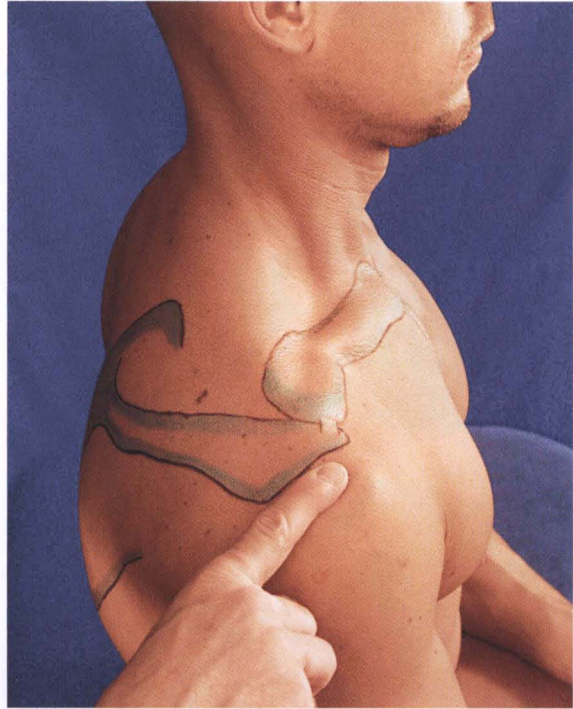


Fig. 2.24 Palpation of the edge of the acromion.

Lateral Edge of the Acromion

Starting at the angle of the acromion, the therapist attempts to follow the edge of the acromion anteriorly. It is not easy to palpate this edge exactly as it is undulated and jagged and its alignment changes a lot.

Technique

A perpendicular palpation technique is used here. Either the fingertips or the entire length of the fingers are placed on the edge of the acromion (Fig. 2.24).

Acromial Spine

The therapist can only follow the edge of the acromion to its anterior border, the acromial spine. This small rounded tip is an important reference point for orientation on the anterolateral aspect of the shoulder.

The therapist uses this point to gain access to the AC joint from anterior and to reliably access the site of insertion for the supraspinatus when the arm is repositioned.

Tip: It is easier to palpate the edge of the acromion and its anterior tip when the therapist pulls inferiorly on the upper arm so that the head of the humerus is distracted from the edge or spine of the acromion (Fig. 2.25).

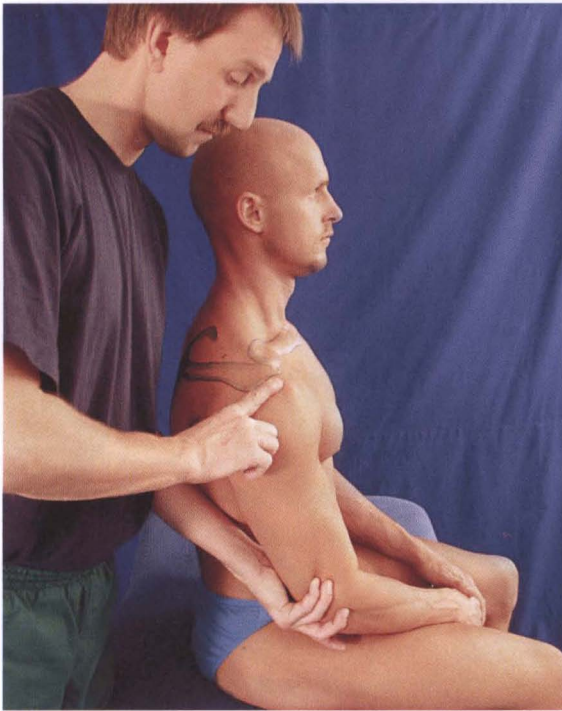


Fig. 2.25 Palpation of the edge of the acromion—with inferior traction of the humerus.

This improves reliability when palpating these structures and differentiating them from the head of the humerus. Manual therapists use the edge of the acromion for orientation when monitoring inferior gliding of the humeral head.

AC Joint—Anterior Approach

The palpation continues medially along the acromial spine. A small indentation is felt first, followed by bone. The fingertips encounter the clavicle at this point; the finger pads are resting in the “anterior V.” The tip of this V-shaped indentation usually points directly posterior. The anterior section of the AC joint capsule ends here.

Tip: This localization is difficult when the acromial spine is not palpated precisely and when the palpating finger does not follow the contours consistently in a medial direction. The most common mistake: the “anterior V” is presumed to be too far medially. The palpatory technique that has proven successful involves placing the medial side of the index finger downward on the patient so that the finger pad palpates the tip of the acromial spine and the fingertip the indentation marking the “V.”

AC Joint—Posterior Approach

The anterior point of access to the AC joint has already been pinpointed. The so-called “posterior V” is needed

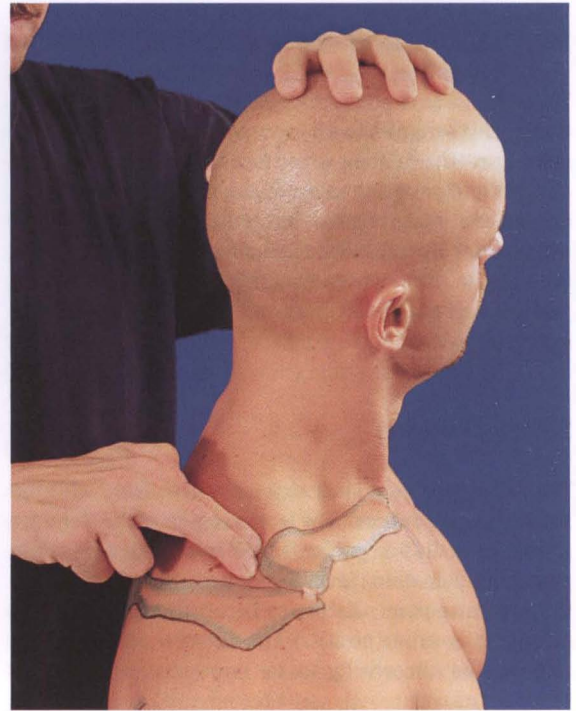


Fig. 2.26 Palpation of the posterior border of the clavicle.

to mark the further course of the AC joint. The laterally directed palpation along the superior border of the spine of the scapula and the posterior edge of the clavicle has already been described. Therapists will notice that the lateral end of the clavicle is significantly larger than generally expected based on the knowledge of topographical anatomy. In addition, the descending part of the trapezius is often quite tense and hinders access to the posterior border.

Technique

Step 1: Posterior Border of the Clavicle

The therapist begins palpating further medially to ensure that the posterior border can be well felt. The clavicle is then consistently followed further laterally using a perpendicular palpation technique.

To ease tension in the trapezius, the muscle is approximated by laterally flexing the head in an ipsilateral direction and rotating it in a contralateral direction. This facilitates palpation (**Fig. 2.26**).

Tip: Another reliable method to locate the posterior border is to palpate in an anterior direction from the superior border of the spine of the scapula. The clavicle must be the next bony structure that offers firm resistance.

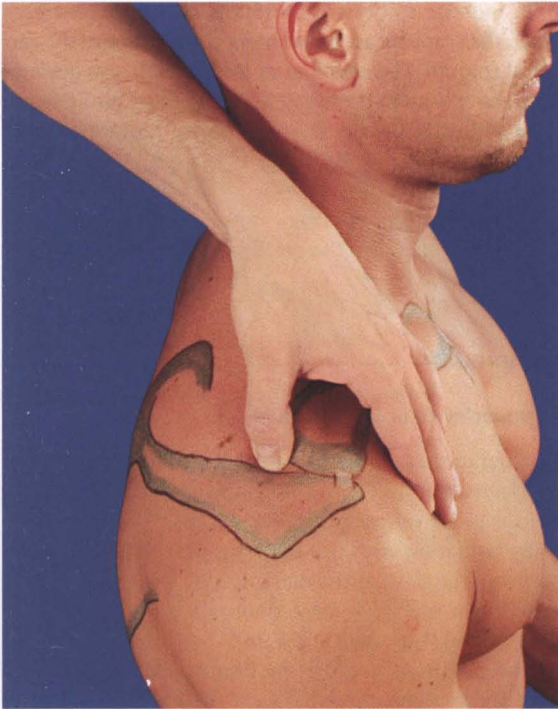


Fig. 2.27 Palpation of the “posterior V.”

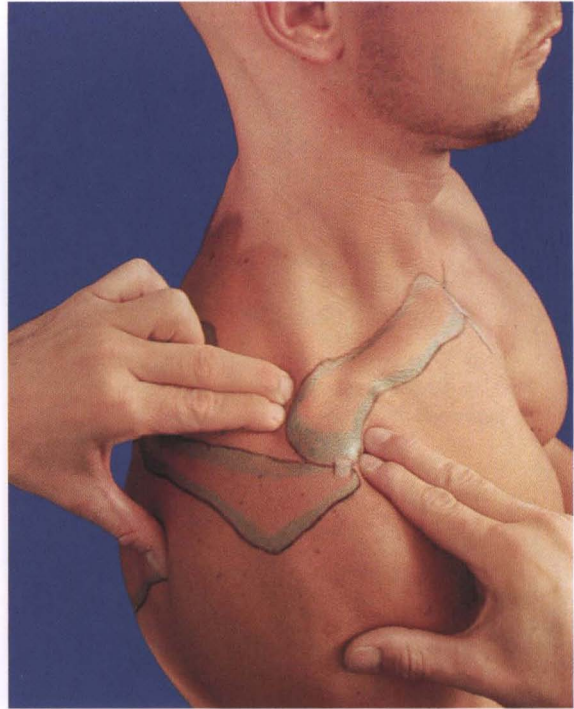


Fig. 2.28 Anterior and posterior borders of the clavicle.

Step 2: “Posterior V”

The “posterior V” is defined as the point where both palpable edges (superior border of the spine of the scapula and the posterior border of the clavicle) meet. The tip of this “V” points anterolaterally.

Therapists change their technique by placing one finger vertically between the border of the spine of the scapula and the border of the clavicle when they wish to locate this point exactly (Fig. 2.27).

The “posterior V” is found exactly at the point where both of these borders prevent the finger from pushing deep into firm-elastic tissue.

The entire dimensions of the lateral clavicle can be determined by following the anterior border of the clavicle from medial to lateral until the “anterior V” is reached (Fig. 2.28).

Its length is often underestimated.

Acromioclavicular Joint

The line connecting the tips of the two “Vs” corresponds to the general alignment of the AC joint space. Only the anterior section of this line (approximately 0.5–1 cm posterior to the “anterior V”) is used for orientation when locating the joint. Based on this information, the AC joint space is generally aligned anteriorly and often a little laterally (Fig. 2.29).

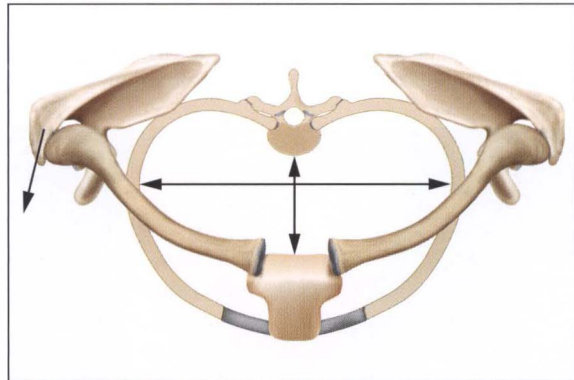


Fig. 2.29 Alignment of the AC joint space when the thorax is normal.

Therapists should also keep in mind that intra- and interindividual variations in the alignment of this joint space are highly probable. The degree of variation in alignment depends strongly on posture, the form of the thorax, and the corresponding position of the shoulder girdle. If the vertebral column is hyperkyphotic, the shoulder girdle hangs down more in protraction and the AC joint is clearly tilted, pointing in a more anteromedial direction (Fig. 2.30).

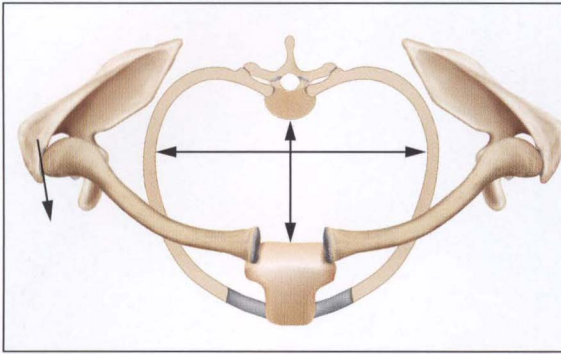


Fig. 2.30 Alignment of the AC joint space when the thoracic spine is hyperkyphotic.

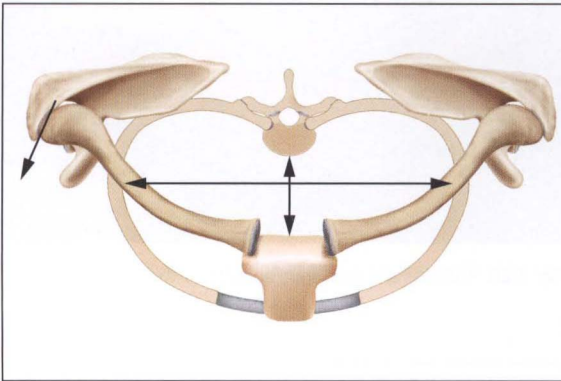


Fig. 2.31 Alignment of the AC joint space when the thorax is flat.

In thoracic spines with a loss of curvature (flat back type), the scapulae are found more medial toward the vertebral column. The shoulder girdle position also deviates from the “norm” in these cases. The shoulder girdle seems to be adducted and the AC joint space is positioned more in the sagittal plane (**Fig. 2.31**).

The procedure described above to locate the AC joint space is used for quick orientation and can be performed more specifically.

Technique

Acromioclavicular Joint Capsule

The therapist starts by palpating the posterior border of the clavicle and following the convex lateral end of the clavicle as it curves anteriorly (**Fig. 2.32**).

By palpating with the fingertip perpendicular to the border of the clavicle, the therapist will feel next a distinct step (finger pad is on the acromion and the fingertip on the clavicle) (**Figs. 2.33** and **2.34**).

The palpating finger is located directly over the AC joint space when the edge feels flattened and at a tilt and no longer like a step (**Figs. 2.35** and **2.36**). This tilted “ramp” is formed by the capsule and its reinforcements are filling up the “step.”

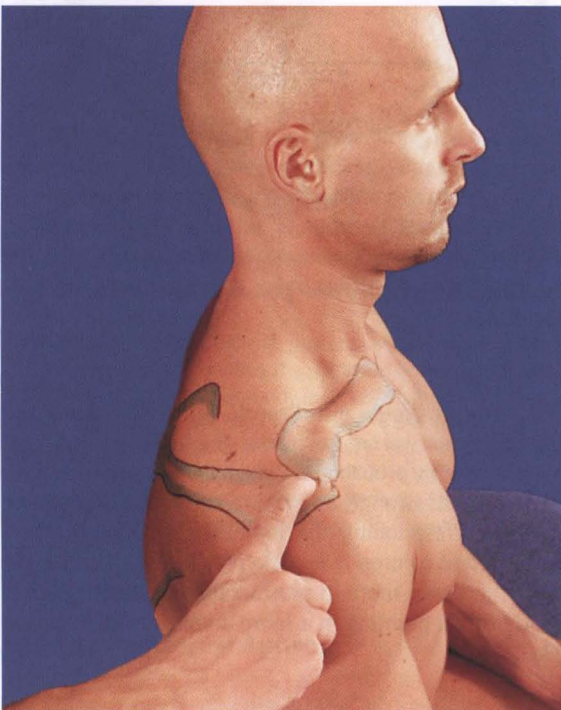


Fig. 2.32 Palpation of the AC joint.

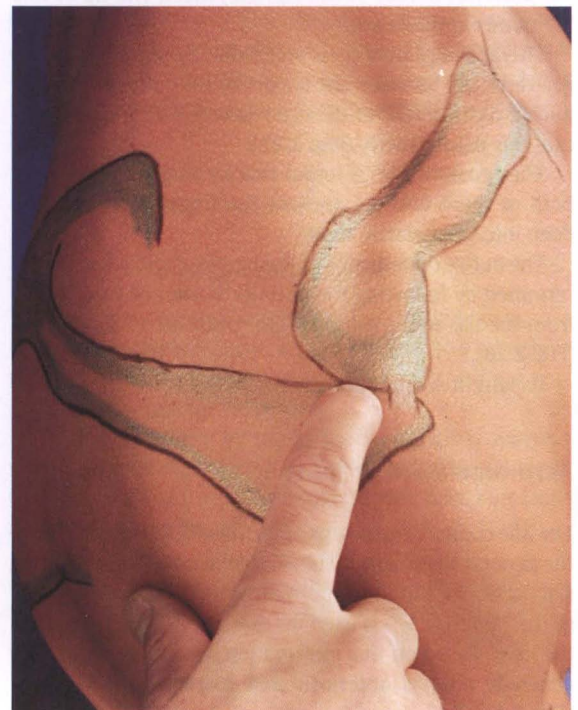


Fig. 2.33 Detailed view

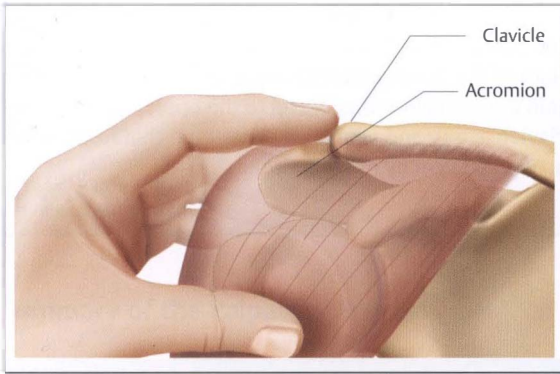


Fig. 2.34 Position of the palpating finger—step.

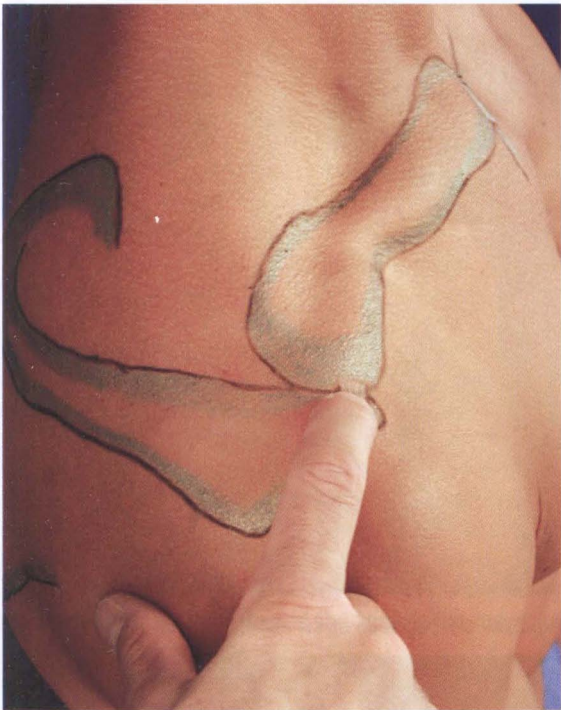


Fig. 2.35 Palpation of the AC joint capsule.

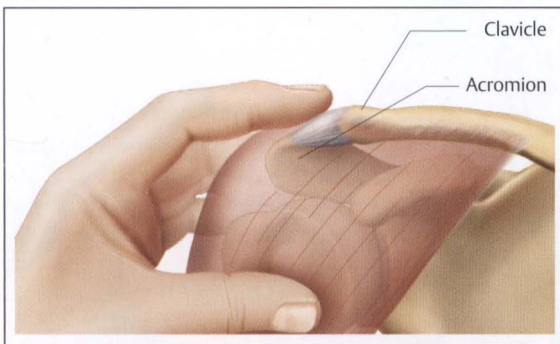


Fig. 2.36 Position of the palpating finger—ramp.

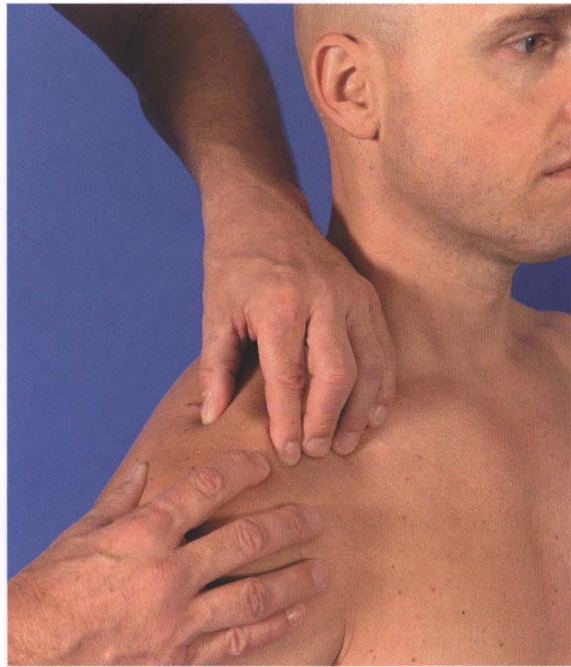


Fig. 2.37 Determining the general alignment and exact position of the AC joint.

Tips for Assessment and Treatment

Therapists use important bony reference points in this region to gain access to a variety of clinically pathological structures:

- The **acromial angle** is another point to start from when determining the dimensions and position of the acromion and is a reliable point to access anterolateral structures.
- The **lateral edge of the acromion** is used to differentiate the scapula from the head of the humerus (important for manual therapy techniques).
- Beginning at the **acromial spine**, the point of greatest clinical interest, the insertion of the supraspinatus as well as the anterior access to the AC joint are located.
- The **general alignment and exact position of the AC joint** has to be determined to successfully apply manual therapeutic techniques targeting the joint and Cyriax cross-frictions on the joint capsule (Fig. 2.37).

Dr. Cyriax's local cross-frictions on the joint capsule have been proven effective in cases of mild arthritis at the AC joint.

In addition to these therapeutic uses for local palpation, the localization of the AC joint forms an important basis for tests of joint play and manual therapy techniques at the AC joint. These techniques are usually applied parallel to the joint space. Knowledge of joint alignment ensures diagnostically conclusive tests and gentle joint mobilization.

General Orientation—Anterior

Starting Position

The patient sits upright with the shoulder girdle relaxed (**Fig. 2.38**). The therapist initially stands in front of the patient.

Supraclavicular and Infraclavicular Fossae

Before palpating specific structures, dividing the anterior shoulder complex into rough subdivisions aids orientation.

The curved length of the clavicle divides this region into depressions on the surface above and below the clavicle (supraclavicular and infraclavicular fossae) (**Fig. 2.39**). The anteriorly curving, convex section of the clavicle forms the inferior boundary of the supraclavicular fossa while its posteriorly curving section forms the superior boundary of the infraclavicular depression. The boundaries of the supraclavicular and infraclavicular fossae can be clearly observed when the muscles are active.

The therapist instructs the patient to raise the arm slightly from neutral. This activates the deltoid muscle in particular. The patient should then horizontally adduct the shoulder (when necessary, pushing against light resistance).

This additionally activates the pectoralis major muscle. Both of the muscular boundaries to the infraclavicular fossa become distinct.

The following structures form the boundaries for the **supraclavicular fossa** (see also Chapter 12, p. 353 f.):

- Inferior boundary = posterior border of the clavicle.
- Medial boundary = clavicular head of the sternocleidomastoid and scaleni muscles.
- Posterior boundary = descending part of the trapezius.

The following structures are found in the floor of the supraclavicular fossa: the first rib, the subclavian vein and artery as they pass through the anterior scalenus gap, the brachial plexus as it passes through the posterior scalenus gap, as well as the further course of these vessels and nerves up to the point where they travel beneath the clavicle.

The following structures form the boundaries for the **infraclavicular fossa**:

- Superior boundary = inferior border of the clavicle.
- Medial boundary = lateral edge of the clavicular head of the pectoralis major.
- Lateral boundary = medial edge of the clavicular part of the deltoid muscle.

This depression is also called the deltopectoral groove or the clavipectoral triangle. Blood vessels are found in the floor of this fossa medial to the anterior fibers of the deltoid muscle before they travel to the upper arm: the subclavian artery and vein, also named the thoracoacromial artery and vein by other authors.




Fig. 2.38 SP—palpation of the anterior aspect.

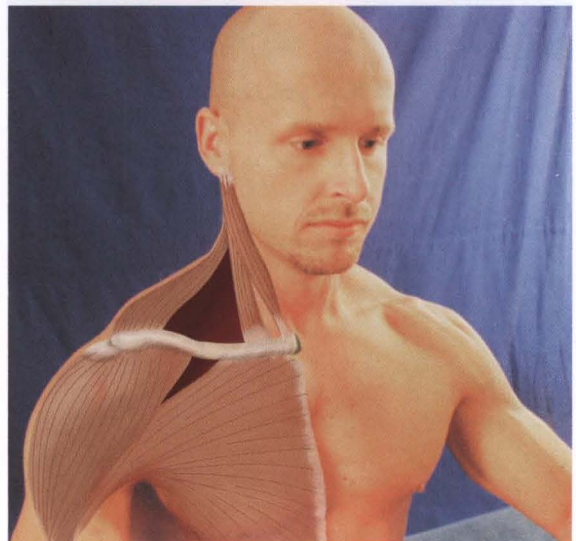

Fig. 2.39 Supraclavicular and infraclavicular fossae.

Local Palpation—Anterior

Overview of the Structures to be Palpated

- Sternocleidomastoid.
- Medial end of the clavicle.
- Sternoclavicular joint space.
- Infraclavicular fossa.
- Coracoid process.

Summary of the Palpatory Process

Certain structures on the anterior shoulder girdle are located quite medially and are used in particular to correctly locate the SC joint. The therapist then gains access to the anterolateral region where it is important that the infraclavicular fossa and coracoid process be precisely located.

Starting Position

The patient sits on a stool or a treatment table (see also Fig. 2.38). The therapist stands behind the patient.

Sternocleidomastoid

The therapist first makes the sternal head of the sternocleidomastoid more distinct by actively rotating the head to the opposite side (Fig. 2.40).

The clavicular head of the muscle will bulge out when the therapist slightly resists lateral flexion to the same side when the sternocleidomastoid is contracted. This head can be followed until it inserts into the medial third of the clavicle.

As a reminder: this muscle forms the medial boundary of the supraclavicular fossa and the anterior boundary of the anterior scalene gap.

Medial End of the Clavicle

The lateral aspect of the muscular cord and tendon of the sternal head of the sternocleidomastoid is palpated and continually followed until its insertion onto the manubrium (Fig. 2.41).

It inserts directly medial to the SC joint space. A bony structure can be clearly felt lateral to the tendon, just before it inserts onto the manubrium: this is the superior section of the medial end of the clavicle.

Approximately half of the increasingly wider end of the clavicle is found superior to the SC joint space when the shoulder girdle is positioned at rest (with the shoulder hanging down normally, Fig. 2.42).

These parts of the articular surface first come into contact with the sternal articular surface when the arm is raised. This is due to the inferior gliding of the clavicle

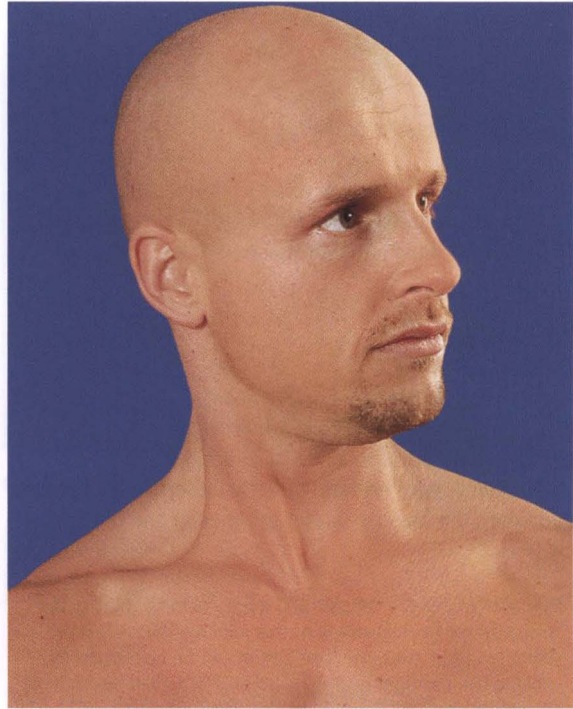


Fig. 2.40 Contraction of the right sternocleidomastoid.

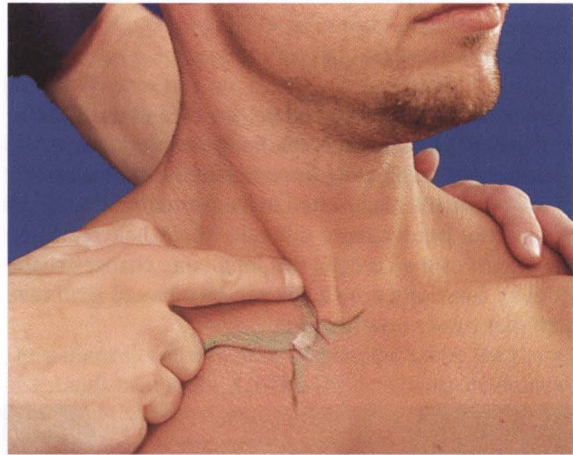


Fig. 2.41 Palpation of the sternocleidomastoid.

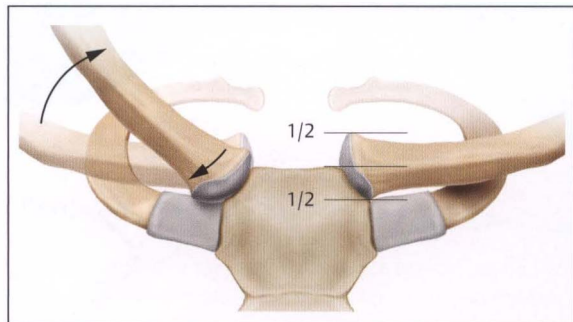


Fig. 2.42 Dimensions of the medial end of the clavicle.

when the arm is raised as a result of the applicable arthrokinematic convex rule.

Sternoclavicular Joint Space

Based on this information, it can be seen that the actual SC joint space is found further inferiorly. Its alignment can be described as superomedial to inferolateral.

Technique

The tendon of the sternocleidomastoid is precisely followed until the manubrium is reached. The palpating finger pads now point in a lateral direction.

The joint space is found directly underneath the finger pad when the finger palpates the medial end of the clavicle (Fig. 2.43).

Tip: Swelling of the capsule in patients with SC joint symptoms can make localization of this joint significantly more difficult. In this case, the localization can be confirmed by moving the shoulder girdle. This is best achieved by applying superiorly directed pressure to the elbow to elevate the shoulder girdle (Fig. 2.44).

Infraclavicular Fossa

Starting at the medial end of the clavicle and the SC joint, the therapist palpates laterally along the inferior border of the clavicle. The muscular insertion of the clavicular part of the pectoralis major often makes exact localization of the inferior border more difficult. About halfway along the length of the clavicle, this long bone changes shape from an anteriorly protruding convex curve to a concave arch that curves inward.

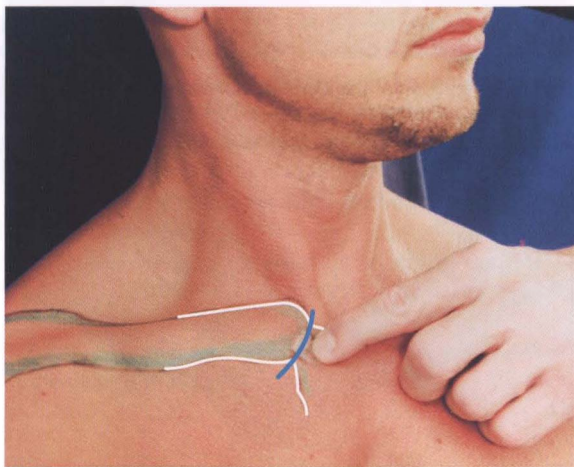


Fig. 2.43 Palpation of the SC joint space.

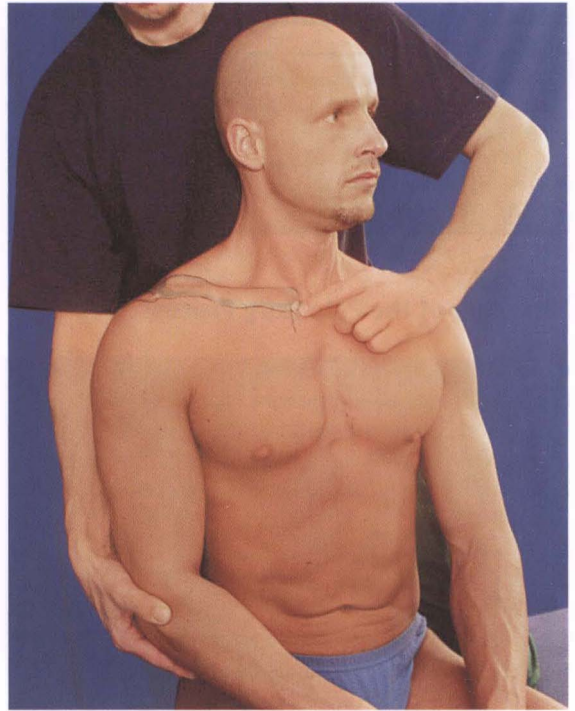


Fig. 2.44 Confirming palpation using shoulder girdle elevation.

The clavicle forms the superior boundary of the infraclavicular fossa, also called clavipectoral triangle, further laterally (see p. 34). The other boundaries are formed by the edges of the clavicular parts of the deltoid and pectoralis muscles (see also Fig. 2.39).

The infraclavicular fossa is the final anterior region to be palpated and is the starting point for the palpation of clinically important anterolateral structures.

As already discussed, it is especially easy to demonstrate the position of this fossa when the muscles actively adduct. The coracoid process forms the lateral osseous boundary of the fossa deep in the tissue. To find this prominent process, it is recommended that the procedure below be followed.

Coracoid Process

Starting Position

The patient sits on a chair or a treatment table. The therapist stands behind the patient. The arm hangs down next to the body and the forearm rests on the thigh so that the forearm is positioned approximately 30° medial to the sagittal plane. This corresponds to the physiological neutral position of the shoulder joint.

The infraclavicular fossa becomes distinct through horizontal adduction against resistance with the arm slightly raised.

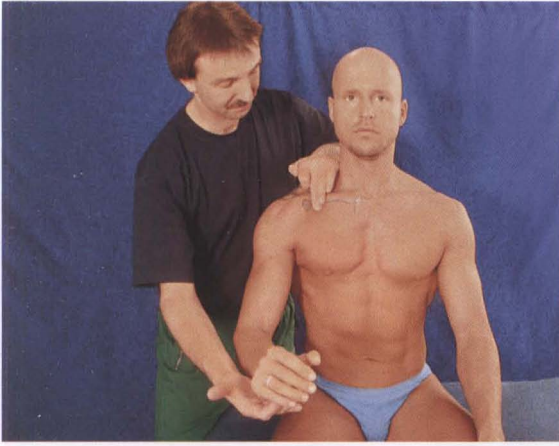


Fig. 2.45 Demonstrating the infraclavicular fossa.

Technique

The therapist palpates with the left hand for this localization. The right hand facilitates arm movement to position the shoulder joint as needed or to apply resistance to movement (Fig. 2.45).

Once the muscles are tensed, the palpating finger (the middle finger is preferred here; Fig. 2.46) is positioned in the fossa and remains there, even when the arm is moved back to the physiological neutral position and relaxes. The middle finger now applies pressure in a more lateral direction and the bony resistance of the lateral border of the coracoid process can immediately be felt.

This localization is the starting point for the palpation of other laterally positioned structures that will be described in the following section.

Tips for Assessment and Treatment

- Exact localization of the SC joint space is very helpful when palpating the separation of the articular surfaces during traction techniques of manual therapy.
- Degenerative processes are often diagnosed in the SC joint and involve active arthritic phases with periods of painful inflammation.
- Exact orientation on the anterior and lateral shoulder facilitates access to the lesser tubercle and the intertubercular sulcus of the humerus.

Local Palpation—Anterolateral

Overview of the Structures to be Palpated

- Borders of the coracoid process.
- Subscapularis tendon.
- Lesser tubercle of the humerus.
- Intertubercular sulcus and the greater tubercle of the humerus.

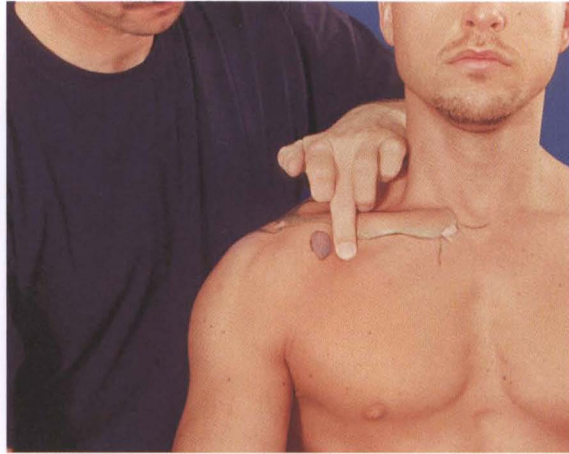

Fig. 2.46 Palpation of the coracoid process—medial border.

- Glenoid cavity.
- Supraspinatus insertion.

Summary of the Palpatory Process

The structures in this region are found in close vicinity to one another. Differentiation is sometimes quite difficult and is often only possible with movement of the joints.

The hand palpates from medial to lateral and encounters a new structure almost every centimeter.

Localization of the infraclavicular fossa and the coracoid process, as described above, are the starting points for access to the anterolateral region. Please also refer to the description for Fig. 2.39.

Starting Position

The patient sits on a chair or a treatment table. The therapist stands behind the patient. The arm hangs down next to the body and the forearm rests on the thigh so that the forearm is positioned approximately 30° medial to the sagittal plane. This corresponds to the physiological neutral position of the shoulder joint.

The right side will be palpated in the following text. In this exercise, the therapist's left hand palpates and the right hand facilitates shoulder movement via the patient's right arm to make it easier to find the structures in question.

Alternative Starting Positions

If the structures in the lateral shoulder region can be correctly found using these exercises, therapists should attempt to palpate in other, more difficult SPs, for example, patient in supine, arm elevation.

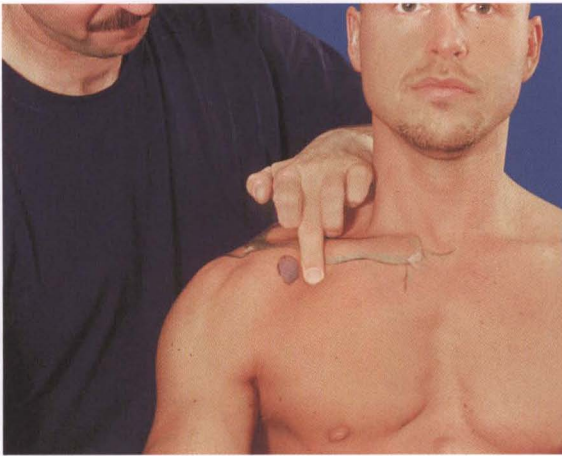


Fig. 2.47 Palpation of the infraclavicular fossa.




Fig. 2.48 Palpation of the coracoid process.

Borders of the Coracoid Process

Technique

The palpating finger (the middle finger here) is placed in the infraclavicular fossa and applies pressure laterally. The hard, bony resistance of the **lateral border** of the coracoid process can be felt (Fig. 2.47).

The index finger of the palpating hand is placed next to the middle finger and the pad of the index finger is now positioned **directly on top of the coracoid process** (Fig. 2.48).

The therapist continues palpating in a lateral direction. The left middle finger remains in the infraclavicular fossa.

Using pressure, the index finger moves approximately one finger-width laterally (Fig. 2.49). An obvious depression can be felt here between the **lateral border of the coracoid process** and the lesser tubercle of the humerus.

The therapist then identifies the boundaries of the tip of the coracoid process: from superior, inferior, and lateral (Fig. 2.50). It is surprising how large the coracoid process is.

Tip: Therapists may come into contact with sensitive structures when palpating. It is recommended that therapists be careful with the amount of pressure they apply.

As a reminder: four ligaments and three muscular structures are inserted at the coracoid process. It is a relay site for forces that stabilize the AC joint and pull the shoulder girdle anteriorly.

The inferior aspect of the coracoid process plays an important role when identifying the position and alignment of the glenoid cavity (see also Figs. 2.56 and 2.57).

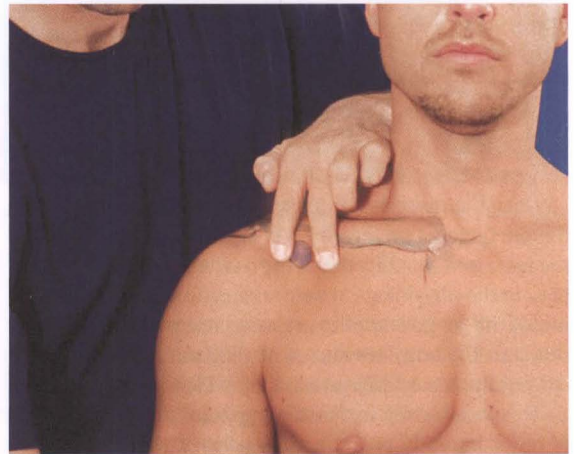


Fig. 2.49 Coracoid process—medial and lateral borders.

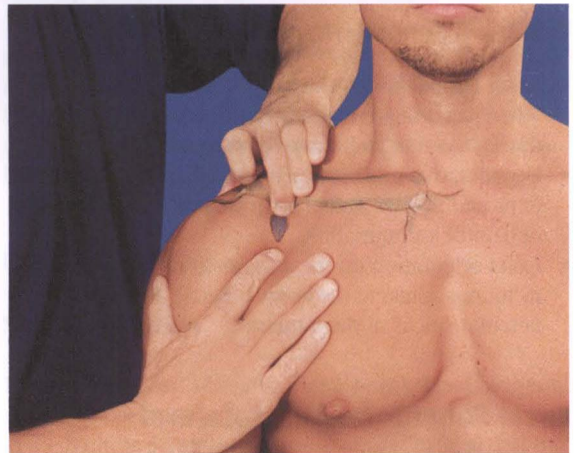


Fig. 2.50 Coracoid process—superior and inferior borders.

Comments and Exercises for the Coracoid Process

The coracoid process changes its position in relation to the clavicle during movement of the arm, especially during shoulder flexion. The following exercise is recommended to give therapists an idea of the position of the coracoid process during this movement.

One finger on the right hand palpates the coracoid process between its superior border and the clavicle. The other hand facilitates passive flexion of the shoulder. It becomes obvious that the tip of the coracoid process moves closer to the clavicle during this movement as the scapula increasingly rotates. This is cross-checked by extending the shoulder, and it is observed that the coracoid process moves away from the clavicle. However, this cannot be felt as clearly, since the scapular movement associated with shoulder extension is significantly smaller than that occurring with flexion of the shoulder. The fibers of the clavicular part of the deltoid also tense during this movement and hinder palpation.

Although the coracoclavicular ligaments are mainly viewed in connection with stabilization of the AC joint, their kinetic role also becomes clear now. The facilitated passive movement of the shoulder tenses the soft tissue surrounding the shoulder joint and the scapula follows the movement. The scapula first moves on the clavicle at the AC joint until the joint's ligaments are placed under tension and the clavicle starts to rotate. The palpating finger on the coracoid process registers this short latency time.

When the arm is elevated, the coracoid process tilts in a posterosuperior direction and the conoid ligament is placed under tension, causing the clavicle to rotate posteriorly. During shoulder joint extension, selective tension in the trapezoid ligament assists anterior rotation.

Subscapularis Tendon

Starting Position

The SP for the following palpation is the same as for the localization of the coracoid process (see **Fig. 2.45**).

Technique

An obvious depression marks the lateral edge of the coracoid process and can be felt underneath the index finger. The lesser tubercle of the humerus lies immediately lateral to this. Its location is confirmed by passively moving the hanging arm into medial and lateral rotation (**Fig. 2.51**). Only the lesser tubercle moves underneath the index finger during this movement. Needless to say, no movement is observed at the coracoid process.

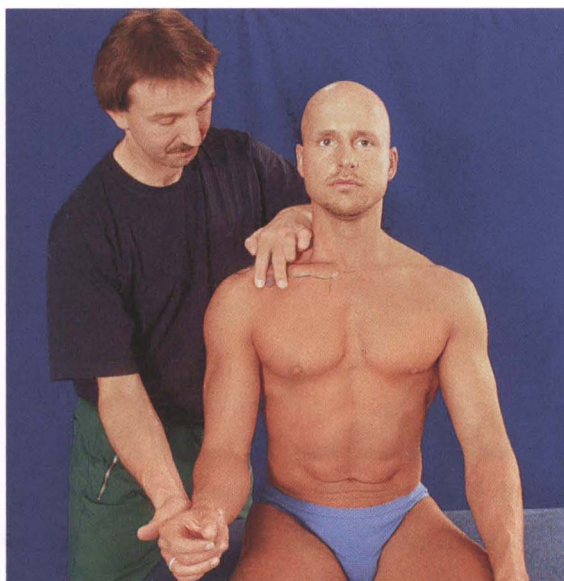


Fig. 2.51 Searching for the lesser tubercle of the humerus.

When the shoulder is positioned in end-range lateral rotation, the wide tendon of the subscapularis is placed under tension and pushes against the palpating finger so that it moves anteriorly onto the surface of the skin. When the palpating index finger applies more pressure to the tense tendon, the tendon responds with a very firm and somewhat elastic consistency.

Lesser Tubercle of the Humerus

The lesser tubercle is shaped like an upside-down teardrop. Its tip becomes thinner more inferiorly and merges into a ridge of insertion, the crest of the lesser tubercle. The intertubercular sulcus forms its lateral boundary.

Tips on Anatomy

The insertion of the subscapularis occupies the entire surface of the lesser tubercle. Superficial fibers extend from here as a transverse ligament over the intertubercular sulcus and ensure that the long tendon of the biceps brachii remains in the groove.

The insertion of the subscapularis tendon can be painful and inflamed as a result of overloading. It can also be trapped underneath the roof of the shoulder, resulting in a painful arc when the arm is raised.

The latissimus dorsi and teres major insert on the next distal structure, the crest of the lesser tubercle.

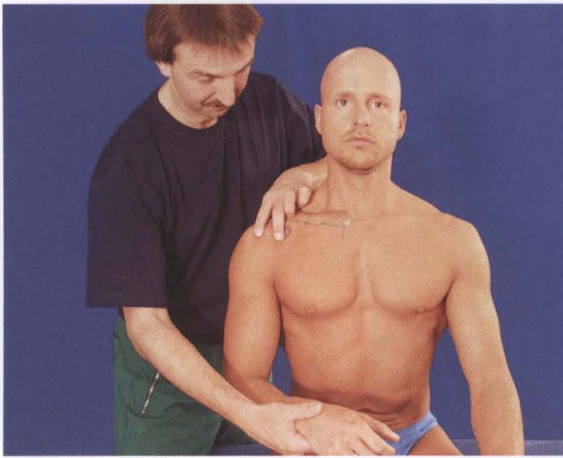


Fig. 2.52 Palpation—intertubercular sulcus.

Intertubercular Sulcus and the Greater Tubercle of the Humerus

Technique

Method 1

The sulcus can be palpated by moving the index finger further lateral across the lesser tubercle. By continuously passively rotating the arm medially and laterally, the therapist can confirm the position of the slender depression of the sulcus as it moves back and forth underneath the finger and can feel the edges of the sulcus (greater and lesser tubercles) (Figs. 2.52 and 2.53). This method is more difficult when parts of the deltoid are well developed.

Method 2

If the sulcus cannot be found using the direct method described above, the therapist can resort to using an indirect method. When the shoulder is actively abducted in the scapular plane (scaption), the sulcus is found directly underneath a gap in the deltoid muscle.

The patient is instructed to hold the shoulder in abduction in the scapular plane so that the intermuscular gap between the acromial and clavicular parts of the deltoid becomes distinct.

The palpating finger is positioned along the length of the intermuscular gap (Fig. 2.54).

The left index finger is used when the right side is being palpated.

The sulcus is found directly underneath the intermuscular gap in this position.

The index finger remains in the intermuscular gap while the arm is brought back to its SP (the neutral physiological position of the shoulder joint).

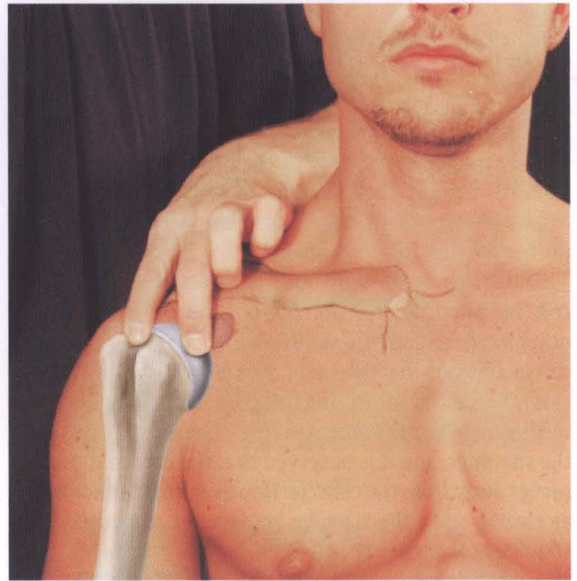


Fig. 2.53 Detailed view

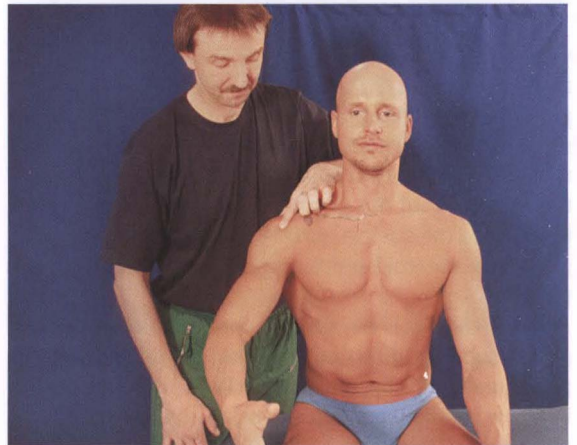


Fig. 2.54 Searching for the gap in the deltoid.

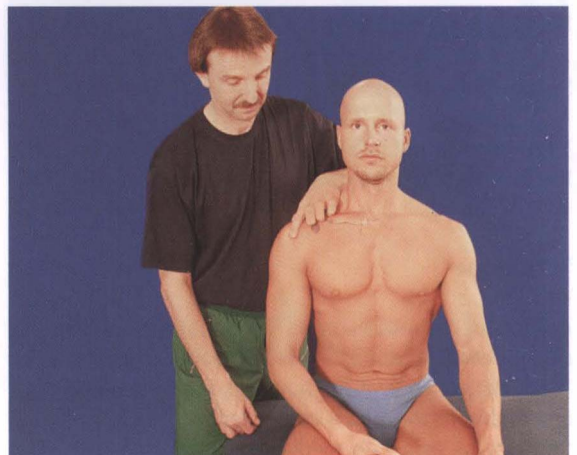


Fig. 2.55 Palpation of the intertubercular sulcus.

The palpating finger is most likely resting on the sulcus now (Fig. 2.55). The localization of the intertubercular sulcus underneath the index finger is confirmed by slightly moving the arm again.

Tips for Assessment and Treatment

The symptoms associated with tendon sheath disease at the long head of the biceps in the intertubercular sulcus are well known in soft tissue disorders of the shoulder. Treatment usually involves the use of local physical therapy techniques, including Cyriax cross-frictions. Treatment is only successful when palpation is precise.

The localization of the intertubercular sulcus should therefore be practiced with patients in other SPs.

Glenoid Cavity

Therapists are now familiar with all structures needed to fully describe the alignment of the shoulder joint socket in space. Its position is a result of the scapula adapting to the shape of the thorax. The glenoid cavity usually opens laterally, anteriorly, and slightly superiorly, and is a direct extension of the spine of the scapula.

It is angled at approximately 20–30° anteriorly away from the frontal plane. This angle is very much dependent on the individual shape of the thorax. The glenoid cavity faces more lateral when the back is flat and more anterior when the thoracic spine is hyperkyphotic. This alignment may also change in the different SPs. When the patient lies prone, supine, or on the side, the position of the scapula on the thorax and the resulting spatial orientation of the glenoid cavity changes.

Hence, therapists need landmarks for reliable orientation to determine the exact alignment of the joint socket. This can only be defined using a connecting line. The ends of this line will be located now: the acromial angle and the inferior aspect of the coracoid process.

Technique

The right thumb is placed over the posterior angle of the acromion (acromial angle) and the index finger is placed on the inferior aspect of the coracoid process. The line connecting these points defines the alignment of the glenoid cavity.

This line travels from posterolateral to anteromedial when viewed from above (Fig. 2.56) and travels anteriorly at a slight angle when viewed from the side (Fig. 2.57).

This illustrates the angle of the glenoid cavity in the sagittal plane.

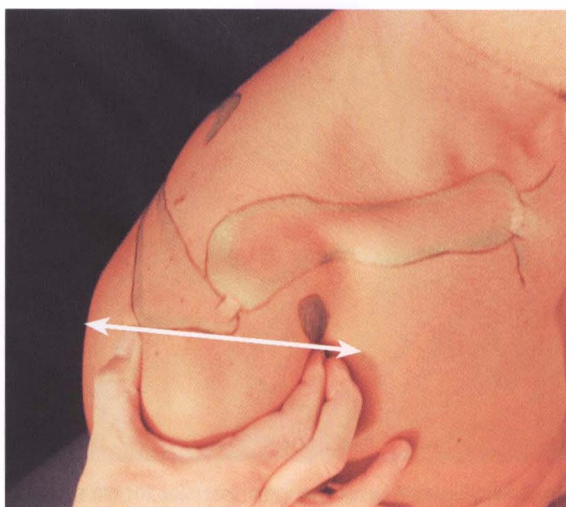


Fig. 2.56 Alignment of the glenoid cavity—superior view.

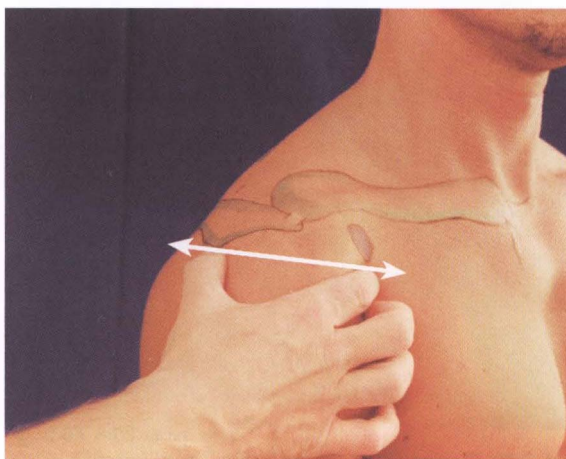


Fig. 2.57 Alignment of the glenoid cavity—lateral view.

Alternative Starting Positions

If therapists find it easy to determine the alignment of the glenoid cavity when the shoulder is at rest, they should practice locating the connecting line with the patient in other SPs or the arm in other positions (e.g., full elevation). Each time they do this, they should attempt to visualize the position of the glenoid cavity in space.

Tips for Assessment and Treatment

It is extremely important that manual therapists be able to exactly identify the plane of the glenoid cavity for the assessment of joint play and the application of manual therapeutic glides. Accordingly, posterior–anterior gliding of the humeral head in the glenoid cavity means that the glide must be directed anteriorly, medially, and slightly inferiorly. If the therapist does not glide the hum-

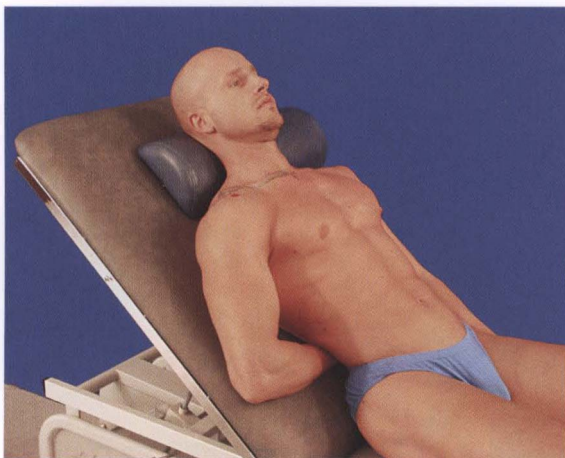


Fig. 2.58 SP—palpation of the site of insertion for the supraspinatus.

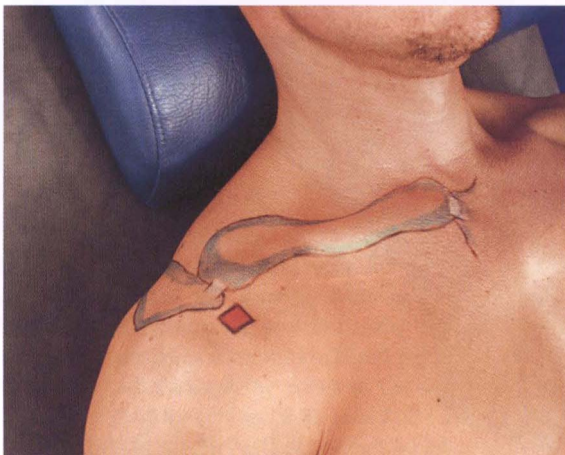


Fig. 2.59 Position of the supraspinatus—site of insertion.

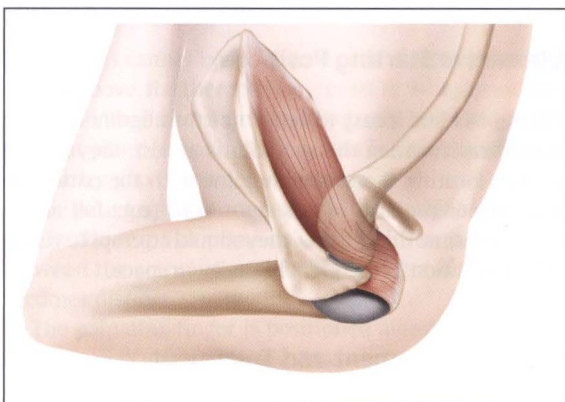


Fig. 2.60 Position of the site of insertion in this SP.

eral head exactly along this line, the test results will not be diagnostically conclusive.

During mobilization of the humerus using anterior-posterior gliding, it is often observed that the direction of the glide is not lateral enough and that sensitive structures such as the glenoid labrum are in danger of being compressed.

Supraspinatus—Insertion

The outer sections of the greater tubercle can be palpated, in sitting position, lateral to the intertubercular sulcus (see also **Fig. 2.53**). These parts are of little clinical interest though. When the shoulder is positioned in its neutral physiological position, the important sites of insertion for the supraspinatus and infraspinatus are found underneath the acromion and cannot be reached.

Starting Position

To make the site of insertion of the supraspinatus accessible, the anterior facet of the greater tubercle must be moved anteriorly. This is achieved by moving the patient's shoulder into extension, slight abduction, and significant medial rotation, so that the back of the hand is resting on the lumbar spine.

The patient then leans back on the foot end of the treatment table so that the upper body is angled at approximately 60° to the horizontal (**Fig. 2.58**).

The approximately 1-cm²-large site of insertion is of great clinical importance and is now found directly anterior to the spine of the acromion on the small osseous horizontal plateau on the humerus (**Figs. 2.59** and **2.60**).

Technique

To find the insertion, the therapist follows the edge of the acromion from the posterior angle to the anterior tip (see p. 29 and the description for **Fig. 2.25**). The palpating index finger should now be positioned so that the finger pad is lying on the bony, approximately 1-cm²-large plateau with the edge of the index finger in contact with the tip (**Fig. 2.61**).

When the finger palpates further anteriorly or medially it slides down from the plateau. The localization is only correct directly in front of the tip of the acromion.

Tips for Assessment and Treatment

Cyriax's cross-frictions are administered when this palpation is being used to provoke pain in the assessment and/or treatment of insertion tendinopathy. The index finger is placed on the skin and moves medially for a short dis-

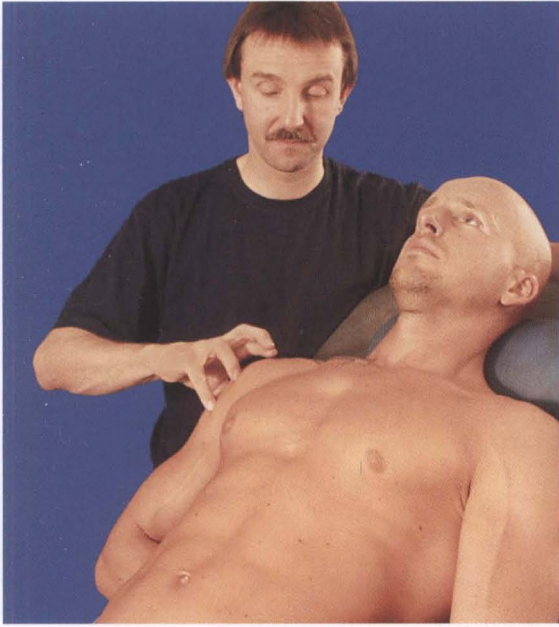


Fig. 2.61 Patient and therapist SPs, position of the hand.

tance, applying only a minimal amount of pressure. Once on the plateau, the finger pushes deeper into the tissues and moves laterally without rubbing the skin (Figs. 2.62 and 2.63). Increased pressure is applied to provoke pain; for treatment, the technique is applied subclinically in per-second increments.

Therapists should always be aware that the palpating finger is never in direct contact with the site of insertion. Deltoid muscle bundles and the subacromial/subdeltoid bursa lie superficial to the insertion. These structures can also be inflamed and painful.

Therapists can only be certain that painful palpation of this region is due to a supraspinatus insertion tendinopathy by appropriately assessing the function of the shoulder joint.

Tips:

- It is sometimes difficult to find the tip of the acromion. The patient's SP is no longer upright-sitting and the therapist has to palpate through the stretched anterior sections of the deltoid muscle. It is recommended that the tip be located first followed by the positioning of the arm.
- To make the palpation ergonomical, it is also recommended that the treatment table be sufficiently elevated and that the therapist stand behind the patient's shoulder.

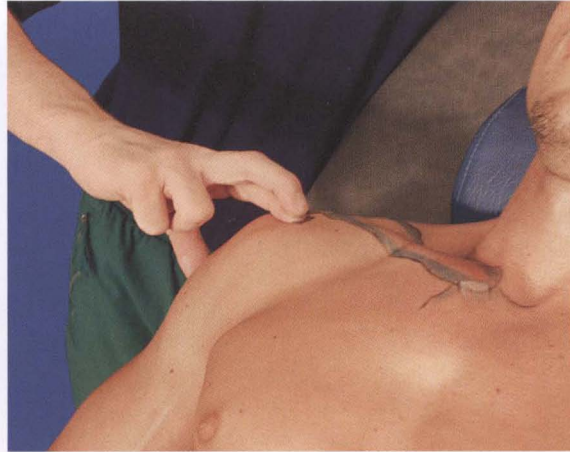

Fig. 2.62 Technique—transverse friction at the supraspinatus.

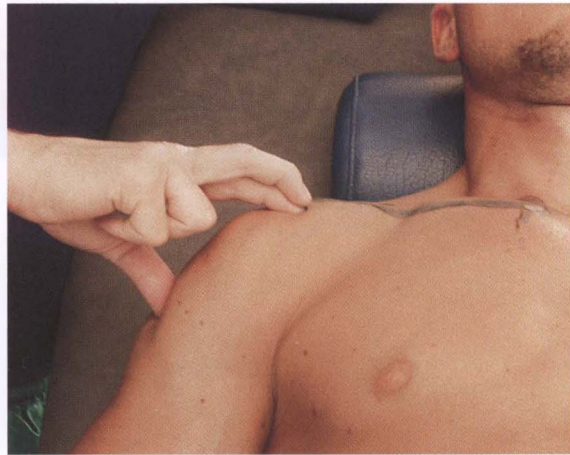


Fig. 2.63 Alternative view

Study Questions

1. Which structures form the infraclavicular fossa?
2. Which muscle is used for orientation when searching for the SC joint space?
3. How can therapists help themselves find the intertubercular sulcus?
4. The anterior tip of the acromion is an important reference point. Which structures can be reached from here?
5. At which bony reference point should therapists start looking for the infraspinatus tendon?
6. What is the alignment of the SC joint space?
7. Which scapular movement can be assessed by looking at the inferior angle?
8. How can the edge of the acromion be better differentiated from the head of the humerus?
9. How does the therapist make the clinically important insertion of the supraspinatus on the greater tubercle accessible?
10. What is the general alignment of the glenoid cavity?

3 Elbow Complex

- Significance and Function of the Elbow Complex ... 47
- Common Application for Treatment in this Region ... 47
- Required Basic Anatomical and Biomechanical Knowledge ... 47
- General Orientation—Anterior ... 49
- Local Palpation—Anterior ... 49
- Local Palpation—Medial ... 54
- Local Palpation—Lateral ... 59
- General Orientation on the Posterior Humerus ... 65
- Study Questions ... 68

THIS PAGE INTENTIONALLY
LEFT BLANK

3 Elbow Complex

Significance and Function of the Elbow Complex

The function of the middle joint of the upper limb (elbow joint) is to increase or decrease the distance between the hand and the body or face. Further, rotation of the hand occurs in the forearm, and is the most significant functional and anatomical difference between this joint and the middle joint of the lower limb, the knee joint.

Flexion and extension mainly take place in the humeroulnar joint (HUJ). The most important joint for controlling rotation of the hand is the proximal radioulnar joint (PRUJ). The humeroradial joint (HRJ) merely functions as an adapter between the center for flexion/extension in the HUJ and the rotational movements of pronation/supination in the PRUJ.

All three joints are found within a capsule that provides sufficient freedom of movement for the very large range of flexion/extension and lateral stability when the elbow is extended. The capsule also holds the radius on the ulna.

Massage therapists and physical therapists find it difficult to locate the bones in the elbow joint complex. Most bony structures can only be reached on the lateral and posterior aspects of the joint. Apart from a few exceptions, the joint space is usually hidden underneath well-developed soft tissue. It is therefore necessary to enlist the help of guiding muscles and spatial relationships to locate the joint. By way of example, when therapists want to reach the anterior radius they must orient themselves on the medial edge of the brachioradialis, then palpate from this point deep into the tissues.

The accuracy of hand placement, for example, for manual therapeutic tests of joint play, depends on the localization of the bony components of the joint and the perception of how articular surfaces are spatially positioned.

In addition to the intricate bony structure, the elbow joint is also characterized by an arrangement of many, at times slender, muscles, that can be subdivided into one extensor and more than 12 flexors. The flexion synergists are particularly symptomatic in overuse syndromes of tendons and insertions, and present therapists with the challenge of trying to find the exact location of the lesion.

These synergists originate on or near the epicondyles of the humerus. Their main actions mostly affect movement of the wrist and fingers.

Common Application for Treatment in this Region

A wide variety of techniques are used to assess and treat the elbow joint, including blood-pressure measurement, testing reflexes in the biceps and triceps, electrotherapy and cryotherapy, as well as local transverse friction and manual therapeutic techniques applied to the individual parts of the joint.

Required Basic Anatomical and Biomechanical Knowledge

When therapists draw on their knowledge of anatomy during continuing education courses covering the elbow joint, they often find their conception of the three-dimensional construction of bones, articular surfaces, and muscles is more vague than concrete.

Precise palpation used to recognize and differentiate deep-lying structures is only valuable if therapists can relate the findings to existing knowledge of topographical relationships. When searching for structures, therapists therefore need to have a good idea of how the bones of the elbow joint are spatially positioned. They must be able to visualize and identify the most important structures from different perspectives (Figs. 3.1 and 3.2).

In particular, the name and position of muscles originating from the epicondyles are required as soft-tissue lesions at the elbow joint are one of the most common sets of symptoms presenting in the physical therapy practice (Figs. 3.3 and 3.4).

Nerves and blood vessels play a less significant role when viewing the elbow complex, from a therapist's point of view. Therapists should nevertheless realize that all three of the main nerves responsible for the innervation of the forearm and the hand pass by the elbow joint. Each of these nerves travels through a passage in the muscles, which may become narrower and cause compression of the nerve (Fig. 3.5).

The **radial nerve** travels posteriorly along the humerus in the radial groove, crosses over the elbow joint anteriorly, and passes through two sections of the supinator muscle.

Blood vessels and the median nerve are found in a soft-tissue groove on the medial side of the biceps brachii, the bicipital groove. The **median nerve** passes over the middle

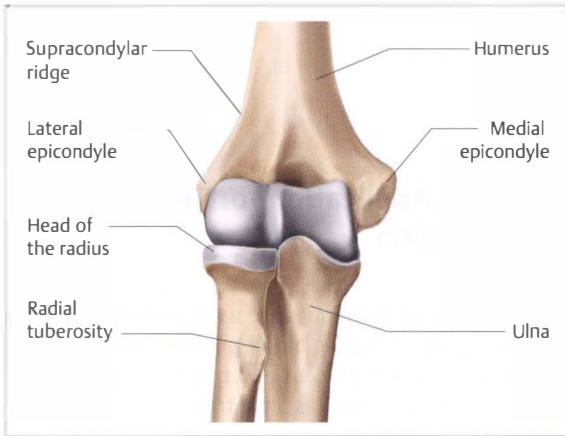


Fig. 3.1 Topography of the bones—anterior view.

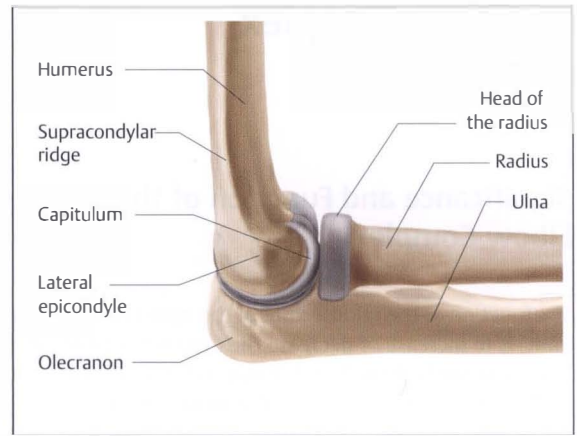


Fig. 3.2 Topography of the bones—lateral (radial) view.

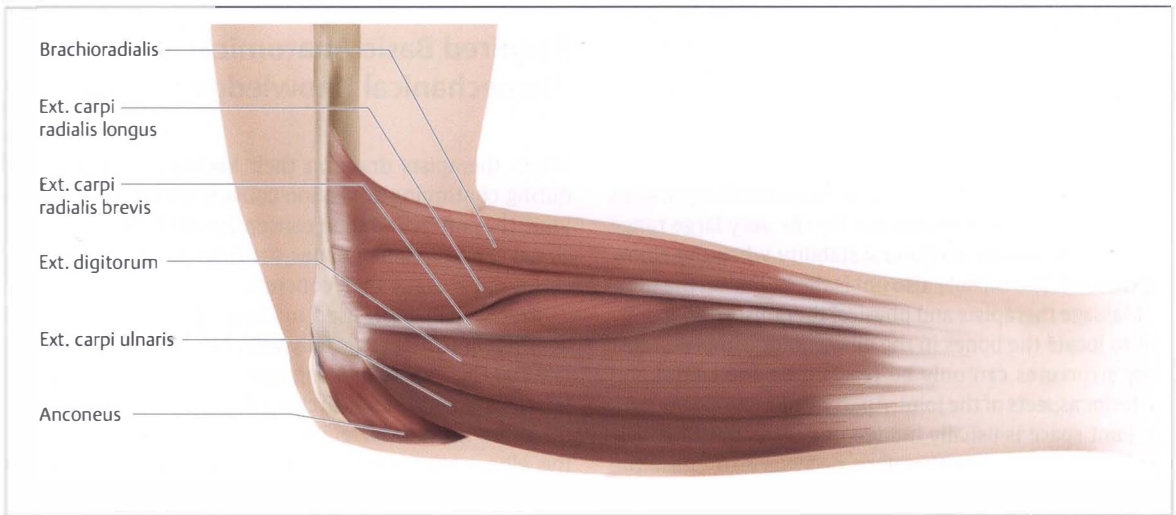


Fig. 3.3 Topography of the muscles—lateral (radial) view.

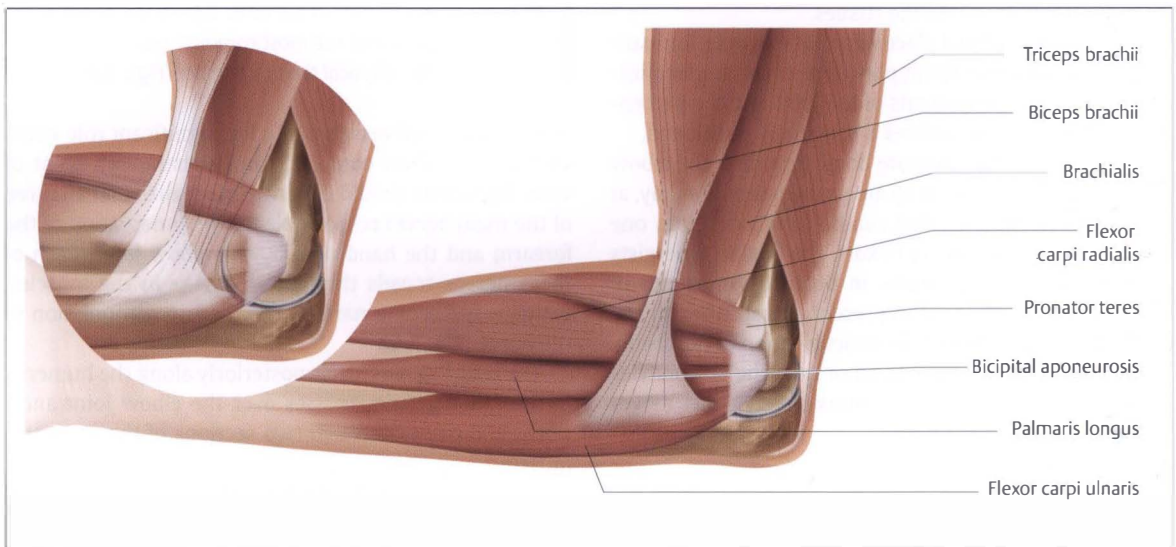


Fig. 3.4 Topography of the muscles—medial (ulnar) view.

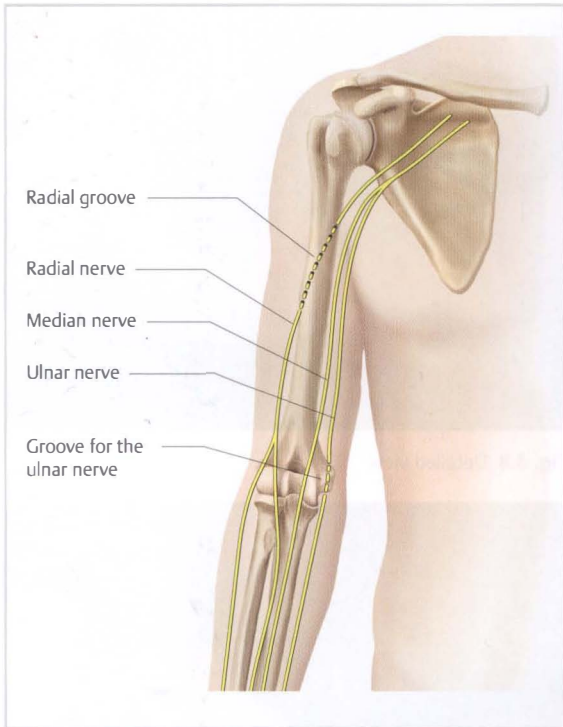


Fig. 3.5 Pathways of the most important peripheral nerves of the arm.

of the elbow joint in the cubital fossa, then penetrates the two bellies of the pronator teres.

The groove for the ulnar nerve is the most well-known neural passage at the elbow. The **ulnar nerve** is the only large peripheral nerve of the arm that crosses over the posterior side of the elbow. The further sections of the nerve are very rarely compressed by the fascia of the forearm and the neighboring muscle belly (flexor carpi ulnaris).

General Orientation—Anterior

Boundaries of the Cubital Fossa

The cubital fossa has a triangular shape. The following structures form its boundaries (**Fig. 3.6**):

- The muscle belly and the tendons of biceps brachii and brachialis proximally (1).
- Brachioradialis laterally (2).
- Pronator teres medially (3).

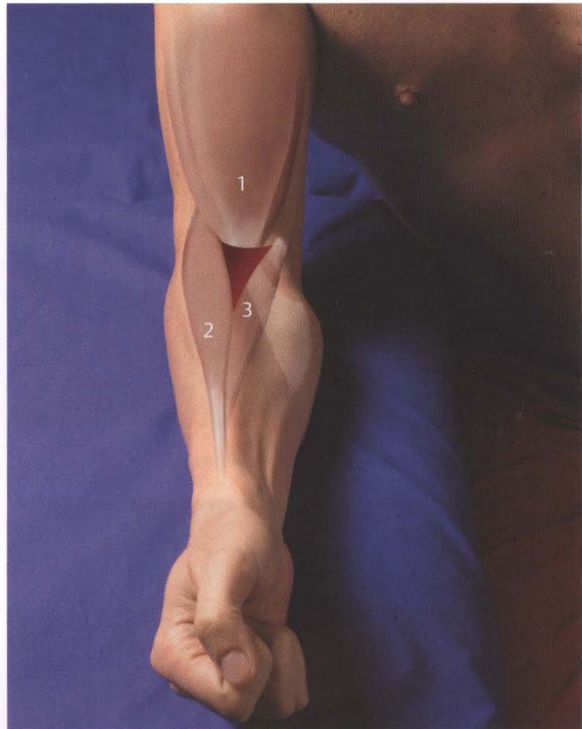


Fig. 3.6 Position of the cubital fossa.

Local Palpation—Anterior

Overview of the Structures to be Palpated

- Humerus—medial shaft.
- Muscle belly and tendons of the biceps brachii.
- Blood vessel and nerve bundle.
- Pronator teres.
- Brachioradialis.
- Proximal radioulnar joint (PRUJ).

Summary of the Palpatory Process

The different structures involved in the formation of the cubital fossa are located by first palpating the medial aspect of the humerus.

The medial structures of the upper arm can be followed in two directions:

- The therapist first palpates inferiorly and anteriorly in the cubital fossa.
- Description of the palpation in an inferior and medial direction follows.

In particular, therapists search for a bundle of nerves and vessels located medially, which will guide them to the anterior aspect of the elbow joint.

Finally, the individual structures of the cubital fossa are differentiated from one another.

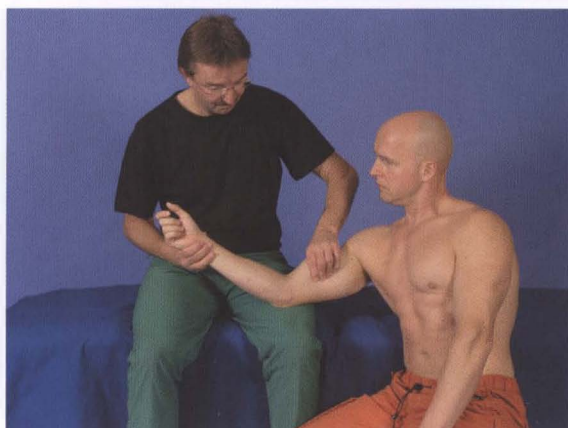


Fig. 3.7 SP for palpation of the anterior aspect.

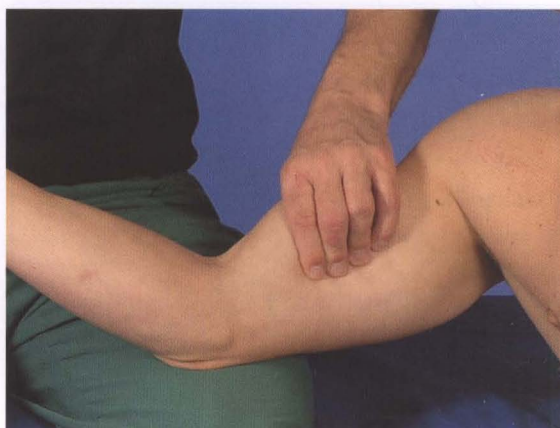


Fig. 3.8 Detailed view

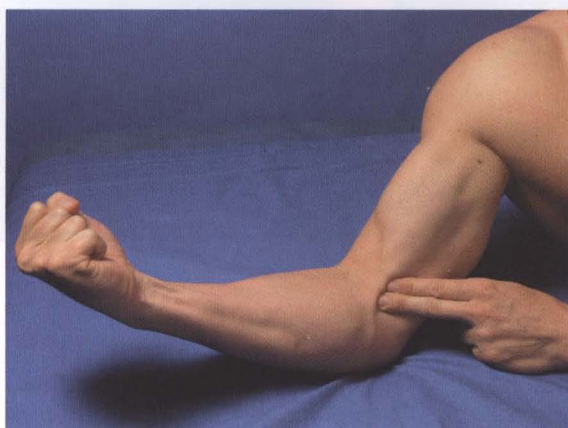


Fig. 3.9 Self-palpation of the arm—for practice purposes.

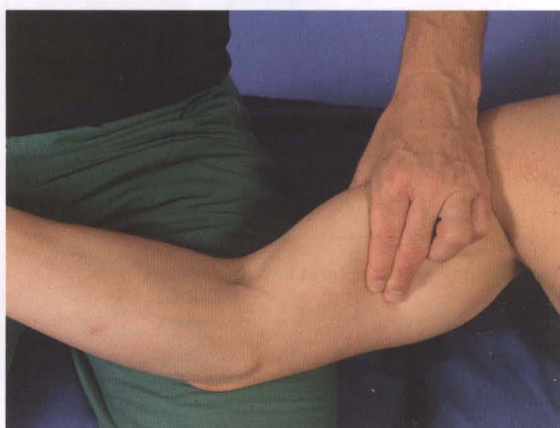

Fig. 3.10 Palpation of the medial humerus.

Starting Position

The following starting position (SP) is suitable when practicing: the therapist sits on a treatment table. The patient sits on a stool in front of the table with the elbow resting on the therapist's thigh. The elbow joint is flexed and placed in mid-position between pronation and supination, during which the cubital fossa should always face upward. The upper arm is now positioned in neutral rotation (Figs. 3.7 and 3.8).

This unusual SP has two main advantages when palpating the medial humerus and the cubital fossa:

- The areas to be palpated are freely accessible.
- It is easy to place the elbow joint in other positions.

The latter point is advantageous when the palpation is confirmed using joint movement or when certain muscle or nerves are initially elongated and placed under tension.

Alternative Starting Positions

Naturally, other positions can be used to reach the following structures. Therapists can practice on their own elbow complex with the opposite hand (Fig. 3.9).

Humerus—Medial Shaft

Technique

Large areas of the medial and lateral aspects of the humerus can be accessed between the anterior elbow flexors and triceps brachii. This is achieved on the medial aspect by placing the hand flat over the flexors and lifting up the flexor mass so that the finger pads are resting on the humerus. Please refer to the technique shown in Fig. 3.10.

This palpation technique locates the shaft of the humerus very quickly, and several thin structures can be observed running along the length of the shaft. Transverse palpation to the humerus is used here, that is, anterior-posterior. When palpating posteriorly, the therapist

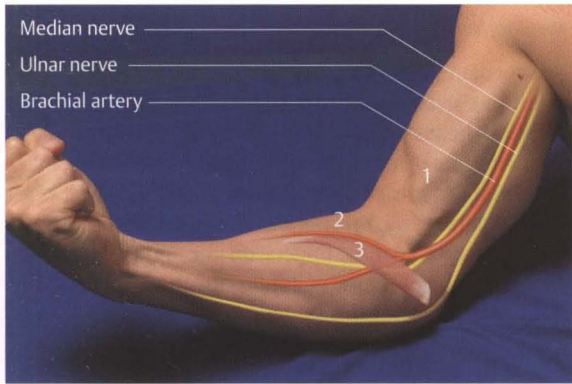


Fig. 3.11 (1) Biceps brachii. (2) Brachioradialis. (3) Pronator teres.

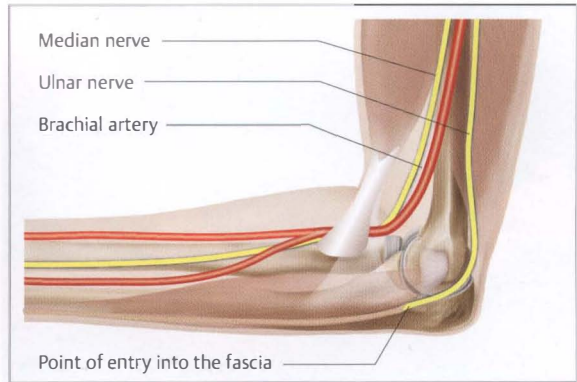


Fig. 3.12 Nerves and blood vessels—medial (ulnar) view.

comes across the soft tissue of the triceps brachii, which is separated from the flexor side by a very firm intermuscular septum.

Tip: As nerves and vessels accompany these structures, the palpation should be very flat and applied with the appropriate amount of pressure. The humerus and the neurovascular bundle are easily accessible in almost every upper arm from the axilla to the medial epicondyle.

Muscle Belly and Tendons of Biceps Brachii

The contours of the biceps muscle can usually be felt quite well when the muscle is active. The medial edge guides therapists to the bundle of nerves and vessels as well as certain structures in the cubital fossa.

Technique

Bicipital Aponeurosis

The therapist searches for the muscle–tendon junction of the biceps brachii—see **Fig. 3.11(1)**—during muscle contraction. The muscle belly becomes thinner more distally. The therapist hooks around the tendon from medial and palpates the tendon as a wide, solid plate (bicipital aponeurosis). The edge is very sharp and the structure is flat and wide when viewed from above (see also **Fig. 3.13**).

The aponeurosis can be followed further distally and medially, where it eventually disappears beneath the fascia of the forearm.

Biceps Tendon

The therapist can reach the main biceps tendon by hooking around the muscle–tendon junction from a lateral position. The tendon can be felt even better by adding isometric contraction and supination in the SP described above. When the tendon is precisely followed in a distal

direction, the palpating fingers land in the floor of the cubital fossa and on the insertion on the radial tuberosity. The tendon “disappears” when the patient pronates the forearm maintaining isometric flexion. It “reappears” when supinated in isometric flexion and is more easily palpable.

The radial tuberosity can actually be accessed, and its location is confirmed using passive pronation and supination of the forearm.

Tip: If the therapist is searching for the source of anterior elbow joint pain that is aggravated by activity, this technique can be used as a diagnostic provocation to palpate the tendon and its insertion.

The brachialis can best be reached directly medial and lateral to the muscle–tendon junction of the biceps.

Neurovascular Bundle

Two important peripheral motor nerves supplying the forearm and hand, as well as two large blood vessels, travel through the medial region of the upper arm (**Figs. 3.11** and **3.12**):

- Median nerve.
- Ulnar nerve.
- Brachial artery.
- Basilic vein.

The basilic vein, the deep brachial artery, and the median nerve, form a neurovascular bundle that can be palpated over the entire length of the humerus. The ulnar nerve is also part of this bundle until the mid-upper arm. From there it travels separately and crosses the elbow joint posteromedially.

The other structures (median nerve and both blood vessels) initially travel in the bicipital groove in the upper arm, cross over the middle of the elbow (through the cubital fossa), and extend down into the forearm.

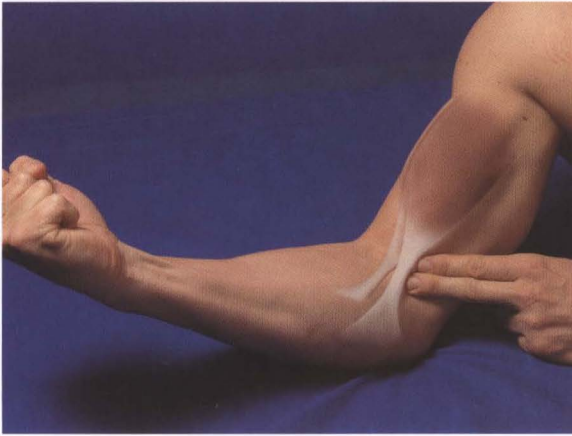


Fig. 3.13 Bicipital aponeurosis and the brachial artery—self-palpation.

These are the longitudinal structures that were observed during the transverse palpation of the medial humerus.

Technique

Brachial Artery

The patient is instructed to maintain a moderately strong isometric elbow flexion and supination. The same transverse palpation technique is used as for the humerus. The bundle of nerves and blood vessels is found slightly beneath the medial border of the biceps, where it lies in a soft tissue groove, the bicipital groove. This means that the palpating fingers have to be slightly flexed to enable the finger pads to reach these structures.

The brachial artery pulse can be clearly felt by placing the fingers flat on the skin and applying moderate pressure. It is easy to follow the artery more distally. It crosses underneath the bicipital aponeurosis and heads toward the middle of the cubital fossa (**Fig. 3.13**). It then divides into the radial artery and the ulnar artery. These arteries are accessible again on the distal forearm near the wrist.

Blood pressure is usually measured just before the artery crosses underneath the bicipital aponeurosis, with the aid of a blood-pressure cuff and a stethoscope.

Tip: If the therapist is not certain that they have found the artery, the palpation can be confirmed by finding the pulse at the wrist and then increasing the pressure applied to the point where the brachial artery is presumed to be. The pulse at the wrist will become weaker if the presumed location is correct. With the exception of severe vascular disease, there are no risks to the patient when pressure is applied for a short amount of time.

Median Nerve

The median nerve accompanies the artery until just before the cubital fossa. It passes between the ulnar and humeral heads of the pronator teres before it travels down the forearm. Compression neuropathies of the median nerve can arise when this muscle is very tense.

The nerve will roll back and forth underneath the transversely palpating fingers on the upper arm when slightly more pressure is applied to the humerus. This feeling is typical for the palpation of a neural structure.

Tip: It is relatively easy to differentiate the median nerve from the parallel blood vessel. It goes without saying that the nerve neither pulsates nor changes the quality of the radial pulse at the wrist. The localization and pathway of a nerve can be confirmed by palpating the nerve as it is placed under alternating tension and relaxation. This procedure carries no risk for the patient as peripheral nerves can usually cope quite well with short, moderate pressure. Pressure occasionally causes formication in the periphery.

In this SP, the median nerve is placed under tension using elbow extension and, when necessary, wrist extension. The nerve becomes more taut underneath the palpating fingers.

Pronator Teres

The lateral border of the pronator teres (**Fig. 3.14**) forms the medial boundary of the cubital fossa. This muscle has already been encountered during palpation of the bicipital aponeurosis. It originates on the humerus proximal to the medial epicondyle (see also the palpation of the medial aspect) and crosses over the proximal forearm onto the shaft of the radius.

Technique

The therapist can palpate its lateral border on the edge of the cubital fossa by instructing the patient to perform active pronation extensively and intensively.

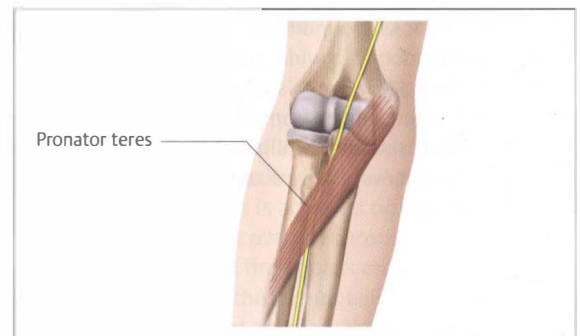


Fig. 3.14 Position of the pronator teres—anterior view.

Brachioradialis

The brachioradialis has an important function as a flexor of the elbow. Its slender muscle belly forms the lateral boundary of the cubital fossa. Its muscle belly becomes especially distinct on contraction during flexion when the forearm is positioned in neutral pronation/supination.

Technique

By following the muscle belly proximally, the palpating fingers are guided onto the lateral aspect of the distal third of the humerus. Distinct isometric contraction of the muscle flattens the soft tissue and usually forms an easily recognizable concavity at the muscular insertion of the brachioradialis.

Proximal Radioulnar Joint

The medial border of the brachioradialis precisely marks the junction between the head of the radius and the ulna at the cubital fossa (Fig. 3.15).

Technique

Movement of the head of the radius can be felt deep in the cubital fossa during rotation of the forearm. Therapists now have an idea of where the PRUJ can be found: on the medial border of the brachioradialis at the height of the head of the radius.

Tips for Assessment and Treatment

- It is very important that all therapists be aware of the exact position of the neurovascular bundle on the medial side of the humerus. Colleagues who experience the position and size of these structures for the first time during courses on palpation are surprised at the ease with which these structures can be reached and, therefore, compressed.
- The medial upper arm must be protected from all types of permanent pressure or traction, whether this occurs during Swedish massage, underwater massage, or the handling of the upper arm as part of manual therapy!
- The median nerve travels through two layers of the pronator teres. Compression neuropathies are particularly observed at this site in competitive athletes (e.g., badminton players or canoeists).
- Familiarity with the course of the biceps brachii tendon is extremely helpful when confirming the presence of a tendinopathy or bursitis at the insertion.

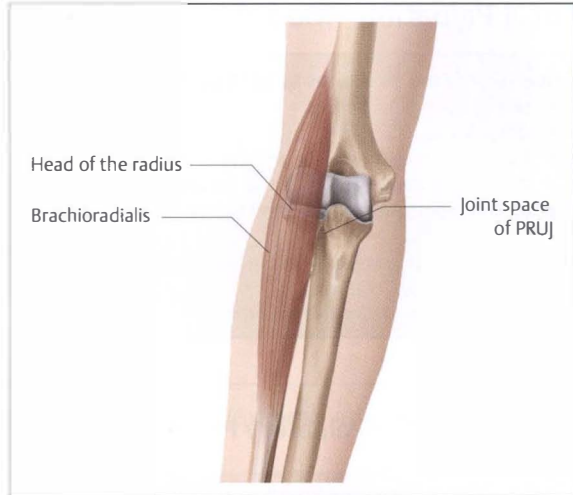


Fig. 3.15 Position of the joint space—PRUJ.

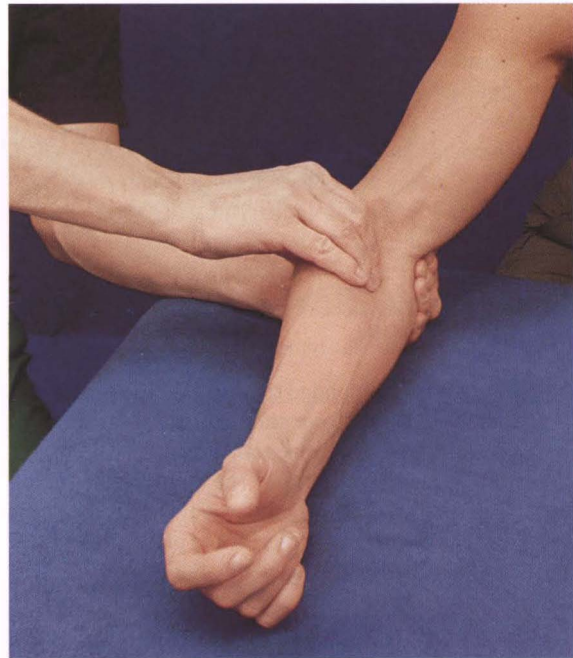


Fig. 3.16 Test of joint play at the PRUJ.

- Gliding of the head of the radius on the ulna and the humerus is part of the manual therapist's repertoire for diagnosis and treatment. Knowing how far the head of the radius extends medially and being able to differentiate it from the ulna ensures correct handling (Fig. 3.16).

Local Palpation—Medial

Overview of the Structures to be Palpated

- Humerus—medial border.
- Ulnar nerve.
- Groove for the ulnar nerve and the cubital tunnel.
- Medial intermuscular septum of the arm.
- Medial supracondylar ridge and the medial epicondyle of the humerus.
- Sites of insertion at the medial epicondyle (common head, pronator teres).
- Quick orientation on the forearm.

Summary of the Palpatory Process

Local palpation begins again on the medial aspect of the shaft of the humerus. The previously sought neural structure in the neurovascular bundle is located and its pathway followed down onto the forearm.

The bony and muscular structures are located next. Their localization and differentiation from other structures is of particular interest in the context of medial epicondylitis.

Hoppenfeld (1992) used a simple and helpful technique to visualize the position of the forearm muscles originating on the medial epicondyle. This will be presented at the end of this section.

Starting Position

Therapists are recommended to use either the practice SP or the alternative SPs from the anterior palpation: the therapist sits on a treatment table and the patient sits on a stool in front of the table. The elbow is resting on the therapist's thigh. The shoulder is flexed and slightly abducted. The elbow joint is flexed and placed in mid-position between pronation and supination.

Humerus—Medial Border

The medial palpation begins by returning to the medial aspect of the shaft of the humerus.

Technique

The therapist attempts to feel the shaft beneath the small amount of soft tissue by using a flat, transverse technique. Handling has already been described in detail in the local palpation of the anterior aspect (Fig. 3.17).

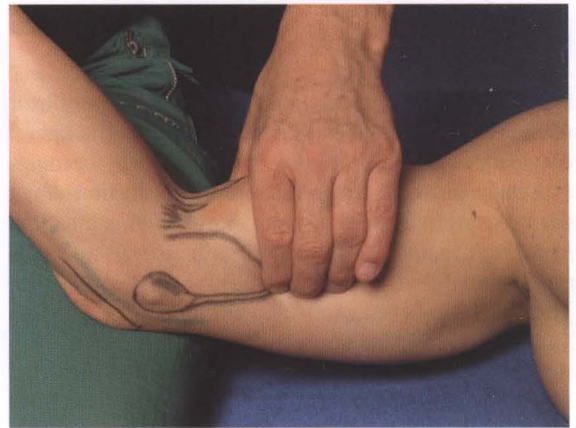

Fig. 3.17 Palpation of the medial shaft of the humerus.

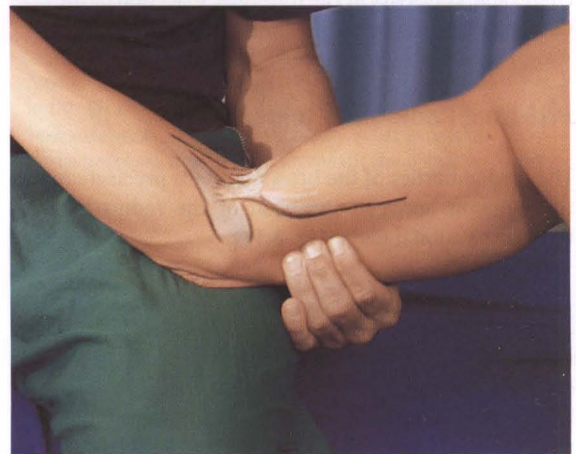

Fig. 3.18 Palpation of the ulnar nerve.

Ulnar Nerve

About halfway down the upper arm the ulnar nerve separates itself from the other structures in the neurovascular bundle. It travels posteriorly, where it is accompanied by the triceps brachii and the intermuscular septum. It passes over the posterior aspect of the elbow joint in the groove for the ulnar nerve and travels down the forearm along the ulna parallel to the flexors of the hand.

Technique

The palpating fingers point distally and posteriorly toward the medial epicondyle, and the fingertips carefully hook around the longitudinal running structures. The nerve is sought especially near the anterior border of the triceps brachii (Fig. 3.18).

Tip: Only experienced therapists can be certain that they have found the ulnar nerve. It is often necessary to use the following measure to gain confidence. The ulnar nerve is placed under tension by passively flexing the elbow and, when necessary, extending the wrist. The nerve then becomes more taut when palpated and can be rolled back and forth underneath the fingertips with the typical feel of peripheral nerves.

Groove for the Ulnar Nerve and the Cubital Tunnel

The groove for the ulnar nerve can be felt on the posterior aspect of the distinct protrusion of the medial epicondyle. The ulnar nerve lies in this groove and is accompanied by a small artery (Fig. 3.19).

Technique

The nerve can be best be felt by using transverse palpation when the elbow is moderately flexed (approximately 40–70°). With greater flexion, the nerve is placed under tension and pushes the palpating finger out of the groove. It now becomes clear that only pointed objects can knock against the ulnar nerve when the elbow is flexed. Habitual and traumatic subluxation of the nerve can be occasionally observed at this site.

The nerve can be followed again more proximally up onto the medial humerus. It is not as easy to palpate the further pathway of the ulnar nerve on the forearm. The nerve penetrates through the fascia of the forearm about 1 cm inferior to the common flexor origin on the medial epicondyle and enters the muscle belly of the flexor carpi ulnaris. The nerve passes through a narrow passage at this point, the cubital tunnel. The nerve can be compressed here and can only be palpated for another few centimeters.

From topographical anatomy, therapists are familiar with the nerve's further pathway on the ulnar side of the forearm down to a site adjacent to the pisiform bone.

Medial Intermuscular Septum of the Arm

The muscle belly of the triceps is separated from the flexors by a membranelike connective tissue, the medial intermuscular septum of the arm. This can best be found on the humerus more distally and medially.

Technique

The therapist returns to the medial humerus and starts palpating distally again, but with a different aim this time. The triceps muscle is contracted slightly and a transverse palpation is again used (Fig. 3.20).

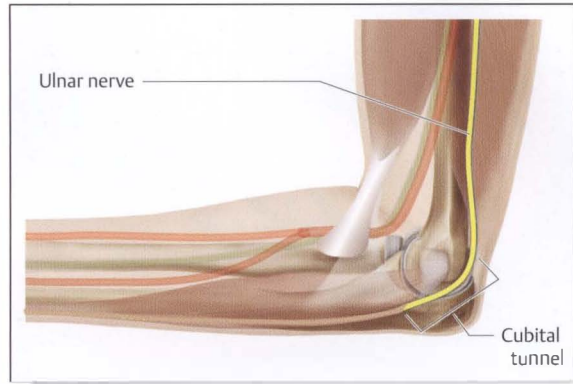


Fig. 3.19 Passage of the ulnar nerve in the groove and the cubital tunnel.

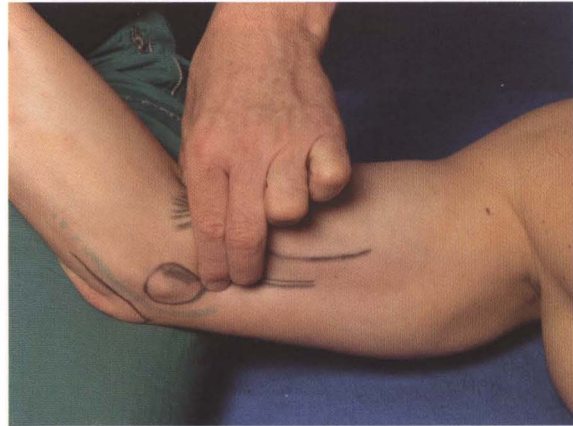


Fig. 3.20 Palpation of the intermuscular septum.

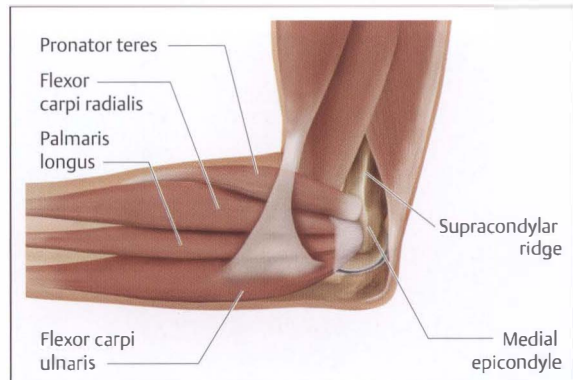


Fig. 3.21 Topography of the muscles—medial (ulnar) view.

Medial Supracondylar Ridge and Medial Epicondyle of the Humerus

Technique

When the fingers palpate the humerus at this level, the therapist will notice that the humerus becomes wider and has a sharp edge. The sharp-edged medial supracon-

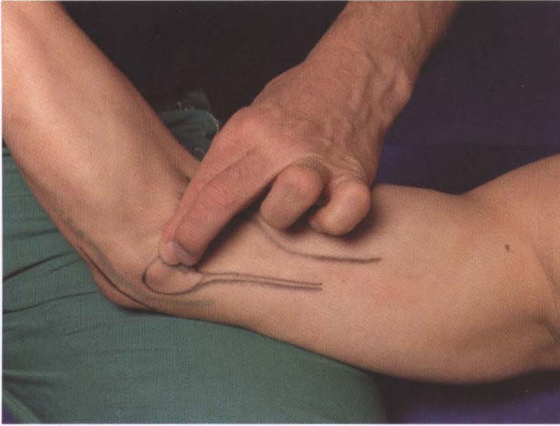


Fig. 3.22 Palpation of the origin of the pronator teres.

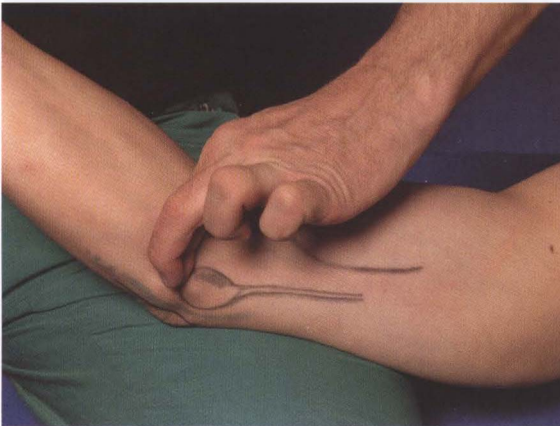


Fig. 3.23 Palpation of the distal tip of the epicondyle.

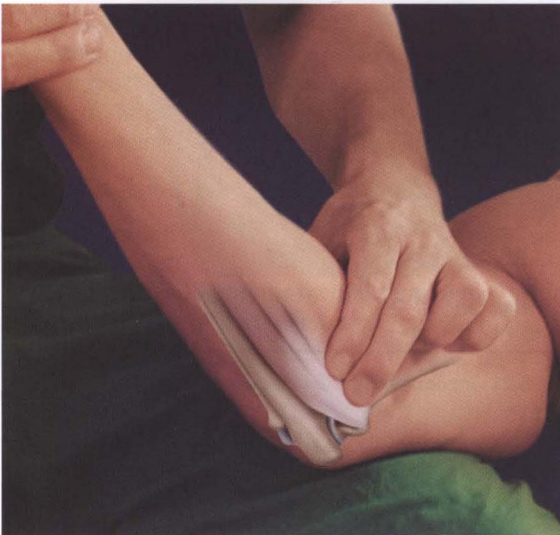

Fig. 3.24 Transverse palpation of the flexor tendon.

dylar ridge guides the palpation onto the tip of the well-developed medial epicondyle. This is the starting point for the palpation of all further muscle attachments in this region (Fig. 3.21).

Sites of Insertion at the Medial Epicondyle (Common Head, Pronator Teres)

Two palpations of muscular insertions start at the tip of the medial epicondyle.

Technique

Pronator Teres

A bony plateau can be clearly felt when the therapist slides the fingers in an anterior direction down from the tip toward the cubital fossa. This is the insertion of the pronator teres (Fig. 3.22). The therapist can be sure of having located the pronator teres correctly when active pronation pushes the palpating fingers away from the plateau. The pronator teres rarely causes epicondylitis. Long-term tension in the muscle belly can endanger the median nerve as it passes through the muscle.

Common Head

When the therapist slides distally from the tip of the medial epicondyle toward the wrist, a taut, rounded structure of approximately 1 cm in width is felt (Fig. 3.23). This structure turns into soft muscle tissue after only a short distance. The communal tendon of origin (common head) is formed by the convergence of three tendons onto the distal tip of the medial epicondyle: the radial and ulnar flexors of the hand and the tensor of the aponeurosis of the hand. The humeral head of the superficial finger flexors joins the common head deep in the tissues (not palpable).

Tip: Muscle activity confirms the correct location. The patient flexes the wrist or fingers, and the therapist can immediately feel the tendon tensing.

Other Techniques

Common Head

The dimensions of the common head can be visualized using two additional techniques.

The first technique involves the use of transverse palpation to determine the thickness of the tendon and the tendon-muscle junction (Fig. 3.24). The patient's shoulder can be placed in a small amount of lateral rotation to allow better assessment of this region.

The second technique involves determining the length of the common head by placing the index fingers on either

side of the tendon (Fig. 3.25). Once again, a moderate amount of activity in the finger or wrist flexors can facilitate locating the tendon.

Differentiation in the Presence of Epicondylitis

The inserting muscular structures seen at the medial epicondyle are responsible for the symptoms associated with “golfer’s elbow.” Winkel (1997) described three types of epicondylitis that mainly differ from one another due to the location of the lesion over the above-described course. The techniques are used for diagnostic provocation in assessment or for treatment. The aim is to first find the most painful point and to then treat this area with appropriate physical therapy methods, including the possible use of cross-frictions according to Cyriax.

Types of Medial Epicondylitis

Type I = common flexor origin on the distal tip of the medial epicondyle.

Type II = tendon of the common head.

Type III = muscle–tendon junction.

Technique

Type I

To reach the insertion of the sturdy common head directly on the epicondyle, a technique is used where the finger pad points toward the distal tip of the epicondyle (Fig. 3.26). In this case, the pad of the index finger of the more proximal hand is used.

The flexors are also approximated to relax the tendon and to provide free access to the insertion. This is achieved by passively moving the patient’s hand into a flexed position.

The side of the index finger pushes down on the tendon, and the finger pad points toward the epicondyle and applies pressure. If necessary, the middle finger is placed on top of the index finger for support. The index finger maintains this posture, increases the pressure, and moves from posterior to anterior (toward the cubital fossa). If epicondylitis is present at this location the patient will confirm this by reporting pain.

Types II and III

The therapist now turns the proximal forearm so that the pad of the index finger pushes down directly onto the approximately 1-cm-wide tendon. Direct pressure is applied onto the tendon during palpation; the direction of movement remains the same (Fig. 3.27).

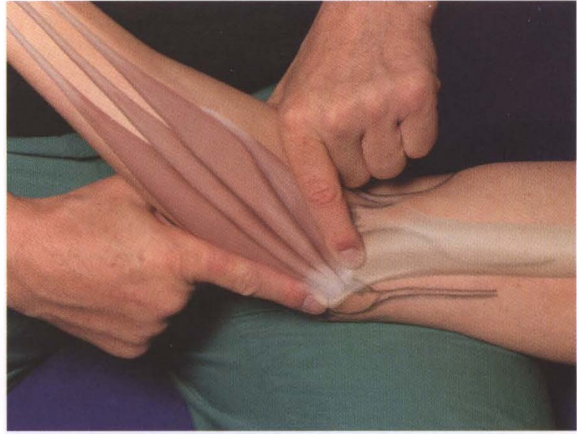

Fig. 3.25 Borders of the common head.

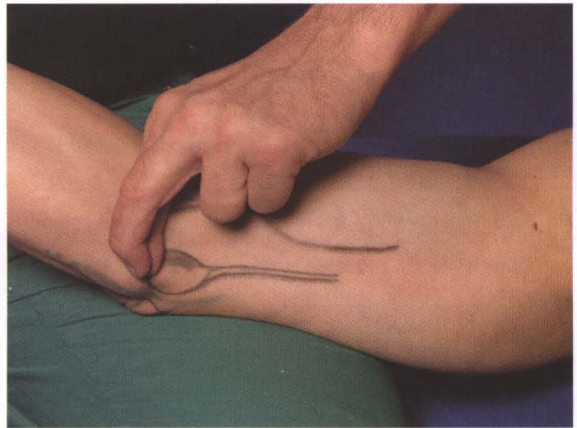

Fig. 3.26 Transverse friction—type I.

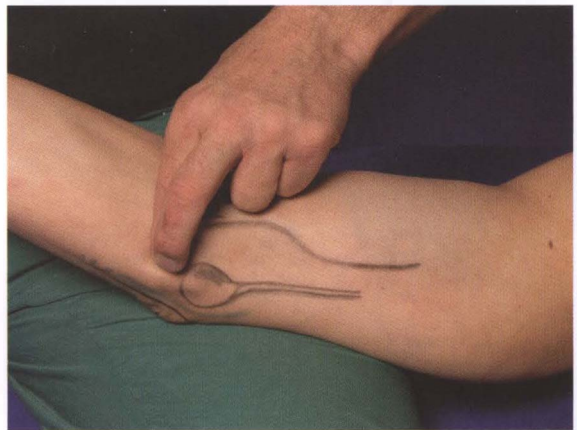

Fig. 3.27 Transverse friction—type II.

If the therapist wishes to access the muscle–tendon junction, the palpating finger slides approximately 1 cm further distal.

The muscle–tendon junction (type III) can be differentiated from the tendon itself (type II) by its greater width and its softer consistency.

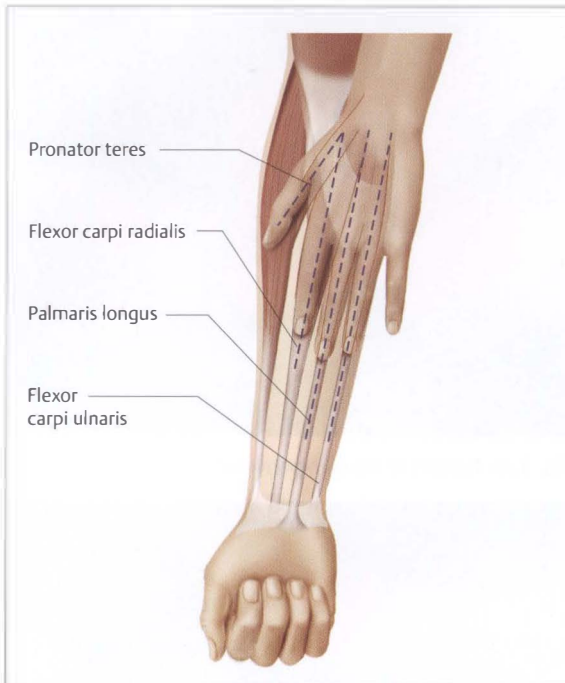


Fig. 3.28 Topography of the muscles in the forearm—anterior view.

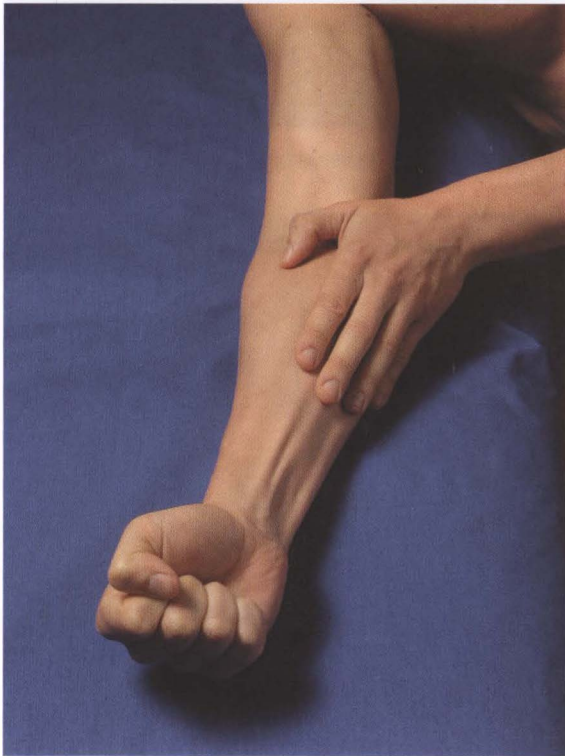


Fig. 3.29 Quick orientation on the forearm.

Tip: The tendon and the muscle–tendon junction should be initially placed under tension to prevent these structures from being pushed deep into the tissues during palpation. Wrist and elbow extension is ideal for this.

Caution

The ulnar nerve travels about 1 cm away from and directly parallel to the insertion, tendon, and muscle–tendon junction. By precisely locating the latter structures, the therapist can be sure that pain caused by this technique is actually related to epicondylitis. Therapists can only be certain that they have not come into contact with the nerve when this technique is conducted precisely and with small movements.

Quick Orientation on the Forearm

As already mentioned, the following muscles are found on the medial epicondyle:

- Flexor carpi ulnaris (travels along the ulna to the wrist).
- Palmaris longus (found in the middle, traveling superficially to the wrist).
- Humeroulnar head of the flexor digitorum superficialis (found in the middle, traveling deeper in the tissue to the wrist).
- Flexor carpi radialis (travels at an angle toward the radius and down to the wrist).
- Pronator teres (travels at an angle toward the radius).

Several of the tendons belonging to these muscles will be reencountered when palpating the wrist. It is not possible to precisely differentiate the muscle bellies in the forearm from one another. Only the pronator can be differentiated from the other muscles in the common head.

Technique

The position of the muscles in the forearm and their alignment to the wrist can be visualized using a supporting measure, and it is recommended that therapists try this out on several arms.

The forearm to be palpated is positioned so that the elbow joint is slightly flexed.

The junction of the thenar eminence and the hypothenar eminence on the left hand is placed over the medial epicondyle. The fingers are spread out slightly and rest on the forearm. Apart from the small finger, each finger represents the position and course of one of the muscles that originate from the epicondyle (Figs. 3.28 and 3.29).

Tips: The actual position of the muscles can be confirmed using muscle contraction:

- The muscle belly of the pronator becomes distinct underneath the left thumb when the patient strongly pronates at end range.
- The index finger indicates the course of the flexor carpi radialis, and the tendon becomes distinct with active wrist flexion and hand abduction.
- The ring finger is positioned over the ulnar flexor of the wrist. Wrist flexion combined with hand adduction activates this muscle.
- Not everyone possesses the palmaris longus. When present, this muscle is found in the middle of the anterior forearm, and the middle finger indicates its position. Further details can be found in Chapter 4.

Tips for Assessment and Treatment

Symptoms presenting on the medial side can be an indication for problems at the HUJ or the presence of soft-tissue lesions in the muscles inserting there. Therapists will quickly become aware of which type of pathological condition they are dealing with during the assessment. Structures are differentiated by assessing passive movement and testing against resistance.

The presence of soft-tissue lesions, commonly known as “golfer’s elbow,” is easily confirmed by letting the patient contract the muscle against strong resistance. Ultimately, the affected structure can only be precisely identified using local palpation. The cubital tunnel syndrome is diagnosed increasingly often and imitates the symptoms of “golfer’s elbow.” In particular, therapists should consider this possibility in cases of burning pain radiating distally. Precise palpation shows the position of the nerve in comparison to the muscular structures.

Local Palpation—Lateral

Overview of the Structures to be Palpated

Locating the Most Important Osseous Structures

- Humerus—lateral border.
- Lateral intermuscular septum.
- Lateral supracondylar ridge.
- Lateral epicondyle and the lateral condyle of the humerus.
- Humeralradial joint space and the muscle belly of the anconeus.
- Head and neck of the radius.

Locating the Muscles and Their Insertions

- Brachioradialis and the radial nerve.
- Extensor carpi radialis longus.
- Extensor carpi radialis brevis.
- Extensor digitorum.
- Extensor carpi ulnaris.

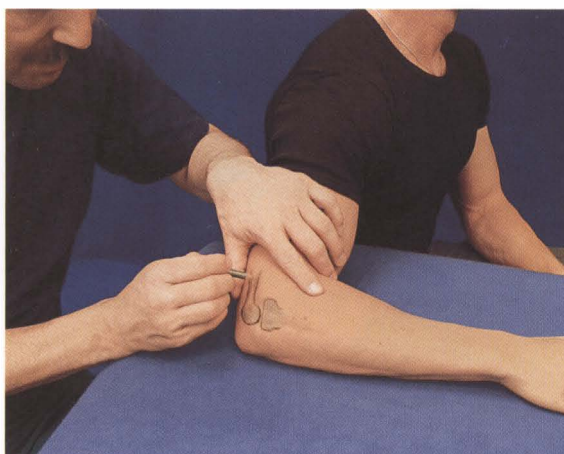


Fig. 3.30 SP for palpation of the lateral aspect.

Summary of the Palpatory Process

The humerus is once again the starting point when searching for specific, important structures.

The first part of the palpation on the lateral elbow is mainly directed toward the bony structures in the humeroradial joint. The muscular structures are then made accessible. The same applies as for the medial side: the exact location should be found that indicates the presence of epicondylitis.

Starting Position

It is recommended that the arm rests on a treatment table with the shoulder in abduction (between 45° and 90°). The elbow is flexed to about 90° and placed in mid-pronation/supination. The therapist sits lateral to the elbow (Fig. 3.30).

Localization of the Most Important Osseous Structures (Fig. 3.31)

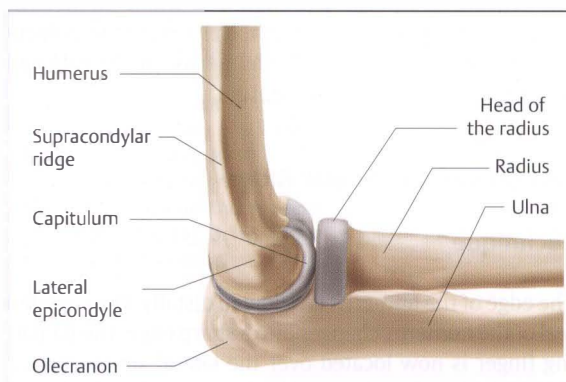


Fig. 3.31 Topography of the bones—lateral (radial) view.

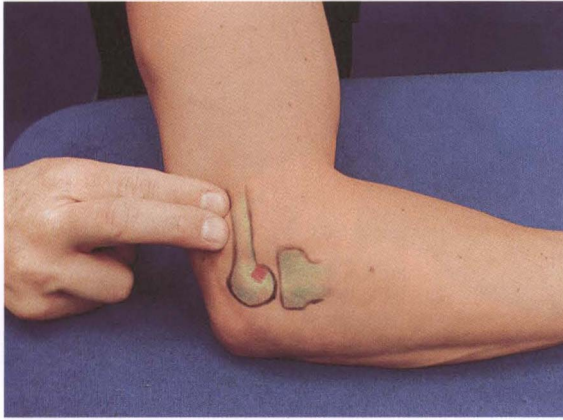

Fig. 3.32 Palpation of the lateral humerus.

Humerus—Lateral Border

Like on the medial side, the increased width of the distal humerus can also be felt laterally. The therapist searches for the humerus in the inferior third of the upper arm between the flexor and extensor groups of muscles.

Technique

The finger pads are placed flat over the lateral side of the upper arm and palpate transversely (Fig. 3.32). The aim is to find a hard structure with rounded contours.

Lateral Intermuscular Septum

While searching for the humerus, the palpating fingers may slide over a layer that is solid but still yields elastically to pressure. This is the lateral intermuscular septum.

Technique

The septum is especially pronounced when the patient tenses the triceps and the therapist attempts to palpate the muscle from anterior. The humerus can be palpated immediately anterior to the septum.

Lateral Supracondylar Ridge

Technique

The edge of the humerus is followed distally. The rounded feel of the humerus changes into a sharp edge. The palpating finger is now located over the lateral supracondylar ridge, which is found immediately proximal to the lateral epicondyle. The origin for the extensor carpi radialis

longus is found here. The brachioradialis originates immediately proximal to the ridge.

Lateral Epicondyle and the Lateral Condyle of the Humerus

Technique

Lateral Epicondyle

The therapist can follow the sharp edge of bone precisely along its further course and feel how the ridge tapers off into the lateral epicondyle.

When palpated flatly, the area inferior to this tip appears to be a small plateau only a few millimeters in diameter. The origin for the extensor carpi radialis brevis is found here. Its exact localization will be described later in the text (see p. 63).

The muscle belly of the anconeus is palpated posterior to the tip as it tenses beneath the finger during active extension. The ulna with the olecranon is encountered next.

Tips: The lateral epicondyle of the humerus is distinctly flatter than its medial counterpart. Consequently, the therapist will not directly notice the tip of the lateral epicondyle when it is being palpated and may have to search harder for it. A transverse palpatory technique is appropriate here to gradually and persistently follow the supracondylar ridge in a distal direction. The supracondylar ridge turns slightly in an anterior direction shortly before the tip of the epicondyle. It is very important to locate the tip when a tennis elbow is suspected and a provocative palpatory technique is administered. This technique will be described later in the text. Another option exists to find the bony structures of the lateral humerus: circling the condyle. This is the part of the bone that supports the articular surface of the humeroradial joint, the capitulum of the humerus.

Lateral Condyle

Starting at the supracondylar ridge, the therapist palpates posteriorly (Fig. 3.33) and follows the very convex-shaped bony border distally down onto the joint space. The palpa-

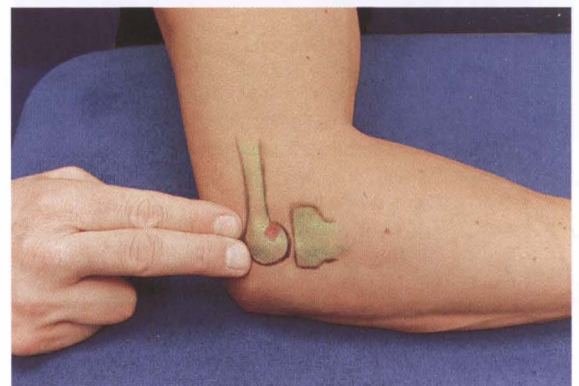


Fig. 3.33 Palpation of the lateral condyle.

tion then continues anteriorly from here, over the condyle, returning to the humerus at the starting point.

Humeroradial Joint Space and Muscle Belly of the Anconeus

Another very simple option exists to find the HRJ space, which starts with the palpation of the previously located tip of the lateral epicondyle.

Technique

The finger starts palpating the tip of the epicondyle and moves distally toward the wrist, where it sinks into an indentation. This is the joint space formed by the condyle of the humerus on the one side and the edge of the head of the radius on the other side.

Tip 1—Confirmation with Movement: The correct position of the palpating finger is determined by passively pronating and supinating the forearm. The joint space has been correctly located when movement is felt at the head of the radius.

Tip 2—The Optimal Point: The inserting tendons make it difficult for therapists to palpate distal to the tip of the epicondyle when trying to reach the HRJ space using the previously described method. Palpation is significantly easier when the joint space is followed more posteriorly. Extensor tendons are missing here, and the joint space is wide between the straighter head of the radius and the convex condyle. This is the best point to locate the HRJ space (**Fig. 3.34**)!

Tip 3—Palpation during Movement: Therapists can now understand how the joint space changes in a variety of elbow positions. The joint space can be best felt when the elbow is extended. As flexion increases, the head of the radius rocks and glides anteriorly on the capitulum and the fascia superficial to the joint becomes more taut. The joint space can no longer be felt as clearly. Several manual therapy training institutes use this movement to assess the position of the HRJ.

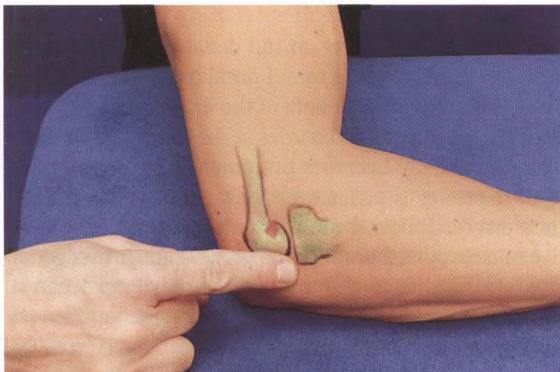


Fig. 3.34 Palpation of the HRJ space.

Head and Neck of the Radius

The contours of the proximal radius will become clear in the following section. When students feel this structure for the first time, they will be surprised by its position and particularly by the dimensions of the head of the radius.

Technique

Head of the Radius

The palpating finger starts at the joint space and slides distally for a short distance. The finger pads are now lying directly over the head of the radius and the more superficially located annular ligament of the radius.

The therapist can feel the head of the radius rotating underneath the finger by rotating the forearm over a large range. As the head of the radius has a transverse elliptical form, the therapist can clearly feel the finger being pushed away when the forearm rotates from supination into pronation.

Neck of the Radius

The head of the radius tapers down further distally into the neck of the radius. This can be observed when the lateral contours of the head of the radius “disappear” deep into the tissue. Soft tissue prevents the radius being directly accessible from this point on.

The palpating finger is positioned laterally and traces the convex curve of the head of the radius toward the cubital fossa. The therapist can slide proximally up onto the joint space and distally onto the neck of the radius to confirm the position.

Tip: It is important that the therapist’s finger remains on the head of the radius until soft tissue prevents further palpation. This soft tissue corresponds to the extensor carpi radialis longus and brachioradialis and will be highlighted later on. The therapist can now use the index fingers to grasp around the accessible anterior and posterior borders of the head of the radius and become aware of its full dimensions (**Fig. 3.35**). Its size is most surprising. The head of the radius is more pronounced than it appears in anatomical illustrations and anatomical models.

As a reminder: the head of the radius is also accessible deep in the cubital fossa (see p. 53, **Fig. 3.15**).

Being able to recognize the entire dimensions of the head of the radius and its differentiation from the neck of the radius is the basis for manual therapy techniques at the HRJ and the PRUJ (see p. 53, **Fig. 3.16**), as well as for the locating important parts of the muscles.

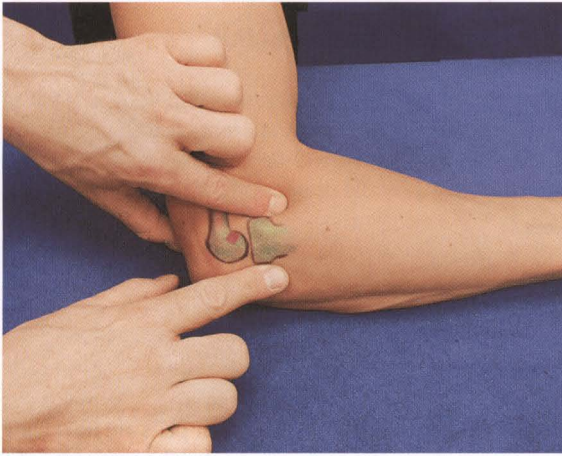


Fig. 3.35 Borders of the head of the radius.

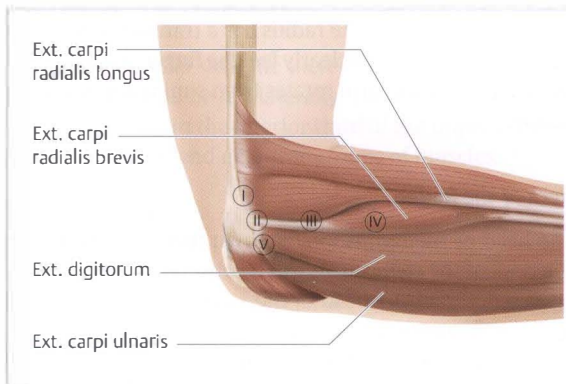


Fig. 3.36 Position of the different types of tennis elbow.

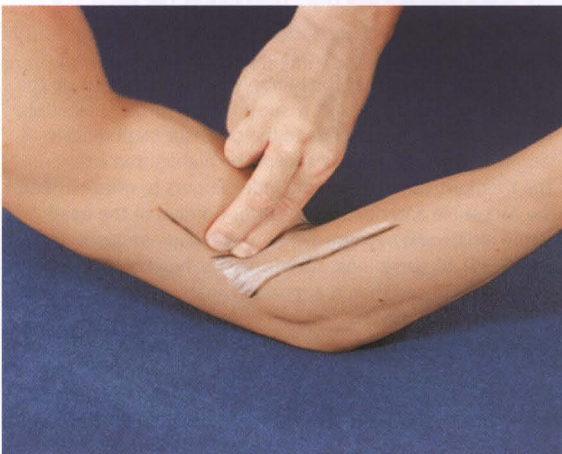

Fig. 3.37 Palpation of the radial nerve.

Locating the Muscles and Their Insertions

The insertion of the posterior forearm muscles on the lateral epicondyle region display comparatively often pathologies. Conditions at this site are commonly known as tennis elbow. Therapists should be aware that only three of the relevant muscles insert directly on the epicondyle. These muscles, however, form a communal tendinous plate at this site, with some of the fibers merging into one another. The term “common head” can also be used here. The extensor carpi radialis brevis and extensor digitorum are particularly tightly interwoven.

It is also known from anatomical specimens that these muscles are in contact with the deeper HRJ capsule, making it more difficult to correctly allocate symptoms in the lateral elbow to soft tissues or problems at the joint.

Localization of the Lateral Insertion Tendinopathies (Fig. 3.36)

- Tennis elbow, type I: insertion of the extensor carpi radialis longus.
- Tennis elbow, type II: insertion of the extensor carpi radialis brevis.
- Tennis elbow, type III: tendon of the extensor carpi radialis brevis.
- Tennis elbow, type IV: muscle-tendon junction of the extensor carpi radialis brevis.
- Tennis elbow, type V: insertion of the extensor digitorum.

Brachioradialis and the Radial Nerve

The radial nerve is the third large peripheral nerve in the arm that crosses over the elbow joint laterally on the flexor side. The brachioradialis is the guiding structure for palpation.

Technique

Further palpation starts on the distal part of the upper arm. The humerus feels round proximal to the supracondylar ridge. The muscle bulk of the brachioradialis is evident here, on the lateral border of the humerus. The slender muscle belly becomes prominent when it contracts against strong resistance opposing elbow flexion. The therapist can follow the muscle to its origin, where the active muscle pulls the soft tissue of the upper arm together and forms a shallow depression. The radial nerve can be palpated immediately proximal to this at the junction between the brachioradialis and the edge of the biceps (Fig. 3.37).

Tip: The nerve is reliably located when an additional technique is used. The therapist follows the medial border of the brachioradialis proximally toward its origin, applies light posteriorly directed pressure onto the bone, and palpates transversely so that the nerve rolls back and forth underneath the finger.

The brachioradialis is a guiding structure. The superficial branch of the radial nerve accompanies this muscle distally and passes through the fascia of the forearm approximately one hand-width proximal to the wrist. Now it is very superficial and palpable again.

Extensor Carpi Radialis Longus

The muscle bulk of the extensor carpi radialis longus is also evident on the supracondylar ridge (**Fig. 3.38**). The therapist can observe the distinct, short, round, and usually noticeably prominent muscle belly when the wrist isometrically contracts while extended with hand abduction.

Technique

The muscle belly can be located using two methods:

- In the first method, therapists start palpating the origin of the brachioradialis and move distally.
- In the second method, the finger starts palpating at the supracondylar ridge and moves anteriorly.

Muscle contraction always pushes against the palpating fingers.

Once the muscle has been located, its borders can be identified when the muscle continues to contract (**Fig. 3.39**).

Winkel (1997) described this form of the insertion tendinopathy as type I tennis elbow.

Extensor Carpi Radialis Brevis

Using the SP described above, it is possible to locate a slender muscle belly, which is the direct extension of the long radial hand extensors.

Technique

A shallow depression can be felt at the junction between the two muscle bellies when these muscles are contracted. Once the muscle has been located, the edges of the muscle belly can be followed (**Fig. 3.40**). The brachioradialis forms its anterior boundary and the extensor digitorum its posterior boundary.

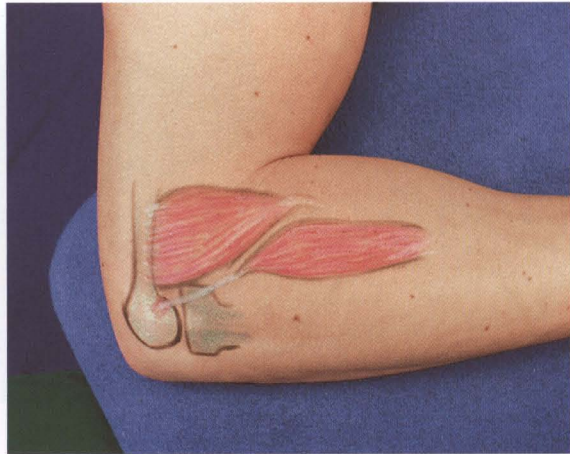


Fig. 3.38 Position of the lateral wrist extensors.

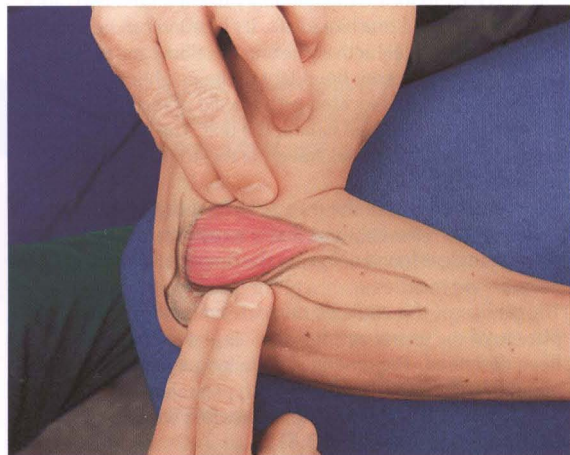


Fig. 3.39 Borders of the extensor carpi radialis longus.

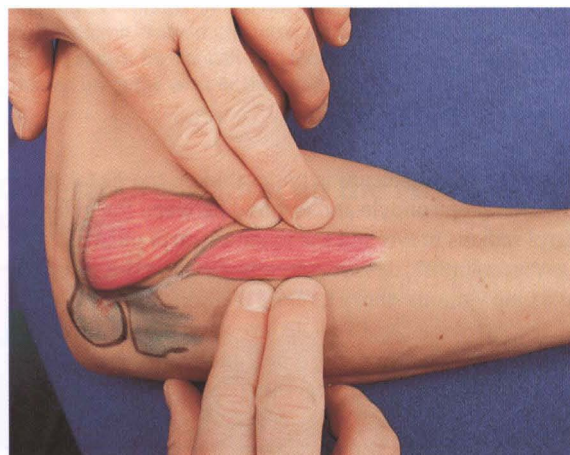


Fig. 3.40 Borders of the extensor carpi radialis brevis.

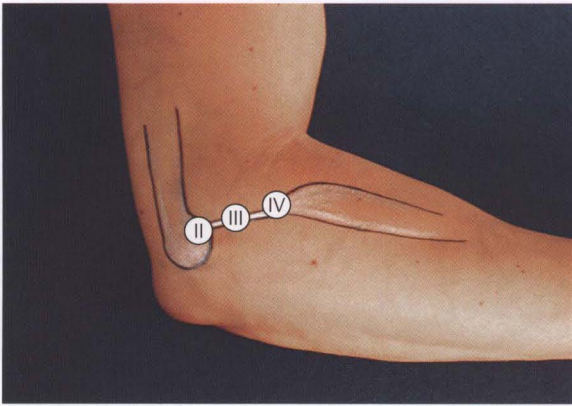


Fig. 3.41 Position of tennis elbow types II-IV.

Tip: It is easy to locate the boundary between the two radial extensors and the brachioradialis. Its location can be confirmed by alternately actively flexing the elbow and extending the wrist. The posterior boundary to the neighboring muscle is less distinct and is located with the aid of reciprocal inhibition, as will be described later in the text. The tendons of the longus and brevis muscles travel parallel to the lateral side of the wrist.

The superficial part of the muscle belly of the extensor carpi radialis brevis is the only part that is accessible. The larger part of the muscle is found deeper in the tissues and is covered by neighboring muscles.

The tendon of this extensor originates directly on the small plateau of the lateral epicondyle. This plateau has already been described. The tendon is quite long and connects the origin to the muscle belly.

According to Winkel (1997), this muscle is linked to three types of tennis elbow (Fig. 3.41):

- Type II: insertion tendinopathy at the lateral epicondyle.
- Type III: tendinopathy at the level of the head of the radius.
- Type IV: lesion at the muscle-tendon junction at the level of the neck of the radius.

Extensor Digitorum

The extensor digitorum is noticeable on the distal tip of the lateral epicondyle and is found between the extensor carpi radialis brevis and the extensor carpi ulnaris.

Winkel (1997) describes tendinopathy at this insertion as a type V tennis elbow. Its close relationship to the origin of the extensor carpi radialis brevis is also observed in clinical practice, where the type II and type V forms of tennis elbow often present together.

Technique

The muscle needs only to contract to differentiate it from the surrounding structures. The therapist resists wrist flexion by applying light pressure to the palm of the hand. This reciprocally inhibits all wrist extensors.

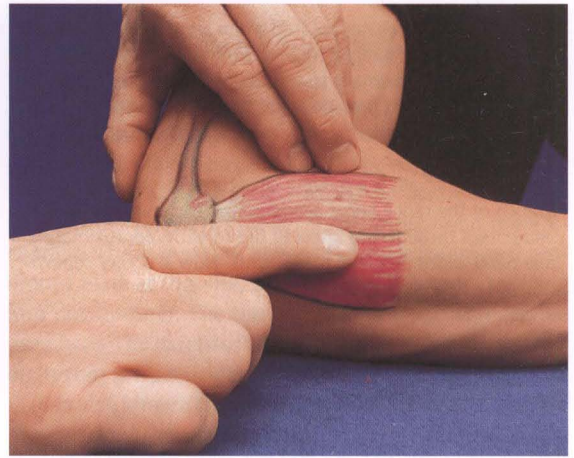


Fig. 3.42 Borders of the extensor digitorum.

When combined with movement of the fingers (as if playing a piano), the medial and lateral borders of the muscle can be clearly differentiated from the wrist extensors (Fig. 3.42).

Extensor Carpi Ulnaris

The medial hand extensors are also noticeable on the distal aspect of the epicondyle and travel distally along the posterior border of the ulna.

Technique

The extensor carpi ulnaris can be differentiated from the ulna by feeling the differences in tissue consistency, that is, the finger palpates softer tissue when on the muscle and significantly harder tissue when feeling bone (Fig. 3.43).

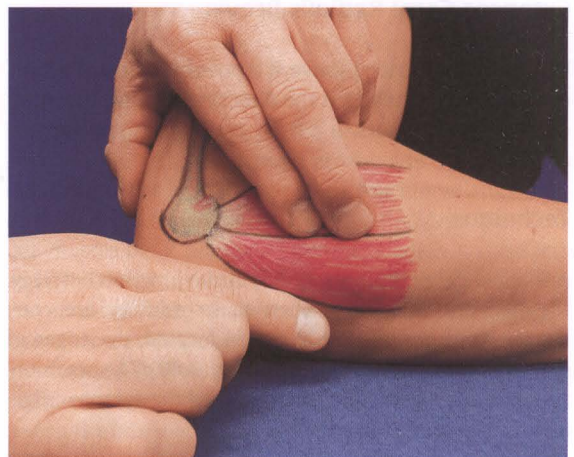


Fig. 3.43 Borders of the extensor carpi ulnaris.

Tip: To identify the entire muscle, the therapist can instruct the patient to actively alternate between the zero position of the wrist and adduction combined with extension.

As has been described above, the lateral border of extensor carpi ulnaris is differentiated from extensor digitorum by reciprocally inhibiting the hand extensors and contracting the finger extensors.

Neither the origin, the tendon, nor the muscle–tendon junction are known to be associated with lateral elbow symptoms. This muscle appears to be insignificant for clinical practice.

Tips for Assessment and Treatment—Local Palpatory Techniques for Type II Tennis Elbow

Pain-provoking transverse friction techniques have been mentioned for the assessment and treatment of all types of tennis elbow. As type II tennis elbow occurs most frequently, the technique for type II tennis elbow will be described in the following section.

Starting Position

There are two points of emphasis in this SP:

- The patient's arm should be resting on a treatment table with approximately 45° of shoulder abduction and approximately 90° of elbow flexion. The small plateau at the insertion of the extensor carpi radialis brevis is horizontal in this position.
- The elbow should protrude over the edge of the table to allow it to be easily reached from all sides.

The therapist uses one hand to conduct the technique and the other hand to stabilize the patient's arm on the treatment table.

Technique

The treatment hand grasps the elbow joint with the finger pads hooking onto the medial side. The finger pads stabilize the transverse frictions applied by the thumb (Fig. 3.44).

The thumb pad is placed on the tip of the lateral epicondyle.

The thumb applies considerable pressure onto the tip and slides in a straight line toward the cubital fossa. The thumb then returns to the tip without applying pressure but still maintaining skin contact.

The tendinous origin of the extensor carpi radialis brevis cannot be palpated as an elevation as it merges flatly into the plateau. It can only be felt as an elevation when the tendon–muscle junction is inflamed and swollen.

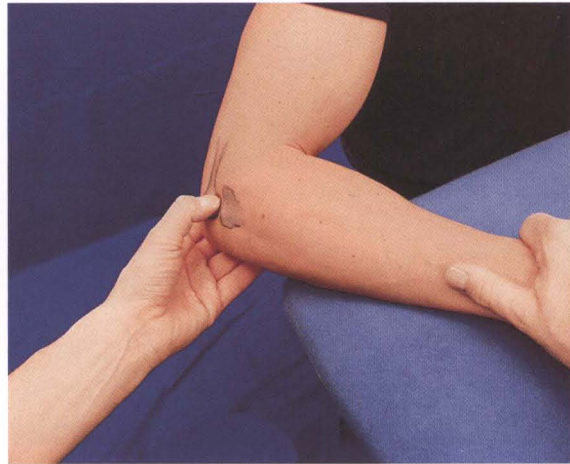


Fig. 3.44 Transverse frictions for the treatment of type II tennis elbow.

This palpation is painful when tennis elbow symptoms are present. The therapist should therefore adjust the amount of pressure applied during treatment.

Tip 1—Localization: The most common mistake made when conducting this technique is to move too much. The plateau of origin is really very small. Its exact localization can be made more reliable using a supporting measure: the more superficial muscle belly of the extensor carpi radialis longus bulges out when the hand is abducted and the patient isometrically contracts into wrist extension.

The therapist is palpating too far anteriorly if the muscle belly pushes against the palpating fingers.

Tip 2—Procedure: It can be quite strenuous for therapists to apply this technique for several minutes. An efficient technique should be used that does not require a great deal of strength. Therapists should not friction by moving the joints of the thumb. Instead, the unsupported arm should be positioned almost horizontally and movement should be conducted using the wrist or the entire arm.

General Orientation on the Posterior Humerus

Overview of the Structures to be Palpated

- Olecranon.
- Lateral epicondyle of the humerus.
- Medial epicondyle of the humerus.
- Elbow joint capsule.
- Olecranon bursa.

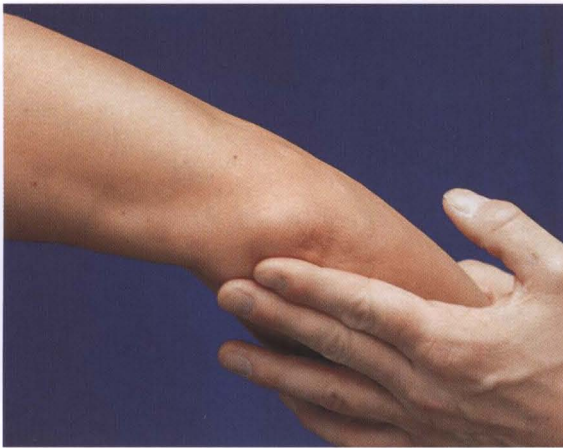

Fig. 3.45 Palpation of the elbow joint capsule.

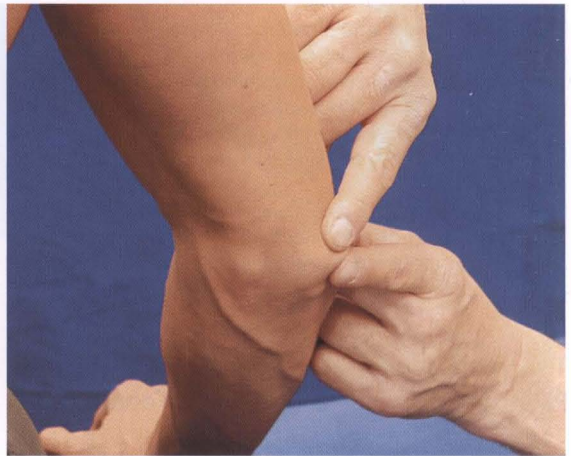

Fig. 3.46 Olecranon bursa—palpation technique.

Summary of the Palpatory Process

Therapists orient themselves on the posterior aspect of the elbow joint to:

- Palpate warmth and swelling.
- Determine the relationship between the three bony elevations.

Starting Position

Although a special SP is not necessary, the posterior aspect of the elbow should be accessible. This is possible in a variety of arm positions, for example, with shoulder flexion or extension.

Palpating Warmth and Swelling

The posterior side of the elbow is the only area that is covered by very little soft tissue. It is easy for the therapist to recognize and palpate swelling of the capsule or the olecranon bursa. The presence of warmth in the inner joint space can only be ascertained on this side of the elbow.

Technique

Temperature is assessed using the back of the hand. The fingertips search for swelling. Capsular swelling is seen immediately medial or lateral to the olecranon. The therapist places the finger pads directly over the capsule and palpates using a gentle, slow technique (Fig. 3.45).

A swollen bursa can be easily recognized with the naked eye. The fluid moves back and forth in the bursa when the fingers palpate the bursa directly (Fig. 3.46).

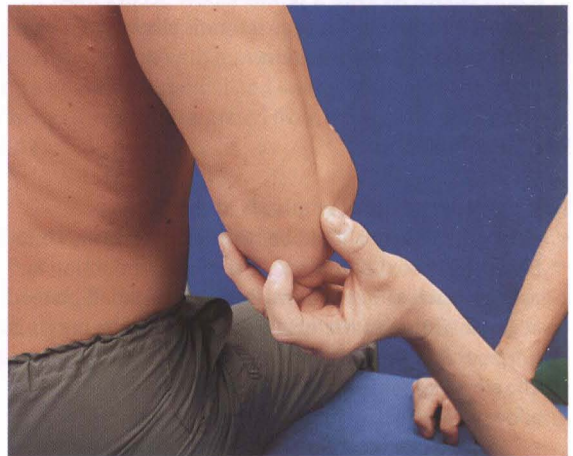

Fig. 3.47 Palpation of bony reference points.

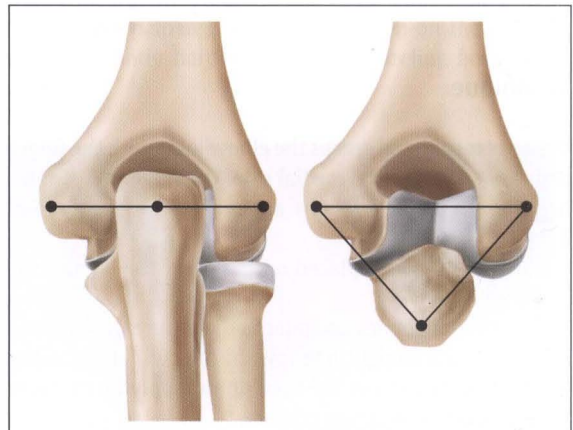


Fig. 3.48 Position of reference points during extension and flexion.

The Relationship between the Three Bony Elevations

The relationship between the palpable sections of bone in different joint positions will be described here. The “clinical reference points” consist of the tip of the olecranon and the two epicondyles of the humerus.

Technique

These landmarks should form an equilateral triangle when the elbow is flexed to 90° and form a line when the elbow is extended (Figs. 3.47 and 3.48).

Tips for Assessment and Treatment

The relationship between these three points provides therapists with a general overview of the position of these sections of bone. It is important to know whether the position of these bony landmarks is physiological when treating patients following trauma. If the therapist recognizes deviations from the norm, radiological clarification is recommended before mobilizing.

Study Questions

1. What is the name of the section of the biceps brachii tendon that can be hooked around from medial?
2. Which muscles participate in the common head at the medial epicondyle?
3. Name the parts of the lateral and distal humerus.
4. In which elbow position can the HRJ space be felt most clearly?
5. How can therapists confirm the position of the HRJ space?
6. Which neurophysiological mechanisms can be used during palpation to differentiate the extensor carpi radialis brevis from the extensor digitorum?
7. Where can the median nerve best be palpated?
8. Which muscles (that can be palpated) are evident directly on the lateral epicondyle?



FIGURE 3-11 Common head of the flexor digitorum profundus and flexor digitorum superficialis.



FIGURE 3-12 Lateral epicondyle of the humerus.



FIGURE 3-13 Distal humerus.



FIGURE 3-14 Elbow joint in a flexed position.



FIGURE 3-15 Elbow joint in an extended position.



FIGURE 3-16 Elbow joint in a neutral position.



FIGURE 3-17 Elbow joint in a flexed position.



FIGURE 3-18 Elbow joint in an extended position.



FIGURE 3-19 Elbow joint in a neutral position.



FIGURE 3-20 Elbow joint in a flexed position.



FIGURE 3-21 Elbow joint in an extended position.



FIGURE 3-22 Elbow joint in a neutral position.



4 Hand

- Significance and Function of the Hand ... 71**
- Common Applications for Treatment in this Region ... 72**
- Required Basic Anatomical and Biomechanical Knowledge ... 73**
- General Orientation—Dorsal ... 76**
- Local Palpation of the Dorsal Soft Tissues ... 79**
- Local Palpation of the Dorsal Aspect of the Carpal Bones ... 84**
- General Orientation—Palmar ... 90**
- Local Palpation of the Palmar Soft Tissues ... 91**
- Local Palpation of the Palmar Aspect of the Carpal Bones ... 94**
- Study Questions ... 100**

THIS PAGE INTENTIONALLY
LEFT BLANK

4 Hand

Significance and Function of the Hand

The **osseous construction** of the hand and foot developed in the same manner during a long period of evolution. Even today, many similarities can be discovered between these two sections of the skeleton. It is well known that the acquisition of upright stand and bipedal locomotion differentiated the skeleton of the upper limb fully from the skeleton of the lower limb.

Hand function can be divided into three main areas: *prehension, touch, and gesture/communication.*

As the end organ of the upper limb, the hand is a well-developed working instrument with a **large variety of very fine functions**. Kapandji (2006) very impressively described the different types of grasp. These include power grips and precision handling, with pinching (bidigital grasping using the thumb and index finger) being the most important function.

The precision with which visually impaired people are able to recognize different surfaces, materials, and consistencies is always impressive. The high density of mechanoreceptors in the skin of the hand and particularly the fingertips provides humans with the extraordinary ability to perceive differences in the smallest of areas (ability to discriminate). The large sensory supply of the hand is mirrored in the hand's representation in the sensory cortex.

The hand naturally plays an important role in nonverbal communication, the interaction between gestures, mimic, and body posture. Everyone is familiar with typical, common, and international gestures and positions of the hand, such as the thumb and the index finger forming an "O" to indicate that everything is "okay."

Causes of the Diversity of Functions in the Hand

- A **large number of joints** in the wrist and the fingers, with some of these joints being very mobile. The amazing interaction between the bones of the wrist (carpal bones) is based on the three-dimensional movements seen in every bone during forward and backward movements of the palm (flexion and extension of the wrist) and sideways movements (ulnar and radial deviation of the wrist). The carpus provides the hand with astonishing mobility, with the range of flexion and extension amounting to a maximum of 180°.

- **Opposition of the thumb and the finger.** The ability of the first ray (thumb and first metacarpal) to turn toward the other fingers distinguishes the human hand from that of primates. This is particularly due to the trapezium, the base of the thumb, having rotated away from the other carpal bones. The saddle-shaped carpometacarpal joint of the thumb is also exceptionally mobile for a junction between the carpus and the

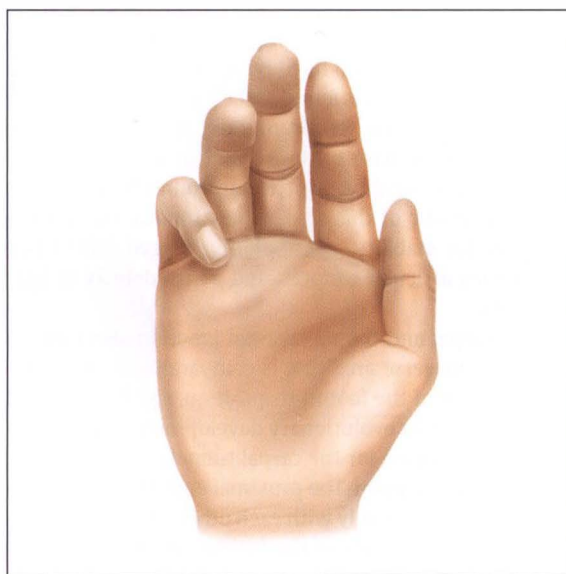


Fig. 4.1 Fifth finger facing the thumb.

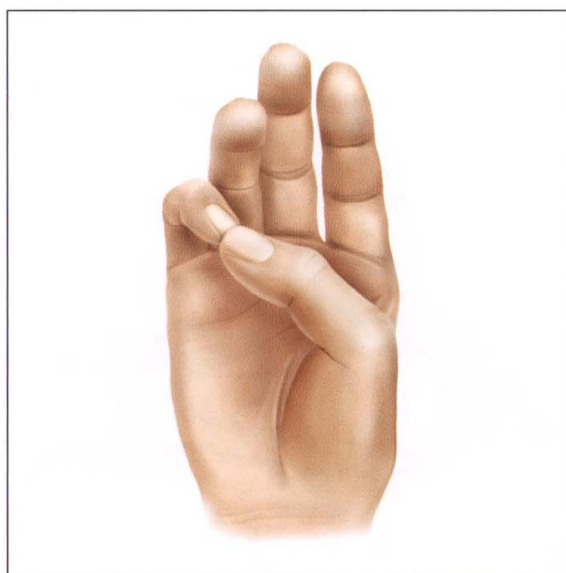


Fig. 4.2 Opposition of the thumb and the fifth finger.

metacarpus. These two characteristics, combined with the special muscles acting on the thumb, enable opposition.

Not only the thumb, but also the fingers are able to oppose. This becomes clear when therapists view the palmar aspect of the extended hand and flex each finger individually. Each fingertip faces the first carpometacarpal joint (Fig. 4.1).

Finger opposition can also be identified when the thumb touches the small finger. The finger pads of the thumb and fifth finger come into contact, not the sides of the fingers. The fifth metacarpal also has its own opponens muscle (Fig. 4.2).

- A **stable bony center** as the foundation for grasp. Mobility, expression, and functional diversity are impossible without a stabile base. The different types of grasp and the development of strength are almost impossible without a central fixed point within the hand.

This stabile center is found at the junction between the carpal bones (the second row of carpal bones in this case) and the base of the second to fifth metacarpal bones. The rigidity of articular connections here is characteristic of this area. All anatomical parameters speak for stability, not mobility: jagged joint lines, complex articular surfaces, and a high density of ligaments.

This carpal and the metacarpal junction also forms a bony transverse arch that is comparable to the transverse arch of the foot in its position, significance, and the point of its evolutionary development. It is the osseous foundation for the carpal tunnel.

- **Pliancy of the palm.** The proximal ends of the metacarpals articulate firmly with each other and with the carpus. The distal ends of the intermetacarpal joints are considerably mobile. The palm can therefore flatten itself out—important for power grips—as well as cupping the hand—which is of importance for precision handling using the fingers.

Moreover, the palm does not possess interfering muscle mass, in contrast to the short muscles in the sole of the foot.

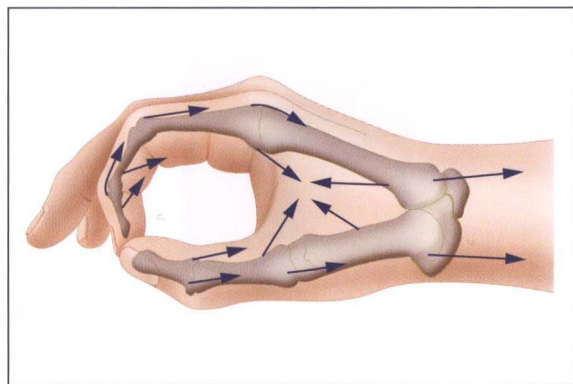


Fig. 4.3 Muscular control of the pincer grip.

Finally, the reinforced fascia of the hand (palmar aponeurosis) can be tightened by muscles designed especially for this purpose.

- The **very selective control of the large number of muscles**, the exceptional presence of the hand in the precentral gyrus, and the higher levels involved in voluntary motor skills are the motoric base needed for the multitude of functions (Fig. 4.3).

Common Applications for Treatment in this Region

Therapists have to deal with multifaceted symptoms in the hand incorporating almost the entire spectrum of symptoms associated with postoperative and nontraumatic conditions of the musculoskeletal system.

The special feature of this section of the skeleton is the close proximity of clinically relevant structures in a tight area. Therapists search for the source of most symptoms either in the carpus or its close proximity. Nontraumatic problems are rarely observed toward the forearm or the fingers. Therefore, the carpus region and the anatomical structures surrounding the carpus take up the largest proportion of the precise palpation of the hand.

Common Pathological Conditions in the Hand

- **Arthritis**, mainly caused by rheumatic disease or trauma. Joint inflammation is not only seen in the wrist area; it can also be observed in the distal radioulnar joint (DRUJ) and the first carpometacarpal joint. This does not make differentiation during assessment easier.
- **Restrictions in mobility**, mostly as a result of immobilization, for example, following fractures near the joint (Colles fracture). When presented with a hand with restricted mobility, the crucial issue for therapists is to localize the point of restriction. Should the therapist start treating the radiocarpal joint, or should the local carpal bones be assessed first?
- **Instability** in the hand region is a common cause for symptoms. It involves circumscribed hypermobility and either presents as capsular and ligamental strain or as an abnormal position (subluxation) of joints under loading.

A variety of areas can be found to be instable: in the carpus (lunate and along the ulnar column), in the distal radioulnar joint, and in the first carpometacarpal joint. The challenge for therapists is to use their understanding of local biomechanics and the precise localization of appropriate structures to find the causative hypermobility and therefore the source of symptoms. Local in vivo anatomy is immensely helpful here.

- **Soft-tissue conditions.** The passage of tendons and the fixed points of the long muscles in the wrist provide sufficient opportunity for the development of overuse problems. The entire spectrum of possible pathological conditions can be observed here: tenosynovitis, myo-tenosynovitis, and insertion tendinopathy. On the dorsal side, the tendons travel in tendon compartments. On the palmar aspect, nine tendons and one nerve are bundled together in the carpal tunnel. Symptoms in this region can often be treated with precisely applied interventions.
- **Nerve compression.** Similar to the situation at the elbow, three large peripheral nerves can also be compressed in the hand.

The median nerve can be compromised in the carpal tunnel. A variety of provocative tests for the carpal tunnel syndrome are based on the careful localization of the point of constriction. Cyclists occasionally compress the ulnar nerve in the Guyon canal. The radial nerve can be compressed as it passes through the fascia of the forearm into the superficial tissue.

It is an advantage of *in vivo* anatomy at the hand that patients are usually able to describe their symptoms exactly. Referred pain is not expected so far distally in the limb. In regard to diagnosis, this means that besides the assessment of function, the pain reported is of great importance to identify the affected structure.

Required Basic Anatomical and Biomechanical Knowledge

Students require a certain amount of important background information to understand the instructions for local palpation:

- The construction of the skeleton of the hand and fingers and, in particular, the name and position of the carpal bones and the longitudinal divisions of the hand.
- The names and positions of the tendons that cross over the wrist.
- The position and dimensions of the retinacula that keep the long tendons in the extensor compartments and the carpal tunnel.
- The position and construction of narrow passages for peripheral nerves in the hand, in particular the carpal tunnel.

Axial Divisions of the Skeleton of the Hand into Columns and Their Clinical Significance

In addition to the familiar horizontal divisions of the hand into the carpus, metacarpus, and phalanges (Fig. 4.4), the skeleton of the hand can also be divided in an axial direction (Fig. 4.5).

This classification is the result of experience when addressing clinical aspects. Each column consists of one or two rays (metacarpals plus phalanges) and the corresponding longitudinally positioned carpal bones.

Radial Column: This column comprises the first and second rays as well as the trapezium and scaphoid. Experience shows that arthrotic changes are most frequently detected here. The scaphoid articulates with four neighboring carpal bones and the radius so that it controls the biomechanics of both capitate and lunate (Fig. 4.6). Hypomobility is mainly observed in the radial column.

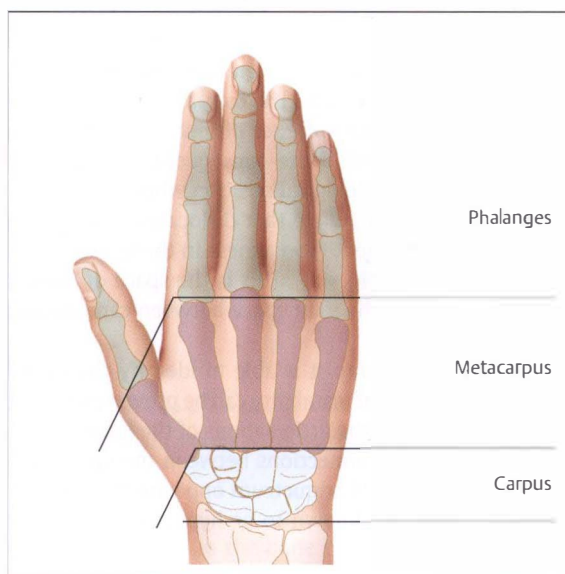


Fig. 4.4 Horizontal divisions of the skeleton of the hand.

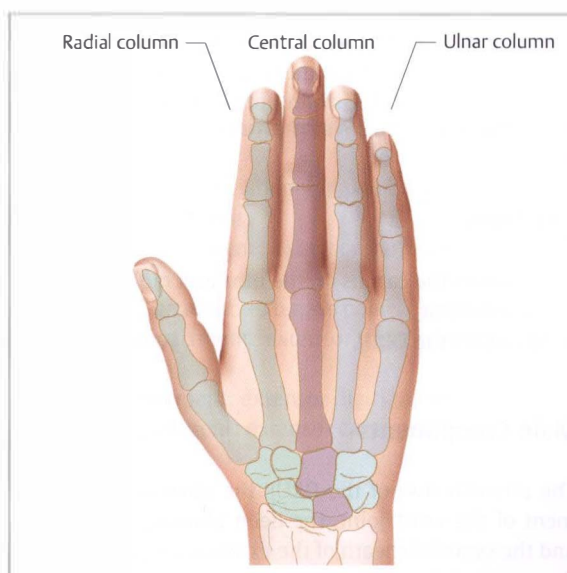


Fig. 4.5 Axial divisions of the skeleton of the hand.

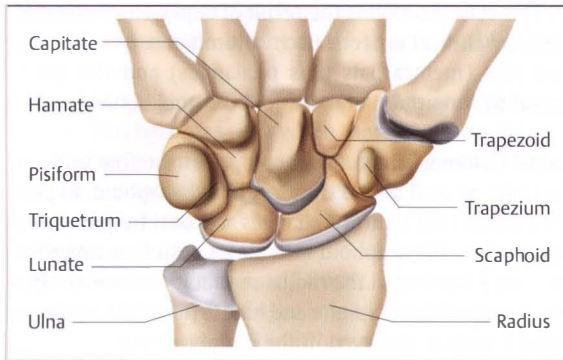


Fig. 4.6 Topography of the carpus—palmar view.

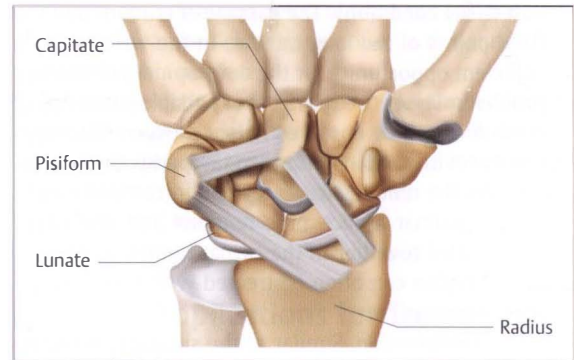


Fig. 4.7 Palmar ligaments

Central Column: The central column is formed by the longest ray of the hand (third metacarpal and the middle finger), capitate, and lunate. The column's special clinical feature is the frequent presence of local instability. This refers to dislocation and the consequential permanent fixation in a nonphysiological position when loaded.

It is primarily the lunate that dislocates, usually in a palmar direction, aided by weakness in the ligaments on the palmar aspect (Fig. 4.7). This is the space of Poirière, which is located in the joint space between capitate and lunate.

Providing the therapist is able to identify the carpal bones, the presence of instability can be proven by testing the local mobility of the articulations of the lunate.

Ulnar Column: The connections between the fourth and fifth rays, hamate, and triquetrum opposite the articular disk of the DRUJ are known to be hypermobile and can cause symptoms.

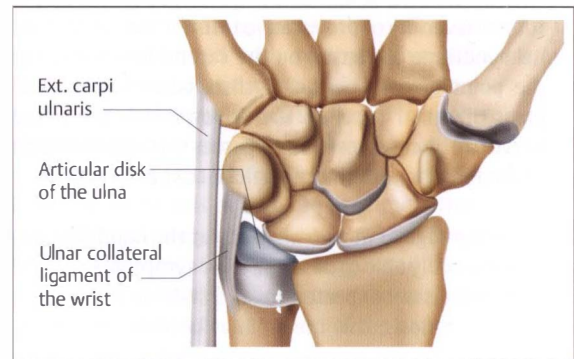


Fig. 4.8 Components of the TFC complex.

The margins of the TFC complex have a vascular and nociceptive supply and can therefore also be a direct source of pain.

Triangular and Fibrocartilage Complex

The triangular and fibrocartilage (TFC) complex controls stability in this region and the region surrounding the distal radioulnar joint. TFC stands for triangular and fibrocartilage (Fig. 4.8).

Functions

- Stabilizes the carpus on the ulna and radius.
- Load bearing.
- Stabilizes the DRUJ.

Main Components

The articular disk of the DRUJ, the ulnar collateral ligament of the wrist joint, the deep ulnocarpal ligaments, and the synovial sheath of the extensor carpi ulnaris tendon.

Construction of the Carpal Tunnel

The two rows of carpal bones form a transverse arch. The term "row" is actually quite confusing. The construction of the carpal arch becomes clear when the therapist examines the parts of bone that protrude palmarly (Fig. 4.9):

- Radial: scaphoid tubercle and trapezium.
- Ulnar: pisiform and the hook of hamate.

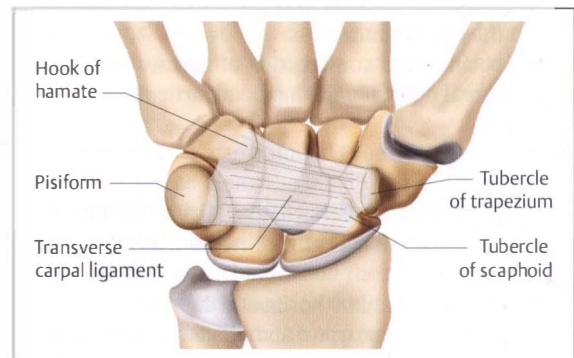


Fig. 4.9 Boundaries of the carpal tunnel.

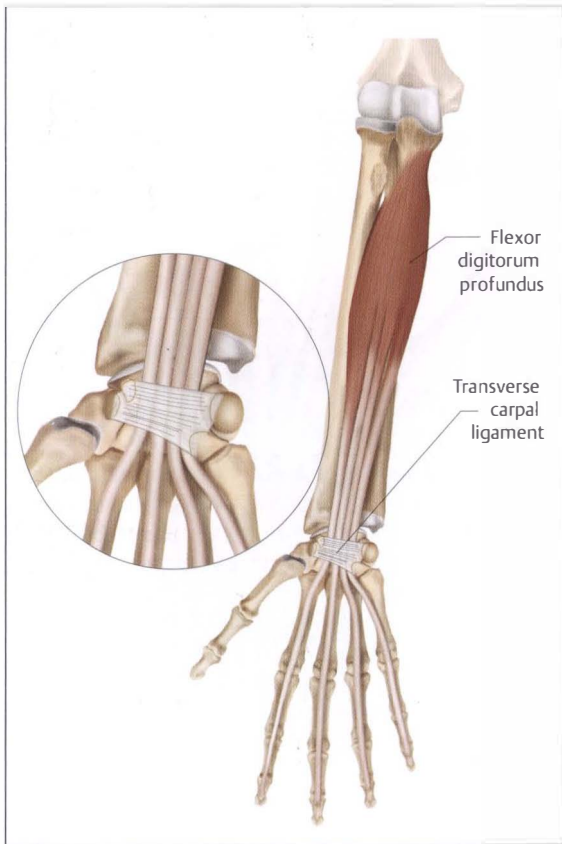


Fig. 4.10 Position and course of the flexor digitorum profundus.

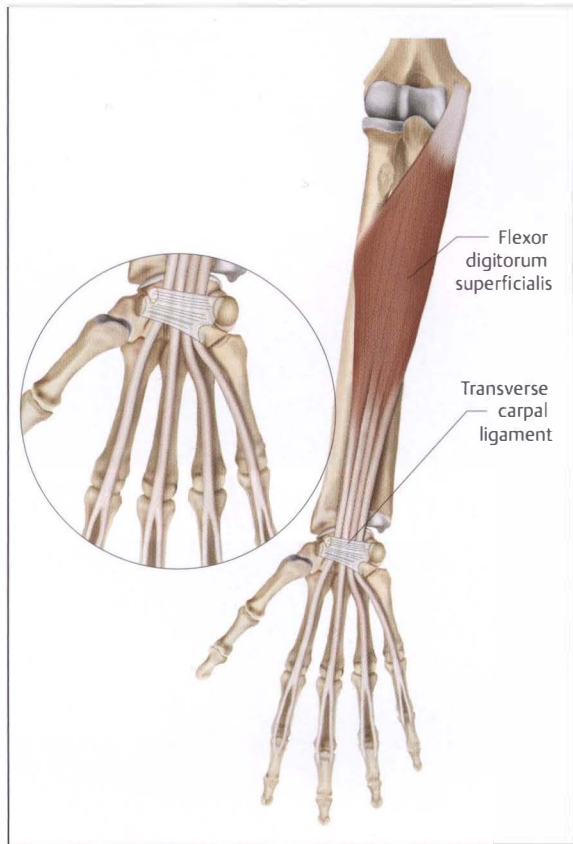


Fig. 4.11 Position and course of the flexor digitorum superficialis.

The transverse carpal ligament encloses this carpal arch, forming the carpal tunnel. The following structures pass through the carpal tunnel:

- The four tendons of the flexor digitorum profundus (**Fig. 4.10**).
- The four tendons of the flexor digitorum superficialis (**Fig. 4.11**).
- The tendon of the flexor pollicis longus (**Fig. 4.12**).
- Median nerve (**Fig. 4.12**).

In the past, the flexor carpi radialis tendon was considered part of the carpal tunnel. Its course underneath the ligament is listed as a separate passage in topographical anatomy (**Fig. 4.13**).

Extensor Tendons and Their Compartments

A thickening in the forearm fascia keeps the tendons of the long (extrinsic) muscles that move the skeleton of the hand and fingers on the dorsal radius and ulna and on the edges of the forearm.

This retinaculum maintains the position of all extensor tendons on the forearm, even during extensive movements of the hand or rotation of the forearm. The retina-

culum is attached to the bone between the tendons, so that small osteofibrotic canals are formed through which the tendons can pass. Tendon sheaths protect the tendons at this point from frictioning during movement.

The six canals through which the tendons pass are named tendon compartments (**Fig. 4.14**).

Tendon Compartments from Radial to Ulnar

- First compartment: abductor pollicis longus and extensor pollicis brevis.
- Second compartment: extensor carpi radialis longus and brevis.
- Third compartment: extensor pollicis longus.
- Fourth compartment: extensor digitorum and extensor indicis.
- Fifth compartment: extensor digiti minimi.
- Sixth compartment: extensor carpi ulnaris.

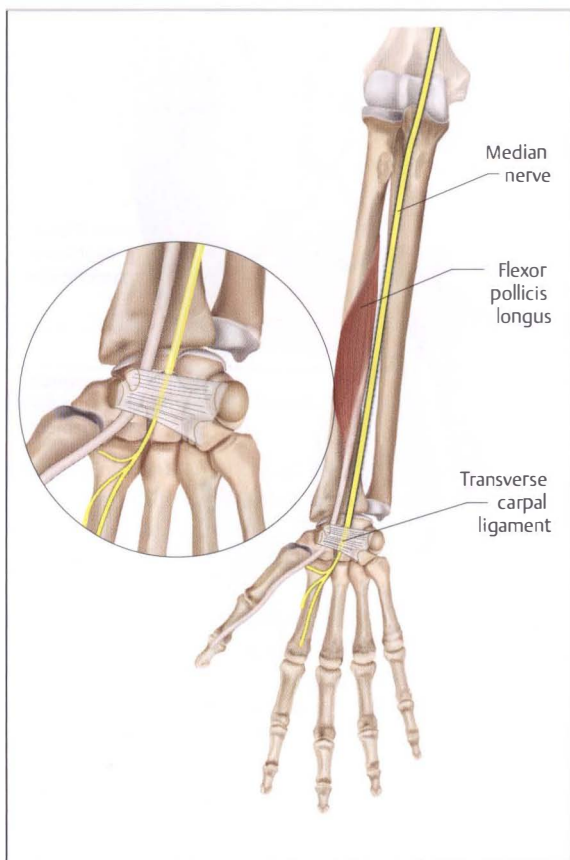


Fig. 4.12 Position and course of the flexor pollicis longus.

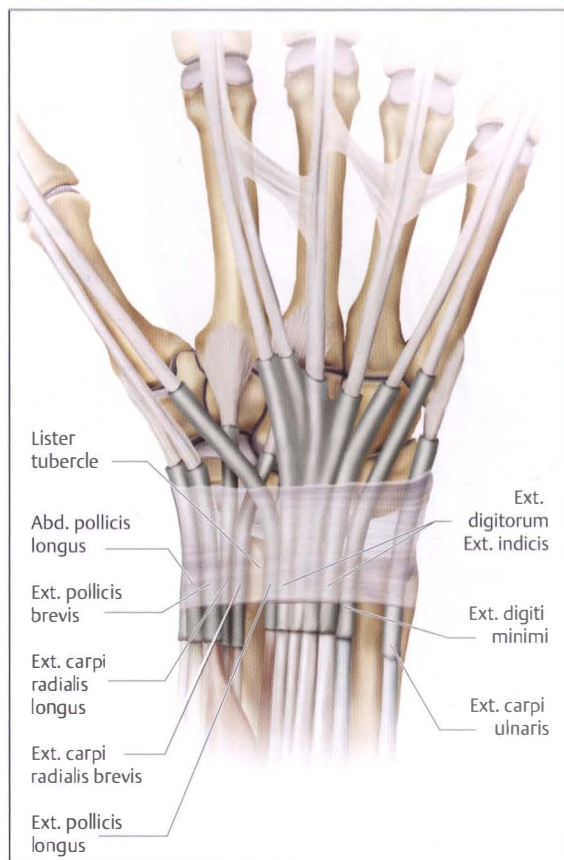


Fig. 4.14 Compartments for the wrist and finger extensor tendons.

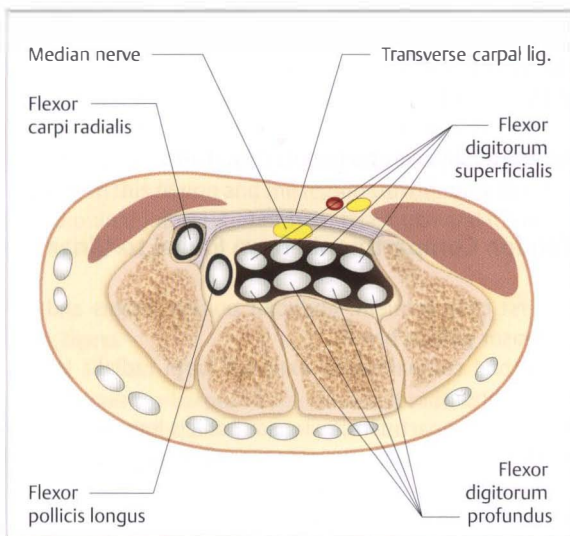


Fig. 4.13 Cross-section through the carpal tunnel.

General Orientation—Dorsal

Overview of the Structures to be Palpated

- Proximal boundary of the carpus (radiocarpal joint line).
- Alignment of the radiocarpal joint space.
- Distal boundary of the carpus (carpometacarpal joint line).

Summary of the Palpatory Process

The following instructions for the localization of the structures of the hand start on the dorsal aspect. The therapist first gains a general impression of the dimensions of the carpus and its proximal and distal boundaries so that precise information can be obtained on the size of the carpus and metacarpus. When first attempting to palpate this region, it is surprising how little space is available for the bones of the wrist on the dorsal aspect. The palpation will identify a space that is approximately as wide as an index finger when the wrist is in neutral.

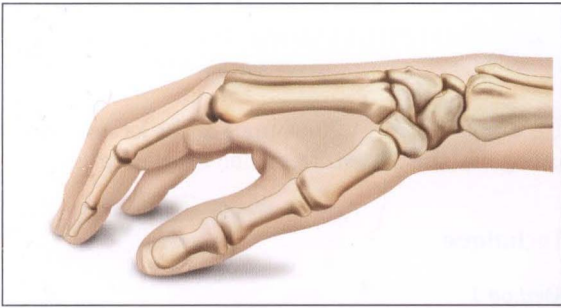

Fig. 4.15 Topography of the bones—ulnar view.

Starting Position

The therapist selects a position where the hand and forearm to be palpated are relaxed and the patient does not need to contract any muscles to maintain the position. When palpating osseous structures, it is of utmost necessity that all types of muscular contraction be avoided by placing the hand and forearm on a level surface (Fig. 4.15). If this is not done, the more superficially located tendons will be placed under tension and impede the specific search for deeper-lying structures. The therapist sits next to the ulnar side of the hand.

Directions will be described with the terms radial (toward the thumb), ulnar (toward the small finger), dorsal (toward the back of the hand), and palmar (toward the palm). This may take a while to get used to, but it enables the use of exact terminology and therefore understanding. For example, the joint space of the DRUJ is found radial to the head of the ulna.

Proximal Boundary of the Carpus (Radiocarpal Joint Line)

The boundary between the proximal row of carpal bones and the forearm marks the joint space for the radiocarpal joint. In particular, the joint line orients itself on the edges of the radius and ulna.

Technique

The palpating finger comes from a distal position so that the fingertip can be positioned on the radius and the head of the ulna (perpendicular palpation) (Figs. 4.16 and 4.17). This is easiest on the radial side of the hand in a depression in the carpus that will be described more precisely later in the text.

A bony edge is clearly palpated here. When the therapist palpates a little more toward the palm, the radial styloid process, which is the radial boundary of the radius, can be found (Fig. 4.18).

The same technique is used to locate the boundaries of the carpus by palpating from radial to ulnar. The rounded

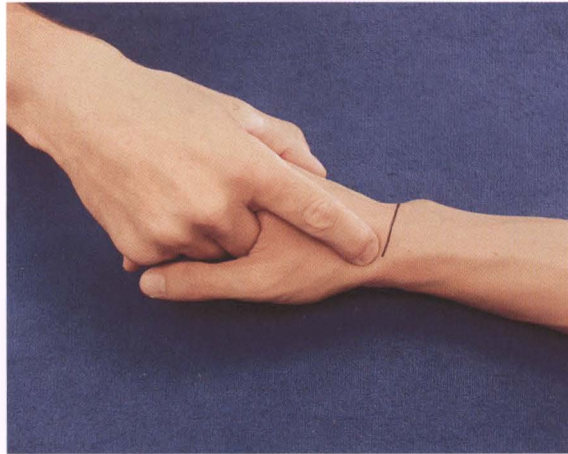


Fig. 4.16 Palpation of the radius from a distal position.

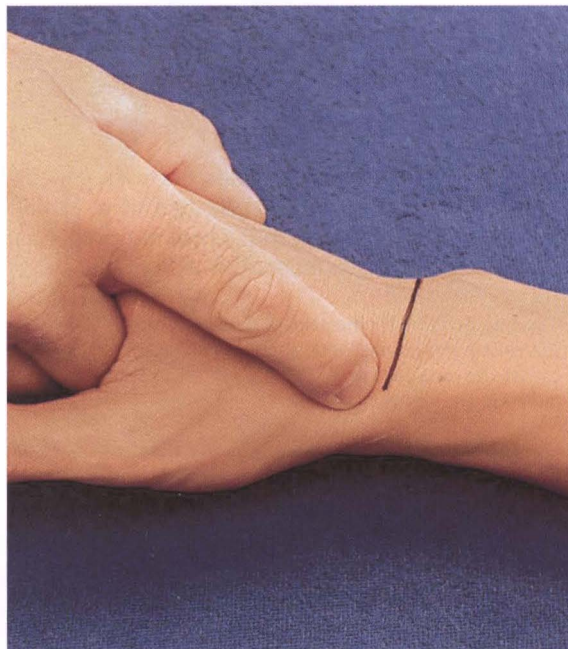

Fig. 4.17 Detailed view

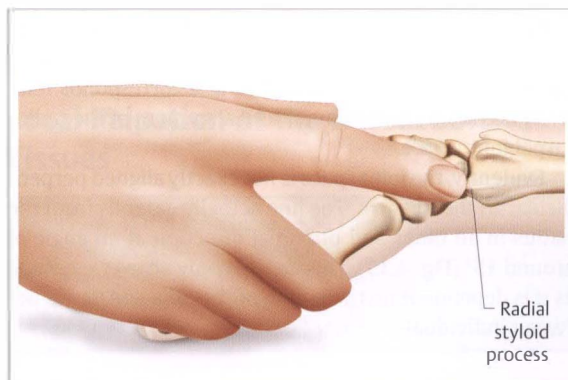


Fig. 4.18 Illustration of the palpation technique.

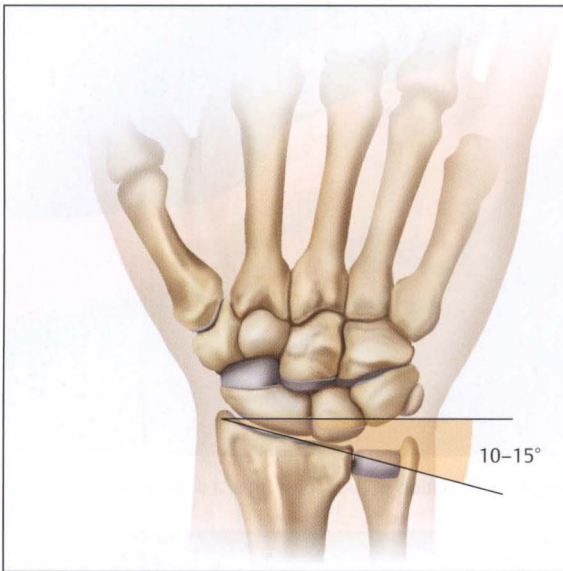


Fig. 4.19 Alignment of the radiocarpal joint space.

tendons passing through their compartments in the wrist increasingly interfere with the palpation more ulnarly. The palpation finishes distal to the head of the ulna and the ulnar styloid process on its ulnar aspect.

Tip: If tendons hinder the palpation of the edge of the radius, the wrist is extended slightly and the hand relaxed. This causes the proximal row of bones to disappear in a palmar direction and relaxes the soft-tissue structures.

Alignment of the Radiocarpal Joint Space

Another structure must be located to enable therapists to quickly find the proximal boundary of the radiocarpal joint space. When the palpating finger moves proximally between the second and third rays and onto the radius, a teardrop-shaped ridge called the dorsal tubercle of the radius or Lister tubercle is felt at the same level as the head of the ulna. The edge of the radius is found immediately distal to this point. It is easy to draw a line between the radial styloid process, the distal aspect of the Lister tubercle, and the ulnar styloid process. This line corresponds relatively accurately to the course and alignment of the radiocarpal joint space.

Evidently, the joint space is not exactly aligned perpendicular to the forearm. The line actually extends from the radius in an ulnar and proximal direction at an angle of around 15° (Fig. 4.19). This angle is only an average value as it is dependent on the length of the ulna and varies between individuals.

Distal Boundary of the Carpus (Carpometacarpal Joint Line)

The distal boundary of the carpus can be located by palpating the base of the corresponding metacarpals.

Technique

Method 1

One method involves stroking the palpating finger over a metacarpal from distal to proximal until the finger pad slides over the slightly raised base and into a shallow depression. The corresponding carpal bone is found here. The distal row of carpal bones generally lies somewhat deeper than the bases of the metacarpals. This depression becomes more apparent when the wrist is passively moved into slight extension.

Tip: This palpation is easier at the junction between the third metacarpal and capitate. The capitate has a slight depression on its dorsal aspect that is easily palpable (Fig. 4.20). This bone is an important starting point for the further localization of the surrounding carpal bones.

Method 2

A more accurate method involves palpating perpendicular to the bases of the metacarpals. The palpating finger is positioned proximally and at a right angle to the base of a metacarpal. The edge of the base can then be precisely identified (Figs. 4.21 and 4.22).

Tip: This palpation is even more reliable when the head of the metacarpal is slightly elevated, causing slight local extension, enabling the therapist to feel the base of the metacarpal pushing against the tip of the finger. Therapists should keep in mind that the fifth metacarpal is somewhat shorter than the other metacarpals so that the ulnar joint line forms a small step.

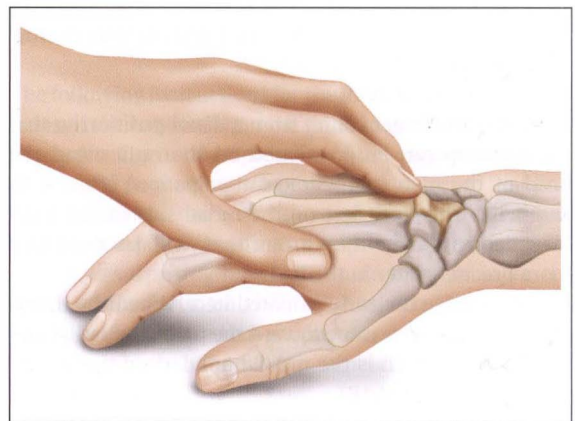

Fig. 4.20 Localization of the capitate.

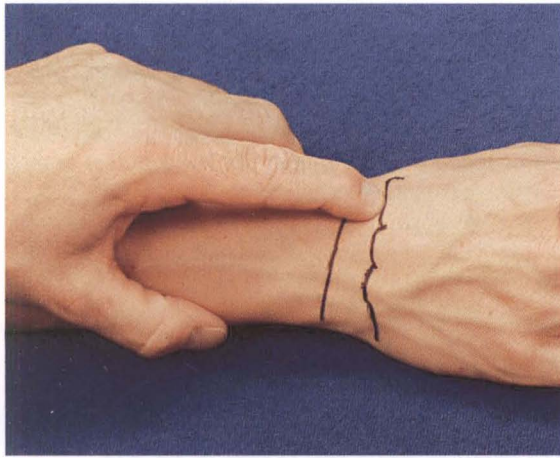


Fig. 4.21 Palpation of the base of a metacarpal.

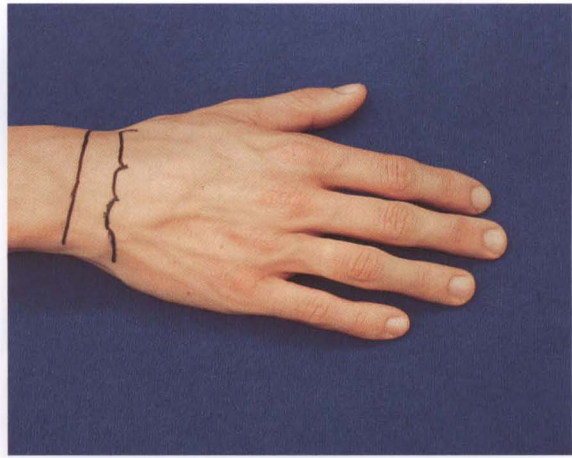


Fig. 4.23 Proximal and distal boundaries of the carpus.

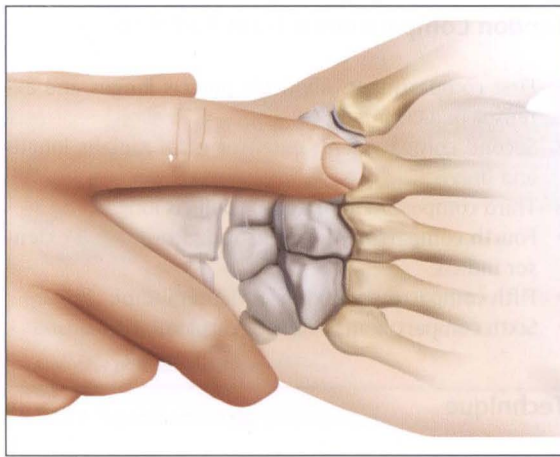


Fig. 4.22 Palpation technique—base of the second metacarpal.

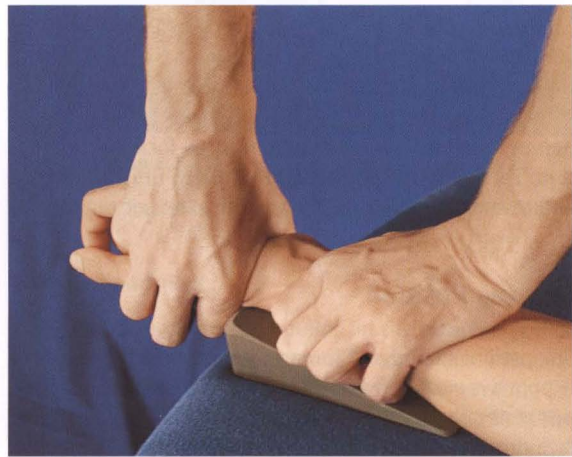


Fig. 4.24 Posterior—anterior glide of the carpus.

The last boundary of the carpus has been found, and the dimensions of the carpus become clear. Two rows of carpal bones are found that form an arch in an area about one finger-width wide (Fig. 4.23).

The carpus appears significantly larger in schematic illustrations of the skeleton of the hand, as well as in most anatomical models used during training or for general orientation. It would be completely misleading if these conceptions of topography were transferred onto live patients without confirming the anatomy using palpation.

Tips for Assessment and Treatment

Identification of the radiocarpal joint line is the most important aspect for orientation in a variety of techniques used in manual therapy. The angle of the joint line from radial to ulnar as well as from dorsal to palmar must therefore be considered and implemented.

The illustrated example demonstrates a translational glide at the radiocarpal joint that is used for assessment and treatment (Fig. 4.24).

Evidently, the position of the forearm on the supportive surface and the handling itself require correct knowledge of the position and alignment of the joint space and the articular bones.

Local Palpation of the Dorsal Soft Tissues

Overview of the Structures to be Palpated

- Radial fossa (anatomical snuffbox).
- Extensor tendons and their compartments.
- Radial nerve, cephalic vein, and radial artery.
- Distal radioulnar joint (DRUJ) space.

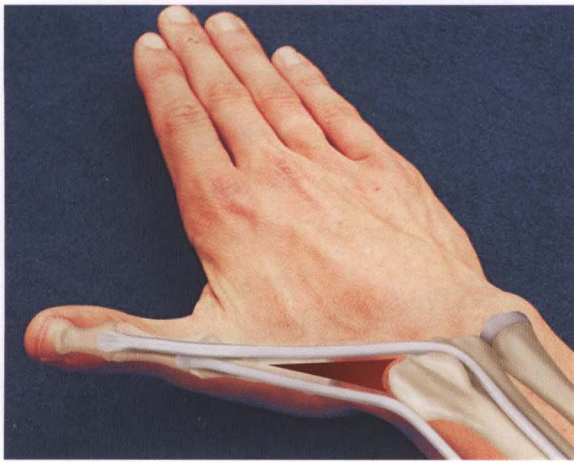


Fig. 4.25 Position of the radial fossa.

Summary of the Palpatory Process

Now that the dimensions and boundaries of the wrist have been clarified, the soft tissues (tendons, blood vessels, and nerves) become the main area of focus for local orientation. The palpation again begins radially, finishes ulnarly, and reveals the exact position of the extensor tendons.

Starting Position

The patient's hand and forearm are relaxed and rest on a supportive surface, which is as level as possible. The therapist generally sits to the side. The palm of the hand should face downward, enabling the dorsal and ulnar aspect of the wrist to be precisely palpated. If structures are being sought more on the radial side, the hand is positioned with the small finger downward.

Radial Fossa (Anatomical Snuffbox)

A triangular-shaped depression can be found in the radial region of the carpus that has already been used as a SP for the palpation of the boundary of the carpus. This depression is called the radial fossa, or the anatomical snuffbox (Fig. 4.25). Therapists can easily observe and palpate swelling here caused by inflammation in the wrist.

The following structure forms the boundaries of the radial fossa:

- Proximal = radius.
- Dorsal = extensor pollicis longus tendon.
- Palmar = extensor pollicis brevis tendon.

Technique

Usually, the participating muscles must contract so that the position of the bordering tendons can be located and

the radial fossa identified. The patient's hand is positioned with the small finger downward, and the patient is instructed to move the thumb upward toward the ceiling (extension of the thumb).

If the radial fossa is not yet obvious, the bordering extensor tendons of the thumb can be identified using a transverse palpation technique.

The two tendons of the thumb extensors come closer to each other more distally. The structures of the radial column are found in the floor of this depression (see instructions for localization on p. 85).

Extensor Tendons and Their Compartments

As a refresher, please refer to page 76, Fig. 4.14.

Tendon Compartments from Radial to Ulnar

- First compartment: abductor pollicis longus and extensor pollicis brevis.
- Second compartment: extensor carpi radialis longus and brevis.
- Third compartment: extensor pollicis longus.
- Fourth compartment: extensor digitorum and extensor indicis.
- Fifth compartment: extensor digiti minimi.
- Sixth compartment: extensor carpi ulnaris.

Technique

First Compartment

The ulnar side of the patient's hand is still positioned downward and the snuffbox is made distinct by moving the thumb (Figs. 4.26 and 4.27). The most palmar tendon bundle is located using transverse palpation. The patient then relaxes the thumb and the tendon bundle is followed proximally until the bony resistance of the radius is felt. This is the point where both tendons pass underneath the retinaculum through the first compartment.

Tips:

- If it is difficult to feel the tendons on the radius, it can be very helpful if the patient actively moves the thumb back and forth in extension and flexion so that the tendon is repeatedly tensed.
- The distal sections of the tendons can be differentiated from one another at the anatomical snuffbox:
 - *Extensor pollicis brevis*: the patient extends the thumb; the wrist remains in neutral.
 - *Abductor pollicis longus*: it is significantly more difficult to palpate or even see this tendon. It can be reliably palpated when the thumb abducts strongly in a palmar direction (perpendicular to the palm), during which the wrist should be slightly flexed. The tendon guides the therapist to the base of the first metacarpal.

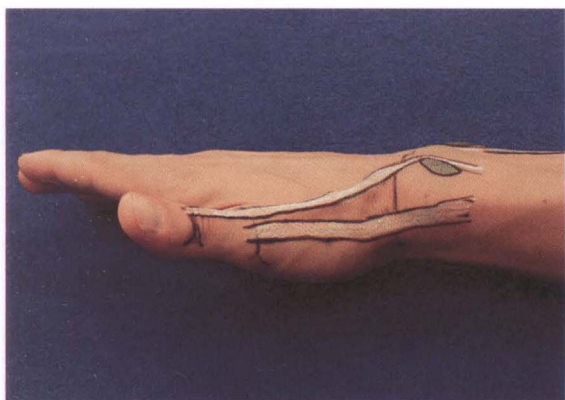


Fig. 4.26 Tendons of the first and second compartments.

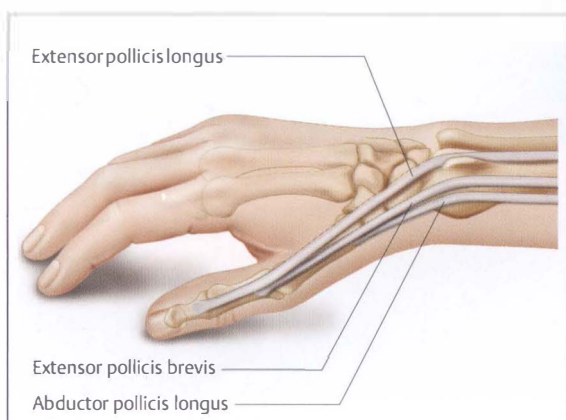


Fig. 4.27 Topography of the ulnar tendons.

The first compartment is one of the most common sites for tenosynovitis, and inflammation here is named de Quervain syndrome.

Second Compartment

The further differentiation of second and third compartments starts on the Lister tubercle.

The therapist palpates radial to the Lister tubercle (see p. 78). The patient gently extends the wrist rhythmically so that tension can again be identified in the tendons of the extensor carpi radialis longus and brevis. Both of these tendons occupy the second tendon compartment. If the therapist follows the tendons distally when the muscles are active, the therapist can identify a “V-formed” separation of the two tendons just before they pass underneath the extensor pollicis tendon. In some cases, it may even be possible to follow both tendons to their insertions. The extensor carpi radialis longus tendon is more obvious radially on the base of the second metacarpal, while the brevis tendon can be found between the bases of the second and third metacarpals.

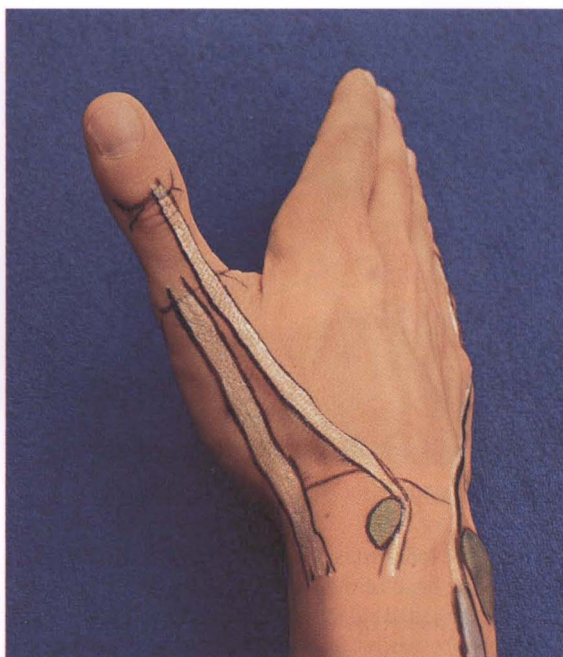


Fig. 4.28 Lister tubercle and the thumb extensor tendons.

Third Compartment

The Lister tubercle acts as a pulley for the extensor pollicis longus tendon. The tendon comes from the distal forearm and changes direction at the tubercle, from where it travels toward the distal phalanx of the thumb (Fig. 4.28). When the thumb is repeatedly extended and flexed over a small range, the therapist can palpate the tendons in its (third) compartment immediately ulnar to the tubercle.

Fourth Compartment

The tendons of the fourth compartment are found immediately ulnar to the extensor pollicis longus tendon. It is easy to palpate the extensor digitorum tendons. To do this, the patient lifts up the fingers one at a time, as if playing a piano. The tendons immediately push against the palpating finger. It is not as easy to isolate the tendon of the second muscle in this compartment, the extensor indicis.

Tip: The extensor indicis tendon is found on the back of the hand, ulnar to the extensor digitorum tendon that travels to the index finger. It can be felt and is sometimes visible when the index finger is extended and moved to the side.

Distal Radioulnar Joint Space and the Palpatory Technique for the Fifth Compartment

Further palpation on the dorsal carpus is directed toward the region surrounding the head of the ulna.

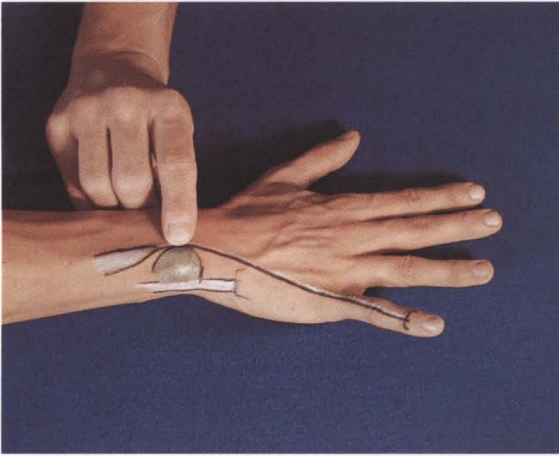


Fig. 4.29 Palpation of the extensor digiti minimi.

When the forearm is supported in a relaxed pronated position, the head of the ulna is surrounded by two tendons. On the radial side, the tendon of the extensor digiti minimi can be easily felt over the metacarpal and carpal bones when the muscle is slightly contracted. The tendon can also be followed further proximally (**Fig. 4.29**). It passes directly radial to the head of the ulna and simultaneously marks the position of the deeper-lying joint space of the distal radioulnar joint (DRUJ). The tendon in the fifth compartment is a guiding structure when searching for the joint space.

Tip: To prevent confusion of the tendons of the extensor digiti minimi and extensor digitorum, reciprocal inhibition of the finger extensors is again recommended as an aid. The patient is instructed to push the pads of the second to fourth fingers into the supportive surface and then extend the small finger (**Fig. 4.30**).

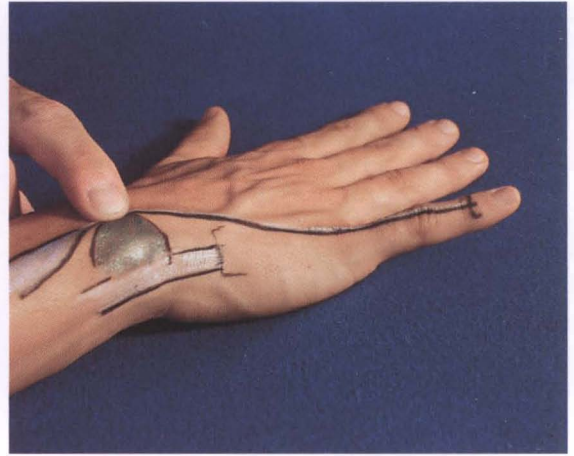


Fig. 4.30 The head of the ulna is surrounded by two tendons.

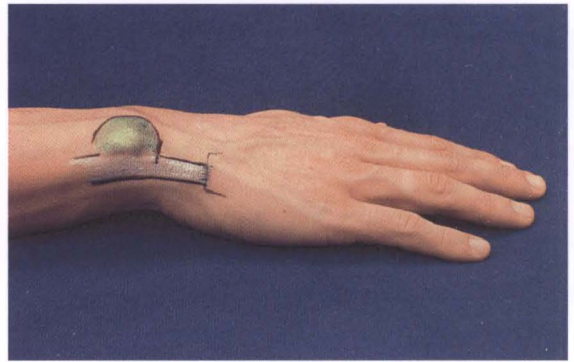


Fig. 4.31 Position of the tendon of the extensor carpi ulnaris.

Sixth Compartment

The extensor carpi ulnaris tendon is found immediately ulnar to the head of the ulna. It can be clearly palpated over the carpus when the muscle is active (wrist extension and ulnar deviation). It is easily followed distally down onto its insertion at the base of the fifth metacarpal and proximally as it passes by the head of the ulna. The tendon travels through the sixth compartment in a shallow osseous groove (**Fig. 4.31**).

By keeping two fingers on the tendon near the head of the ulna and supinating the forearm, the therapist will discover that the head of the ulna rotates underneath the tendon and that the tendon is now lying on the dorsal aspect of the head of the ulna. This shows the strain that is placed on the synovial sheath of the tendon through constant repetition of forearm rotation.

Radial Nerve, Cephalic Vein, and Radial Artery

The superficial branch of the radial nerve is found in the second compartment proximal to the anatomical snuff-box. It penetrates the fascia of the forearm immediately proximal and radial to the short muscle bellies, where it lies directly beneath the skin. The muscle bellies involved here abduct and extend the thumb.

Technique

Radial Nerve

Initially, the contracted muscle bellies of the thumb extensors are located. The hand forms a fist (including the thumb) and is facilitated into ulnar deviation and extension of the wrist. The radial nerve rolls underneath the transversely palpating fingertips immediately proximal and radial to the muscle bellies.

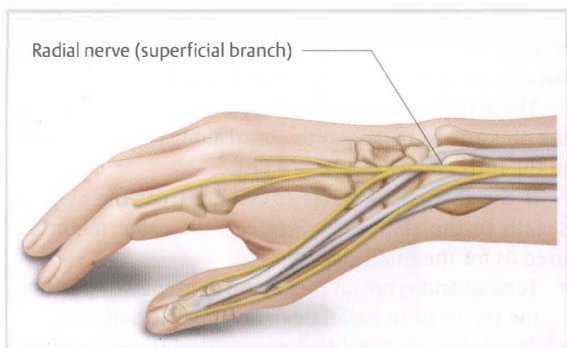


Fig. 4.32 Branches of the radial nerve—ulnar view.

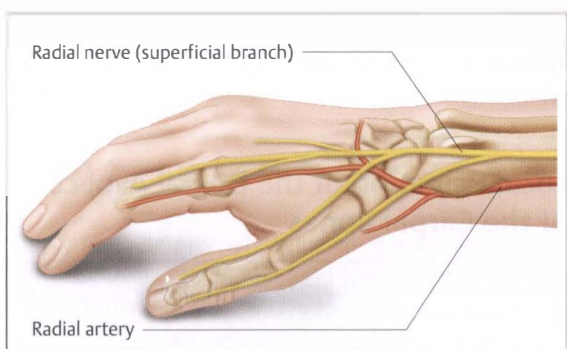


Fig. 4.33 Course of the radial artery.

The nerve can be followed over its entire radial course (Fig. 4.32):

- It first crosses over the tendons of the first compartment.
- It lies between the first and second tendon compartments, directly superficial to the bone of the distal radius.
- The cephalic vein accompanies the radial nerve in the anatomical snuffbox, crossing over the snuffbox superficially. This is an appropriate site for intravenous access as the vein is located just beneath the skin and usually easy to reach. The weak pulse of a radial artery branch can be felt deep in the anatomical snuffbox by palpating its osseous floor with light pressure (Fig. 4.33).
- Finally, the nerve and vein can be followed as they cross over the tendon of the extensor pollicis longus.

Tip: The tension in the radial nerve increases when the elbow is extended and the forearm supinated. The nerve's superficial position makes it susceptible to compression, often arising when bracelets or watches are too tight.

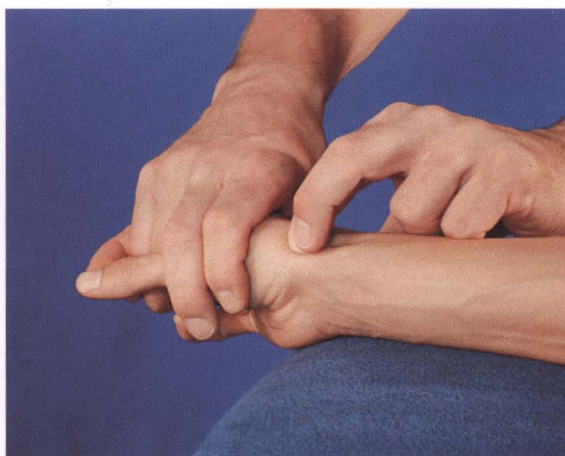


Fig. 4.34 Transverse friction at the tendons of the first compartment.

Tips for Assessment and Treatment

As already emphasized, predestined for inflammatory processes are the passages of tendons and their synovial sheaths through the extensor compartments. The first compartment is one of the most common sites for tenosynovitis. The de Quervain syndrome is located at the extensor retinaculum or more distally at the anatomical snuffbox.

Technique

Transverse Frictions at the First Compartment

Transverse frictions is administered as a provocative test and for treatment.

The patient's hand is first positioned in ulnar deviation and the thumb positioned more ulnarly (pain free). This places the tendon and synovial sheath under sufficient tension to ensure that they do not disappear deeper into the tissue or roll away from underneath the finger when pressure is applied during frictioning.

The free hand holds onto the back of the hand and stabilizes the thumb. The index finger is placed over the affected site, and the middle finger is placed with light pressure over the index finger as a support (Fig. 4.34). The frictions are conducted by applying pressure from palmar to dorsal exactly perpendicular to the fibers of the tendon. The fingers return to the starting position without applying pressure, but nevertheless maintaining skin contact.

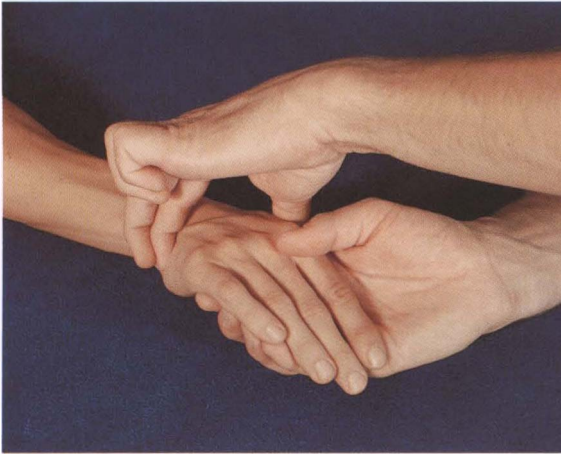


Fig. 4.35 Transverse frictions at the tendons of the sixth compartment.

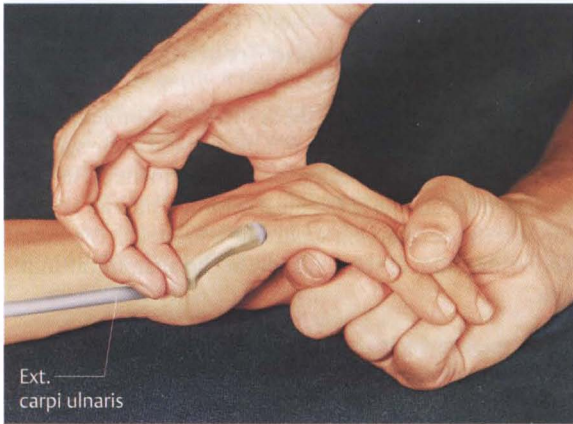


Fig. 4.36 Transverse frictions—radial view.

Transverse Frictions for Insertion Tendinopathies in the Sixth Compartment

Another example of the application of local palpation of the hand is the application of transverse frictions onto the insertion for the extensor carpi ulnaris at the base of the fifth metacarpal.

As the tendon comes from a proximal position and inserts directly into the base of the fifth metacarpal, the therapist is faced with the challenge of even reaching the site of insertion.

This can be achieved when two aspects are taken into consideration:

- The tendon must be pushed deep into the tissues onto the carpal bones.
- The palpating finger pads come from a proximal position and rest against the base of the metacarpal.

This is possible when the hand is positioned so that the tendon is passively approximated and the palpating hand is positioned in pronation (Fig. 4.35).

The actual transverse frictions are conducted by applying pressure from palmar to dorsal along the ulnar border of the fifth metacarpal (Fig. 4.36).

If the therapist wishes to mainly treat the synovial sheath in the sixth compartment, the same method is used as for the first compartment:

- Tendon and synovial sheath are tightened by positioning the wrist in radial deviation and flexion.
- The technique is applied perpendicular to the tendon; pressure is applied during the movement from palmar to dorsal.

This procedure can be used for all other conditions of the synovial sheath.

Local Palpation of the Dorsal Aspect of the Carpal Bones

Overview of the Structures to be Palpated

- Carpal bones in the radial column:
 - Bones in the anatomical snuffbox (edge of radius, scaphoid, trapezium).
 - First carpometacarpal joint.
- Carpal bones in the central column:
 - Capitate.
 - Lunate.
 - Boundary between the lunate and scaphoid.
- Carpal bones in the ulnar column:
 - Triquetrum.
 - Hamate.

Summary of the Palpatory Process

Therapists now have a general idea of the dimensions of the carpus and metacarpus. The superficial soft-tissue structures on the back and edges of the hand have been located.

The next step involves palpating deep in the tissue to differentiate the individual wrist bones in the carpus from one another. Therefore, therapists orient themselves on the longitudinal divisions of the hand, the columns, consisting of rays (metacarpals and phalanges) and carpal bones (Fig. 4.37). Palpation begins radially and finishes ulnarly.

Starting Position

The patient's hand and forearm relax again on a supportive surface, which is as level as possible. The therapist generally sits to the side. The palm of the hand should face downward to enable the dorsal and ulnar aspect of

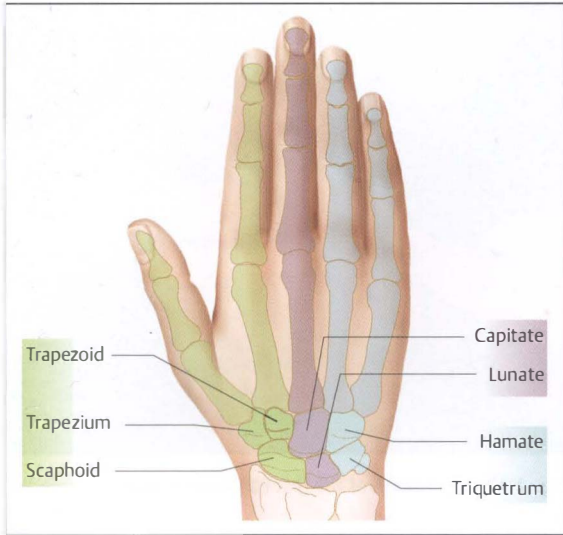


Fig. 4.37 Division of the hand into columns.

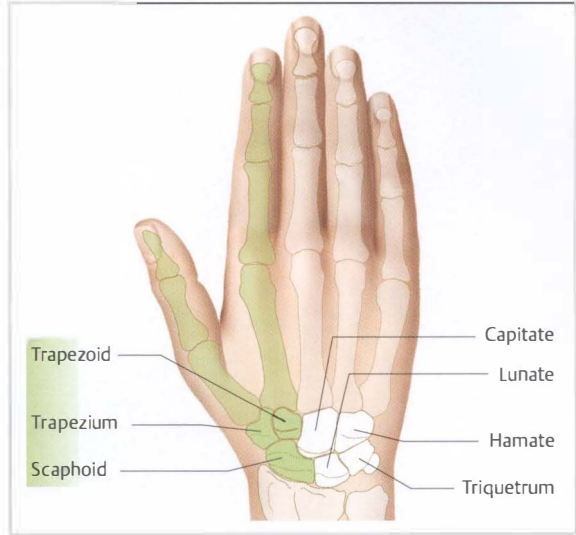


Fig. 4.38 Parts of the radial column.

the wrist to be precisely palpated. If more radial structures are being sought, the hand is placed with the small finger downward.

Carpal Bones in the Radial Column (Fig. 4.38)

Bones in the Anatomical Snuffbox

The anatomical snuffbox is formed when the thumb extends to the side. Therapists are familiar with its tendinous and bony borders (see p. 80). The carpal bones will now be palpated in the floor of the snuffbox.

Technique

Scaphoid

The index finger of the palpating hand comes from a distal position and strokes over the thumb in a proximal direction until the pad of the index finger is resting in the anatomical snuffbox. The tip of the index finger can now feel the edge of the radius very clearly, and the pad of the index finger is resting directly over the radial aspect of the scaphoid (Fig. 4.39).

Tip: The palpation is confirmed using the pattern of scaphoid movement during passive radial and ulnar deviation of the hand. The scaphoid pushes against the pad of the index finger during ulnar deviation and lies in a deeper depression during radial deviation.

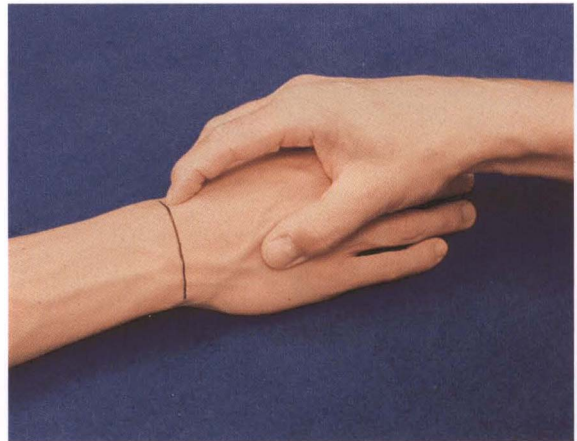


Fig. 4.39 Localization of the scaphoid.

Trapezium

To palpate the borders of the trapezium, the tip of the index finger must be turned so that it points distally toward the tip of the thumb by rotating the palpating hand 180°. The pad of the index finger rests again in the shallow depression of the anatomical snuffbox. The fingertip now comes into contact with the hard, bony resistance of the trapezium (Fig. 4.40).

Tip: The correct localization is confirmed through a small motion. The tip of the index finger should not feel any movement during small-range, passive extension of the thumb (Fig. 4.41).

The scaphoid again disappears deep into the tissue during small-range radial deviation, and the distinct edge of the trapezium remains palpable.

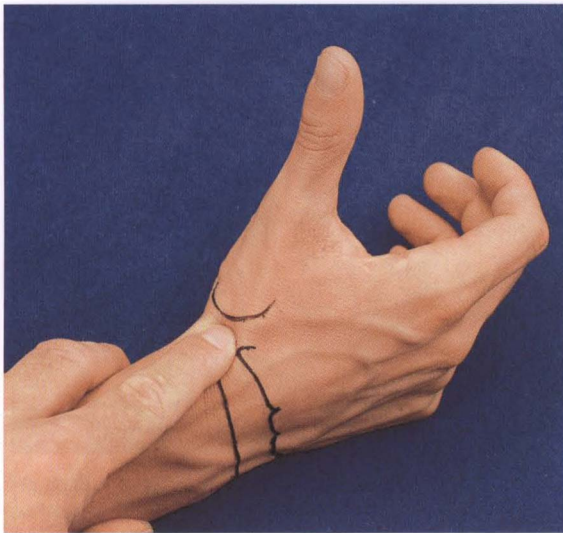


Fig. 4.40 Localization of the trapezium.

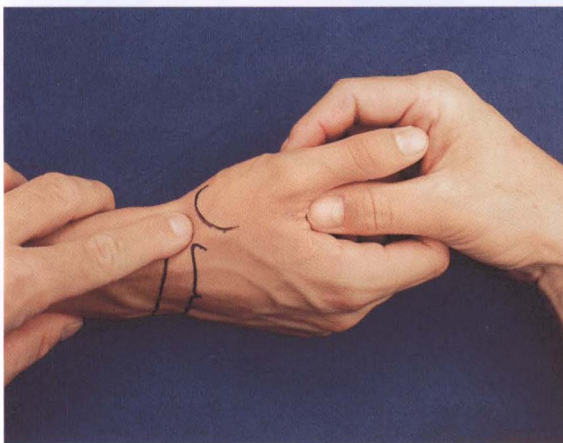


Fig. 4.41 Confirmation of the correct localization using movement.

First Carpometacarpal Joint

The exact localization of this joint is important. Symptoms may arise here as a result of hypermobility and arthritis.

The index finger initially remains on the scaphoid with the fingertip resting on the trapezium. The palpating index finger now slides a few millimeters distally.

When the therapist now passively extends the thumb, movement should be felt as the base of the first metacarpal pushes against the finger. The first carpometacarpal joint space is found here (Fig. 4.42).

The entire dimensions of the base can be identified by constantly moving the thumb over a small range. Movement of the thumb in a dorsal and palmar direction is suitable if therapists wish to follow the base on the palm. Adduction of the thumb causes the base to protrude palmarly (Fig. 4.43).

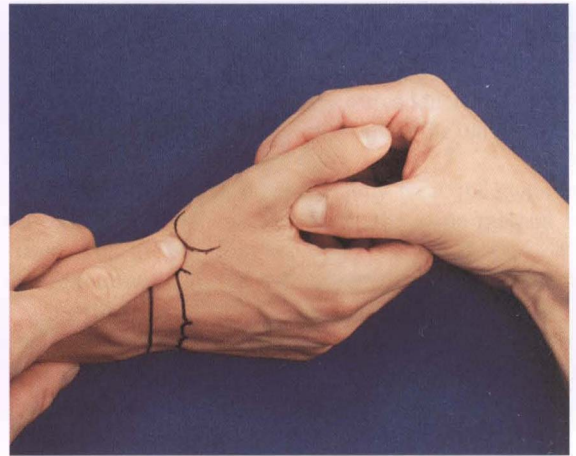

Fig. 4.42 Localization of the first carpometacarpal joint space.

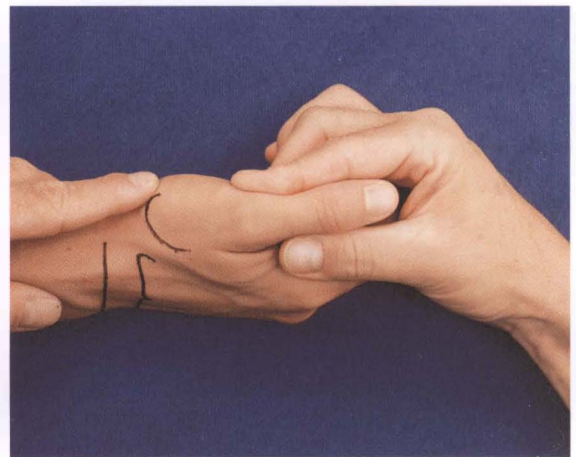


Fig. 4.43 Palmar palpation of the joint space.

During this movement, the base follows the rolling and gliding behavior according to the concave-convex rule of local biomechanics. The trapezium is found proximal to this. The localization of its palmar aspect will be described more precisely later in the text.

Tips for Assessment and Treatment

The following examples demonstrate possible uses for local palpation of the radial column:

- Once a carpal bone has been located, the therapist can move the articulations with its neighboring bones in a palmar and dorsal direction. By comparing sides, information can be obtained on possible changes in mobility, that is, hypermobility or hypomobility. In particular, minor or end range restrictions in wrist mobility can be identified.

An example is the isolated movement of the scaphoid on the radius (Fig. 4.44). This is achieved by resting

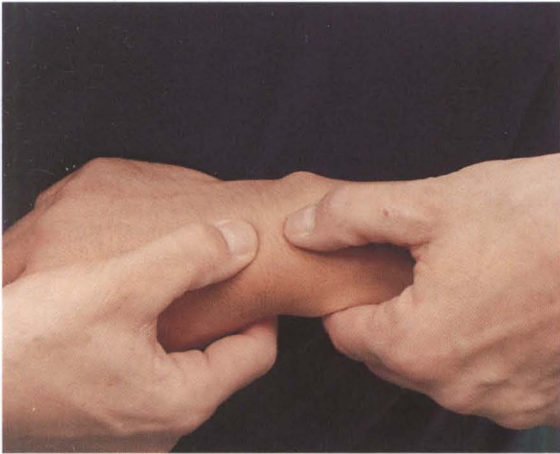

Fig. 4.44 Gliding of the scaphoid on the radius.

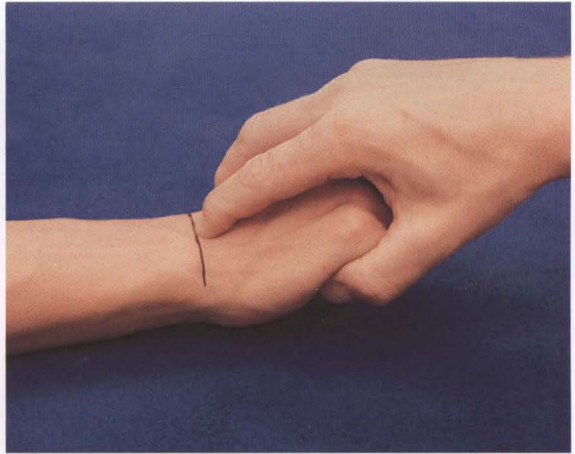


Fig. 4.46 Searching for the capitate.

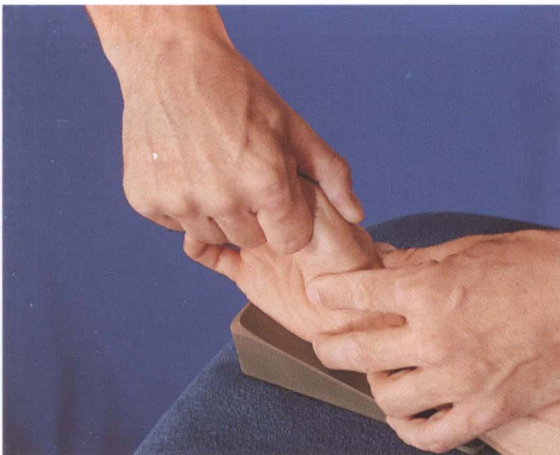

Fig. 4.45 Traction of the first carpometacarpal joint.

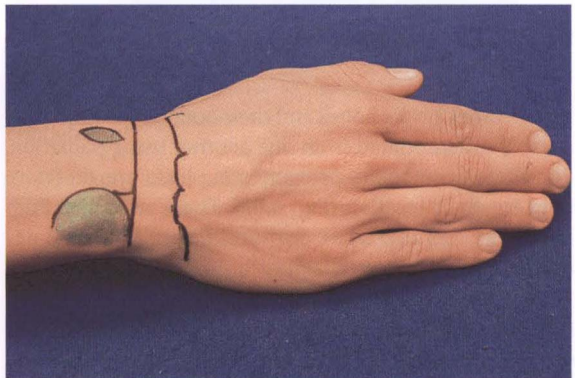

Fig. 4.47 Overview—osseous borders on the dorsal aspect.

the ulnar side of the patient's hand against the body to stabilize the hand. One hand grasps around the radius to fixate it. The other holds onto the scaphoid on its dorsal and palmar aspects (see p. 96). The therapist can now translate the scaphoid dorsally and palmar and compare range of motion with the other hand.

- These changes in mobility can also be found in the often painful arthritic condition (acute basal joint arthritis) of the carpometacarpal joint of the thumb. One of the manual therapy techniques that can be used here is traction (Fig. 4.45), which assesses the current level of elasticity in the capsule by pulling on the first metacarpal. The advantage of accurate knowledge of local anatomy is demonstrated during the necessary precise stabilization of the trapezium.
- Transverse frictions applied to the capsule of the first carpometacarpal joint have been proven effective in relieving pain. The therapist must be able to locate the joint space to use this technique.

Carpal Bones in the Central Column

Technique

Capitate

The palpation starts distally. The hand of the therapist is positioned along the extended axis of the patient's hand.

The pad of the index finger or middle finger slides proximally along the third ray. A slightly bulging osseous structure can be felt at the base of the third metacarpal. The therapist then slides the finger pad more proximally directly into a shallow depression (Fig. 4.46).

This depression becomes deeper when the wrist extends and slowly disappears when it flexes. On feeling this, the therapist can be certain that the finger pad is on the capitate.

The Lister tubercle and the DRUJ space are needed as reference points for the further differentiation of carpal bones from one another (see pp. 78 and 81) (Fig. 4.47).




Fig. 4.48 Connecting lines that radiate from the capitate.

The other carpal bones and their boundaries cannot be reliably differentiated from one another using palpation. Bony reference points or connecting lines are therefore used for their location (Fig. 4.48). These reference lines have been reproduced on anatomical specimens and demonstrate consistent reliability.

Orientation begins on the capitate.

Lunate

The lunate, another component of the central column, is located by moving the palpating finger about 1 cm proximal and slightly ulnar. The lunate is found exactly halfway along the line connecting the capitate and the joint space of the DRUJ.

Tip: The correct localization is confirmed by moving the wrist into flexion and extension, as was the case for the capitate. The lunate disappears palmar during passive extension of the wrist and the edge of the radius becomes palpable.

Boundary between the Lunate and Scaphoid

The scaphoid can be found halfway along the line connecting the capitate and Lister tubercle. Another connecting line reveals the boundary between the lunate and scaphoid and involves connecting the Lister tubercle to the DRUJ space. The joint space between these two carpal bones is found halfway along this line.

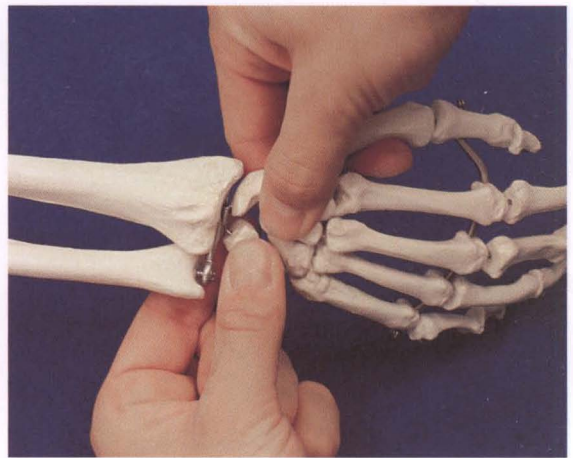


Fig. 4.49 Testing the mobility of the lunate on the capitate on a skeletal model.

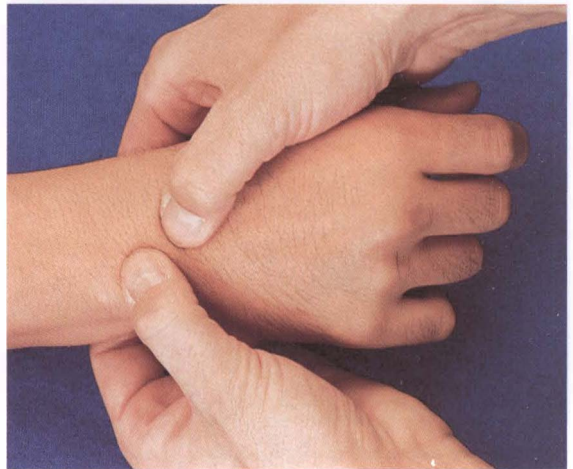

Fig. 4.50 Testing the mobility of the lunate on the capitate in vivo.

Tips for Assessment and Treatment

In particular, the assessment of lunate mobility on the capitate and the radius provides therapists with information on the presence of lunate instability within the central column (Figs. 4.49 and 4.50).

Mobility is often restricted in the articulation between lunate and scaphoid and can interfere with mobility in both the proximal row of the carpal bones and movements in the wrist as a whole (Figs. 4.51 and 4.52).

Carpal Bones in the Ulnar Column

The palpation begins proximal, on the forearm. The recommended position for the therapist is on the thumb side of the hand, allowing free access to the ulnar column (Fig. 4.53).

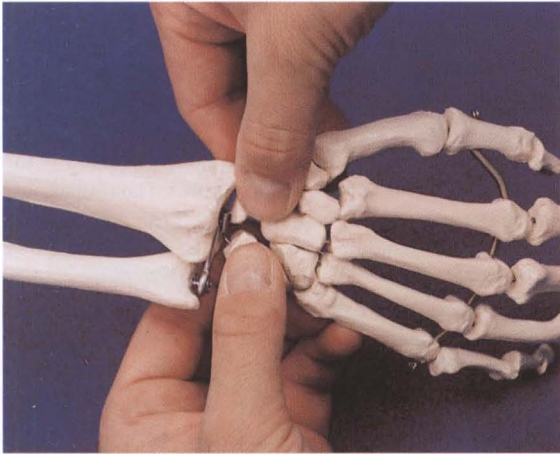


Fig. 4.51 Testing the mobility between the lunate and the scaphoid on a skeletal model.

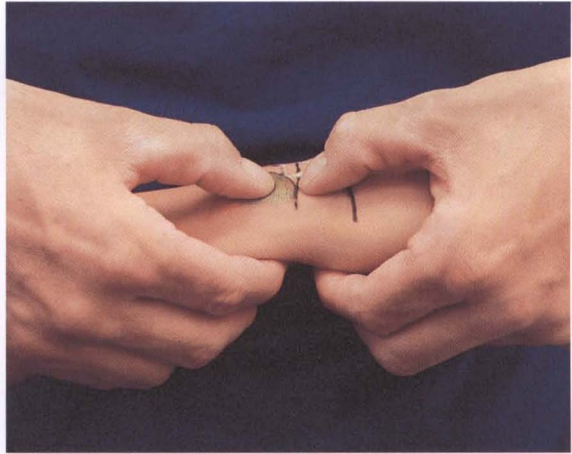


Fig. 4.54 Differentiating between the head of the ulna and triquetrum.

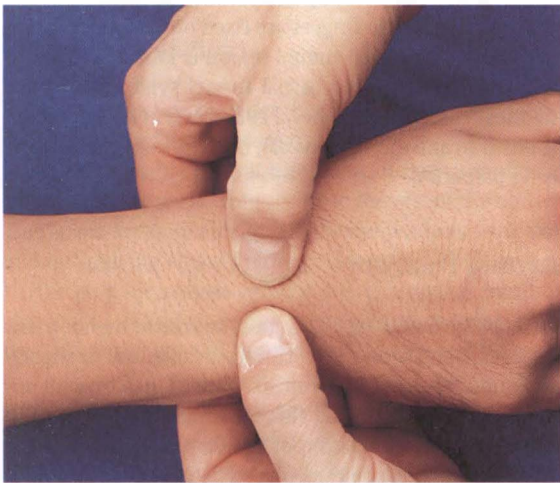


Fig. 4.52 Testing the mobility between the lunate and the scaphoid in vivo.

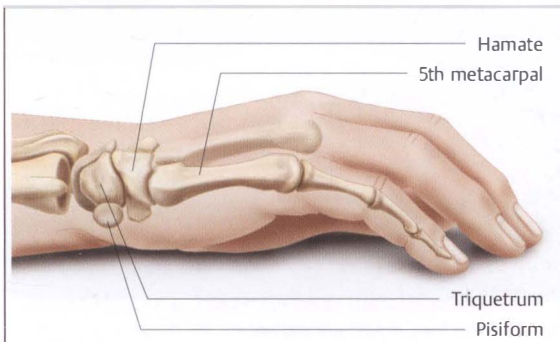


Fig. 4.53 Topography of the ulnar column.

Technique

Triquetrum

The therapist starts palpating the head of the ulna. The triquetrum is the next bony structure distal to the head of the ulna. A depression can be felt at the junction between these two structures, indicating the presence of an articular disk.

It is easy for the thumb and the index finger to hold onto the dorsal triquetrum and palmar pisiform and to move these bones, with the articular disk, opposite the head of the ulna in a posterior–anterior direction (**Fig. 4.54**).

This movement is always extensive compared with the previously described movements within the carpus. The range of motion indicates the presence of hypermobility and therefore the ability of the TFC complex (see p. 74) to stabilize the ulnar column.

Tips: In principle, it is relatively easy to locate the triquetrum because it is the most prominent carpal bone distal to the head of the ulna. There are situations, however, that require additional reassurance. The localization is confirmed by assessing the way the triquetrum moves during movement of the wrist, as was done with the scaphoid in the radial column:

- The therapist palpates the dorsal aspect of the triquetrum and passively flexes and extends the wrist. The triquetrum protrudes dorsally during flexion and disappears in a palmar direction during extension.
- When conducting radial and ulnar deviation of the wrist, it becomes evident that the normal rolling and gliding movements are accompanied by rotation. The triquetrum becomes more prominent during radial deviation and disappears again in a palmar direction during ulnar deviation. This makes the large range of motion in the ulnar direction possible and permits the base of the fifth metacarpal to move closer to the ulna.
- The movement of the triquetrum can be felt beneath the tendons of the extensor carpi ulnaris, similar to the be-

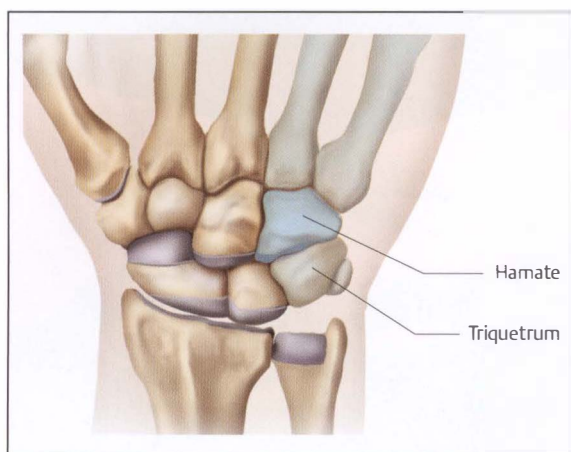


Fig. 4.55 Position of the hamate in the ulnar column.

havior of the scaphoid in the anatomical snuffbox during movements of the hand. The position of this carpal bone becomes more obvious during radial and ulnar deviation. Radial deviation of the hand pushes the triquetrum out on the ulnar side.

Hamate

It is difficult to locate the hamate. Therapists must remember how the hamate and triquetrum are arranged to locate this bone. It is quite easy to reach the triquetrum on the ulnar side. This bone becomes more slender radially. The hamate is not very conspicuous ulnarly, but becomes increasingly prominent radially toward the capitate. It mainly has a triangular form, with the wide section facing the capitate.

The hamate fills the gap between the triquetrum and the base of the fifth metacarpal and can also be felt on the ulnar edge of the hand (Fig. 4.55).

Tip: If the therapist wishes to include the hamate in the local assessment of mobility or in mobilizing techniques, this is possible by locating the hamate directly proximal to the base of the fifth metacarpal.

Tips for Assessment and Treatment

The “hypermobility stronghold” in the hand is found here, in the ulnar column. Physical therapists often have to support themselves on the ulnar side of the heel of the hand, where they are subject to local pressure. It is therefore not surprising that ulnar instability causes aggravation of symptoms during professional training. The use of special hand bandaging is often recommended to prevent the carpus from being further distracted from the ulna and the articular disk.

General Orientation—Palmar

Summary of the Palpatory Process

The second large section in palpation of the hand is the precise localization of palmar structures. The transitional region between the distal forearm and the wrist will be covered in the following palpations.

The distal forearm usually presents itself as a surface covered by a large number of tendons, blood vessels, and neural structures. This raises the question of where the actual distal bony border of the forearm is and which soft-tissue structures can be differentiated from one another using palpation.

The region commonly known as the “heel of the hand” is prominent further distally. The balls of the thumb and small finger (thenar and hypothenar eminences) join together at this point. Many short, intrinsic muscles acting on the first and fifth fingers are fixed on the bones (originate) here. The carpal tunnel region is found here and is well known due to the carpal tunnel syndrome, one of the most common peripheral compression neuropathies. Its position and dimensions can be determined accurately using palpation.

Starting Position

For all of the following palpations, it is recommended that the forearm rests on a level surface in a neutral or slightly supinated position. Therapists should position themselves next to the hand. This SP should not be used in some situations (palpation of the carpal bones). In these cases, the hand is positioned vertically (Fig. 4.56).

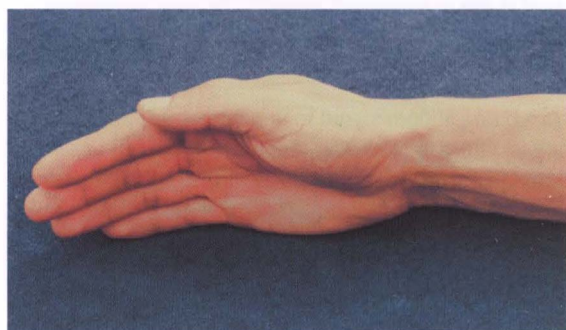

Fig. 4.56 SP for palmar orientation.

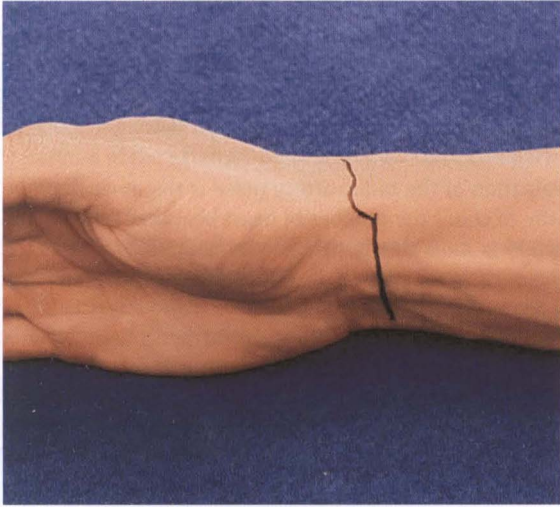


Fig. 4.57 Radiocarpal joint line—palmar view.

Edge of the Radius

Therapists require considerable skill and experience to feel the distal edge of the forearm. The border of the radius is easily accessible only at one point. A large number of thick tendons prevent free access to the rest of the border. Therapists are only able to bypass the tendons with skill and by applying slightly more pressure.

The palpation starts again in the anatomical snuffbox (see p. 80). Using the same technique perpendicular to the radius, the edge of the radius is sought and followed in a palmar direction over the tendons. It is easy to access the radius immediately palmar to the tendons in the first compartment. The shape of its edge can also be well demonstrated at this point. The flexor tendons interfere greatly with palpation further toward the middle of the forearm and the ulna.

Tip: If the therapist wishes to palpate the edge of the radius farther, the hand must be flexed significantly and, most importantly, move into passive flexion. The therapist then positions the palpating finger vertically, palpates between the tendons, and attempts to hook around the edge of the radius. The line of the radiocarpal joint reveals itself if the palpation is successful. Like on the dorsal aspect, the joint line runs at a slight angle so that it is more proximal on the ulnar side and more distal on the radial side (see Fig. 4.57).

It also becomes evident that in comparison to the dorsal line, the palmar line is displaced slightly proximally, demonstrating that the radius is a little longer on its dorsal than its palmar side. This is important for the gliding techniques used in manual therapy, regardless of whether the entire carpus or individual carpal bones move on the radius.

Local Palpation of the Palmar Soft Tissues

Overview of the Structures to be Palpated

- Flexor carpi radialis.
- Tubercle of scaphoid.
- Radial artery.
- Flexor pollicis longus.
- Palmaris longus.
- Flexor digitorum superficialis.
- Flexor carpi ulnaris.
- Pisiform.
- Ulnar artery and nerve.

Summary of the Palpatory Process

The patient is instructed to tighten the fist with the wrist flexed. The therapist then examines the tendons in the wrist area. Frequently, three tendons can already be observed in the middle of the wrist.

These tendons and other soft-tissue structures crossing over the wrist will be differentiated from one another and identified. Once again, the palpation begins radially and ends on the ulnar side.

Netter (1994) labeled the structures in the radial section as the “**radial trio**” (Fig. 4.58).

These are listed from radial to ulnar:

- Radial artery.
- Flexor carpi radialis tendon.
- Flexor pollicis longus tendon.

Netter (1994) labeled the ulnar area on the palmar side of the forearm as the “**ulnar trio**” (Fig. 4.59):

- Flexor carpi ulnaris tendon.
- Ulnar nerve.
- Ulnar artery.

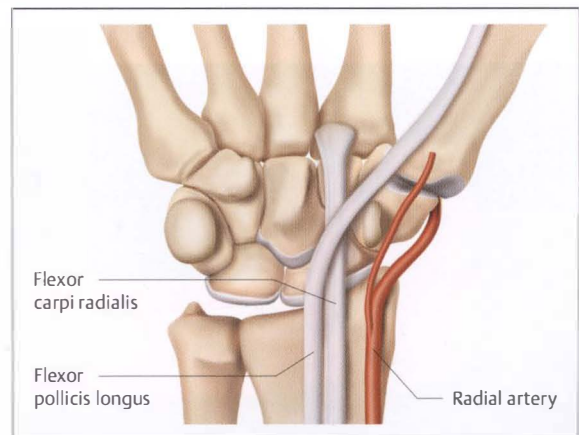


Fig. 4.58 “Radial trio” according to Netter.

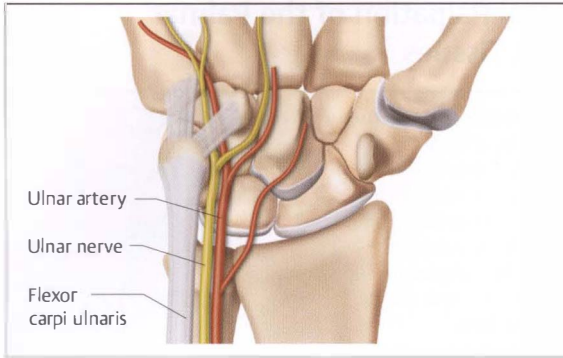


Fig. 4.59 “Ulnar trio” according to Netter.

Starting Position

The previously described SP is recommended for this palpation.

Flexor Carpi Radialis and Tubercle of Scaphoid

The patient makes a fist, actively flexes the wrist, and then holds this position with an isometric contraction.

The palpation is conducted from radial to ulnar and locates the thick tendon of the flexor carpi radialis first. This is clearly the most radially positioned tendon. The tendon protrudes even further when wrist flexion is combined with radial deviation (Fig. 4.60).

When the therapist follows the tendon more distally, the tendon guides the palpating fingers onto an important bony reference point: the tubercle of scaphoid. The tendon is not found on this tubercle, but rather passes ulnar to the tubercle, where it subsequently travels underneath the transverse carpal ligament via a compartment sepa-

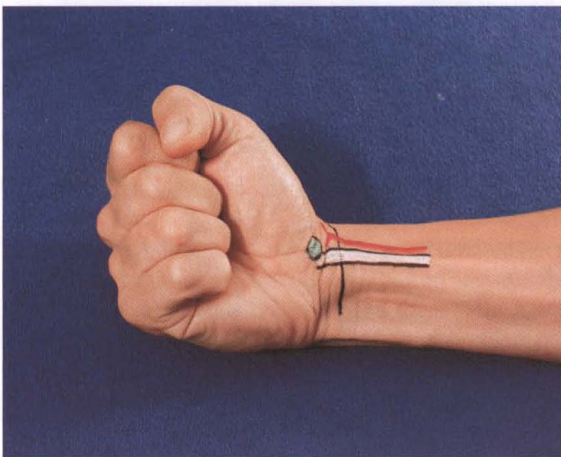


Fig. 4.60 Flexor carpi radialis tendon and tubercle of the scaphoid.

rate to the carpal tunnel, and inserts into the base of the second metacarpal.

Radial Artery

Palpation of the radial artery pulse is the most common way to count the number of heart beats per minute. The artery is most clearly palpable immediately radial to the flexor carpi radialis on the flat plateau of the radius (Fig. 4.61).

Therapists are familiar with its further course, which is only partially palpable, from their knowledge of topographical anatomy. The radial artery bends more dorsally at the wrist, just before the tubercle of scaphoid, then disappears between the tendons of the first compartment and the scaphoid where it enters the anatomical snuffbox. It then crosses underneath the tendon of the extensor pollicis longus and travels further dorsally between the second and third metacarpals.

Flexor Pollicis Longus

The final radial triad structure is the tendon of the flexor pollicis longus. Similar to the radial artery, this tendon is also found directly adjacent to the tendon of the flexor carpi radialis, but is located slightly deeper in the tissue beneath the artery. Contraction of the muscle belly can be clearly felt a little more proximally. This tendon is one of the 10 structures that pass through the carpal tunnel.

Tip: If it is still difficult to differentiate the tendons from one another, the wrist should be actively extended to reciprocally inhibit and relax the carpal flexor.

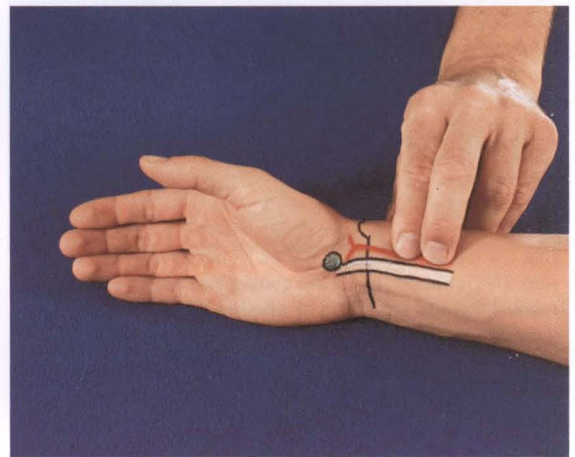


Fig. 4.61 Palpation of the radial artery.

Summary of all Radial Structures

The palpable structures on the radial side of the hand have the following order from dorsal to palmar:

1. Tendon of the extensor pollicis longus (third compartment).
2. Lister tubercle.
3. Tendons of the extensor carpi radialis longus and brevis (second compartment).
4. Superficial branch of the radial nerve, cephalic vein.
5. Tendons of the extensor pollicis brevis and the abductor pollicis longus (first compartment).
6. Radial artery.
7. Tendon of the flexor pollicis longus.
8. Tendon of the flexor carpi radialis.

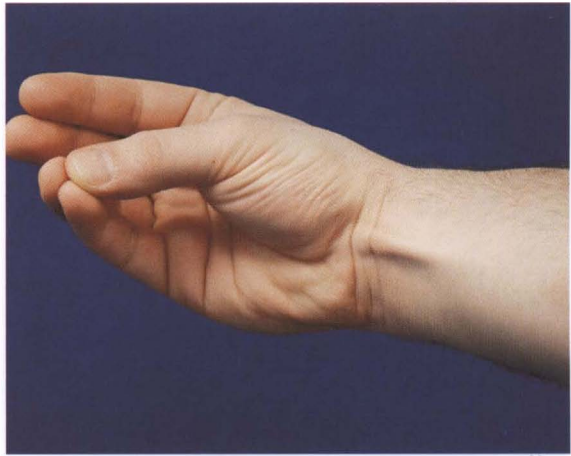


Fig. 4.62 Demonstrating the palmaris longus tendon.

Palmaris Longus

Three centrally located tendons are observed initially when the patient makes a fist. The middle tendon belongs to the palmaris longus. This tendon, similar to the tendon of the flexor carpi radialis, does not pass through the carpal tunnel.

Tip: The palmaris longus is subject to anatomical variation, being absent in approximately 16% of the population. When present, it can be clearly observed by opposing the thumb and the small finger (Fig. 4.62). The tendon illustrates the pathway of the median nerve. The nerve is found directly beneath the tendon and passes through the carpal tunnel.

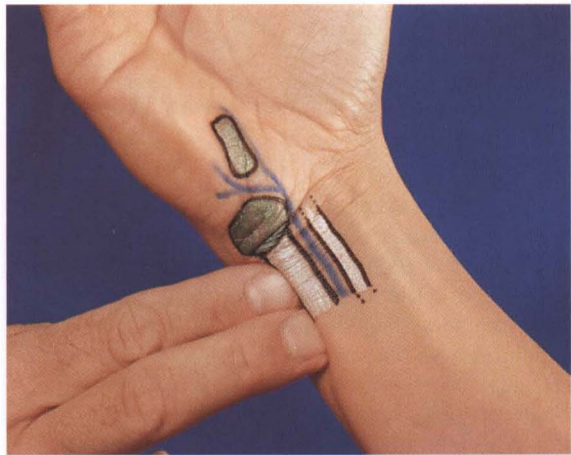


Fig. 4.63 Palpation of the flexor carpi ulnaris.

Flexor Digitorum Superficialis

The patient is instructed to make a tight fist again. The therapist palpates further ulnarly and identifies another tendon that is especially easy to palpate when the patient additionally increases the pressure from the fourth and fifth fingers onto the palm of the hand. This is the tendon of the flexor digitorum superficialis.

Flexor Carpi Ulnaris and Pisiform

Another tendon can be palpated when the hand makes a fist again and either flexes and ulnar deviates the wrist against a strong resistance, or ulnar deviates the hand extensively (Fig. 4.63). The flexor carpi ulnaris tendon lies very ulnarly and guides the palpating finger distally onto the pisiform.

The tendon is only very rarely visible as the fascia of the forearm is very soft at this point. Therefore, a large amount of muscle activity and palpation immediately proximal to the pisiform is required to identify the tendon.

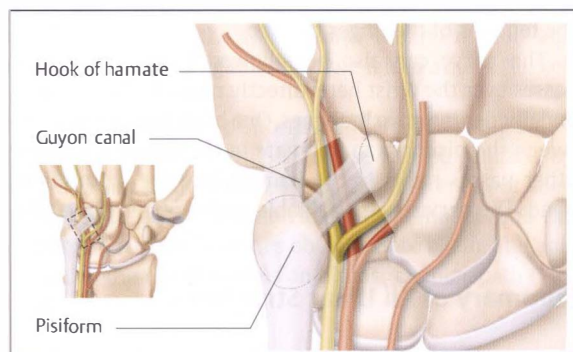


Fig. 4.64 Topography of the "ulnar trio" and the Guyon canal.

Ulnar Artery and Nerve

The pulse of the ulnar artery can be felt between the tendons of the flexor digitorum superficialis and flexor carpi ulnaris (Fig. 4.64).

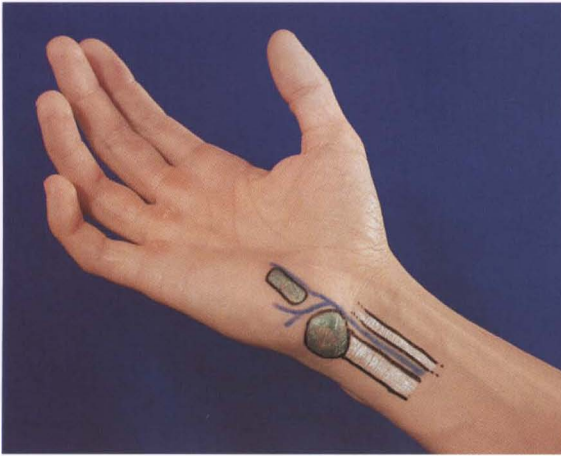


Fig. 4.65 Overview of the radial structures on the palmar aspect.

Tip: It is not as easy to feel this artery as the artery on the radial side. This palpation therefore requires that the palmar tendons and muscles be fully relaxed. The therapist must be patient when palpating flatly with one or two finger pads.

The ulnar nerve is found immediately adjacent to the artery. The fingers are again positioned vertically between the tendons of the flexor carpi ulnaris and flexor digitorum superficialis for this palpation (Fig. 4.65). In some cases, the nerve may be mistaken for a tendon as both structures have the same thickness. When the therapist palpates superficially and perpendicularly, the nerve will roll back and forth underneath the palpating finger and its position and consistency do not change during active finger flexion.

The artery and nerve can be followed for at least three to four finger-widths proximally until they are covered by the tendons of the finger flexors.

The nerve can also be followed further distally. It passes over the wrist here, directly radial to the pisiform, and divides into two branches. One branch disappears between the pisiform and hamate in the Guyon canal; the other passes radial to the hamate into the palm of the hand. The nerve is also palpable at this point (Fig. 4.66).

Summary of All Ulnar Structures

The palpable structures on the ulnar side of the hand have the following order from dorsal to palmar:

1. Extensor digiti minimi tendon (fifth compartment).
2. Head of the ulna.
3. Extensor carpi ulnaris tendon (sixth compartment).
4. Flexor carpi ulnaris tendon.
5. Ulnar nerve and artery.
6. Flexor digitorum superficialis tendon.

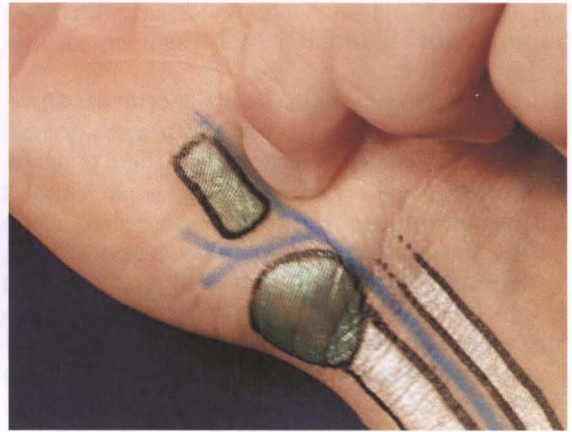


Fig. 4.66 Palpation of the ulnar nerve directly adjacent to the hook of hamate.

Tips for Assessment and Treatment

The Guyon canal is formed by both of its neighboring osseous structures, pisiform and the hook of hamate, as well as the superficially situated pisohamate ligament. This ligament is one of the two continuations of the tendon of the flexor carpi ulnaris that originates on the pisiform bone.

Compression neuropathies of the ulnar nerve in the canal are known as the handlebar palsy. These pressure lesions develop when weight is placed on the ulnar aspect of the hand, the wrist is positioned in extension, and the hand radially deviated.

Local Palpation of the Palmar Aspect of the Carpal Bones

Overview of the Structures to be Palpated

- Pisiform.
- Hook of hamate.
- Scaphoid.
- Trapezium.
- Transverse carpal ligament and the carpal tunnel.
- Median nerve.

Summary of the Palpatory Process

The palpation of the accessible palmar carpal bones aims to identify the position of the carpal tunnel by locating radial and ulnar bony landmarks. Afterward, the bony landmarks of the carpal tunnel are connected and drawn onto the surface of the skin to highlight the position of the tunnel (Fig. 4.67).

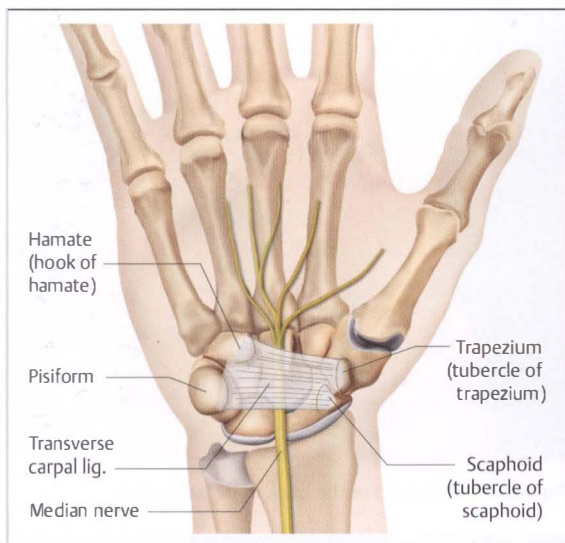


Fig. 4.67 Structures of the carpal tunnel.

Starting Position

The SP for the palpation of palmar soft tissue is also the standard SP here. Movement is used and the hand is placed in a vertical position to assess the localization of some structures.

Pisiform

The therapist starts on the pisiform bone. It has already been discovered and palpated at the end of the flexor carpi ulnaris tendon (see p. 93). It transfers the pull of the tendon onto the hook of hamate and the base of the fifth metacarpal. In this respect, it can be said that the pisiform is the only carpal bone with the tendon of an extrinsic muscle attached to it.

Furthermore, the pisiform acts like a sesamoid bone, positioned in the middle of the ulnar wrist flexor tendon. The absence of a synovial sheath underlines this presumption. The tendon does not rub against the skeleton of the hand or forearm regardless of the hand position.

Moreover, the pisiform is positioned in the middle of the hypothenar muscles and provides a bony fixed point, for example, for the abductor of the small finger. This becomes obvious when the patient is instructed to relax the hand and then rhythmically abduct and adduct the small finger extensively. Contraction of the abductor pulls the pisiform in a distal direction and, from this direction, tenses the flexor carpi ulnaris tendon.

It is almost impossible to overlook the pisiform at the base of the hypothenar eminence. The pisiform can be held by the thumb and index finger and moved sideways on the more dorsally positioned triquetrum when the hand is relaxed (Figs. 4.68 and 4.69). On the contrary,

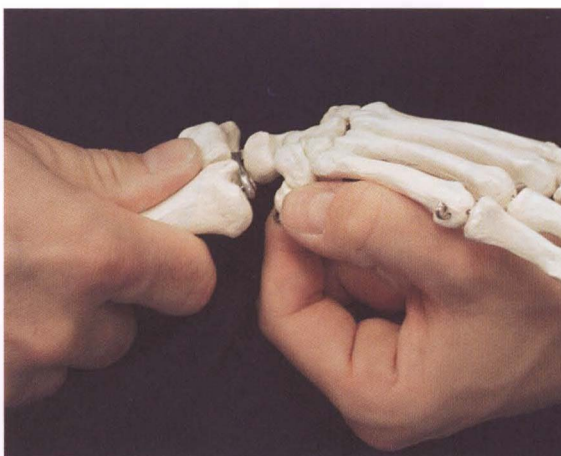

Fig. 4.68 Localization of the pisiform on a skeletal model.

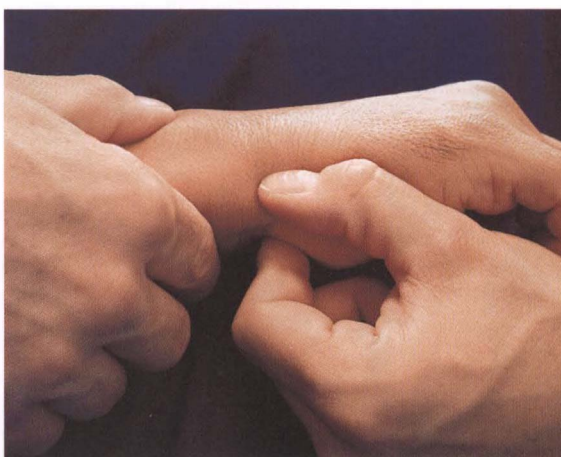


Fig. 4.69 Localization of the pisiform in vivo.

large-range wrist extension causes the pisiform to be clamped between the flexor carpi ulnaris tendon and the pisometacarpal ligament, where it is in a quasi "locked position."

If the edges of the pisiform are identified using a perpendicular palpation, the therapist will be amazed by the large size of the carpal bone. The difference between the construction of common anatomical models and the palpated structure becomes obvious once again. The palpation of the edges follows an almost circular path (Fig. 4.70).

Tip: The pisiform can be accessed from all sides. Its edge can even be palpated in the space between the pisiform and the hook of hamate (Guyon canal). Therefore, the palpating finger should be positioned almost vertically and the wrist relaxed in slight flexion. The ulnar nerve is being palpated if local pressure in the canal causes formication in the patient's hypothenar eminence.

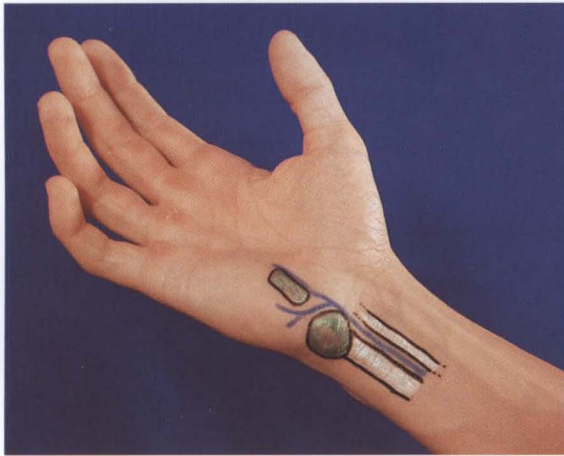


Fig. 4.70 Position of the pisiform and hook of hamate.

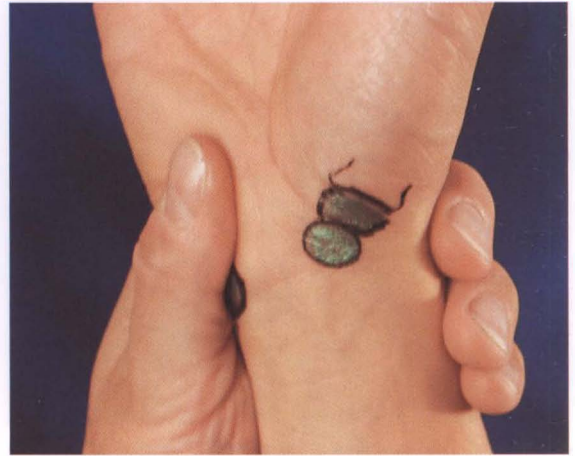

Fig. 4.72 Localization of the hook of hamate—phase 2.

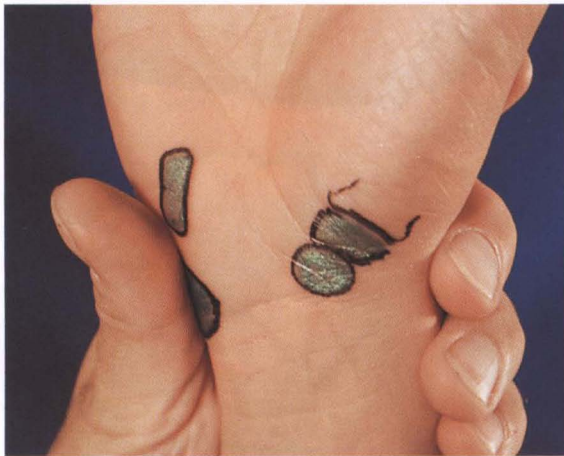

Fig. 4.71 Localization of the hook of hamate—phase 1.

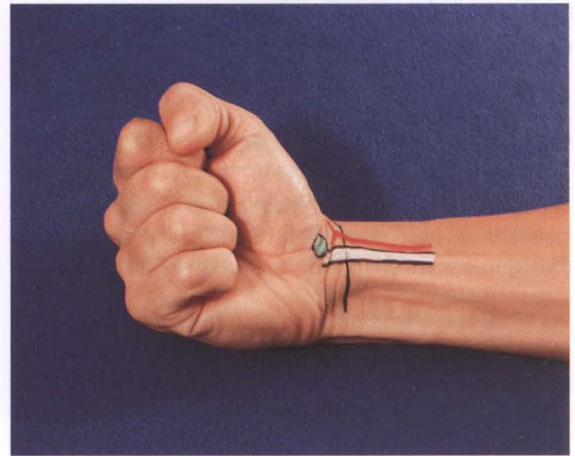


Fig. 4.73 The flexor carpi radialis tendon leads onto the tubercle of the scaphoid.

Hook of Hamate

Another carpal bone accessible on the ulnar side of the palm is the hamate. It is located at its prominent process, the hook. A supporting measure is used to quickly find this structure and has been described by Hoppenfeld (1992).

The therapist places the middle section of the thumb's interphalangeal joint fold over the pisiform. The tip of the thumb points toward the middle of the palm. The hook of hamate is found at the tip of the thumb's distal phalanx (Fig. 4.71).

If the pad of the thumb applies light pressure, the bony resistance of the hook of hamate will be felt immediately (Fig. 4.72).

The therapist can attempt to locate the boundaries of the hook of hamate by applying the same technique used in the palpation of the edges of the pisiform.

The pisiform and the hook of hamate form the ulnar osseous boundary of the carpal tunnel.

The ulnar nerve divides into two branches at the hook of hamate. The further pathway of one of these branches can be palpated immediately radial to this bony landmark.

The other branch passes through the space between the pisiform and the hook of hamate, the Guyon canal, and can also be palpated here using a vertical and transverse palpatory technique.

Scaphoid

The scaphoid and trapezium form the radial boundary of the carpal tunnel. Both bones have tubercles that can be very easily identified using palpation of the palmar aspect of the hand. The tubercle of the scaphoid has already been noticed during palpation of the palmar soft tissues. The flexor carpi radialis is the guiding structure here (Fig. 4.73).

To accurately locate the tubercle, the tendon of the flexor carpi radialis is made more distinct by making a

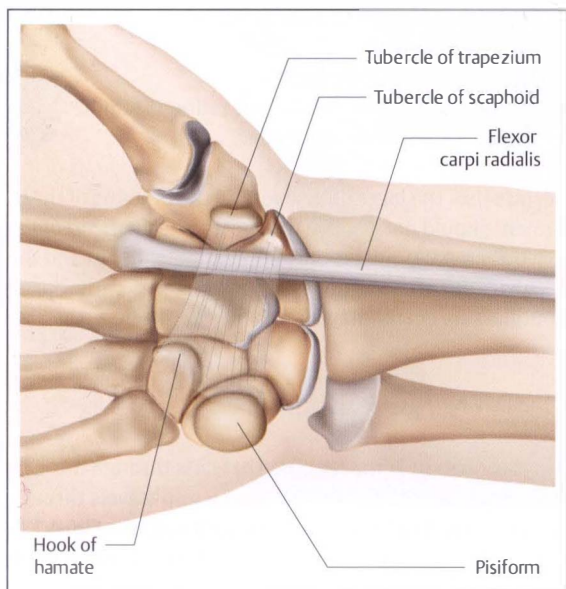


Fig. 4.74 Osseous boundaries of the carpal tunnel and the flexor carpi radialis tendon.

tight fist with the wrist in flexion and emphasizing the tension on the radial side of the hand.

The prominent tendon guides the transverse palpation onto the distinctive bony landmark of the tubercle of the scaphoid.

The tubercle is identified as a rounded bony landmark, which becomes more prominent during wrist extension.

The therapist should keep in mind that the tendon is not present on the tubercle, but rather guides the palpation to this point.

The flexor carpi radialis passes through its own canal adjacent to the carpal tunnel and onto the base of the second metacarpal (**Fig. 4.74**).

Trapezium

The tubercle of the trapezium is located immediately adjacent to the scaphoid, with both structures separated by only a small groove. The finger should be positioned almost vertically to palpate the groove. This groove feels similar to the “anterior V” in the AC joint and marks the joint space between the scaphoid and trapezium. The tubercle is again identified as a rounded, hard structure.

The pattern of movement in the two neighboring carpal bones can be used to confirm the localization. It is based on the local arthrokinematic convex-concave rule as well as the associated rotation that each carpal bone conducts during movements of the wrist.

The pad of the middle finger comes from a radial direction and is positioned over the scaphoid. The pad of the index finger is positioned directly next to it on the trapezium.

Tip 1: The wrist is first actively or passively extended and flexed. The positioned finger pads follow the movement of the hand. The two carpal bones move against each other. During wrist extension, the scaphoid becomes more prominent and the trapezium less distinct. Flexion causes the trapezium to protrude, and the scaphoid disappears dorsally. The groove between both of these bones becomes more distinct.

Tip 2: The finger pads remain on the tubercles and the hand is now moved into radial or ulnar deviation. The scaphoid becomes clearly more superficial during radial deviation and virtually pushes the middle finger away from the hand (**Fig. 4.75**). The opposite pattern of movement is observed during ulnar deviation of the hand (**Fig. 4.76**).

The first carpometacarpal joint space is found next along a line formed by these bones. It is comparatively easy to identify the base of the first metacarpal by adducting the thumb. The base protrudes in a palmar direction during this movement (see p. 86).

Transverse Carpal Ligament and the Carpal Tunnel

Now that the ulnar and radial walls of the carpal arch have been located, the therapist can clarify the position and dimensions of the transverse carpal ligament, the ligament that closes the carpal arch to form a tunnel. Direct palpation of this ligament is not exactly possible. An area of very firm and elastic consistency can be differentiated from the

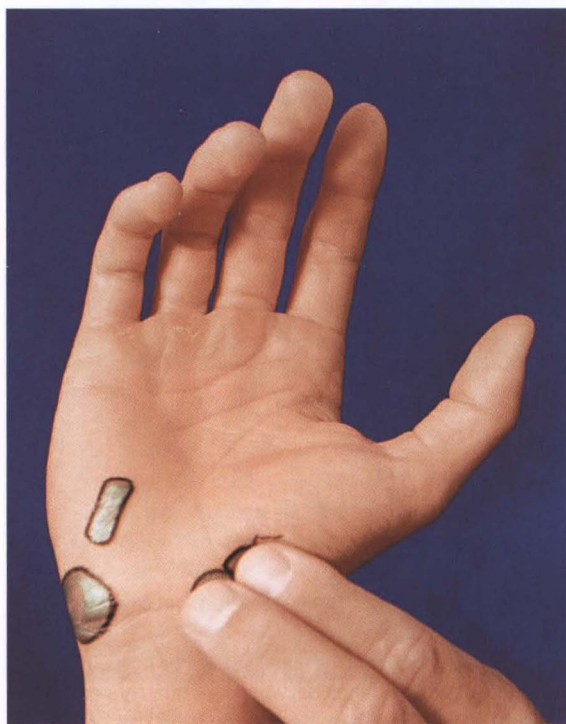

Fig. 4.75 Localization of the scaphoid using radial deviation of the hand.

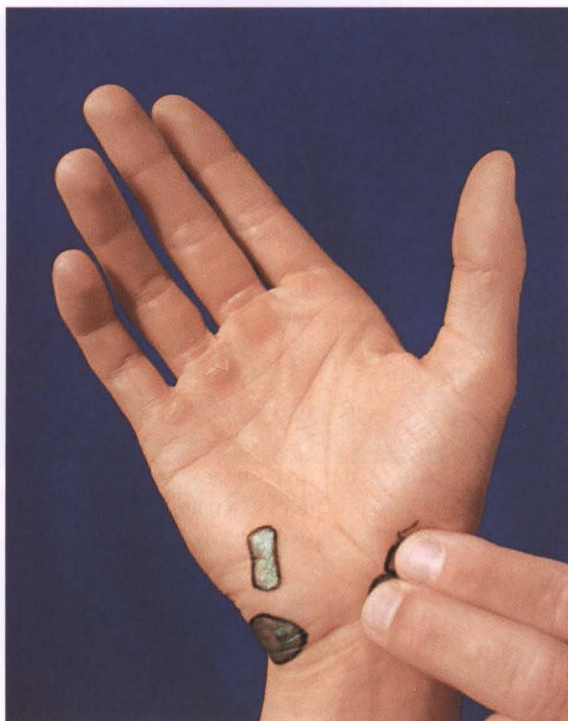

Fig. 4.76 Localization of the trapezium using ulnar deviation of the hand.

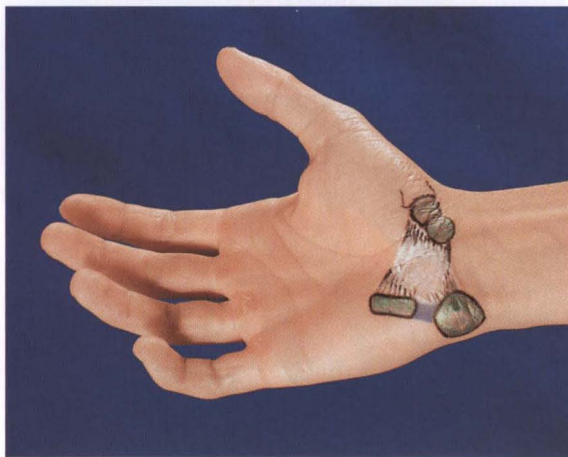


Fig. 4.77 Palmar elevations of the carpal bones.

hard carpal bones and the soft structures in the palm, but a clear palpatory differentiation of structures is nevertheless not entirely possible. The therapist therefore concludes that the ligament must be found between the identified carpal bones.

The dimensions of the ligament become clear when the therapist draws lines between the ulnarly positioned pisiform and hook of hamate and the tubercles of the scaphoid and trapezium on the radial side (**Fig. 4.77**).

Two facts in particular stand out when examining the drawing on the skin:

- The ligament is quite large.
- The ligament is not square, but rather resembles a trapezoid with a wide ulnar edge.

Despite this, the large dimensions of the drawing of the ligament should not deceive therapists. The diameter of the osseous carpal tunnel is only approximately 1 cm and the entire length of the tunnel is approximately 5 cm. It has an hourglass form and may already be narrow at birth.

Median Nerve, Position

In addition to the nine tendons that pass through this narrow carpal tunnel, the median nerve also travels through the tunnel with a very superficial pathway (see **Fig. 4.13**), which cannot be determined using palpation. Anatomical aids are required again.

The palmaris longus (see **Fig. 4.62**) marks its position in the distal forearm. The nerve lies directly beneath the tendon and also travels with the tendon through the carpal tunnel, where it later mainly supplies the thenar eminence (**Figs. 4.78** and **4.79**).

The nerve position in the carpal tunnel is not constant. It slides up to 2 cm proximally or distally during movements of the fingers, hand, and even the elbow and shoulder.

Tips for Assessment and Treatment

Identification of the carpal bones on the palmar aspect of the wrist is used for both assessment and treatment, and is divided into two areas:

- **Exact localization of the carpal bones.** This is especially useful when individual bones have to be accurately differentiated from one another for local tests and treatment at the wrist joint. Using the example of the localization of the scaphoid dorsally and palmar, it becomes apparent that the palmar and dorsally positioned fingers are not found directly opposite one another.

If the scaphoid can be reached dorsally as the continuation of the Lister tubercle, the palmar-positioned tubercle of the scaphoid is not found at the same level, but is rather displaced slightly more distally. Therapists cannot avoid precisely locating the bony landmarks if tests are not diagnostically conclusive.

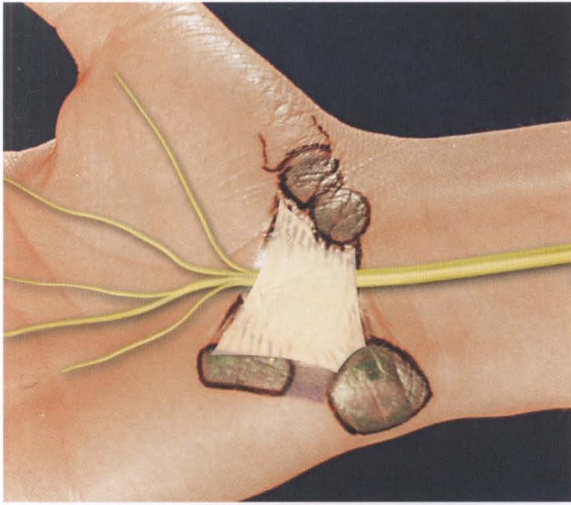


Fig. 4.78 Projection of the transverse carpal ligament and the median nerve.

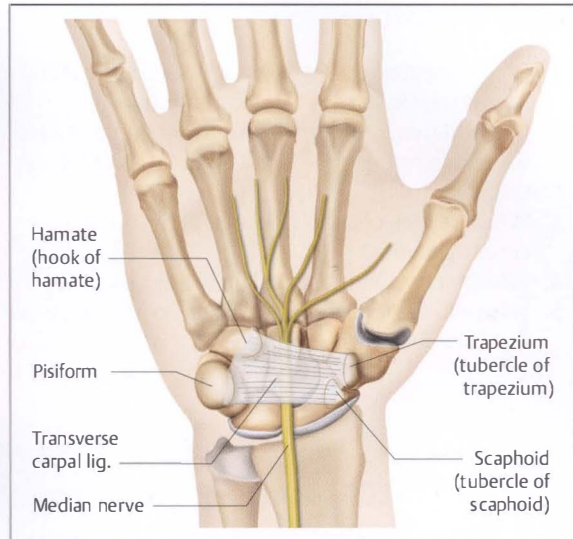


Fig. 4.79 Carpal tunnel structures and the median nerve.

- **Provocation of compression neuropathies.** The presence of nerve compression syndromes in the hand can be proven by using local pressure on the narrowing passage to provoke symptoms. This applies to the carpal tunnel syndrome and the compression of the ulnar nerve in the Guyon canal. Knowledge of local *in vivo* anatomy is useful in the carpal tunnel area when Tinel and Tetro tests are being used:

In the Tinel test, percussion is applied to the carpal tunnel to provoke the patient's symptoms (**Fig. 4.80**).

The Tetro test uses constant local compression of the carpal tunnel combined with wrist flexion (**Fig. 4.81**).

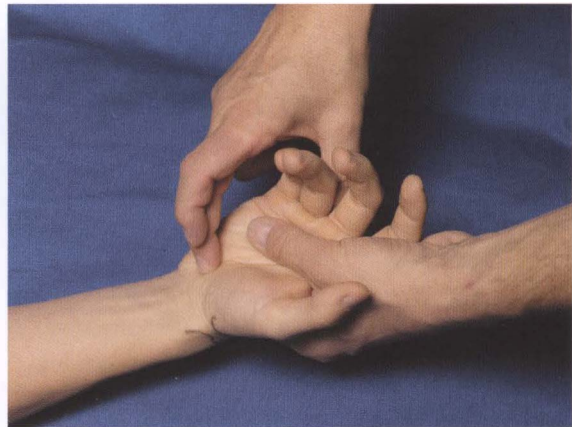

Fig. 4.80 Tinel test

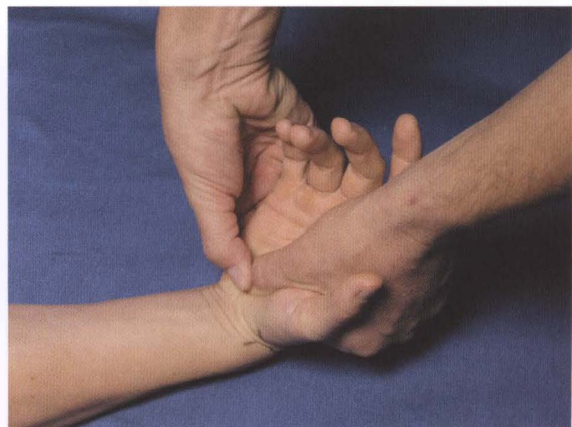

Fig. 4.81 Tetro test

Study Questions

1. Which structures intersect the extensor pollicis longus tendon in the anatomical snuffbox?
2. On which bony edge do therapists orient themselves when determining the distal boundaries of the carpus?
3. Which tendon changes its course at the dorsal tubercle of the radius?
4. Which nerve can be located on the distal radius?
5. Where is the tendon of the flexor pollicis longus in the distal forearm?
6. Which tendon guides the palpation onto the DRUJ?
7. How do therapists locate the lunate?
8. How can therapists access the ulnar nerve?
9. Which carpal bones form the radial borders of the carpal tunnel?
10. The scaphoid can be palpated on three of its sides. Describe how its dorsal, radial, and palmar aspects are located.
11. Attempt to plot the boundaries of the anatomical snuffbox by drawing the first and second compartment tendons on a hand!



5 Hip and Groin Region

- Significance and Function of the Hip and Groin Region ... 103**
- Common Applications for Treatment in this Region ... 103**
- Required Basic Anatomical and Biomechanical Knowledge ... 103**
- Local Palpation—Posterior ... 106**
- Local Palpation—Anterior ... 109**
- Study Questions ... 117**

THIS PAGE INTENTIONALLY
LEFT BLANK

5 Hip and Groin Region

Significance and Function of the Hip and Groin Region

The lumbopelvic–hip (LPH) region is a functional unit composed of the hip joints, pelvic connections, and the lumbar spine. As this book addresses the precise palpation of the joints of the limbs, the lateral and anterior hip complex will be selected out of this functional unit and discussed in detail. The posterior hip and pelvic region is discussed in Chapter 9.

The LPH region is subject to the principles of bipedal locomotion, as is the case for the entire construction of the lower limb. Support and locomotion are the most important aspects of these principles.

With this in mind, the first role of the LPH region is to form a connection between the lower limbs and the trunk. The sacroiliac (SI) joints are very large and rigid in comparison to the more delicate sternoclavicular joint that forms the junction between the upper limb and the trunk. The very steep articular surfaces and the tilted position of the sacrum make the construction and ligamentous stability in the SI joint complicated in many respects.

The small movements observed in the SI joints and the pubic symphysis are especially necessary to cushion the transmission of loading, that is, for shock absorption. The principle of shock absorption is not only seen in the pelvis, but is also demonstrated in all sections of the lower limbs.

The complex connection between the lower limbs and the vertebral column also results in movement of the hip joint being transmitted directly onto the vertebral column. Movements of the pelvis and more superior movements acting on the pelvis also affect the other components of the LPH region. This becomes clear when looking at the example of hip extension. The normal range of hip extension is 10–15°. This movement is transmitted very quickly onto the articulations of the pelvis (SI joints and symphysis) and from there immediately onto the inferior segments of the lumbar spine.

Common Applications for Treatment in this Region

The symptom patterns of the hip that therapists have to deal with are multifaceted and comprehensive.

It is not easy to assess the LPH region, especially when pain is present in the buttocks or groin. The source of pain may be found in the lumbar spine, the articulations of the pelvis, and the hip-joint region. This is made more complicated by pain originating from structures near the trunk that may refer pain into the legs.

When assessing the LPH region, it is therefore suggested that the recommendations of Cyriax be followed and all parts of the musculoskeletal system that are possible sources of symptoms be included in the assessment.

Common Pathological Conditions in the Hip

Lateral hip symptoms: Soft-tissue conditions superficial to the greater trochanter (e.g., trochanteric bursitis, snapping hip) and “referred pain” from the hip joint.

Local posterior hip symptoms: Hamstring insertion tendinopathy.

Groin pain: Insertion tendinopathy (e.g., of the adductors), irritation of the pubic symphysis, referred pain originating in the lumbar spine or the SI joint, and naturally problems in the hip joint (arthritis, lesions of the labrum and pubic symphysis, etc.).

This represents only a selection of all problems in the hip and the groin that are frequently observed in the physical therapy practice. Posterior symptoms are mainly discussed in Chapter 9.

Most groin symptoms can be differentiated from one another using special tests during assessment. Precise palpation is nevertheless required when tests do not help the therapist and when the exact position of the lesion needs to be identified and confirmed.

Required Basic Anatomical and Biomechanical Knowledge

Students require significant background information to understand the instructions for local palpation:

- The bony construction of the pelvis, especially the accessible elevated areas of bone.
- The geometry of the proximal femur, especially the femoral neck anteversion (FNA) angle.
- The names and positions of the muscles that cross over the hip joint with special emphasis on the extensors and adductors.

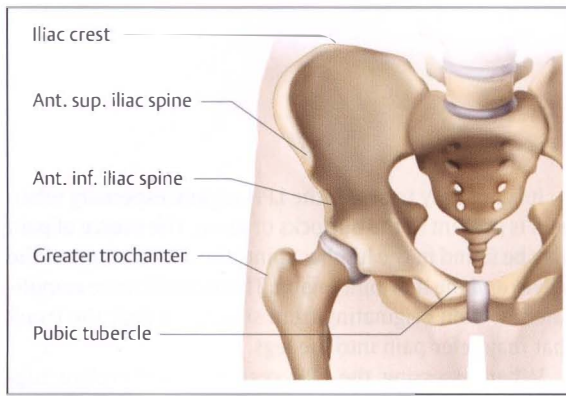


Fig. 5.1 Pelvic structures—anterior view.

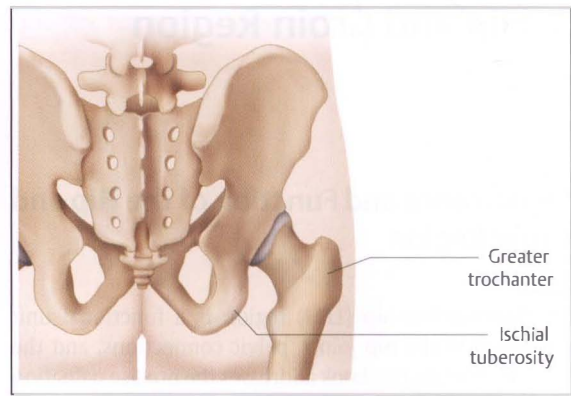


Fig. 5.2 Osseous structures—posterior view.

Bone Anatomy

The remarkable aspect of the bony pelvis is the three-dimensional construction of the large bones that form a ring. It is very difficult to illustrate this in the two-dimensional illustrations that are readily available to therapists. Therefore, it is important for therapists to develop the ability to visualize the structure of the ring from different perspectives.

The bony landmarks of the pelvis, whose precise localization will be discussed in this section, mainly lie on the anterior aspect.

These are consolidated into the anteriorly accessible sections of the ilium and pubis (Fig. 5.1).

The local anatomy of the deep structures in the posterior pelvis will also be addressed in this guide on palpation of the hip region.

The ischial tuberosity is the only posterior reference point that will be sought (Fig. 5.2). All other structures will be discussed in Chapter 9.

The greater trochanter is especially easy to access on the femur. The remaining structures are either hidden by thick layers of soft tissue or can only be identified using guiding structures.

The size of the greater trochanter in living subjects is astonishing. For example, the posterior area between the trochanter and the lateral border of the ischial tuberosity amounts to only approximately two to three finger-widths.

Once again, illustrations and common anatomy models cause confusion as the trochanter is too small in these examples and the spatial relationship to the pelvis too large.

Femoral Neck Anteversion Angle

The FNA angle helps determine the amount of medial rotation at the hip joint. The larger the angle is, the greater the ability of the hip joint to medially rotate—providing the soft tissues (capsule and muscles) have normal elasti-

city. Restrictions in medial rotation of the hip joint are one of the signs used for the early detection of initial changes to the capsular pattern.

The FNA angle describes the range of anteriorly directed femoral head torsion in relation to the femoral shaft. The position of the femoral shaft is usually illustrated using a transverse line that passes through the condyles of the distal femur (Fig. 5.3).

Children have a larger FNA angle and are therefore often able to medially rotate over a surprisingly large range. Skeletal growth reduces the FNA angle to an average normal value of approximately 12° (Kapandji, 2006). The reduction in the childhood FNA angle results in inter-individual and especially intra-individual differences. The FNA angles of the left and right hip joints are therefore often found to differ.

As the FNA angle helps determine the range of medial rotation, and its angle varies greatly between individuals, what does this mean when the left and right hips are found to have different ranges of medial rotation? Is it permissible, for example, to conclude that capsular tension is starting to increase due to arthritis of the hip?

These conclusions should only be made when both the right and left FNA angles have been measured. It is only when both FNA angles have been found to be the same or almost the same that a reduction in medial rotation is seen to be an indication of initial changes to the capsular pattern.

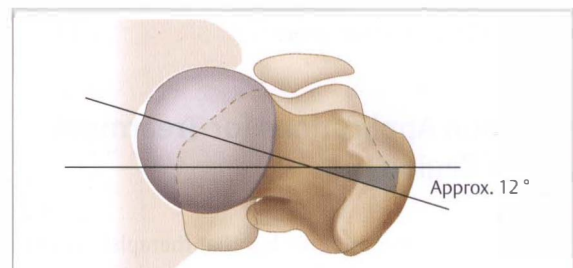


Fig. 5.3 FNA angle

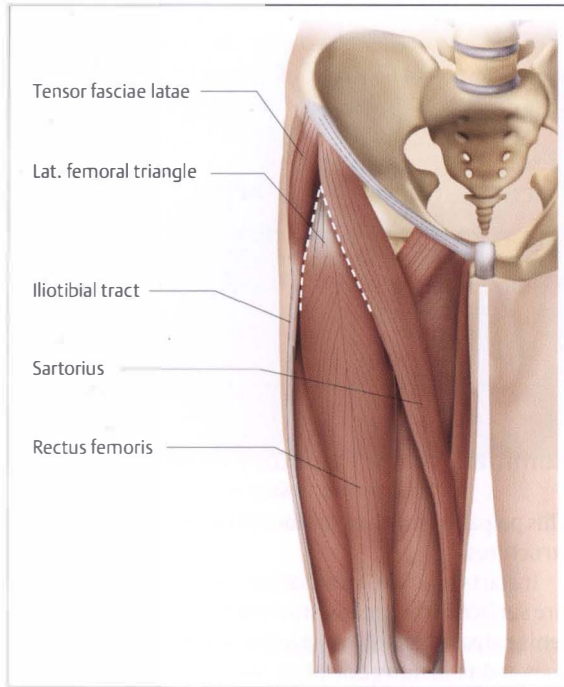


Fig. 5.4 Lateral femoral triangle.

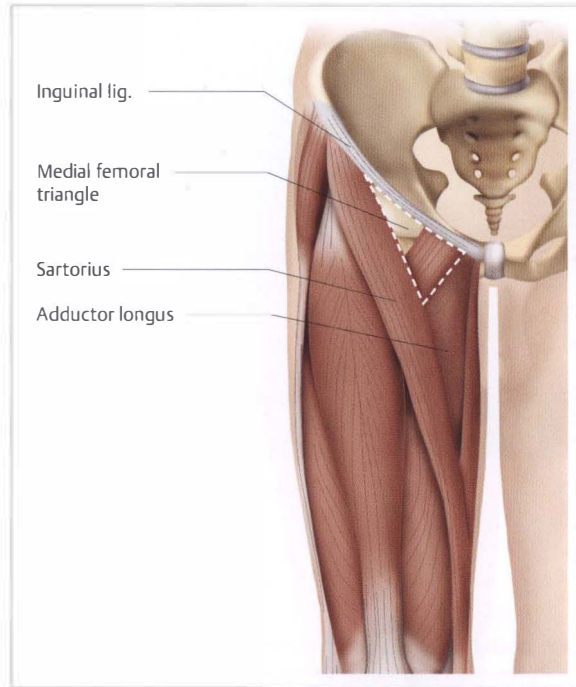


Fig. 5.5 Medial femoral triangle.

Relevant Anterior Soft Tissues

The position of the anterior muscles is usually divided into:

- The lateral femoral triangle.
- The medial femoral triangle.

This topographical classification aids orientation on the anterior aspect.

The **lateral femoral triangle** is bordered by:

- The tensor fasciae latae (medial edge of the muscle belly).
- The sartorius (lateral edge of the muscle belly).

This area is actually not a triangle, but is instead shaped like an arrowhead with its tip pointing superiorly (Fig. 5.4). The triangle does not have a third border. The two participating muscles are in contact with the anterior superior iliac spine (ASIS). This is the most important osseous orientation point on the anterior pelvis.

The anterior inferior iliac spine (AIIS) and rectus femoris are found deep in this "triangle."

The **medial femoral triangle** is a proper triangle and is formed by:

- The sartorius (medial edge of the muscle belly).
- The adductor longus (medial edge of the muscle belly).
- The ligament of the groin (inguinal ligament) (Fig. 5.5).

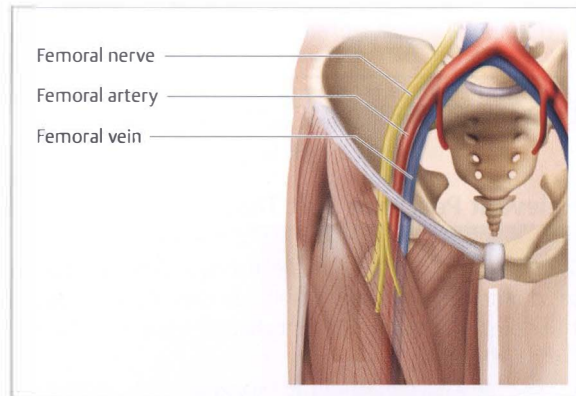


Fig. 5.6 Neurovascular bundle in the groin.

In addition to the previously mentioned ASIS, the pubic tubercle is also another important bony point for orientation.

Knowledge of this triangle aids therapists in the localization of lesions in the clinically important flexor and adductor muscle groups. Furthermore, the position of the large neurovascular bundle directly anterior to the hip joint can be identified.

The following structures (from lateral to medial) are:

- The femoral nerve.
- The femoral artery.
- The femoral vein (Fig. 5.6).

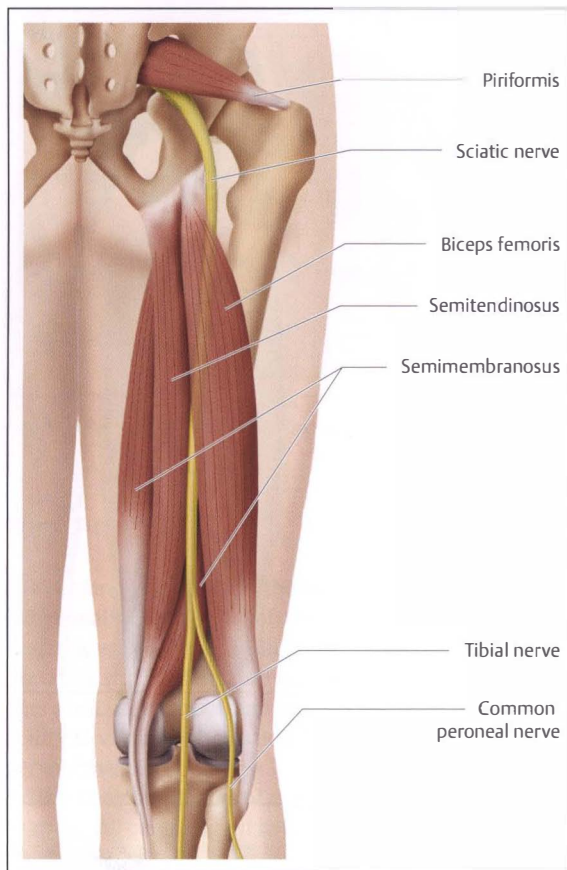


Fig. 5.7 Important posterior soft-tissue structures.

Relevant Posterior Soft Tissues

The hamstring muscles and the insertion of their common head onto the ischial tuberosity are the soft-tissue structures posterior to the hip joint that are important for palpation (Fig. 5.7).

The muscle bellies of the biceps femoris, semimembranosus, and semitendinosus converge together proximally and form a common tendon of origin.

Contrary to common belief, the muscle bellies are not aligned along the middle of the proximal femur, but are rather angled in a medial direction. The reason for this angled course is seen in the more medial position of the tuberosity.

Fibers from the tendon of origin sometimes even merge further into the sacrotuberous ligament (see also Chapter 9, p. 212 f) and can therefore, theoretically, directly influence the SI joint (Vleeming, 1995).

The functional importance of this muscle group is viewed far beyond its concentric–dynamic actions (extension of the hip joint, flexion of the knee joint). Proximally, the hamstrings assist other muscles to help control the pelvis in the sagittal plane and prevent the pelvis from tilting down anteriorly. Toward the knee joint, the ham-

strings develop their strongest contraction at the end of the swing phase. The muscles decelerate the anterior swing of the lower leg just before heel strike to prevent excessive loading on the passive structures in the joint.

Local Palpation—Posterior

Overview of the Structures to be Palpated

- Greater trochanter.
- Femoral neck anteversion angle (FNA).
- Ischial tuberosity.
- Hamstrings.

Summary of the Palpatory Process

This palpation involves the localization of easily accessible structures.

It starts with the localization and palpation of the entire surface of the greater trochanter. The greater trochanter is palpated to provoke pain in locally inflamed soft tissues and to identify one of the most important aspects in the geometry of the proximal femur: the FNA angle.

The therapist then concentrates on an osseous structure that is easy to find, the ischial tuberosity. This structure not only transmits the load of the pelvis in the sitting position, it also acts as a fixed point for the strong ligaments that help stabilize the SI joint (sacrotuberous ligament) as well as the strong extensor muscles (hamstrings).

Starting Position

The patient is positioned in prone lying, the arms rest next to the body and a foot roll is positioned underneath the ankles. This prone position only needs to be modified for patients suffering from hip joint or lumbar spine symptoms.

It can be advantageous to position the patient on the side with the hips flexed when palpating the hamstring tendon of origin.

Greater Trochanter

As almost the only directly accessible section of the proximal femur, the greater trochanter acts as an important orientation point in the lateral region of the hip. It is the site of insertion for several small muscles coming from the pelvis, lengthens the lever for the small gluteal muscles, and its palpation allows conclusions to be drawn regarding the geometry of the femur.

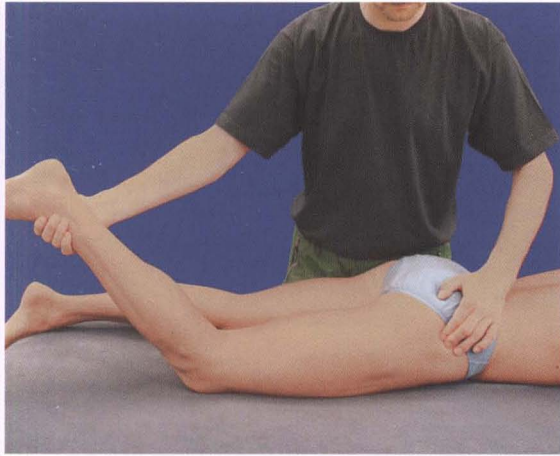


Fig. 5.8 Localization of the greater trochanter.

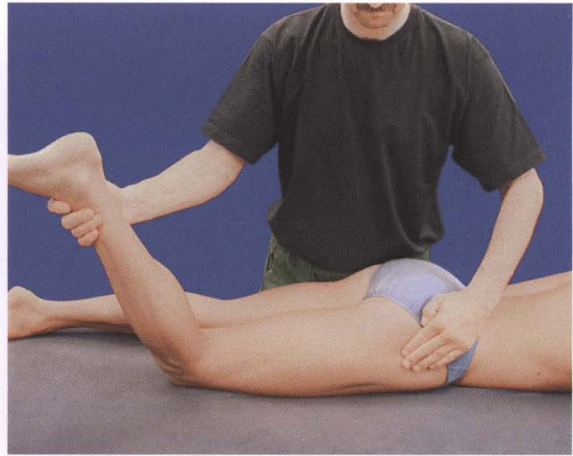


Fig. 5.9 Demonstrating the FNA angle—phase 1

Technique

The greater trochanter is found laterally, at around the same level as the tip of the sacrum approximately at the start of the gluteal cleft. The trochanter is located approximately one hand-width inferior to the iliac crest.

Tip: As this region is often obese, palpation may be difficult and it may be necessary to confirm the localization using the following aid.

The therapist flexes the ipsilateral knee and uses the lower leg as a lever to alternately medially and laterally rotate the hip joint. The trochanter then rolls back and forth underneath the palpating finger so that both its lateral surface and its superior aspect can be well palpated (Fig. 5.8).

The superior tip of the greater trochanter acts as the site of insertion for muscles, including the often impressively tense piriformis.

Its lateral surface is a good reference point for the manual identification of the FNA angle.

Technique

The therapist positions the hip in neutral rotation and flexes the knee. The flat hand palpates laterally over the trochanter (Fig. 5.9).

The hip is placed in medial rotation by moving the lower leg laterally away from the sagittal plane. The therapist should now be able to visualize the greater trochanter moving in a large arc around the head of the femur during the medial rotation movement.

While continuing to palpate, the medial rotation movement is stopped at the position where the trochanter is felt to be most lateral (Fig. 5.10).

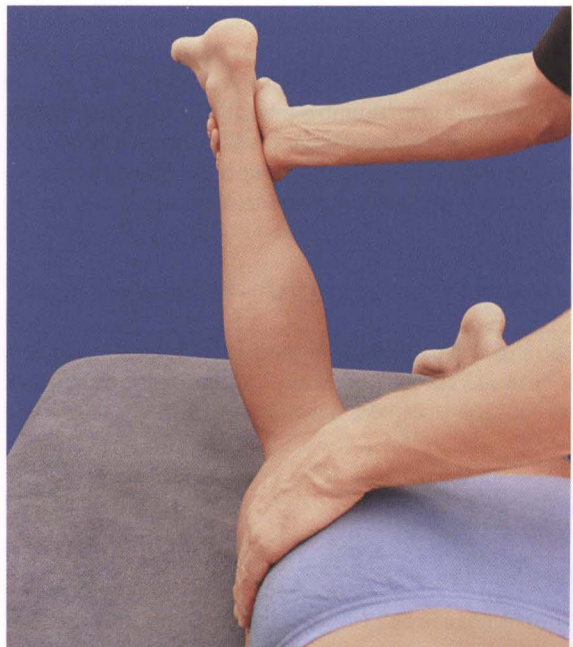


Fig. 5.10 Demonstrating the FNA angle—phase 2.

Femoral Neck Anteversion Angle, Measurement

The FNA angle helps determine the amount of medial rotation at the hip joint. The larger the angle is, the greater the ability of the hip joint to medially rotate—providing the soft tissues (capsule and muscles) have normal elasticity. Restrictions in medial rotation of the hip joint are one of the signs used for the early detection of initial changes in capsular pattern.

Therapists should only conclude that medial rotation of the hip joint is restricted when the left and right FNA angles have been compared. Thus, the manual assessment of the FNA angle is very helpful in supporting the assessment of the hip joint.

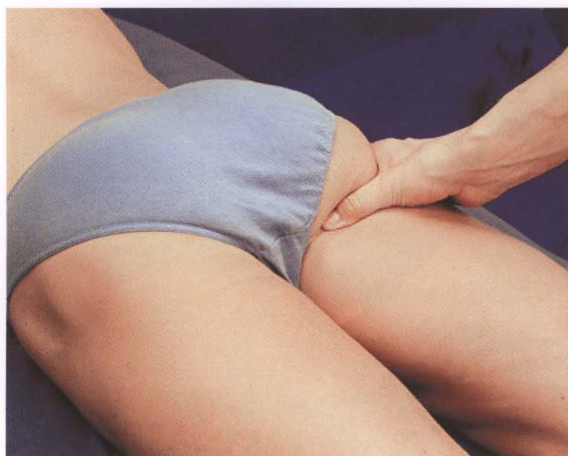

Fig. 5.11 Palpation of the ischial tuberosity.

The therapist assesses the FNA angle by measuring the lateral angle of the leg away from the sagittal plane in degrees.

This method does not clearly identify the FNA angle to the degree, but its use is acceptable to identify rough differences in the amount of FNA angle between the sides.

Ischial Tuberosity

The ischial tuberosity (synonym: tuberosity of the ischium) is another large structure important for orientation. It is an important fixed point for strong ligaments and muscles (hamstrings).

Technique

Using a pinch grip (thumb is medial), the therapist follows the transverse gluteal fold medially until the thumb pushes against the tuberosity (Fig. 5.11). The tip of the tuberosity is initially of importance.

Hamstrings

The aim is to palpate the borders of the muscles and their insertions. The bellies of the muscles become distinct when the muscles contract into knee flexion against resistance.

Technique

Muscle Bellies

The borders can be easily palpated by holding the contraction or rhythmically contracting and relaxing (Fig. 5.12). It is noticeable that the muscles on the posterior thigh do

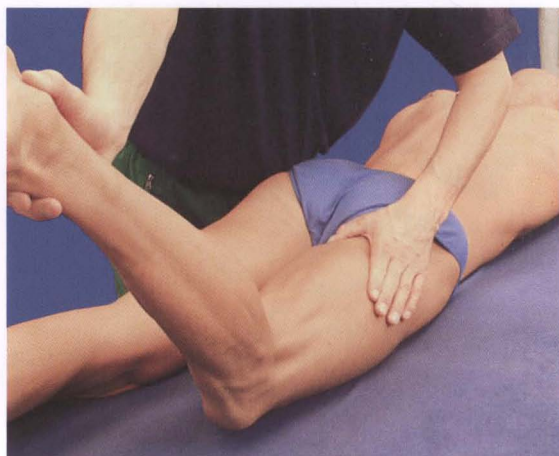


Fig. 5.12 Demonstrating the muscle bellies.

not follow the axis of the leg, but have an angled course. They travel proximally and medially toward the ischial tuberosity.

Tip: As the muscles are approximated proximally in the prone position, the knee should not be flexed extensively and the therapist should not let the patient contract the muscle too strongly to avoid the risk of muscle cramping.

The vastus lateralis of the quadriceps femoris forms the lateral boundary to the hamstrings, in particular the biceps femoris. This is all the more surprising because the vastus lateralis is expected to be found more anteriorly on the thigh than posteriorly. It actually lies not only anteriorly and laterally beneath the iliotibial tract, but also quite posteriorly.

Tendon of Origin

The edges of the muscle can be easily followed more proximally. The muscles merge together into a common head and can therefore no longer be differentiated from one another. The common tendon of origin is found more on the lateral side of the tuberosity. As described in Chapter 9, the insertion is found immediately adjacent to the sciatic nerve. The tendon itself can be differentiated from the surrounding softer tissues by palpating with the thumb and index finger or by using both hands (Figs. 5.13 and 5.14).

Tip: If contraction of the gluteus maximus impedes palpation, this muscle can be reciprocally inhibited by asking the patient to push the knee down into the treatment table.

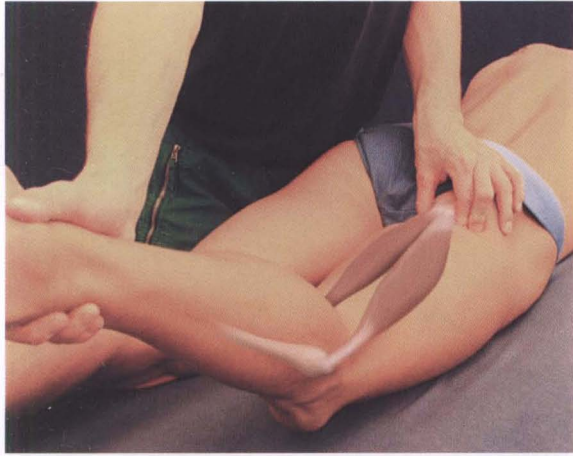

Fig. 5.13 Palpation of the common head—method 1.

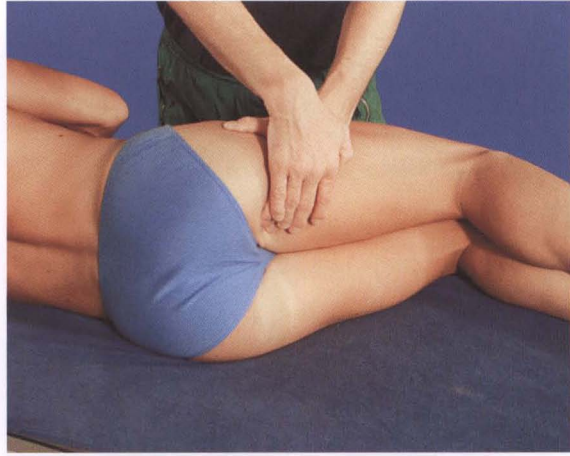

Fig. 5.15 Transverse frictions at the common head.

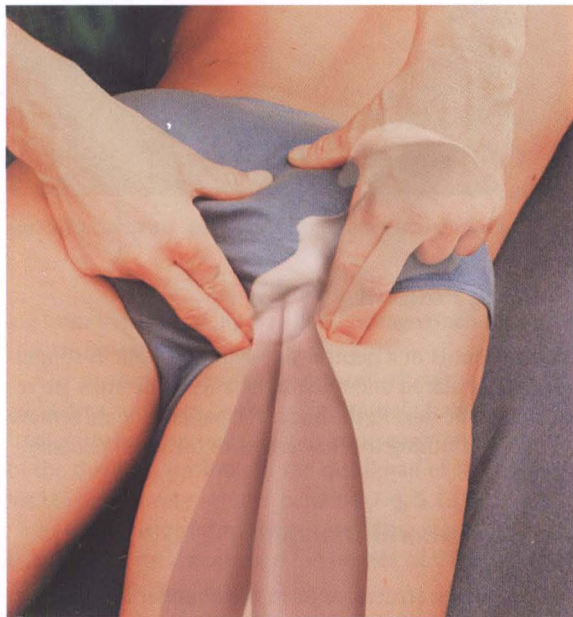

Fig. 5.14 Palpation of the common head—method 2.

Posterior Pain

The hamstrings can be conspicuous, especially in athletes, when insertion tendinopathy or tendinitis near the insertion causes local pain. Local palpation makes the targeted search for the affected structure more reliable.

Transverse frictions, used for provocation of pain or treatment, are primarily conducted in side-lying.

Technique

Tendinopathy

The therapist selects a starting position (SP) where the hips are clearly flexed so that the tendon of origin is placed under slight tension and remains still during frictioning. If necessary, the knees can be extended a little further.

The hand palpates distal to the ischial tuberosity and applies transverse friction. More pressure is applied during the movement from medial to lateral (Fig. 5.15).

It is recommended that the other hand assists in the application of pressure to make this technique less tiring.

Tips for Assessment and Treatment

Lateral Pain

The trochanteric bursa and the iliotibial tract are found on the lateral surface of the greater trochanter. When inflamed, these structures cause localized symptoms on the lateral aspect of the hip. Pressure is used to provoke pain to confirm this source of pain.

Local Palpation—Anterior

Overview of the Structures to be Palpated

This region is divided into two triangles to aid orientation. The borders of these triangles, as well their contents, are the target of localization.

Lateral Femoral Triangle

- Sartorius.
- Tensor fasciae latae.
- Tendon of rectus femoris.
- Anterior inferior iliac spine (AIIS).

Medial Femoral Triangle

- Sartorius.
- Adductor longus.
- Inguinal ligament.

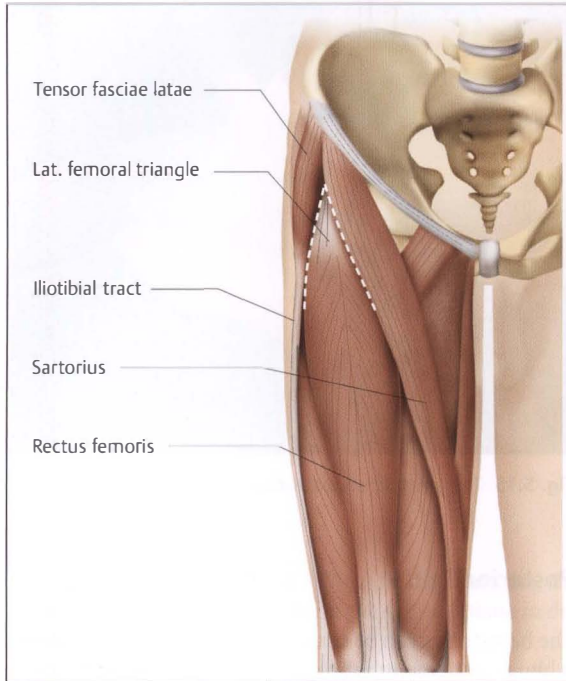


Fig. 5.16 Lateral femoral triangle.

- Anterior superior iliac spine (ASIS).
- Iliopsoas, iliopectineal bursa.
- Femoral nerve, artery, and vein.
- Pectineus.
- Pubic tubercle.
- Adductor longus.
- Gracilis.

Summary of the Palpatory Process

This region is divided into two triangles to aid orientation: lateral femoral triangle and medial femoral triangle. The borders of these triangles, as well their contents, are the target of localization.

Local palpation of the anterior hip region in particular aims to locate the soft-tissue structures, that is, muscle bellies and their insertions that are of particular clinical importance.

Palpation begins on the lateral triangle of the thigh. The bordering muscles and their edges will be precisely identified. The structures deep in the tissues will be located with the aid of guiding structures and muscle contraction.

This is followed by the palpation of the medial triangle of the thigh. Its boundaries will also be located first, followed by the palpation of the structures inside the triangle.

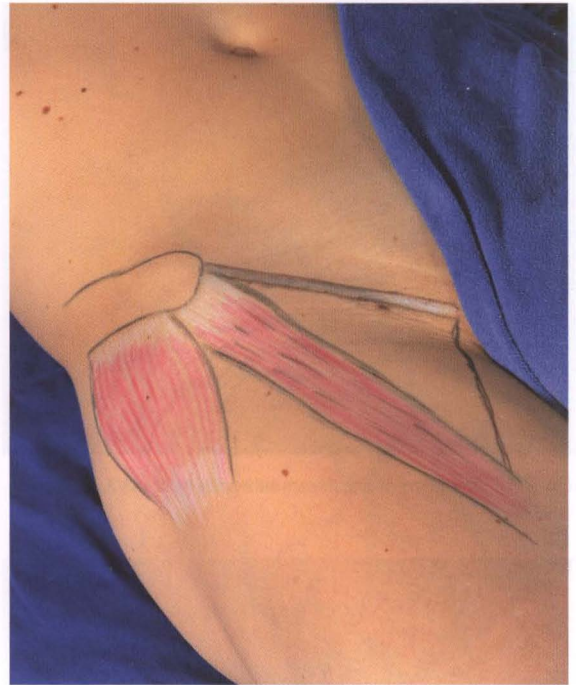


Fig. 5.17 Drawing of the lateral femoral triangle structures following palpation.

Starting Position

The patient is in a neutral side-lying position. A supportive roll is placed underneath the knees; the arms are relaxed and lie next to the body. The patient should remove sufficient clothing to allow access to the groin region.

Lateral Femoral Triangle

The following structures form the boundaries of the lateral triangle of the thigh (Fig. 5.16):

- Lateral edge of the sartorius.
- Anterior edge of the tensor fasciae latae.

The ASIS is the most important osseous structure. This area is actually not a “triangle,” but is instead shaped like an arrowhead with its tip pointing superiorly. The triangle does not have a third border (Fig. 5.17).

Sartorius

The sartorius is the central muscle used for orientation. Its diagonal course over the thigh separates the lateral triangle from the medial triangle.

The sartorius and tensor fasciae latae are hip joint flexors. Their position can be illustrated by actively flexing the hip. To do this, the patient is instructed to slightly raise the

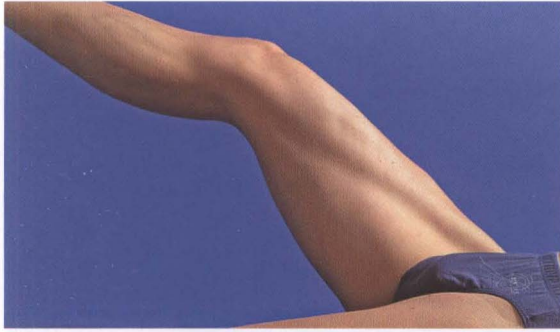


Fig. 5.18 Sartorius—entire course.

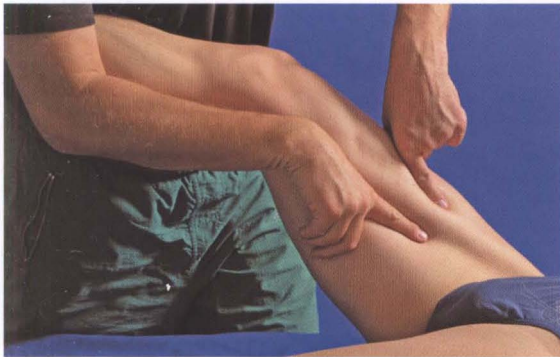


Fig. 5.19 Sartorius—palpation of the edges of the muscle.

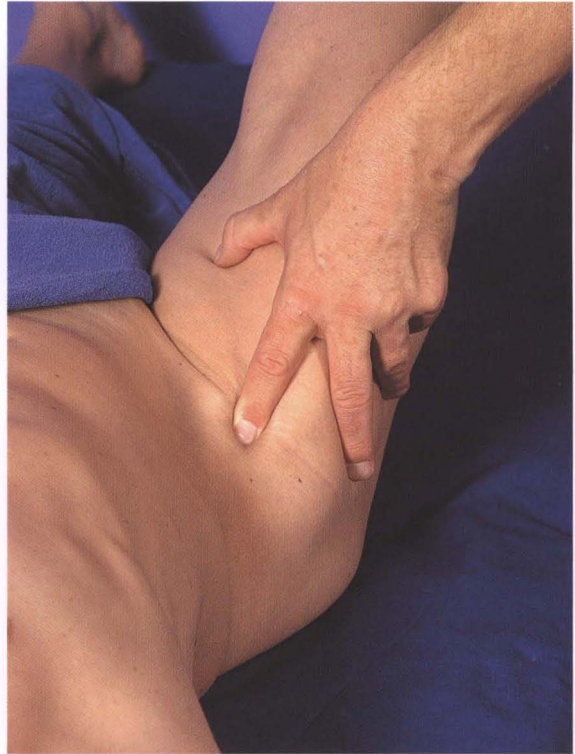


Fig. 5.20 Palpation in the lateral femoral triangle.

leg from the neutral hip position, during which the knee may be flexed slightly.

The sartorius becomes prominent when the hip joint additionally rotates laterally. The muscle belly can very frequently be observed along its course up to the middle of the thigh. Its position in the distal half of the thigh is visible only in very slender patients (Fig. 5.18).

Its medial edge forms the border of the medial femoral triangle and its lateral edge the border of the lateral femoral triangle (Fig. 5.19).

In patients with a normal amount of body fat, the contours of two muscles can be identified in the hip region when the hip flexor contraction is held.

The lateral edge of the sartorius is now followed more proximally until the palpating finger encounters soft-elastic resistance on the lateral aspect (Fig. 5.20). This is the anterior edge of the tensor fasciae latae.

Tensor Fasciae Latae

The tensor fasciae latae becomes particularly distinct when the patient moves the flexed leg from lateral rotation into medial rotation.

The anterior edge of the tensor fasciae latae can be palpated quite well, while the posterior edge usually merges into the fascia of the thigh.

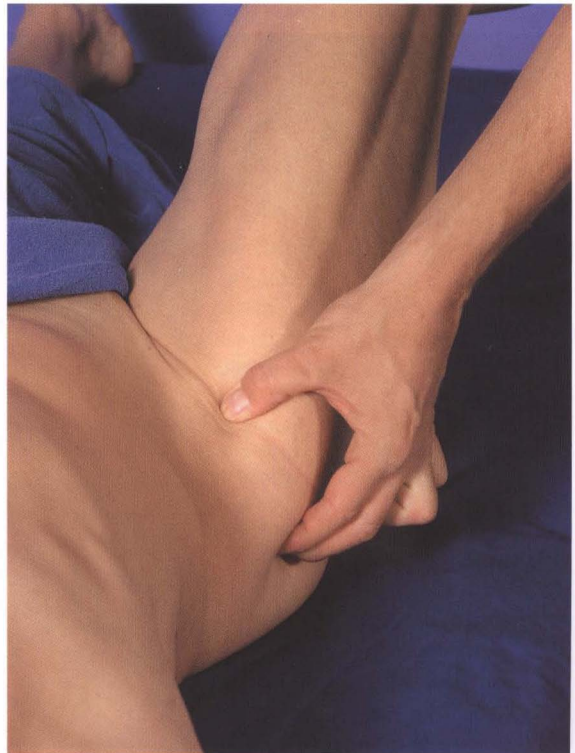


Fig. 5.21 Edges of the tensor fasciae latae.

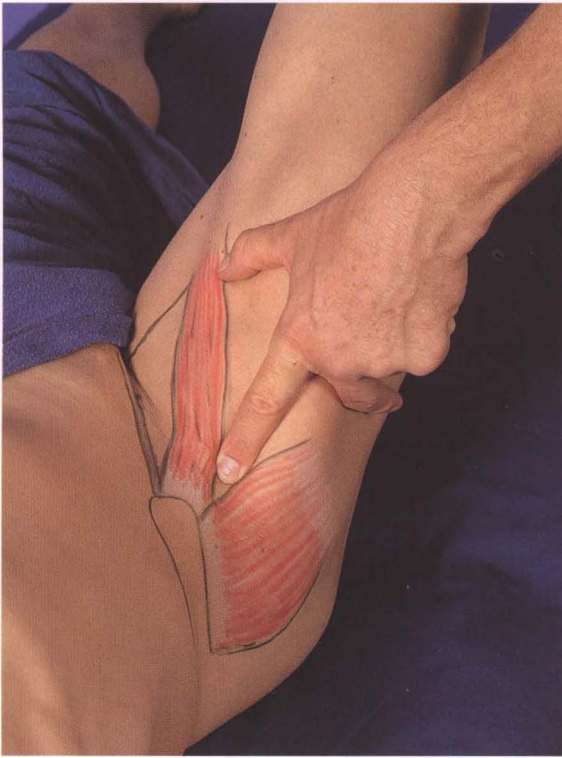


Fig. 5.22 Tip of the lateral triangle of the thigh.

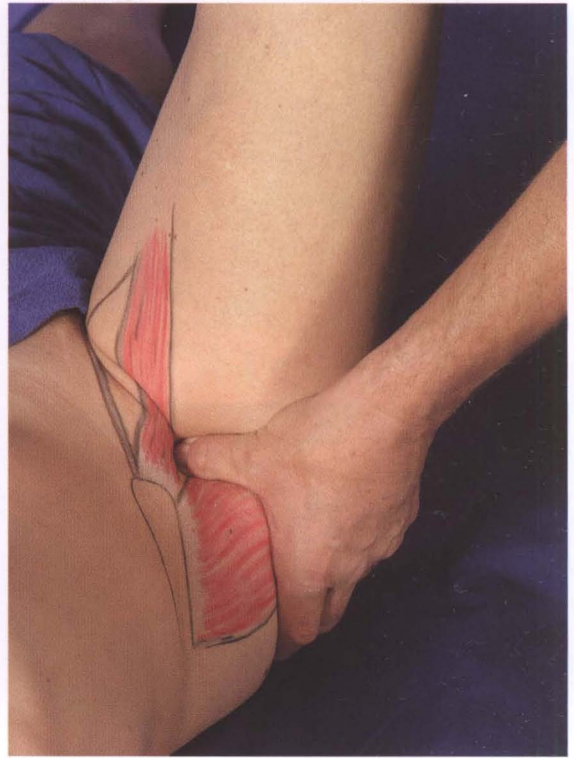


Fig. 5.24 Palpation of the tendon of origin for the rectus femoris.

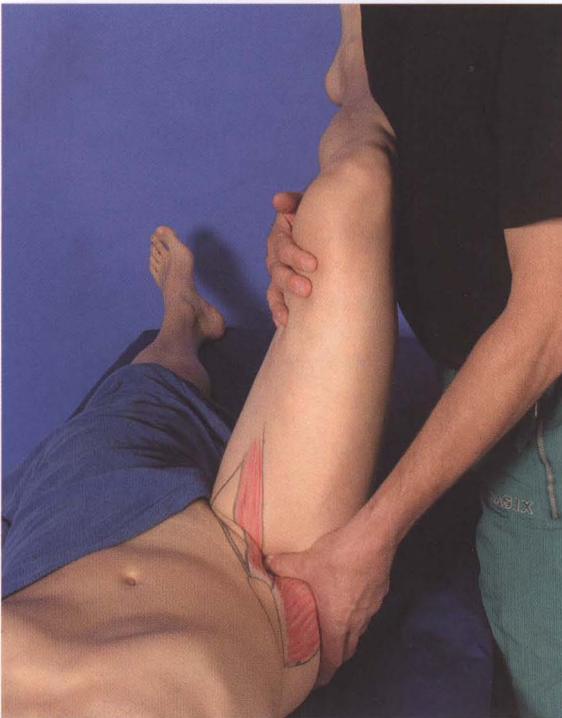


Fig. 5.23 Palpation of the AILS.

The muscle belly is followed up onto its muscular origin. It becomes obvious that this involves not only the ASIS, as is often specified in anatomy books, but also a wide section of the iliac crest (Fig. 5.21).

Rectus Femoris

The muscular edges of the tensor fasciae latae and sartorius meet superiorly and form an inverted “V” shaped like an arrowhead (Fig. 5.22). The tip is found immediately inferior to the ASIS. The rectus femoris forms the floor of this incomplete triangle of the thigh.

Where the muscular edges of the tensor fasciae latae and sartorius meet, the rectus femoris tendon of origin disappears deep into the tissue as it heads toward the AILS (Fig. 5.23).

To reach this insertion, the leg to be palpated is passively moved into approximately 90° hip flexion and the lower leg held in a horizontal position.

The patient must fully relax the leg during this part of the procedure. Using the thumb of the free hand, the therapist transversely palpates the deep tissue at the tip of the triangle, applying moderate pressure (Fig. 5.24). An attempt is then made to locate the rectus femoris tendon. This tendon is somewhat firmer than the surrounding tissues.

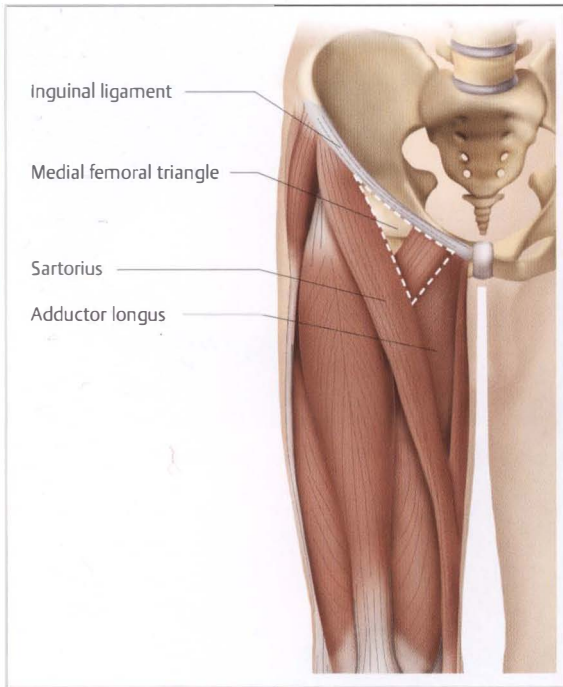


Fig. 5.25 Medial femoral triangle.

Tip: The tendon can be immediately located when the patient rhythmically extends and flexes the knee slightly as if kicking a ball toward the ceiling. The surrounding hip flexors remain relaxed during this movement and the rectus femoris is the only muscle that is active.

Once the tendon has been found, the therapist follows the tendon to the AILS. This structure has been reached when an osseous structure is felt.

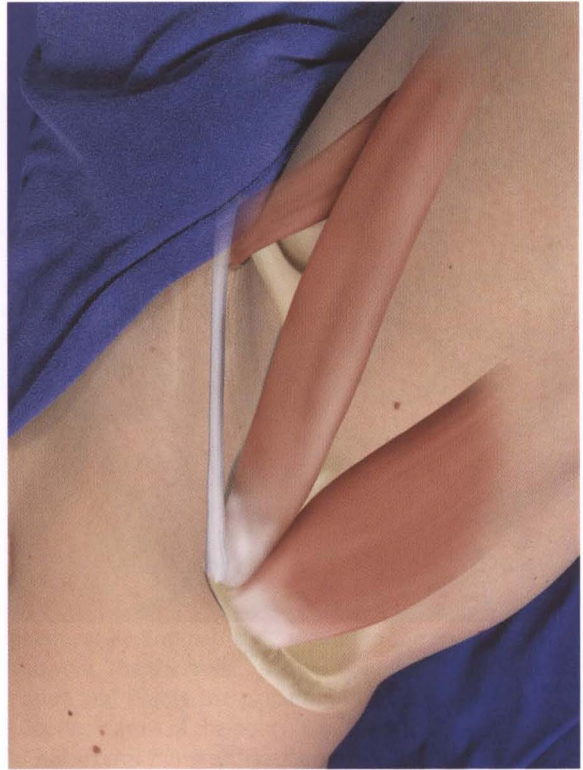


Fig. 5.26 Demonstrating the medial triangle of the thigh.

is identified using the technique described above (see Fig. 5.20). Its edges are followed distally as far as possible until at least the middle of the thigh has been reached.

Medial Femoral Triangle

The following structures form the boundaries of the medial triangle of the thigh (Figs. 5.25 and 5.26):

- Inguinal ligament.
- Lateral edge of the adductor longus.
- Medial edge of the sartorius.

In particular, the following structures will be located (in the triangle from lateral to medial):

- A section of the iliopsoas, the iliopectineal bursa.
- Femoral nerve, artery, and vein.
- Proximal insertion (origin) of the pectineus.
- Proximal insertion (origin) of the adductor longus.
- Course of the gracilis.

Sartorius

The sartorius is once again a crucial structure needed for orientation at the medial triangle of the thigh. The muscle

Adductor Longus

The patient moderately flexes the thigh then lowers it, abducting the hip to around 45°. All adductors work isometrically when the patient holds the leg in this position.

The adductor longus is the most prominent adductor of this muscle group (Fig. 5.27).

Tip: If this activity is not enough to make the belly of the muscle visible or palpable, the therapist can position their hand on the medial knee joint and instruct the patient to push against the hand in an isometric contraction. This should suffice to make the entire length of the muscle distinct. The medial edge of the adductor longus is an important boundary for the medial triangle.

Inguinal Ligament

The course of the groin ligament (inguinal ligament), the last bordering structure of the triangle, will now be clarified. This ligament extends from the ASIS to the pubic tubercle, the structure found immediately superolateral to

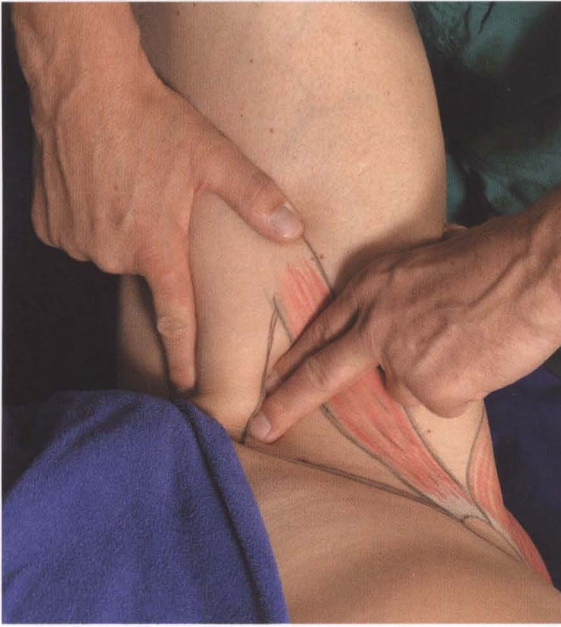

Fig. 5.27 Edges of the adductor longus.

the symphysis. This ligament of the groin is a fusion of several layers of fascia. When the therapist attempts to transversely palpate the ligament, the typical firm and elastic feel and the clear differentiation from the (usually) soft neighboring tissues is absent.

The ASIS is differentiated from the ligament by assessing consistency. A rounded, hard contour can be felt when the therapist is transversely palpating the ASIS (Fig. 5.28), while the structures distal to the tip are elastic when pressure is flatly applied during transverse palpation (Fig. 5.29).

The special structures listed above are found in the “floor” of the triangle. Their localization will now be described.

Iliopsoas, Iliopectineal Bursa

The first structure that can be palpated directly medial to the ASIS and the insertion of the sartorius is a section of the iliopsoas muscle. This muscle can only be accessed at this site. The iliopectineal bursa is found beneath the muscle and can be indirectly located by applying pressure deep into the tissues. It is sensitive to pressure in the presence of bursitis.

Femoral Nerve, Artery, and Vein

The neurovascular bundle is the next structure further medially (Fig. 5.30). The femoral artery is the most suitable structure for direct localization.

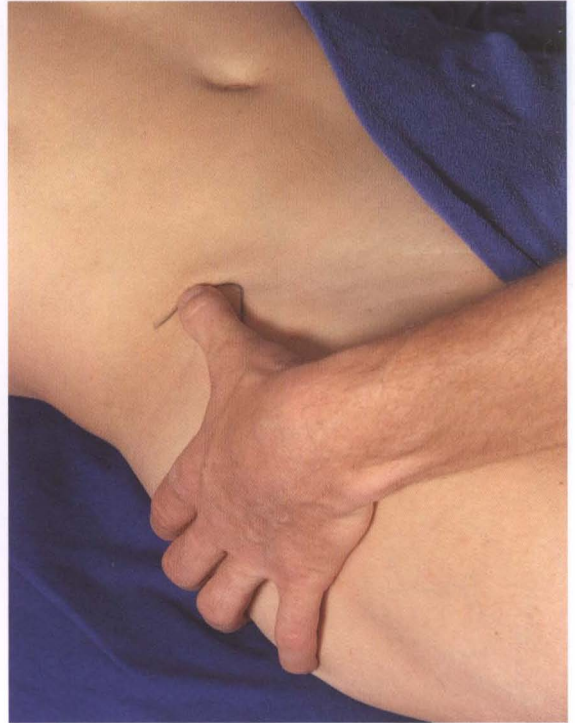

Fig. 5.28 Palpation of the ASIS.

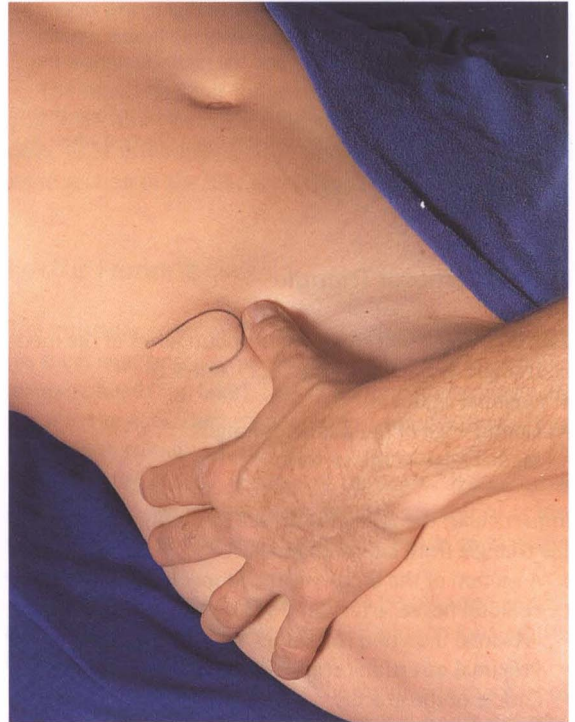


Fig. 5.29 Palpation of the inguinal ligament.

It extends from the middle of the inguinal ligament to the tip of the medial femoral triangle. It enables the thera-

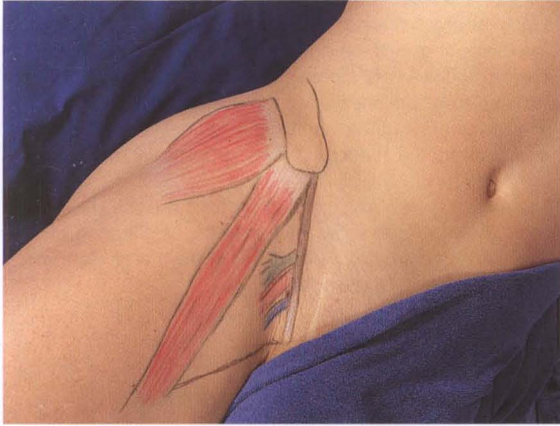

Fig. 5.30 Femoral artery and nerve in the medial femoral triangle.

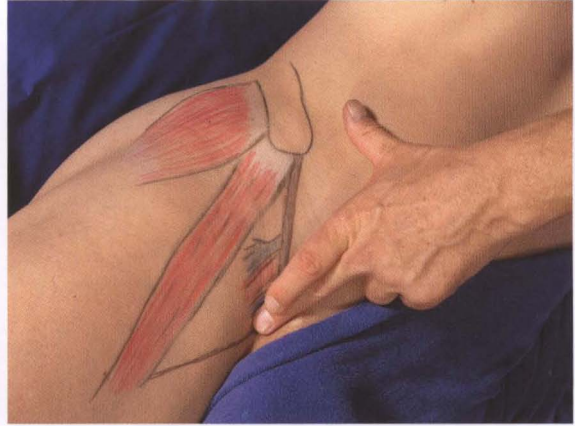


Fig. 5.32 Palpation of the pectineus.

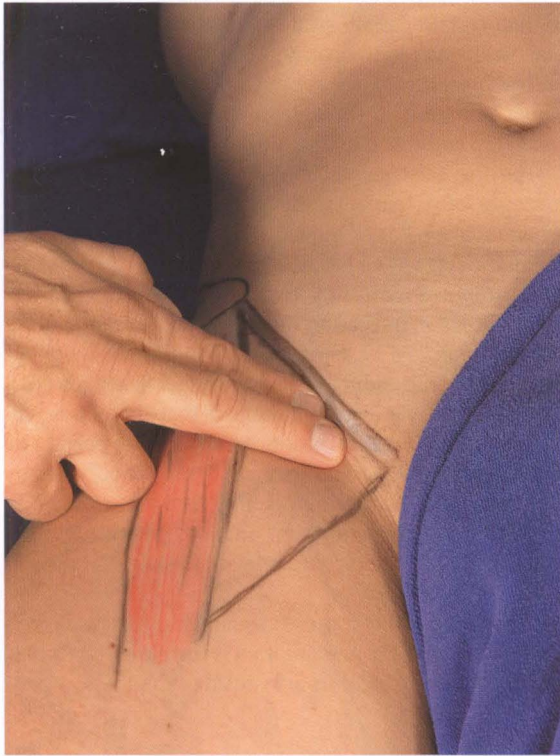


Fig. 5.31 Palpation of the femoral artery.

pist to visualize the position of the head of the femur found directly beneath it.

For the palpation, one or several finger pads are placed flat over the middle of the inguinal ligament and apply only light pressure (**Fig. 5.31**).

One of the finger pads feels the rhythmical pulse of the artery within a very short amount of time. Topographical anatomy dictates that the nerve must be lying immediately lateral to the artery and the femoral vein immediately medial.

Proximal Insertion of the Pectineus

The pectineus can be palpated on the sharp edge of the pectineal line immediately medial to the femoral artery and vein. The therapist pronates the forearm for this palpation and points the palpating finger pads toward the superior ramus of the pubis (**Fig. 5.32**). The therapist applies frictions from medial to lateral during this palpation.

Tip: As the pressure of palpation is often quite uncomfortable, the therapist should apply pressure with care when conducting the technique. As with the palpation of all muscles presented in this book, this technique can be used to provoke pain or as a form of treatment.

Proximal Insertion of the Adductor Longus

The proximal insertion of the adductor longus on the pubic tubercle is the next medial structure.

To palpate this structure, the palpating finger moves slightly more medially (**Fig. 5.33**). The pubic tubercle is found at the superior border to the pubic symphysis.

The tendon of insertion is subject to variation and may be divided into two tendons. The tendon(s) and the muscle–tendon junction can be easily differentiated from one another. The consistency of the muscle–tendon junction is considerably softer than the tendon. The tendon is a taut collagenous structure and is significantly firmer.

If the tendon of insertion cannot be identified as the structure medial to the pectineus, the therapist can identify the muscle belly of the adductor longus by using the technique described above (see **Fig. 5.27**) and following the muscle proximally onto its insertion.

The therapist is already familiar with the position of the muscle belly from the previously described boundaries of the medial femoral triangle.

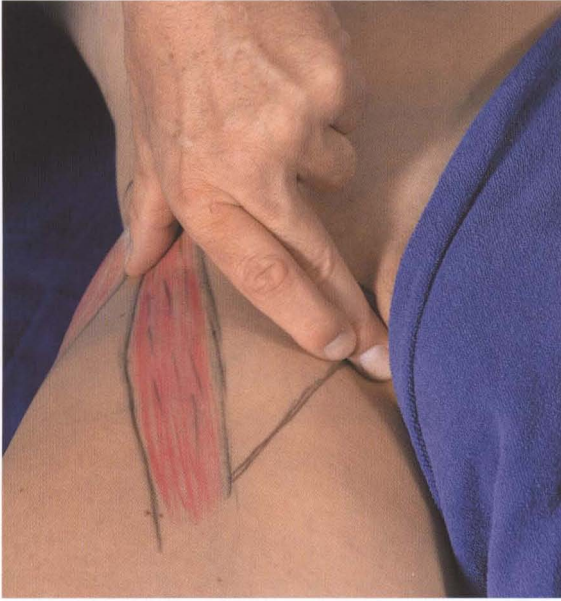

Fig. 5.33 Palpation of the pubic tubercle.

Gracilis

To differentiate the position and course of the gracilis from that of the adductor longus, the muscle belly of the adductor longus must be displayed (see Figs. 5.27 and 5.34).

The patient holds the flexed leg as it falls to the side with an isometric contraction. The edges of the adductor longus muscle belly can be easily differentiated again from the surrounding soft tissues (Fig. 5.34).

The patient is then instructed to push the heel into the treatment table (and toward the buttocks). The gracilis should tense here as it is a flexor of the knee. Its muscle belly is now prominent and can, in turn, be followed onto its insertion on the pubic symphysis (Fig. 5.35).

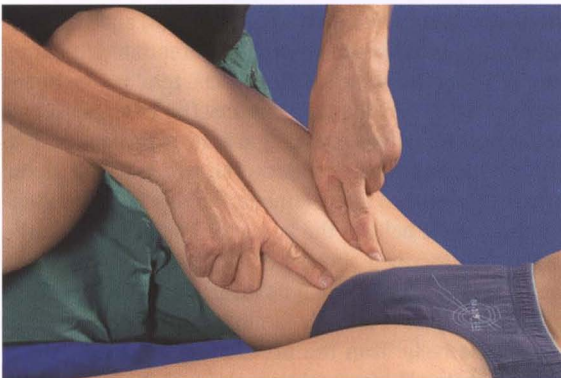


Fig. 5.34 Edges of the adductor longus.

Tip: If the gracilis cannot be clearly located using this method, the therapist uses the reciprocal inhibition principle again. The hip and knee are slightly flexed and the patient is instructed to let the knee fall to the side. The therapist then applies light resistance to the lateral knee. The patient must now contract the abductors, which reciprocally inhibits all of the adductors.

The patient is then instructed to contract the knee flexors again (now using its second action in the neighboring knee joint). At this point, the muscle belly of the gracilis protrudes clearly in relation to its surroundings.

Tips for Assessment and Treatment

The palpation of all muscle bellies and their insertions can be used to differentiate structures during assessment. These techniques may also be used as Cyriax cross-friction to treat certain pathological conditions in the soft tissues (e.g., insertion tendinopathy).

The presence of disease in the adductors usually becomes apparent in the assessment of isometrically resisted hip adduction and, at times, hip flexion.

The therapist should nevertheless first consider the presence of a tendinopathy or insertion tendinopathy when involvement of the sacroiliac joints and especially the pubic symphysis has been excluded. Recurring groin pain combined with adductors that are sensitive to pressure is often an indication that these joints are the cause of symptoms.

If resisted hip adduction in a neutral or flexed hip position is positive, it is recommended that the test be repeated with a seat belt positioned around the pelvis. The fixating seat belts commonly used in manual therapy are suitable for this. The resistance test that resulted in groin pain or “adductor pain” and was positive without the use of a seat belt is repeated with the seat belt in position.

If the repeated test causes significantly less pain, it is highly likely that the presumption is correct and the pubic symphysis or the SI joints are causing symptoms.

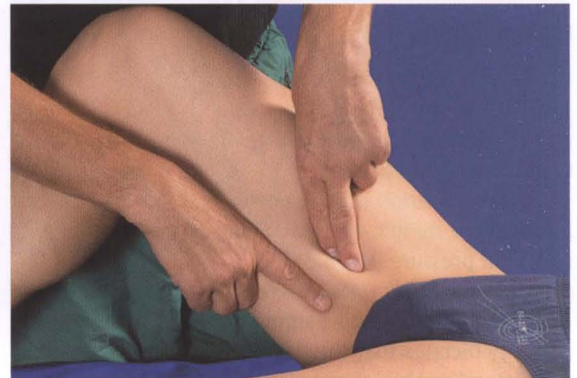

Fig. 5.35 Edges of the gracilis.

Study Questions

1. Which bony landmarks are connected by the inguinal ligament?
2. How do therapists reach the insertion of the rectus femoris?
3. Where can the iliopectineal bursa be found?
4. Which structure indicates the position of the hip joint or the head of the femur?

THIS PAGE INTENTIONALLY
LEFT BLANK



6 Knee Joint

- Significance and Function of the Knee Joint ... 121
- Common Applications for Treatment in this Region ... 122
- Required Basic Anatomical and Biomechanical Knowledge ... 122
- Palpating Edema and Increase in Temperature ... 123
- Local Palpation—Anterior ... 125
- Local Palpation—Medial ... 130
- Local Palpation—Lateral ... 137
- Local Palpation—Posterior ... 144
- Study Questions ... 148

THIS PAGE INTENTIONALLY
LEFT BLANK

6 Knee Joint

The knee joint is not only the largest joint of the body; it is also the joint with the most complicated biomechanics. Therapists frequently have to deal with this joint in their daily work. Post-traumatic and postoperative treatment of this joint is part of the treatment repertoire of every clinic and private practice.

Comparatively, the large number of knee operations is extraordinary. The common indications for surgical intervention are arthritic changes in articular surfaces and injury to the complex ligamentous construction and the menisci.

In addition to appropriate postoperative treatments, the concepts of which are now quite refined, therapists are often presented with joint symptoms that are difficult to allocate. Symptoms arising from overloading of muscles and collagen, with and without edema, make it necessary for therapists to approach assessment with skill. Therefore, precise palpation, in addition to systematic questioning and assessment, is of great importance when searching for the cause of symptoms.

Significance and Function of the Knee Joint

*One of the **basic principles of joint function** in the lower limbs will also become obvious in the knee joint. It aims to lock the lower limbs so that it forms a supportive column when necessary and to provide the lower limbs with the required amount of mobility.*

This **knee joint mobility**, with its enormous range of flexion, means that the distance between the body and foot is reduced, and can be observed in everyday situations such as crouching down, climbing steep stairs, or getting into a car.

The second form of mobility is the **rotation of the knee joint**. This movement is linked to the angle of knee-joint

flexion and is only possible between approximately 20–130° of knee flexion. If active rotation in end-range extension was possible, it would presumably be at the cost of stability, which is of particular importance in the extended position.

The **ability of the foot to rotate** is mainly anchored in the knee joint. The remaining rotation occurs in the kinematic chain formed by the talocrural joint (ankle joint), the talocalcaneonavicular (TCN) joint, the subtalar (ST) joint, and the proximal tarsal joints.

Above all, it is the ability to rotate that places specific demands on the construction of the articulating bones at the knee joint. Axial rotation of the lower leg at the knee joint requires a central rotary column (primarily the posterior cruciate ligament), a flat rotary plate (proximal end of the tibia), and articular surfaces with almost only one single point of contact.

This rotary plate causes a high degree of **incongruency between the articular surfaces**. The knee would be unable to rotate as well if the tibial articular surface were more curved. Although incongruency facilitates rotation, stability and the transfer of load suffer. The menisci complement this joint, forming a mobile articular socket to balance the pointlike contact between the articular surfaces and to lubricate the joint.

As **stability** can no longer be provided by the bones, internal and external ligamentous structures (cruciate and collateral ligaments) as well as sections of muscle that radiate into the capsule (dynamization) fulfill this function (**Table 6.1**).

The cruciate ligaments stabilize the joint in the sagittal plane. This function can also be assessed using a test conducted in the sagittal plane, the drawer test. These ligaments also modulate tension to control the arthrokinematics during flexion and restrict the amount of medial rotation.

Table 6.1 Muscular attachments and dynamized structures

Quadriceps femoris	Anterior capsule (patellar ligament and a variety of retinacula), menisci (via the patellomeniscal ligaments)
Adductor longus	Medial collateral ligament
Biceps femoris	Lateral collateral ligament and the lateral meniscus
Popliteus	Posterior capsule (arcuate ligament of the knee) and the lateral meniscus
Semimembranosus	Posterior capsule (oblique popliteal ligament), medial meniscus, medial collateral ligament
Gastrocnemius	Posterior capsule

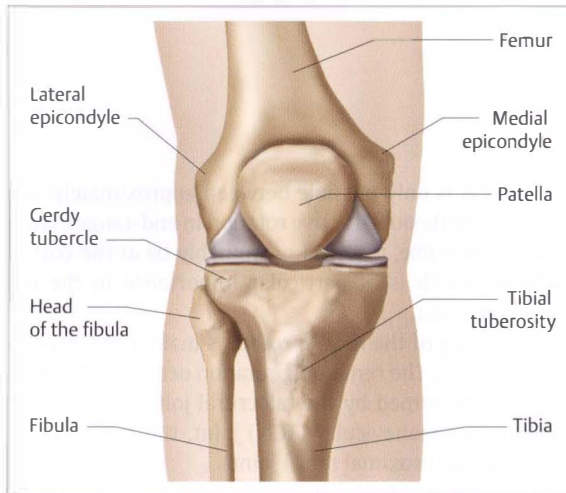


Fig. 6.1 Topography of the osseous reference points—anterior view.

Knee-joint stabilization in the frontal plane is the function of both the collateral ligaments and the posterior capsule.

The **dynamization** of different collagenous structures at a joint was not an “invention” of the knee joint. However, it is quite distinct in this region. Dynamization means that muscles, and sometimes their tendons, are attached to the capsule or menisci. Different sections of the capsule are placed under tension and strengthened when these muscles contract. During active movement of the knee, the femoral condyles not only “roll” over the menisci on the tibia in an anterior or posterior direction, the contraction of muscles also pulls on the menisci and causes movement.

Common Applications for Treatment in this Region

A Selection of Possible Symptoms

It is beyond the scope and objectives of this book to list all types of disease and injuries seen in the knee joint. Therefore, only the most important groups are listed below:

- Capsular and noncapsular restrictions in movement.
- Hypermobility and/or instability.
- Pathological conditions of the meniscus.
- Injuries to ligaments or ligamental overuse syndromes.
- Injuries to the muscles or muscular overuse syndromes (including tendons and insertions).
- Disease of the femorotibial articular cartilage (e.g., arthritis or osteochondrosis dissecans) or the patellofemoral articular cartilage (e.g., chondromalacia patellae or patellofemoral pain syndrome).

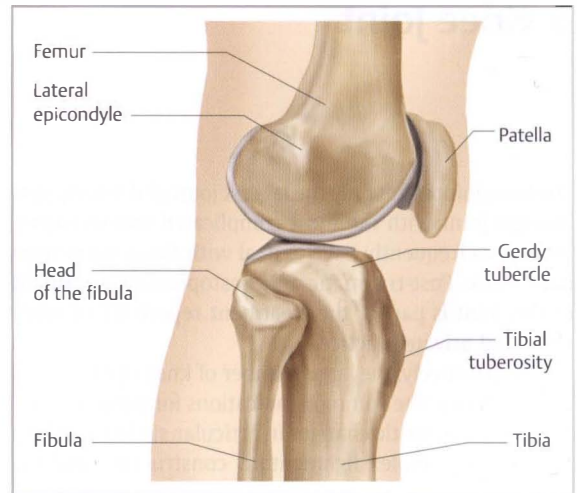


Fig. 6.2 Topography of the osseous reference points—lateral view.

Common Assessment and Treatment Techniques

- Assessment and mobilization of existing restrictions in mobility.
- Improvement of muscular tracking of the joint in cases of instability.
- Treatment of injuries in ligaments and muscles or the symptoms associated with overloading.

The high prevalence of irritation or injury to ligaments, tendons, and bursae shows in the established use of independent terms such as “runner’s knee” (iliotibial band friction syndrome), “jumper’s knee” (insertion tendinopathy of the patellar ligament at the apex of the patella), and “housemaid’s knee” (prepatellar bursitis).

Required Basic Anatomical and Biomechanical Knowledge

Therapists must have a good basic knowledge of anatomy to locate specific important structures in the knee joint and its surroundings. Therapists are familiar with most bony and ligamentous structures. It is important to develop good spatial sense so that the construction of the knee can be considered from different perspectives. Here are a few pointers:

Construction of the Femorotibial Joint

- Anterior view of the position and shape of the femoral condyles (**Fig. 6.1**).

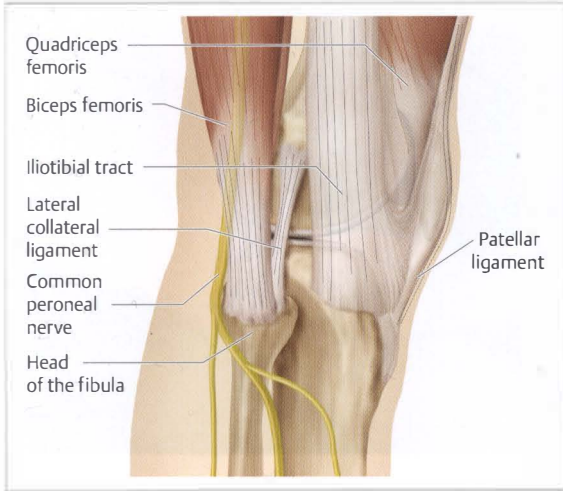


Fig. 6.3 Relevant lateral soft tissues.

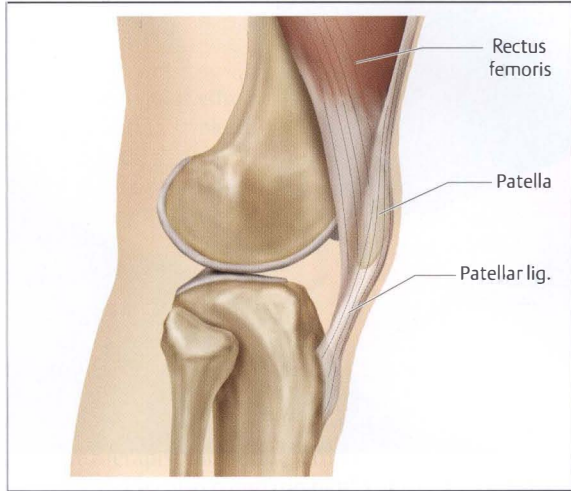


Fig. 6.6 Rectus femoris, patella, and ligament during knee extension.

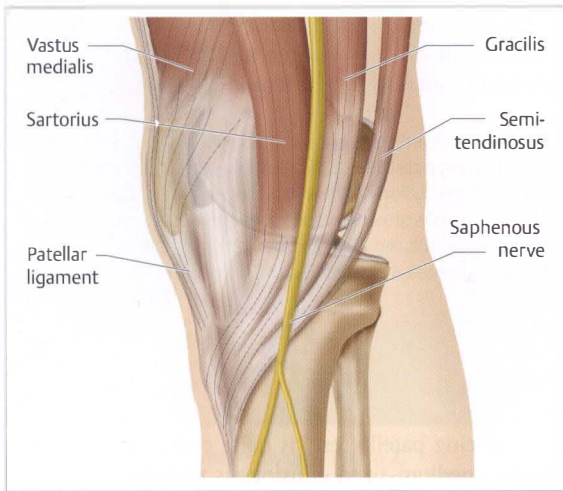


Fig. 6.4 Relevant medial soft tissues.

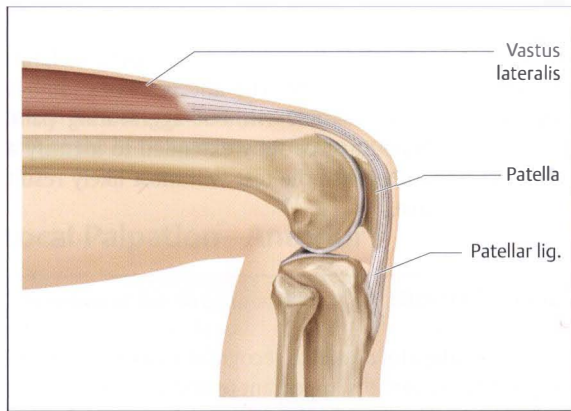


Fig. 6.7 Rectus femoris, patella, and ligament during knee flexion.

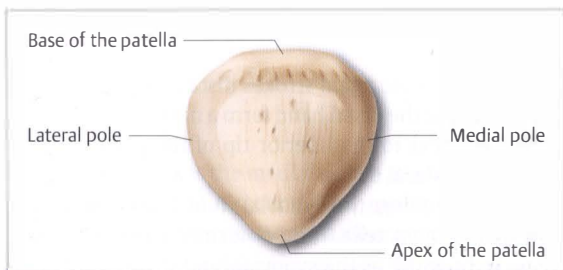


Fig. 6.5 Sections of the patella—anterior view.

Construction of the Patellofemoral Joint

- General construction of the patella (its shape in the view demonstrating its base, poles, and apex; **Fig. 6.5**).
- Patellar ligament (**Figs. 6.6** and **6.7**).
- Position of the patella in extension and flexion (**Figs. 6.6** and **6.7**).

Palpating Edema and Increase in Temperature

Summary of the Palpatory Process

Techniques will be described that identify the presence of edema and increased temperature in the joint in terms of:

- Large effusions.
- Medium-sized effusions.
- Minimal effusions.
- The palpation of an increase in temperature.

- Shape of the tibial plateau, crucial when locating the joint space and following the space laterally (**Figs. 6.2** and **6.4**).
- Position and pathway of peripheral nerves (tibial nerve, common peroneal nerve, and saphenous nerve; **Fig. 6.4**).

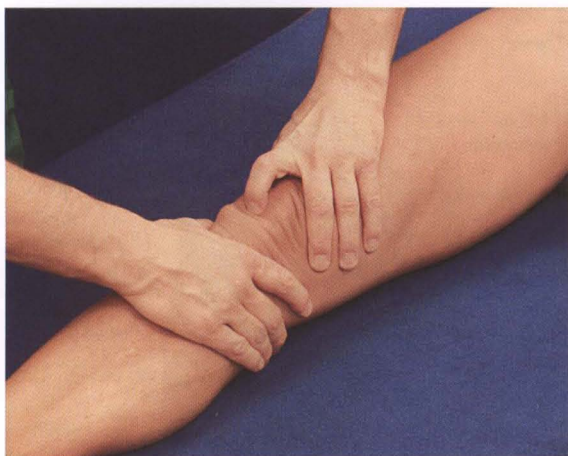


Fig. 6.8 Test for large effusions.

Starting Position

The patient is positioned in either prone-lying or long-sitting on a treatment table. The affected knee joint is extended as far as possible without aggravating pain. However, the knee must be fully extended to identify a small effusion, otherwise the test will most likely result in a false negative.

Large Effusion

It does not take a lot of skill to recognize a large swelling in the joint. However, it is important to know whether swelling is intra-articular or extra-articular to ensure the correct treatment approach.

The posterior, medial, and lateral sections of the capsule are taut when the knee is extended. Intra-articular fluid accumulates anteriorly underneath the patella and, in some cases, lifts the patella away from the femur.

Technique

This test aims to collect the synovial fluid underneath the patella and to identify the extent of the edema by applying pressure to the patella.

The thumbs of both hands are abducted here. The distal hand is positioned over the joint space of the knee (Fig. 6.8). It prevents the synovial fluid from spreading distal and lateral to the patella.

The proximal hand starts stroking widely over the thigh approximately 10cm superior to the patella so that the synovial fluid is milked out of the suprapatellar pouch and accumulates underneath the patella. This raises the patella. One finger of the proximal hand is then placed on the patella and pushes it down until it comes into contact with the articular surface of the femur.

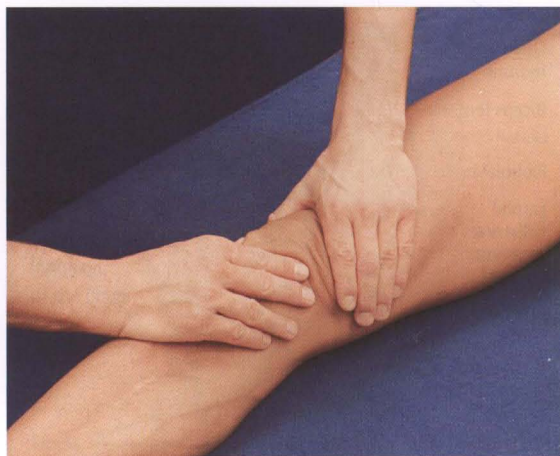


Fig. 6.9 Test for medium-sized effusions.

The criterion for this test to determine the extent of the edema is the amount of time it takes for the patella to come into contact with the femur.

Tip: The sides are compared in this test. This test is also called the “dancing patella test,” “ballotable patella,” or the “patella tap test.” Execution of the test varies significantly. All forms are permissible providing the following details are observed: fluid is accumulated and held beneath the patella, and perpendicular pressure is applied onto the patella.

Medium-sized Effusion

The “dancing patella test” is quite common; the test to identify medium-sized effusions is used less often (Fig. 6.9).

Technique

The proximal hand again strokes distally. The thumb and index finger of the distal hand form a narrow “V,” which is positioned next to the inferior tip of the patella and its medial and lateral edges.

During stroking, the synovial fluid is pushed distally underneath the patella. The “V”-formed hand feels an increase in pressure as the synovial fluid spreads out.

The criterion for this test is the different extent of this pressure.

Minimal Effusion

It is very simple to identify a moderate- or large-sized edema in the knee joint. A special technique, the minimal effusion test, is needed to document the (minimal) contribution of the capsule in the presenting symptoms, that is,

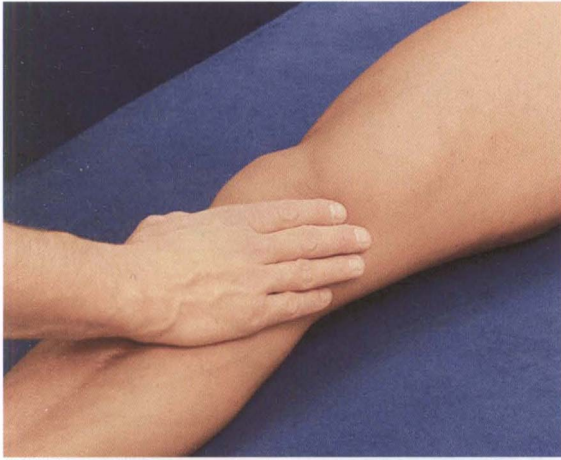

Fig. 6.10 Test for minimal effusions—phase 1.

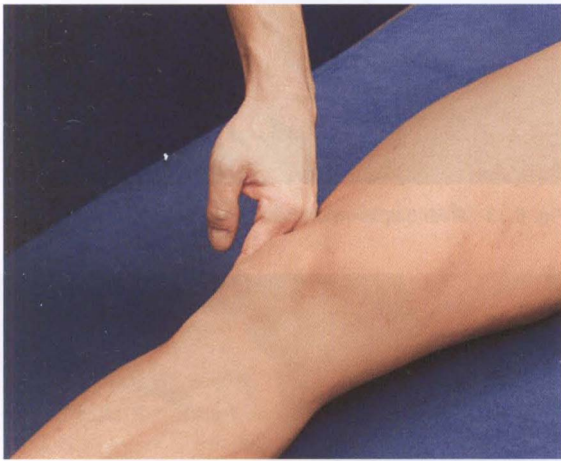


Fig. 6.11 Test for minimal effusions—phase 2.

to identify the presence of “minimal effusion.” Starting position (SP) for the test is full extension of the knee.

Technique

Phase 1

The therapist strokes the medial side of the kneejoint in a proximal and lateral direction. This moves the synovial fluid laterally and into the suprapatellar pouch (Fig. 6.10).

Phase 2

Now, the lateral side of the knee joint is milked in a proximal and medial direction in order to push back the synovial fluid in a medial direction (Fig. 6.11). The therapist simultaneously observes the medial joint space adjacent to the patella, usually taking on a slightly concave shape.

Test Evaluation

When a small joint effusion is present, a small “bulge” is produced during stroking of the lateral aspect in a medial direction, which can be explained as follows:

The milking on the medial side pushes the synovial fluid laterally. The subsequent milking of the lateral side causes the synovial fluid to flow back medially through the joint space.

Palpating an Increase in Temperature

An increase in temperature is also a sign of capsule irritation. The therapist can decide if this is the case by comparing sides and by also comparing the knee with the proximal and distal soft tissues. Obviously, both knees should have the same temperature when normal. However, examination of the joint in relation to its surroundings is of interest. Therapists can assume that a nonpathological joint feels colder than its surroundings, that is, compared with the soft tissues proximally and distally/laterally. Palpation for increased temperature and edema is an integral part of the basic assessment of the knee joint.

Local Palpation—Anterior

Overview of the Structures to be Palpated

- Base of the patella.
- Edges of the patella.
- Apex of the patella.
- Patellar ligament, differentiation.
- Tibial tuberosity.

Summary of the Palpatory Process

Palpation of the anterior aspect locates the borders of the patella and their connection to the tibia (patellar ligament) (Fig. 6.12).

Starting Position

The patient sits in an elevated position, for example, on the edge of a treatment table. The therapist either sits in front of the patient or a little to the side (Fig. 6.13).

When possible, the lower leg should hang freely over the couch and be able to flex freely when the therapist's hand facilitates movement.

This SP ensures that the palpable structures on the anterior, medial, and lateral sides of the knee joint are freely accessible. This SP should only be considerably altered when palpating the posterior aspect of the knee.

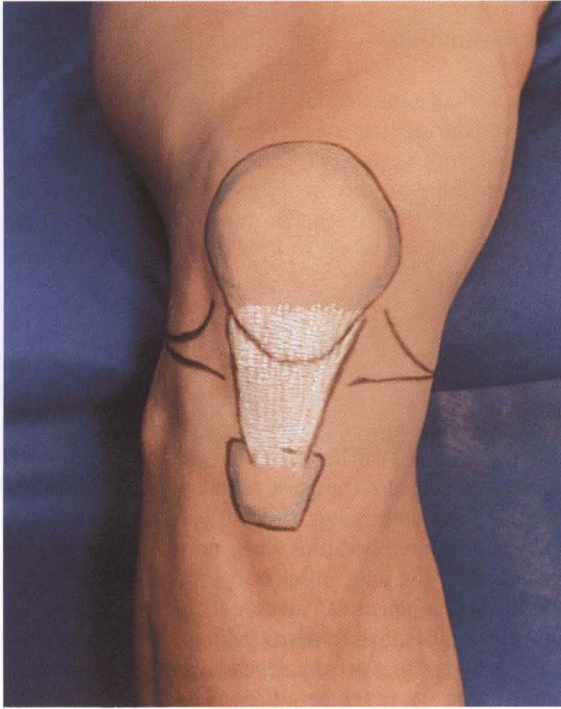


Fig. 6.12 Accessible structures on the anterior aspect.

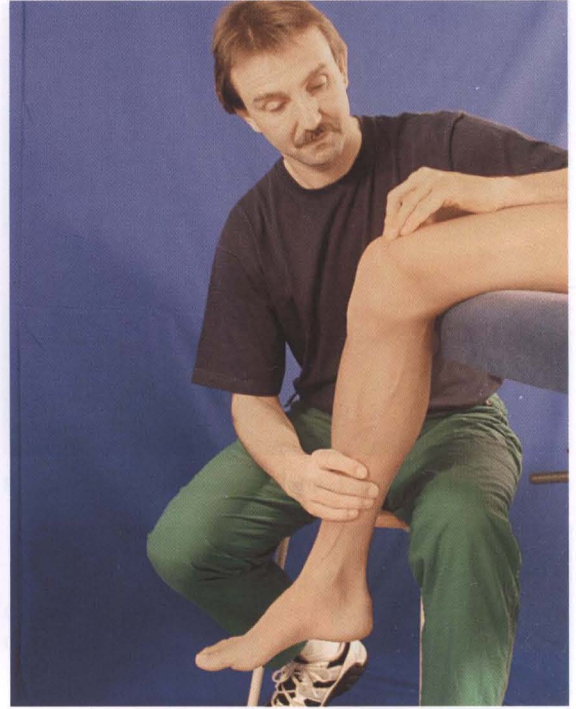


Fig. 6.13 SP for palpation of the anterior aspect.

Alternative Starting Positions

The SPs described above are mainly used when practicing. Other SPs may be necessary in the everyday assessment and treatment of the knee joint. In these cases, therapists may have to approach the knee from a different angle and position the knee with a different amount of flexion.

When the following palpation has been correctly applied to study partners or patients, it should be repeated in its modified forms:

- Full extension.
- Increasing amount of flexion.
- Patient in side-lying position.
- Without visual control.
- On arthritic and/or swollen joints.

When the knee is fully extended it is easier to palpate the base and the poles and more difficult to palpate the apex of the patella and the ligament through the laterally protruding infrapatellar fat pad of Hoffa.

It becomes increasingly difficult to locate all contours with more flexion. Arthritis-related edema and bony deformation alter the expected consistency and contours of the respective structure.

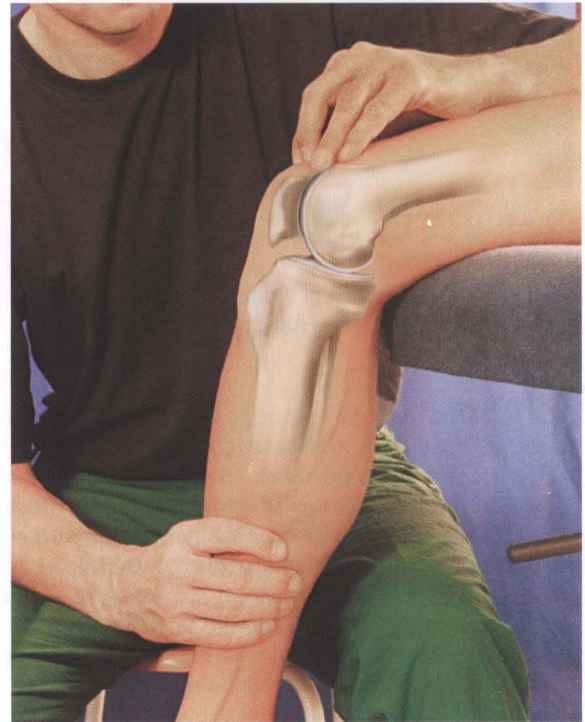


Fig. 6.14 Palpation of the base of the patella.

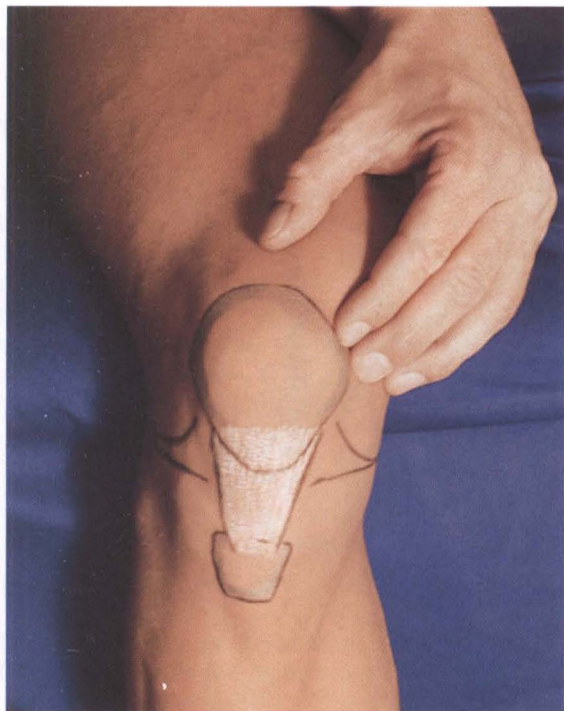


Fig. 6.15 Palpation of the medial pole of the patella.

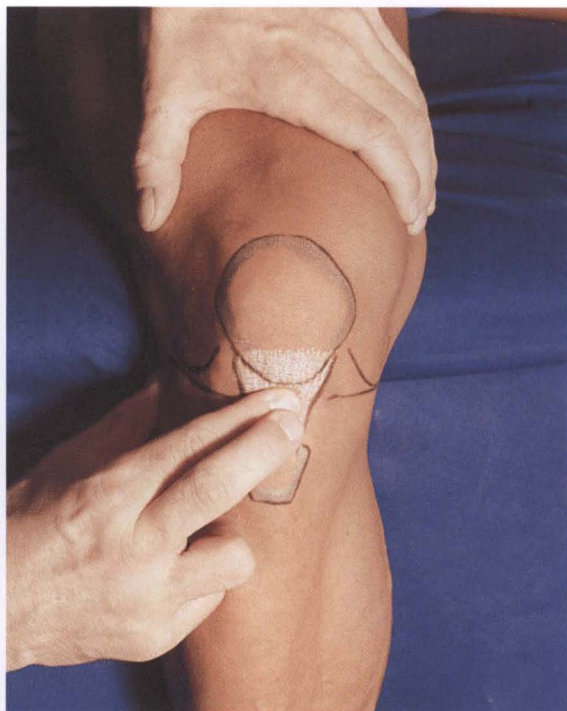


Fig. 6.16 Palpation of the apex of the patella.

Base of the Patella

The therapist starts palpating the edges of the patella at the base. As mentioned in the introduction to the knee joint, the base of the patella is very thick and has an anterior and posterior border.

The anterior border can be easily reached in the extended position. It connects both poles with a curved line.

The posterior edge is the most important border in the flexed position. The palpation aims to identify this edge and differentiate it from the femur and the surrounding soft tissues.

Technique

The base of the patella is parallel to the thigh when the knee is flexed. Its posterior edge is embedded in the soft tissue of the quadriceps femoris and clings to the form of the femoral condyles. Its boundaries can therefore only be palpated when the knee is slightly passively extended and flexed.

The therapist places several fingertips on the thigh approximately 3–4 cm proximal to a line connecting the medial and lateral poles of the patella (Fig. 6.14). The fingertips point distally. The other hand facilitates slight passive knee extension. The patella then automatically moves proximally for a short distance and pushes against the fingertips of the palpating hand.

Tip: The facilitated movement of the lower leg should be minimal and completely passive! Every contraction in the quadriceps makes locating the base of the patella extremely difficult.

Edges of the Patella

The palpation of the borders of the patella now continues onto the apex, past the medial and lateral poles of the patella.

Technique

Compared with the medial side, it is relatively difficult to identify the exact border of the lateral pole of the patella. The knee joint must be moved occasionally to differentiate the pole from the lateral femoral condyle (Fig. 6.15). The previously described perpendicular technique is used for palpation.

Apex of the Patella

The patellar ligament uses the distal third of the patella, including the apex, as proximal area of attachment. This border of the patella can therefore only be reached via the ligament.

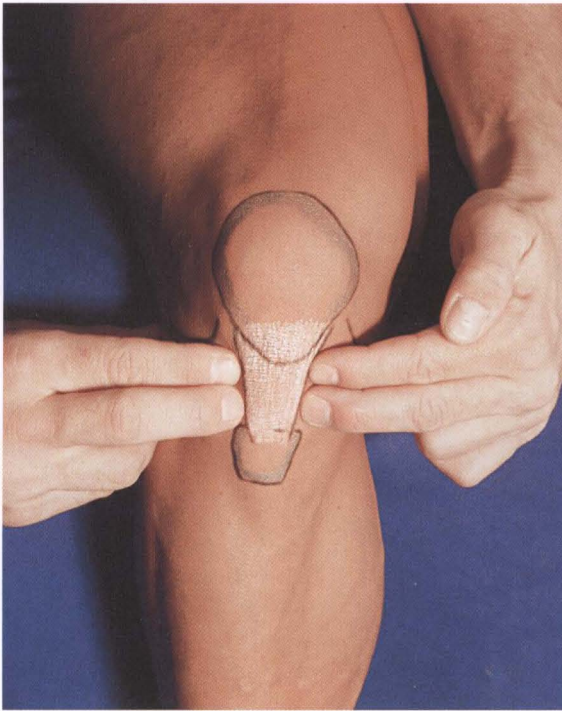


Fig. 6.17 Edges of the patellar ligament.

Technique

The palpating hand approaches the apex using a perpendicular technique once more (**Fig. 6.16**). Firm pressure is initially applied to the patellar ligament. A structure is felt here that has a clear, firm consistency. While maintaining the pressure on the ligament, the palpating fingertips attempt to make contact with the more proximal apex. The consistency of the apex is expected to be hard and the edge distinct.

Pathological conditions are frequently present in these soft tissues, therefore precise localization techniques are of great advantage. The treatment of these conditions will be discussed later in the text.

Tip: The ligament is reasonably tensed in the flexed position. Thus, firm pressure should be applied to the ligament. If it is not possible to differentiate the apex from the ligament, a further attempt is made with the knee in extension.

Patellar Ligament, Differentiation

The patellar ligament's proximal and distal insertion will be differentiated from fixed points on the bones. Its side contours can also be identified and will be subsequently described.

The therapist can approach the edges of the ligament from two directions (**Fig. 6.17**).

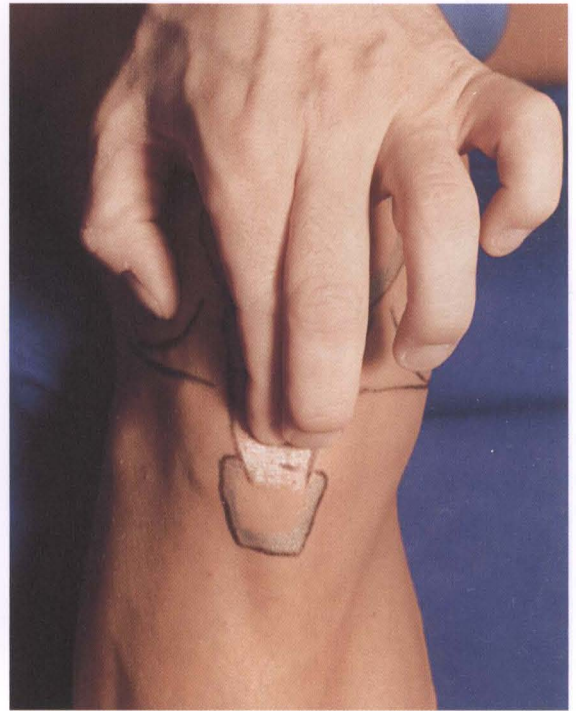


Fig. 6.18 Palpation of the junction between the patellar ligament and the tibial tuberosity.

Technique

Method 1

Starting at the apex, the therapist palpates slightly more distally so that the fingers are directly on top of the ligament. The side borders are then sought from this position.

Method 2

Two shallow indentations are found at the level of the patellar apex in knee joints, which are neither swollen nor arthritic. The anterior knee joint space can be accessed here. Starting at these indentations, the therapist palpates medially and encounters the firm yet somewhat elastic consistency of the patella ligament.

The edges of the ligament can be followed from the patella onto the tibial tuberosity. The palpation reveals that:

- The ligament is very wide.
- It converges and slightly tapers down into the tibial tuberosity.

Tibial Tuberosity

The tuberosity tapers off distally and merges into the anterior border of the tibia. This border can be easily palpated along the entire length of the lower leg. On its medial aspect, the tibia possesses a surface that is adjacent to the medial border of the tibia. A rough area is found on the

lateral and proximal aspects of the tuberosity at the insertion of the iliotibial tract (Gerdy tubercle).

Technique

The patellar ligament is differentiated from the tibial tuberosity using the same technique as for the apex.

A firm structure is felt when direct pressure is applied to the ligament (Fig. 6.18). Significantly stronger resistance is felt when the palpation moves more distally onto the tibial tuberosity.

Tip: Insertion tendinopathies at the distal insertion of the ligament are well known but relatively rare. Bursitis can occasionally present with pressure sensitivity in this region. It can be felt through the fluctuation in fluid in the inflamed bursa.

Tips for Assessment and Treatment

The palpation techniques used for the anterior region of the knee are used in two common assessment and treatment techniques:

- The assessment of mobility and the mobilization of the patellofemoral joint.
- Transverse frictions at the patellar ligament and the apex of the patella.

Techniques at the Patellofemoral Joint

The assessment or restoration of patellar mobility on its femoral articular surface is an important component of postoperative treatment of the knee joint.

In the very early phases of postoperative treatment, this is possible when the knee is almost fully extended. It is easiest to move the patella in all directions in this position as the surrounding structures are most relaxed.

Treatment aims to preserve the elasticity of the capsule and the suprapatellar pouch in particular. Therefore, it is most important to maintain patellar mobility in a distal direction.

If necessary, stretching is used to restore mobility at a later stage of postoperative treatment. This only makes sense when the knee is positioned at maximum flexion. The knee is therefore assessed starting in this position and, when necessary, mobilized (Fig. 6.19).

In vivo anatomy techniques help therapists to locate the base of the patella precisely and to apply handling effectively, even in joints that are still swollen.

Transverse Frictions at the Patellar Ligament

Tendinopathies and insertion tendinopathies of the patellar ligament are prevalent lesions in the soft tissues.

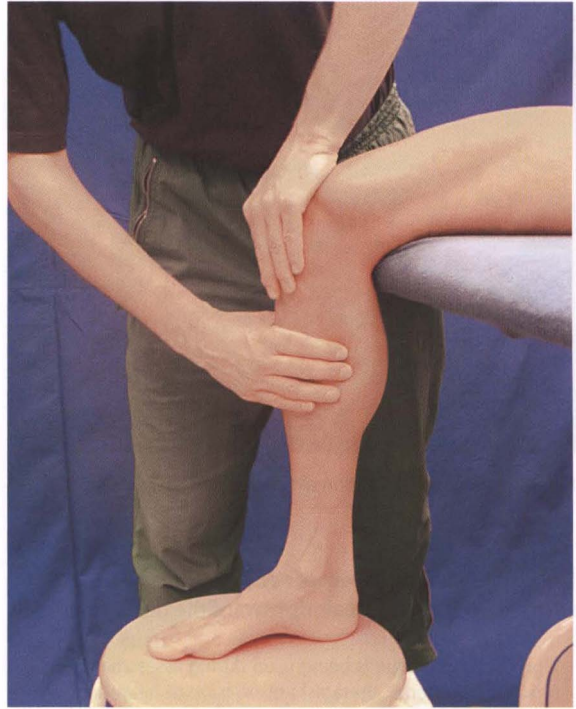


Fig. 6.19 Inferior glide of the patella.

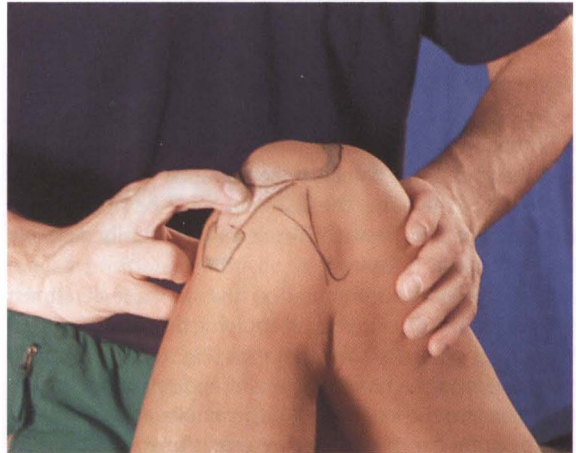


Fig. 6.20 Transverse frictions at the patellar ligament.

Cyriax transverse frictions are used to precisely locate and treat the affected part of this large structure.

If the technique targets the ligament itself, the joint should be positioned so that the ligament does not give way to the pressure of the fingers applying transverse frictions. The therapist should therefore choose to position the knee in flexion to initially place the ligament under tension (Fig. 6.20).

The middle finger is placed on top of the index finger, with the index finger being used again to conduct the technique. The hand is stabilized by the thumb, which

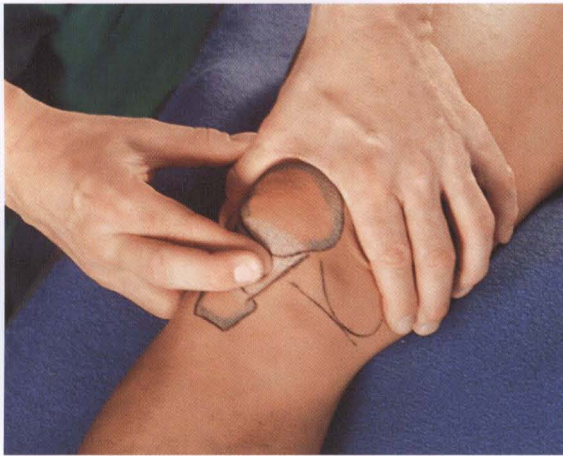


Fig. 6.21 Transverse friction at the apex of the patella.

rests on the lateral aspect of the knee. Pressure is applied to the frictions when moving toward the therapist's body.

Tip: If this technique is being used during assessment to provoke symptoms, therapists often have to be patient and palpate several points before they can find the affected part of the ligament.

Therapists should stand a little proximal to the knee joint to prevent their body obstructing the palpating hand.

Transverse Frictions at the Apex of the Patella

It is not easy to palpate the junction between the ligament and the apex of the patella. If the therapist wishes to reach the edge of the bone, the ligament must be first pushed deeper into the tissues. This is only partially possible when the joint is flexed.

It is therefore recommended that the knee be almost fully extended. The finger pad applying the transverse frictions now points toward the apex (Fig. 6.21). Sustained pressure is applied to the ligament and several points on the apex and the side edges of the patella are palpated.

The other hand stabilizes the patella proximally to prevent it moving to the side. It is also possible to apply slightly more pressure to the base of the patella so that the apex tilts upward and is easier to access.

Local Palpation—Medial

Overview of the Structures to be Palpated

- Boundaries of the joint space.
- Medial epicondyle of the femur.
- Adductor tubercle and the tendon of the adductor magnus.
- Saphenous nerve.
- Medial collateral ligament.
- Pes anserinus muscle group.

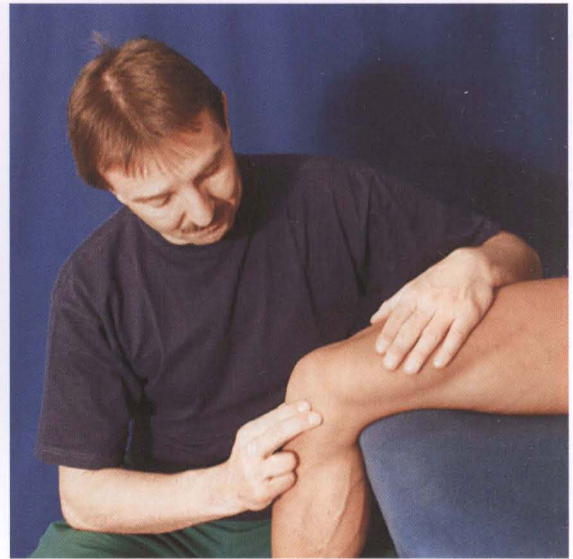

Fig. 6.22 SP for palpation of the medial aspect.

Summary of the Palpatory Process

Now that the therapist has finished palpating the anterior aspect of the knee, the side regions of the knee joint will next be discussed. A reliable point will be sought on the medial side to access the joint space. The articulating bones will be followed, if possible, from the anterior side of the knee to the posterior side.

Starting Position

The patient sits in an elevated position, for example on the edge of a treatment table. The therapist sits a little to the side, in front of the patient (Fig. 6.22).

When possible, the lower leg should hang freely over the table and be able to flex sufficiently when the therapist's hand facilitates movement. This SP guarantees free access to the palpable structures on the medial side of the knee joint.

Alternative Starting Positions

The SPs described above are mainly used when practicing. Other SPs may be necessary in the everyday assessment and treatment of the knee joint. In these cases, therapists may have to approach the knee from a different angle and position the knee with a different amount of flexion.

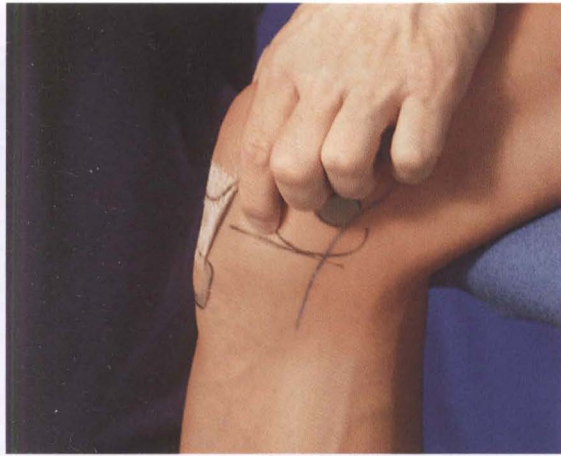


Fig. 6.23 Palpation of the edge of the tibia.

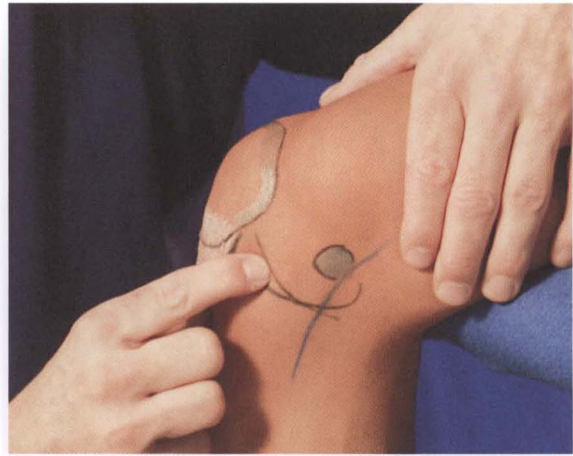


Fig. 6.24 Palpation of the medial condyle of the femur.

Boundaries of the Joint Space

The medial femoral condyle and the medial tibial plateau form the boundaries for the joint space. With some practice, it is possible to follow the joint space posteromedially for quite a distance until reaching the soft tissues of the pes anserinus muscles.

The edge of the tibial plateau is generally used to describe the spatial alignment of the joint space. A perpendicular technique is used to systematically palpate the bony structures.

Two dimples, or at least two areas, that are soft to touch are always found medially and laterally at the level of the apex of the patella. These are the most reliable points to access the articulating bones.

This correlation remains the same, regardless of the amount of knee flexion. It is only at end-range extension that the infrapatellar fat pad of Hoffa protrudes medially and laterally to the patellar tendon, making localization more difficult.

Technique

Tibial Plateau

If the therapist wishes to precisely palpate the edge of the tibial plateau, one hand comes from a proximal direction and palpates using a perpendicular technique while the other hand controls the lower leg. (Fig. 6.23)

The palpating finger pads are placed in the dimple medial to the apex of the patella. The fingertip pushes distally against the hard resistance of the edge of the tibia.

The tibial plateau can be followed posteriorly from this point onward for quite a distance when using this technique.

The palpation is expected to follow a straight line and tilt down in a slightly inferior direction on the posterior side of the knee.

Tip: It will become harder to discern the edge of the tibia when palpating more posteriorly due to the presence of the medial collateral ligament. To increase confidence, the palpation can be confirmed by moving the lower leg:

- This is achieved more anteriorly on the tibia by passively extending the knee slightly so that the tibia pushes against the palpating fingertip.
- Extensive rotation is suitable to confirm the palpation further posteriorly.

Medial Condyle of the Femur

The palpating hand now comes from a distal position and is again positioned in the depression medial to the apex of the patella. The fingertip pushes down into the depression and attempts to reach the superior bony structure (Fig. 6.24). The hard resistance felt is the cartilage coating of the articular surface of the medial condyle. If the therapist slides a little more proximally from here, another edge will be reached that corresponds to the cartilage–bone border of the condyle.

Starting at the first point of hard contact, the femoral condyle is palpated further posteriorly. The palpation must follow the shape of the femoral condyle, which is expected to form a convex line (Figs. 6.25 and 6.26).

As was the case when palpating the edge of the tibial plateau, it is hard to discern the edge of the femur for approximately 3–4 cm. The medial collateral ligament again hinders direct access here.

Tip: Occasionally it seems more appropriate to position the finger perpendicular to the surface of the knee and use the fingernail to palpate. The bony edge is then more distinct.

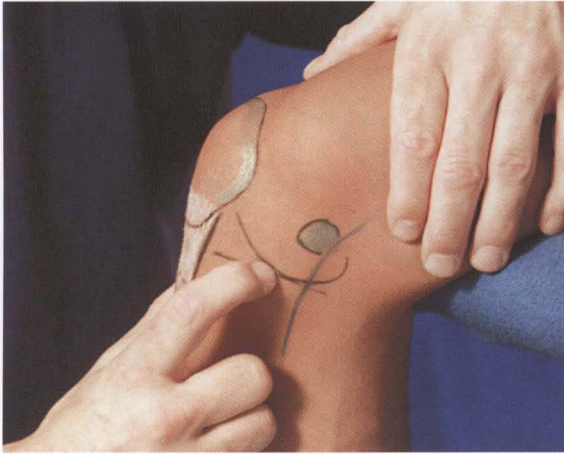


Fig. 6.25 Following the edge of the femoral condyle posteriorly.

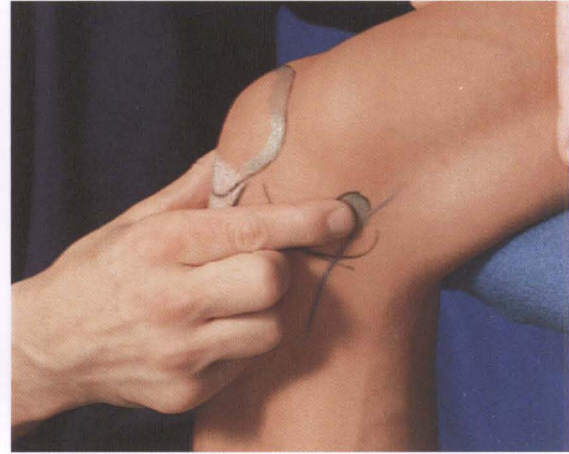


Fig. 6.27 Palpation of the medial epicondyle.

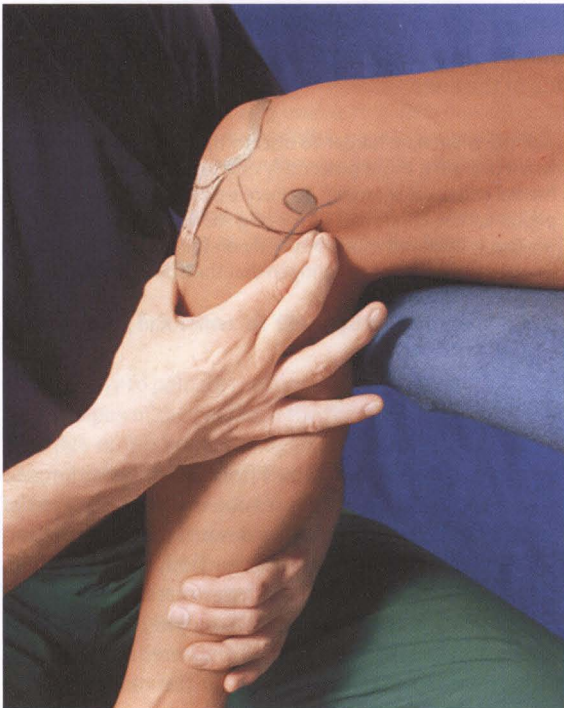


Fig. 6.26 Palpation of the posterior aspect of the femoral condyle.

The finger encounters several soft structures further posteriorly. These are the muscles that are attached proximally to the pes anserinus.

Tip: The joint space can be followed further posteriorly when the therapist lifts the lower leg, so that the thigh muscles hang down.

The palpating finger can reach the femoral condyle more easily again on the posterior aspect.

Medial Epicondyle of the Femur

This structure is used for orientation when identifying the position of the medial collateral ligament.

Technique

The medial epicondyle is a largely protruding structure that can be easily found once the medial aspect of the distal thigh has been located. Several finger pads are positioned flat over this region and palpate gently with a circling movement (Fig. 6.27). The most prominent elevation is the medial epicondyle.

Adductor Tubercle and the Tendon of Adductor Magnus

The bony region around the medial epicondyle is quite large. The tendon belonging to part of the adductor magnus comes from a proximal position and inserts proximal to the epicondyle. Its site of insertion is quite prominent and is labeled the adductor tubercle in the literature.

Technique

Adductor Tubercle

To locate this structure, the therapist places a flattened hand on the inner side of the thigh, applies moderate pressure, and strokes in a distal direction. The first bony structure that is encountered is the tubercle that the therapist is looking for. A local technique is used to determine the exact dimensions of this elevation.

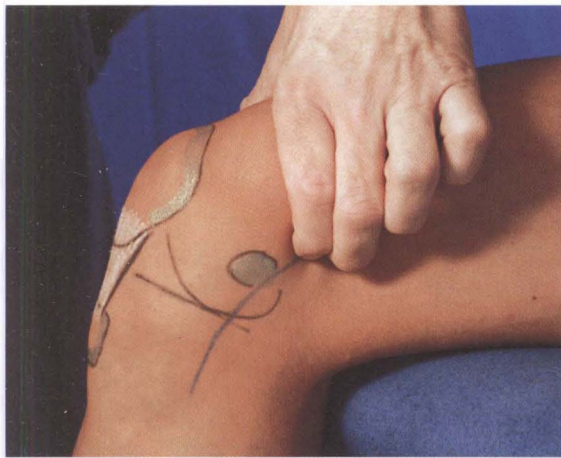


Fig. 6.28 Palpation of the adductor magnus tendon.

Adductor Magnus Tendon

This tendon is found directly proximal to the tubercle and can be clearly felt using transverse palpation (**Fig. 6.28**).

Tip: If the pes anserinus muscles impede palpation, the thigh can be lifted so that the muscles hang down (**Fig. 6.29**).

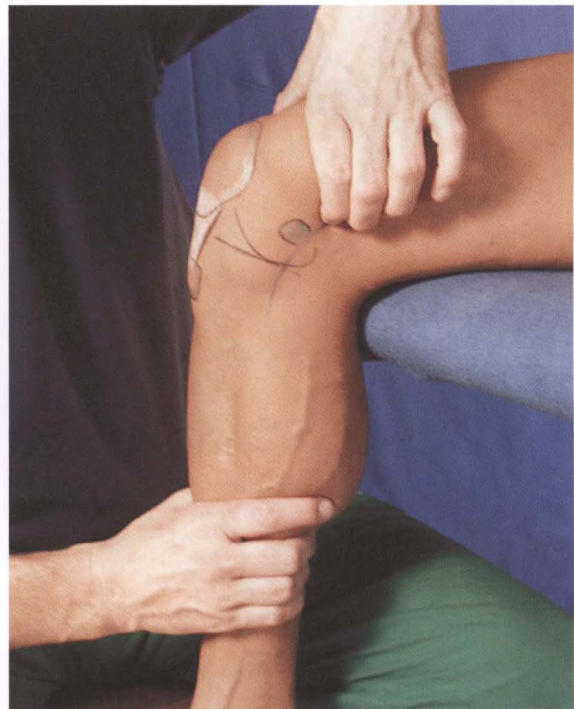


Fig. 6.29 Palpation after raising the thigh.

Saphenous Nerve

The most important neural structures pass over the knee on its posterior aspect. Only one large branch of the femoral nerve crosses over the medial side of the joint: the saphenous nerve. Its position varies greatly (Lanz and Wachsmuth, 2004d). The illustrated position is therefore only an example demonstrating the anatomy of this individual.

Technique

A very special technique is needed to palpate neural structures. The therapist attempts to hook around the nerve and pluck it, as if plucking a loose guitar string. In this technique, the therapist tries to find the thin structure by first positioning the finger flat over the skin and then positioning the fingertip almost vertically on the skin (**Fig. 6.30**). It is extremely difficult to locate this structure.

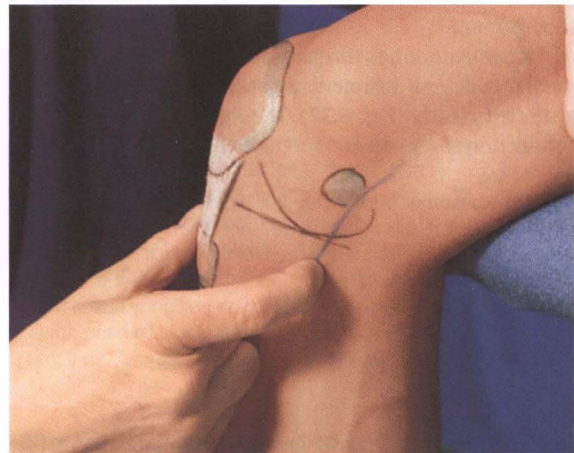


Fig. 6.30 Palpation of the saphenous nerve.

Medial Collateral Ligament

The medial collateral ligament made it difficult to follow the edges of bone when identifying bony structures. The entire ligament should now be identified as well as possible. The femoral point of fixation, the medial epicondyle, has already been identified. The side borders and the tibial point of fixation are still missing.

Technique

The palpating finger pads apply significant pressure to the depression medial to the apex of the patella. The fingertip is now positioned horizontally, aligned with the joint space.

When the therapist palpates along the edge of the tibia, the palpating finger is soon pushed out of the tissues by a flat structure that is very firm and occasionally possesses a sharp edge. This structure makes it difficult to palpate the borders of the joint space.

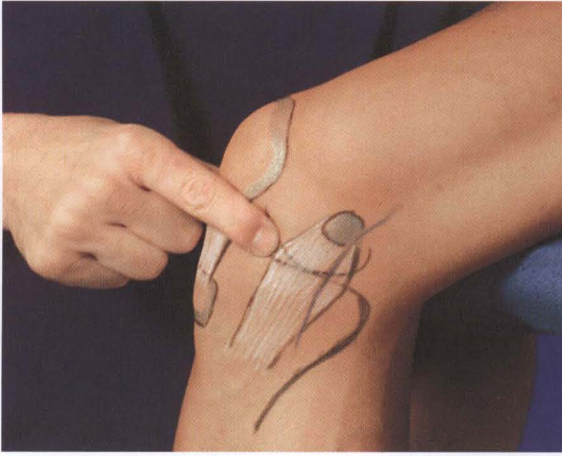


Fig. 6.31 Palpation of the medial collateral ligament, anterior edge.

This edge corresponds to the anterior border of the medial collateral ligament (**Fig. 6.31**). It is approximately 3–4 cm wide at the knee joint space. In principle, as long as the joint space cannot be clearly palpated, the collateral ligament is reinforcing the capsule. In slender patients, it is possible to palpate the superficial part of the ligament as a narrow and extremely distinct structure in the middle of the ligament.

The palpation has reached the posterior border of the medial collateral ligament when the joint space can be again felt clearly (**Fig. 6.32**). The ligament has its closest connection to the medial meniscus in this area.

Tip: The posterior border can only be located by concluding that the ligament is no longer present when the articulating femur and tibia can be felt without interference from another structure. To palpate the joint space, the therapist should push on the lower leg so that the thigh is slightly raised from the treatment table and the muscles are able to hang down (**Fig. 6.33**).

To identify the entire dimensions of this ligament, the therapist draws a line between its borders at the level of the joint space and the medial epicondyle. Its further course is illustrated by visualizing that the ligament extends approximately 8 cm further distally and anteriorly from the joint space. It merges into the periosteum on the medial surface of the tibia underneath the pes anserinus. This information has been gained from anatomical specimens and transferred onto living subjects here.

When the therapist considers the entire course of the ligament as it extends distally and anteriorly and the ligament's mass of collagen that reinforces the capsule, it is easy to understand that this ligament is also the primary decelerator for lateral rotation of the joint.

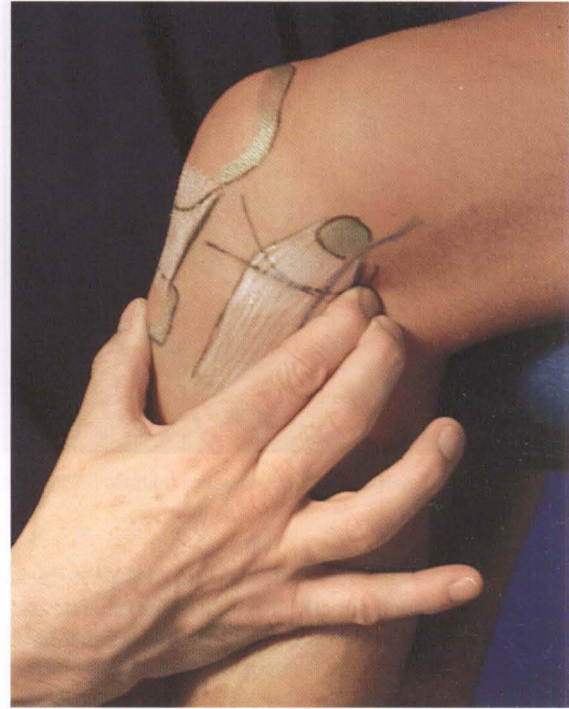


Fig. 6.32 Palpation of the posterior border.

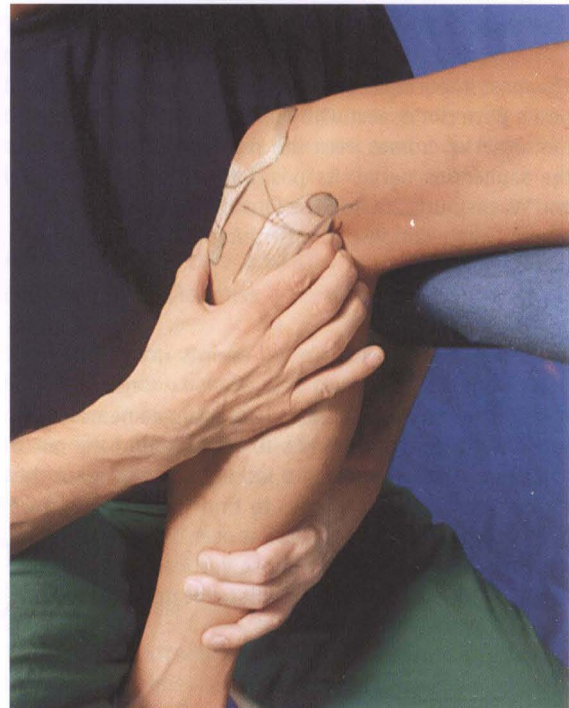


Fig. 6.33 Palpation of the posterior border after raising the thigh.

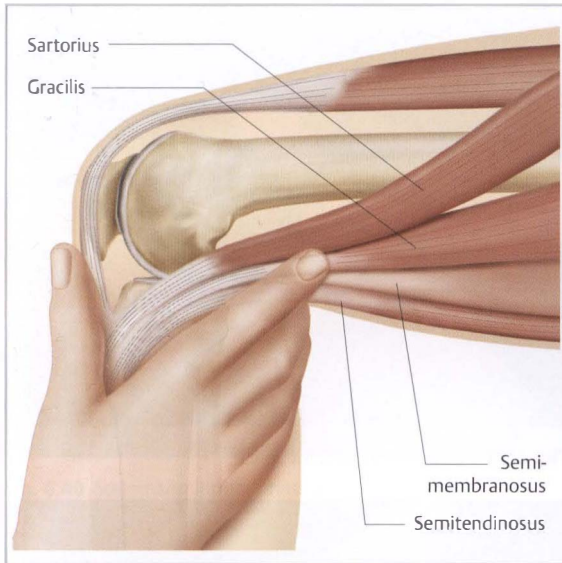


Fig. 6.34 Illustration of the area of insertion for the pes anserinus muscles.

Pes Anserinus Muscle Group

The structures that have previously interfered with the localization of structures near the joint will now be identified. This incorporates the group of muscles attached to the pes anserinus. The individual muscles are listed here from anterior to posterior:

- Sartorius.
- Gracilis.
- Semimembranosus.
- Semitendinosus.

Technique

Area of Insertion

It is impossible to differentiate the tendons from one another in the area of the pes anserinus when palpating locally and when examining anatomical specimens. The therapist can only identify the inferior border of the area of insertion.

The palpating hand is positioned flat over the medial aspect of the lower leg; the thumb is on the anterior edge of the tibia. When the therapist strokes over the leg from distal to proximal, the finger will first feel the more convex form of the gastrocnemius followed by a shallow concavity. The inferior border of the pes anserinus has been found once the finger feels a slightly convex area again (**Fig. 6.34**).

Differentiation of Muscles

The individual muscles can be differentiated from one another proximal to the knee joint; this is best achieved pos-

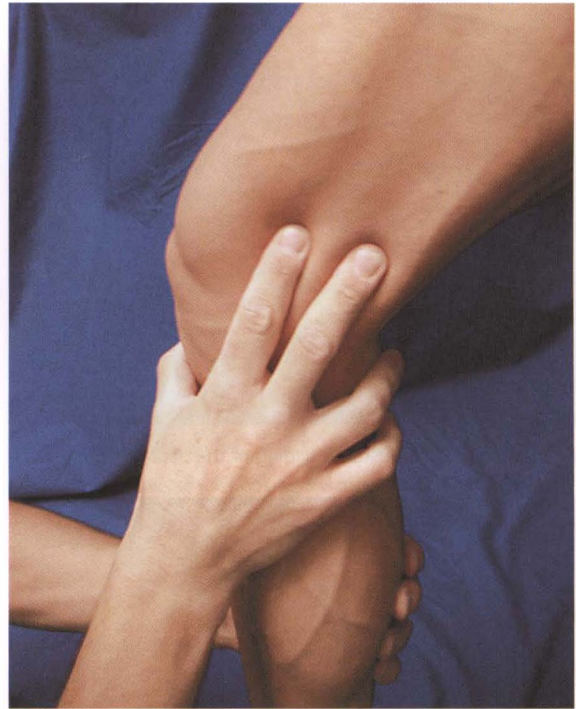


Fig. 6.35 Differentiation proximal to the knee joint.

terior to the vastus medialis (**Fig. 6.35**). Knee flexion causes the muscles to contract as a group. If necessary, medial rotation of the knee can also be used.

Tip: The individual muscles can be located by using their selective actions at the other joint, the hip joint.

The therapist can then locate:

- The sartorius using additional active hip flexion.
- The gracilis using additional active hip adduction.
- The semitendinosus using additional active hip extension.

Tips for Assessment and Treatment

Why Do Therapists Need to Locate the Joint Space?

As already mentioned, the edge of the tibial plateau is used to determine the spatial alignment of the joint space. This is very important for orientation when using translational manual therapy techniques. The joint space is not completely perpendicular to the longitudinal axis of the tibia. Instead, it tilts down distally by approximately 10°.

The illustrated examples demonstrate why identification of the joint space is necessary to glide the tibia posteriorly. This technique is used to produce the necessary amount of translation to allow the knee to flex freely (**Figs. 6.36** and **6.37**).

Regardless of whether the joint is positioned in approximately 100° flexion or at end of range, the therapist

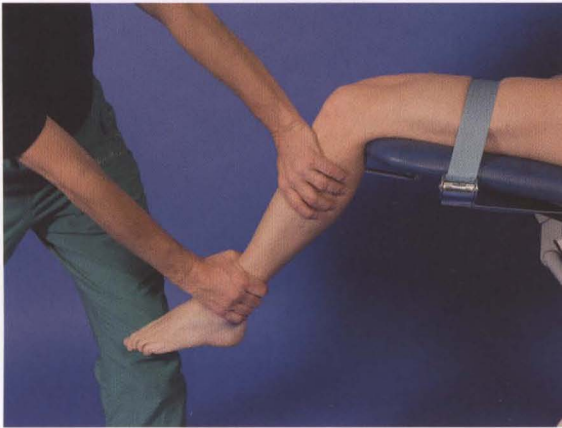


Fig. 6.36 Anterior–posterior gliding of the tibia on the femur.

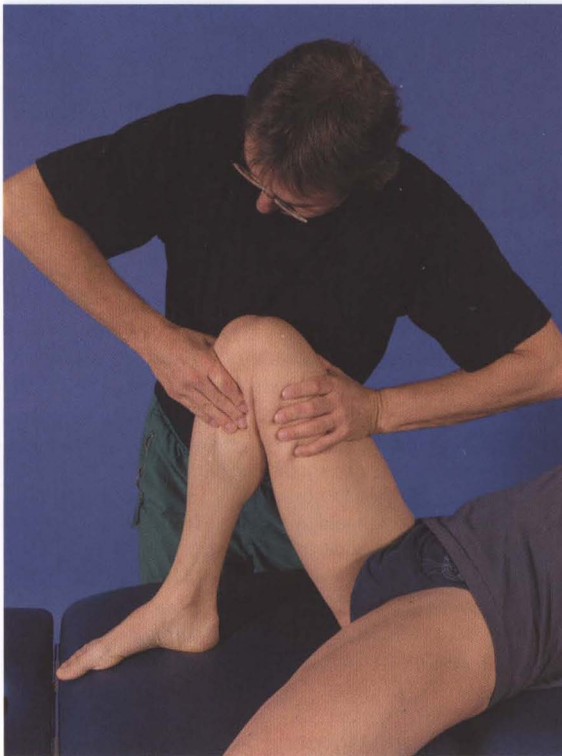


Fig. 6.37 Gliding with the knee prepositioned at end of range.

must pay attention to the exact spatial alignment of the joint.

Which Structures Can Be Palpated in the Joint Space?

The medial meniscus moves posteriorly on the tibial plateau during knee flexion and anteriorly during knee extension. The anterior horn can be palpated in the joint space next to the apex of the patella when the knee is fully extended.

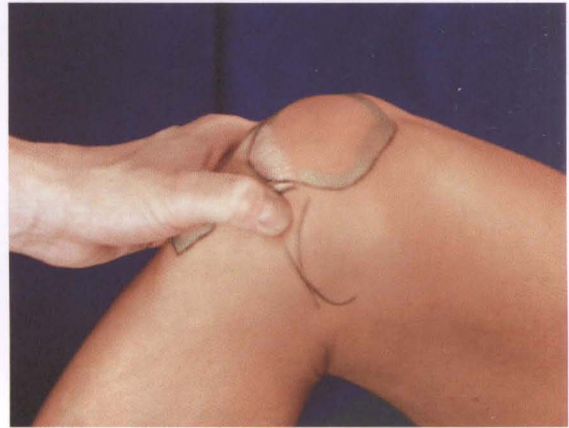


Fig. 6.38 Palpation of the joint space.

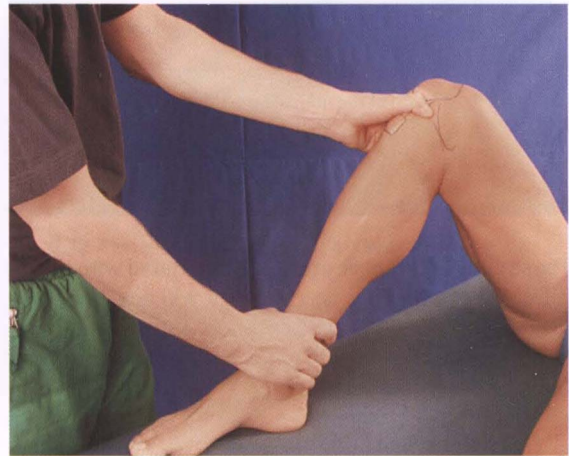


Fig. 6.39 Steinmann II sign, phase 1.

The Steinmann II sign is a provocative test for pain in the anterior horn of the meniscus.

To conduct this test, the knee joint is first positioned in moderate flexion. The thumb of the testing hand applies significant pressure to the joint space adjacent to the apex of the patella (phase 1, Figs. 6.38 and 6.39).

The knee joint is then slowly moved out of flexion and into full extension (phase 2, Fig. 6.40). The meniscus glides anteriorly on the tibia during this movement and pushes against the thumb positioned in the joint space. This test is painful if a lesion of the anterior horn of the meniscus is present.

Can Other Structures Be Palpated in the Joint Space?

The indentation adjacent to the apex of the patella is not only the starting point for locating the articulating surfaces of the femur and tibia; it is also the starting point for the palpation of the medial collateral ligament. Other

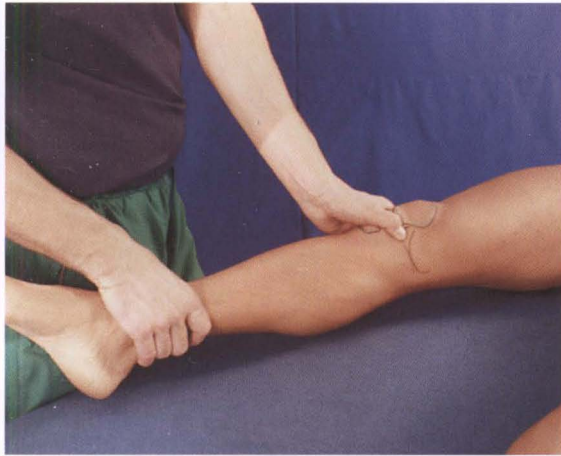

Fig. 6.40 Steinmann II sign, phase 2.

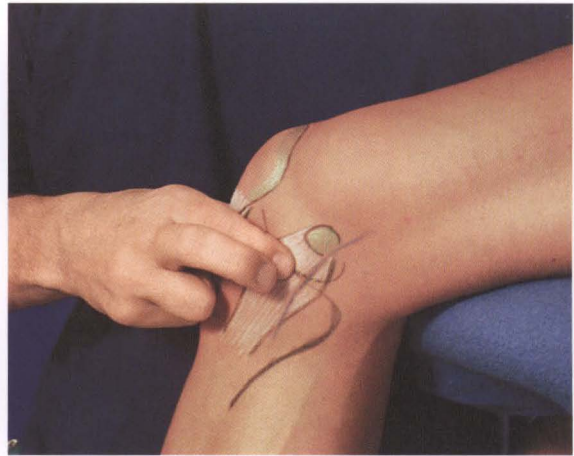


Fig. 6.42 Transverse frictions at the medial collateral ligament.

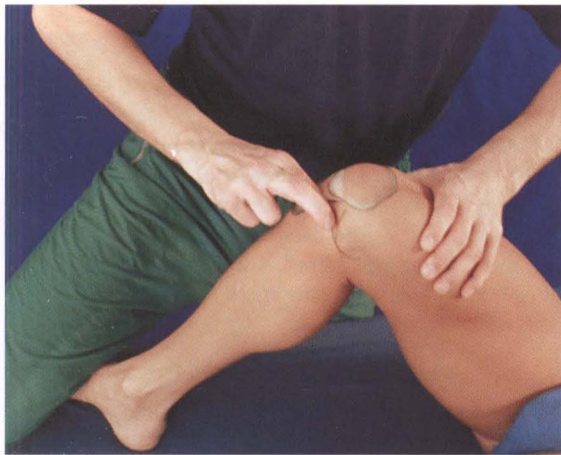


Fig. 6.41 Transverse frictions at the meniscotibial ligaments.

ligaments can also be palpated. The “coronary ligaments” or meniscotibial ligaments often cause symptoms in the anteromedial knee.

These ligaments are reached using a transverse frictions technique. The palpating index finger is placed over the familiar indentation next to the apex of the patella so that the finger pad faces distally toward the tibial plateau. To facilitate access to the tibial plateau, the knee is positioned in lateral rotation so that the plateau protrudes more.

The finger administers transverse frictions by applying pressure (onto the tibia) from the medial side of the knee toward the apex of the patella (Fig. 6.41). This technique can be used for both the provocation of pain in affected structures as well as for treatment.

Transverse Frictions at the Medial Collateral Ligament

The medial ligament is frequently injured. Experience shows that most of the lesions along the 12-cm-long ligament occur at the level of the joint space.

The therapist uses the previously described technique for localization of the anterior edge of the ligament to precisely identify the affected part of the ligament. This ensures that the therapist is palpating at the level of the joint space. Transverse frictions are then applied at 5-mm intervals in a posterior direction over the entire width of the ligament (Fig. 6.42).

The diagnostically conclusive pressure is applied during the transverse frictions toward the patella.

Local Palpation—Lateral

Overview of the Structures to be Palpated (Fig. 6.43)

- Boundaries of the joint space (1).
- Iliotibial tract (2).
- Gerdy tubercle (3).
- Lateral epicondyle of the femur (4).
- Head of the fibula (5).
- Lateral collateral ligament (6).
- Biceps femoris (7).
- Common peroneal nerve (8).

Summary of the Palpatory Process

Most of the procedure is identical to the one on the medial side. Initially, a reliable point will be sought on the lateral side to access the joint space. The articulating bones are followed from the anterior side of the joint onto the posterior side. Structures that cross over the joint space will be identified and named.

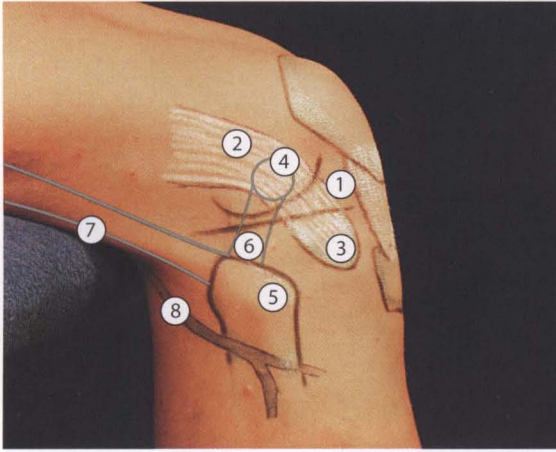


Fig. 6.43 Structures on the lateral aspect of the knee joint.

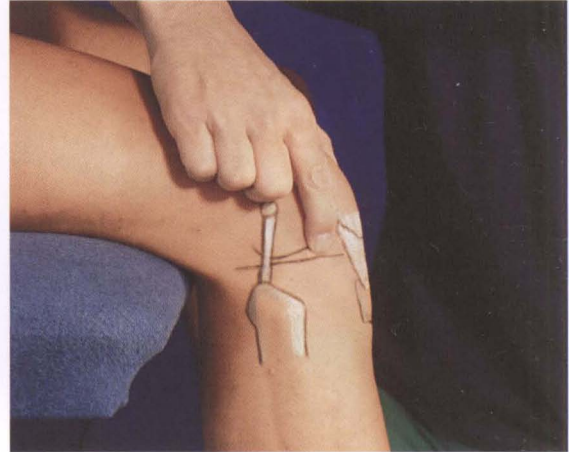


Fig. 6.45 Palpation of the edge of the tibia.

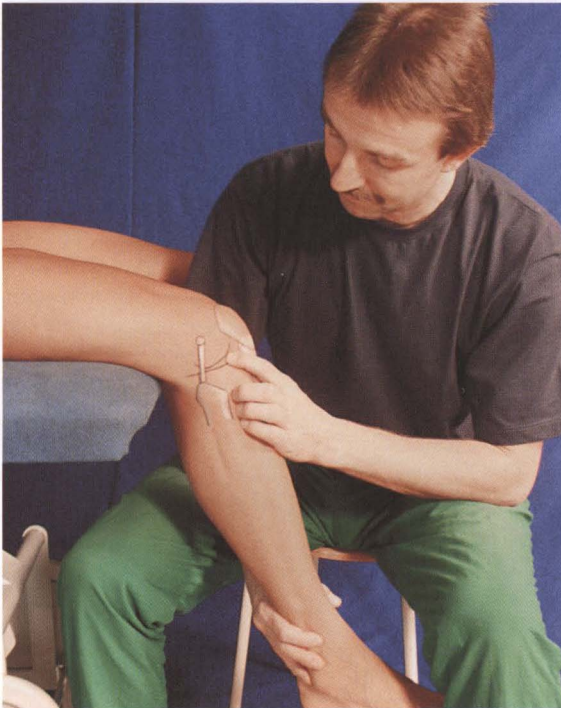

Fig. 6.44 SP for palpation of the lateral aspect.

Starting Position

An SP is again selected with the patient sitting high up, for example, on the edge of a treatment table. The therapist sits a little to the medial side, but still in front of the patient.

When possible, the lower leg should hang freely over the table and be able to flex extensively when the therapist's hand facilitates movement (Fig. 6.44). This SP guarantees free access to the palpable structures on the lateral side of the knee joint.

Alternative Starting Positions

The SPs described above are mainly used when practicing. Assessment and treatment techniques often force therapists to use other angles of knee flexion in their everyday work with the lateral side of the knee joint. Once the following structures have been located in the practice SP, palpation should therefore be repeated in the SPs used in the daily work with patients to consolidate palpatory skills.

Boundaries of the Joint Space

The procedure and techniques applied here correspond to those in medial palpation. Therapists need to reorient themselves on the apex of the patella to easily reach the joint space. This is bordered by the lateral femoral condyle and the lateral side of the tibial plateau.

Technique

Tibial Plateau

The hand coming from the proximal direction uses a perpendicular technique to palpate the edge of the tibia precisely. The other hand is used to control the lower leg.

The palpating finger pads are placed in the dimple medial to the apex of the patella. The fingertip pushes distally against the firm resistance of the edge of the tibial plateau (Fig. 6.45).

From here, the tibial plateau can be followed posteriorly for quite a distance using this technique. Again, the palpation is expected to follow a straight line and tilt down in a slightly inferior direction at the posterior side of the knee.

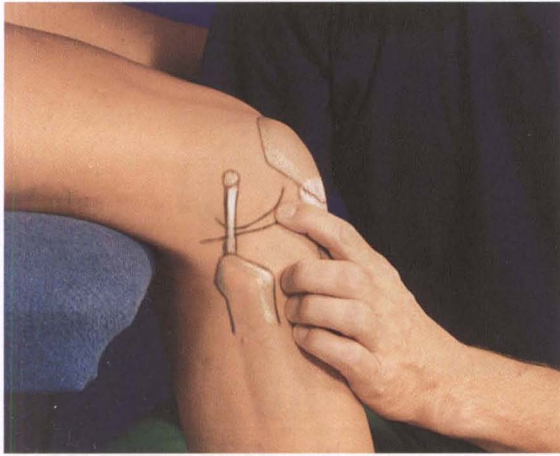


Fig. 6.46 Palpation of the anterior aspect of the femoral condyle.

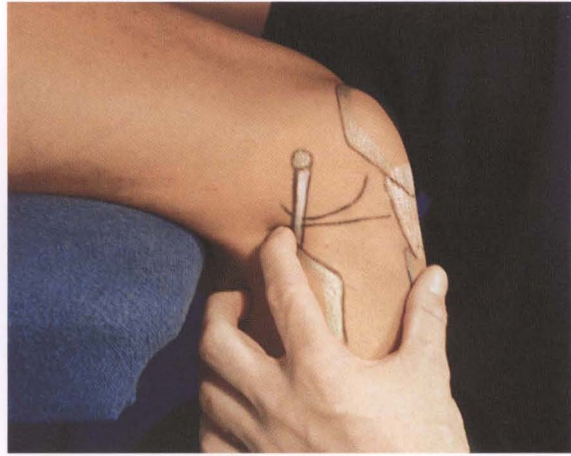


Fig. 6.48 Palpation of the posterior aspect of the femoral condyle.

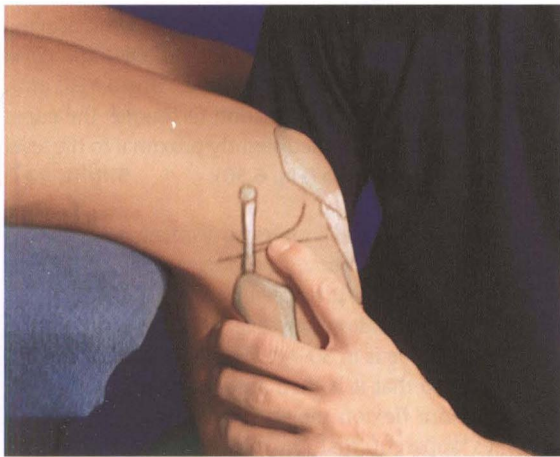


Fig. 6.47 Palpation of the lateral femoral condyle.

Tip: It will not be as easy to discern the edge of the tibial plateau more posteriorly due to the presence of the two soft-tissue structures. To improve the reliability of the palpation, the therapist can confirm the localization by moving the lower leg. Slight passive extension and extensive rotation of the joint are ideal for this.

Lateral Femoral Condyle

The palpating hand now comes from a distal position and is again placed in the depression lateral to the apex of the patella. The fingertip pushes down into the depression and attempts to reach the superior bony structure (Fig. 6.46). The firm resistance felt is the cartilage coating of the articular surface of the lateral condyle. If the therapist slides slightly more proximally, another edge will be reached that corresponds to the boundary between the cartilage and the bone of the condyle.

Starting at the first point of hard contact, the femoral condyle is palpated further posteriorly (Fig. 6.47). The pal-

pation must follow the shape of the femoral condyle and is expected to have the form of a convex line (Fig. 6.48).

Tip: The therapist should expect to feel a convex line that marks the contours of the femoral condyle and can assume that this will be more curved on the lateral than on the medial side.

It is generally easier to feel the bony borders of the joint space on the lateral side than on the medial side. If it should still be difficult to palpate the borders, the therapist can position the finger vertically and palpate with the fingernail. This makes it easier to feel the edge of the bone.

Soft tissues do not obstruct palpation of the posterior section of the joint space on the lateral side. Therefore, it is not necessary to raise the leg to allow the muscles to hang down.

Iliotibial Tract

The iliotibial tract is a flat, wide, firm-elastic structure when it crosses over the knee joint. It inserts immediately distal to the joint space on a roughened area.

The tract crosses over the joint space at the same position as the medial collateral ligament on the medial side. It is not as impressive as the ligament though, as it is narrower and not as firm. The anterior edge of the tract is also not as sharp as in the medial collateral ligament.

Technique

At the Joint Space

The palpating finger pads apply firm pressure to the depression lateral to the apex of the patella. The fingertip is now positioned horizontally, aligned with the joint space (Fig. 6.49).

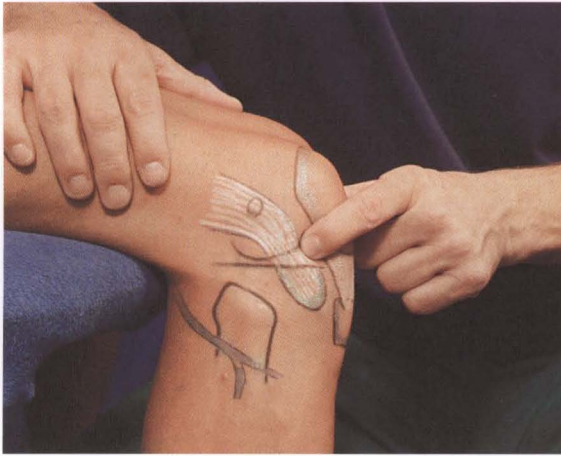


Fig. 6.49 Palpation of the iliotibial tract—anterior edge.

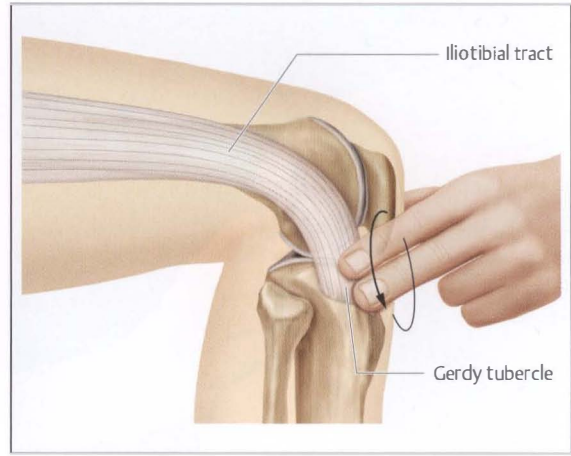


Fig. 6.51 Palpation of the Gerdy tubercle.

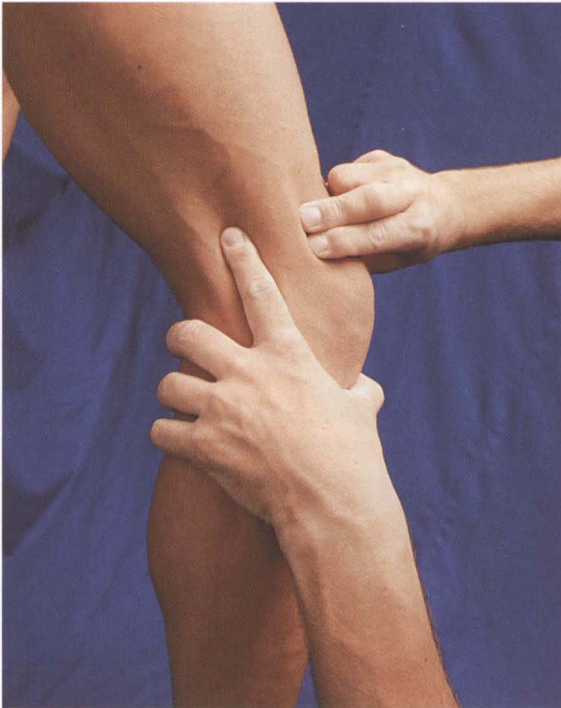

Fig. 6.50 Differentiation proximal to the knee joint.

When the therapist palpates laterally over the femoral and tibial condyles, the fingers are soon pushed superficially out of the joint space again.

Proximal to the Knee Joint

The entire width of the tract can be located when this collagenous structure is tensed by the strong contraction of muscles. The vastus lateralis and tensor fasciae latae contract here.

With the knee in slight flexion, the patient is instructed to isometrically contract the quadriceps. The hip is also flexed, abducted, and medially rotated.

Using a perpendicular palpation technique, the edges of the tract can be identified slightly proximal to the level of the base of the patella (Fig. 6.50).

Note

- The tract is found directly over the lateral epicondyle when the knee is in 30–40° flexion. Less flexion shifts the tract so that it is then anterior to the epicondyle, while more flexion moves it posteriorly. It now becomes apparent that the iliotibial tract must slide over the epicondyle during the gait cycle. This can occasionally cause symptoms.
- A significant number of tract fibers extend down to the lateral edge of the patella and insert slightly distal to the vastus lateralis tendon.

Gerdy Tubercle

The iliotibial tract's main insertion has many names. It is generally referred to as the "Gerdy tubercle." Other terms used in the literature include lateral condyle of the tibia and lateral tibial condyle.

Technique

It is usually easy to locate this area of roughness and its borders by again using several flattened fingers to stroke over the anterolateral side of the tibia slightly inferior to the joint space (Fig. 6.51). This elevation is palpated as a semicircular structure directly inferior to the edge of the tibial plateau.

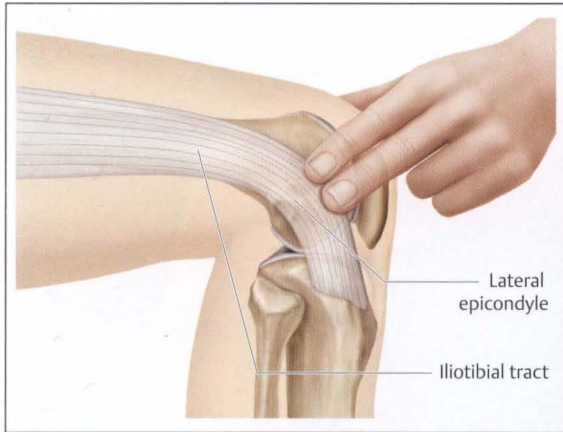


Fig. 6.52 Palpation of the lateral epicondyle of the femur.

Lateral Epicondyle of the Femur

This structure is significantly less prominent yet easier to find than its medial counterpart.

Technique

The same palpatory procedure is used here as for the medial side. This region is palpated by placing several finger pads flat over the region and applying gentle pressure. The most prominent elevation is the lateral epicondyle (Fig. 6.52).

Tip:

- This structure can be used as a point of orientation when searching for the lateral collateral ligament.
- The tendinous insertion of the popliteus can be felt from the epicondyle by palpating approximately 0.5 cm distal to the tip of the epicondyle and then 0.5 cm anterior. The tendon inserts between the collateral ligament and the capsule and can only rarely be differentiated from the neighboring structures. Localization is therefore confirmed by instructing the patient to rhythmically flex and extend the knee slightly. A contraction is felt underneath the palpating finger. However, this localization can be categorized as rather difficult.

Head of the Fibula

The next stage of the palpation of the lateral knee joint encompasses the entire dimensions of the head of the fibula.

Technique

The localization of the posterolateral tibial plateau can usually be palpated without problems by initially using the flattened finger pads. The anterior, proximal, and pos-

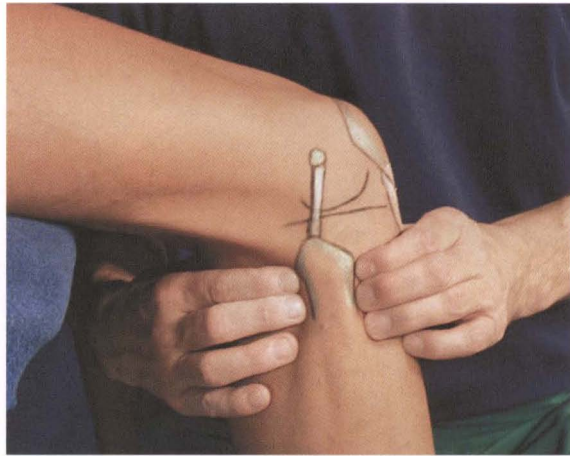


Fig. 6.53 Borders of the head of the fibula.

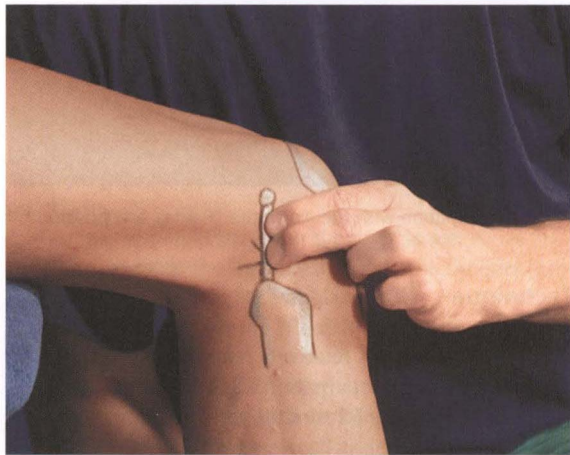


Fig. 6.54 Palpation of the lateral collateral ligament.

terior contours of the head of the fibula are identified next. Again, a perpendicular palpation technique is used. Therapists will be surprised by how large the head of the fibula is when they locate it for the first time (Fig. 6.53).

It also becomes apparent that the head of the fibula has a tip that varies greatly between individuals and marks the lateral collateral ligament as well as the large portion of the biceps tendon.

Tip: If it is still difficult to locate this structure and palpate it in its entirety, the prominent tendon of the biceps femoris can be followed distally onto the tip of the head of the fibula (see the "Biceps Femoris" section below, p. 142).

Lateral Collateral Ligament

The therapist can mark the course and dimensions of the lateral collateral ligament by drawing a line between the lateral epicondyle and the head of the fibula (Fig. 6.54).

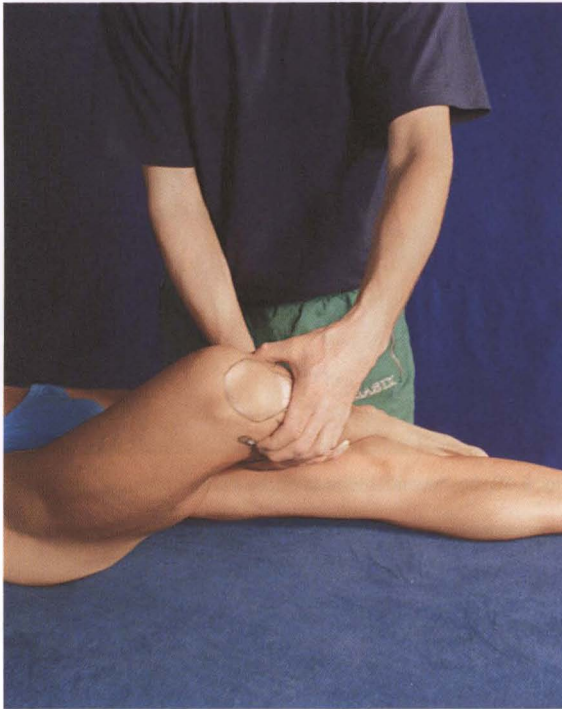


Fig. 6.55 Palpation with the aid of the “Patrick test position.”

Technique

The ligament remains relatively relaxed in the previously described SP used for palpation of the lateral knee joint. It is difficult to directly locate the ligament using transverse palpation.

Tips: Two methods exist to make the ligament more distinct:

1. The SP is altered to confirm the localization. One finger remains in contact with the region where the ligament is presumed to be. The leg is placed in the “Patrick test position” by placing the leg to be palpated on top of the other leg so that this hip is positioned in flexion, abduction, and lateral rotation (Fig. 6.55).

When the knee hangs down passively, the joint is subject to varus loading that produces tension in the collateral ligament.

The ligament can now be palpated as a short, thick, and rounded structure. The finger remains on the ligament while the leg is brought back into the original starting position.

2. It takes a lot less effort to confirm the location of this ligament when the joint is moved passively into extensive lateral rotation. As the ligament extends inferiorly in a posterior direction, this position places the ligament under tension, making it easier to locate.

Biceps Femoris

The biceps femoris is the only effective flexor *and* lateral rotator of the knee joint.

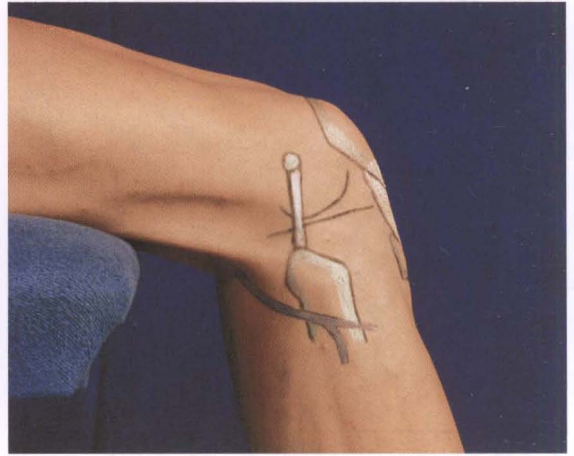


Fig. 6.56 Contraction of the biceps femoris.

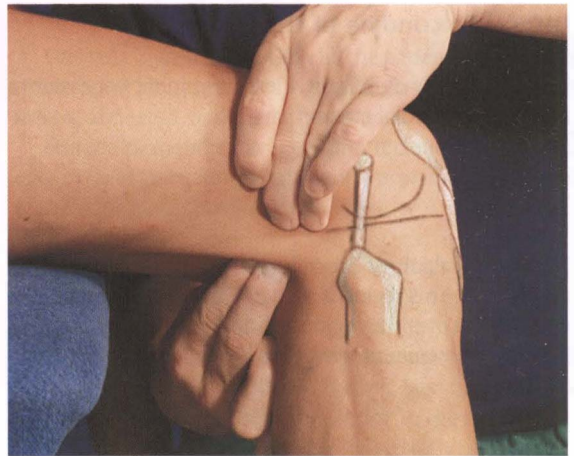


Fig. 6.57 Edges of the biceps femoris proximal to the knee joint.

Its tendon is visible especially when the muscle isometrically contracts (Fig. 6.56). Several of its fibers are evident on the lateral meniscus or “hug” the lateral collateral ligament. The largest part of the tendon inserts onto the head of the fibula.

Technique

The anterior and posterior borders of this wide, prominent structure can be identified using perpendicular palpation (Fig. 6.57).

The next anterior structure is the iliotibial tract and the next posterior structure the common peroneal nerve.

Common Peroneal Nerve

This nerve is one of the large peripheral nerves that cross over the knee joint. Therapists are familiar with its pathway from topographical anatomy. The nerve separates it-

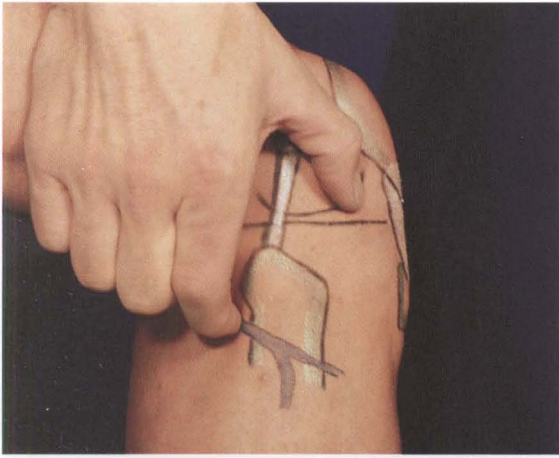


Fig. 6.58 Palpation of the common peroneal nerve.

self from the tibial nerve approximately one hand-width proximal to the joint. It then accompanies the biceps femoris tendon and crosses over the fibula inferior to its head before dividing into its deep and superficial branches.

Technique

Lateral

A finger is positioned perpendicular to the head of the fibula. The fingertip slides down distally until the thick head of the fibula can no longer be felt and only soft tissue can be palpated. The nerve can be palpated slightly more posterior to this position and is “plucked” using a small transverse movement (proximal–distal) (Fig. 6.58). The therapist will be surprised by how thick this nerve is. Its further proximal pathway will be identified in the section “Neural Structures in the Popliteal Fossa” below, page 145.

Tips for Assessment and Treatment

Joint Space

The palpation of the lateral joint space is also used when applying manual therapy glide techniques. In these techniques, the angle of glide has to be accurate to the degree.

Lateral Meniscus

The Steinmann II sign can also be used in the same manner to provoke symptoms in the anterior horn of the lateral meniscus (see also Figs. 6.39 and 6.40).

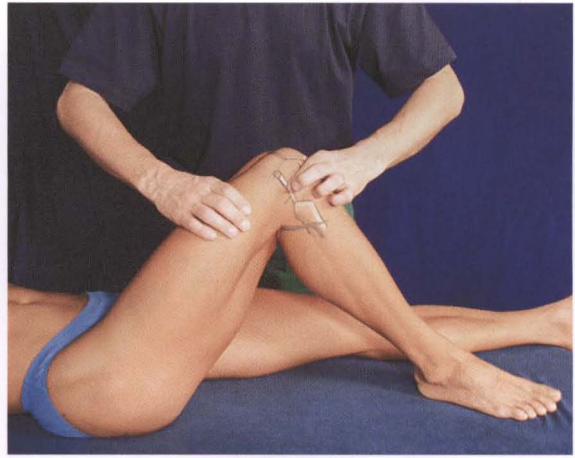


Fig. 6.59 SP for transverse friction at the lateral collateral ligament.

Treatment of the Lateral Collateral Ligament

As was the case medially, transverse frictions can be used to confirm or treat pain arising in the lateral ligament.

Three possible methods are available to find the ligament:

1. Transverse palpation along the joint space.
2. Palpating from the ligament’s bony attachments (epicondyle and head of the fibula).
3. Moving the leg into the “Patrick test position.”

Experience has shown that approximately 90° knee flexion in prone-lying is a suitable SP for the patient (Fig. 6.59). The ligament can be placed under slightly more tension by laterally rotating the knee minimally to ensure that the ligament does not slide away as easily from underneath the finger that applies the frictions. Other SPs are also possible.

The therapist stands on the opposite side of the patient. One hand is used to stabilize the leg position while the other hand applies the frictions. The middle finger is placed on top of the index finger applying the frictions, and the thumb rests on the medial side of the knee to stabilize the hand (Fig. 6.60).

Once the ligament has been located, transverse frictions are applied to the structure to identify the affected part. The tendon is assessed in several small sections. The same technique is used with appropriate pressure to ease pain.

Iliotibial Band Friction Syndrome

There are a large number of causes for lateral knee pain. Symptoms are too often connected to the femorotibial joint, the “real knee joint,” with treatment focusing on this joint. Therefore, two pathological conditions will be presented here that have nothing to do with the joint as

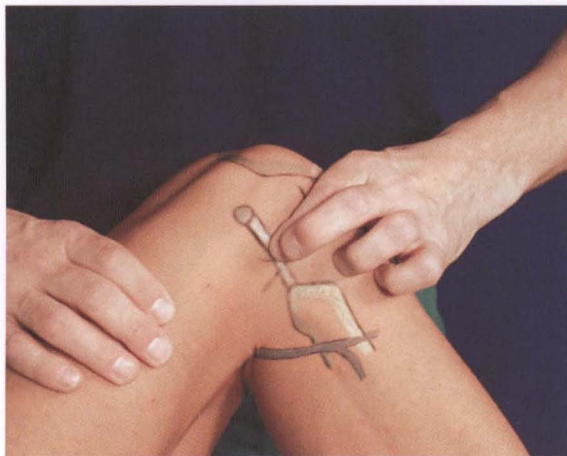


Fig. 6.60 Detailed view of the transverse friction.

such. Knowledge of in vivo anatomy is the indispensable prerequisite for recognizing and naming the cause of the symptoms.

Athletes who flex and extend the knee very often during movement can develop “runner’s knee,” otherwise known as the iliotibial band friction syndrome. This is caused by repeated rubbing of the iliotibial tract (also known as iliotibial band) over the lateral epicondyle during flexion and extension. In most cases, additional pathogenic factors, such as abnormal varus joint statics, also play a role.

The benefits of in vivo anatomy are demonstrated when therapists are able to confirm the presence of friction at the iliotibial tract or the bursa between the tract and epicondyle. Reaching the conclusion that these problems are due to a (more easily treatable) periarticular problem is important in setting the course for further assessment and treatment of the affected knee.

Arthritis of the Tibiofibular Joint

Another set of symptoms involves pain on the anterolateral aspect of the knee region and is related to arthritis in the joint between the head of the fibula and the tibia. The fact that this does not usually involve the knee joint is also of great importance.

The tibiofibular joint functionally belongs to the kinematic chain associated with the important joints of the foot (talocrural, TCN, and ST joints, etc.). The fibula, in particular, moves during flexion and extension of the foot. Of course, this also occurs proximally. Trauma associated with “twisting the ankle” can damage the ligaments of the ankle and often results in the fibula changing its position in the tibiofibular joint. This malpositioning manifests itself as anterolateral pain when present over a long period and is associated with irritation of the capsule.

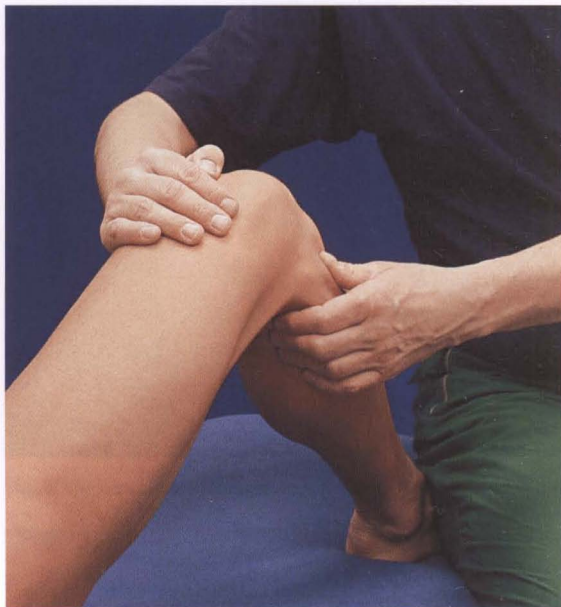

Fig. 6.61 Test of tibiofibular joint play.

Aside from this particular injury, the pain cannot be easily linked to any other precipitating factors.

Only local palpation of the anterior aspect of the joint or a well-conducted test of joint play at the tibiofibular joint can confirm the source of these symptoms (Fig. 6.61).

Local Palpation—Posterior

Overview of the Structures to be Palpated

- Neural structures in the popliteal fossa.
- Biceps femoris.
- Pes anserinus muscle group.

Summary of the Palpatory Process

The hollow of the knee (popliteal fossa) characterizes the topographical anatomy and palpation of the posterior aspect of the knee joint. It is a diamond-shaped depression with muscles forming its boundaries.

The aim of in vivo palpation is to make the borders of the popliteal fossa and its contents accessible.

Starting Position

To gain orientation in the popliteal fossa, it is recommended that the therapist places the soft-tissue structures (muscles and nerves) under significant tension to make their contours distinct.

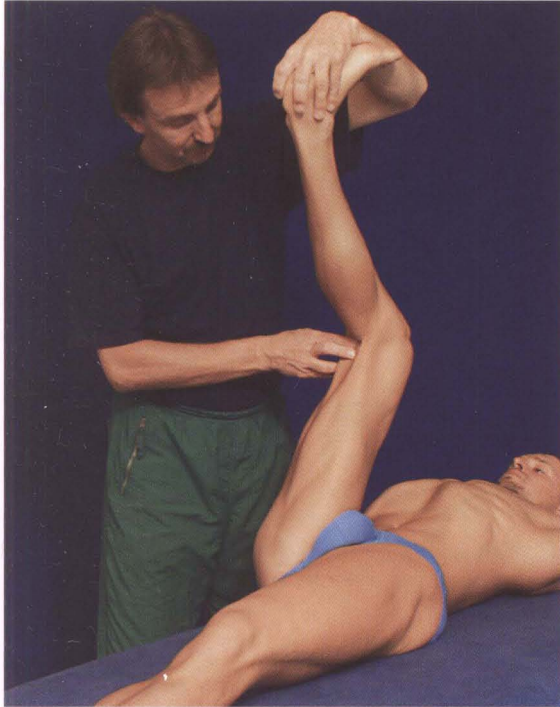


Fig. 6.62 SP for palpation of the posterior aspect.

The patient lies prone. The therapist places the leg in a position similar to that used in the Lasègue test (straight leg raise). The steps involved here vary slightly from this test (Fig. 6.62).

The following combination is recommended when practicing: extensive hip flexion with approximately 30° knee flexion and dorsiflexion of the ankle.

The advantage of this SP is the unobstructed view of the hollow of the knee, the free access for the palpating hand, as well as the initial tension in the soft-tissue structures.

One hand stabilizes the position of the leg. Handling should permit the facilitation of additional ankle dorsiflexion to tighten other muscular and neural structures. The other hand is free to search for the structure being sought.

Alternative Starting Positions

This SP is not particularly comfortable for patients and is only recommended when practicing. Once therapists are able to reliably locate the described structure, they should therefore practice the palpation in other, more comfortable SPs. The position of the muscular structures is then confirmed using selective contraction of the muscles.

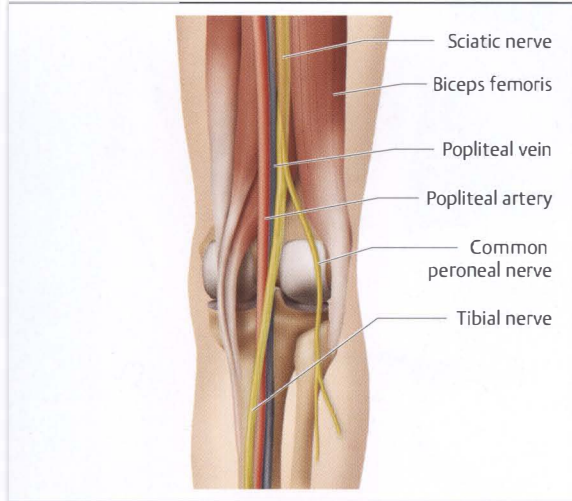


Fig. 6.63 Topography of the neurovascular bundle on the posterior aspect.

Neural Structures in the Popliteal Fossa

The following neural and vascular structures pass through the popliteal fossa (Fig. 6.63):

- Tibial nerve.
- Common peroneal nerve.
- Popliteal artery and vein.

The neural structures in the popliteal fossa can be easily identified when the therapist uses the above-described SP and places the ankle in additional dorsiflexion. End-range hip flexion and moderate flexion of the knee have already stretched these peripheral nerves fully. The positioning of the foot causes them to be maximally tensed.

Technique

Tibial Nerve

The sciatic nerve divides into its two branches approximately one hand-width proximal to the knee joint (Fig. 6.63). The tibial nerve is observed directly (Fig. 6.64) in the middle of the popliteal fossa. The stretched nerve feels very firm and elastic when palpated directly. The expected diameter of the structure can be described as varying from the thickness of a pencil to that of a small finger.

Tip: If the position of the leg does not stretch the nerve sufficiently to identify it as a firm structure, the therapist can additionally move the hip into adduction and medial rotation. This increases tension in the nerve.

Common Peroneal Nerve—Posterior

After branching out from the tibial nerve, the common peroneal nerve passes laterally and accompanies the biceps tendon to the head of the fibula. It crosses further

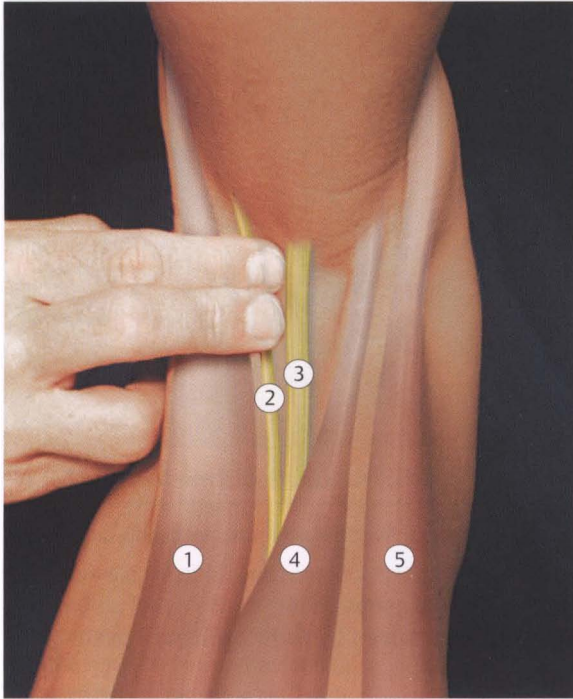


Fig. 6.64 Palpation of the tibial nerve. (1) Biceps femoris. (2) Common peroneal nerve. (3) Tibial nerve. (4) Semitendinosus. (5) Gracilis.

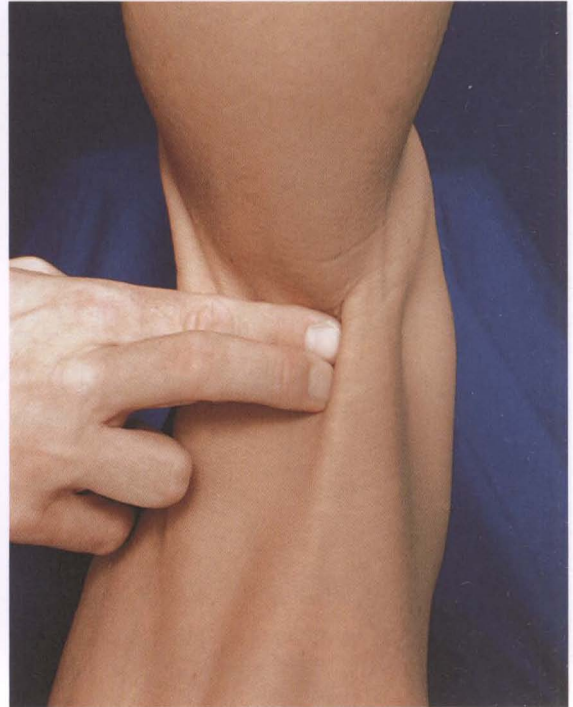


Fig. 6.66 Palpation of the tendon of the semitendinosus.

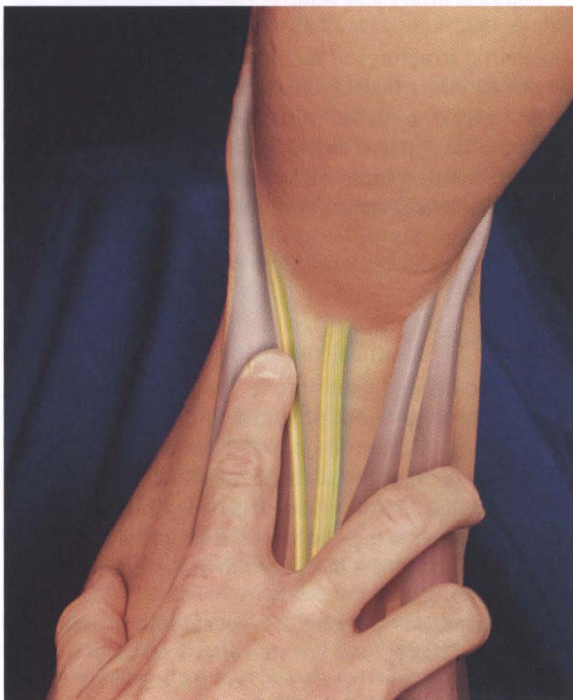


Fig. 6.65 Palpation of the common peroneal nerve.

anterolaterally, distal to the head of the fibula, and then branches out.

The nerve is approximately 1 cm wide and found more medially at the level of the biceps tendon. The tension in the nerve makes it easy to clearly differentiate it from the tendon (**Fig. 6.65**).

Tip: If the nerve does not feel like a firm structure because it is not stretched sufficiently, the therapist can additionally alter the position of the foot to increase tension. Adduction and supination is ideal for this. In theory, plantar flexion also increases tension, but its use is not as appropriate here because it causes the neighboring gastrocnemius to relax and makes it more difficult to differentiate the nerve from its surroundings.

Biceps Femoris

The biceps tendon forms the lateral border of the popliteal fossa. The tendon is stretched so much and is so prominent in this SP that it cannot be missed. Palpation of the tendon in a distal direction leads the therapist onto the head of the fibula again. Proximally, the disappearance of the distinct contour of the tendon marks the start of the muscle belly of the short head.

Pes Anserinus Muscle Group

It is significantly more challenging to differentiate the muscles forming the medial border of the popliteal fossa.

Technique

Semitendinosus

The semitendinosus has the most prominent tendon in this muscle group. It is easy to use the fingertips to hook around the tendon from the middle of the popliteal fossa (Fig. 6.66). The tendon can be followed a little distally. Its contours disappear into the collagenous plate of the pes anserinus on the inner side of the knee.

Tip: If tissue conditions make precise location of the tendon difficult, the therapist can confirm the location by instructing the patient to actively extend the hip, which causes the tendon to clearly protrude.

Gracilis

The tendon of the gracilis can be palpated directly medial to the semitendinosus tendon, which is best achieved when the patient adducts the hip. These tendons are separated by a small gap (Fig. 6.67).

Sartorius

The palpating finger can locate the more flattened structure of the sartorius further medially after passing another small gap in the muscles.

Precise differentiation of this muscle from the gracilis is achieved by flexing the hip against resistance. This causes the gracilis to relax again and the sartorius becomes more distinct (without figure).

Tips for Assessment and Treatment

Caution: Popliteal Fossa

- Knowing how easy it is to reach very sensitive structures in the hollow of the knee, such as the peripheral nerves or their neighboring blood vessels, should prevent therapists from applying excessive pressure to the popliteal fossa. This area is at risk when applying underwater pressure massage and local friction techniques, for example, to the popliteus, or during mobilization when pressure is applied to the calf near the knee joint.
- Transverse frictions should be applied very accurately to the biceps tendon or the muscle–tendon junction. It is very important that these structures be differentiated from the common peroneal nerve when conducting these techniques. Knowledge of the correct anatomy of living subjects provides therapists with the necessary basic skills.

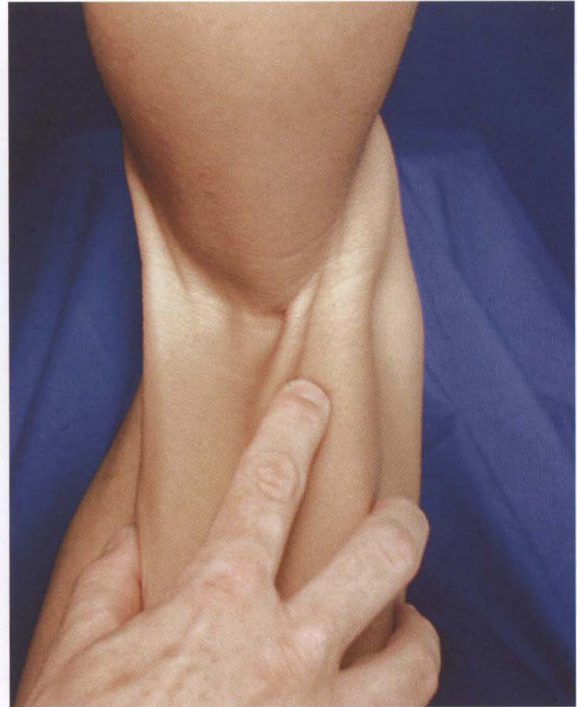

Fig. 6.67 Differentiation between the semitendinosus and gracilis.

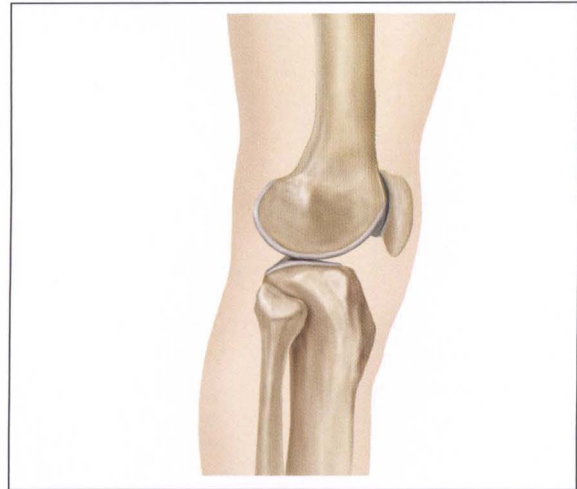


Fig. 6.68 Drawing exercise

Study Questions

1. Where can the therapist access the anterior horn of the medial meniscus?
2. How is it possible to differentiate the patellar ligament from the tibial tuberosity?
3. List the characteristics of the medial collateral ligament.
4. Which structure is about as wide as one finger and is found in the hollow of the knee next to the biceps tendon?
5. Which bony reference point marks the insertion for the lateral collateral ligament?
6. Which position is used to make the lateral collateral ligament more prominent?
7. The hollow of the knee (popliteal fossa) is diamond-shaped due to its boundaries. Which muscles form its boundaries?
8. How can the position of the head of the fibula be described?
9. Independently identify the part of the medial epicondyle that protrudes significantly. What is its name?
10. How does the therapist recognize mild irritation of the capsule in the knee joint?
11. Draw all of the structures on the lateral aspect of the knee that you are familiar with (**Fig. 6.68**).

7 Foot

- Significance and Function of the Foot ... 151
- Common Symptoms in the Foot ... 152
- Required Basic Anatomical and Biomechanical Knowledge ... 152
- Palpating the Medial Border of the Foot ... 154
- Palpating the Lateral Border of the Foot ... 162
- Palpating the Dorsum of the Foot ... 170
- Palpation of the Posterior Foot ... 175
- Study Questions ... 179

THIS PAGE INTENTIONALLY
LEFT BLANK

7 Foot

Significance and Function of the Foot

Function

- **Transmission of body weight onto the underlying surface.** During the gait cycle and bipedal stand, the construction of the foot absorbs shock and cushions the transfer of body load onto the underlying surface.
- **Shock absorption.** This is one of the basic principles spanning the entire lower limb and vertebral column. It is achieved in the foot by:
 - several chambers in the sole of the foot;
 - the bony construction, more similar to a cushioning sheet than an inflexible arch;
 - the astonishing range of motion within the tarsal joints.
- **Locomotion.** The gait cycle is the most complicated pattern of movement in the musculoskeletal system, followed by full elevation of the arm. The foot's function in the lower limb is to establish contact, support the weight of the body, adapt to uneven terrain, provide a stable supportive surface, and to propel the body.
- **Sensory function.** In addition to thermic receptors, a large number of mechanoreceptors are integrated into the joints, ligaments, and sole of the foot. The information received from these receptors contributes to coordination in standing and locomotion as well as the development of balance.

Special Characteristics of the Bony Construction

- In comparison to the construction of the skeleton of the hand, the tarsal bones stand out from their surroundings with their noticeable increase in bony mass and their reduced mobility.
- Shape of the longitudinal and transverse arches. The medial arch is higher than the lateral arch. The calcaneus became upright during evolution, moving the talus with it into a vertical position and thus creating the longitudinal arch. This arch is not rigid, but very elastic as it transfers the load of the body onto the underlying surface. The longitudinal arch is stabilized by the plantar fascia and ligaments as well as the short muscles of the foot using tension banding.
- In the metatarsal region, the evolutionary affiliation of the first ray and the big toe with the rest of the bones of the mid-foot is striking. This development improved

the ability of the foot to both support the body and partake in heel-toe gait, but was at the cost of grasp, with enormous losses being made here in comparison to the feet of primates.

- The angle between the skeleton of the foot and the axis of the leg is almost perpendicular and is labeled the “double-angled lever construction.” This enables locomotion on the soles of the feet and provides a long lever for the long muscles originating in the lower leg.

Special Biomechanical Characteristics

An outstanding biomechanical characteristic in the foot is the formation of the kinematic complex composed of the talocrural (ankle) joint, subtalar (ST) joint, and the transverse tarsal (TT) joint. This articular complex must always be viewed as a functional unit. The articular components always act together, especially during movement in a closed kinematic chain.

The TT joint and its biomechanical connection to the ankle and talocalcaneonavicular (TCN) joints play a crucial role in the mobility and flexibility of the foot. Disorders within the kinematic chain—also known as the Chopart joint line—can only be identified using tests of joint play at the respective articulation.

The biomechanics of two connected movements in particular are to be highlighted: eversion and inversion.

Eversion is a combination of movements that particularly arise mid-stance, the phase mainly identified as the shock absorption phase. It comprises:

- Dorsiflexion at the ankle joint.
- Valgus at the TCN joint.
- Extension, abduction, and pronation of the TT joints.

Inversion (plantarflexion, adduction, supination, and varus) particularly arises when the free-hanging foot is positioned in plantarflexion. It is only observed in the hindfoot when weight-bearing. Although inversion of the calcaneus does initiate movement at heel-off, inversion is not passed onto the rest of the foot due to the contraction of the peroneus longus holding down the medial border of the foot on the underlying surface. Therefore, the center of pressure pathway does not pass through the fifth toe, but instead heads medially toward the first toe.

The individual components influence each other and are always to be viewed, assessed, and, if necessary, treated as a unit when mobility is affected. Sites of hypomobility and hypermobility are often found adjacent to one another. Hence, all joints should be assessed individually in

cases of abnormal mobility. Accurate knowledge of the position of the joint space is required to locate the respective joint.

Common Symptoms in the Foot

Any dysfunction of sensation, mobility, and motor control in the foot affects the more superior sections of the lower limbs, and even the pelvis and vertebral column. Therefore, particular attention should always be paid to symptoms of the foot.

Arthritis: Arthritis primarily has traumatic or rheumatic origins. Traumatic arthritis mainly develops following the common “twisting the ankle” trauma. The anterior talofibular ligament reinforcing the anterolateral aspect of ankle joint capsule is one of the most commonly injured structures in the musculoskeletal system.

Restricted mobility: Hypomobility in the ankle joint, usually resulting from immobilization or arthritis, is very common. It is important that therapists think functionally and always consider the other components of the kinematic complex as well.

Another common location of restricted mobility and, at times, deformities, is the first metatarsophalangeal joint in the form of hallux rigidus or hallux valgus. These changes in mobility cause changes in the entire pattern of movement during the stance phase of the gait cycle.

Hypermobility and instability: Ligamentary instability at the ankle is common. The anterior ligaments of the ankle have the task of holding the tibia on the talus during weight-bearing. This can no longer be upheld in cases of extreme laxity, so that the tibia is no longer positioned over the center of the talus. During dorsiflexion in weight-bearing, dysfunctional arthrokinematics of the ankle can be confused with a restriction in mobility at the joint.

Other hypermobile joints may be hidden in the remaining components of the ankle, TCN, and TT joints' kinematic complex. Ligamentary laxity in the medial tarsal joints (talus–navicular, navicular–medial cuneiform, etc.) decelerates the foot too late in the heel-strike phase and results in excessive pronation of the foot during the mid-stance phase.

Pathological conditions in the soft tissues: In addition to ligamentary injuries, inflammation of the synovial sheaths of the extrinsic (long) muscles of the foot is particularly painful. This can occur on both sides of the foot at the point where the extrinsic tendons change directions:

- Lateral—peroneal muscles.
- Anterior—ankle dorsiflexors, toe extensors.
- Medial—deep ankle plantarflexors and toe flexors in the tarsal tunnel.

The Achilles tendon can present with tendinitis or tenosynovitis (**achillodynia**).

Insertion tendinopathy is observed on the medial and lateral sides of the skeleton of the foot: base of the fifth metatarsal—peroneus brevis, tuberosity of the navicular—tibialis posterior.

Local plantar pain is often summed up as the symptoms associated with “heel spur,” located at the attachment of the plantar fascia and the short plantar muscles.

It is also possible for **neural structures to be compressed or overstretched** in the foot. Two peripheral nerves are most commonly affected:

- The tibial nerve in the tarsal tunnel (posterior to the medial malleolus).

Narrowing of the tarsal tunnel, through which the flexor hallucis longus, flexor digitorum longus, and tibialis posterior also travel, mainly compresses the neural structure. The tibial nerve divides into two plantar nerves after it exits the tunnel.

- The intermediate branch of the superficial peroneal nerve. This nerve branch is found very superficially on the anterolateral aspect of the lower leg and foot. Injury may occur from traumatic overstretching when the ankle is “twisted,” during open ligament reconstruction following ankle sprain, or may be associated with irritation arising from local transverse frictions applied to the talocrural joint ligaments.

The consistent characteristics indicate the presence of nerve irritation: burning pain and sensory disorders in the nerve's area of supply.

Aside from these neural symptoms, patients can generally provide very precise information on their pain. Pain is not expected to be referred (i.e., symptoms will be perceived only at the site of origin). It is imperative to consider the patient's information about pain location when taking further action. This location must then be aligned with assessment results and local anatomy to reliably identify the affected structure.

Required Basic Anatomical and Biomechanical Knowledge

Therapists should have sound knowledge of topographical anatomy when palpating the foot.

Therapists should also be familiar with the bony construction of the foot and its individual sections, the joint lines, as well as the names of the individual tarsal bones and their mobile connections (**Fig. 7.1**).

Relevant soft-tissue structures include:

- Muscular structures: tendons and synovial sheaths of the extrinsic foot muscles, in particular their course at the ankle and their insertions (**Figs. 7.2, 7.3, 7.4**).
- Ligamentous structures: ligaments of the ankle (**Figs. 7.5 and 7.6**).
- Neural structures: tibial nerve, deep and superficial peroneal nerves (see **Figs. 7.18, 7.54, 7.56**).

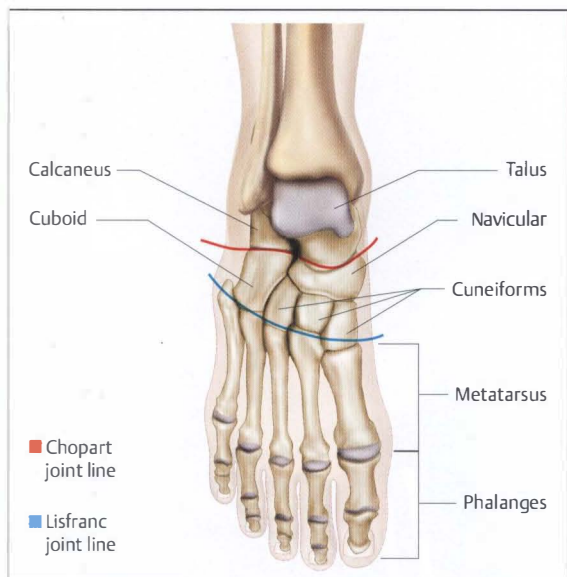


Fig. 7.1 Topography of the skeleton of the foot.

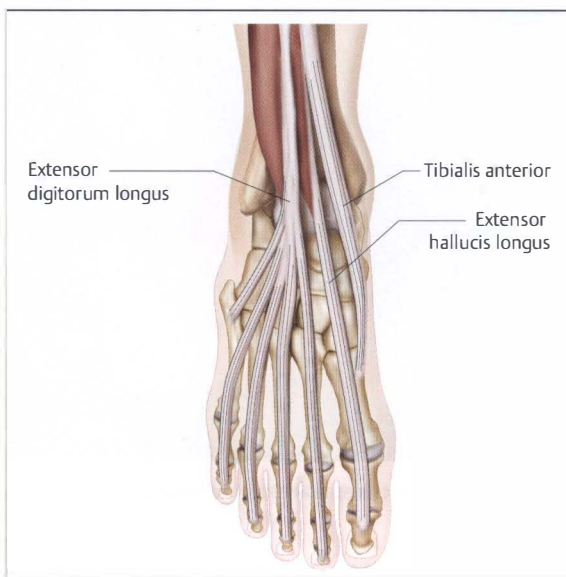


Fig. 7.4 Important muscles—dorsal aspect.

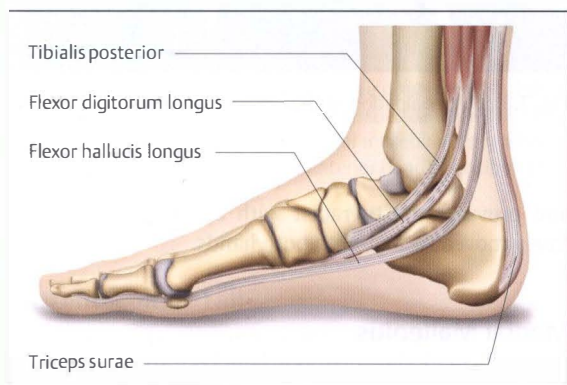


Fig. 7.2 Important muscles—medial aspect.

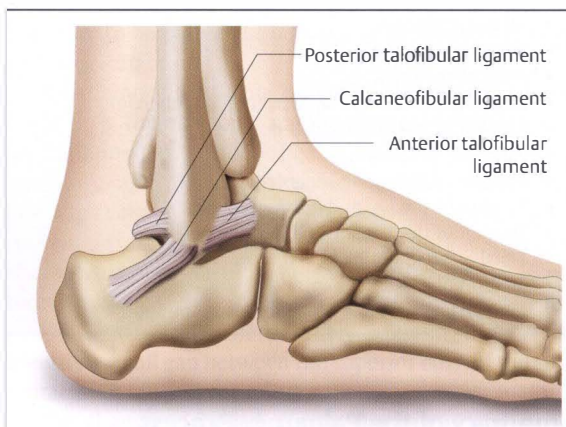


Fig. 7.5 Ligaments of the lateral ankle joint.

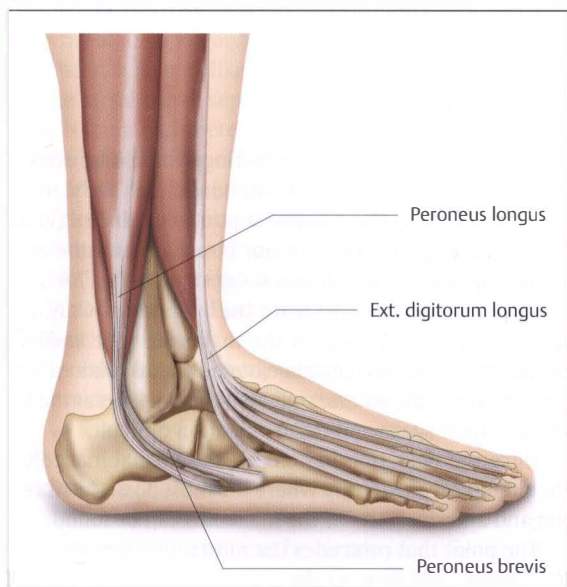


Fig. 7.3 Important muscles—lateral aspect.

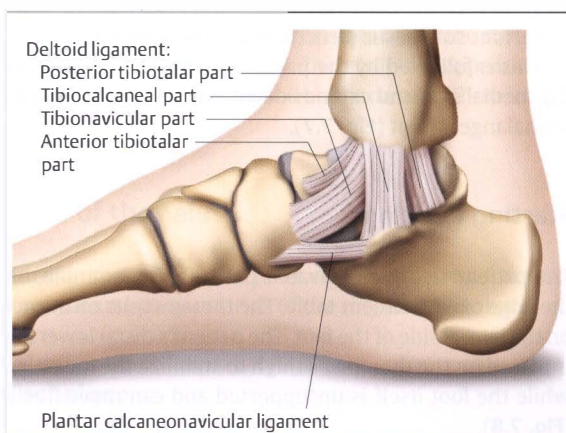


Fig. 7.6 Important ligaments of the medial ankle and TT joints.

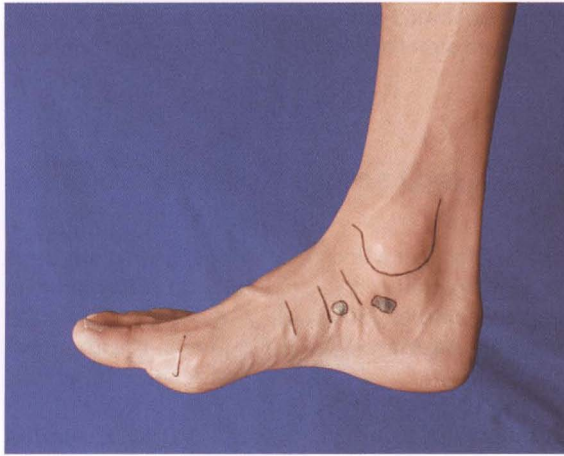


Fig. 7.7 Several structures drawn on the medial aspect of the foot.

Palpating the Medial Border of the Foot

Overview of the Structures to be Palpated

- Medial malleolus.
- Sustentaculum tali.
- Neck of the talus.
- Posterior process of the talus (medial tubercle).
- Tendon of the tibialis posterior.
- Navicular tuberosity.
- Position of the medial ligaments.
- Tendon of the flexor digitorum longus.
- Tendon of the flexor hallucis longus.
- Tibial artery and tibial nerve.
- Tendon of the tibialis anterior.
- Joint spaces on the medial border of the foot.

Summary of the Palpatory Process

All relevant structures in the area of the ankle will first be located. Both the bony reference points and the clinically important soft-tissue structures are of interest.

This is followed by the palpation of all joint spaces on the medial side and extends down onto the first metatarsophalangeal joint (Fig. 7.7).

Starting Position

The patient sits in an elevated position, for example, on the edge of a treatment table. The therapist sits on a stool on the lateral side of the foot. The patient's distal lower leg is placed on the therapist's thigh to stabilize the lower leg while the foot itself is unsupported and can move freely (Fig. 7.8).

This starting position (SP) is not mandatory when practicing palpation. The therapist can also choose to position the patient differently. The SP described here allows the patient to maintain the position over an extended period

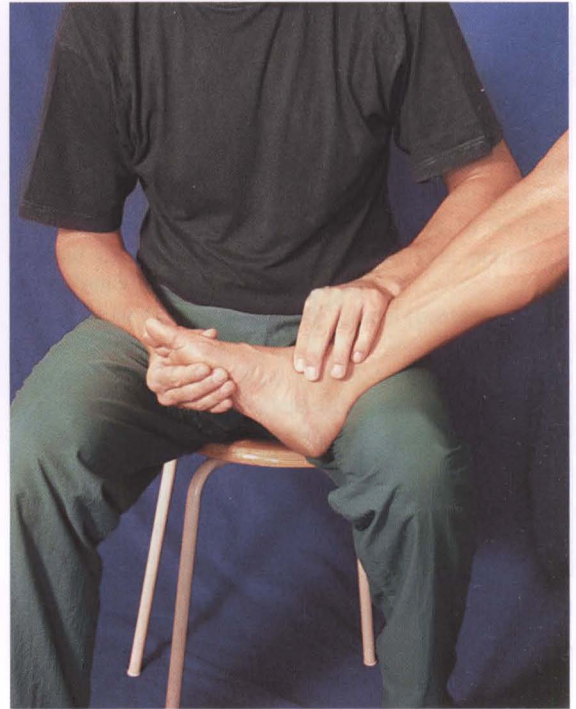


Fig. 7.8 SP for palpation of the medial aspect.

and provides the therapist with optimal access to the freely moveable foot with both hands.

Medial Malleolus

The palpation starts by circling around the medial malleolus. The perpendicular palpation technique is used to locate the bony structures on the edge of the malleolus.

Technique

The posteriorly positioned index finger should be used to palpate the posterior and inferior boundaries of the medial malleolus and the anteriorly positioned index finger for the palpation of the anterior boundary and the area of transition onto the talocrural joint space (Fig. 7.9).

In general, it is easy to reach the boundaries. Only one tendon crosses over part of the malleolar edge and can hinder palpation to a certain extent. Several tendons impede access to the anterior edge of the malleolus at the talocrural joint space and make palpation difficult.

Once the palpation has circled the medial malleolus, the therapist can identify where the most posterior, inferior, and anterior parts of the malleolus can be found.

The point that protrudes the most:

- Anterior will be later described as the anterior tip of the malleolus.

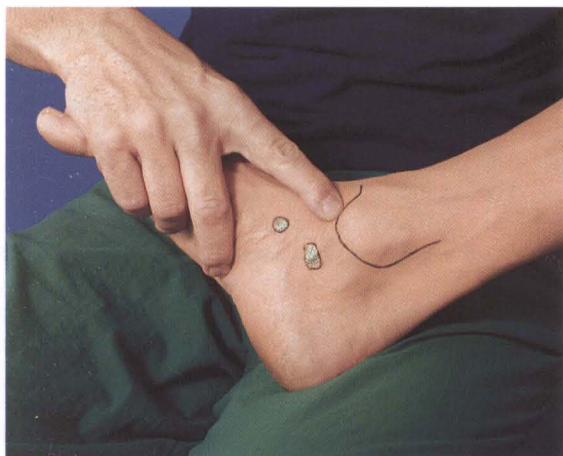


Fig. 7.9 Circling around the medial malleolus.

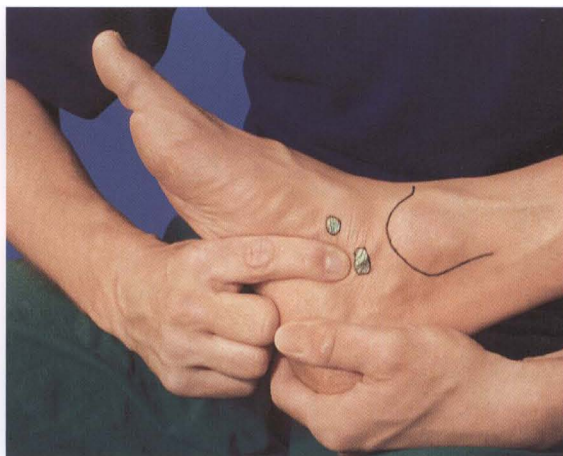


Fig. 7.10 Palpation of the sustentaculum tali.

- Inferior will be later described as the inferior tip of the malleolus.
- Posterior will be later described as the posterior tip of the malleolus.

Tip: The therapist should avoid excessive prestretching of the medial soft tissues because the soft tissues can prevent free access to the bony edge of the medial malleolus if stretched. This is best resolved by using the anterior hand to position the joints of the foot in neutral.

Sustentaculum Tali

The next structure is found approximately 1 cm inferior to the inferior tip of the malleolus: the sustentaculum tali. This is a bony eminence on the calcaneus that protrudes in a medial direction. The sustentaculum tali is quite interesting in terms of its topography and functional anatomy:

- It bears a balconylike prominence medial to the talus.
- The tarsal canal, separating the two chambers of the TCN joint, ends here.
- The tendon of flexor hallucis longus crosses beneath it. In active dorsiflexion, the tendon holds the medial side of the foot up, guaranteeing the upright position of the calcaneus.
- Two ligaments insert at the sustentaculum tali: a section of the deltoid ligament and the plantar calcaneonavicular ligament.
- The talus can be directly palpated on the medial aspect between the sustentaculum tali and the malleolus.

Technique

The sustentaculum tali can be clearly identified from an inferior direction. It is very difficult to identify its junction with the talus.

The therapist can access the inferior boundary by palpating the soft tissue from the sole of the foot toward the malleolus. The sustentaculum tali is the first osseous structure to be palpated that has a correspondingly hard feel (Fig. 7.10).

The therapist gently places one finger between the inferior tip of the malleolus and the sustentaculum tali (i.e., on the talus located underneath) to locate the superior boundary, and tilts the calcaneus medially (varus) and laterally (valgus) using small movements. During these movements, the therapist is able to identify a structure that moves (sustentaculum tali) and a structure that is immobile (talus).

In “slender feet,” the precisely palpating finger can identify a small gap between the superior edge of the sustentaculum tali and the talus.

The changes palpated during the valgus and varus movements represent the alternating tension and relaxation in the superficially located soft tissues (retinacula and deltoid ligament).

The posterior and anterior boundaries of the sustentaculum tali are also identified. This structure appears to be approximately 1 cm wide and approximately 2 cm long in total.

Neck of the Talus

Further sections of the talus can be accessed from the anterior and posterior tips of the medial malleolus.

Technique

The neck of the talus is reached immediately anterior to the anterior tip (Fig. 7.11).

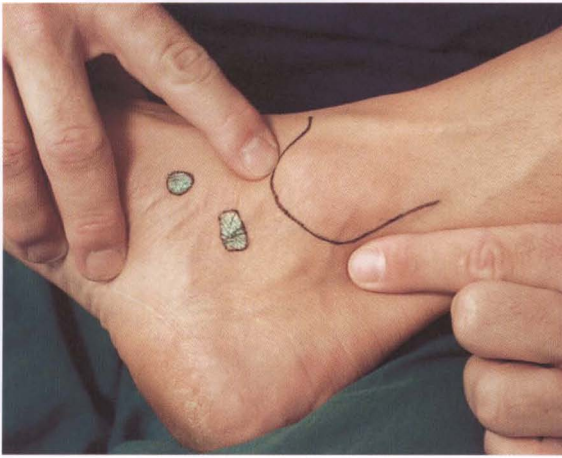


Fig. 7.11 Palpation of the neck and posterior process of the talus.

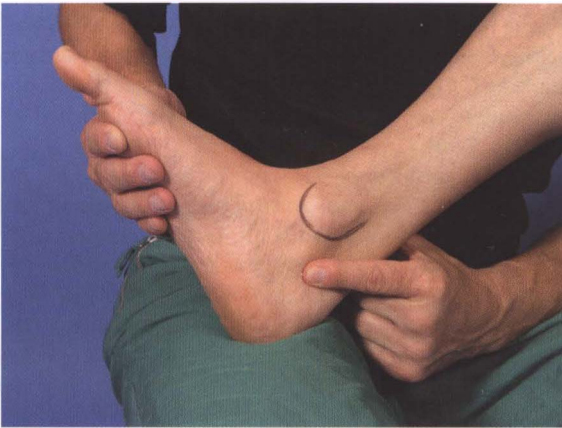


Fig. 7.12 Palpation of the posterior process of the talus.

It becomes more distinct underneath the palpating finger during plantarflexion and disappears into the tissues during dorsiflexion.

The anterior section of the deltoid ligament inserts at this point: the anterior tibiotalar part.

Posterior Process of the Talus (Medial Tubercle)

Another bony reference point is found posterior to the medial malleolus.

Technique

The palpating finger applies moderate pressure to the posterior tip of the medial malleolus and gradually moves posterior and slightly inferior. Another bony structure can be very easily identified, the medial tubercle of the poster-

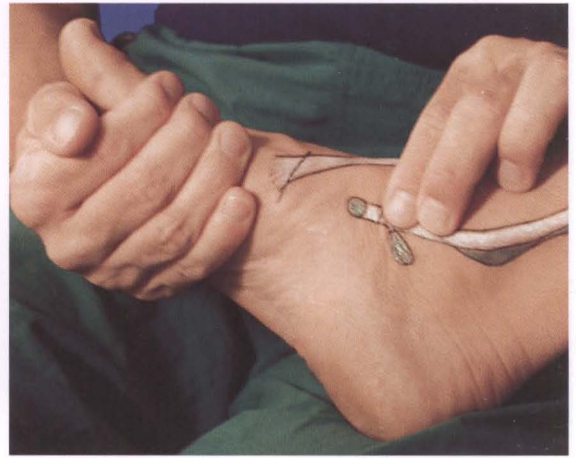


Fig. 7.13 Palpation of the tibialis posterior tendon.

ior process of the talus (**Figs. 7.11** and **7.12**). Another section of the deltoid ligament inserts here—the posterior tibiotalar part.

Tip: Movement is used to confirm the definite identity of this structure. The free hand facilitates alternating ankle dorsiflexion and plantarflexion.

The posterior process of the talus increasingly pushes against the palpating finger during dorsiflexion and disappears into the tissues during plantarflexion. This results from the rolling and gliding motion of the talus during this movement and the associated changes in spatial position.

Tendon of Tibialis Posterior

This is the most prominent tendon on the medial side. It is one of the tendons held on the foot and the skeleton of the lower leg by the flexor retinaculum. The distinctive feature of the tendon's course is its position on the medial malleolus immediately inferior to the flexor/extensor axis of the ankle.

This tendon is used to guide the therapist onto the navicular, which is the last important bony reference point on the medial aspect of the foot.

Technique

Theoretically, the tendon can be found using a flat, transverse palpation technique over the malleolus. Practically, this often proves difficult.

The tendon is made more distinct for palpation by isometrically or rhythmically contracting the muscle with inversion of the foot (plantarflexion, adduction, and supination). This allows the tendon to be traced over its entire length, from the distal lower leg to its primary insertion (**Fig. 7.13**).

Navicular Tuberosity

Technique

A bony elevation is reached when the tibialis posterior tendon is consistently followed in a distal direction: the navicular tuberosity. To locate this structure precisely, the muscle should be relaxed and the tendon free of tension. The tubercle presents as a distinct, rounded elevation. It feels hard when pressure is applied. In contrast, the tendon reacts with slightly more elasticity.

Position of the Medial Ligaments

The sections of the deltoid ligament and the plantar calcaneonavicular ligament are the most important ligaments accessible on the medial side of the foot.

By locating the bony reference points in the immediate vicinity of the medial malleolus, all reference points have been identified that are needed to establish the position of the deltoid ligament.

The deltoid ligament can be divided into several parts based on its topographic anatomy. The ligament is labeled according to the bony fixed points.

They include—according to their position from anterior to posterior—the following:

- Anterior tibiotalar part:
medial malleolus—neck of the talus.
- Tibionavicular part:
medial malleolus—navicular tuberosity.
- Tibiocalcaneal part:
medial malleolus—sustentaculum tali.
- Posterior tibiotalar part (**Fig. 7.14**):
medial malleolus—posterior process of the talus.

Technique

Deltoid Ligament

The different parts of this ligament cannot be located using palpation as too many other soft tissues lie superficial to the ligament and prevent direct access (flexor retinaculum and a variety of tendons).

Only the dimensions of the ligaments can be identified, by drawing a line between the respective bony fixed points on the skin.

The advantages of this procedure are the production of a three-dimensional shape and comprehension of the tension in the different structures in a variety of joint positions.

For example, the therapist comprehends that the posterior tibiotalar ligament is placed under more tension as dorsiflexion of the ankle increases. The medial tubercle of the posterior process of the talus projects posteriorly and moves away from the medial malleolus. This tightens the

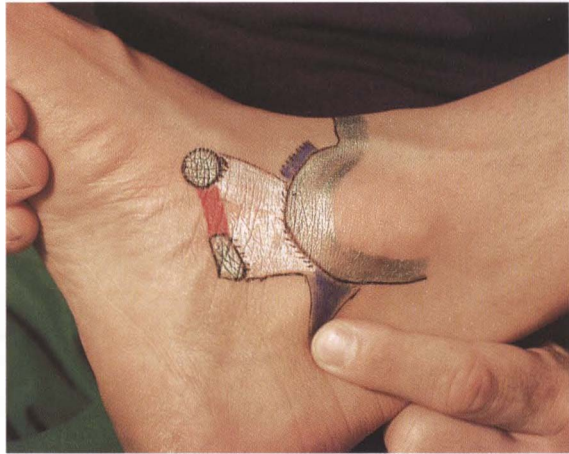


Fig. 7.14 Demonstrating the course of the posterior tibiotalar part.

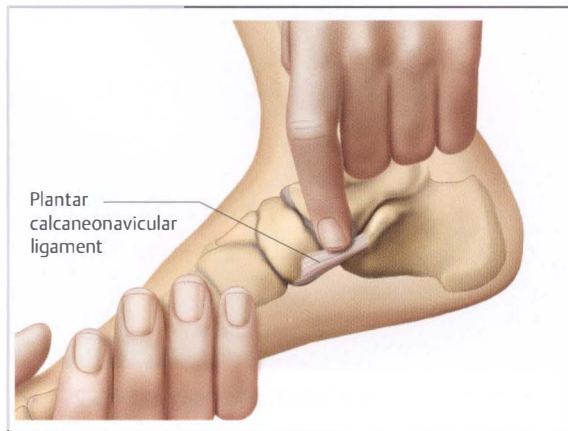


Fig. 7.15 Palpation of the calcaneonavicular ligament.

ligament and supports the approximation of the articulating bones in the ankle.

For further practice: The following movements place the respective parts of the deltoid ligament under tension:

- Anterior tibiotalar part:
plantarflexion, abduction, and pronation.
- Tibionavicular part:
plantarflexion, abduction, and pronation.
- Tibiocalcaneal part:
valgus (tilting the calcaneus laterally).
- Posterior tibiotalar part:
dorsiflexion (with abduction and pronation).

Plantar Calcaneonavicular Ligament

The plantar calcaneonavicular ligament passes underneath the head of the talus between the sustentaculum tali and the navicular tuberosity. It is palpable as a thick, rounded structure and converges with the tibialis posterior tendon onto the tuberosity (**Fig. 7.15**).

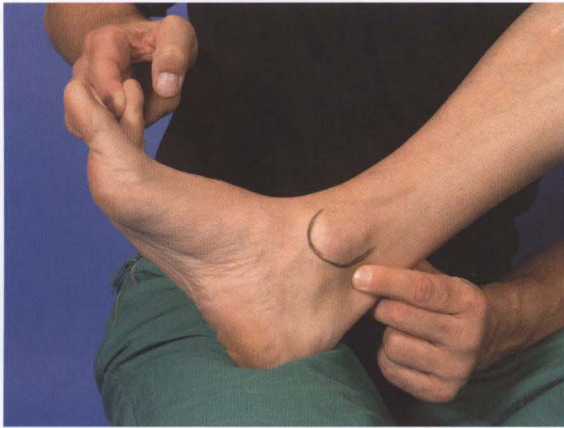


Fig. 7.16 Palpation of the flexor digitorum longus tendon.

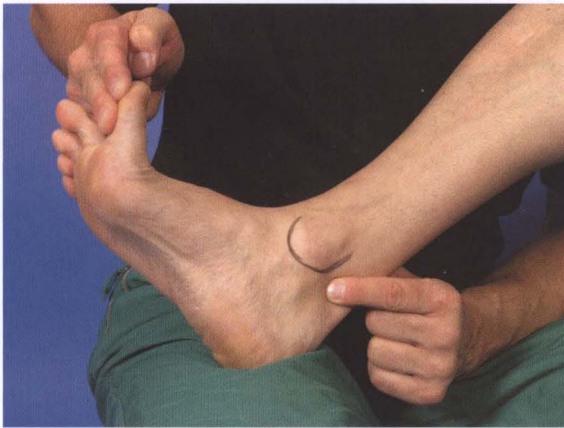


Fig. 7.17 Palpation of the flexor hallucis longus tendon.

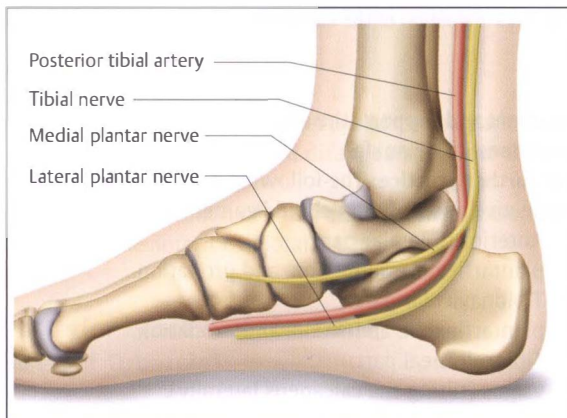


Fig. 7.18 Illustration of the tibial artery and nerve.

Differentiation of the plantar calcaneonavicular ligament from the surrounding tissue is confirmed by moving the forefoot. The ligament relaxes when the calcaneus is fixated and the foot adducted, and clearly tightens during abduction.

Tendon of the Flexor Digitorum Longus

This is the second tendon that passes through the “tarsal tunnel” with its synovial sheath. As with the following tendons, the flexor digitorum longus tendon can only be felt proximal to the talus and calcaneus.

Technique

The therapist first locates the tendon of tibialis posterior and follows it proximally until a point approximately two to three finger-widths superior to the malleolus.

From the tendon, the therapist palpates posteriorly toward the Achilles tendon. The next bulging elevation felt is the tendon of the flexor digitorum longus (Fig. 7.16).

Tip: As this area is often filled with fatty tissue, it is unlikely that the tendon can be located using transverse palpation alone. The therapist therefore uses active and rhythmical toe flexion to confirm the correct localization. Now, the increase and decrease in tension in the tendon is rather distinct.

Tendon of the Flexor Hallucis Longus

The next tendon and its synovial sheath are palpated using the same method. This tendon is found immediately posterior to the above-described tendons and is the third tendon held on the skeleton of the lower leg and foot by the flexor retinaculum.

Technique

Starting at the tendon of flexor digitorum longus, palpation again moves slightly more posteriorly toward the Achilles tendon (Fig. 7.17). The tendon of the flexor hallucis longus is palpated as the last firm and elastic structure before the Achilles tendon. Localization is confirmed here using rhythmical active flexion of the first toe.

The tendon travels in its own groove between the medial and lateral tubercles of the posterior process of the talus, toward the sole of the foot. It is therefore possible to transversely palpate and follow the tendon until a point directly proximal to the medial tubercle.

Tibial Artery and Tibial Nerve

In addition to the three tendons and synovial sheaths described above, three structures pass underneath the flexor retinaculum (Fig. 7.18):

- Tibial vein.
- Posterior tibial artery.
- Tibial nerve.

The artery can be reliably palpated, as can the nerve, with a little more difficulty.

Technique

Artery

The posterior process of the talus is located first. The therapist gently places one finger pad flat on the skin slightly more proximal to this structure.

The pulse of the artery can be felt after a short amount of time and can be followed proximally for a short distance.

Nerve

The tibial nerve lies directly posterior to the artery. It divides into two branches after exiting the tarsal tunnel, forming the plantar nerves. The therapist attempts to identify the nerve by hooking around it (like with a guitar string), by using a pointed palpation technique perpendicular to the structure. The nerve rolls away underneath the palpating finger when it has been exactly located.

It is not possible to precisely identify the vein using palpation.

Tendon of the Tibialis Anterior

The palpation leaves the region surrounding the medial malleolus and concentrates on other structures on the medial side of the foot. Another soft-tissue structure helps in the localization of joint spaces—the tendon of the tibialis anterior.

Technique

The wide tendon of the tibialis anterior can be clearly demonstrated using dorsiflexion, adduction, and supination to contract the muscle. Its edges can be marked without any difficulty and followed distally down onto the medial edge of the foot (Fig. 7.19). The tendon widens here and eludes further palpation. This is the location of the joint space between the medial cuneiform and the base of the first metatarsal (MT).

Joint Spaces on the Medial Border of the Foot

The following joint spaces will be located (Figs. 7.20 and 7.21):

- Talus—navicular:
part of the TT joint line (Chopart joint).
- Navicular—medial cuneiform.
- Medial cuneiform—base of the first MT:
part of the tarsometatarsal joint line (Lisfranc joint).

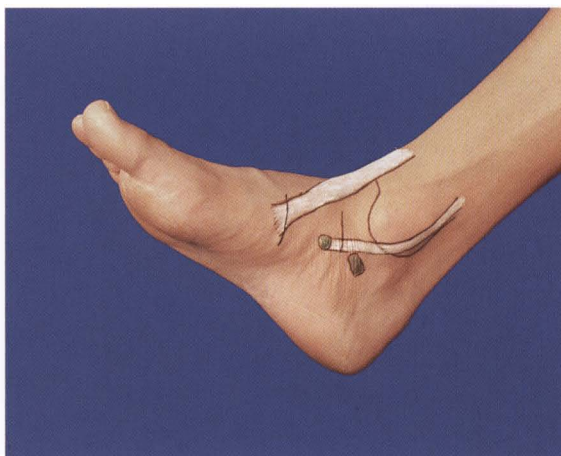


Fig. 7.19 Demonstrating the tendons of the tibialis anterior and posterior.

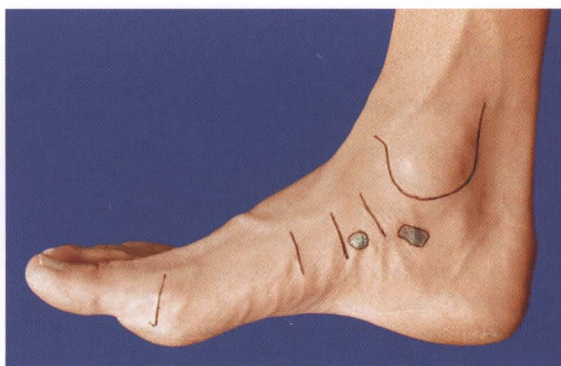


Fig. 7.20 Joint spaces on the medial border of the foot.

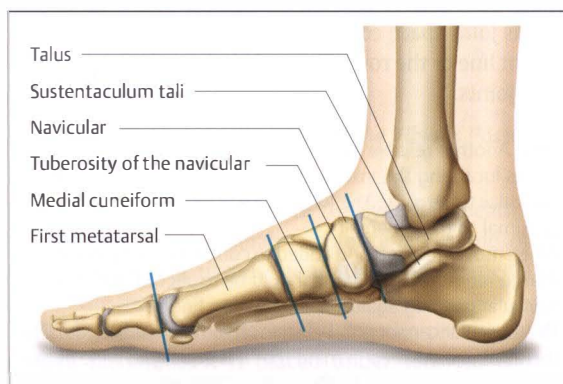


Fig. 7.21 Position of the medial joint spaces.

- Head of the first MT—base of the first proximal phalanx:
first metatarsophalangeal joint.

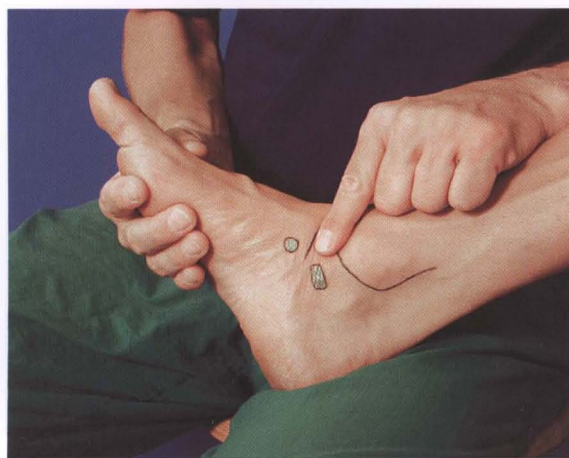


Fig. 7.22 Palpation of the talonavicular joint space.

Technique

Talus—Navicular Joint Space

Using adduction and supination (see Fig. 7.19), the two prominent tendons on the medial side of the foot—tibialis anterior and posterior—become more pronounced and a fossa can usually be observed on the medial side of the foot. Its position and shape is remotely similar to the anatomical snuffbox of the hand.

The talonavicular joint space can be found in this fossa. The joint space on the medial side of the foot does not extend perpendicular to the edge of the foot, but rather declines somewhat in a plantar–posterior direction (Fig. 7.22).

This joint space corresponds to the medial part of the TT joint line or the row of joints belonging to the proximal tarsal joints.

Tips: Another reliable method to locate the joint space involves localizing the insertion of the tibialis posterior at the navicular tuberosity. The joint space is found immediately proximal to the tuberosity.

When movement is being added to confirm localization, quite a large range of movement should be expected, with the navicular pushing against the palpating finger.

The navicular cannot only be accessed on the medial side. The therapist should keep in mind that it is equally as wide as the talus. Please also refer to the section “Palpating the Dorsum of the Foot,” page 170.

It is not possible to accurately differentiate the dorsal dimensions of the other tarsal bones from one another using either palpation or tests of joint play. It is, however, easy to differentiate between these bones and the sole of the foot: the palpating finger moves away from the firm resistance of the tarsal bones and encounters tissue of soft and elastic consistency.

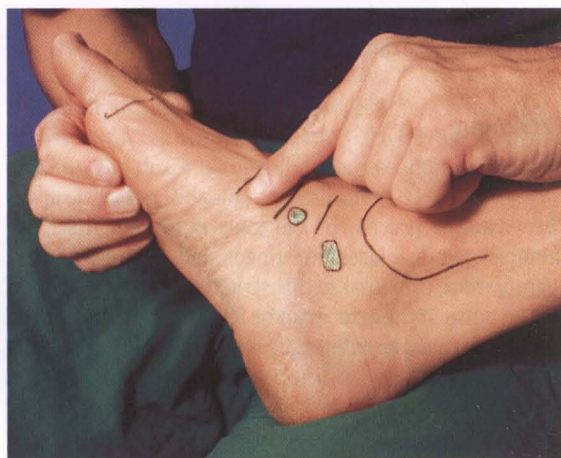


Fig. 7.23 Palpation of the joint space between the medial cuneiform and the first MT.

Navicular—Medial Cuneiform Joint Space

The palpating finger slides into a shallow depression directly distal to the navicular tuberosity reminiscent of the anterior “V” of the AC joint. This indentation marks the joint space between the navicular and the adjacent medial cuneiform.

Medial Cuneiform—Base of the First Metatarsal Joint Space

It is very difficult to access this joint space using palpation (Fig. 7.23).

First, the joint space is small, and second, there is hardly any movement at this joint that could be used to locate it more accurately. This is typical of the joints along the tarsometatarsal joint line.

Tip: The medial cuneiform is approximately as wide as the navicular on the medial side of the foot. The tibialis anterior tendon widens at the height of the joint space. This enables the muscle to be used as a guiding structure, leading the therapist to the joint space.

First Metatarsophalangeal Joint Space

The distal, prominent head of the first MT must first be located. It appears large and convex on the distal end of the first MT. The first metatarsophalangeal joint space lies distal to it (Fig. 7.24). This must be emphasized as many “palpation novices” seek out the joint space proximally.

Confirmation of Joint Space Localization Using Movement

In the following section, the optimal technique will be described to confirm localization of the joint space using movement.

Apart from the talonavicular joint, only small movements are available to feel the joint spaces on the medial aspect of the foot. This technique must therefore accomplish three goals:

- To clearly fixate the proximal bones with a large area of contact so that the bones do not move (using the proximal hand).
- To palpate movement in the joint space (using the proximal hand).
- To facilitate small movements (using the distal hand).

The index or middle finger of the proximal hand is always used for palpation. The remaining fingers and the hypothenar eminence use a large area of surface contact to stabilize the bones proximal to the joint space, ensuring that the slight facilitated movement does not continue more proximally. The distal hand facilitates movement so that the edge of the distally positioned bone pushes against the palpating finger. This usually involves either adduction or extension movements.

Confirmation of Joint Space Localization Using Reference Measurements

If the distance between the inferior tip of the malleolus and the first metatarsophalangeal joint space is used for reference, the joint space between the medial cuneiform and the base of the first MT is found approximately half-way along this line (Fig. 7.25).

The proximal half can be divided into thirds:

- Proximal third = from the malleolus to the talonavicular joint space.
- Middle third = from the talonavicular joint space to the navicular–medial cuneiform joint space.
- Distal third = from the joint space between the navicular and the medial cuneiform to the joint space between the medial cuneiform and the first MT.

The marking of these two bony structures enables the therapist to locate structures quickly and fairly reliably.

Tips for Assessment and Treatment

Transverse Frictions

In principle, all accessible soft-tissue structures (here, tendons and ligaments) can be treated using local transverse frictions. These transverse frictions can in turn be administered provokingly to confirm assessment results. It can also be used for treatment, for example, in cases of tendinopathy, insertion tendinopathy, and tendovaginitis. The techniques used to locate structures on patients are often similar to the techniques used for treatment.

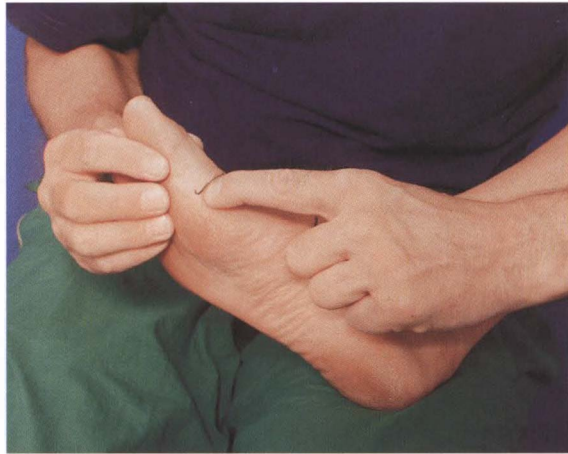


Fig. 7.24 Palpation of the first metatarsophalangeal joint space.

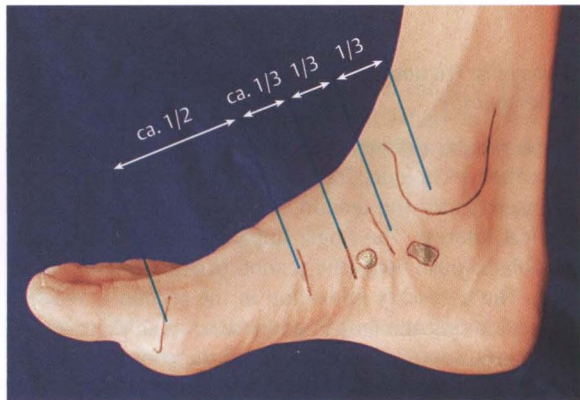


Fig. 7.25 Demonstrating the distance between the medial joint spaces.

Technique

Transverse Frictions in Disorders of the Tibialis Posterior Synovial Sheath

Tendinopathy and irritation of the synovial sheath or of the insertion of the tibialis posterior are some of the most common soft-tissue lesions arising on the medial aspect of the foot.

After the tendon is located using the previously described technique, it is placed under tension, without causing pain, and transverse frictions are applied. The foot is therefore positioned in abduction, pronation, and, if necessary, some dorsiflexion (Fig. 7.26). The preliminary tension stabilizes the structure whilst the technique is being administered and prevents it from rolling back and forth underneath the finger applying the frictions. The proximal hand palpates the entire accessible length of the tendon and synovial sheath. Transverse frictions are applied to the site that the patient indicates to be most painful.

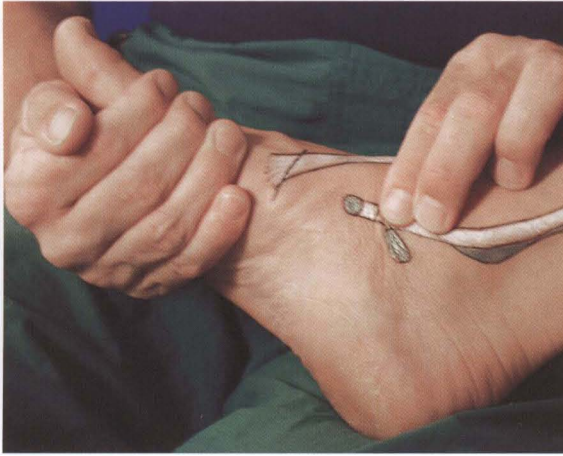


Fig. 7.26 Transverse frictions on the tibialis posterior—technique applied to the tendon.

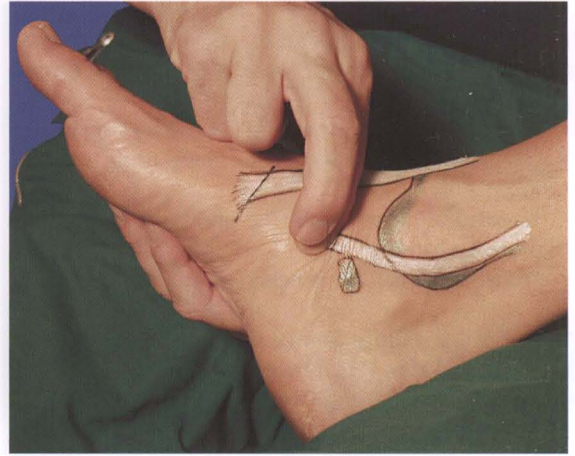


Fig. 7.27 Transverse frictions on the tibialis posterior—technique applied to the insertion.

Transverse Frictions in Cases of Tibialis Posterior Insertion Tendinopathy

The navicular tuberosity is located using the previously described technique. The tuberosity is not the sole area of insertion for the tendon, but is nevertheless a site of clinical interest. The finger applying the frictions must be able to push away the tendon to reach the insertion well. The necessary relaxation in the tendon is reached by positioning the foot in adduction, supination, and, if necessary, some plantarflexion. The technique involves applying pressure as the finger moves from plantar to dorsal (Fig. 7.27). This should be performed with the distal hand as the pad of the index finger is clearly able to come into contact with the tuberosity.

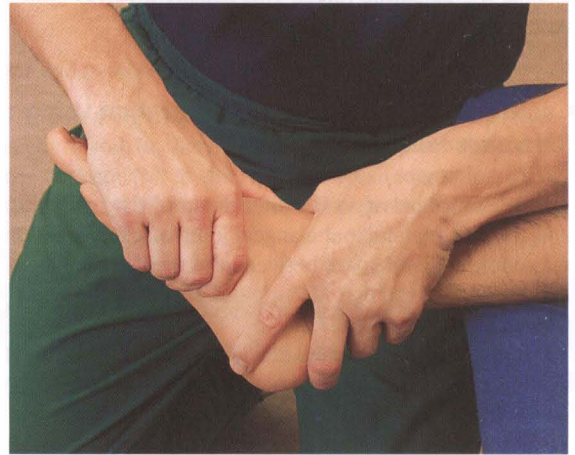

Fig. 7.28 Gliding the navicular on the talus.

Joint Specific Techniques

The TT joint and its biomechanical connection to the ankle and TCN joints play a crucial role in the mobility and flexibility of the foot. Disorders within the kinematic chain of the TT joint line can only be identified using tests of joint play at the respective joint. Therefore, knowledge of the exact position and alignment of joint spaces is crucial.

Talonavicular Joint

The talonavicular joint is found on the medial side and is to be assessed and, if necessary, mobilized.

In this technique, it is imperative that the therapist holds onto the tarsal bones as near to the joint as possible and mobilizes them exactly parallel to the joint space.

The mobile navicular permits plantar and dorsal translation in relation to the talus (Fig. 7.28). The possible range of motion is quite large in comparison to the other joint spaces accessible on the medial skeleton of the foot.

Other Examples of Application

The quality of the tibial artery pulse provides information on the circulation and blood supply in the foot and toes and is important for the evaluation of peripheral occlusive arterial disease.

Palpating the Lateral Border of the Foot

Overview of the Structures to be Palpated

- Lateral malleolus.
- Peroneal trochlea.
- Base of the fifth metatarsal.
- Peroneus longus and brevis.
- Calcaneocuboid joint.
- Fourth/fifth metatarsal—cuboid joint space.
- Dimensions of the cuboid.
- Position of the lateral ligaments.
- Anterior tibiofibular ligament.

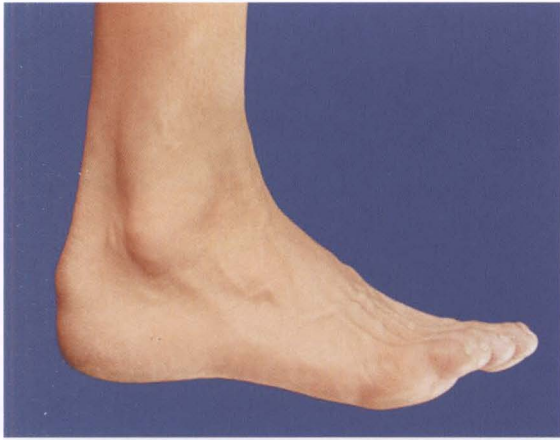

Fig. 7.29 View of the lateral side of the foot.

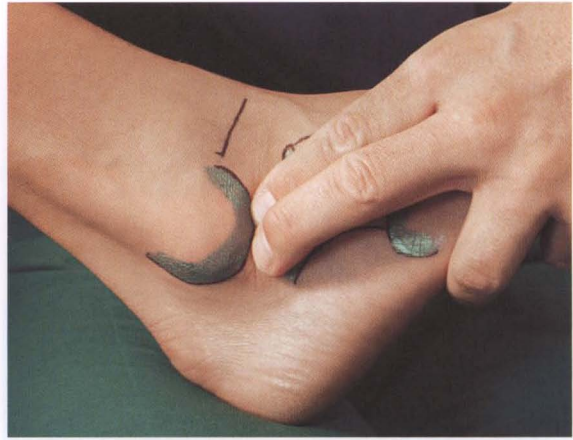


Fig. 7.31 Circling around the lateral malleolus.

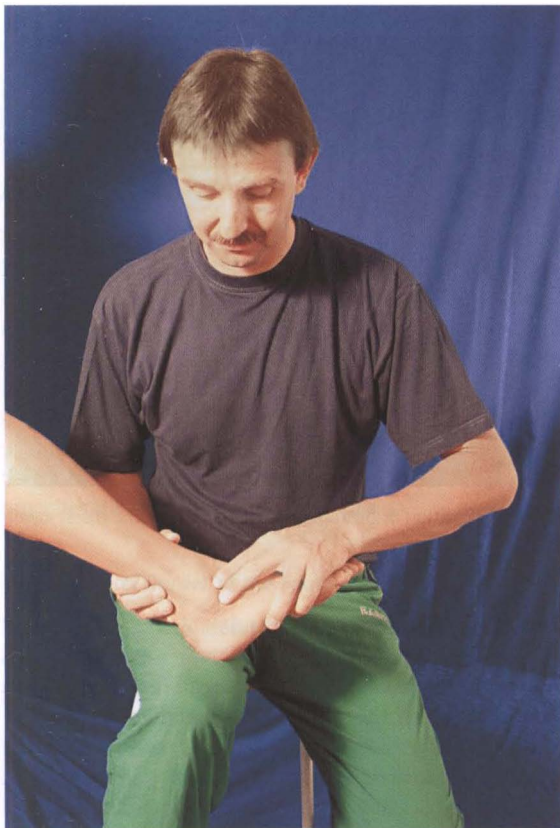


Fig. 7.30 SP for palpation of the lateral border.

Summary of the Palpatory Process

All relevant osseous elevations will be located and demonstrated first, followed by the identification of the large tendons and their synovial sheaths (Fig. 7.29). The important joint spaces will be located and an idea of the position of the ankle ligaments conveyed.

Starting Position

The therapist sits on the medial side of the foot. The patient's lower leg rests on the therapist's thigh to allow access to structures from a wide variety of directions while the foot remains mobile (Fig. 7.30).

Lateral Malleolus

The start of this palpation is comparable to the start of the palpation tracing around the malleolus on the medial side.

Technique

The distal hand palpates perpendicularly to demonstrate the edges of the lateral malleolus (Fig. 7.31), which is an easy task as the entire malleolus is very prominent.

Tip: The transition onto the anterior border of the tibia can also be demonstrated by following the edge of the malleolus anteriorly. This is the joint space of the ankle. The neck and head of the talus is found immediately distal to this. The terms anterior and inferior tips are used here to describe the boundaries of the malleolus.

Peroneal Trochlea

The peroneal trochlea is described as a small, tear-shaped elevation on the lateral aspect of the calcaneus. The parallel tendons of the peroneal muscles separate at this point (Figs. 7.32 and 7.33).

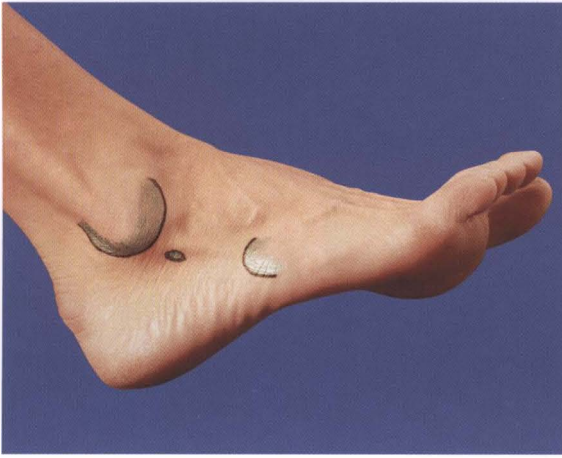


Fig. 7.32 Position of the most important osseous reference points on the lateral side of the foot.

Technique

A small bony landmark is palpable plantar and distal to the inferior tip of the malleolus. Its size is subject to considerable variation between individuals. To clearly demonstrate the peroneal trochlea, the foot must be completely relaxed, otherwise the thick peroneal tendons will impede identification.

Base of the Fifth Metatarsal

It is relatively easy to feel the increase in width of the proximal end of the fifth metatarsal on the lateral border of the foot. There are two options.

Technique

Method 1

The therapist uses two to three fingertips and slides them from the heel toward the fifth toe. The first distinct, bony elevation encountered is the base of the fifth MT, also known as the tuberosity.

Method 2

The patient is instructed to actively “point the toes down and out” (i.e., plantarflexion, abduction, and pronation). This noticeably activates the peroneal muscles. One of the tendons can be followed down onto the base of the fifth MT (**Fig. 7.33**).

Tip: Another tendon inserts on the base. This is the tendon of the peroneus tertius, which is not present in all individuals. Although misleadingly labeled as such, this muscle is not the third peroneus muscle, but rather a section of the extensor digitorum longus that has split off.

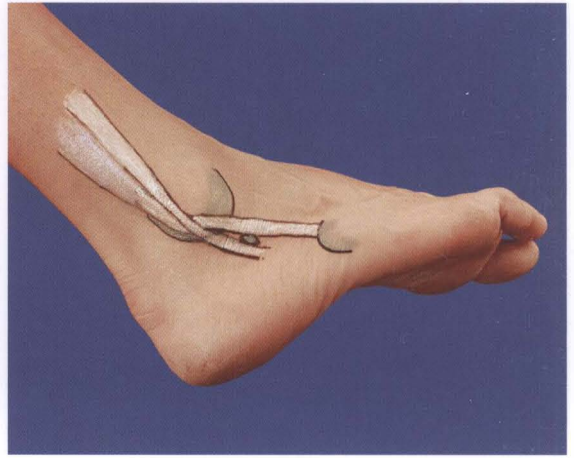


Fig. 7.33 Position of the peroneals.

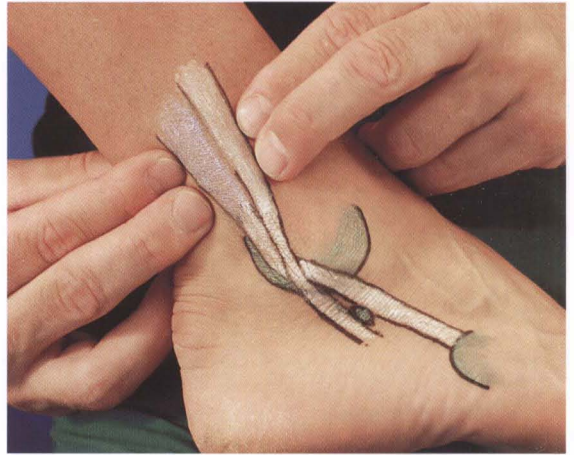


Fig. 7.34 Position of both peroneal tendons on the distal lower leg.

Peroneus Longus and Brevis

Both of the peroneal muscles belong to the plantarflexor muscle group of the ankle. They therefore run behind the flexion/extension axis of the ankle, traveling posterior to the lateral malleolus to reach the skeleton of the foot.

Technique

In the Lower Leg

Both muscles originate laterally, on the fibula. Therefore, the peroneus longus tendon travels superficial to the muscle belly of the peroneus brevis for a certain distance and the tendons are on top of one another immediately proximal to the malleolus. The tendon that can be palpated at this point is that of the peroneus longus. In comparison, the peroneus brevis tendon is significantly more difficult to reach, “hidden” beneath the longus tendon (**Fig. 7.34**).

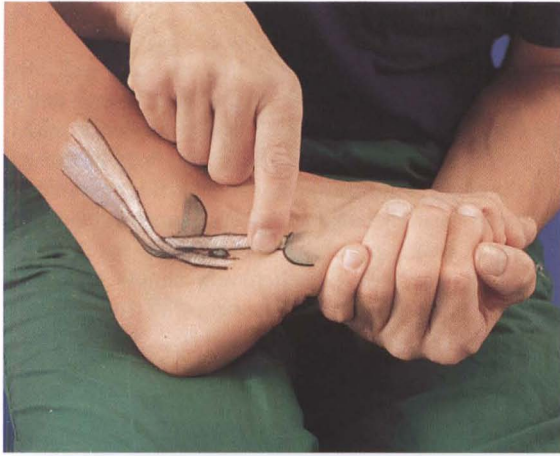

Fig. 7.35 Palpation of the peroneus brevis tendon.

Rhythmical contraction of the peroneals is used to differentiate them from the fibula and the tissue surrounding the Achilles tendon.

At the Malleolus

Both tendons travel on top of one another posterior to the lateral malleolus in their own individual sulcus and are secured by the retinaculum. The synovial sheath of peroneus brevis may even be in contact with the capsule of the ankle. Capsule ruptures therefore often cause bleeding in the synovial sheath. Subluxation of the tendons out of the secure position in the guiding groove occurs as a result of trauma or congenital tendency. The peroneus longus tendon can only be palpated here when the therapist approaches the malleolus from posterior.

On the Lateral Border of the Foot

Both tendons are guided together onto the peroneal trochlea, where the tendon of the peroneus brevis appears from underneath the peroneus longus tendon.

Their communal course ceases at the trochlea and the tendons separate. The peroneus longus tendon travels to the cuboid along the lateral border of the foot and then runs in a plantar and medial direction. This is the third change in direction for the tendon over its entire length. It is usually extremely difficult to palpate the tendon on the lateral aspect of the foot and to differentiate it from the peroneus brevis tendon.

The peroneus brevis tendon can be easily traced down onto its insertion (Fig. 7.35). If it is not possible to observe or transversely palpate the tendon between the trochlea and the base of the fifth MT, the patient is instructed to activate the muscle, that is, to plantarflex, abduct, and pronate the foot.

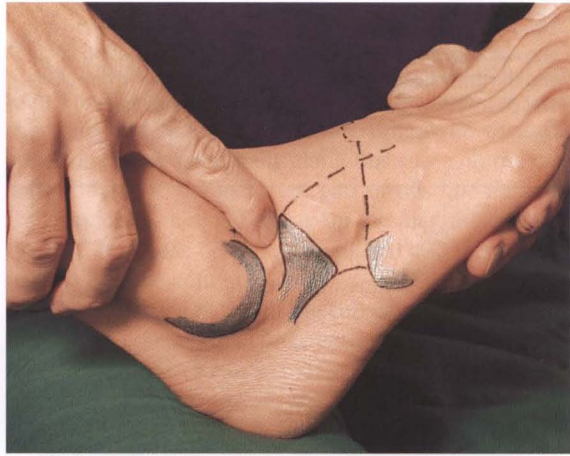


Fig. 7.36 Palpation of the tip of the calcaneus.

Calcaneocuboid Joint

Palpation now leaves the region surrounding the malleolus and concentrates on the localization of the other tarsal bones and their articulations. In particular, this involves identification of the cuboid and its neighboring structures.

Before continuing, a few rules are listed below for this region:

- *Approximately two-thirds of the length of the calcaneus is found posterior to the lateral malleolus and only one-third anterior.*
- *The cuboid is very small on the edge of the foot (approximately one finger-width).*
- *All dorsiflexor tendons lie on the talus.*

The calcaneocuboid (CC) joint space is decidedly the most interesting joint space on the lateral border of the foot. It represents the lateral section of the TT joint line. There are two methods to locate this joint space.

Technique

Method 1

The first method starts on the superior edge of the calcaneus. This edge can be found by first placing the foot in slight inversion (plantarflexion, adduction, and supination) and then palpating anterior to the lateral malleolus toward the sole of the foot. A sharp edge can be felt. The therapist should follow this edge until the head of the talus prevents further palpation (Figs. 7.36 and 7.37).

Incidentally, this is also the access for the tarsal sinus or canal.

From this tip of the calcaneus, the therapist marks a line perpendicular and onto the outer edge of the foot. The CC joint space is found along the entire length of this line (Fig. 7.38).

Tip: The localization is confirmed using a minimal movement. The calcaneus is stabilized proximally by the palpating finger, and the distal hand facilitates slight abduction and pronation. The cuboid now pushes against the palpating finger.

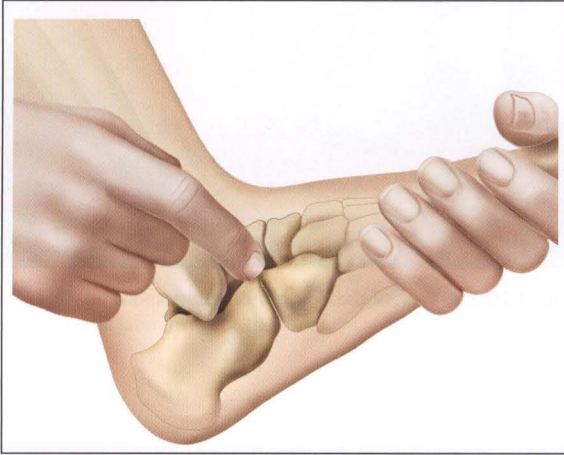

Fig. 7.37 Illustration of the palpation technique.

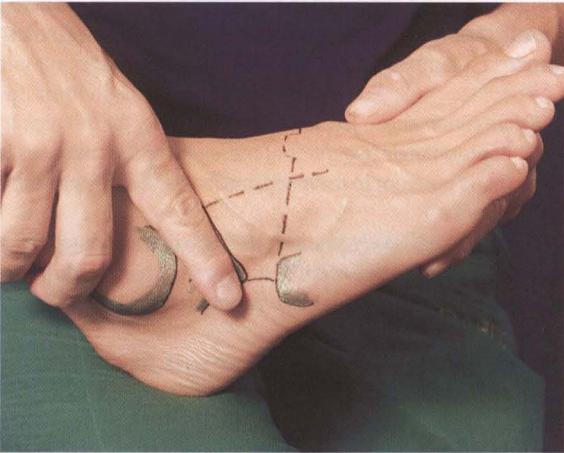


Fig. 7.38 Localization of the CC joint space.

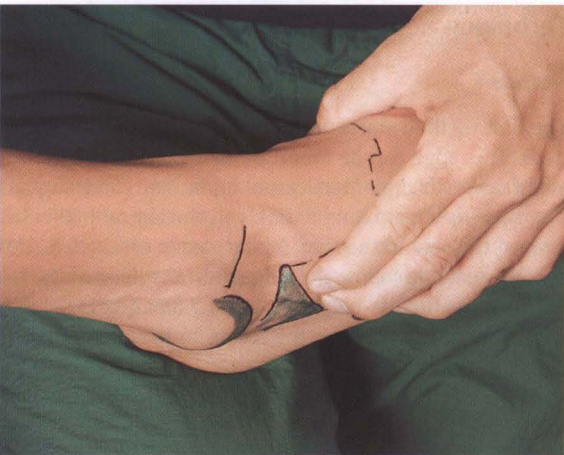

Fig. 7.39 CC joint space—method 2.

Method 2

The second method can be applied particularly well if the foot is very mobile. The distal end of the calcaneus bulges out significantly as the muscle bulk of the intrinsic toe extensors attaches there. The shape of this bony protrusion and the edges of the calcaneus leading to this protrusion is similar to the funnel-shaped bell of a trumpet. This end, in particular, clearly protrudes in mobile feet positioned in extensive inversion. It is then very simple to palpate from distal and locate the joint space. The trumpet is felt here as a clear, hard edge (Fig. 7.39).

Correct localization is confirmed when the foot is passively returned to neutral or moved further into eversion (dorsiflexion, abduction, and pronation). The step is no longer palpable as the cuboid translates dorsally.

Fourth/fifth Metatarsal—Cuboid Joint Space

The joints with the bases of the fourth and fifth MTs belong to the tarsometatarsal joint line. The range of motion at these joints is minimal. The most stable articulations are found centrally, on the dorsum of the foot:

- Intermediate cuneiform—base of the second MT.
- Lateral cuneiform—base of the third MT.

The more mobile joints are found on the edges.

Technique

Localization of these joints starts at the base of the fifth MT. The therapist comes from a proximal direction and hooks around the base (Fig. 7.40). A line is then drawn medially from this point onto the base of the first MT. Its localization has been described in the section “Palpating the Medial Border of the Foot,” page 160. This line is used for orientation, reflecting the position of the tarsometatarsal joint line fairly accurately.

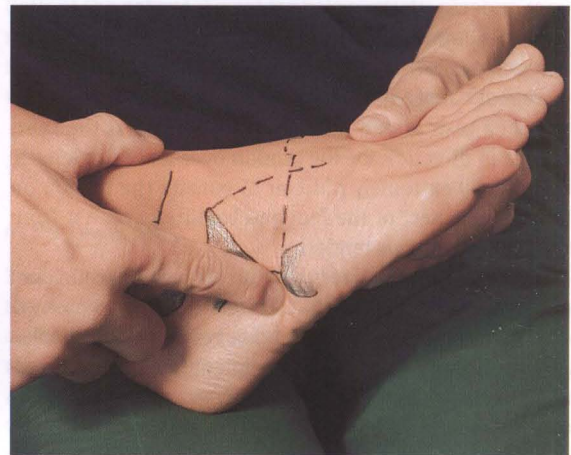


Fig. 7.40 Palpation of the base of the fifth MT.

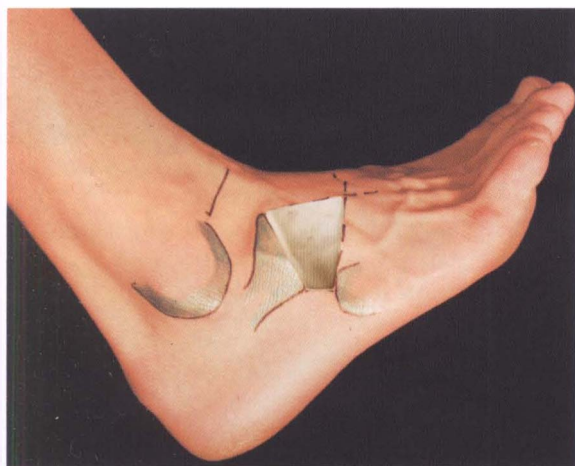


Fig. 7.41 Position of the cuboid.

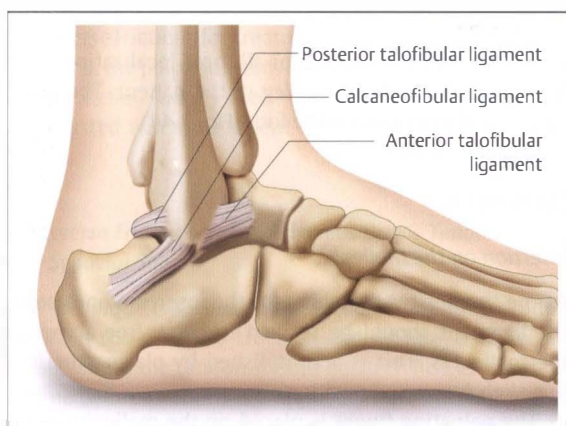


Fig. 7.42 Lateral ligaments

The joint between the cuboid and the bases of the fourth and fifth MTs is roughly found along this line.

Dimensions of the Cuboid

The cuboid articulates with the following bones:

- Calcaneus—proximally:
this joint has already been located.
- Fourth and fifth metatarsals—distally:
these joints are part of the tarsometatarsal joint line. Therapists are also already familiar with them.
- Navicular and lateral cuneiform—medially.

Another true, planar joint is present in these tarsal bones between the cuboid and the medially positioned bones: navicular and lateral cuneiform. It represents an important functional component of the proximal tarsal joints and plays an important role for the kinematic complex of this region. It should not be forgotten when searching for very local restrictions in mobility. A guiding line is

needed to identify this joint space as it cannot be clearly palpated.

Topographical anatomy is of help here, stating that this joint line lies along the elongation of the space between the third and fourth metatarsals. When the therapist slides the finger proximally along this space on the dorsum of the foot, the extended part of this line indicates the position of the joint space. On the plantar surface of the foot, the space between the second and third MTs is used to find the joint line.

The joint space between the cuboid and the medially positioned bones articulating with it therefore extends from plantar–medial to dorsal–lateral. In other words, it extends at a right angle to the plane of the dorsum of the foot.

Several conclusions can be made about the cuboid following palpation and the use of guiding lines (Fig. 7.41):

- It is definitely not shaped like a “cube.”
- The CC joint space is almost as wide as the joint space between the cuboid, the fourth MT, and the fifth MT.
- It is very narrow laterally, only around one finger-width wide.
- The muscle bellies of the intrinsic toe extensors lie superficial to the cuboid, but originate on the calcaneus. The muscle bellies can be clearly demonstrated by strongly extending the toes.

Position of the Lateral Ligaments

The position and course of the ligaments on the lateral side of the ankle are similar to those on the medial side. Of course, some differences exist (Fig. 7.42):

- The ligaments are not as thick laterally.
- No ligament is present that originates from the malleolus and crosses over the TT joint line.
- Certain sections of the ligaments can be reached very easily.

The **anterior and posterior talofibular ligaments** are part of the control and stability mechanisms found in the ankle joint.

The **posterior ligament** cannot be accessed as the peroneal tendons and their retinaculum lie on top of it. Also, the corresponding tubercle on the posterior process of the talus lies inaccessible, deep in the tissue.

In comparison, the course and the insertion of the **anterior talofibular ligament** onto the fibula and talus can be easily accessed (Fig. 7.43). As this is one of the most commonly traumatized structures in the human musculoskeletal system, many physicians and therapists are interested in its exact localization. It extends between the anterior tip of the lateral malleolus and the neck of the talus. According to anatomical literature, the length of the ligament is approximately 1 cm. When the outer edge of the foot is positioned at 90° to the lower leg, the ligament runs parallel to the lateral edge of the foot.

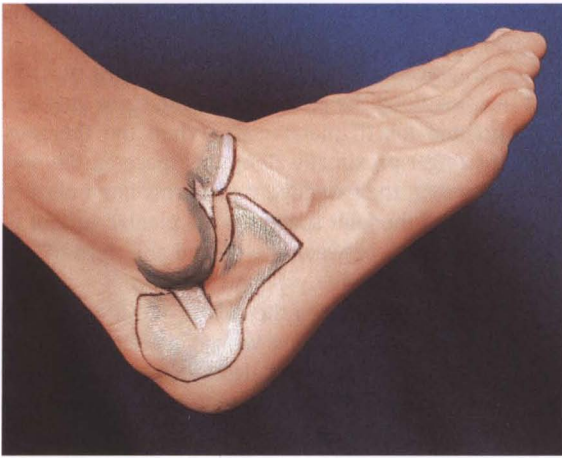


Fig. 7.43 Position of the anterior talofibular and calcaneofibular ligaments.

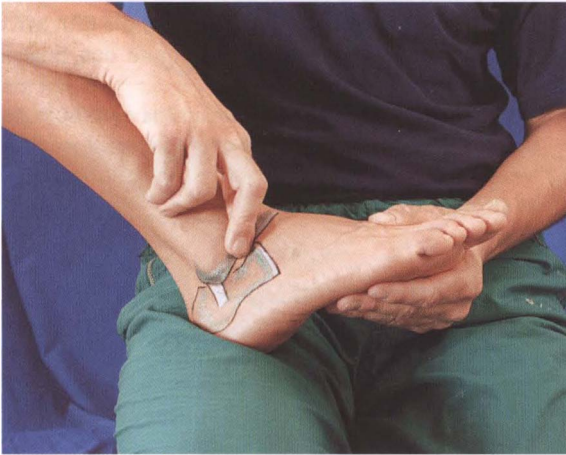


Fig. 7.44 SP for palpation of the anterior tibiofibular ligament.

The third ligament, the **calcaneofibular ligament**, extends between the inferior tip of the fibula and the calcaneus at an angle of around 30° in a posterior-plantar direction (**Fig. 7.43**). It is also difficult to access the entire length of this ligament. Its attachment on the fibula is the only section that can be accessed when the foot is inverted as this position moves the peroneal tendons away from the ligamental insertion.

Anterior Tibiofibular Ligament

This ligament can be accessed at three different locations:

- The insertion on the anterior tip of the malleolus.
- The insertion on the neck of the talus.
- Its course between these two fixed points.

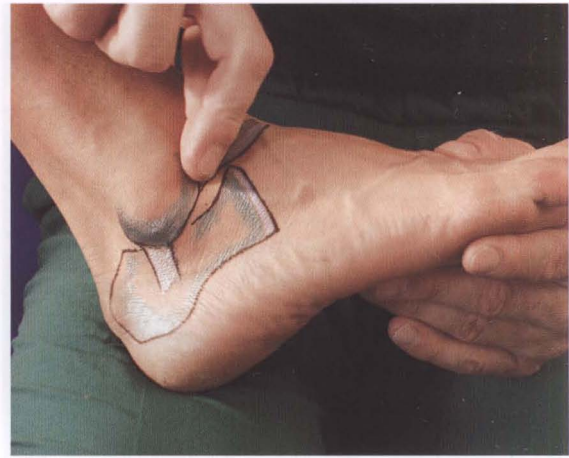

Fig. 7.45 Transverse frictions on the anterior tibiofibular ligament at the insertion on the malleolus.

The proximal hand is used for all three localizations. The forearm rests on the lower leg of the patient. The distal hand is used to position the foot (**Fig. 7.44**).

Technique

Insertion on the Malleolus

As the therapist is searching for the insertion onto bone, the ligament should be relaxed to allow free access to the malleolus. This is accomplished by placing the foot in a slightly everted position.

The palpating finger is placed on the malleolus, with the middle finger pressing down on the finger from above. The forearm is extensively pronated during this movement (**Fig. 7.45**).

Pressure is applied to the palpating movement from plantar to dorsal and reduced in the opposite direction.

Middle Section

The technique applied here corresponds to the previous description, with a few modifications:

- The forearm is not pronated as much.
- The finger pad is placed between the two bony fixed points.
- The distal hand moves the foot into an inverted position. This tightens the ligament and stabilizes it beneath the palpating finger. If a patient presents with injury to the structure following a varus-inversion trauma, the therapist should pay attention to pain-free positioning of the foot.

Insertion on the Talus

The procedure is characterized by:

- The foot being positioned in slight eversion to relax the ligament.

- The arm being positioned in slight supination.
- The pad of the index finger coming into contact with the neck of the talus.

Tips for Assessment and Treatment

Several examples demonstrate the application of accurate in vivo palpation of the lateral border of the foot. These include techniques treating ligamentous structures, synovial sheaths, and insertions, as well as manual therapy techniques that target the joints.

Technique

Transverse Frictions at the Anterior Tibiofibular Ligament

Transverse frictions for treatment are administered as described in the palpation above and will not be explained in further detail. Merely the intensity and duration should be adjusted when treatment is the aim of the intervention.

Transverse Frictions at the Peroneus Brevis Tendon and Synovial Sheath

The technique is similar to the localization of the tendon between the peroneal trochlea and its insertion. To aid stabilization, the tendon should be stretched to a certain degree before frictions are applied. Therefore, the foot is positioned in adduction, supination, and, if necessary, some dorsiflexion.

The index finger transversely palpates and treats the structure with or without the help of the middle finger. The therapeutically effective pressure is applied during the movement from plantar to dorsal (Fig. 7.46).

Transverse Frictions at the Insertion of the Peroneus Brevis

It is imperative that the peroneus brevis tendon is relaxed and does not impede free access to the base of the fifth MT. The proximal hand therefore moves the foot into an abducted and pronated position. The index finger of the distal hand is now used to palpate and the thumb placed medially to aid stability (Fig. 7.47).

The insertion for the peroneus brevis is not on the side of the base, but rather on the proximal end. For this reason, the distal forearm is positioned in pronation so that the index finger is coming from a proximal direction and can push down on the insertion. The middle finger can be positioned on top of the index finger for support (Fig. 7.48). The therapeutically effective movement is conducted by applying pressure from plantar to dorsal.

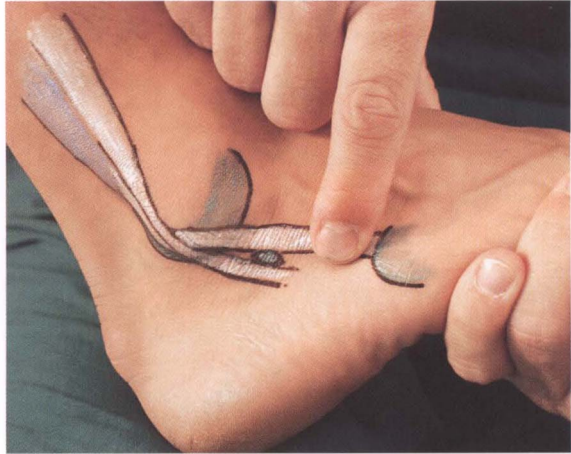


Fig. 7.46 Transverse frictions on the peroneus brevis—technique applied to the tendon.

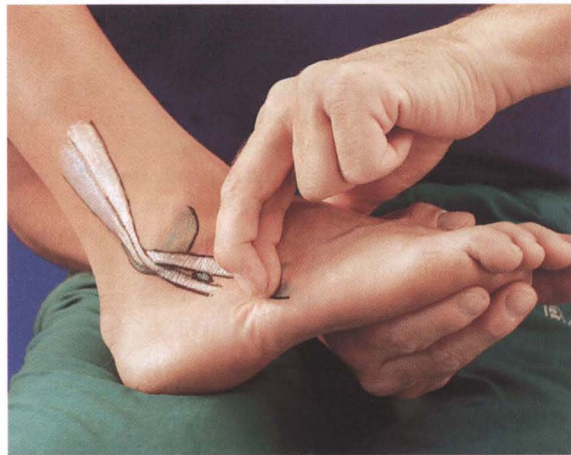


Fig. 7.47 Transverse frictions on the peroneus brevis—technique applied to the insertion.

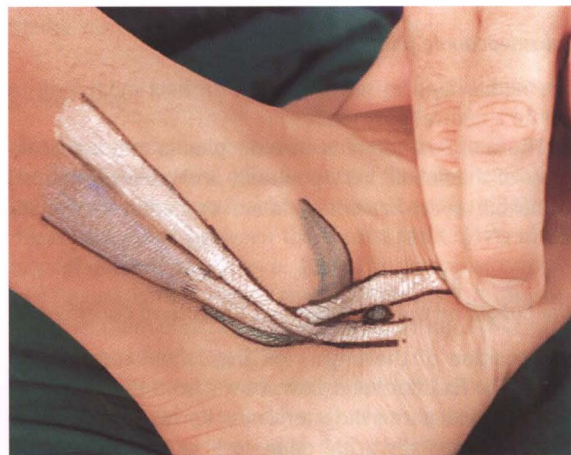


Fig. 7.48 Technique applied to the insertion—alternative view.

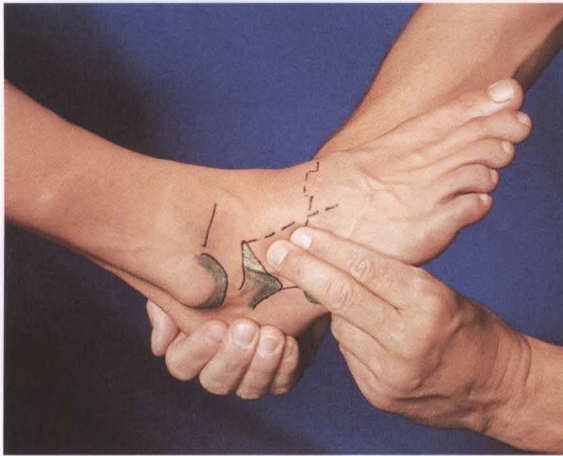

Fig. 7.49 Test of joint play at the CC joint.

Tests of Joint Play at the Proximal Tarsal Joints

This joint complex includes the talonavicular joint medially as well as the articulations between the cuboid and the calcaneus, navicular, and lateral cuneiform. It is crucial to know that both joints move simultaneously when the cuboid is being mobilized and that it is only the fixed component of the joint that decides which joint is being assessed and which joint may take part in the movement.

Therefore, the prerequisites for the successful application of techniques targeting the tarsal joints are:

- Exact knowledge of the position of the respective tarsal bones.
- Exact knowledge of the position and alignment of the joint spaces.
- Experience and information regarding the applicable intensity and speed of the technique.

Test of Joint Play

Calcaneocuboid Joint

The medial hand is used to stabilize the heel and the entire foot in a neutral position.

The lateral hand holds onto the plantar and dorsal aspects of the cuboid very pointedly and moves it parallel to the joint space in a dorsal–lateral or plantar–medial direction (Fig. 7.49).

The Cuboid on the Navicular and the Lateral Cuneiform

The position of the fingers on the cuboid remains the same. The fixating hand now moves from the calcaneus to the navicular and the lateral cuneiform, both of which are found medially at the same level as the cuboid (Fig. 7.50).

The cuboid is again mobilized in the same manner. The calcaneus is now permitted to follow this movement to some extent.

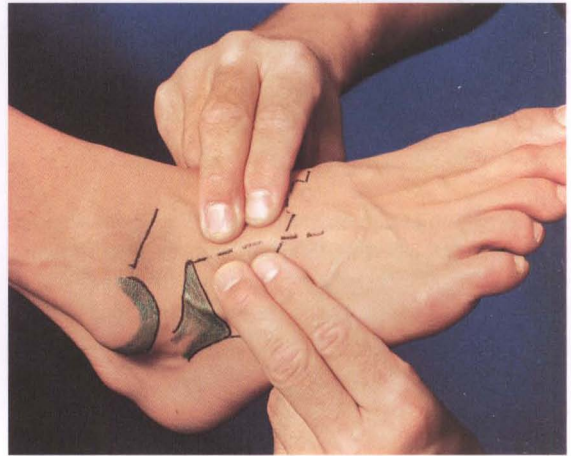


Fig. 7.50 Test of joint play at the “intermediate joint.”

Palpating the Dorsum of the Foot

Overview of the Structures to be Palpated

- Joint space of the ankle.
- Neck and head of the talus.
- Blood vessels on the dorsum of the foot.
- Neural structures on the dorsum of the foot.

Summary of the Palpatory Process

A main concern during palpation of the dorsum of the foot is the localization of the talus, as articulating surface for the ankle joint and the proximal tarsal joints.

Vascular and neural structures are also accessible on the dorsum of the foot and may be part of assessment and treatment.

Starting Position

An SP can be selected that corresponds to the descriptions seen in the palpation of either the medial or the lateral borders of the foot. It is important that the dorsum of the foot is freely accessible and that the foot be able to move easily.

Joint Space of the Ankle

The joint space has already been successfully accessed when the outer borders of the medial and lateral malleoli are encircled. The thick tendons of the dorsiflexors make accurate localization significantly more difficult. It is nevertheless very important that localization be exact when applying certain techniques that target the joint.

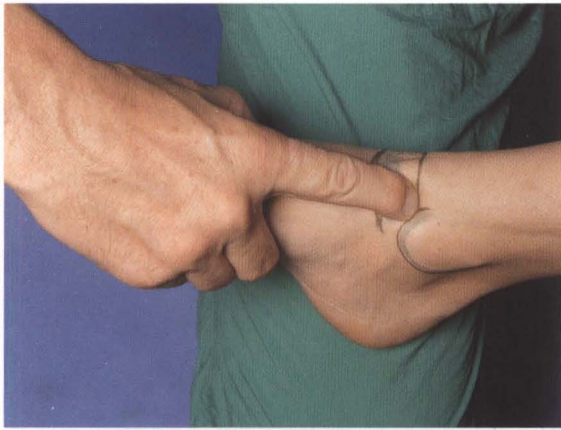


Fig. 7.51 Site used to access the ankle joint.

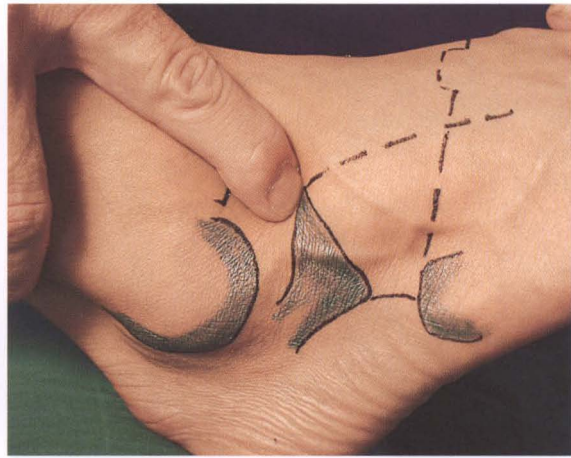


Fig. 7.52 Hooking around the talus from lateral.

Technique

Similar to the procedure for the radiocarpal joint, the joint space is made accessible by relaxing the superficial soft tissues by passively positioning the ankle in slight dorsiflexion.

To demonstrate the entire width of the anterior edge of the tibia, the therapist can choose to access the joint from either the medial or lateral malleolus, using the index finger for palpation.

The talus is found immediately distal to this edge (Fig. 7.51).

Neck and Head of the Talus

Technique

Localization from Lateral

In the section examining palpation of the lateral border of the foot, it has already been described how the fingers can push against the talus from a lateral position by first palpating the edge of the calcaneus (Fig. 7.52). The tarsal sinus is also found here.

The lateral dimensions of the talus are now clarified.

The position of the ankle in plantarflexion/dorsiflexion determines which part of the talus is being reached this way (neck or head of the talus).

This is more likely to be the neck of the talus when in plantarflexion and the head of the talus in dorsiflexion, and is linked to the pattern of rolling and gliding of the articulating surfaces in the ankle.

Localization from Medial

The talus can be accessed from medial at several points:

- Medial tubercle of the posterior process of the talus.
- Between the medial malleolus and sustentaculum tali.
- Between the medial malleolus and the navicular tuberosity.

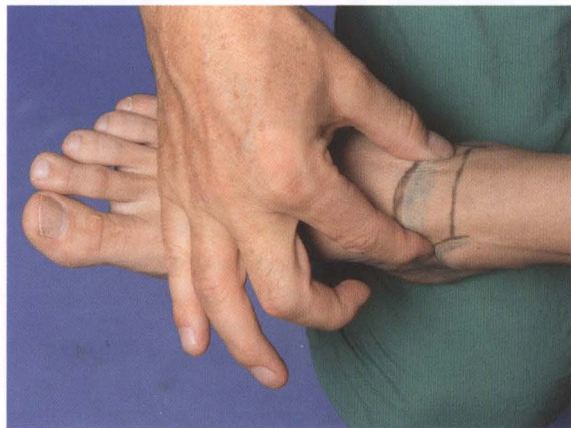

Fig. 7.53 Identifying the entire width of the talus.

The localization of these bony reference points has already been extensively described in the section "Palpating the Medial Border of the Foot" above, page 160.

Dorsal Talus

Two important points should be connected to illustrate the dimensions of the dorsal aspect of the talus: the lateral point, where the talus can be accessed (see Fig. 7.52), and the medial point, between the medial malleolus and the navicular tuberosity (see p. 160). The therapist can use two fingers to hook around these two points. The distance between them illustrates the width of the talus (neck and head of the talus) (Fig. 7.53).

The therapist can now verify the two corresponding rules mentioned previously: all tendons belonging to the dorsiflexors of the ankle and the extensors of the toes are found on the dorsal surface of the talus as they pass over the ankle. There is no tendon dorsal to the calcaneus, thus the width of the talus can be easily recognized by the clearly visible tendons.

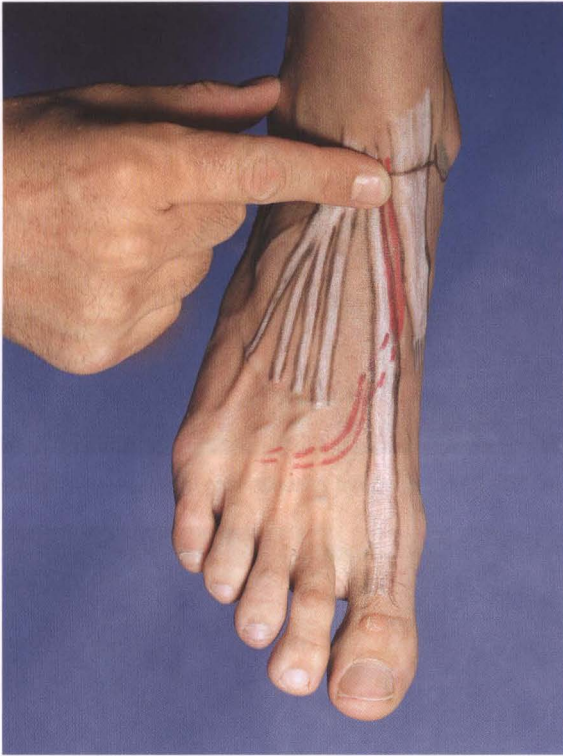


Fig. 7.54 Palpation of the anterior tibial artery.

The navicular is equally as wide as the talus and is found immediately distal to it.

Blood Vessels on the Dorsum of the Foot

Technique

Anterior Tibial Artery

The access in the ankle region that is used to locate the artery is fairly reliable. According to Netter (1994), the anterior tibial artery lies immediately lateral to the tendon of the extensor hallucis longus. Winkel (2004) states that its position is rather variable and recommends that therapists be patient and use only gentle pressure to locate the blood vessel.

The tendon of the long extensor of the first toe is therefore made visible using an isometric contraction. A finger pad is placed flat, applying only gentle pressure:

- laterally, between the tendons of the extensor hallucis longus and extensor digitorum longus; and
- medially, between the tendons of extensor hallucis longus and tibialis anterior, remaining there until the pulse can be clearly felt (Fig. 7.54).

Once the artery has been found, its pulse can be followed proximally for some distance along the lower leg.

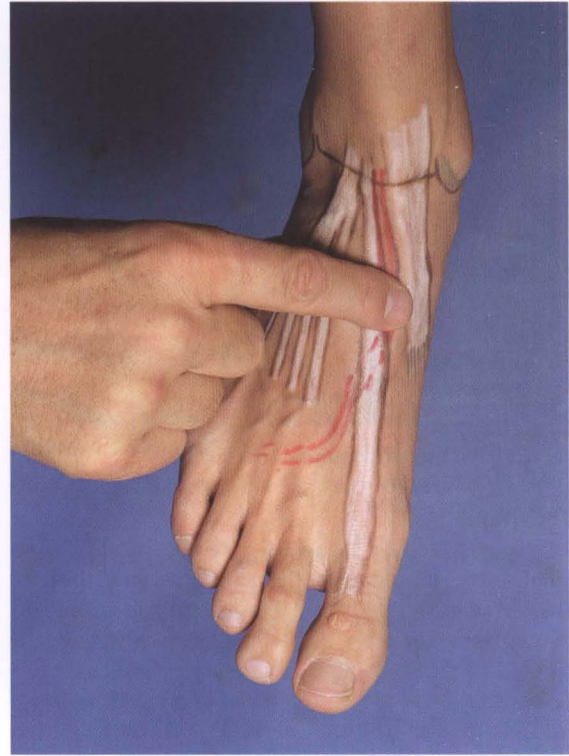


Fig. 7.55 Palpation of the dorsalis pedis artery.

Dorsalis Pedis Artery

This artery is palpable in a distal direction (still parallel to the tendon of the extensor hallucis longus) until the mid-foot region. It then travels to the surface distally, between the second and third metatarsals, as the dorsalis pedis artery. This artery can again be felt by palpating very locally and flatly (Fig. 7.55).

Neural Structures on the Dorsum of the Foot

Both branches of the peroneal nerve cross dorsally over the ankle. They travel in different tissue layers and have only sensory qualities.

Technique

Deep Peroneal Nerve

The deep peroneal nerve accompanies the anterior tibial artery over its entire length. It becomes superficial in the distal lower leg as it exits the anterior compartment. Proximally, the nerve can be accessed with some effort slightly superior to the joint space of the ankle. If palpated with pointed fingers, it is felt as a rolling structure that does not pulsate or react to the contraction of muscles.

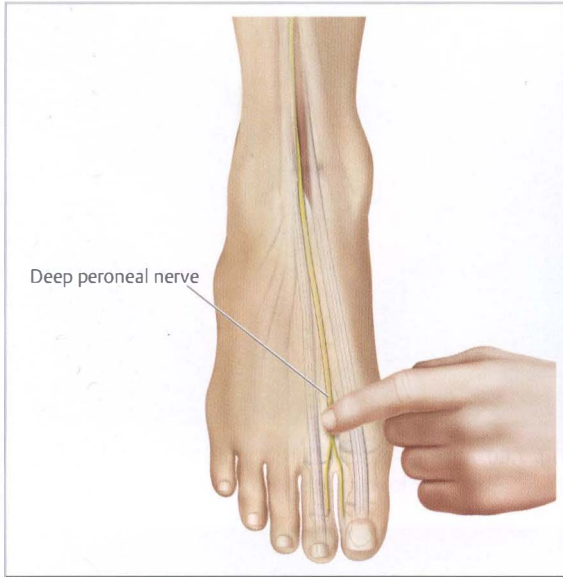


Fig. 7.56 Palpation of the deep peroneal nerve.

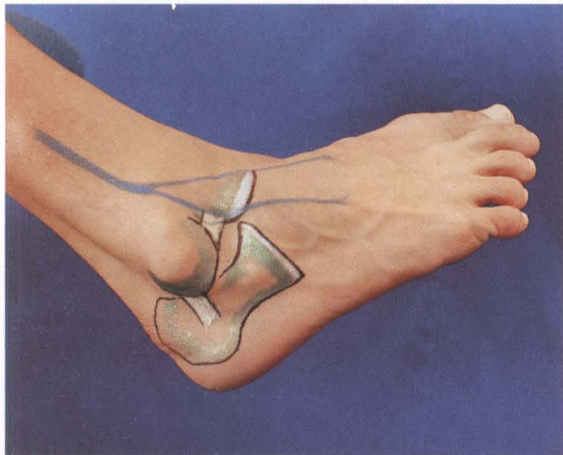


Fig. 7.57 Position of the branches of the superficial peroneal nerve.

The nerve then disappears deeper into the dorsal fascia of the foot and can be neither accessed nor accurately located beneath the different tendons. It is significantly easier to palpate the nerve again on the distal metatarsus adjacent to the dorsalis pedis artery (Fig. 7.56).

Superficial Peroneal Nerve

Two superficial neural structures can be located on the dorsum of the foot that are not covered by the retinaculum. They are therefore easier to find and are sometimes visible as a fine, white line (Fig. 7.57).

Both of these structures belong to the superficial peroneal nerve:

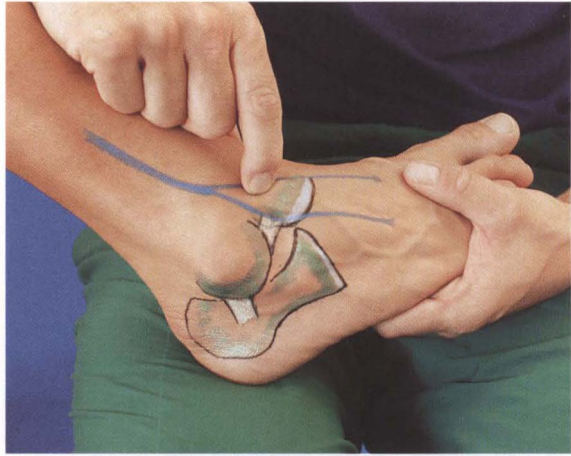


Fig. 7.58 Palpation of the branches of the superficial peroneal nerve.

- Medial dorsal cutaneous nerve.
- Intermediate dorsal cutaneous nerve.

The entire length of these branches can be seen and palpated by passively positioning the foot in extensive inversion. In some cases, the intermediate dorsal cutaneous nerve can be followed onto the head of the fourth MT.

A suitable palpation technique is a pointed, transverse palpation where therapists once again attempt to hook around these structures as they would a guitar string (Fig. 7.58).

It is sometimes possible to locate the division of the superficial peroneal nerve into both of its branches through palpation on the distal lower leg.

Tips for Assessment and Treatment

Techniques Targeting the Ankle Joint

A variety of manual therapy techniques fall back on the therapist's knowledge of local anatomy. This is not so much about the ability to grasp the tibia and fibula, but the ability to reach the talus near the joint. It is often observed that not only the talus is being fixated, but also the distally located tarsal bones. This results in several joints moving and the technique does not exclusively act on the ankle joint.

Example—"Anterior-Posterior Glide of the Talus"

This technique is suitable to improve dorsiflexion of the ankle. The accurate placement of the mobilizing hand on the talus guarantees successful treatment (Fig. 7.59).

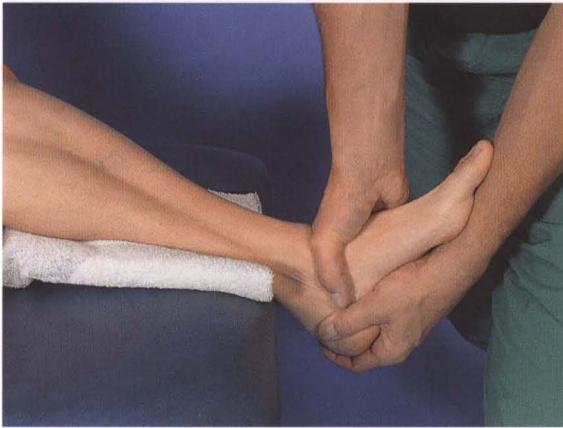

Fig. 7.59 Anterior-posterior glide of the talus.

Example—“Anterior-Posterior Glide of the Tibia on the Talus”

This technique, used for both assessment and to improve plantar flexion of the ankle, depends entirely on the complete stabilization of the talus during mobilization of the lower leg. A common mistake when conducting this procedure is to place the fixating hand too far from the talus (Fig. 7.60).

Test of Range of Motion in the Talocalcaneonavicular Joint

Another example that can be used to clarify the application of local topographical knowledge is the testing of mobility in the TCN joint.

It is well known that the TCN joint is an extremely complex construction and is important for functional foot movements during weight-bearing. Range of motion is assessed in the following directions:

- Varus—medial tilting of the calcaneus.
- Valgus—lateral tilting the calcaneus.

This is quite difficult and depends on the therapist's sense of touch.

The varus and valgus movements are movements of the calcaneus that can be conducted without difficulty. They are very small and easily cause the talus to move in the ankle mortise. The palpation of movement in the talus is a sign that movement in the TCN joint has ceased.

One hand facilitates the tilting of the calcaneus and the other hand palpates the medial and lateral aspects of the talus to identify movement of the talus (Fig. 7.61).

The therapist should know where to reach the sides of the talus. From the previous palpations of the medial and lateral aspects, it is evident that the talus can be accessed:

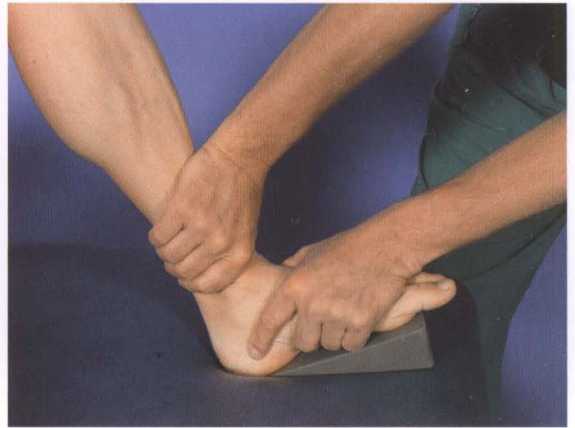

Fig. 7.60 Anterior-posterior glide of the tibia on the talus.

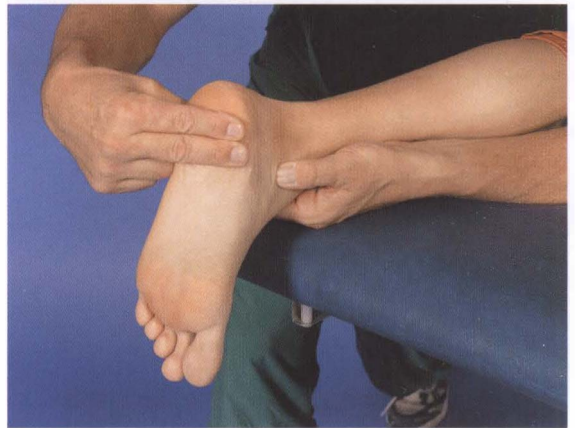


Fig. 7.61 Testing range of motion at the TCN joint.

- medially, between the medial malleolus and sustentaculum tali; and
- laterally, directly anterior to the lateral malleolus.

Test for Arterial Blood Flow

The arteries at the ankle and along the dorsum of the foot are palpated to assess the arterial supply in the foot. The localization of the foot pulse is therefore one of the skills performed by physicians and therapists.

Endangering Neural Structures

Transverse frictions conducted on neural structures should be refrained from at all costs. There is one situation that can lead to unintentional irritation of a neural structure on the dorsum of the foot.

The superficial peroneal nerve and one of its branches (intermediate dorsal cutaneous nerve) can pass directly superficial to the anterior tibiofibular ligament (Fig. 7.62).

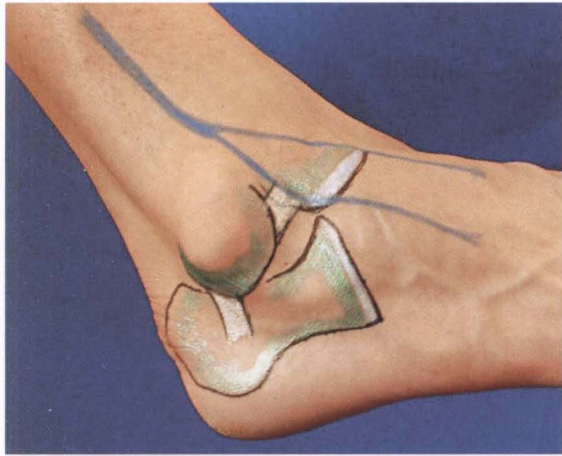


Fig. 7.62 Neural structures on the dorsum of the foot.

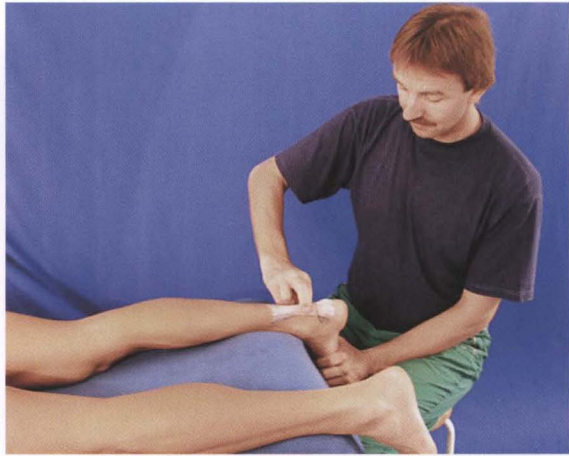

Fig. 7.64 SP for palpation of the Achilles tendon.

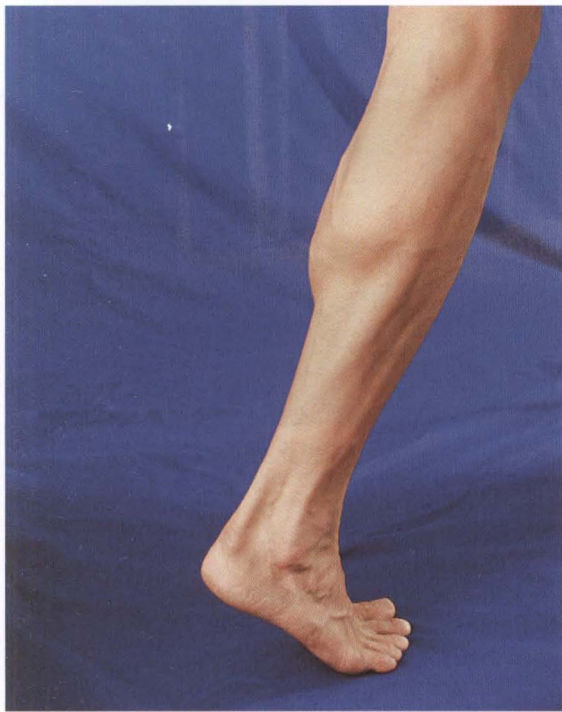


Fig. 7.63 Triceps surae and the Achilles tendon.

This ligament is one of the most commonly injured ligaments in the musculoskeletal system and is therefore quite frequently subject to surgical intervention or treatment with local frictions.

The position of the nerve branch superficial to the ligament can, in some circumstances, lead to the nerve becoming entwined in the surgical suture, which causes neural irritation. The therapist may also irritate this neural structure during treatment with local transverse frictions. In both cases, sensory disturbances, pain, and, at times, hyperesthesia indicate the presence of neural irritation.

Palpation of the Posterior Foot

Overview of the Structures to be Palpated

- Borders of the achilles tendon.
- Insertion of the triceps surae.
- Palpation of the tendon.

Summary of the Palpatory Process

Palpation of the posterior aspect is only used to accurately identify the Achilles tendon and its insertion (Fig. 7.63).

The palpatory techniques and their therapeutic use (otherwise discussed in their own section above, "Tips for Assessment and Treatment") merge together.

Starting Position

It is recommended that the patient be positioned in prone-lying with the foot hanging over the edge of the table. It is then easy to access the Achilles tendon, and the foot can move freely.

The therapist usually sits distal to the foot (Fig. 7.64).

Borders of the Achilles Tendon

The collagenous parts of the triceps surae are bundled together in the Achilles tendon, the calcaneal tendon (Fig. 7.65). The heads of the gastrocnemius form a tendinous plate. The soleus muscle radiates into this plate from anterior. These fibers taper more distally into a free-running tendon that inserts into the calcaneal tuberosity.

The attachment onto the bone is by no means limited to one point. The tendon broadens over the entire width of the calcaneus and is visible down onto the plantar aspect of the calcaneus in anatomical specimens.

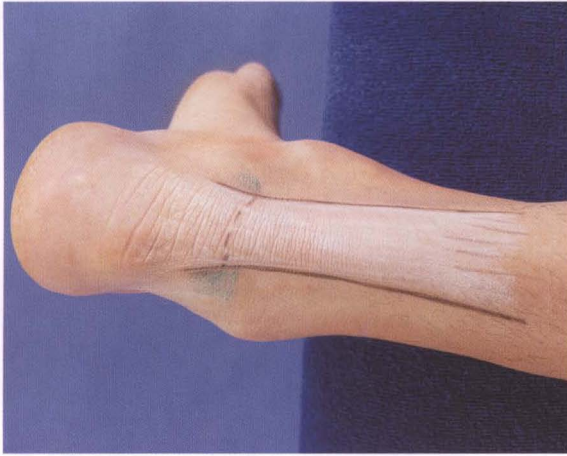


Fig. 7.65 Illustrating the Achilles tendon.

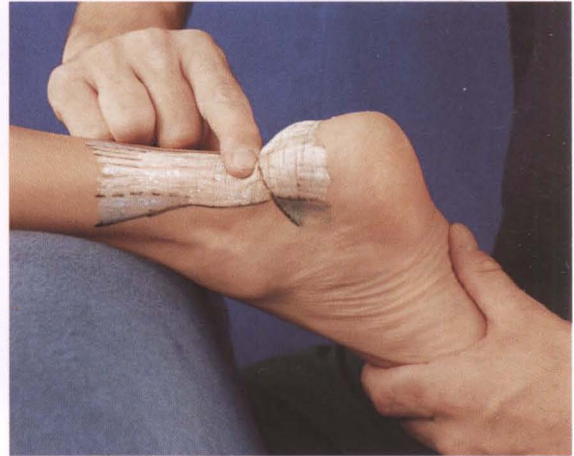

Fig. 7.67 Junction between tendon and insertion.

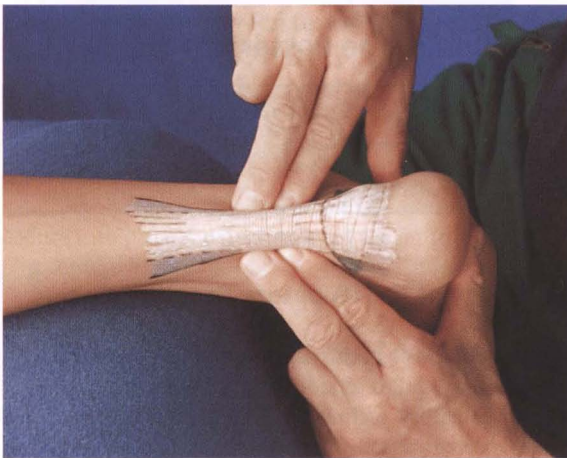


Fig. 7.66 Borders of the Achilles tendon.

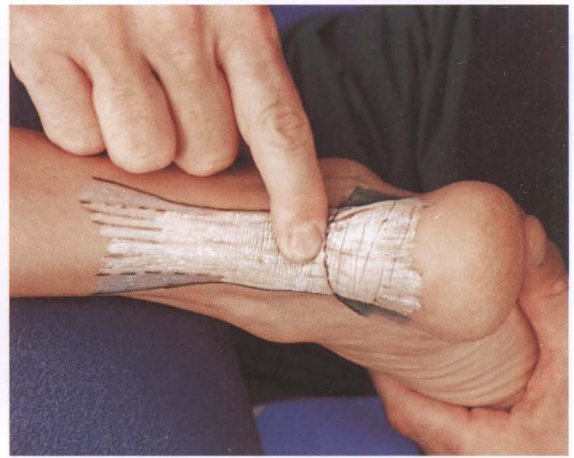

Fig. 7.68 Palpation of the insertion.

The clinically most important section of the tendon is found between the tendinous plate and the proximal border of the calcaneus.

Technique

Side Borders

Starting at the calcaneal tuberosity, the therapist palpates proximally and attempts to mark the side borders of the tendon (Fig. 7.66). These borders are followed proximally until discrete borders can no longer be felt in the increasingly wide tendon. The aponeurosis with the deeper-lying soleus begins at this point.

Insertion of the Triceps Surae

The start of the area of insertion for the triceps surae, the proximal border of the calcaneal tuberosity, can be clearly demonstrated.

Technique

The foot is positioned passively in extensive plantar flexion. Tension in the Achilles tendon is relieved by the approximation of the triceps surae.

This is now palpated from proximal to distal, with firm pressure applied (Fig. 7.67). The transition from tendon to tuberosity is identified by the sudden change from a firm-elastic feel to a significantly stronger form of resistance (Fig. 7.68). The area of tendon insertion starts at this point. Bursae are found here both subcutaneous and underneath the tendon (subcutaneous calcaneal bursa and the bursa of the calcaneal tendon). Local pressure can provoke pain in these bursae when inflamed.

Tip: The junction between the tendon and calcaneus can also be identified when the calf muscles are contracted. Significantly more pressure must be applied by the palpating fingers.

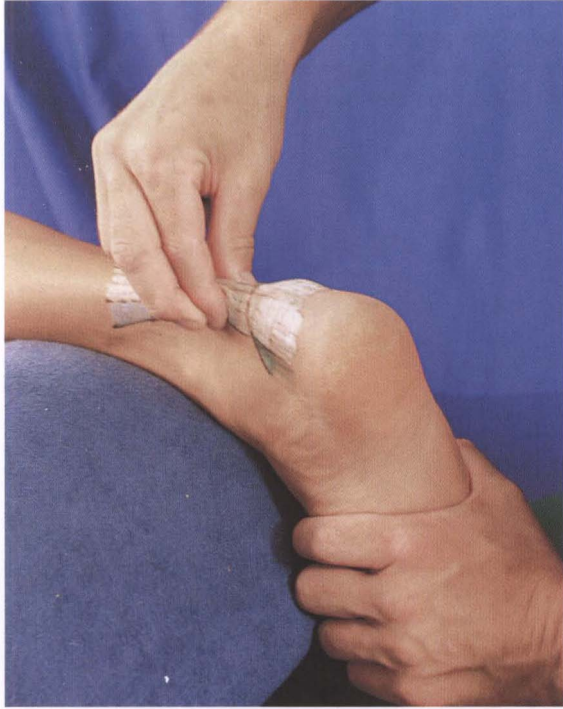


Fig. 7.69 Bilateral transverse frictions.

Palpation of the Tendon

Now that the clinically important areas have been identified in which tendopathy, bursitis, and insertion tendinopathy may be found, the tendon itself will be palpated.

The aim is to locate painful sites within the tendon that can be treated, for example, with the different methods used in electrotherapy. A variety of transverse-friction techniques are used to find these sites.

Technique

Method 1

This palpation technique uses the pincer grip by simultaneously using the pads of the thumb and the index finger (Fig. 7.69).

It is particularly suitable for the localization and treatment of conditions at the edge of the tendon.

Technique procedure:

1. The tendon is initially placed under tension by passively dorsiflexing the ankle.
2. The finger is moved anteriorly without applying pressure (toward the floor).
3. The thumb and index finger pinch into the tissue.
4. With sustained pressure, the fingers are then pulled posteriorly (toward the ceiling). This is the diagnostic and/or therapeutically effective component of the technique.

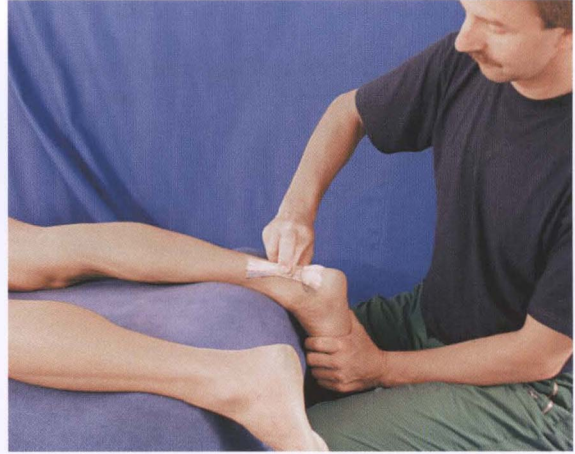


Fig. 7.70 SP for posterior transverse frictions.

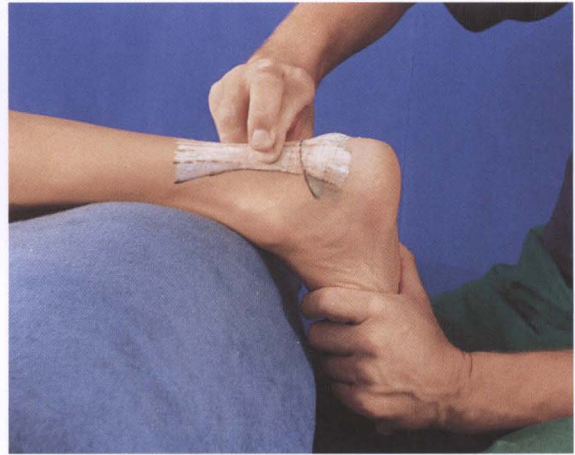


Fig. 7.71 Posterior transverse frictions—detailed view.

Tip: It is not permissible to rub the skin at any phase of the technique. Most likely, rubbing the skin will result in blistering. The tendon is palpated in steps of 1 cm if this technique is being used diagnostically to identify the most affected part.

Method 2

Only the index finger is used in this method.

Once again, the therapist is sitting distal to the foot. The tendon is initially placed under tension again by positioning the ankle in end-range dorsiflexion. This tension is important so that the technique can be performed on a stable tendon. The palpating finger would constantly slide off the tendon if the tendon were relaxed.

The palpating hand moves toward the side of the tendon (Figs. 7.70 and 7.71).

The middle finger is placed on top of the index finger, which is positioned on the tendon. The thumb rests on the malleolus on the side of the foot, stabilizing the hand.

In the illustrated example, the index finger maintains skin contact and moves medially without applying pres-

sure. Pressure is applied to the tendon as the finger moves laterally.

As with the first method, this method is also used for both diagnosis and treatment.

This technique can be used to identify the most painful point by palpating the entire length of the tendon. From experience, this is approximately 2 cm proximal to the edge of the calcaneal tuberosity.

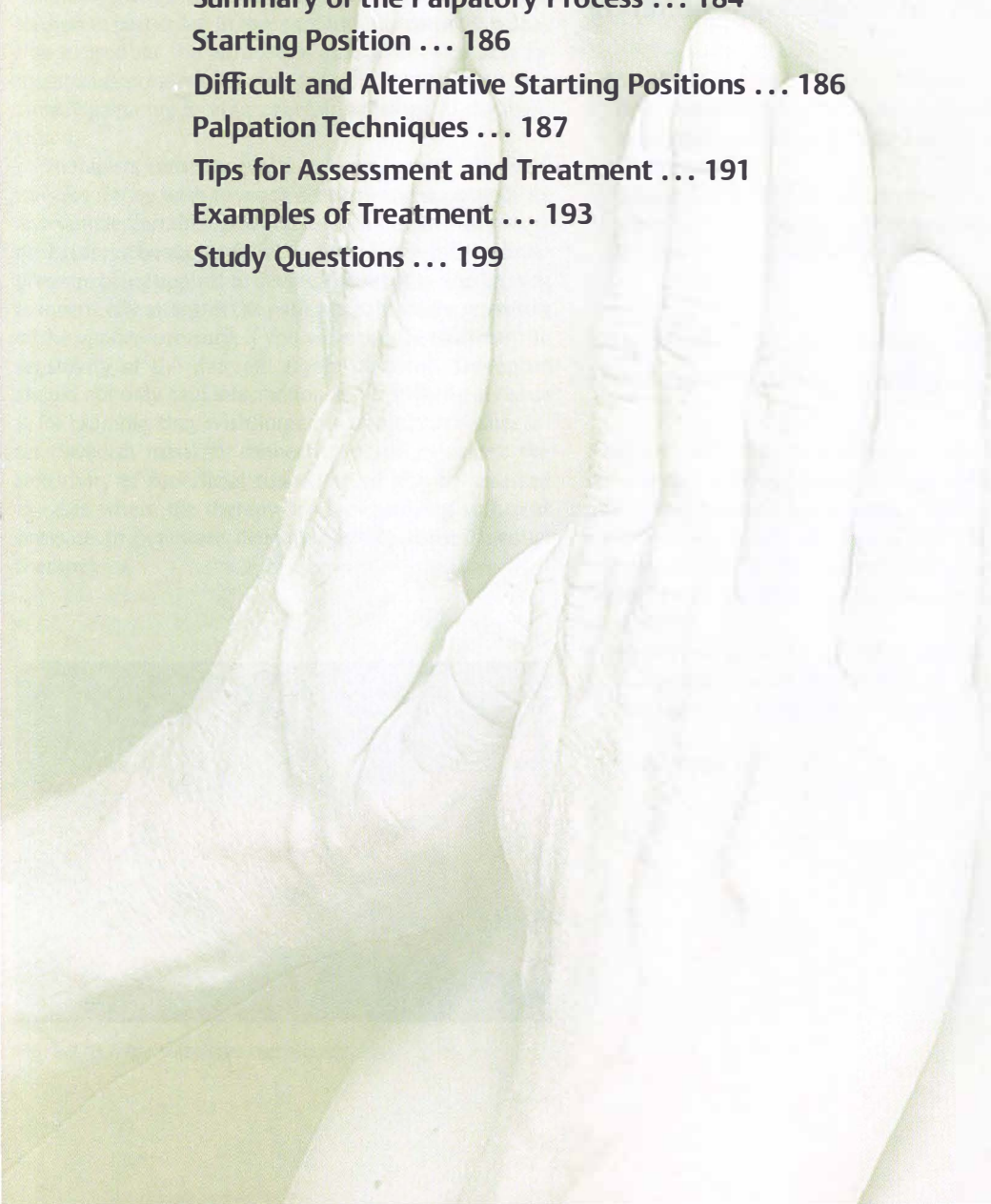
Study Questions

1. Where can the therapist access the medial aspect of the calcaneus? Which ligaments are attached to the calcaneus?
2. The posterior part of the talus (posterior process of the talus) forms a groove. Which tendon travels through this groove?
3. Which important bony reference point is marked by the insertion of the tibialis posterior?
4. What is the alignment of the joint space between the talus and navicular?
5. How many joint spaces can be identified on the medial side?
6. Where is the tarsal canal, otherwise known as the "tarsal tunnel"?
7. Which ligamental reinforcements of the capsule of the ankle control the biomechanics during dorsiflexion and plantarflexion?
8. In which foot position is it easy to locate the joint space between the calcaneus and cuboid?
9. Where can the neural structures or arteries be palpated in the foot?

THIS PAGE INTENTIONALLY
LEFT BLANK

8 Soft Tissues

Significance and Function of Soft Tissues ...	183
Common Applications for Treatment ...	183
Required Basic Anatomical and Biomechanical Knowledge ...	183
Summary of the Palpatory Process ...	184
Starting Position ...	186
Difficult and Alternative Starting Positions ...	186
Palpation Techniques ...	187
Tips for Assessment and Treatment ...	191
Examples of Treatment ...	193
Study Questions ...	199



THIS PAGE INTENTIONALLY
LEFT BLANK

8 Soft Tissues

Significance and Function of Soft Tissues

Skin and muscles represent independent sensory input organs for treatment methods based on reflexes (connective-tissue massage) and energy flow (acupuncture) as well as locally applied treatment methods (e.g., Swedish massage).

Systematic palpation of these tissues has long been a topic of discussion. In connective-tissue massage, changes in skin consistency, for example, are attributed to specific disorders of the inner organs or the vertebral column. Classical massage treatment targets pathological muscle tension in particular. In these treatment methods, palpation is used for the purpose of assessment and also for monitoring progress. Massage is rarely used without previously palpating local or general hardening in the muscles.

Therapists must manually palpate through skin and muscles if they wish to reach deeper-lying structures. As an example, certain segmental tests and treatment procedures cannot be successfully conducted without moderate pressure being applied to deeper tissues. It would be easy to incorrectly interpret the patient's pain solely as a result of the applied pressure, if you were unable to assess the sensitivity of the different layers of tissue. Therapists should not only gain information about superficial tissue if, for example, they wish/intend to treat these tissues later (Swedish massage, connective-tissue massage); the sensitivity of superficial tissue should also be assessed in cases where the therapy involves applying sufficient pressure to penetrate deeper layers of tissue (manual therapy).

In particular, patients with chronic back symptoms are the least able to provide exact information about their symptoms. These patients are frequently affected by hyperalgesia or hyperesthesia as a result of central sensitization. They have difficulty describing the exact location of their symptoms, and the corresponding interpretation of tests that use direct pressure is unsuccessful.

When therapists are unable to recognize such changes, they tend to attribute the symptoms to the skin, the muscles, or bony parts, depending on which area their work mainly focuses on.

Common Applications for Treatment

Skin and muscle are frequently the tissue targeted in:

- Reflex-based treatment forms: connective-tissue massage, reflex zone therapy based on the work of Gläser/Dalichow, etc.
- Regional or locally applied techniques: Swedish massage, heat therapy, soft-tissue techniques in manual therapy (Fig. 8.1), and more.

Required Basic Anatomical and Biomechanical Knowledge

Even beginners only need a short amount of time to gain the relevant prerequisite knowledge. Being able to initially orient yourself using general bony and muscular structures in the neck, back, and pelvis is sufficient. The techniques used to locate these structures will be described in the coming sections. Two prerequisites should be created:

- To conduct an orienting and systematic palpation.
- To be able to describe the location of palpated structures well and to document these findings.

(See also Table 8.1.)

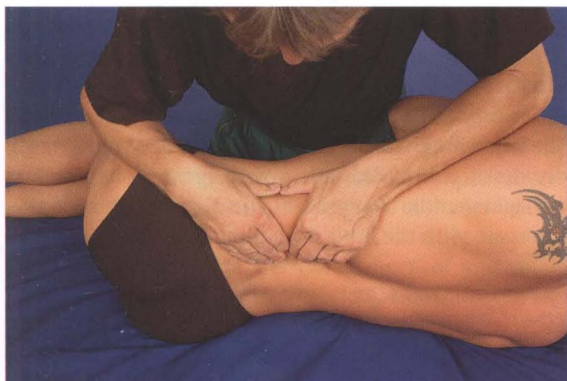


Fig. 8.1 Lumbar soft-tissue technique.

Table 8.1 General orientation from posterior

Bony Orientation (Fig. 8.2)	Muscular Orientation (Fig. 8.3)
Edge of the sacrum	Gluteal muscles
Iliac crest	Erector spinae, especially: <ul style="list-style-type: none"> – multifidus lumborum – spinalis thoracis – semispinalis cervicis
Greater trochanter	Latissimus dorsi
Ischial tuberosity	Descending part of trapezius
All accessible spinous processes and ribs Borders, angles, and protruding processes of the scapula From the occiput to the mastoid process	

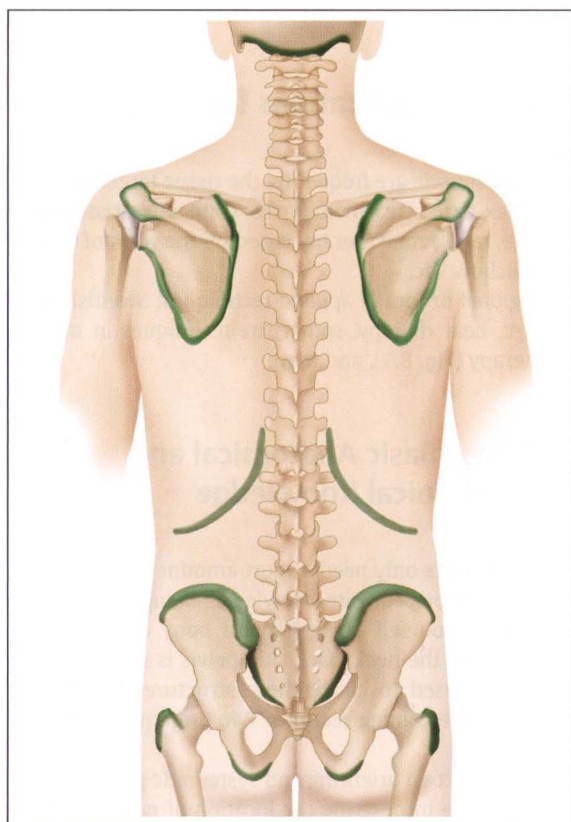


Fig. 8.2 Bony orientation

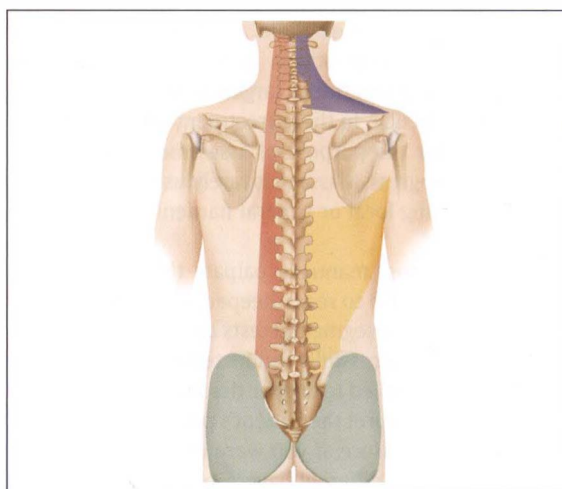


Fig. 8.3 Muscular orientation

Criteria for Palpation

What will be assessed:

- The surface of the skin.
- The consistency of tissue.
- Sensation.
- Pressure pain sensitivity.

Surface of the Skin

The following characteristics are assessed: smooth/rough, dry/moist, warm/cold, hair growth, protrusions. Check as well whether the changes are general or only found locally (compare with the other side of the body!).

Tip: As an exercise, try to write a list of adjectives describing the characteristics of the skin surface, for example, soft, coarse, elastic, tensed, thickened, parchmentlike, cracked.

Summary of the Palpatory Process

Extent of the Palpation

The entire surface of the skin and the underlying muscles from the gluteal area to the occiput will be palpated. This includes the following muscles in particular: the glutei, erector spinae, latissimus dorsi, trapezius, rhomboids, infraspinatus, supraspinatus, and the deltoid.

Consistency of Tissue

The term consistency has many different meanings. It is used here as a standard to measure the compliancy of tissues when displaced or when pressure is placed on the tissues. It is along these lines that the viscoelastic properties of tissue are assessed.

Skin and muscles have their own terminology for consistency. The term turgor is used for the skin and tension for the muscles. Both of these terms are used in palpation to define the amount of tension that the displacing or pressurizing finger feels as resistance.

Sensation

Skin sensation is checked in passing when the surface of the skin and its consistency are being examined. It does not need to be assessed separately in clinical practice. The therapist will be made aware that the sensation needs to be assessed during the subjective assessment or when the patient informs them of sensory changes during palpation.

What should the therapist pay attention to?

Sensory deficits are rare in the trunk. Sensory deficits are more likely to occur in the joints of the limbs as a result of nerve-root compression or peripheral-nerve lesion. A hypoesthesia or an anesthesia in the region of the back is to be classified as dangerous! If one of these symptoms is encountered, it is necessary to clarify whether this is a familiar symptom or whether it should be investigated further.

Do not treat the back if the cause of sensory deficits has not been clarified!

Sensory deficits interfere with massages or other interventions (e.g., electrotherapy) as the patient cannot provide the therapist with important feedback regarding the appropriate dosage. Such treatment must be performed with appropriate caution.

When considering whether, and in what dosage, treatment should be administered, it is also important to identify possible hypersensitivity to touch (hyperesthesia) or pain stimuli (hyperalgesia). It is normal for tissue to be hypersensitive to pressure during wound healing in the acute, exudative stage. This is the result of peripheral sensitization. Pathological hyperesthesias or hyperalgesias develop secondary to chronic pain. This is the result of central sensitization in the dorsal horn of the spinal cord. Hypersensitive parts of the body transmit pain signals when touched roughly and can only be treated using techniques where minimal pressure is applied or large surface contact is made (e.g., stroking as part of classical massage). At times it may be appropriate not to treat

manually at all (refer to Gifford, 2006 or Butler and Moseley, 2003 to gain further knowledge of the physiology of chronic pain).

Sensitivity to Pressure that Causes Pain

The size of the area being treated and the selection, speed, and intensity of treatment techniques are chosen according to the pain sensitivity of the tissue, amongst other factors. It is also possible to estimate the expected results of muscle treatment by assessing whether the muscles are the source of pain. Ideally, the techniques described later in the book provoke pain in the patient's muscle tissue. If the techniques do not provoke pain in the muscles or if the skin or skeleton are the source of symptoms, the treatment of soft tissue will not result in any kind of pain relief.

Method and Techniques of the Palpatory Process

A specific methodology is available that enables palpation to be conducted comprehensively in a short period. This succession of techniques places increased stress on the tissue:

- **Skin:**
 - Stroking the skin to assess its qualities.
 - Stroking the skin to assess its temperature.
 - Assessing the skin's consistency using displacement tests.
 - Assessing the skin's consistency using the lifting test.
 - Assessing the skin's consistency using skin rolling.
- **Muscles:**
 - Assessing the muscles' consistency using transverse frictions with the fingers.

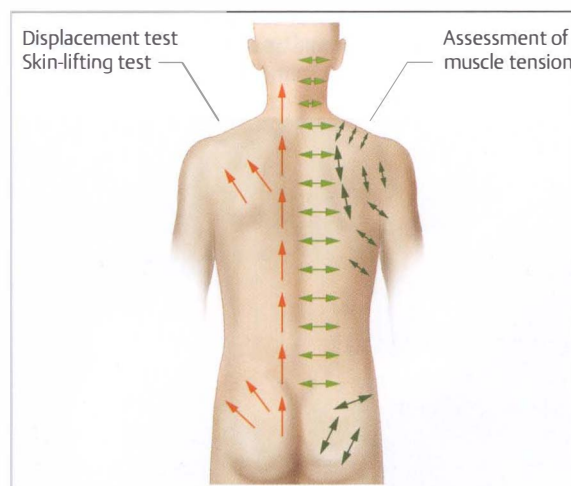


Fig. 8.4 Procedure used for skin and muscle palpation.

Figure 8.4 illustrates the procedure used to assess the consistency of the skin (left-hand side) and the muscles (right-hand side).

The techniques are conducted using different areas of the hand. These areas are suitable for the palpation of certain sensations due to their differing degrees of special receptor dispersion. For example, the most successful method for the palpation of skin temperature is to use the back of the hand or the posterior surface of the fingers. A large number of thermoreceptors are found here. The finger pads are used to detect fine differences in contour and consistency in tissue. The high density of mechanoreceptors makes the finger pads ideal for this purpose.

Starting Position

Neutral and relaxed pronation is appropriate when assessing the soft tissue of the posterior trunk. This should be standard for comparable assessment techniques. Of course, it is possible to alter this neutral starting position (SP) if necessary for certain treatment techniques or if it ensures that the patient is free of symptoms when lying. For example, padding is placed under the hip joint, pelvis, and abdomen in cases of arthritis. The following description depicts an ideal case scenario and applies to most of the SPs in Chapters 9–12.

During general inspection of the prone patient (Fig. 8.5), the therapist determines whether the head, thoracic spine, thorax, lumbar spine, and pelvis are situated in a straight line without lateral shift or rotation:

- If possible, the head is positioned in neutral rotation. The nose is placed in the face hole of the treatment table.
- The arms are positioned next to the body; the fingers can be placed slightly under the pelvis. Alternatively, the arms may also be placed over the side of the table. The arms should never be positioned at head level. This tenses the thoracolumbar fascia, making palpation of structures more difficult at the transitional area be-

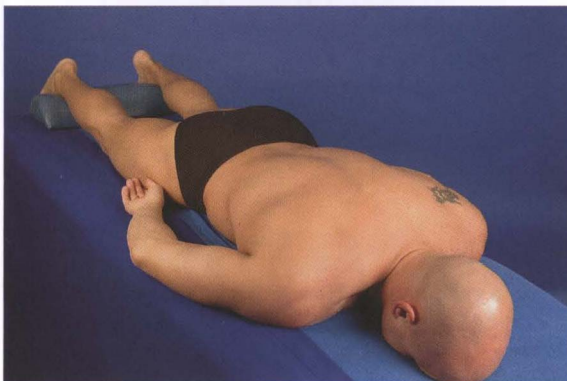


Fig. 8.5 Patient in prone position.

tween the lumbar spine and the sacrum. In addition, it causes rotation of the scapula, which in turn alters the length of various muscles in the shoulder girdle.

- The distal lower leg rests on a foot roll, ensuring that the muscles of the lower leg and thigh are relaxed. The foot roll may be dispensed with if the rotation of the legs does not change the tension in the gluteal muscles.

Some frequently asked questions are: Should padding always be placed underneath the pelvis and abdomen and the head end of the treatment table lowered? How much lordosis or kyphosis should be allowed or supported? What can therapists decisively orient themselves on in addition to what the patient feels? The answers can be found when you look at the patient's posture in standing. The general rule is: the curvature of the patient's spine in standing is also permitted in the prone position. This is achieved by altering the position of the treatment table or providing support with padding.

The therapist stands to the side of the treatment table opposite the side to be palpated. Naturally, the therapist pays attention to the height of the treatment table. The table should be sufficiently high to ensure an ergonomical standing position.

Difficult and Alternative Starting Positions

Observation and palpation findings in the prone position differ significantly from the vertical (e.g., sitting) and side-lying position. One reason for this is that gravity causes the skin to sag. The skin is therefore subject to some degree of preliminary tension. The back and neck muscles are more tense in unsupported sitting as they maintain the body's upright position. It is therefore difficult to feel changes in muscle consistency (e.g., increased muscle tension).

If you want to reduce the anti-gravity effect in the trunk and neck muscles, ensure that the weight of the head, arms, and, when necessary, the upper body rests on a supportive surface. This can be achieved by sitting on the side of a treatment table and using appropriate padding. When the active muscle tension in the back and neck muscles is reduced, the body bends forward and hip flexion surpasses 90° (caution with recent total hip replacements [THR]). This results in a flexed lumbar spine, with flexion continuing more or less up into the thoracic spine. This in turn increases the passive tension in all posterior fasciae and the trunk muscles, and increases the resistance that the palpating finger has to work against.

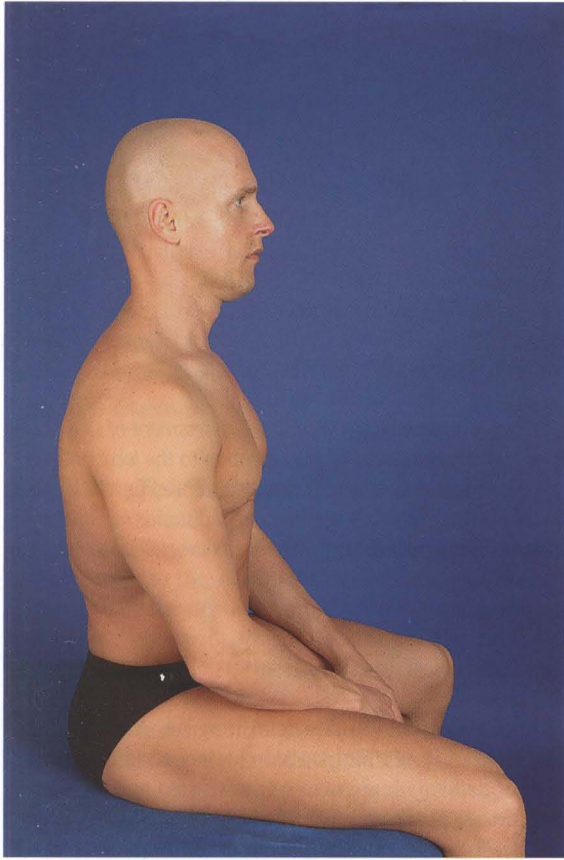


Fig. 8.6 Patient positioned in unsupported sitting.

Neutral Starting Position: Sitting

The neutral sitting position roughly imitates the curvature of the spine when the patient is standing upright. The best position to obtain this is unsupported sitting on the corner of a treatment table. This SP is generally not very stable. Description of a more stable SP in sitting follows below (Fig. 8.6).

The patient sits on the treatment table with the thighs resting fully on the table. It is recommended that only patients with circulatory disorders and those with poor stability have the soles of the feet in contact with the floor. The knees are separated further than the width of the hips, facilitating pelvic tilt movements. This enables positioning of the lumbar lordosis. The thoracic and cervical curvatures are positioned to correspond with the curvatures in standing or are corrected when necessary. The patient's arms hang down loosely beside the body. The forearms or the hands rest on the thighs.

The therapist stands to the side of the patient and opposite the side to be palpated. The therapist should pay attention to the height of the treatment table, ensuring that the standing position is ergonomical.

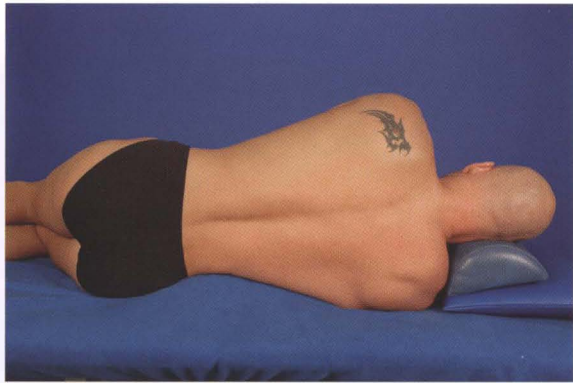


Fig. 8.7 Patient positioned in side-lying.

Neutral Starting Position: Side-lying

This SP also attempts to reproduce the patient's natural spinal curvature (Fig. 8.7). If the patient cannot adopt this position without pain, the position is naturally adapted to make it possible for the patient to remain in the side-lying position for a certain amount of time.

Otherwise the following short formula applies: no lateral flexion, rotation, forced kyphosis, or forced lordosis.

This is achieved by placing the patient in an easily accessible side-lying position and placing padding underneath the lumbar and cervical spines so that these sections of the vertebral column are no longer laterally flexed. This accommodation requires individual effort.

The upper body and the pelvis are then placed in neutral rotation: both sides of the pelvis and both shoulders lie on top of each other.

Both legs should rest on top of each other. The hip joints are not flexed more than 70° so that the lumbar spine is not forced out of its lordotic position. The knee joints are clearly flexed. Check the head position again.

The therapist stands facing the back of the patient. The therapist should check that the treatment table is high enough to ensure an ergonomic stance.

Palpation Techniques

Overview of Structures to be Palpated

- Skin:
 - Stroking the skin to assess its qualities.
 - Stroking the skin to assess its temperature.
 - Assessing the skin's consistency using displacement tests.
 - Assessing the skin's consistency using the lifting test.
 - Assessing the skin's consistency using skin rolling.
- Muscles:
 - Assessing the muscles' consistency using transverse frictions with the fingers.

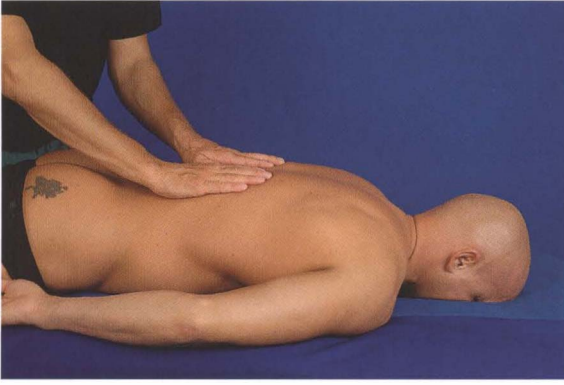


Fig. 8.8 Palpating the quality of the skin.

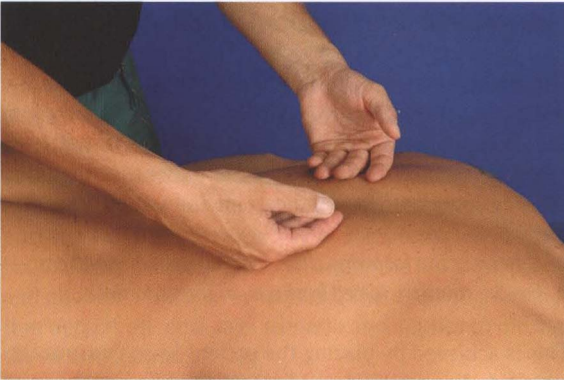


Fig. 8.9 Palpating the skin temperature.

Palpating the Surface of the Skin

The procedure for palpating the skin incorporates all posteriorly accessible parts of the skin. The palpation starts in the pelvic region, in particular over the sacrum and the iliac crests, and continues upward to the occiput. Attention is paid to the skin's quality and varying temperature (see also Chapter 1, p. 7).

Technique Used for the Surface of the Skin

The qualities of the skin, its roughness, etc., are assessed by slowly stroking the skin systematically with flattened hands (Fig. 8.8).

Technique Used to Assess the Temperature of the Skin

The back of the hand or the posterior side of the fingers are used to perceive the skin's temperature (Fig. 8.9). The therapist pays attention to possible differences between the left- and right-hand sides and between neighboring superior and inferior regions. It is frequently observed

that the pelvic or the lumbar region is colder without pathological cause.

Palpating the Quality of the Skin (Turgor)

The skin's consistency is dependent on the balance of fluid in the skin and can be ascertained using elasticity tests. The aim is to determine general elasticity of the skin and whether there are areas of differing elasticity that may provide the therapist with information about the skin's reflex response to pathological irritants such as internal organs.

When comparing sides during the assessment of skin consistency, it is important to pay attention to the location of assessment. It should be at the same distance from the vertebral column on both sides. Differences in distance result in different palpatory findings, which means the assessment is then unreliable.

Criteria

All tests consist of initially deforming the skin with minimal force and stretching the skin to the maximum. The degree of deformation reached is evaluated and the time it took to reach this stretch is observed. The skin is then mildly stretched in a rhythmic manner. The elasticity felt in the skin's response is noted. There are principally no differences between this procedure, including the criteria applied, and the assessment of passive movement or joint play.

Full tissue deformation can only be successful with the appropriate intensity. This requires considerable concentration, especially when a beginner is palpating.

Displacement Test Technique

This is the simplest and least provocative test. The outstretched hand is placed on the surface of the skin. Minimal pressure is applied and the skin is pushed in a superior direction until the increasing tension in the skin restricts further movement (Fig. 8.10). The therapist conducts this test in a rhythmic manner, paying special attention to the tissue's resistance to movement and the path that both hands follow over the body's surface.

The area to be assessed encompasses the sacral region, passes over the iliac crests in a lateral direction, runs paravertebral up to the cervicothoracic junction, and includes both scapulas (see also Fig. 8.4). This is the only test that can be used to gain information about the skin's consistency if the skin is extremely sensitive. Both of the following tests are more aggressive.

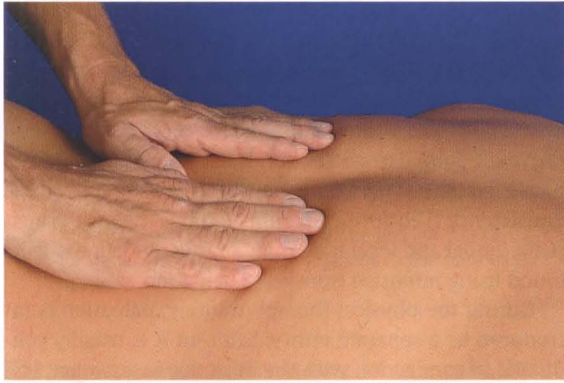

Fig. 8.10 Displacement test

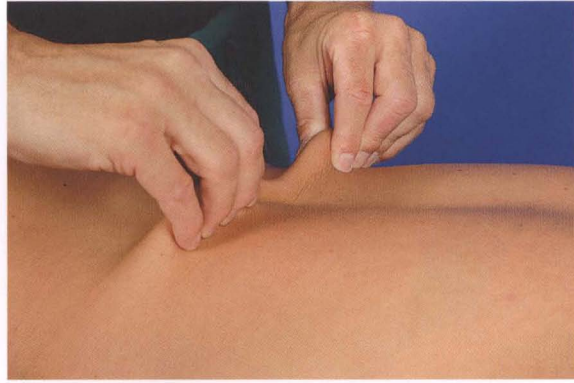


Fig. 8.11 Skin-lifting test.

Skin-lifting Test Technique

The test on the next level of intensity deforms the skin perpendicular to the skin's surface. This test can also be performed bilaterally and simultaneously. The thumb and a few finger pads grasp a section of the skin and form a skin fold, which is then lifted away from the surface of the skin (Fig. 8.11).

The same assessment criteria apply here: tissue resistance and the degree of motion. It is almost impossible to assess these criteria when patients are obese or have a high level of turgor. Also, it is frequently observed that it is impossible to lift up the skin in the lumbar region. This is purely a variation of the norm. The skin is usually lifted up several times paravertebrally from approximately S3 to T1.

Skin-rolling Technique

This technique combines skin lifting perpendicular to the body's surface and displacement parallel to the body's surface. It is very informative but is a fairly aggressive, more challenging technique, and can only be conducted on one side at a time.

Both hands are used to form a skin fold on one side of the body, similar to the skin-lifting test. Starting with the lumbosacral region, this skin fold is then quickly rolled paravertebrally in a superior direction (Fig. 8.12). The therapist tries to keep the skin lifted as much as possible and to not lose the skin fold during the movement. The finger pads always pull new skin into the fold, and the thumbs push the fold upward in a superior direction.

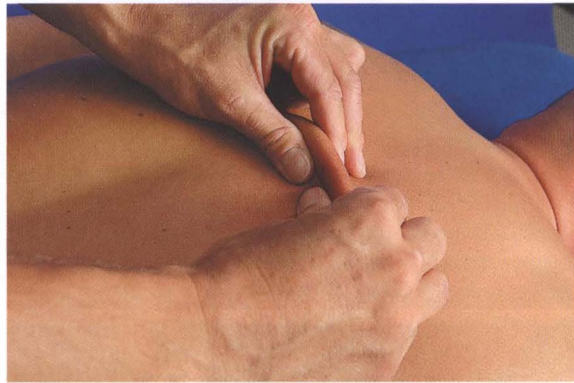

Fig. 8.12 Skin rolling

tension justifies the use of soft-tissue treatment techniques (e.g., massage). Therefore, the state of the muscle must be systemically examined at the start of a treatment series and also be included at the start of each treatment session. It is not enough to depend on information from the patient to accurately observe treatment progress.

The palpation of tissue resistance in muscles requires a certain intensity, appropriate technique, and a reliable procedure (see also Fig. 8.4). Muscle tension is palpated after the skin has been pushed against the body's fasciae. This prevents the skin from providing the therapist with further information. Furthermore, the amount of pressure applied depends on the size or the thickness of the muscle to be palpated.

The technique applied is, therefore, transverse friction using the fingers. This should be performed in the gluteal and the lumbar regions with the hand pushing down (with the aid of the other hand when necessary) so that deeper-lying muscles such as the piriformis can be reached. Palpation is performed in the thoracic, cervical, and scapula regions with both hands separate from one another to save time.

The palpating hands now "scan" the muscle tissue using large movements. An attempt is made to gain a general idea of the consistency. The tissue is only palpated at a

Palpating the Consistency of Muscle (Assessment of Muscle Tension)

Most soft-tissue techniques on the trunk influence the pathologically altered muscle consistency (muscle tension). Only a positive result in the assessment of muscle

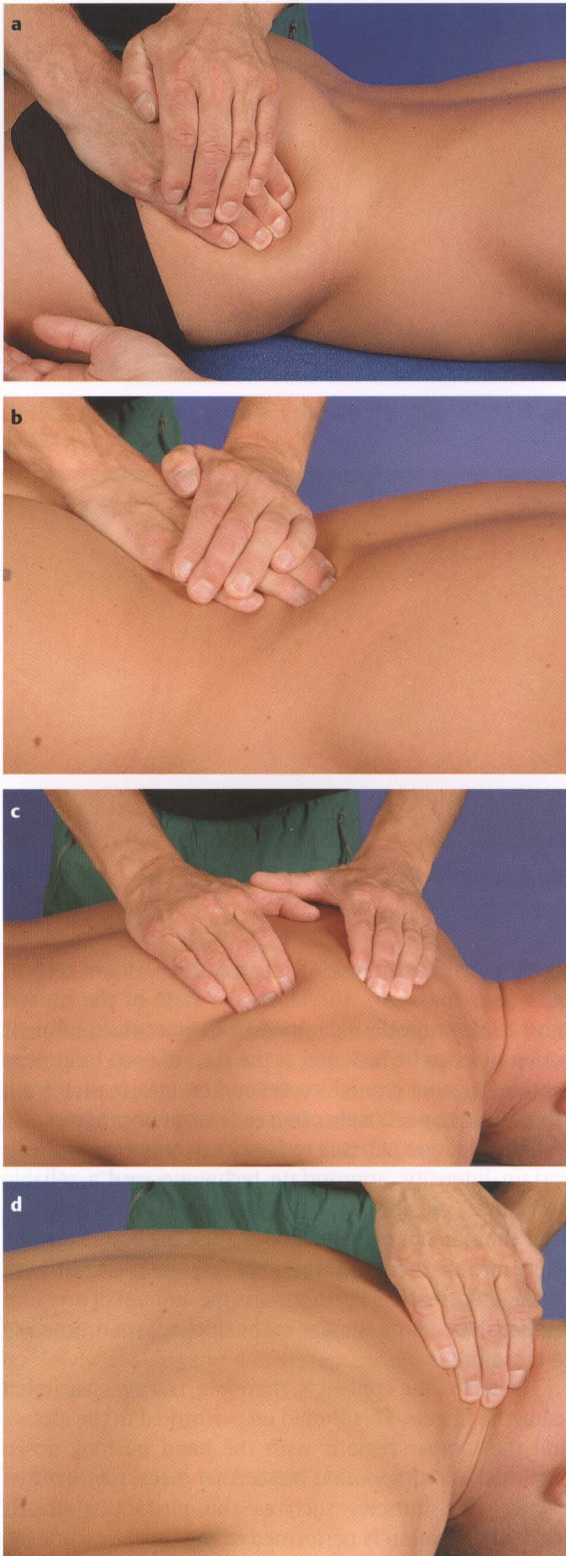


Fig. 8.13a–d Assessing muscle tension.
a In the gluteals.
b In the lumbar region.
c Along the scapula.
d In the cervical region.

local level if abnormalities have been identified during the general “scan.” Local palpation of muscle is then conducted using small movements, assessing the muscle’s precise condition and the extent of change. This way of proceeding saves time and is effective. If the palpation provokes pain, extra attention must be paid toward the hardened tissue (see the section “Interpreting the Muscle Consistency [Tension] Palpation Findings” below). Principally, global and local hardening of muscles can easily be found using intensive transverse palpation.

During the physical therapy training, palpation is introduced as a separate entity. Later on it is usually conducted in connection with the objective assessment. It is nevertheless recommended that beginners separate the results of observation and palpation to train the respective senses.

Techniques

1. The therapist begins by pushing the fingers of one hand down onto the gluteal area at the edge of the sacrum and applies frictions.
2. The hand moves transversely over the gluteus maximus and the underlying piriformis.
3. The hand then moves laterally onto the small gluteal muscles (Fig. 8.13a) in the space between the iliac crest and the greater trochanter.
4. The lumbar erector spinae are palpated paravertebally (Fig. 8.13b). If the back extensors are very well developed, the palpation will have to be separated into more medial and more lateral segments.
5. The thoracic erector spinae are palpated paravertebally until approximately the level of T1 is reached. The therapist will be able to use both hands simultaneously for the palpation from here onward most of the time. It is no longer necessary to place extra weight on the palpating hand to apply enough pressure to reach the deep tissues.
6. The therapist moves along the medial border of the scapula in the area of the rhomboids and the transverse and ascending parts of the trapezius (Fig. 8.13c).
7. The infraspinatus and supraspinatus are assessed, moving laterally from a medial position over the scapula.
8. The belly of the descending part of the trapezius is then palpated, returning in a medial direction.
9. The paravertebral and suboccipital neck muscles are assessed next (Fig. 8.13d).
10. Tense adductors are expected to be found in patients with overloaded or painful shoulder joints. The palpation continues laterally along the scapula and the consistency of latissimus dorsi, teres major, and teres minor is felt. It is useful to also palpate the deltoids since a loss of muscle tone may be found here as a result of inactivity.

Tip: The lumbar extensors form a uniform muscle mass due to the osteofibrotic sheath consisting of the vertebral processes and the thoracolumbar fascia. A variety of techniques in classical massage or functional massages utilize this fact, pushing the complete muscle mass laterally away from the row of spinous processes. The back extensors are no longer a uniform muscle mass in the thoracic region:

- The amount of muscle decreases.
- The fascia ends approximately at the level of T7–T8.
- The spinalis is found directly adjacent to the spinous processes.

The palpating finger must not only overcome the skin to reach the muscles; it must also overcome the body's fascia. These fasciae are not always of the same thickness in each section of the back (see Chapter 1). When the therapist is aware of how the fasciae are constructed, expectations regarding the consistency of the muscle tissue to be palpated will be correct.

Tips for Assessment and Treatment

The palpation of the posterior soft tissue is analyzed first. When the patient indicates pain, the therapist should consider how they can proceed systematically to clearly identify the tissue in which pain originates. Following this, the results of the individual palpatory findings are discussed. This section ends with examples of treatment, the main focus being on the treatment of muscles.

Differentiating between Tissues

How can you find out which tissue is affected?

The pressure applied during palpation is uncomfortable when the skin is hyperesthetic or hyperalgesic. It is also known that a certain amount of palpatory pressure, for example, onto the back extensors, is transferred as a slight movement onto the vertebral segment. How is it then possible to reliably find the affected tissue when pressure causes pain?

We will discuss this by using the example of paravertebral palpation along the middle thoracic spine. Visualize the situation with a patient. The therapist systematically palpates the back extensors from inferior to superior using transverse frictions. At the level of the scapula the patient reports the pressure to be very uncomfortable. The question is: does muscle hardening definitely cause the reported pain? The therapist must now differentiate between tissues to answer this question.

Is the skin sensitive to pressure? The therapist should have already gained information about this when assessing skin consistency. It can happen that something is overlooked, in which case the skin consistency test is repeated

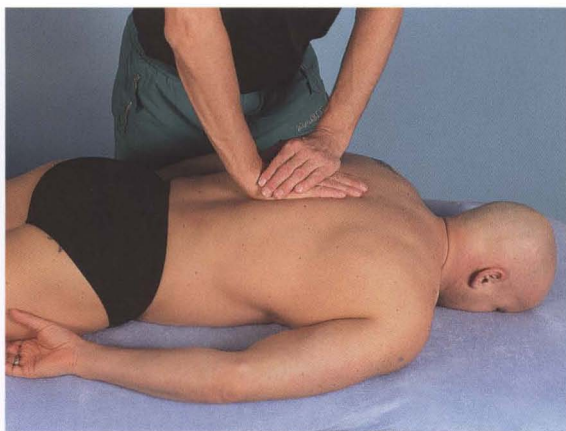


Fig. 8.14 Careful provocation of the thoracic spine.

using the technique that stresses the skin the most: skin rolling. The therapist broadly rolls the skin over the affected area now and compares it to the other side. When the patient indicates the same symptoms as those that appeared during localized pressure, the skin is the source of pressure pain. More precise information about the condition of deeper-lying structures is not possible using palpation. If the muscles are treated (e.g., soft-tissue technique or massage) despite the skin sensitivity, treatment must be conducted with caution and with a large area of surface contact.

Is the vertebral column causing the symptoms? The therapist places the flat hand directly over the vertebral column and pushes anteriorly, alternating between more pressure and less pressure while gradually increasing the overall pressure (Fig. 8.14). If this is not precise enough, the therapist can use the ulnar side of the hand and the same technique on the spinous and transverse processes in the area of pain. The vertebral column is at least partially the source of symptoms if the patient indicates the same symptoms felt during the previous palpation.

Are the costovertebral joints sensitive to pressure? It can be difficult to differentiate a myogelosis (local muscle hardening) from a sensitive costovertebral joint in thin patients. Both are found very locally and are very firm. A myogelosis can mostly be pushed somewhat to the side. This cannot be expected with a rib. To make sure, the therapist places the ulnar side of their hand or thumb on the rib and pushes down onto the rib using a slow rocking motion and gradually increasing the pressure (Fig. 8.15) (see also the section “Posterior Palpation Techniques,” Chapter 11, p. 284). If this is the most painful test, the source of symptoms can be found in an irritated or blocked costovertebral joint. Treating the muscle alone will most likely not result in permanent relief.

The therapist can be sure that the muscles are sensitive and are the cause the patient's symptoms when the provocation of skin, vertebral column, and the costovertebral joints do not provide clear answers. Remember these dif-

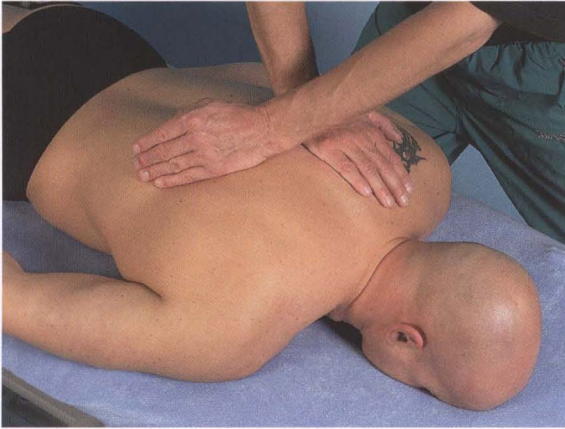


Fig. 8.15 Careful provocation of the costovertebral joints.

ferentiating tests, especially when soft-tissue treatment has not yet produced the desired result.

Interpreting the Findings of Skin Surface Palpation

The most important questions following this are:

- Does the skin give you a reason not to test or treat deeper-lying structures? Possible reasons include diseases or injuries to the skin, but can also include rough, cracked, parched skin where strong deformations of the skin, as is the case during massages, are contraindicated. Acne, scarring, and lipomata also restrict the area that can be treated. The chronification of pain and disorders of the peripheral nervous system can cause hyperalgesia or hyperesthesia. The pressure from the therapist's hand may then be perceived as unpleasant. The treatment is questionable in this case.
- How much pressure can probably be applied when the use of a manual technique is possible?
- When classic massage treatment is used, how much of the massage product should be used?

Interpreting the Skin Consistency (Turgor) Palpation Findings

All three tests presented here should result in the same findings. Elasticity and sensitivity noted should be equal. The techniques should be reassessed or the patient questioned again if this is not the case. These tests stress the skin with different degrees of stretch (see also Chapter 1).

The sympathetic nervous system regulates the balance of fluids. Reflex changes to fluid accumulation are a sign of nociceptive afferents that are above or below threshold and arise from sections of a neurological segment (viscerotome, sclerotome, myotome). These changes may be seen during observation in the form of retracted skin or swell-

ing. For further explanations, please read the relevant literature on reflexology. Certain changes in consistency, especially the retraction or adhesion of skin, can be positively affected by manual techniques (skin rolling, soft-tissue techniques to the thorax, etc.). Such findings are seen during the skin palpation of patients suffering from pulmonary and bronchial disorders (bronchial asthma, post-pneumonia).

Interpreting the Muscle Consistency (Tension) Palpation Findings

The assumption regarding “normally tensed” tissues and the corresponding palpable resistance is critical when interpreting the muscle consistency results. It can be assumed that muscle tissue yields quite a lot to pressure applied perpendicular to the muscle tissue and that the tissue has a soft and very elastic feel. Palpation on patients frequently results in completely different findings.

Muscle-tissue consistency can change due to physiological and pathological reasons. It can be either softer or harder than expected.

Softer consistencies are seen in atrophies following immobilization or injury as well as in disorders of the nervous system that are accompanied by hypotonic paralysis.

Harder consistencies are interpreted as hardened muscles when the entire muscle or large parts of the muscle are affected. Smaller areas of hardening are identified as myogeloses or trigger points (see also Chapter 1).

Besides these harder consistencies, classified as pathological, there are also completely normal deviations from the expected consistency norm.

What Does it Mean When a Hardened Muscle Is Found?

Not every hardened muscle has to be treated. Painful, hardened areas that correspond to the patient's reported area of pain are of interest. Naturally, hardened muscles that hinder the access to deeper-lying structures (e.g., facet joints) are also of interest.

If the therapist finds an abnormally hardened area in a muscle during palpation, it is recommended that the therapist ask the patient the following questions to determine the pathological degree of the hardened area and its importance to the patient:

- **Question 1: Can you feel the hardened area?**
 - The therapist does not attach any meaning to the findings if the patient's answer is “no.”
 - The therapist proceeds with the questioning if the patient's answer is “yes.”

- **Question 2: Is the pressure that I apply to the hardened area uncomfortable?**
 - The therapist does not attach any meaning to the findings if the patient's answer is "no."
 - The therapist proceeds with the questioning if the patient's answer is "yes."
- **Question 3: Does the hardened area correspond to the area where your symptoms are?**
 - The therapist attaches little meaning to the findings if the patient's answer is "no."
 - The therapist makes a mental note of the findings if the patient's answer is "yes," classifying the findings as particularly important, and documents this on a body chart.

This list of questions enables the therapist to individually structure their treatment using soft-tissue techniques or massage to target the symptoms. It also prevents the therapist spending too much time on less important areas of muscle. The therapist should pay particular attention to the following areas of hardening when planning treatment:

- Hardening that was conspicuous during the third question.
- Hardening that prevents access to deeper-lying structures.
- Hardening that is important for the familiarization with and the treatment before the application of manual-therapy techniques.

Examples of Treatment

Lumbar Functional Massage in the Prone Position

Functional massages are used to supplement the treatment of lumbar back extensors and quadratus lumborum, making massage even more effective. The first of the two phases used in this technique can also be used for extremely painful conditions in the lumbar spine. It is also suitable to prepare the patient for manual therapy techniques, especially when these involve lateral flexion. The technique can be conducted rhythmically or as a static stretch. Both variations decrease the tension in the muscle.

There are two variations available when applying this technique. The first variation does not involve targeted vertebral movement during treatment. The vertebral column may move as it follows the movement of other structures or be placed in lateral flexion before starting treatment to optimize the mobilizing effect.

Starting Position—Variation 1

The patient lies prone in a neutral position or with padding underneath the abdomen. The therapist places

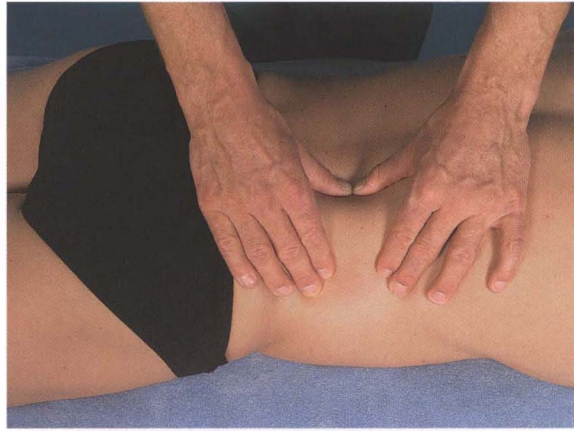

Fig. 8.16 SP for the lumbar functional massage in the prone position.

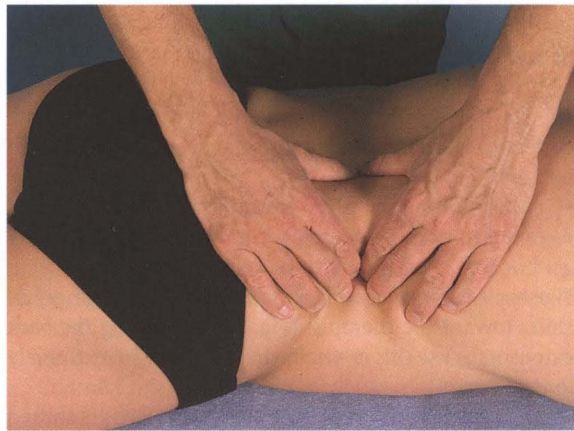

Fig. 8.17 Lumbar functional massage technique in the prone position.

both hands over the back extensors on the other side of the patient. The thumbs are placed flat over the hollow between the bulk of the muscle and the spinous processes. They exert significant pressure into this hollow. The fingers point laterally and grasp around the muscle belly between the costal arch and the iliac crest (**Fig. 8.16**).

Technique

While continuing to hold onto the muscle, the therapist stretches the muscle laterally by pushing with the thumbs and slightly spreading the fingers. This movement is quite small. It can be conducted in either a rhythmical manner or as a static stretch (**Fig. 8.17**).

Tip: It is crucial for the success of this technique that the thumbs maintain contact with the medial border of the back extensors and not slip over them. The movement is stopped as soon as the therapist notices that contact is being lost. Only an extremely small movement is to be expected.

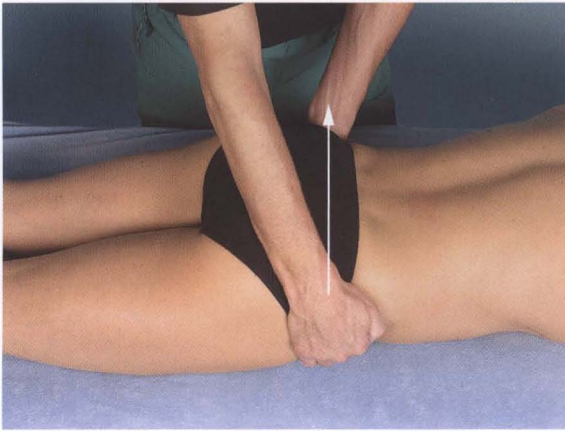


Fig. 8.18 SP (variation 2) with the approximation of the back extensors—the pelvis is shifted over toward the therapist.

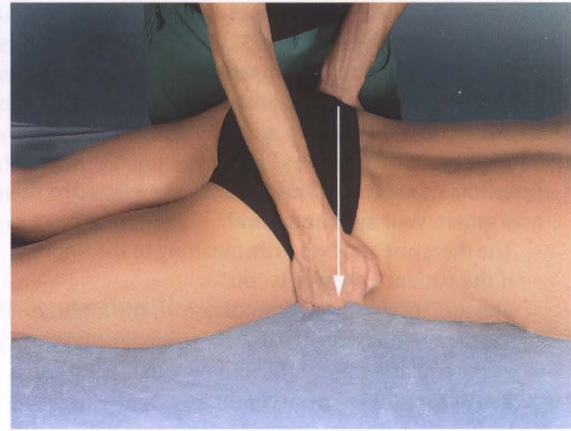

Fig. 8.19 SP (variation 2) with lengthening of the back extensors—the pelvis is shifted away from the therapist.

Starting Position—Variation 2

The starting position can be altered with the help of the patient to make treatment more effective. This is achieved by:

- either shifting the pelvis toward the therapist;
- or shifting the pelvis away from the therapist.

The back extensors are approximated when the pelvis shifts toward the therapist (**Fig. 8.18**), relaxing the back extensors → use this method when muscles are extremely tense.

The muscles are lengthened when the pelvis is shifted away from the therapist (opposite side, **Fig. 8.19**). This results in the muscles being placed under preliminary tension in a longitudinal direction. Accordingly, transverse stretching is even more effective in terms of decreasing muscle tension → use this method when muscles are moderately tense.

Tip: The therapist should not slide the pelvis over by themselves because it weighs too much. The patient is given precise instructions on assisting the therapist during the pelvic shift.

You should abstain from using this second variation in cases of extreme pain unless positioning in lateral flexion to a particular side relieves pain in lying.

Lumbar Functional Massage in Side-lying

This functional massage involves significantly more movement than the previous massage. It should therefore only be used after lateral flexion has been assessed and the contraindications have been checked. However, the decrease in muscle tension and the mobilization is particularly effective.

Starting Position

The patient is found in neutral lateral flexion. The side to be treated is uppermost. The therapist places both hands paravertebrally, grasping the upper-lying back extensors. The superior end of the therapist's forearm rests against the patient's thorax. The inferior end of the forearm rests on the pelvis between the greater trochanter and the iliac crest (**Fig. 8.20**).

Technique

Phase 1: The back extensors being treated are displaced laterally (in spatial terms toward the roof). The therapist achieves this by pulling the finger pads upward and slightly separating the thumbs.

Phase 2: To intensify this technique, the therapist pushes the elbows against the areas of support. The more inferiorly positioned arm slides up to 80% during this movement. The role of the more superiorly positioned forearm is to prevent the thorax from moving with the rest of the

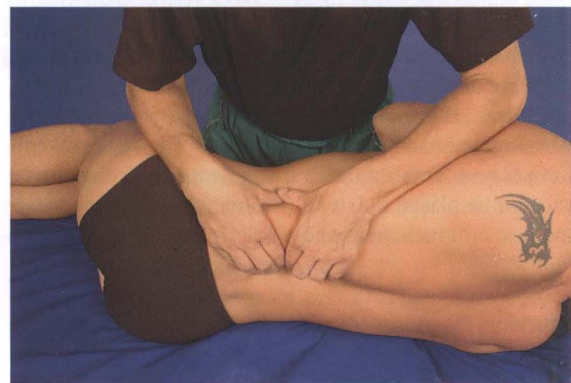

Fig. 8.20 SP for lumbar functional massage in side-lying.

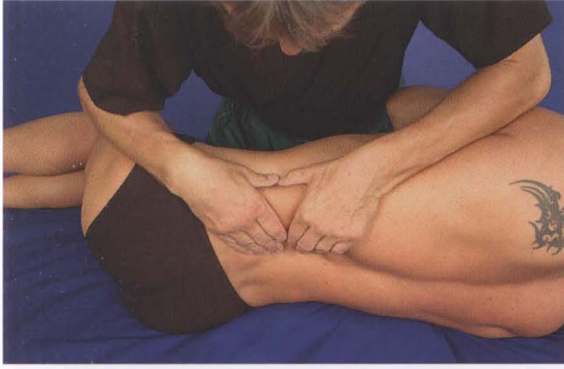


Fig. 8.21 Lumbar functional massage in side-lying, technique phase 2.

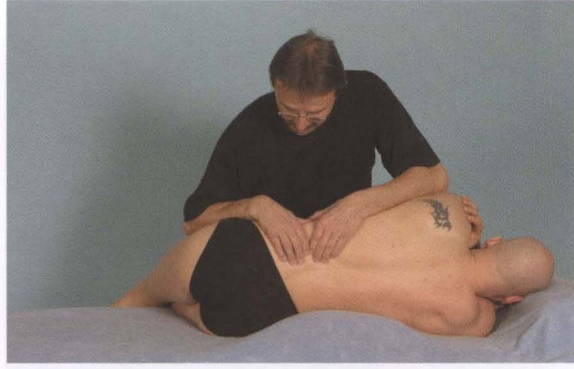

Fig. 8.23 Lumbar functional massage with side-bending, technique phase 3b.

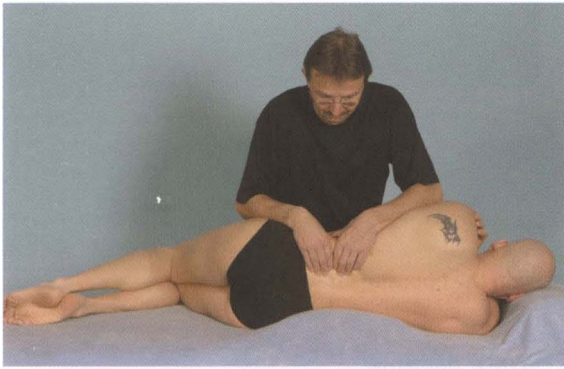

Fig. 8.22 Lumbar functional massage with side-bending, technique phase 3a.

Tip: The muscles in the area of the lumbosacral junction can be reached by changing the hand placement in each variation of this technique (**Fig. 8.24**). Only the therapist's more superiorly positioned hand hooks medially around the back extensors. The more inferiorly positioned hand rests on the pelvis and facilitates lateral flexion only. It is no longer in contact with the back muscles.

The treatment effect can be intensified by using neurophysiological aids to increase the range of pelvic and leg motion (in phase 3), which increases the movement in the lumbar spine:

- Reciprocal inhibition for phase 2.
- Contract relax for phase 3.

Reciprocal Inhibition for Phase 2

The aim is to inhibit the upper-lying back extensors through activity in the lower-lying muscles. Therefore, the therapist instructs the patient to move the upper-lying side of the pelvis inferiorly. The patient can only achieve this by activating the lower-lying lumbar muscles (and therefore inhibiting the upper-lying lumbar muscles). The patient begins to move at exactly the same moment when the therapist uses both arms to force lateral flexion.

body. Its job is not to force lateral flexion! The result should be lateral flexion of the lumbar spine (toward the right in this example). This combines the transverse stretch from phase 1 with a longitudinal stretching of the back extensors (**Fig. 8.21**).

Phase 3: The lower legs can be used as a lever to increase the range of lateral flexion in younger patients where lateral flexion is pain free. The patient's lower legs hang over the edge of the treatment table (phase 3a, **Fig. 8.22**). The therapist pushes on the pelvis with the forearm and the patient lowers their lower legs (phase 3b, **Fig. 8.23**) → lateral flexion is increased immensely. Not every patient can be expected to undergo this enormous stress on the lumbar spine. There are, therefore, a few contraindications that should be observed with this technique:

- Any acute, painful symptoms in the lumbar spine.
- Pronounced instability in the lumbar spine.
- Arthritis and severe restrictions in mobility in one hip.
- Total hip replacement.
- All other contraindications for physical therapy.

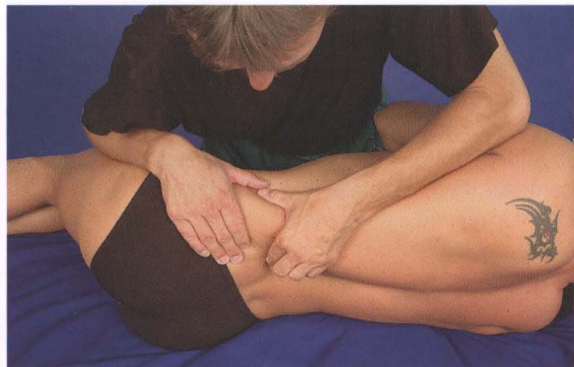


Fig. 8.24 Lumbosacral hand placement.

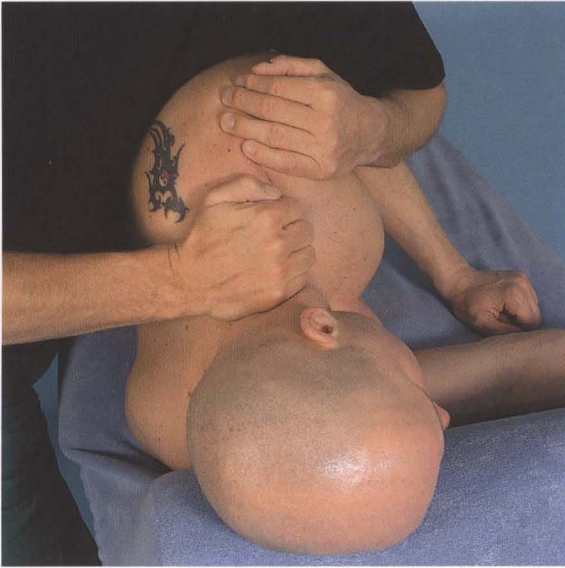


Fig. 8.25 SP for the functional massage of the trapezius in side-lying.

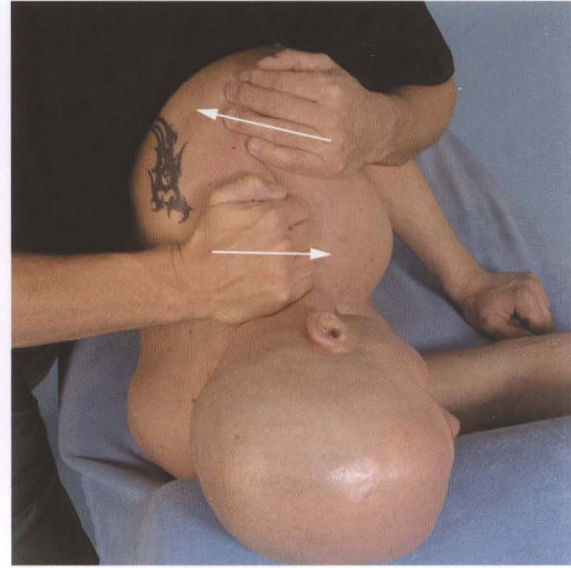


Fig. 8.26 Functional massage of the trapezius in side-lying, variation 1.

Contract Relax for Phase 3

The relaxing effect following isometric muscular activity has been discussed in the literature. Neurophysiological evidence cannot be described at present. This principle functions though in clinical situations. It is therefore important that the patient becomes increasingly involved in the procedure by focusing their attention on the muscle tension and relaxation, and that the patient is given enough time to relax. During the phase 3 procedure, the patient lifts both lower legs to the level of the treatment table, then holds this for a few seconds, perceives the tension in the lumbar spine and the pelvis, lets the lower legs drop, and then feels the relaxation. It is only now that the therapist manually forces lateral flexion and changes the erector spinae's form.

Functional Massage of the Trapezius in Side-lying

The functional massage in side-lying is one of the most effective options to decrease tension in the frequently painful and tense descending fibers of the trapezius. The technique combines longitudinal stretching (movement of the shoulder girdle) with a manual transverse stretch. As patients are often unable to relax their shoulder girdle muscles, it is recommended to first passively protract, retract, elevate, and depress the scapula and move the scapula diagonally. At the same time the therapist can assess whether the necessary movements can be performed without causing pain in the shoulder girdle joints.

The technique itself starts with the trapezius in a slightly approximated position, followed by a diagonal

movement of the shoulder. The hand molded over the trapezius applies an impulse or pressure onto the muscle belly in the opposite direction.

Starting Position

The patient lies in a neutral side-lying position and slides as close as possible to the edge of the treatment table next to the therapist, who stabilizes the patient with their body from a standing position.

One hand is resting on the shoulder joint and facilitates the shoulder girdle, while the other hand holds onto the descending fibers of the trapezius using the palmar grip (**Fig. 8.25**).

Variation 1 of the Technique—Depression and Retraction with an Anterior Stretch from the Hand

The muscle is approximated by slightly elevating and protracting the shoulder girdle (scapula moves forward and upward).

The thenar eminence pushes the muscle in an anterior direction without the hand slipping over the skin → transverse stretch.

The shoulder girdle is facilitated into an extremely depressed and retracted position (scapula moves backward and downward, **Fig. 8.26**) → longitudinal stretch.

The stretch is stopped if the muscle belly slips out from underneath the therapist's hand.

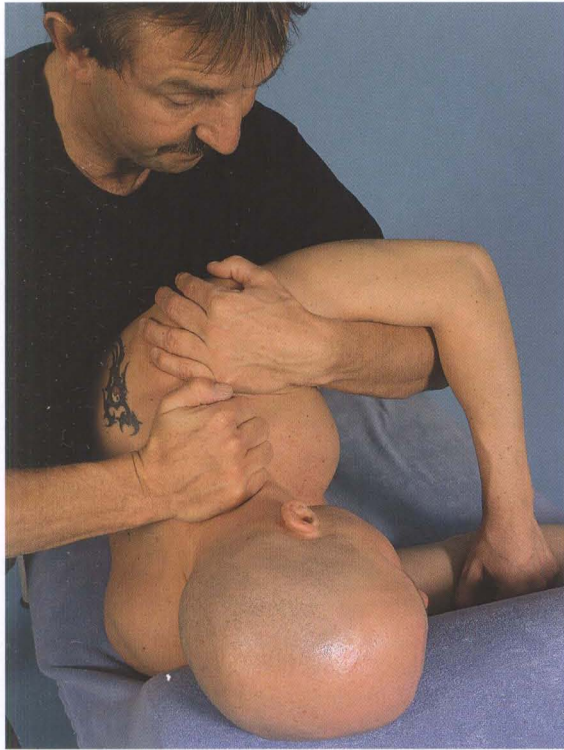


Fig. 8.27 Functional massage of the trapezius in side-lying, variation 1 with arm elevation.

Tip: If the heel of the therapist's hand continuously rubs up against the superior angle of the scapula during the previously described technique, the scapula can be moved out of the way. This is achieved by passively elevating the arm to a sufficient extent (at least 90° of glenohumeral joint flexion) and maintaining this position. The scapula is placed in extensive external rotation, and the superior angle of the scapula moves inferiorly. There is now more space on the trapezius for the therapist's molding hand (variation according to Matthias Grötzinger, **Fig. 8.27**).

Variation 2 of the Technique—Depression and Protraction with a Posteriorly Directed Stretch

The muscle is approximated to some extent by slightly elevating and retracting the shoulder girdle (scapula moves backward and upward).

The fingers are slightly flexed and move the muscle in a posterior direction without sliding over the skin.

The shoulder girdle is eased into extensive depression and protraction (scapula moves forward and downward, **Fig. 8.28**).

The stretch is stopped if the muscle belly slips out from underneath the hand. As sensitive neural and vascular structures are found here, the therapist must exercise a great deal of caution when grasping with the fingertips.

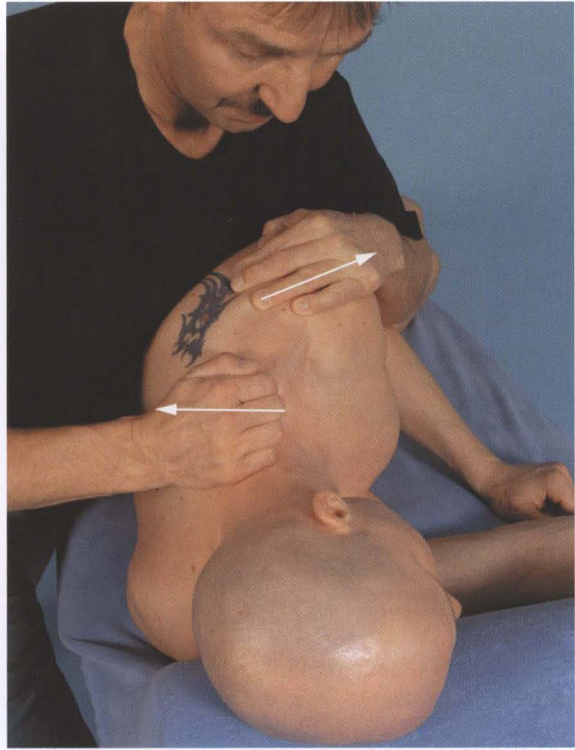


Fig. 8.28 SP for the functional massage of the trapezius in side-lying, variation 2.

Tip: The effectiveness of this technique can be further improved by prestretching the muscle farther using lateral flexion away from the side to be treated (the head section of the treatment table is lowered or the pillow is removed). The stretch is significantly more effective due to this (**Fig. 8.29**). Caution: lateral flexion must be pain-free for the patient and must be assessed before commencing the technique.

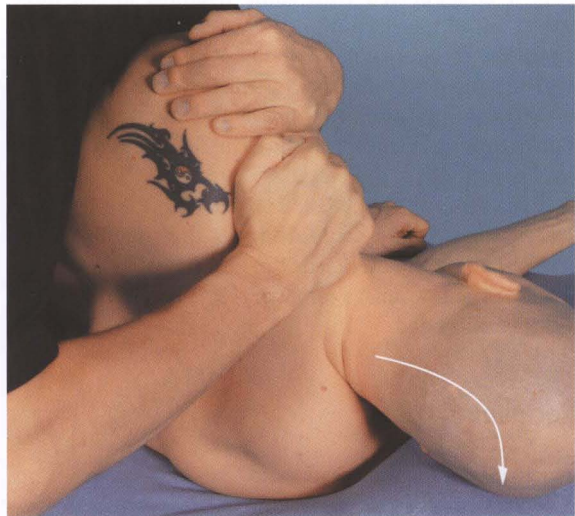

Fig. 8.29 SP for the functional massage of the trapezius in side-lying; the head end of the treatment table is lowered.

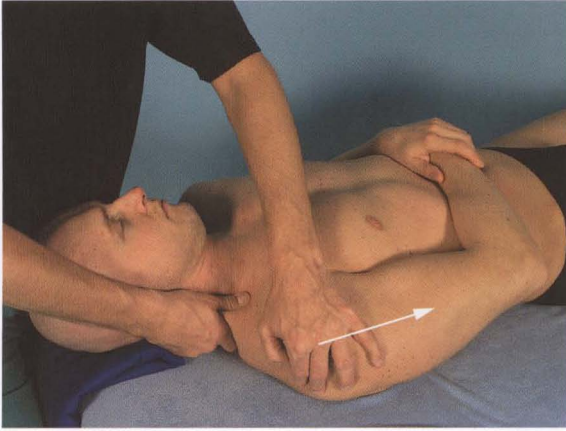

Fig. 8.30 Functional massage of the trapezius in the supine position, variation 1.

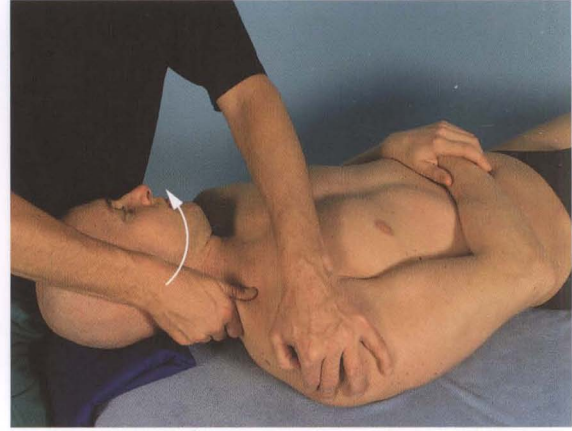

Fig. 8.31 Functional massage of the trapezius in the supine position, variation 2.

Functional Massage of the Trapezius in the Supine Position

A technique in the supine position provides the therapist with another option to lower the tension in the descending part of the trapezius and the paravertebral neck muscles. It essentially differs from the technique in side-lying through its use of cervical rotation and simple shoulder girdle depression. The range of pain-free cervical rotation must therefore be assessed before applying the technique.

Starting Position

The patient lies toward the head-end of the treatment table in a neutral supine position. The back of the head should actually extend somewhat over the edge of the bed. It is supported with some padding, for example, with a folded towel. Caution: do not place padding underneath the cervical spine!

The patient's forearm on the side to be treated is placed on the abdomen and held onto by the other hand (variation according to Oliver Oswald). This facilitates the necessary movement of the scapula (**Fig. 8.30**).

The therapist's body is in contact with the side of the patient's head. One hand facilitates the shoulder girdle while the other hand grasps the trapezius and molds the muscle. The therapist's forearm rests against the side of the patient's head.

Technique

The hand nearest the head molds the muscles (trapezius and neck muscles) by stretching the trapezius transversely in an anterior direction and stretching the paravertebral muscles more to the side. The therapist's forearm facilitates the head into cervical rotation while the thera-

pist slightly moves their body out of the way. The second hand leads the shoulder girdle into depression. The deformation of muscles and the depression are eased again as the therapist's body brings the patient's head back into a neutrally rotated position:

- **Variation 1 (Fig. 8.30)**: more emphasis is placed on the trapezius, forced shoulder girdle depression, and less cervical rotation. The grip is more to the side.
- **Variation 2 (Fig. 8.31)**: more emphasis is placed on the paravertebral neck muscles using less depression and significant rotation. The grip is therefore more medial.

Study Questions

1. Which bony orientation points should the therapist be familiar with before starting to palpate the back/shoulder/neck area?
2. Which criteria are used for the palpation of posterior soft tissue?
3. Which type of sensory change in the back is to be classified as particularly menacing?
4. Explain the meaning of the term "central sensitization."
5. Why is palpation of the lumbar area unfavorable when the patient places their arms at head level?
6. How does the state of the skin change in regard to palpation when the patient changes from the prone position to unsupported sitting?
7. How is the vertebral column positioned in neutral side-lying?
8. Which of the tests used to assess skin consistency is the most aggressive?
9. Which of the three skin consistency tests would you select if the patient has sensitive skin?
10. Which technique is best to assess the consistency of muscles?
11. Carry out the entire palpation of muscles once using the procedure suggested.
12. Why is it more difficult to palpate the deep layers of the back extensors in the lumbar area?
13. Which types of hardened muscles are clinically relevant and must be preferentially treated in your opinion?
14. Recall the contraindications for the lumbar soft-tissue technique with forced lateral flexion.
15. A change in position can increase the effectiveness of the manual transverse stretch and the longitudinal stretch during the functional massage of the trapezius. Which change in position is being referred to?

THIS PAGE INTENTIONALLY
LEFT BLANK

9 Posterior Pelvis

- Significance and Function of the Pelvic Region ... 203
- Common Applications for Treatment in this Region ... 203
- Required Basic Anatomical and Biomechanical Knowledge ... 205
- Summary of the Palpatory Process ... 213
- Palpatory Techniques for Quick Orientation on the Bones ... 214
- Palpatory Procedure for Quick Orientation on the Muscles ... 217
- Local Palpation Techniques ... 221
- Orienting Projections ... 229
- Local Palpation of the Pelvic-Trochanter Region ... 233
- Tips for Assessment and Treatment ... 237
- Study Questions ... 238

THIS PAGE INTENTIONALLY
LEFT BLANK

9 Posterior Pelvis

Significance and Function of the Pelvic Region

The pelvis is the kinetic and kinematic center of the musculoskeletal system. It is the center of the functional unit of the lumbopelvic-hip (LPH) region. The kinematic chains of the vertebral column and the lower limbs meet here. The pelvis must be able to withstand a variety of biomechanical demands, especially when the body is in upright position. Vleeming states (personal communication):

“The body’s core stability starts in the pelvis so that the three levers—legs and vertebral column—can be moved safely!”

The pelvis has adapted itself to these demands throughout the phylogenetic evolution (Fig. 9.1):

The large, protruding ala of the ilium provides a large area for the attachment of soft tissues and therefore the muscular prerequisites for an upright posture in standing: gluteal, back, and abdominal muscles. This protruding area of the ilia envelops and protects several organs.

The sacroiliac (SI) joint has increased greatly in size; the ligamentous apparatus has become considerably stronger. The load-transferring area between the SI joint and the acetabulum or the ischial tuberosities has been reduced in length and strengthened.

The sacrum has remained in the same position in the sagittal plane, tilting inward toward the abdominal cavity. This allows lumbar lordosis and enhances shock absorption. Ligaments stabilize the sacrum’s position.

Mobility in the SI joint is related to age and gender. The range of motion is governed by hormones, among other things, in females. Pelvic movement enables the birth canal to dynamically adapt during delivery.

The increase in hip-joint mobility, especially in extension, is also the result of phylogenetic development. The femoral head is integrated into the body’s plumb line. During walking, the trochanter point is transported forward during the mid-stance phase.

The pelvic muscles have been strengthened and their endurance improved. This allows the body to economically maintain upright positions and ensures that standing on one foot is safe. The pelvis absorbs impulses arising from the legs and increases the range of hip-joint motion by rapidly transferring movement up into the lumbar spine.

In total, the phylogenetic adaptations are a good example of morphological and functional adaptation in the en-

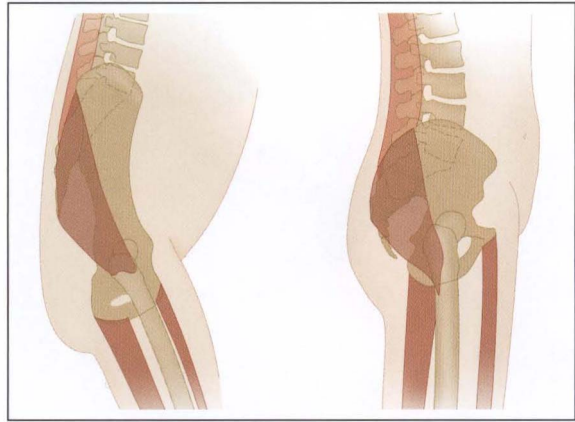


Fig. 9.1 The evolutionary development of the pelvis.

tire musculoskeletal system. These adaptations are shaped significantly by three aspects:

- Bipedal locomotion.
- Grasping function of the hands.
- Spatial adjustment of the head.

Common Applications for Treatment in this Region

The pelvis is frequently the focus of treatment for symptoms in the LPH region (lumbar spine, pelvis, hip) due to the intensive strain that the pelvis experiences during different tasks. Therapists have a special task when assessing patients: to find out why the patient is suffering from pain in the buttocks or the groin.

The following structures possibly generate pain (tissues that cause pain):

- Lumbar or inferior thoracic structures.
- The SI joints and their ligaments.
- Structures in the hip joint.
- Nerves in the gluteal region.
- Muscular components.

The last can be a primary or secondary source of pain and appear tensed and tender to touch.

Also, various internal organs are represented in the Head zones located in the skin of the gluteal region.

Certain assessment techniques and forms of treatment are thus applied to the gluteal region. Apparently, over 50 provocation and mobility tests have been described for the SI joint at an international level. Each study group

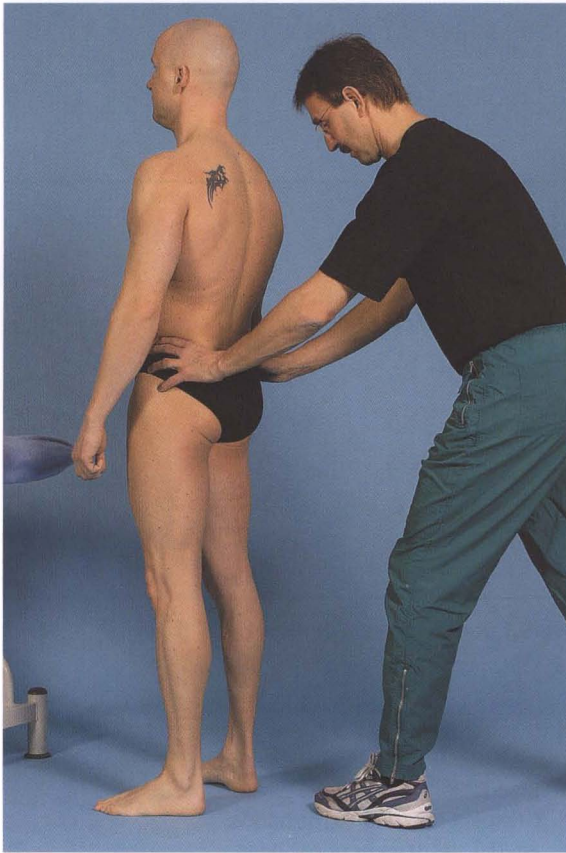


Fig. 9.2 Palpation of the posterior spines in standing.

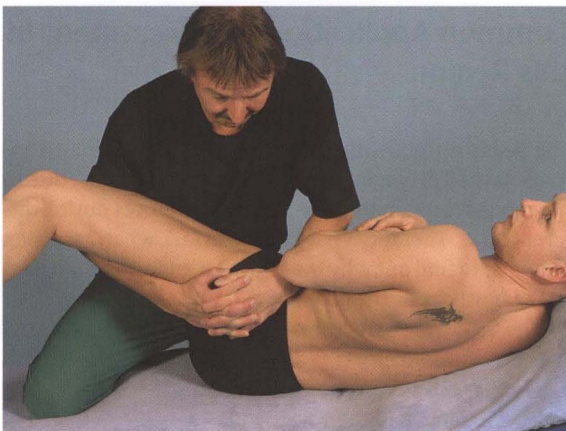


Fig. 9.3 SI joint mobilization.

for manual therapy uses their own individual test. International standardization is not yet foreseeable. When these tests are being conducted or the patient is being mobilized, it frequently makes sense that certain osseous reference points (iliac crests, anterior and posterior iliac spines) are palpated accurately and their position compared with the other side (Fig. 9.2).

The sacrum and the ilium are often mobilized in opposite directions during assessment and treatment (Fig. 9.3).

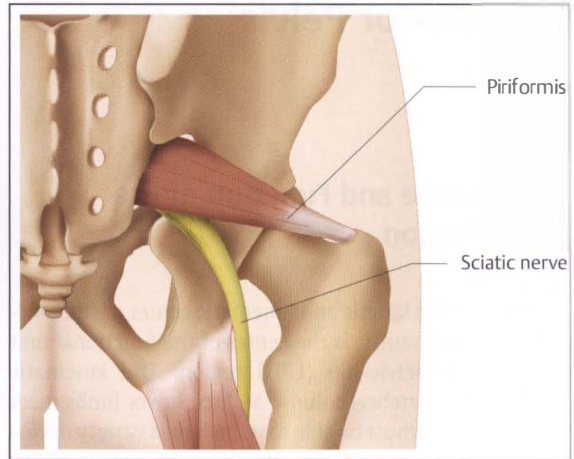


Fig. 9.4 Position and pathway of the sciatic nerve.

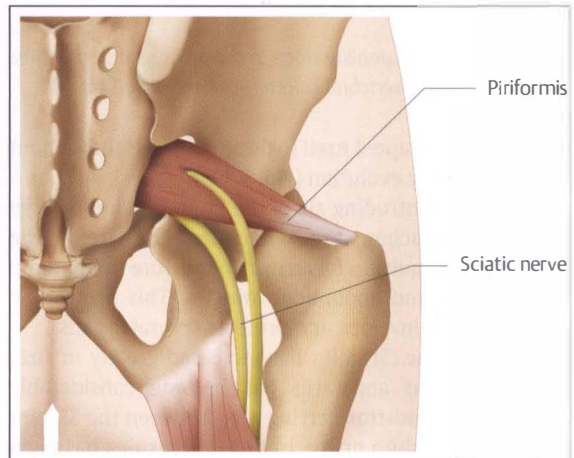


Fig. 9.5 Variations in the anatomy of the sciatic nerve.

It is very important that the hand position is well placed and secure.

Some peripheral nerves can be irritated locally as they pass through the gluteal region on their way to their target organ. In the case of the sciatic nerve, this can occur at two locations (Fig. 9.4):

- Compression neuropathies caused by an extremely tense piriformis (the piriformis syndrome).
- Friction at the ischial tuberosity and the hamstrings tendon of origin (the hamstrings syndrome).

These problems can be confirmed using an accurate and detailed palpation with the application of pressure.

A piriformis compression syndrome occurs only when at least a portion of the sciatic nerve passes through the muscle belly of the piriformis. According to Vleeming, the fibular part passes through the piriformis muscle belly in only 4%–10% of all people (Fig. 9.5). A sustained muscle contraction alone is not expected to compress the nerve as the muscle is smooth and fibrous on the side facing

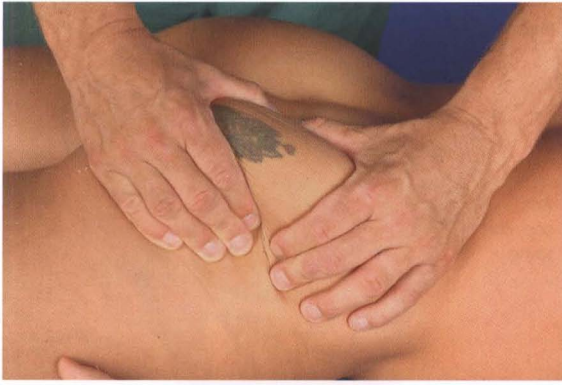

Fig. 9.6 Kneading the gluteal muscles.

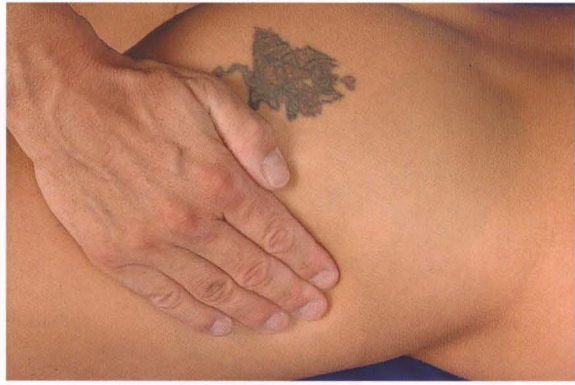

Fig. 9.8 Palpating for bursitis.

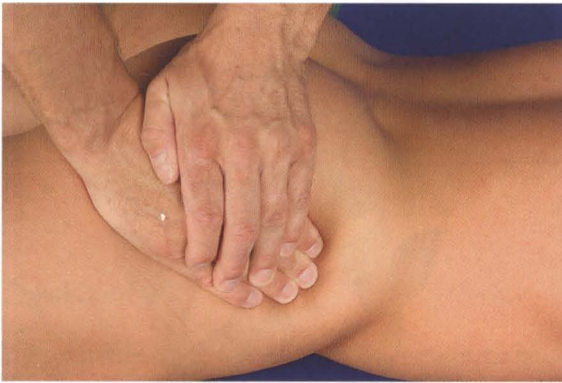

Fig. 9.7 Local frictions on the gluteal muscles.

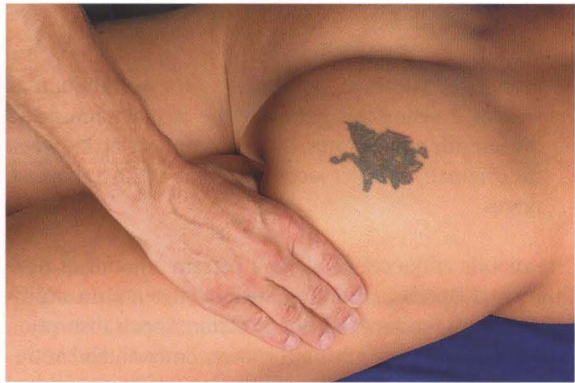

Fig. 9.9 Palpating for muscle activity in the pelvic floor.

the nerve. Also, the 4 cm-long muscle belly cannot expand so much during contraction that it compromises or stretches the nerve.

The trigger-point treatment, based on the work of Travell and Simons (1998), is concerned with the localization of locally hardened muscles that may act as independent pain generators. Dvořák also dealt with the subject of tender points within manual diagnostics. These points provide the clinician with information regarding the spinal level of sacroiliac and lumbar aggravation (Dvořák, 2008).

Dvořák labeled tender points as tendinoses and zones of irritation. Local *in vivo* anatomy is used here to find the appropriate muscular structure or to link the point that is tender on palpation to its respective muscle.

Muscle pathologies are treated using classical massage techniques, such as kneading (Fig. 9.6), local frictions (Fig. 9.7), or a variety of specialized techniques. These techniques can be conducted more accurately when the therapist has a good knowledge of the available area and can correctly feel the muscular structure being sought.

Precise palpation is also used to confirm bursitis by applying local and direct pressure (Fig. 9.8) (e.g., when presented with a type of snapping hip) or to perceive muscle activity in the pelvic floor directly medial to the ischial tuberosity (Fig. 9.9).

Required Basic Anatomical and Biomechanical Knowledge

The pelvis is the anatomical and functional center of the “lumbopelvic region.” Two movement complexes meet at the sacrum: the vertebral column and the pelvis. This means that vertebral movement is directly transmitted onto the pelvis, and vice versa.

Several points on the pelvis are of static and dynamic significance: the base of the sacrum, iliac crest, SI joint, pubic symphysis, and the ischial tuberosity. The different types of loading are dealt with here, for example, by transferring the load in sitting or standing. Important ligamental structures and muscles insert here.

Surprisingly, anatomical literature does not always agree on the bony compilation of the pelvis. Netter (2004) only includes the two pelvic bones. In total, the pelvis should be understood to be a bony ring consisting of three large parts: two pelvic bones (consisting of the ilium, ischium, and pubis) and the sacrum (Fig. 9.10).

The different parts are joined together by mobile and immobile bony connections:

- Mobile: two SI joints and the pubic symphysis.

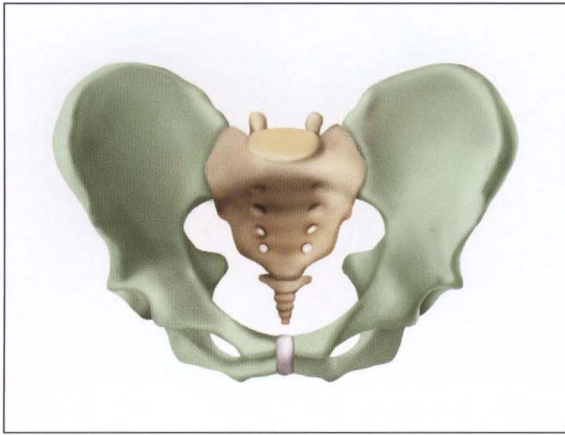


Fig. 9.10 Parts of the coxal bone.

- Immobile: Y-formed synostosis in the acetabulum as well as a synostosis between the ischial ramus and the inferior pubic ramus, the bony connection between the originally distinct sacral vertebrae at the transverse ridges.

The mobile connections allow a certain amount of flexibility in the pelvis, absorbing the dynamic impulses coming from a superior or inferior direction. Shock absorption is an important principle for the lower limbs and is continued in the pelvis. This flexibility also creates a gradual transition from the more rigid pelvic structures to the mobile lumbar segments.

Gender-based Differences

The gender-specific characteristics of the pelvis are presented in almost every anatomy book. In summary, these characteristics are based on the difference in form and are most distinctly seen in the ala of the ilium and the ischial tuberosities. In total, the male pelvis is described as being long and slender and the female pelvis as being wider and shorter. The dimensions of the female pelvis are therefore seen as a phylogenetic adaptation to the requirements of the birth canal during child birth.

The differences in detail:

- The alae of the ilia are higher and more slender in the male pelvis.
- The inner pelvic ring, the level of the pelvic inlet, or the arcuate line tend to be rounder in the male pelvis and more transversely elliptical in the female pelvis.
- The two inferior pubic rami form an arch (pubic arch) in the female pelvis. It has been described as more of an angle (pubic angle) in the male pelvis.

Naturally, these different characteristics in the bony anatomy of the pelvis also have a meaning for local *in vivo*

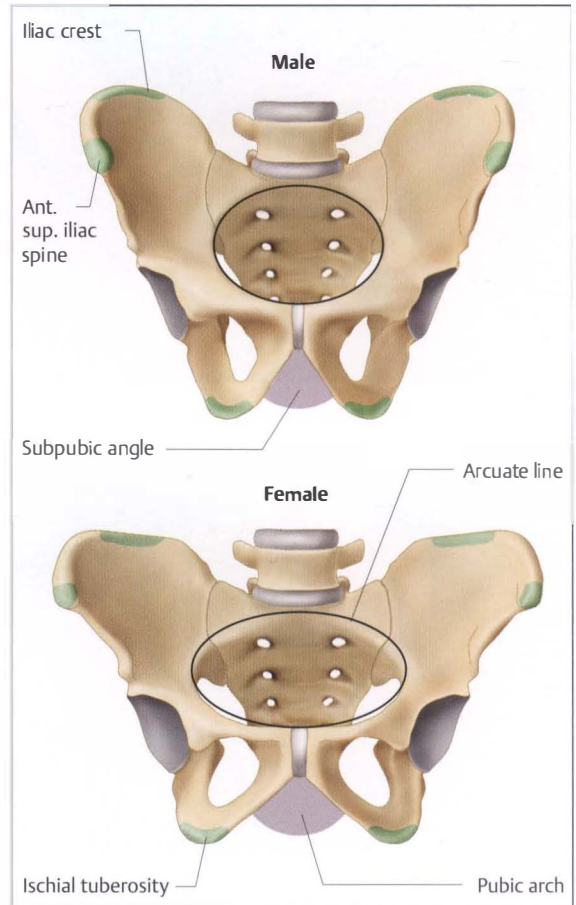


Fig. 9.11 Gender-based differences and bony reference points.

anatomy. They determine what is to be expected topographically when searching for a specific structure (Fig. 9.11):

- The iliac crests are readily used for quick orientation in the lumbar area. The most superior aspect of the iliac crest is found higher up in males than in females:
 - Males: mostly between the L3 and L4 spinous processes.
 - Females: mostly at the level of the L4 spinous process.
- As with the iliac crests, the anterior superior iliac spine (ASIS) is preferably located to determine levels within the pelvis. It can be assumed that the female ASISs are found significantly further apart than their male counterpart. Therefore, it is necessary to search for them more laterally.
- The inferior pubic rami meet at a significantly smaller angle in the male pelvis. It is therefore expected that the ischial tuberosities can be palpated significantly more medially in the male pelvis than in the female pelvis.

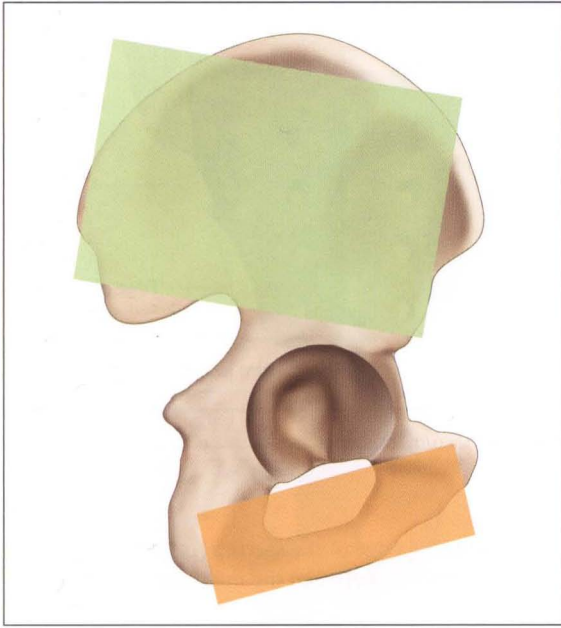


Fig. 9.12 Illustrating the planes on the coxal bone.

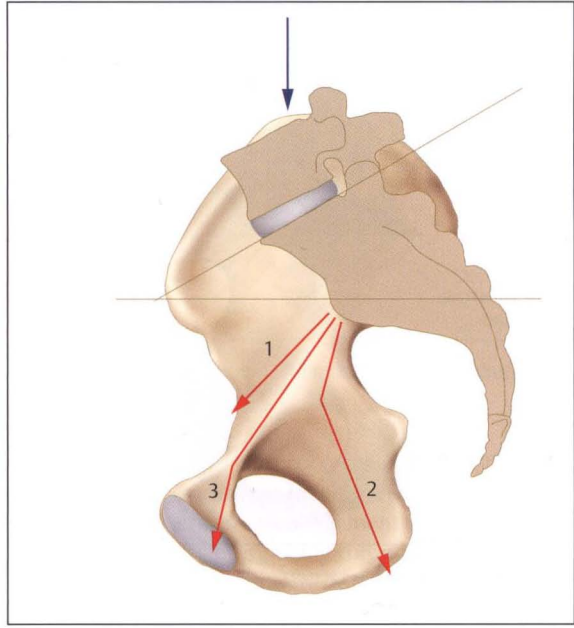


Fig. 9.13 Spongy thickening in the coxal bone.

Coxal Bone

The coxal bone is the largest fused bony entity in the musculoskeletal system once skeletal growth has been completed. Two surfaces extend superiorly and inferiorly from a central collection of bony mass in the acetabular area:

- Superior surface = ala of the ilium. This surface is entirely osseous. Its borders are strengthened by strong edges and projections (iliac crest and diverse spines). Although the middle of the ala of the ilium is osseous as well, it tends to be thinner and can be perforated in some cases.
- Inferior surface = the rami of the ischium and the pubis with a central collagen plate (obturator membrane).

When planes are drawn at a tangent over these superior and inferior surfaces, these planes are seen to be found at a 90° angle to each other (Fig. 9.12).

The protruding edges, spines, and flattened areas of both surfaces of the coxal bone act as possible sites of origin or insertion for muscles and ligaments. Anatomical specimens show that the ilium is almost completely enclosed by the small gluteal muscles and the iliacus. The obturator membrane is likewise located between the obturator externus and the obturator internus. Thus, a series of active dynamic forces act on the coxal bone.

Other sections with significantly spongy thickening (Fig. 9.13) can be identified in addition to the previously mentioned bony bracing at the edge of both coxal bones and the central bony mass:

- The body's weight in standing is transferred from the SI joint to the acetabulum and vice versa along the arcuate line. The arcuate line divides the greater lesser pelvis (1).
- Weight is transferred in sitting between the SI joint and the ischial tuberosity (2).
- Pressure and tensile stresses are transmitted from the coxal bone onto the symphysis via the superior pubic ramus (3).

The weight of the body is transferred from the vertebral column onto the pelvis at the SI joint. This is approximately 60% of the entire body weight in an upright position.

Sacrum

The sacrum is the third and central part of the bony pelvis. It is well known that the sacrum is a fusion of at least five originally distinct vertebrae. The final ossification into a single bone occurs in the fifth decade of life. Remnants of cartilaginous disks are existent prior to this.

Location and Position

The location and position of the vertebral column's kyphotic section at the pelvis can be identified in the median cut of the pelvis. The recognizable tilt of the sacrum into the pelvic space can be calculated by using the angle between the transverse plane and a line extending from

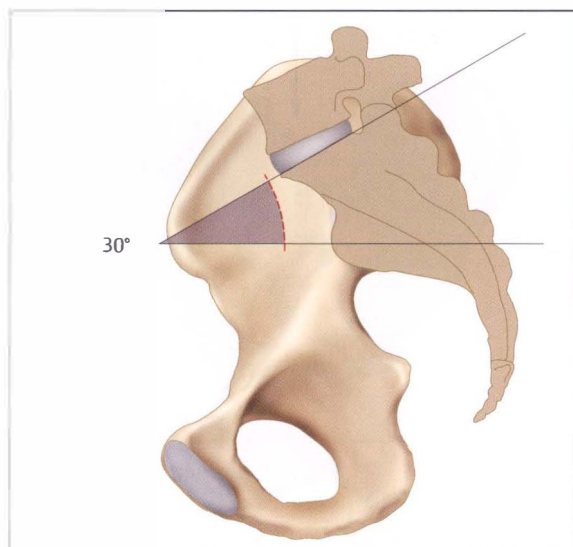


Fig. 9.14 Position of the sacrum.

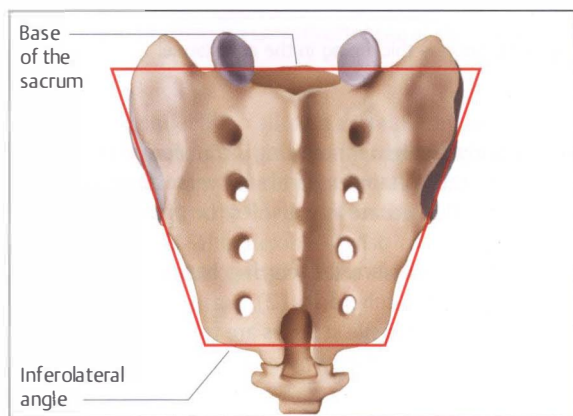


Fig. 9.15 General shape of the sacrum.

the end plate of S1 (Kapandji, 2006). This generally amounts to approximately 30° (Fig. 9.14).

The sacrum's position has several consequences:

- It is the foundation for the lumbar lordosis and therefore the double "S" seen in the vertebral column.
- The tip of the sacrum points posteriorly and enlarges the inferior section of the birth canal.
- Vertical loading in the upright position is transformed less into translational movement and more into rotational movement (tendency to nutate). This is absorbed by the ligamentous apparatus.

The sacrum's distinctive form becomes evident in the posterior view (Fig. 9.15). It is characterized by various structures:

- The S1 end plate (base of the sacrum).
- The sides of the sacrum:
 - S1 to S3 = auricular surface and the sacral tuberosities (neither are palpable)

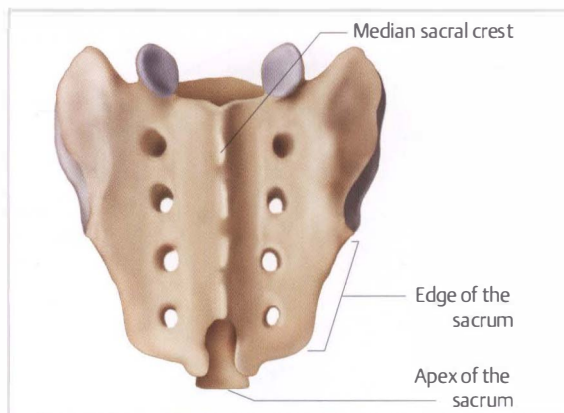


Fig. 9.16 Sacrum, posterior aspect.

– S3 to S5 = edge of the sacrum (palpable).

- The connection between the inferolateral angles.

It is now apparent that the sacrum is not triangular in shape but rather trapezoid.

Detailed Anatomy

The posterior aspect demonstrates additional interesting details (Fig. 9.16):

- S1 has not only received the vertebral body end plate, but also the superior articular processes. These form the most inferior vertebral joints with L5.
- Generally, it is possible to look through the bony model in four places on each side. The sacral foramina are found posteriorly and anteriorly at the same level and allow the anterior rami and the posterior rami of the spinal nerves to exit from the vertebral column and into the periphery.
- Long ridges are found over the entire remaining posterior surface. These ridges are formed by the rudiments of the sacral vertebrae that have grown together. The median sacral crest is the most important of these ridges for palpation. The rudiments of the sacral spinous processes can be seen here as irregular protrusions and can be palpated well. All other crests and the posterior foraminae are hidden under thick fascia and the multifidus muscle.

Apex of the Sacrum and the Coccyx

The apex of the sacrum forms the sacrum's inferior border. It lies in the middle, slightly inferior to the line connecting the two inferolateral angles. The mobile connection to the coccyx is found here. This is interchangeably labeled a synovial joint or a synchondrosis (with the intervertebral disk) in literature (Fig. 9.17).

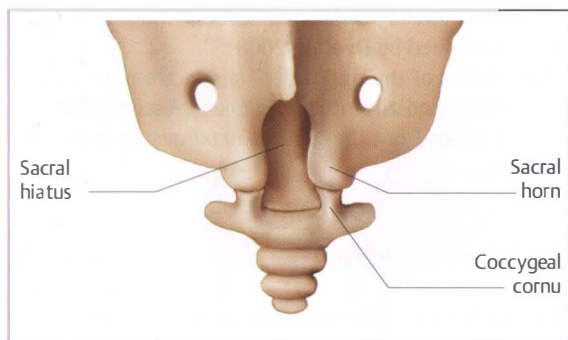


Fig. 9.17 Sacrococcygeal transition

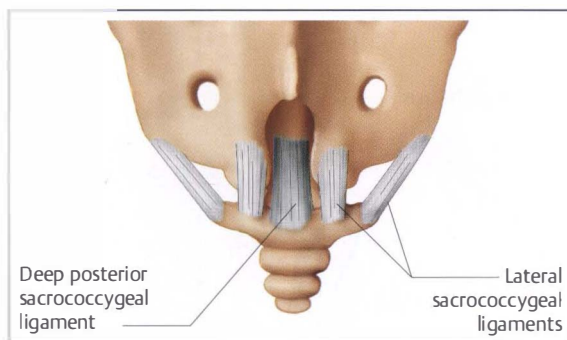


Fig. 9.19 Ligamentous connections between the sacrum and coccyx.

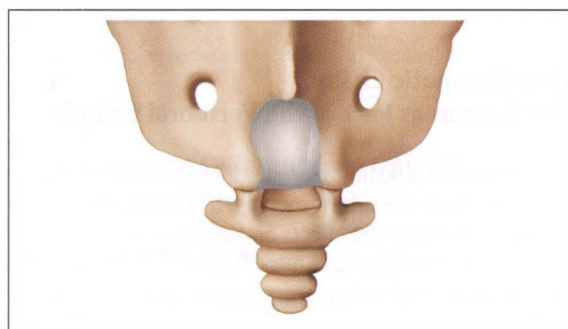


Fig. 9.18 Hiatus and membrane.

Great variations are seen in the construction of the inferior sacral area. The median sacral crest usually runs down to the level of S4. Normally no rudiments of the spinous processes can be observed at the S5 level. Instead, an osseous cleft can be seen: the sacral hiatus. According to Lanz and Wachsmuth (2004a), this posterior cleft is only found in approximately 46% of the population at the level of S5 and extends to the level of S4 or S3 in 33.5%. This makes accurate palpatory orientation on the inferior sacrum significantly more difficult.

The S5 arch leading to the hiatus is incomplete and is covered by a membrane (Fig. 9.18). Small osseous horns (sacral horns) form its borders on the side. These horns are easily palpable in most cases, but vary greatly in size and are irregularly shaped. They face two small osseous protrusions in the coccygeal bone, the coccygeal cornua, which are also palpable.

The covering membrane at the level of S5 is a continuation of the supraspinous ligament and continues onto the coccyx as the superficial posterior sacrococcygeal ligament. The membrane covers the vertebral canal as it tapers inferiorly. It is palpated as a firm and elastic structure, which clearly distinguishes it from the osseous borders.

Additional ligamentous connections between the sacrum and coccyx are (Fig. 9.19):

- The deep posterior sacrococcygeal ligament, the continuation of the posterior longitudinal ligament.
- The lateral sacrococcygeal ligament (intercornual and lateral sections), presumably continuations of the former ligamenta flava and the intertransverse ligament.

These ligamentous structures are traumatically overstretched when people fall onto their buttocks and especially onto the coccyx. Their tenderness on pressure can be treated successfully using transverse frictions to relieve pain when they are directly palpated.

The Pelvic Ligaments

The ligaments of the pelvis can be classified according to their position and function. We are therefore familiar with ligaments that:

- act to maintain contact between the surfaces of the SI joint:
 - interosseous sacroiliac ligaments, located directly posterior to the SI joints;
- restrict nutation and therefore stabilize the sacrum:
 - anterior sacroiliac ligaments (reinforce the capsule);
 - posterior sacroiliac ligaments;
 - sacrotuberous ligament;
 - sacrospinous ligament;
- can limit counternutation:
 - long posterior sacroiliac ligament.

The **anterior sections of the capsule** (anterior sacroiliac ligaments) are very thin (≤ 1 mm) and have little mechanical relevance (personal correspondence from the IAOM study group). They perforate easily when joint pressure is increased (arthritis). They are not stretched during the iliac posterior test (SI joint test) as the entire function of the ligament is found posterior to the joint.

The **interosseous ligaments** are very short, nociceptively supplied ligaments that act as pain generators in the presence of sacroiliac pathologies (e.g., instability or

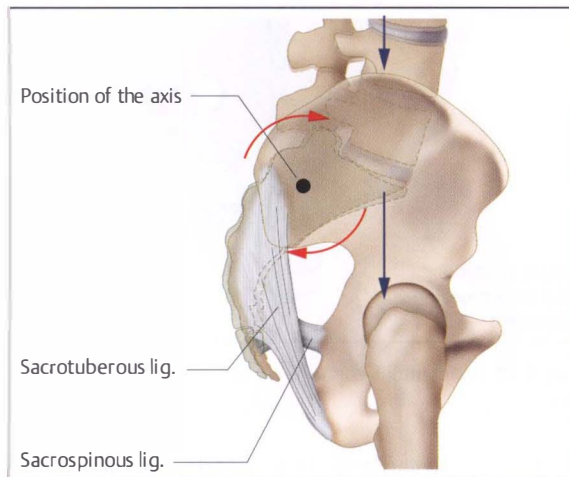


Fig. 9.20 Function of the nutation restrictors.

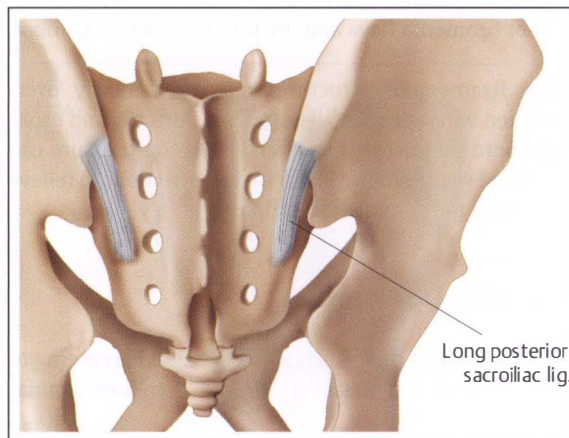


Fig. 9.21 Long posterior sacroiliac ligament.

blockages). Their function is to maintain the traction in the respective SI joint.

It is easiest to understand the function of the **nutation restrictors** by looking at the stress on the sacrospinous and sacrotuberous ligaments when the body is in a vertical position (Fig. 9.20). Approximately 60% of the body's weight bears down on the S1 end plate. This is positioned quite anterior to the nutation/counternutation axis so that the base of the sacrum tends to "fall" farther into the pelvic space. This tendency is counteracted by the posterior and anterior ligaments positioned very close to the joint. The tip of the sacrum tends to lever itself anteriorly and superiorly. This movement is counteracted by the sacrospinous and sacrotuberous ligaments.

The **long posterior sacroiliac ligament** (Fig. 9.21) connects both posterior superior iliac spines (PSISs) with the respective edge of the sacrum. It is approximately 3–4 cm long, 1–2 cm wide, and extends inferiorly into the sacrotuberous ligament. It is the only ligament that counteracts counternutation. It has been described by Vleeming

(1996) and already published several times. It has also been mentioned by Dvořák (2008).

The fibers of the multifidus muscle are noticeable as they extend medially into the ligament. A section of the ligament arises from the gluteus maximus on the lateral side.

The Sacroiliac Joint

The significance of the pelvis as central element in the musculoskeletal system has already been described. To understand the exceptional significance of the SI joint, the functional relationship between the various kinematic chains should first be clarified.

First Kinematic Chain: The Sacrum as Part of the Vertebral Column

The L5, sacrum, and ilium form a kinematic chain. No bone moves without the others moving. It is nearly impossible to clearly attribute the effects of pathology and treatment to a specific level. The iliolumbar ligaments (especially the inferior short, stiff sections) are important for the linkages within this chain.

Second Kinematic Chain: The Sacrum as Part of the Lower Limbs

The largest SI joint movements occur when the hip joints are included in the movement symmetrically and without loading, such as is the case during hip flexion in supine position.

Third Kinematic Chain: The Sacrum as Part of the Pelvic Ring

The SI joint biomechanics are controlled by the symphysis. Extensive, opposing movements of the iliac bones primarily meet up at the symphysis. SI joint instability can also affect the symphysis. We therefore differentiate the SI joint instability types into those without loosening of the symphysis and those with loosening of the symphysis.

Few topics concerning the musculoskeletal system are discussed as controversially as the SI joint. Views and opinions about the SI joint vary between the individual manual therapy study groups as well as between manual therapists and osteopaths. The significance given to the SI joint therefore depends on each therapist's personal criteria and individual point of view.

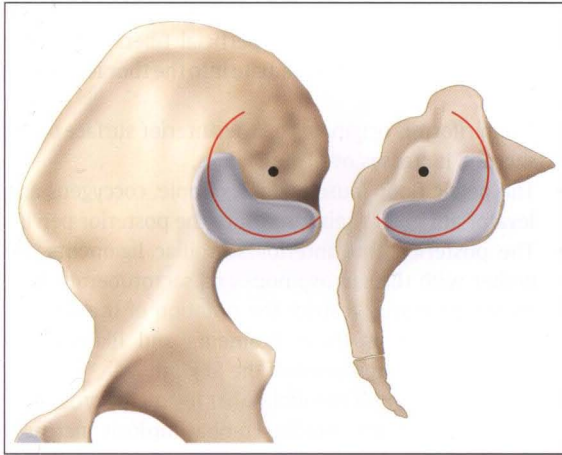


Fig. 9.22 SI joint surfaces (according to Kapandji).

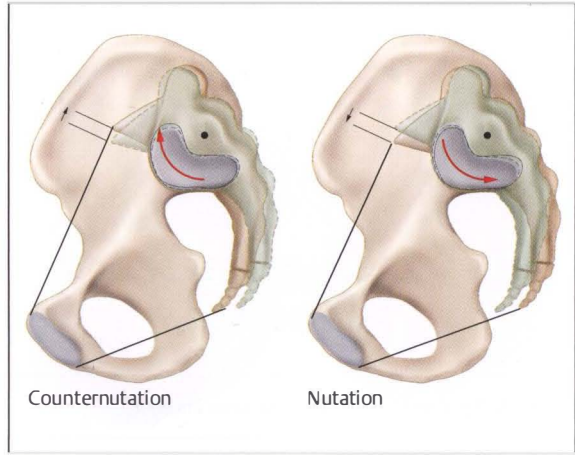


Fig. 9.23 SI joint movements (according to Kapandji).

Reasons for the Differences in Opinion about the SI Joint

Special Anatomical Factors

The construction of this joint cannot be compared with any “traditional” joint (Fig. 9.22):

- It is a firm joint (amphiarthrosis) anteriorly and connects the bones posteriorly via a ligamentous structure (syndesmosis).
- The joint surfaces are curved at all levels and have ridges and grooves.
- The sacral joint surface is very thick, the iliacal surface extremely rough.

SI Behavior during Movement

- The sacrum and the ilium always move against each other in a three-dimensional manner.
- Describing the position of the axes during these movements is extremely complicated.
- Movement primarily occurs around a frontotransversal (transversal) axis and is very slight (according to Goode [2008], approximately a maximum of 2°). These movements are labeled nutation and counternutation (Fig. 9.23). Women affected by hormones are particularly subject to movement here (Brooke, 1924, and Sashin, 1930). Mobility also increases when SI joint disorders are present, for example, with arthritis.
- The male SI joint starts to become immobile from around age 50 due to the formation of osseous bridges (Brooke, 1924 and Stewart, 1984).

The complexity of this joint also makes it easy to understand why comparatively few good studies exist that examine standardized assessment methods and treatment techniques. More than 50 tests have been described for assessment alone.

For these reasons, the SI joint remains obscure and difficult to comprehend—a mystical structure, a platform for experience and speculation.

Sacroiliac Joint Biomechanics

The SI joint is held together by its structure and the strength of tissues. This can be seen in the frontal plane by looking at the general alignment of the joint surfaces. According to Winkel (1992) the joint surfaces are tilted at approximately 25° from the vertical (Fig. 9.24).

The sacrum’s wedge shape permits the auricular surface to support itself on the similarly shaped iliacal joint surface (force closure). Nevertheless, the joint’s construction and the friction coefficient of the uneven and roughened surface are not sufficient to stabilize the sacrum’s position.

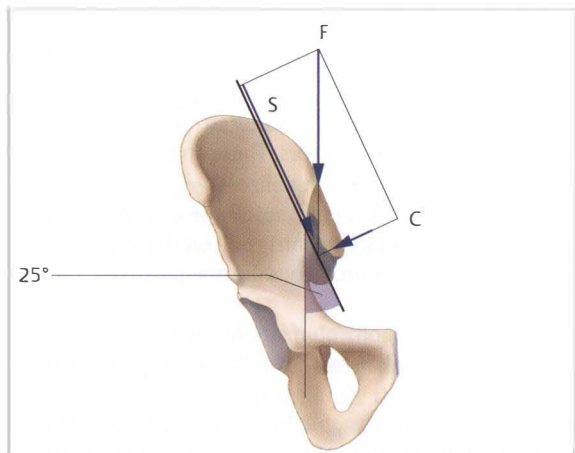


Fig. 9.24 Alignment of the SI joint surfaces (from Winkel, 1992). F = force, S = shear force, C = compression.

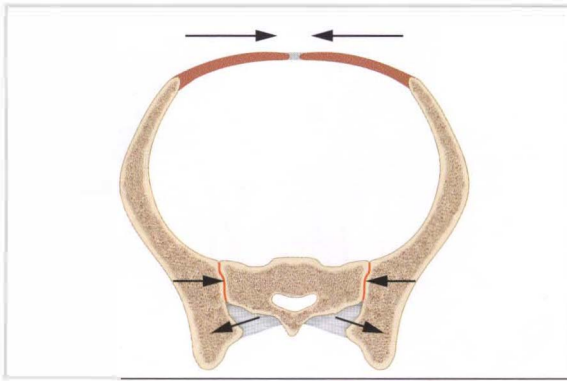


Fig. 9.25 Tension placed on the ilia from anterior.

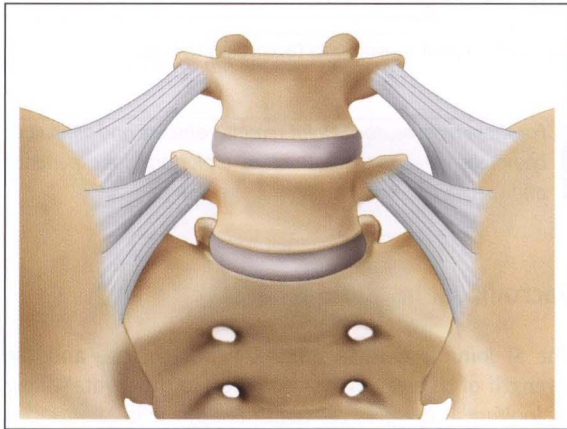


Fig. 9.26 Iliolumbar ligaments (according to Kapandji).

It therefore becomes clear that additional strength is needed to keep the joint surfaces together (holding the joint together with the strength of tissues). In particular, this is the function of the interosseous sacroiliac ligaments. These ligaments lie immediately posterior to the joint surfaces and are made of short, very strong, and nociceptively innervated collagen fibers. The SI joint is held together more by the joint structure in males and the strength of tissues in females.

The interosseous ligaments are supported by muscular structures and other ligamentous structures that generally act as nutation restrictors. These structures therefore qualify as further SI joint stabilizers:

- The anterior abdominal muscles (especially the oblique and transverse sections) pull on the ilia anteriorly and place the interosseous ligaments under tension (Fig. 9.25).
- The complex thoracolumbar fascia is considered an important stabilizer of the lumbosacral region (Vleeming, 1995).
- The multifidus acts as a hydrodynamic strengthener. Its swelling during contraction tightens the thoracolumbar fascia.

- The gluteus maximus originates on the posterior surface of the sacrum. The superficial fibers cross over the SI joint and likewise radiate into the thoracolumbar fascia.
- The piriformis originates on the anterior surface of the sacrum. It crosses over the SI joint.
- The pelvic floor muscles, for example, coccygeus and levator ani exert their force onto the posterior pelvis.
- The posterior and anterior sacroiliac ligaments, together with the sacrospinous and sacrotuberous ligaments, primarily restrict the nutation of the sacrum. Loading tightens these ligaments and likewise increases the compression of the SI joint.
- Several sections of the iliolumbar ligaments cross over the SI joint in the middle. Lumbar lordosis increases the SI joint surface compression (Fig. 9.26).

Pool-Goudzwaard et al. (2001) described in a study the stabilizing role of the iliolumbar ligaments on the SI joint. Gradual transection of the ligaments resulted in a significant increase in SI joint mobility in the sagittal plane.

The ligaments also contribute to sacroiliac movements being transmitted onto the lower lumbar segments and vice versa. Movement within the pelvic ring and movement in L4–S1 must always be regarded as a kinematic chain.

The dominating concept until several years ago was that the SI joint, as a classic amphiarthrosis, was not supplied with its own muscles. This presumption is correct as regards the mobility function. However, it can be put on record that force closure, in the form of a multitude of dynamized ligaments and muscles, holds the joint surfaces together and stabilizes the SI joint.

Ligament Dynamization in the Sacroiliac Joint

The interplay between muscles and ligaments near joints has been known for a long time now. The knee joint is a perfect example of this. The extension of muscles into capsular–ligamentous structures is called ligament dynamization. Two examples of pelvic ligaments are presented here to demonstrate how intensive the contact is between muscles and the functional collagen in this region.

Sacro tuberous Ligament

The sacrotuberous ligament is connected to the:

- Gluteus maximus from a posterior direction.
- Biceps femoris from an inferior direction.
- Piriformis from an anterior direction.
- Coccygeus from a medial direction.

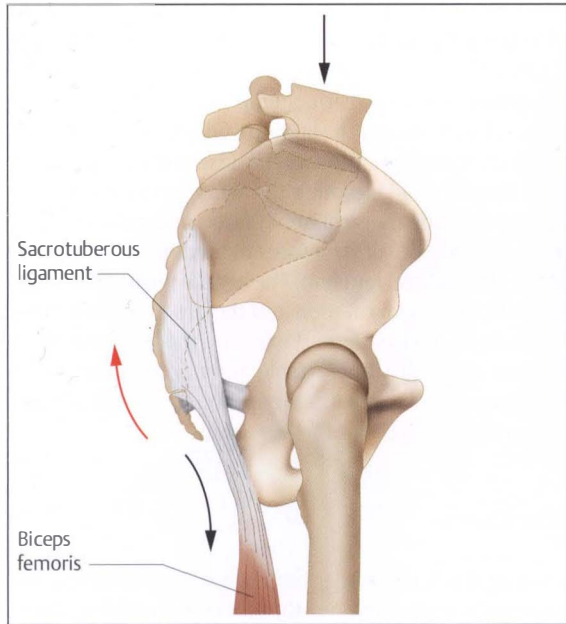


Fig. 9.27 Dynamization of the sacrotuberous ligament.

Vleeming (1995) explains the functional significance of the sacrotuberous ligament, dynamized by the biceps femoris, on the SI joint as follows:

We know that the hamstring muscles are most active at the end of the swing phase during gait. The hamstrings slow down the anterior tibial swing a few milliseconds before heel contact, decelerating knee extension.

The long head of the tensed biceps femoris often merges with the sacrotuberous ligament via large bundles of collagen (also without contact with the ischial tuberosity) and dynamizes the ligament (**Fig. 9.27**). The biceps femoris activity prevents the sacrum from fully nutating and stabilizes the SI joint directly before the landing phase.

Thoracolumbar Fascia

The thoracolumbar fascia consists of three layers:

- Superficial layer—posterior layer.
- Middle layer—inserted on the lumbar transverse processes.
- Deep layer—anterior layer found anterior to quadratus lumborum and iliopsoas.

The posterior, superficial layer contains collagen fibers arising from several muscles that can tighten up this aponeurosis:

- Latissimus dorsi.
- Erector spinae.
- Gluteus maximus.

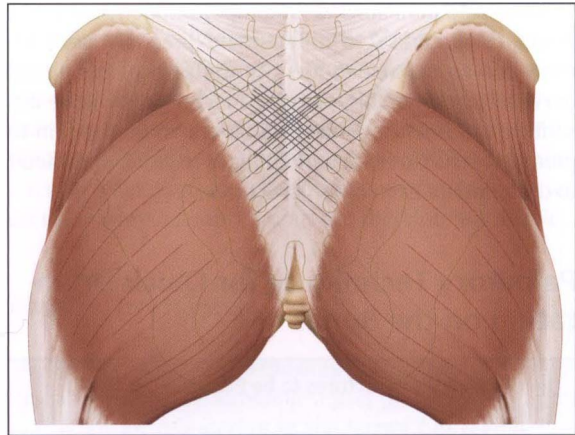


Fig. 9.28 Alignment of the collagenous fibers in the thoracolumbar fascia.

Each of the muscles is able to dynamize the fascia. The fascia forms a diagonal sling between the latissimus dorsi and the contralateral gluteus maximus (**Fig. 9.28**). The force of the sling acts perpendicular to the joint surfaces, stabilizing the SI joint and the inferior lumbar spine during strong rotation. Consequently, the participating muscles and the fascia belong to the primary SI joint stabilizers. This sling can be especially trained using trunk rotation against resistance.

This fascial layer is also connected to the supraspinous ligament and the interspinous ligament up to the ligamentum flava. Vleeming (personal communication) comments on this: “The entire system is dynamically stabilized.”

Muscles also dynamize the middle and deep layers. It is well known that the transversus abdominis tightens the middle layer (see also the section “Detailed Anatomy of the Ligaments,” in Chapter 10, p. 248).

The required background information on the pelvic muscles is given in the section “Palpatory Procedure for Quick Orientation on the Muscles” below, page 214.

Summary of the Palpatory Process

Two different approaches to the palpation of the posterior pelvic region will be explained below:

- Quick orientation.
- Local palpation.

The introductory quick orientation is used to obtain an initial rough impression of the location and shape of prominent bony landmarks that delineate the working area for diagnostic and treatment techniques in the region. Large muscles are defined and differentiated from one another in their position and course.

Local palpation aims to find important bony reference points (landmarks), to differentiate precisely between form and tissue, and to identify the path of peripheral nerves. To achieve this, palpatory techniques will be described and orienting lines will be drawn on the skin to point out structures that are difficult to reach or difficult to differentiate from other structures.

Palpatory Techniques for Quick Orientation on the Bones

Overview of the Structures to be Palpated

- Iliac crest.
- Greater trochanter.
- Sacrum.
- Ischial tuberosities.

First, the large structures in this region are searched for to enable quick and effective orientation in the region of the bony pelvis (Fig. 9.29): iliac crest, greater trochanter, sacrum, and ischial tuberosities.

Therapists should be aware of the location and dimensions of these structures for a variety of reasons. The bony landmarks constitute the border of the area of treatment for the gluteal muscles. When orientation is exact, the actual treatment area for this muscle, for example, using classical Swedish massage or functional massage techniques, becomes considerably smaller than perhaps originally expected. Those therapists that orient themselves less can apply massage techniques occasionally to the sacrum. Quick orientation restricts the area to be treated to the gluteal muscles and their insertions.

These large osseous structures provide important clues for the precise local palpation that comes up later.

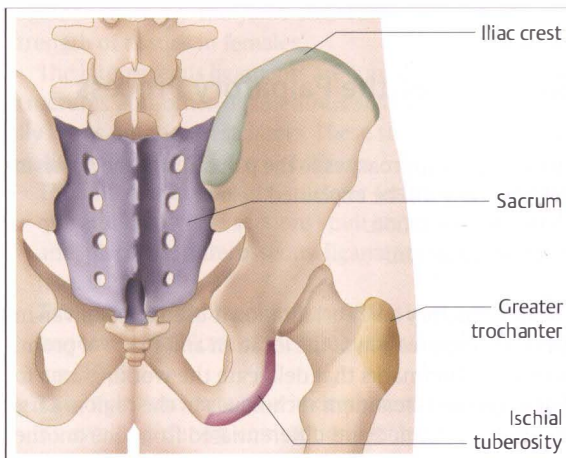


Fig. 9.29 Bony reference points.

Starting Position

The patient lies on a treatment table in a neutral prone position. The sections of the body are positioned without lateral shift or rotation. The arms lie next to the body. The patient should avoid elevating the arms up to head level as this tightens the thoracolumbar fascia and makes the palpation of a variety of structures more difficult in the area of the lumbosacral junction. The head is positioned, when possible, in neutral rotation and the nose is placed in the face hole of the treatment table. The therapist stands on the side of the treatment table and opposite the side to be palpated. Please refer to the section "Starting Position," Chapter 8, page 186 for further details.

Iliac Crests

Locating the iliac crests is the quickest and most preferred approach for orientation in the LPH region. It is possible to roughly orient yourself in the lumbar region from here, find the lowermost rib, and locate the superior border of the pelvis.

Technique

The quick orientation can be conducted simultaneously on both sides of the patient's body. Both hands form a firm surface; the thumbs are abducted. The lateral sides of the hands are placed on the patient's waist and move in a medial direction while moderate pressure is being applied. This technique is continued until the tissue resistance significantly increases and eventually stops further movement (Fig. 9.30).

Starting from this position, the hand is pushed in a variety of directions:

- Pressure in a medial direction → resistance is soft and elastic: pressure is being applied to the edges of the latissimus dorsi, quadratus lumborum, and erector spi-

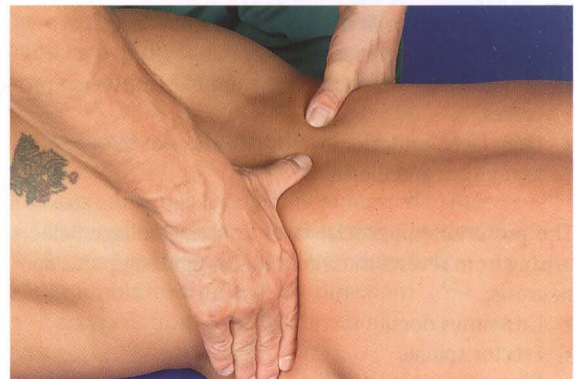


Fig. 9.30 Quick orientation: iliac crests.

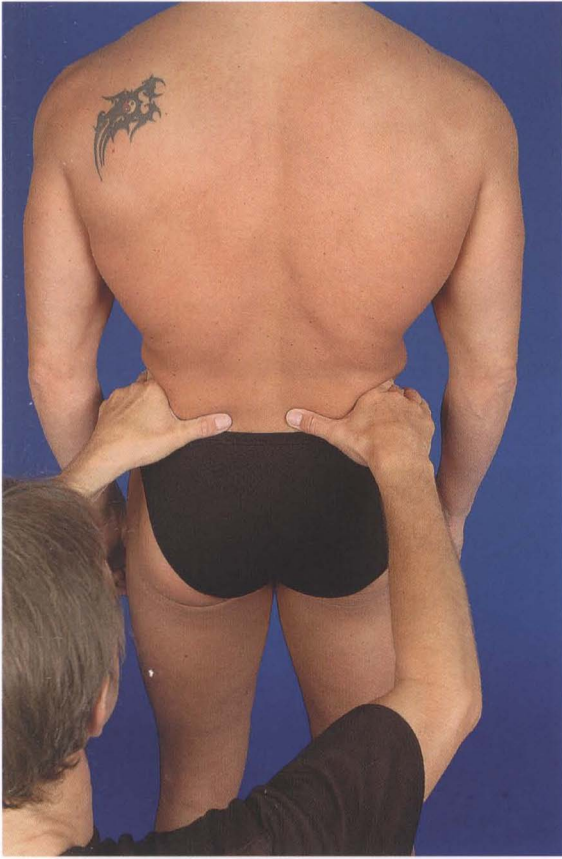

Fig. 9.31 Quick orientation: iliac crests—SP in standing.

nae. This is approximately at the level of the L3/L4 spinous processes.

- Pressure in a superior direction → resistance becomes significantly firmer. The 12th or 11th rib is reached when coming from an inferior position.
- Pressure in an inferior direction → resistance becomes significantly firmer: pressure is applied onto the iliac crest when coming from a superior position = superior border of the pelvis.

When palpating the distance between the lowest rib and the iliac crest, we see that this distance is approximately two fingers wide and hence clearly smaller than on common skeletal models. This small distance clearly demonstrates the necessity of flexibility in the 11th and 12th ribs. The lowest ribs move closer to the iliac crests during extensive lateral flexion and must, at times, move out of the way in an elastic manner.

Tip: Start the palpation anteriorly if the soft tissue at the waist does not permit palpatory differentiation between the iliac crest and the lowest rib. Localization of the anterior superior iliac spine is also possible and accurate in the prone position. The upper edge of the iliac crest can be followed from here until the posterior trunk is reached.

The technique described here is also used when assessing the presence of pelvic obliquity. The bipedal stand is used as the SP (Fig. 9.31). This SP requires significantly more muscle activity in the patient to stabilize the upright posture. Due to the increased tension in the muscles, more resistance is felt during palpation, it is more difficult to conduct the palpation, and conclusions or evaluations based on these bony reference points are therefore unreliable.

Greater Trochanter

The greater trochanter is the only part of the proximal femur that is directly accessible and is therefore an important point for orientation in the lateral hip region. It is the attachment site for many small muscles that come from the pelvis and elongates the lever arm for forces arising from the small gluteal muscles. The greater trochanter additionally provides therapists with the possibility of drawing conclusions about the geometry of the femur.

Technique

It is very helpful if the therapist can clearly visualize the topography of this region. Two additional aids can be used for orientation if it is difficult to picture the position of the greater trochanter accurately:

- The greater trochanter can be found at approximately the level of the tip of the sacrum. This is roughly found at the level of the start of the postanal furrow at S5 (Fig. 9.32).
- The trochanter is found approximately one hand-width inferior to the iliac crest.

The therapist places the flat hand on the lateral pelvis and expects to feel a large, rounded structure—bony and hard to the touch—when directly palpating it (Fig. 9.33).

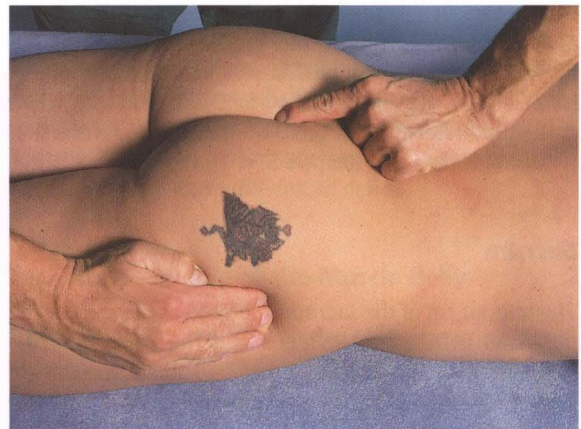


Fig. 9.32 Locating the greater trochanter.

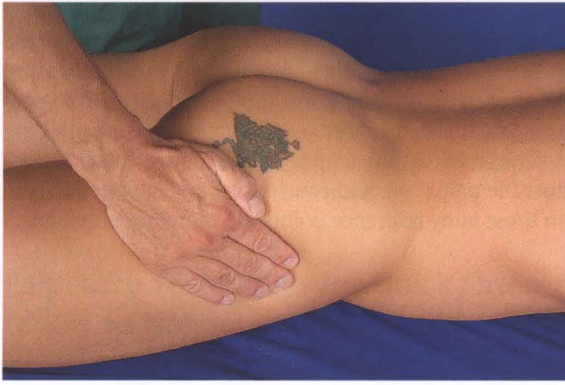

Fig. 9.33 Palpating the greater trochanter.

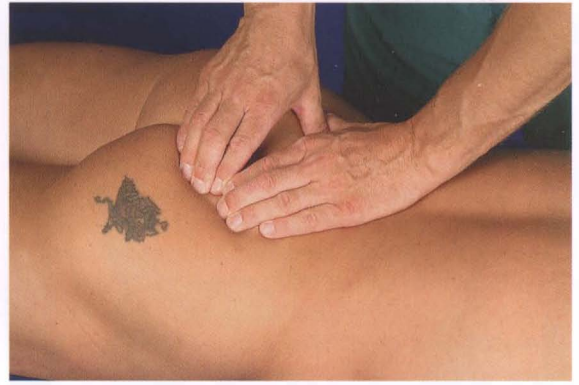


Fig. 9.35 Palpating the edge of the sacrum.

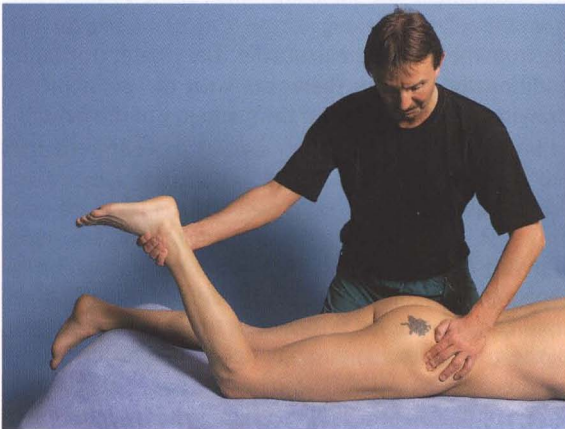


Fig. 9.34 Confirmation with movement.

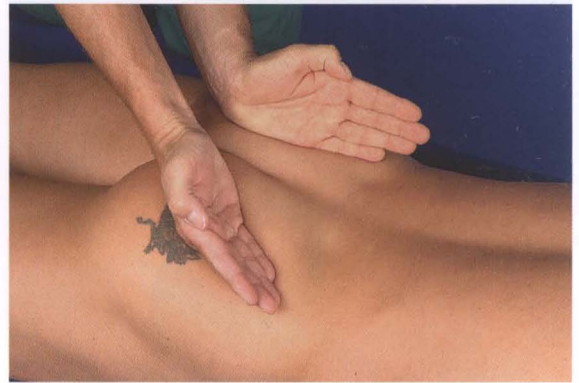


Fig. 9.36 Demonstrating the size of the sacrum.

Tip: It is sometimes difficult to find the trochanter as this region may be obese in some patients. In these cases another aid is needed to confirm the location of the trochanter. The therapist can flex the knee on the ipsilateral side and use the lower leg as a lever, internally and externally rotating the hip joint. This results in the trochanter rolling back and forth underneath the palpating fingers and enables the lateral surface and the superior aspect to also be palpated well (Fig. 9.34).

The superior tip of the greater trochanter is the point of insertion for the often tensed piriformis, among others (see also p. 230). The lateral surface is a good lead when manually determining the femoral neck anteversion (FNA) angle (see also Chapter 5, p. 104).

Sacrum

The inferior tip of the sacrum is located at the start of the post-anal furrow and extends superiorly for approximately one hand-width. As mentioned above, the sacrum is significantly wider than is commonly perceived or seen on skeletal models.

Technique

Several fingertips of one or both hands are placed perpendicular to the longitudinal axis on the area where the sacrum is suspected to be. This is several finger-widths superior to the post-anal fissure.

Transverse palpation is used. The sacrum feels like a flat, irregularly shaped structure. It always feels hard when direct pressure is applied to it during the assessment of consistency. A more precise differentiation of the structures on the sacrum will be described in the sections below (see p. 224 ff). The transverse palpation proceeds in a lateral direction until the finger pads slide anteriorly (Fig. 9.35).

The consistency assessment demonstrates a soft, elastic form of resistance. This is the edge of the sacrum, which is now followed along its entire length superiorly and inferiorly. The inferolateral angle of the sacrum is reached when palpating in an inferior direction.

Tip: Once the position of the two edges has been found, the medial edges of the hands can be used to show the entire length of the sacral edges. The entire width of this central structure in the bony pelvis is now recognizable (Fig. 9.36). As

will be explained later during precise palpation, the palpated edge does not correspond to the entire length of the sacrum (superior–inferior dimensions). The edge is only palpable from the inferior angle to the level of S3. The SI joint and the iliac crest are connected at the superior end.

Ischial Tuberosity

The ischial tuberosity is another large structure and a major important point for orientation. It is an important attachment site for thick ligaments (sacrospinous ligament) and muscles (hamstrings).

Technique

The therapist uses a pinch grip (thumb medial), palpating along the gluteal fold in a medial direction until the thumb comes across the hard resistance of the tuberosity (Fig. 9.37). The tuberosity is a surprisingly wide structure. The tip of the tuberosity is relevant for now.

Palpatory Procedure for Quick Orientation on the Muscles

Overview of Structures to be Palpated

- Sacrum—medial.
- Iliac crest—superior.
- Ischial tuberosity—inferior.
- Greater trochanter—inferolateral.

The quick osseous orientation has determined the position of the muscular soft tissue in the gluteal region (Fig. 9.38). The muscles extend between the sacrum—medial, iliac crest—superior, ischial tuberosity—inferior, and greater trochanter—inferolateral.

In most cases it is impossible to recognize the borders or the protruding points of the buttock muscles or their insertion. Muscular activity is required to define the position and the borders of these muscles.

Starting Position

The neutral prone position described above is generally sufficient to gain access to the laterally lying muscles. Side-lying is another possible SP.

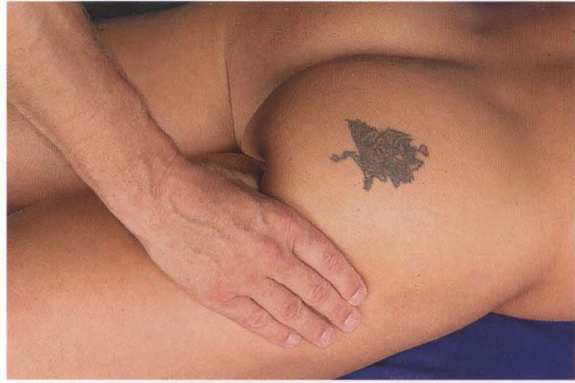

Fig. 9.37 Locating the ischial tuberosity.

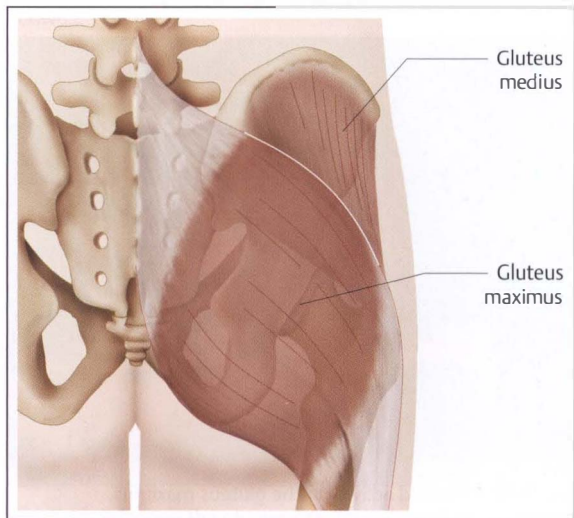


Fig. 9.38 Position of the gluteal muscles between the osseous boundaries.

Gluteus Maximus

The most prominent muscular structure in the posterior pelvis is the large muscle of the buttocks. In most cases, the shape of the muscle belly can be clearly observed when the muscle is active. The medial and lateral borders of the muscle belly are well defined as this muscle largely contributes to the development of the post-anal fissure and the gluteal fold. The superior and inferior borders are significantly more difficult to define.

Technique—Middle of the Muscle Belly

The patient is asked to raise the leg off the treatment table to demonstrate the shape of the muscle. The second hand can be used to resist active hip extension if the muscle is not active enough to be located (Fig. 9.39). If this is also not sufficient to define the muscle, the flattened hand is

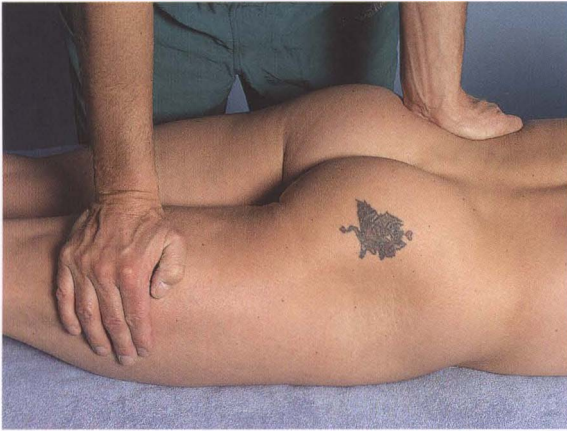


Fig. 9.39 Activity in the gluteus maximus.

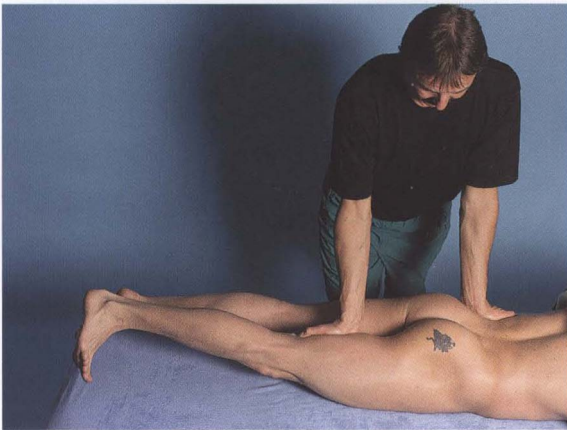


Fig. 9.40 Increased activity in the gluteus maximus.

placed in the center of the buttock and the muscle is reactivated with hip extension.

Tip: If active extension, with or without resistance, is not sufficient in defining the shape of the muscle belly, the other functions of the gluteus maximus can be used. Repeated muscular contractions are used to emphasize the prominences and contours more clearly.

The gluteus maximus is a strong external rotator of the hip joint. Its action in the sagittotransversal (sagittal) plane is the subject of controversy in the literature. As the superior parts of the muscle are found superior to the adduction–abduction axis, it remains questionable whether the muscle only adducts or whether it can also abduct the hip. Hip adduction is recommended to gain better differentiation to the small gluteal muscles.

The muscle activity is increased using the following method:

- The patient turns the tip of the foot outward and the heel inward before or during leg elevation.
- While maintaining the muscle activity in extension and external rotation, the therapist applies additional

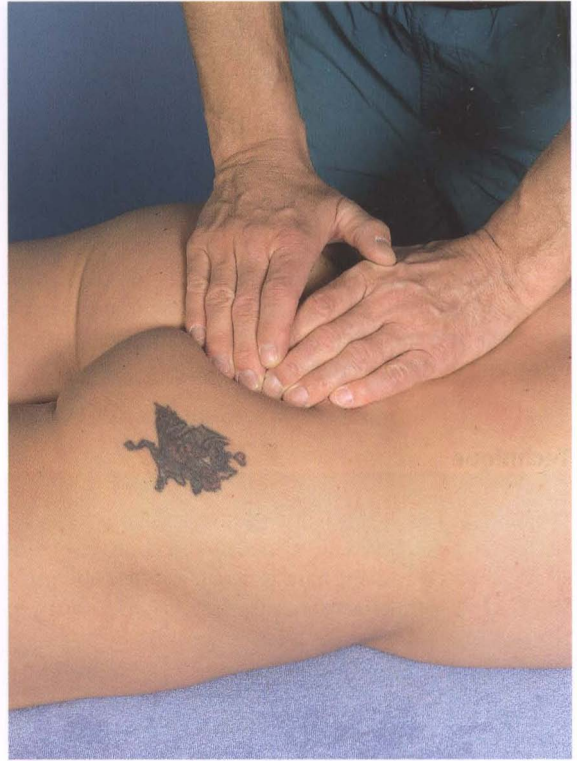


Fig. 9.41 Palpating the gluteus maximus—area of origin when relaxed.

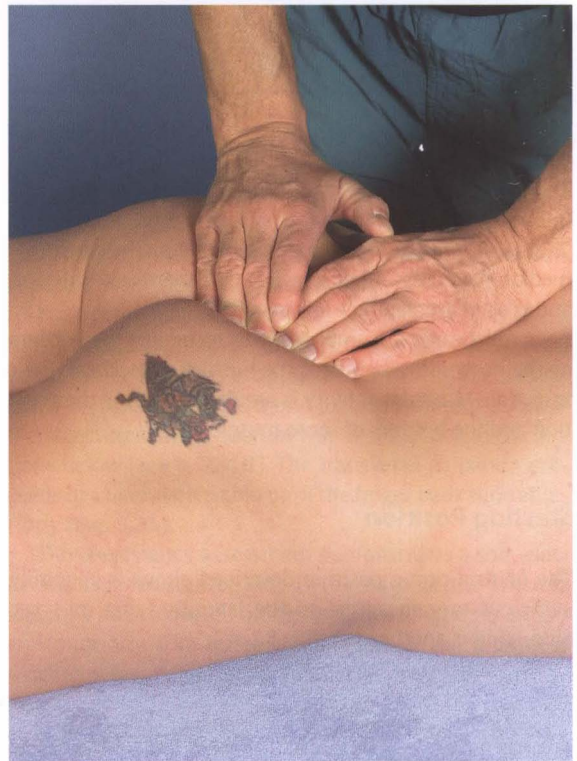


Fig. 9.42 Palpating the gluteus maximus—area of origin when active.

pressure from the inner side of the thigh and stimulates adduction (Fig. 9.40).

The contours of the muscles protrude maximally using this method. The borders of the muscle can be specifically reached from the middle of the muscle belly.

Technique—Area of Origin

The origin (proximal area of attachment) is located using palpation moving in a superomedial direction. The muscle belly leads the palpation mainly onto the sacrum. The muscle's area of origin is often defined as the edge of the sacrum in the literature. However, it becomes noticeable that the therapist almost reaches the middle of the sacrum and not the edge of the bone, as could be expected. This can be explained by looking at the anatomy of the superficial part of the muscle, which does not have a bony insertion. Rather, these parts of the muscle radiate into the thoracolumbar fascia.

Tip: The muscle's dimensions on the surface of the sacrum can be palpated more exactly by alternately relaxing (Fig. 9.41) and tensing (Fig. 9.42) the muscle.

Technique—Area of Insertion

The insertion of the gluteus maximus (distal area of attachment) is located by starting the palpation in the middle of the muscle belly and moving in an inferolateral direction. It is always found inferior to the greater trochanter.

It is also impossible to isolate the point of attachment here—the gluteal tuberosity—using palpation. If the muscle is followed along its length, using slow rhythmical activity if necessary, the palpation ends relatively laterally on the thigh (Fig. 9.43). Again, the superficial sections of the muscles do not demonstrate bony attachments here. Rather, they radiate into the soft tissue. In this case, the soft tissue is the iliotibial tract. Dvořák et al. (2008) refers to these sections as the tibial portion. It is therefore not possible to clearly define the muscle in its inferolateral section.

Technique—Medial Edge

The medial boundary is easy to see and simple to palpate compared with the previously described techniques. Here the muscle forms the post-anal furrow. It covers the ischial tuberosity when the hip is extended.

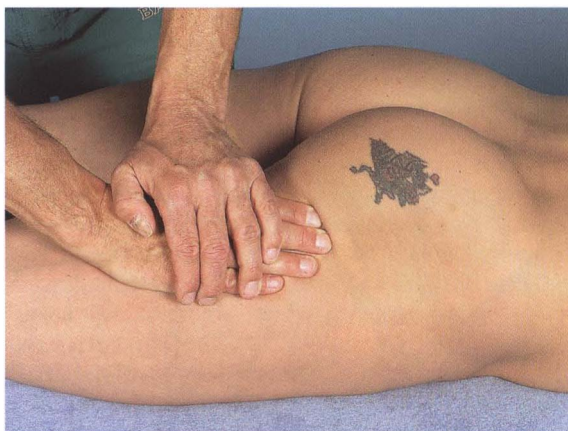

Fig. 9.43 Palpating the gluteus maximus—area of insertion when active.

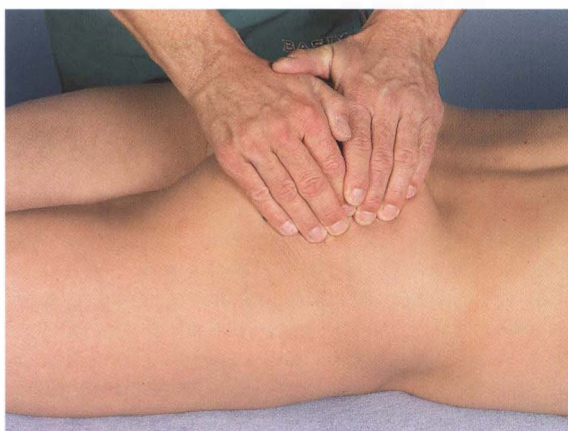

Fig. 9.44 Palpating the gluteus maximus—lateral edge.

Technique—Lateral Edge

It is admittedly very difficult to differentiate between the superolateral sections of the gluteus maximus and the small gluteal muscles. When relaxed, the gluteal region tends to present itself as a uniform, protruding form. Even when the gluteus maximus is tensed, the edge of the muscle is not clearly recognizable. It partially covers the posterior section of the gluteus medius.

It is not possible to differentiate the muscles through contraction with extension or external rotation only, as the posterior sections of the small gluteal muscles perform these actions as well. This leaves the therapist with the only option of working with adduction (the gluteus maximus) or abduction (gluteus medius and minimus).

The muscle is activated using extension and external rotation, and the muscle belly of the gluteus maximus is followed in a superolateral direction until the assumed region of the muscle border is reached (Fig. 9.44). Adduction of the muscle is now additionally stimulated, causing the muscle belly of the gluteus maximus to protrude. Subse-

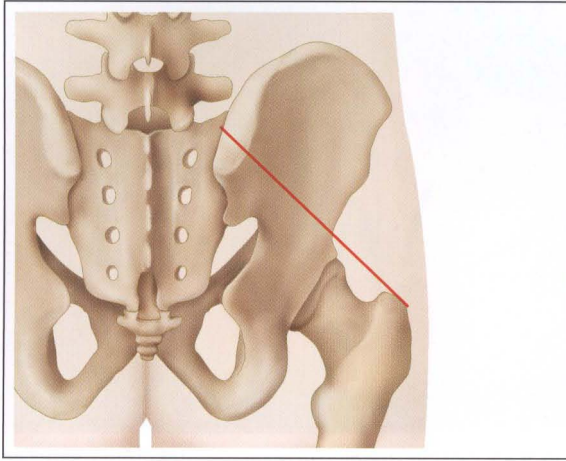


Fig. 9.45 Graphical illustration of the superolateral edge of the gluteus maximus.

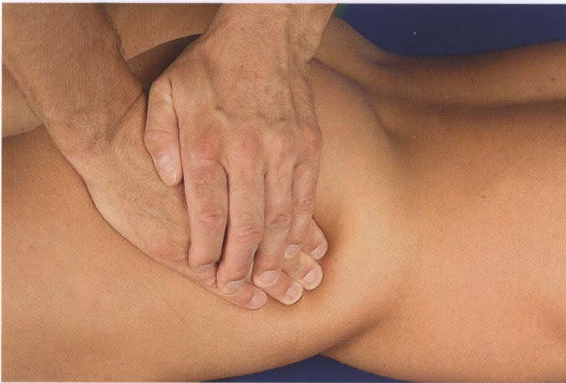

Fig. 9.46 Palpating the gluteus medius.

quently, abduction is conducted to emphasize the small gluteal muscles.

Tip: The recommendations of Winkel (2004) are to be followed should the attempt to locate the superolateral edge of the muscle fail. Based on his experience, this edge is located along the line connecting the PSIS with the tip of the trochanter (**Fig. 9.45**).

Gluteus Medius

The muscle belly attaches itself directly onto the superolateral edge of the gluteus maximus muscle belly. An attempt to differentiate between these muscles using muscle activity has already been described. The gluteus minimus is completely covered by the gluteus medius. It is therefore not possible to differentiate between these two muscles using palpation.

Technique

The palpating hand (when necessary with the second hand applying pressure to it) is placed on the side of the pelvis between the iliac crest and the tip of the trochanter. Pressure is applied deep into the tissue. The finger pads feel the expected soft consistency of the tissue (**Fig. 9.46**). The position of the gluteus medius only becomes evident when it is activated with abduction. The patient does not have to expend a lot of effort for this. Normally only slight activity is sufficient.

This technique enables the therapist to easily palpate the entire length of the muscle between its origin (iliac crest) and its insertion (greater trochanter). Only the palpatory border anterolateral to the tensor fasciae latae and medial to the gluteus maximus is more difficult in this SP.

Tip: When trying to differentiate between the gluteus maximus and the gluteus medius, the therapist can also attempt to reciprocally inhibit the gluteus maximus. The patient pushes their knee down into the treatment table (hip flexion) or lets the heel fall out to the side (internal rotation). The gluteus medius can be selectively observed by subsequently instructing the patient to abduct the hip.

Iliotibial Tract

This long and collagen-intensive reinforcement of the fascia in the thigh runs an interesting course (**Fig. 9.47**):

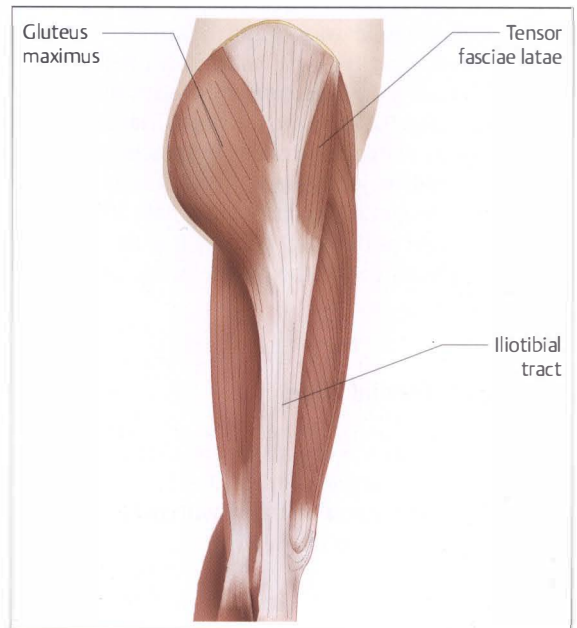


Fig. 9.47 Position of the iliotibial tract.

- The proximal point of attachment is at the most superior part of the iliac crest.
- It passes lateral over the pelvis and the small gluteal muscles;
- over the greater trochanter, along the side of the thigh;
- lateral over the knee joint space, mainly inserting into the Gerdy tubercle (or the lateral condyle of the tibia).

The tract is placed under tension when:

- Muscle activity radiates from the superficial layer of the gluteus maximus.
- Muscle activity radiates from the tensor fasciae latae.
- The muscle belly of the gluteus medius protrudes during activity.
- The muscle belly of the vastus lateralis protrudes during activity (the most effective form of tension, according to personal correspondence from Vleeming).

Technique

During the palpation of the muscle belly of the gluteus medius (as in **Fig. 9.46**) from medial to lateral using transverse frictions, the palpating hand encounters an area of firm consistency. The difference is especially apparent in athletes. When the entire area of firm consistency is palpated, the therapist palpates a structure that is two to three fingers wide between the trochanter and the iliac crest.

Tip: It is impossible to successfully differentiate using muscle activity because it is the difference between soft and firm consistencies that make the position of the tract distinct. Muscle activity removes the soft consistency during palpation.

Local Palpation Techniques

Overview of the Structures to be Palpated

- Ilium—iliac crest.
- Ilium—posterior superior iliac spine (PSIS).
- Sacrum—S2 spinosus process.
- Sacrum—median sacral crest.
- Sacrum—insertion of the multifidus.
- Sacrum—sacral hiatus.
- Sacrum—sacrococcygeal transition.
- Sacrum—inferolateral angles of the sacrum.
- Sacrotuberous ligament.
- Long posterior SI ligament.

Summary of the Palpatory Procedure

The iliac crest is a common point used for orientation when the pelvis is being palpated. Starting from here, therapists orient themselves when ascertaining the level of structures in the lumbar area, start searching for the

PSIS, and compare sides to ascertain whether the left- and right-hand sides are found at differing heights and whether a pelvic obliquity is present.

The PSIS belongs to the most frequently located structures in the pelvis. Accurate palpation of the PSIS is the basic prerequisite to ensure that relevant information is correctly gained. This palpation is used in the upright posture when diagnosing the level of disorders. As part of the SI joint diagnostics, the PSISs must be accurately located and palpated during movement to assess the standing flexion test. Additional precise palpation of the sacrum also starts at the PSIS.

The localization of both PSISs is the first step to reliably differentiate between the sacral and lumbar spinous processes.

All other accessible sections of the sacrum will be palpated during later sections of the palpatory procedure. Muscular activity in the multifidus and the localization of important pelvic ligaments follow. Finally, several lines will be drawn on the pelvis to clarify the position of other muscular and neural structures.

Starting Position

The patient lies in a neutral prone position on the treatment table, with a face hole. The sections of the body are positioned without lateral shift or rotation. The arms are lying next to the body. Elevation of the arms to the level of the head should be avoided as this tenses the thoracolumbar fascia and impedes palpation of different structures in the area of the lumbosacral junction. If possible, the head is not positioned in rotation. The therapist stands to the side of the treatment table opposite the side to be palpated. Please see the section “Starting Position,” Chapter 8, page 186 for further details.

Ilium—Iliac Crest

The iliac crest has already been located during the quick orientation. It is now necessary to accurately palpate its superior border.

Technique

The palpation changes to a perpendicular palpation once the iliac crest has been found. The hand is positioned here superior to the iliac crest and the finger pads push down against the iliac crest at a right angle (**Fig. 9.48**).

Tip: As a reminder: the most superior border of the iliac crest is at approximately the level of L3/L4.

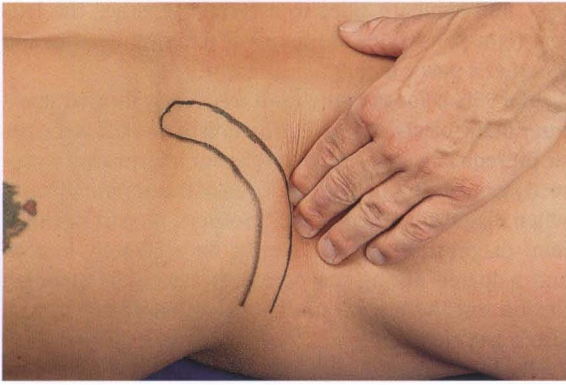


Fig. 9.48 Local palpation of the iliac crest.

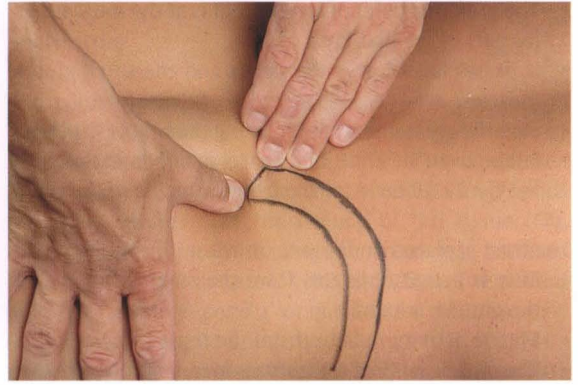


Fig. 9.50 Locating the PSIS—variation 1: final position.

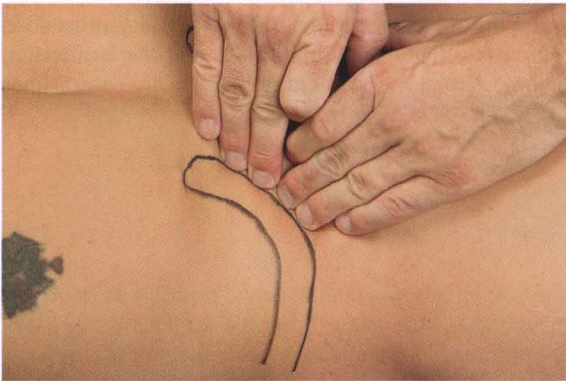


Fig. 9.49 Locating the PSIS—variation 1: SP.

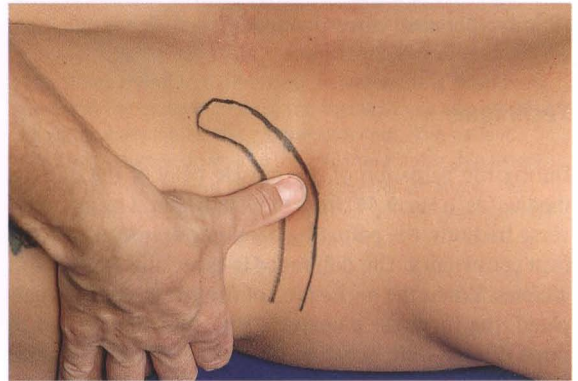


Fig. 9.51 Locating the PSIS—variation 2: SP.

Ilium—Posterior Superior Iliac Spine

The significance of the PSIS has already been emphasized in the summary of the palpatory procedure. The PSIS's exact layout can be determined using two different techniques. One common misconception should be discussed first. Therapists often connect the PSIS to the localization of the “dimples,” the indentations in the skin over the posterior pelvis. This is definitely not correct. The PSISs are not found at the level of these dimples; they are found on average approximately 2 cm inferior and lateral to these indentations. The much-cited “dimples” are found where the gluteal and lumbar fasciae connect with deeper layers.

Technique—Variation 1

The perpendicular technique is used again when locating the iliac crest (as described above). The iliac crest is palpated centimeter by centimeter in a medial direction (Fig. 9.49). The palpation increasingly turns in an inferior direction to reach and, when necessary, mark that most inferiorly located section of the PSIS (Fig. 9.50).

Tip: This technique is very exact, but can only be used on rather slender people.

Technique—Variation 2

A transverse palpation of the iliac crest is conducted. The thumb moves with a sweeping, low-pressure, transverse movement from inferior to superior across the crest (Figs. 9.51 and 9.52), where the therapist expects to feel a round structure.

This palpation gradually moves in a medial and inferior direction (Figs. 9.53 and 9.54).

Finally, the therapist should focus on the point where the structures no longer feel rounded, but instead feel flat and slanted (Figs. 9.55 and 9.56). At this point the fingers are no longer on the iliac crest, but are already located over the lateral edge of the sacrum. The transitional area between the iliac crest and sacrum should be visualized again:

- Slightly further superior: rounded palpation of the iliac crest.
- Slightly further inferior: flattened slant of the edge of the sacrum.

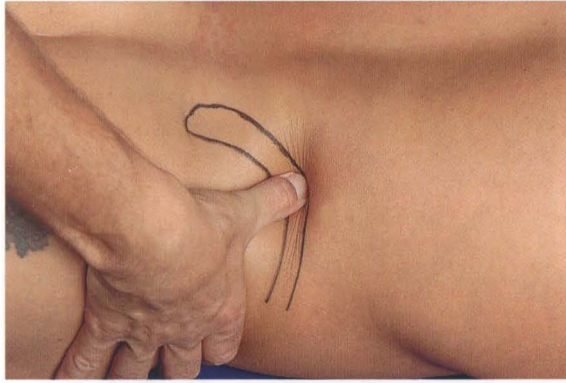


Fig. 9.52 Locating the PSIS—variation 2: final position.

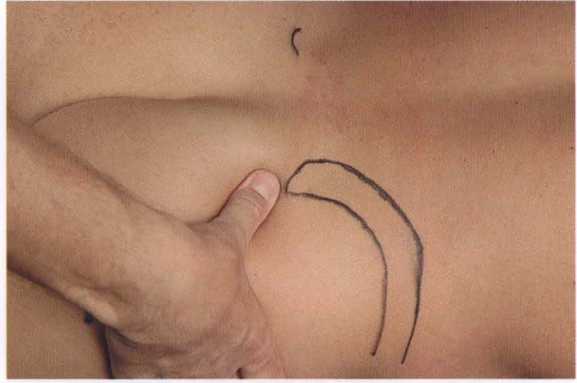


Fig. 9.55 Locating the PSIS—variation 2: SP; edge of the sacrum.

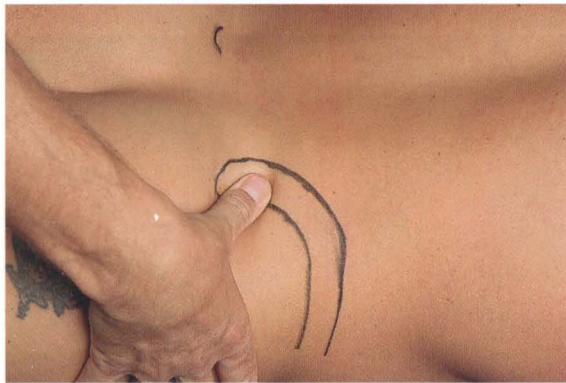


Fig. 9.53 Locating the PSIS—variation 2: SP; further medial and inferior.

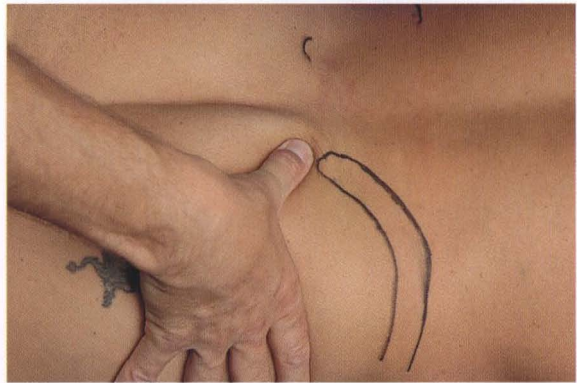

Fig. 9.56 Locating the PSIS—variation 2: final position; edge of the sacrum.

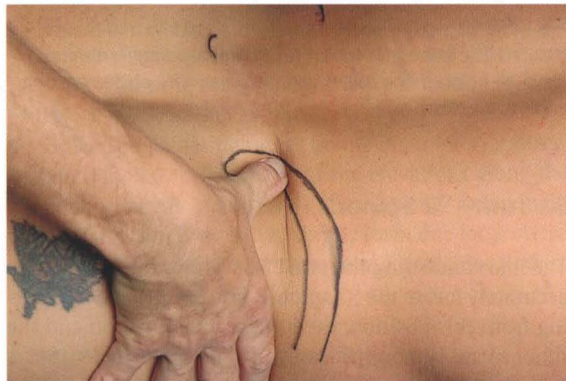

Fig. 9.54 Locating the PSIS—variation 2: final position; further medial and inferior.

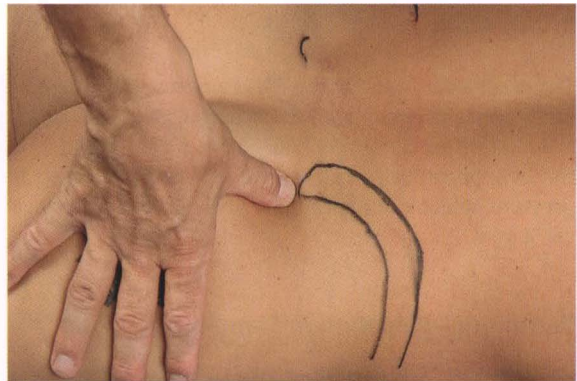


Fig. 9.57 Locating the PSIS—variation 2: inferior edge of the PSIS.

The thumb is now positioned over the edge of the sacrum, points in a superior direction, and hooks around the iliac crest. This technique is used to mark the inferior edge of the PSIS (Fig. 9.57).

Tip: In this technique it is especially important to carry out a rather large movement with the thumb. The iliac crest is a very wide structure that requires a wide movement to feel its rounded contour.

Accurate localization of the PSIS is the crucial palpatory technique on the posterior pelvis. If you are unable to clearly identify it, all further attempts to clearly define structures are bound to fail.

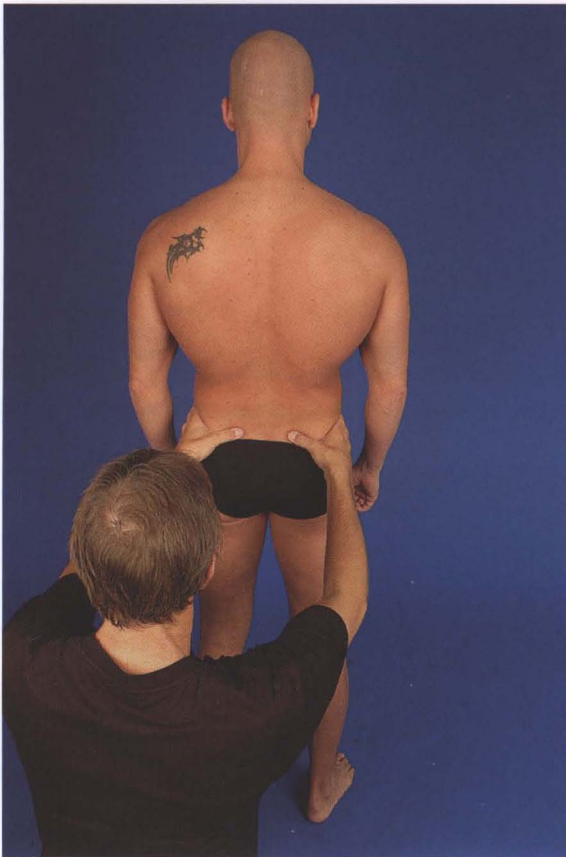


Fig. 9.58 Palpating the PSIS in standing.

Information on Pathology

The exact localization of the PSIS can cause patients pain under certain circumstances, especially when locating the inferior aspect of the PSIS. This is most likely due to the long posterior sacropiliac ligament being sensitive to pressure, which can indicate the presence of a pathological SI joint.

Technique—Palpation in Standing

Localizing the PSIS in the standing position is much more difficult than in the prone position. The increased tension in the gluteal and multifidus muscles makes distinct palpation cumbersome. The thumb must palpate with more pressure to feel the bony shapes and determine the differences in consistency between tense soft tissues and bones (Fig. 9.58).

Tips: Palpation can first be conducted on one side in difficult cases using technique variation 2 and a lot of pressure. To do this, the therapist stands more to the side of the patient and stabilizes the pelvis anteriorly.

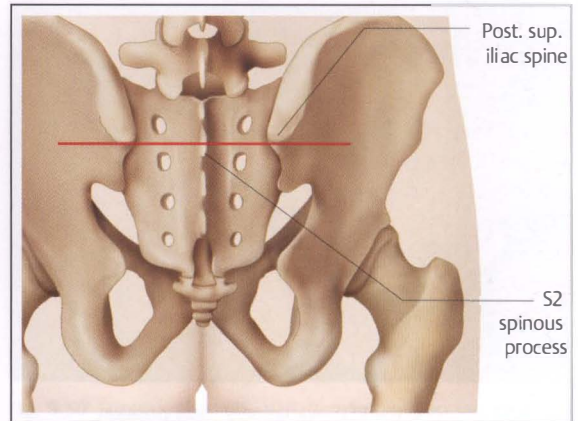


Fig. 9.59 Level allocation: both PSISs—S2 spinous process.

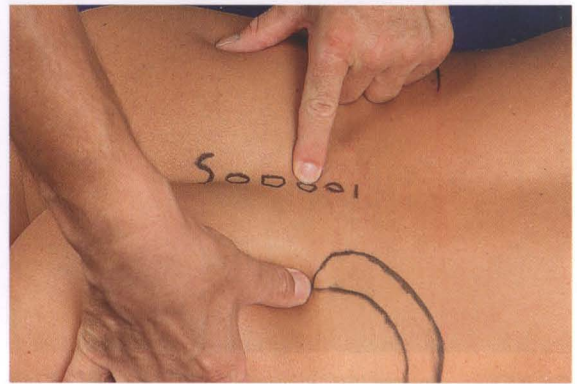


Fig. 9.60 Locating S2

In other cases, flexion of the vertebral column and the associated iliac bone movement (as in the standing flexion test) can be helpful. The spines can become more obvious during this movement.

Sacrum—S2 Spinous Process

The line connecting the two PSISs allows the therapist to accurately locate the S2 spinous process (Fig. 9.59). Starting from this position, the lumbosacral junction and the other sacral spinous processes can be correctly located.

Technique

To correctly depict these structures, both PSISs are first located using the thumbs. The spinous process of S2 is located at the middle of the line connecting the PSISs. It is quite large and can usually be clearly palpated as a roughened area over the sacrum (Fig. 9.60).

Sacrum—Median Sacral Crest

Three different ridges are located on the posterior side of the sacrum and represent the rudiments of the sacral spinous and articular processes. Most of the posterior aspect of the sacrum is so densely covered with ligamentous structures that only the median sacral crest can be palpated with certainty. The spinous process has been reduced to the level of a tubercle. Considerable variation is found in its shape:

- The shape of the S1 spinous process varies greatly between individuals. It can be felt as an obvious or slight elevation superior to S2, or may be completely absent. The S1 spinous process is still going to play an important role for palpation later on. First, the SI joint extends superiorly to a limited extent; second, palpation of the lumbar spine starts here.
- The S5 spinous process is always absent. The laminae of the original S5 vertebra are not closed and therefore do not unite posteriorly to form a structure resembling the spinous process.

Technique

The location of the S2 spinous process can be accurately found by connecting both PSISs (see above). Subsequent palpation is performed using small circular movements, preferably with the pad of the index or middle finger, moving directly superior and inferior away from the S2:

- S1: the palpating finger points in a superior direction (Fig. 9.61). If the S1 spinous process is palpable, the neighboring superior structure will be the L5 spinous process (see the section “Local Bony Palpation,” Chapter 10, p. 260).
- S3, S4: the palpating finger points in an inferior direction (Fig. 9.62). The shape of the elevations along the median sacral crest also varies among individuals. One variation is that they simply form one large structure. The level of S5 can then be accurately located.

Sacrum—Insertion of the Multifidus

The fibers of the lumbar multifidus are evident on the posterior surface of the sacrum directly next to the mid-line. Its collagen fibers merge with the rear ligaments, for example, with the long posterior sacroiliac ligament.

The action of the multifidus is similar to a hydrodynamic reinforcement of the thoracolumbar fascia. The multifidus swells up during contraction and tightens the fascia from the inside outward, like a bicycle tire becoming more taut when the inner tube is pumped up.

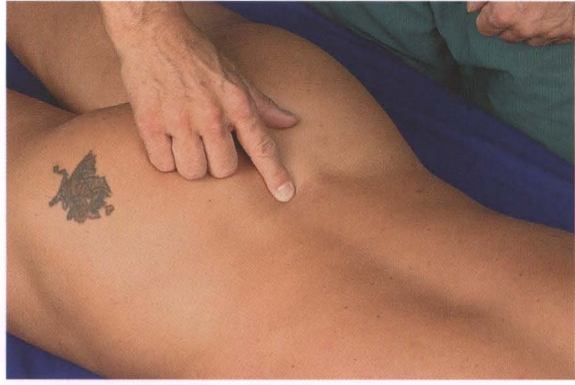

Fig. 9.61 Locating S1

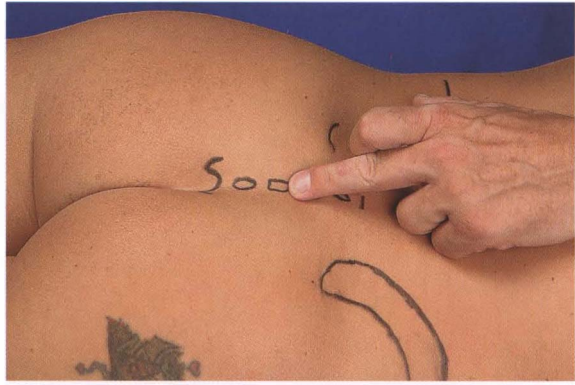


Fig. 9.62 Locating S3

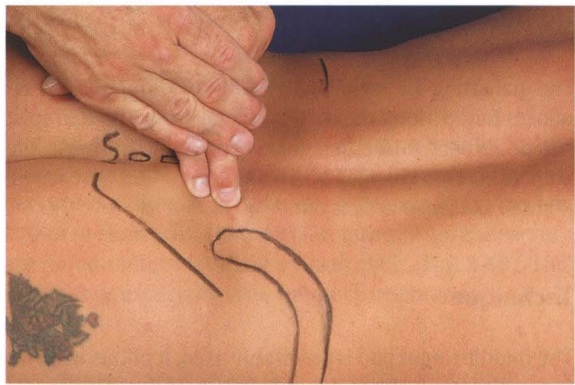


Fig. 9.63 Palpating the multifidus when active.

Technique

Several palpating finger pads are placed directly next to the mid-line over the sacral surface. The patient slightly increases their lordosis (Fig. 9.63). The consistency of the tissue to be palpated becomes distinctly firmer when it is activated.

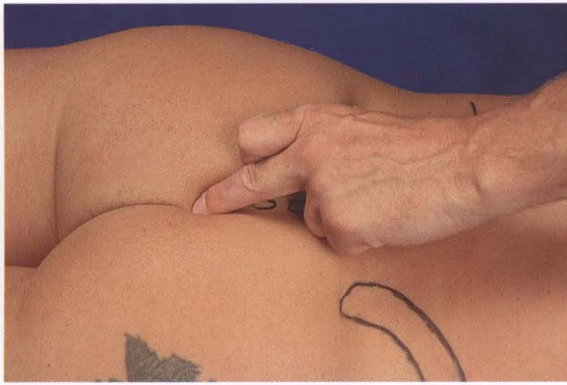

Fig. 9.64 Palpating the sacral hiatus.

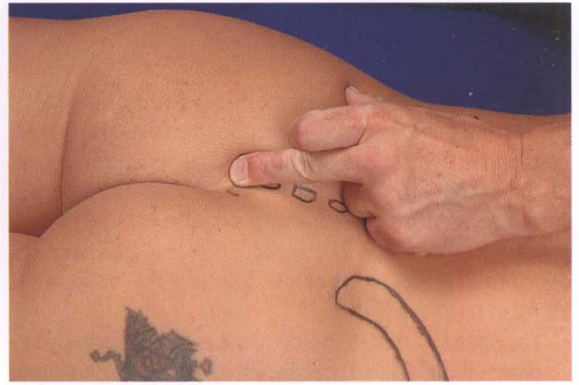

Fig. 9.66 Locating a sacral horn.

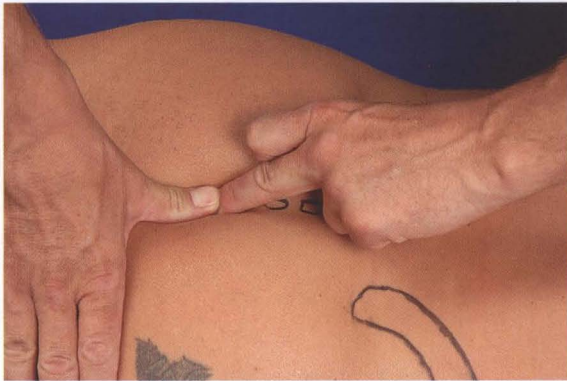

Fig. 9.65 Applying pressure to the membrane.

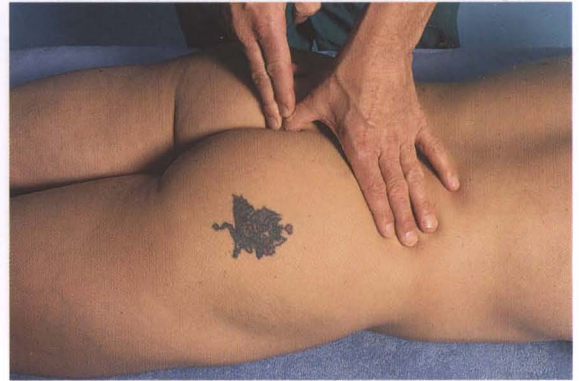

Fig. 9.67 Assessing the consistency at S4.

Sacrum—Sacral Hiatus

The palpating finger searches for the different prominences found along the median sacral crest. The therapist should expect to feel irregular prominences during the palpation. This changes when the level of S5 is reached. A small flattened area is felt.

Technique

The middle finger pad is preferably used. It points in an inferior direction, slides down from S4, and moves onto a small, flattened plateau (Fig. 9.64). The sacral hiatus and its covering membrane, representing the level of S5, are felt here.

Tip: There are two different methods available to confirm the correct localization:

- Pressure is applied in an anterior direction. The covering membrane is being palpated when the tissue yields elastically and no hard bony resistance is felt (Fig. 9.65).
- The finger pads collide with protruding bone when they are moved to the left and right. More circular palpation demonstrates that these elevated structures are osseous processes (Fig. 9.66). These are the sacral horns, the rudiments of the S5 vertebral arch laminae. Their shape and

size varies between individuals. A difference between left and right may even be seen in the same patient. It is not possible to detect the inferior sacral borders precisely as the sacral horns also face the protrusions in the coccyx bone. The horns will be searched for again during the further course of precise palpation of the pelvis.

Sacrum—Sacrococcygeal Transition

The apex of the sacrum and its mobile articulation with the coccyx is found directly inferior to the hiatus.

Technique

The fingers are placed at a steep angle to the sacral hiatus and the finger pads palpate. The fingers slide inferiorly into a transverse groove directly inferior to the hiatus. This is where the sacrum connects to the coccyx.

The sacrum and the coccyx are further differentiated from one another by assessing consistency. The resistance is quite firm when direct pressure is applied to the sacrum (safest at the S4 level) (Fig. 9.67). Inferior to the joint, the coccyx reacts to pressure with more elasticity (Fig. 9.68).

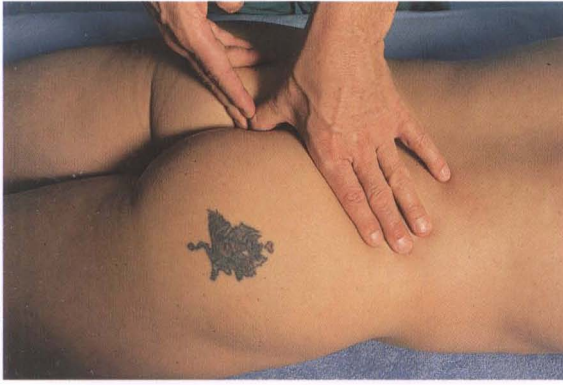


Fig. 9.68 Assessing the consistency of the coccyx.

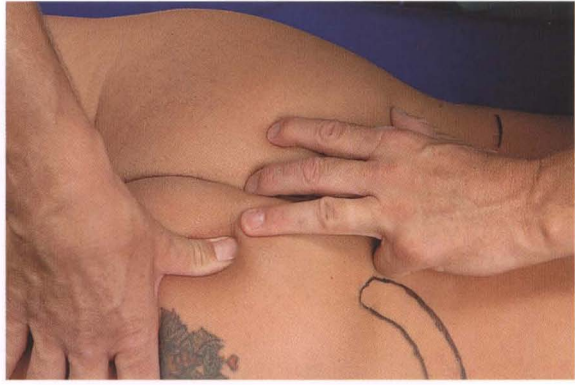

Fig. 9.70 Locating the inferolateral angle of the sacrum—variation 2.

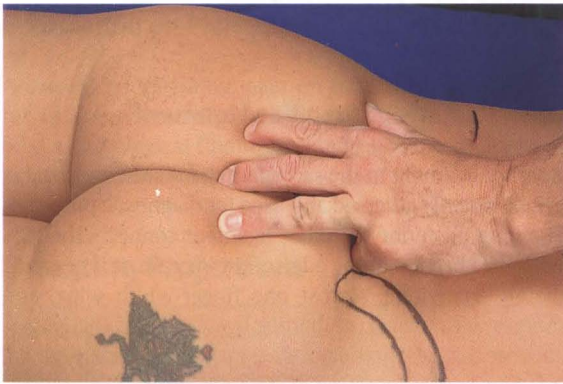

Fig. 9.69 Locating the inferolateral angle of the sacrum—variation 1.

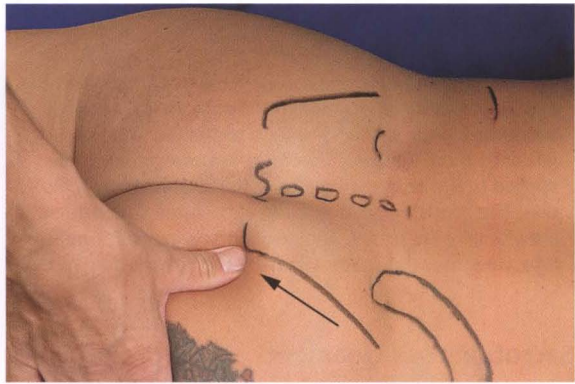


Fig. 9.71 Locating the inferolateral angle of the sacrum—variation 3.

Information on Pathology

People who have fallen and compressed their coccyx may still experience pain when they are palpated here. This is due to an overstretching of the ligamentous connections that stabilize the joint. These ligaments (lateral sacrococcygeal ligaments) originate from the posterior aspect of the sacral horns. Local transverse frictions at the origin are used as treatment to relieve pain.

Sacrum—Inferolateral Angles of the Sacrum

The inferolateral angles of the sacrum are found at the level of the sacral horns. The distance between these two angles demonstrates how wide the inferior part of the sacrum is. It is apparent that the sacrum is not triangular, but is shaped more like a trapezoid. The inferolateral angles of the sacrum can be reached using three different techniques.

Technique—Variation 1

The pad of the middle finger is used to palpate the membrane covering the sacral hiatus again. Index and ring fingers are slightly spread out to the side and rest on the surface of the buttocks. The inferolateral angles of the sacrum are found underneath these finger pads (**Fig. 9.69**). This variation is especially used for quick orientation.

Technique—Variation 2

The inferior edge of the sacrum is palpated by moving laterally from the sacral apex. The inferolateral angle is situated at the point where the palpating finger changes direction and palpates more superolaterally (**Fig. 9.70**).

Technique—Variation 3

This technique is used for quick orientation at the sacrum to detect the edges of the sacrum. The finger pads or the medial edge of the hand are used for this technique, palpating along the edge of the sacrum in an inferior direc-

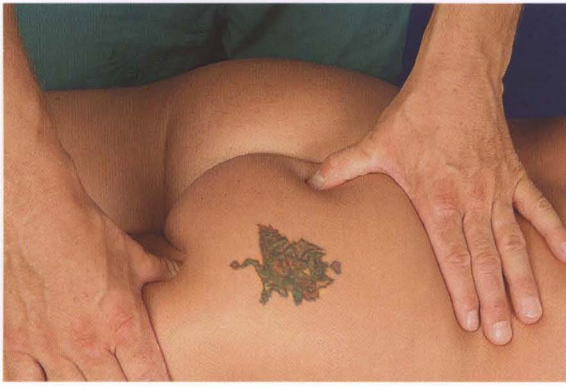

Fig. 9.72 Sacrotuberous ligament—locating the fixed points.

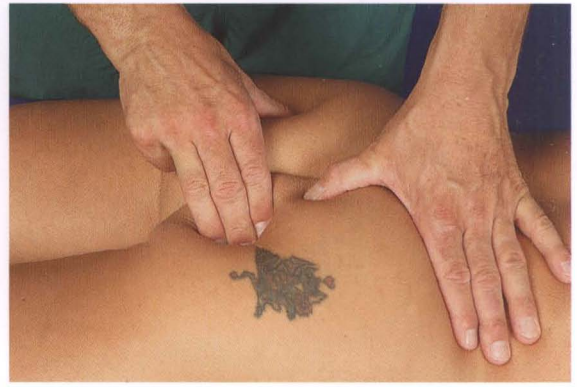

Fig. 9.73 Sacrotuberous ligament—direct palpation.

tion until the edge of the sacrum clearly turns in a medial direction (Fig. 9.71).

Tip: The presence of strong collagenous structures makes the precise palpatory localization of the inferolateral angle, as conducted in the second and third technique variations, significantly more difficult. Therefore, firm pressure must be applied to the respective edges of the sacrum during palpation. The consistency assessment of palpated structures is likewise very important. The neighboring ligaments are very firm, yet somewhat elastic, when directly pressed down upon.

Sacrotuberous Ligament

One of the most strongly collagenous structures in the musculoskeletal system connects each edge of the sacrum—especially at the level of the inferolateral angle—with the corresponding ischial tuberosity: the sacrotuberous ligament.

Technique

The two important bony structures, the inferolateral angle of the sacrum and the ischial tuberosity, have already been found (Fig. 9.72). The ligament is almost as wide as a thumb and is located between these two bony reference points. Transverse palpation with the thumb or pressure from the index finger is used to palpate. The ligament is very firm, but nevertheless elastic when directly palpated (Fig. 9.73).

Information on Pathology

As this ligament belongs to one of the most important nutation restrictors, it is not fully tightened in the supine position and yields somewhat elastically when direct pressure is applied to it. Several manual therapeutic study groups interpret the tension in the ligament by comparing sides. Different levels of tension cause different levels of

elasticity when pressure is applied and indicate the presence of a pathological SI joint.

Long Posterior Sacroiliac Ligament

Another ligament in the sacroiliac ligamentous apparatus can be directly accessed and used for diagnostic purposes. The long posterior sacroiliac ligament connects the PSIS with the corresponding edge of the sacrum. It is approximately 3 cm long, almost one finger-width wide, and merges with the sacrotuberous ligament. It is the only ligament that restricts counternutation. As already stated, it is one area of insertion of the multifidus.

Technique

The ligament can be reached using transverse palpation directly inferior to the PSIS and is felt as a rounded structure (Figs. 9.74 and 9.75). The further course of the ligament (after approximately 2 cm) as it heads toward the edge of the sacrum can only be palpated vaguely.

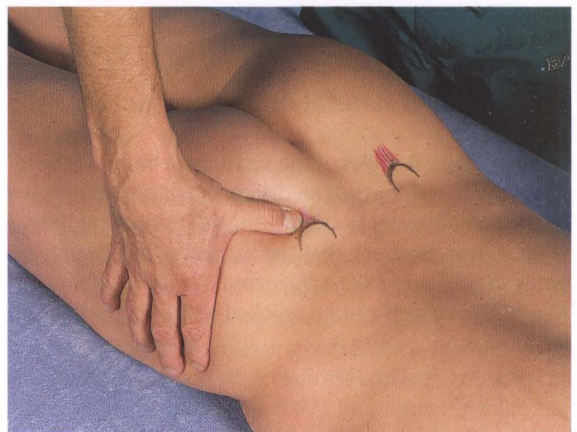


Fig. 9.74 Long posterior sacroiliac ligament, SP.

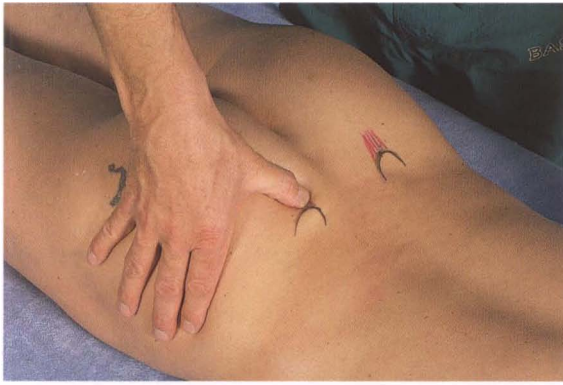

Fig. 9.75 Long posterior sacroiliac ligament, final position.

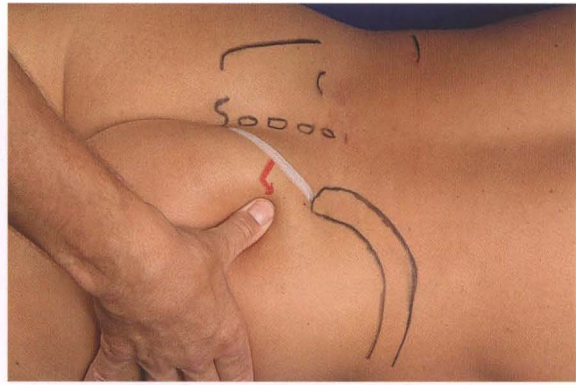


Fig. 9.76 Palpating the PIIS.

Information on Pathology

According to Vleeming, pain on transverse palpation of the ligament immediately inferior to the PSIS is considered a pathological finding and indicates the presence of a pathological SI joint.

Orienting Projections

Overview of the Structures to be Palpated

- Posterior inferior iliac spine (PIIS).
- Sacroiliac (SI) joint projection.
- Piriformis.
- Sciatic nerve and the gluteals.

Several structures in the posterior pelvis cannot be palpated at all or can only be palpated using aids. Therefore therapists need to project structures onto the surface of the skin and mark guiding lines to orient themselves. First a guiding line is marked between a PSIS and a sacral horn. This is the foundation for all further projections and palpations.

Posterior Inferior Iliac Spine

The connecting line is halved by a 2-cm-long line that is marked at a right-angle. The end of this second line is the starting point for the local palpation of the PIIS.

Technique

A thumb is placed on this point and pushes anteriorly with ample pressure. The other thumb can be used for support when necessary. The thumb tries to move in a superior direction. Hard bony resistance is felt. The therapist now

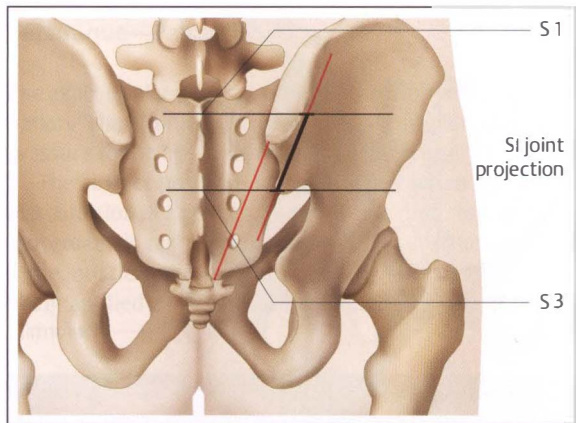


Fig. 9.77 Position of the SI joint, posterior aspect.

hooks around the PIIS, coming from an inferior direction (Fig. 9.76).

The PIIS is always found at the level of the S3 spinous process and represents the inferior border of the SI joint. The joint surface is only approximately 1 cm away from the palpation at this point, which can be better understood when viewing an anatomical specimen.

Tip: This technique can be somewhat unpleasant for patients as the palpation must be conducted using firm pressure. This is mostly tolerated as it is impossible to endanger truly sensitive structures, for example, vessels or nerves.

Sacroiliac Joint Projection

It is now possible to transfer the exact position of the joint onto the surface of the skin to better visualize the joint's spatial dimensions and size.

The posterior projection of the joint space is found approximately 2 cm lateral and parallel to the line connecting the PSIS and the sacral horn (Fig. 9.77).

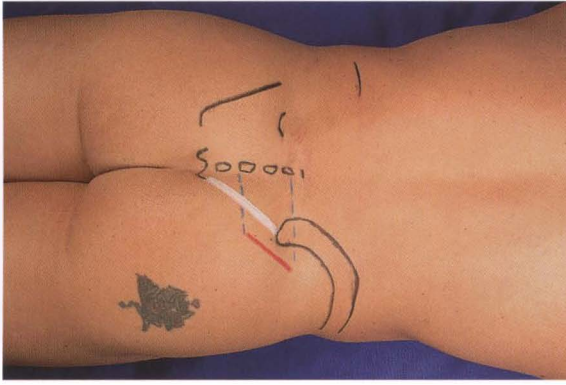


Fig. 9.78 Projecting the SI joint onto the skin.

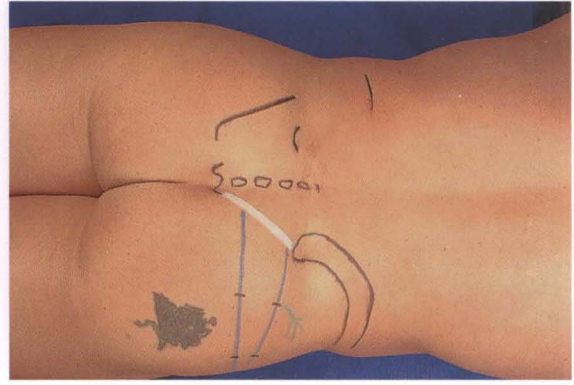


Fig. 9.80 Projection of the piriformis—muscle belly.

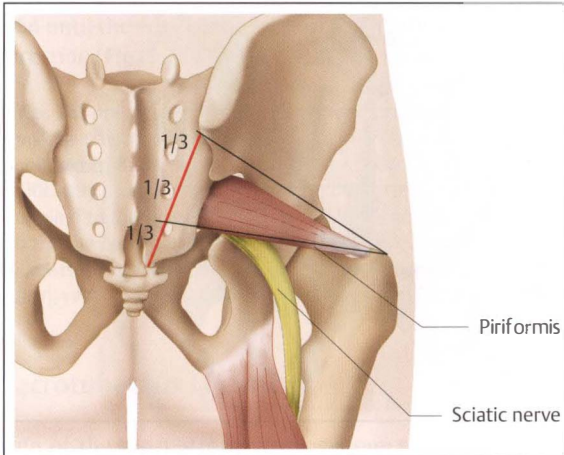


Fig. 9.79 Position of the piriformis.

Technique—Projection

- A connecting line is marked again if necessary.
- The PIIS is found and the S3 spinous process located in the sacral mid-line.
- The S1 spinous process is identified using palpation. The level of the S2 spinous process can also be confirmed, if necessary, by connecting the two PSISs.
- A line is marked parallel and approximately 2 cm lateral to the connecting line.
- The positions of S3 and S1 are transferred onto this parallel line.

This results in the SI joint's position, alignment, and superior/inferior level being projected onto the posterior surface of the body (Fig. 9.78). It is now evident that the edge of the sacrum can only be palpated between the inferolateral angles at the level of S5 and the PIIS (at the level of S3). The SI joint is found superior to this and makes direct palpation impossible.

Piriformis

This muscle is said to be of significant importance in various pathological conditions. The assessment of its consistency has a type of monitoring function. Its localization can therefore be important in the assessment or, in some cases, the treatment of symptoms in the LPH region.

The muscle is located in two steps. Its position is first projected onto the surface of the skin, followed by the palpatory assessment of consistency (Fig. 9.79).

Technique—Projection

- The muscle's position is clarified by first drawing a line between the PSIS and the sacral horn. This line is now cut into thirds.
- The superior tip of the greater trochanter is needed as a further bony reference point. Its localization has already been described (see the section "Greater Trochanter" above, p. 215).
- A line is drawn from the inferior aspect of the PSIS to the tip of the trochanter. This line represents the superior border of the piriformis.
- A line is drawn between the tip of the trochanter and the point between the middle third and the superior third of the divided connecting line. This line illustrates the inferior border of the piriformis.
- The result is a slender triangle with its base positioned medially and the tip laterally (Fig. 9.80).

Technique—Palpation

After the location of the piriformis has been projected onto the skin, the muscle belly can be directly palpated. Two to three fingers push down onto the center of the triangle. The finger pads are used for palpation and firm pressure is applied. The therapist is looking for a rounded structure. This structure's consistency is somewhat firmer than its direct surroundings.

Tip: The edge of the sacrum is located approximately 2–3 cm lateral to the line connecting the PSIS and the sacral horn. The approximately 4 cm-long muscle belly is searched for directly lateral to this. This mostly corresponds to the center of the triangle. The muscle turns into an inserting tendon further laterally, which cannot be palpated.

Information on Pathology

This muscle is frequently pathologically dense and tender to pressure when lumbar, SI joint, or hip and thigh symptoms are present.

A piriformis syndrome is referred to when a permanent increase in muscle tension irritates the sciatic nerve. This diagnosis is apparently supported when trigger points are discovered in this muscle.

Mercer et al. (2004), in their literature review, investigated a multitude of differing recommendations dealing with the palpation of these sensitive points in the muscle. They furthermore examined the position and shape of the piriformis on 10 bodies in a study, applying the palpatory procedures recommended in literature to locate the piriformis. Only two methods were found to be reliable. They looked at the inferior edge of the muscle belly in relation to the tip of the coccyx and found that this distance varied by up to 2 cm.

Sciatic Nerve and the Gluteals

The position and the further pathway of the thickest of all peripheral nerves (sciatic nerve) (Fig. 9.81) can likewise be accurately projected onto the surface of the skin. Direct palpation leads the palpating finger onto the nerve, which cannot be felt as such. It is too relaxed in the supine position and lies slightly corrugated in the tissue. This results in the nerve yielding somewhat to direct palpation, and it cannot be identified as an independent structure. The nerve can normally cope well with direct and firm pres-

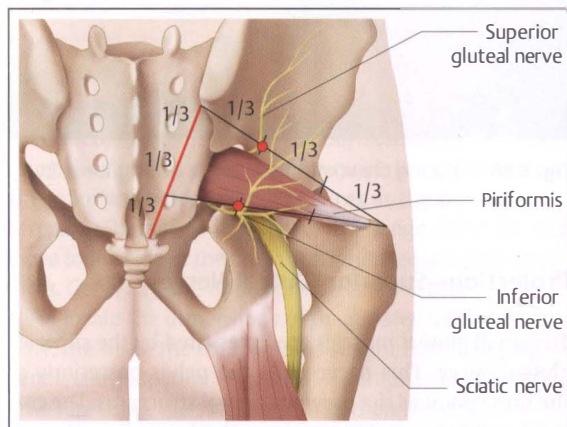


Fig. 9.81 Position of important nerves in the gluteal region.

sure. Palpation is painful only when a true neuritis is present.

Projection—Exit Point Out of the Pelvis

The sciatic nerve passes underneath the piriformis for several centimeters and emerges at a point that can be very well described using the lines already present. The connecting line demonstrating the inferior boundary of the piriformis is divided into three. The nerve emerges from underneath the muscle at the intersection between the medial and medial third, exiting the pelvis posteriorly (Fig. 9.82).

Technique—Palpation

The exact localization can be reliably confirmed using palpation. The thumb or another finger applies moderate pressure to the tissue in an anterior direction.

The correct position has been found when the therapist additionally pushes in a superior direction and the movement is restricted by a firm, elastic structure. This is the muscle belly of the piriformis. While pressure is still being applied in an anterior direction, additional move-

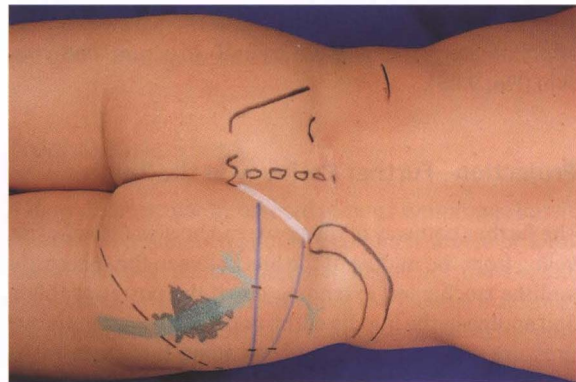


Fig. 9.82 Projection of the sciatic nerve as it exits the pelvis.

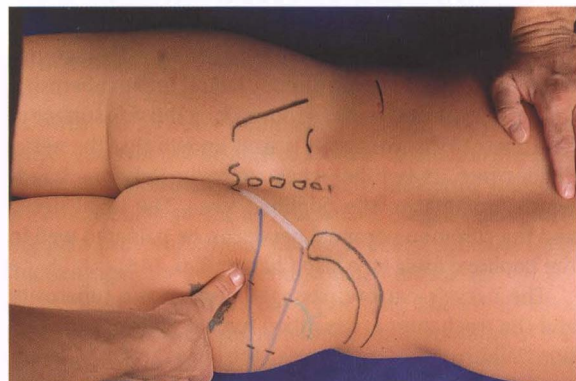


Fig. 9.83 Palpating the sciatic nerve at its exit point.

ment in a medial direction results in the palpating finger pushing against the hard edge of the sacrum (Fig. 9.83).

This confirmed palpation marks the infrapiriform foramen. This is where the inferior gluteal nerve—the motor supply for the gluteus maximus—also travels to the surface. The posterior femoral cutaneous nerve is another neural structure that passes through this foramen. A portion of its rami are found posterior to the ischial tuberosity, and some are found inferior to the ischial tuberosity as they travel in a medial direction.

Projection—Further Pathway in the Pelvis

The sciatic nerve's further pathway along the posterior pelvis can be determined using two more bony reference points (Fig. 9.84). Local palpation confirms the nerve's pathway projected onto the skin for orientation.

The required reference points have already been found:

- Ischial tuberosity.
- Greater trochanter.

Another line is marked between the tip of the ischial tuberosity and the tip of the greater trochanter and cut in half.

The middle of this line is connected to the previously found exit point for the sciatic nerve under the piriformis. This enables the therapist to project the pathway of this approximately thumb-wide neural structure onto the skin (Fig. 9.85).

Projection—Further Pathway in the Thigh

The further pathway of the nerve can be visualized as traveling from the middle of the line between the tuberosity and the trochanter, extending down the posterior thigh, and ending in the middle of the popliteal fossa. Significant pressure can be applied halfway along the above-mentioned line. The deeper tissues are simultaneously penetrated and pressure is applied directly onto the nerve. The finger is then pushed in a medial direction and immediately feels the bone of the ischial tuberosity (Fig. 9.86). The pathway of the sciatic nerve can be seen on anatomical specimens as running directly lateral to the tuberosity.

The nerve even forms a groove along the side surface of the tuberosity as we age. It is well-known that the nerve divides into its two branches approximately one hand-width proximal to the popliteal fossa. The tibial nerve and the common peroneal nerve can be palpated well in the popliteal fossa (see also Chapter 6, p. 145).

The nerve's narrow passage between the tuberosity and the trochanter is described further below in the section "Width of the Gap between the Pelvis and the Greater Trochanter," page 235.

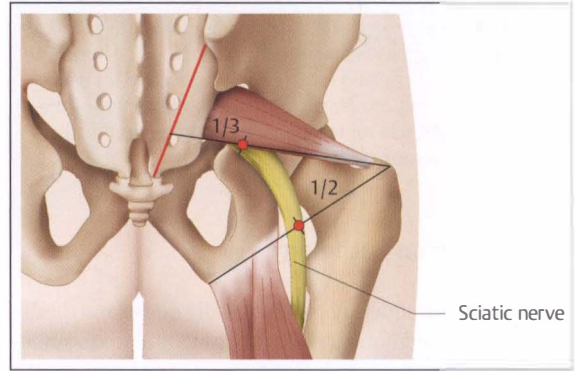


Fig. 9.84 Pathway of the sciatic nerve in the pelvis.

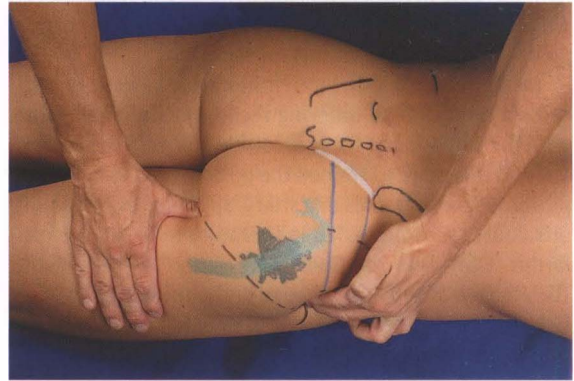


Fig. 9.85 Projection of the sciatic nerve pathway.

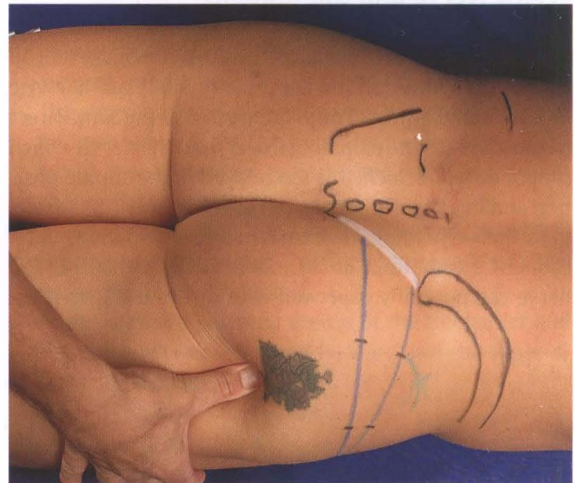


Fig. 9.86 Palpating the sciatic nerve at the ischial tuberosity.

Projection—Superior Gluteal Nerve

The small gluteal muscles are innervated by the superior gluteal nerve. This nerve exits the pelvis posteriorly at the same point as the previous neural structures. The correct localization of this nerve can also be confirmed using the same method for palpation (Fig. 9.87).

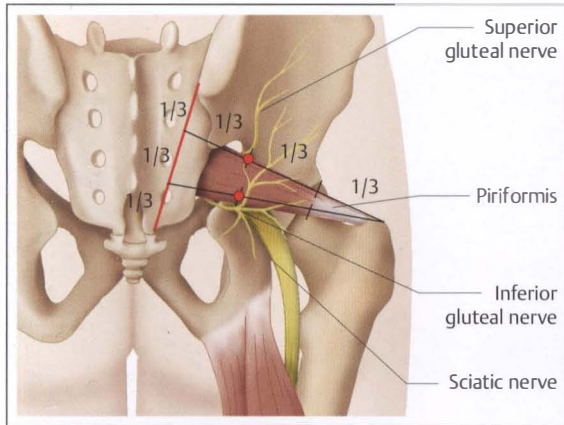


Fig. 9.87 Exit site for the superior gluteal nerve out of the pelvis.

The upper line indicating the superior border of the piriformis is divided into three. Again, the exit point for the nerve is found at the intersection between the medial and middle thirds. This point can be verified by applying pressure in an anterior direction and moving in a superior direction against the muscle belly of the piriformis and moving medially against the hard edge of the sacrum. This marks the suprapiriform foramen.

Local Palpation of the Pelvic-Trochanter Region

Overview of the Structures to be Palpated

- Region of the trochanter and the ischial tuberosity.
- Trochanteric bursa.
- Measuring the femoral neck anteversion (FNA) angle.
- Insertions on the trochanter.
- Width of the gap between the pelvis and the greater trochanter.
- Ischial tuberosity and sciatic bursa.
- Palpating muscle activity in the pelvic floor muscles.

Region of the Greater Trochanter and Ischial Tuberosity

The tuberosity is located in the horizontal gluteal crease using the familiar technique for quick bony orientation. The following palpation commences at the tip of the tuberosity. Therapists may have to change their SP and move to the side of the palpation when locating the structures. Generally, the opposite side is preferred.

To locate the dimensions of the greater trochanter exactly, the tip of the trochanter is sought first using a perpendicular palpation (Fig. 9.88). Therapists orient themselves by using the side areas first, then the edges.

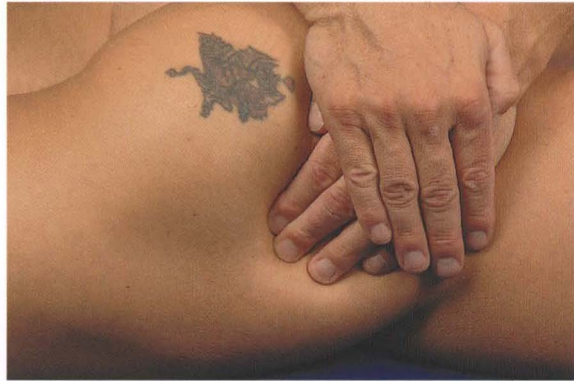

Fig. 9.88 Palpating the tip of the greater trochanter.

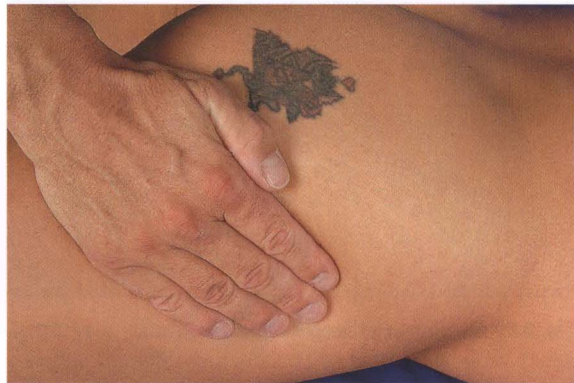

Fig. 9.89 Palpating the trochanteric bursa.

Trochanteric Bursa

Alongside muscular or osseotendinous symptoms, bursitis in the trochanter region is a common source of local lateral buttock pain. Inflammation occurs most commonly in the trochanteric bursa of the gluteus maximus. The side of the trochanter and the point medial to the gluteal tuberosity can be palpated to assess tenderness on pressure. The flattened technique, as described above, is used here (Fig. 9.89).

Information on Pathology

As with every other prominent location containing a bursa, you will not be able to feel the trochanteric bursa. In the case of bursitis, the only signs indicating that you are on the bursa are the feedback from the patient regarding pain provocation and possibly feeling synovial fluid fluctuating in the swollen bursa when palpating.

Trochanteric bursitis has been long known to be a cause of lateral hip pain. A detailed understanding of the peritrochanteric bursa morphology is important when confirming a diagnosis with palpation as well as for treatment, for example, with local infiltration. A study by Dunn

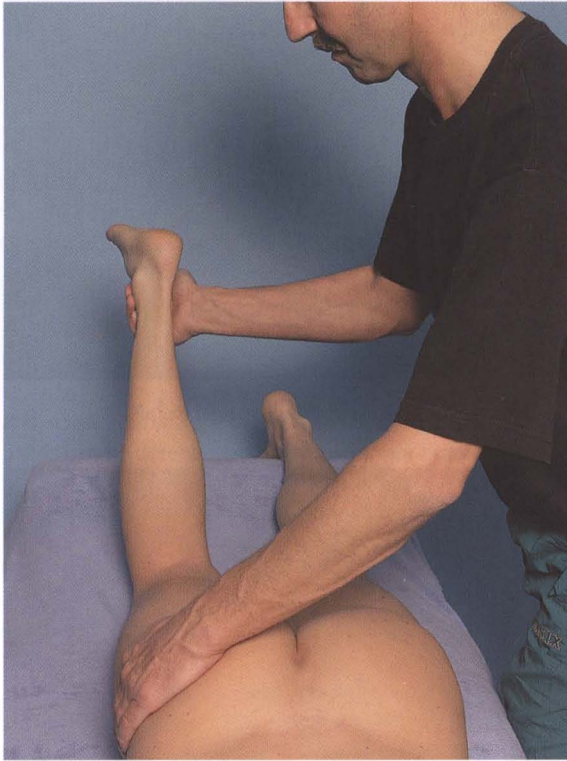


Fig. 9.90 Determining the FNA angle, SP.

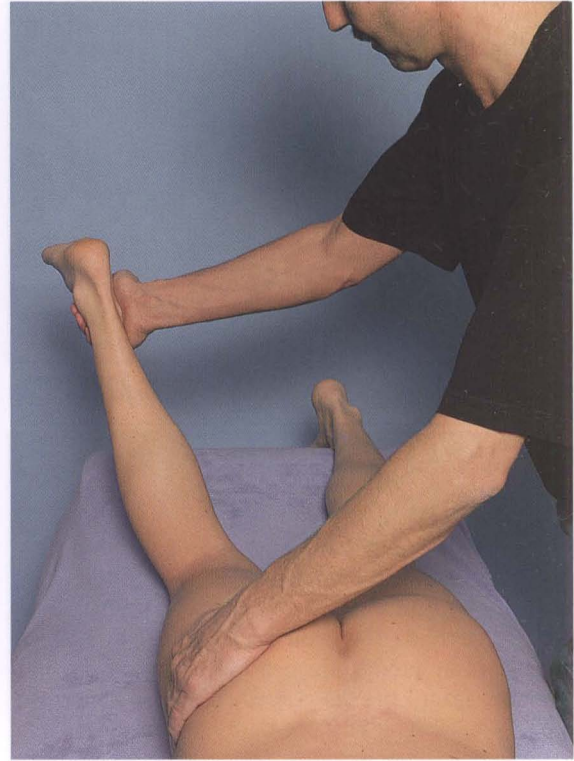


Fig. 9.91 Determining the FNA angle, final position.

et al. (2003) investigated the morphological relationships and positions of various peritrochanteric bursae on 21 bodies. They were able to locate a total of 121 bursae at 10 different locations. The bursae varied greatly, but a bursa was always observed between the greater trochanter and the gluteus maximus or the iliotibial tract. In most cases a bursa was discovered that belonged to the gluteus minimus.

Measuring the Femoral Neck Anteversion Angle

The lateral area provides the therapist with good clues when the FNA angle is being manually determined. It is largely responsible for the extent of internal rotation at the hip joint. The larger the FNA angle is, the more the hip joint is able to internally rotate when the soft tissues (capsule and muscles) are of normal elasticity. One sign that capsular mobility is beginning to become less elastic (capsular pattern) is the restriction in internal rotation of the hip joint. The FNA angle should be assessed and compared with the other side before an exact conclusion can be drawn as to whether the hip joint suffers restricted internal rotation. This is the reason why manual identification of the FNA is extremely helpful when examining the hip joint.

Technique

The hip joint is positioned in neutral rotation and the knee is flexed. The palpating hand molds itself flat around the lateral trochanter.

The hip is placed into internal rotation by moving the lower leg laterally in the sagittal plane (Figs. 9.90 and 9.91). The circular arc is visualized while the greater trochanter rotates inwardly around the femoral head.

The internal rotation movement is stopped when the trochanter has reached the point of the most lateral protrusion. The neck of the femur is now positioned horizontally and the FNA angle can be assessed.

The therapist assesses the lateral deviation of the lower leg in the sagittal plane in angular degrees.

This method does not determine the FNA exactly to the degree. It nevertheless always provides the therapist with an acceptable possibility to recognize rough differences in FNA angle ranges between left and right.

Insertions on the Trochanter

Palpation can be used to assess the tenderness to pressure at the insertion of the pelvic–trochanteric muscles and the small gluteals. The therapist stands on the opposite side for this.

The patient slides closer toward the therapist.

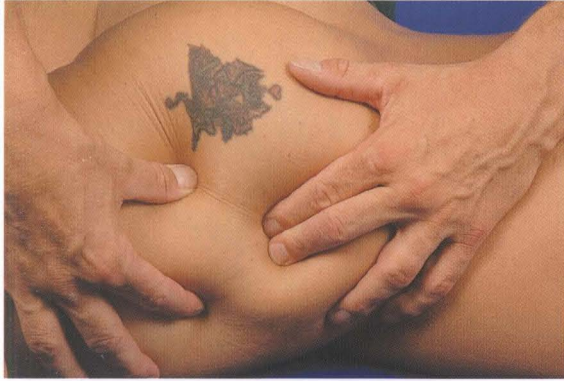

Fig. 9.92 Palpating the width of the greater trochanter.

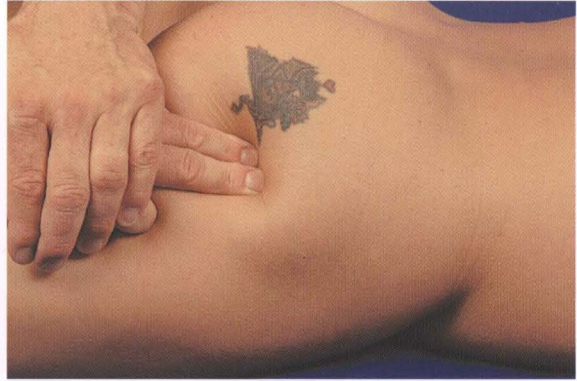

Fig. 9.94 Illustrating the gap between the pelvis and the greater trochanter.

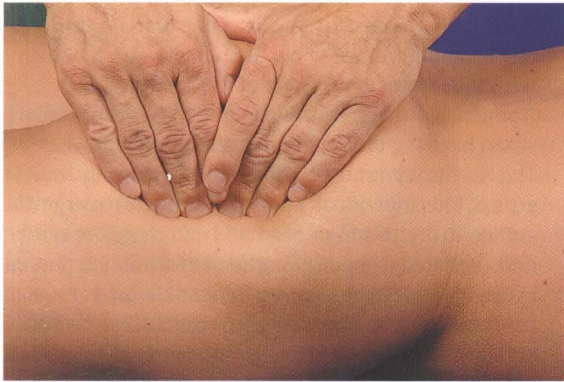


Fig. 9.93 Palpating the posterior insertions into the greater trochanter.

Tip: If it is difficult to feel the edges of the trochanter, its correct location can be easily reconfirmed by rotating the leg and feeling the movement of the bone underneath the palpating hand.

Information on Pathology

Patients frequently indicate that the lateral region of the buttocks is painful. It is not possible to primarily assess whether the symptoms are arising from this region. These symptoms frequently arise from referred or projected pain. The source of pain is located more proximally in this case. Function should be assessed thoroughly. In addition, the location of the pain source is determined accurately through local palpation for pain provocation.

Width of the Gap between the Pelvis and the Greater Trochanter

The space between the greater trochanter and the ischial tuberosity is presented as excessively large in anatomy books and in the common anatomical models. The gap measures only two to three finger-widths when the leg is positioned in neutral rotation, and significantly less when the hip is externally rotated. As discussed previously, the pelvic-trochanteric muscles and the thumb-wide sciatic nerve are located here.

Technique

The therapist continues from the last technique. The hand is turned and two fingers press firmly into the soft tissue on the posterior surface of the greater trochanter (**Fig. 9.94**). Tissue consistency is now assessed to confirm the correct localization of the bony structure and its surroundings. One finger is used to push against the edge of the trochanter, and the other finger pushes toward

Technique

The finger pads are placed in contact with the tip of the trochanter. The location of the trochanter may possibly have to be confirmed using rotation of the leg. The entire width of the trochanter is often underestimated. It is assessed by using the second hand to palpate the anterior and posterior edges of the trochanter (**Fig. 9.92**).

The finger pads push somewhat into the depths of the tissue and come into contact with the surrounding muscles. This technique is conducted with increasing pressure as a provoking palpation. The finger pads move transverse to the muscle being palpated.

Many muscular insertions into the greater trochanter and the depths of the intertrochanteric crest can be addressed during this procedure:

- Anterior and proximal insertions: anterior sections of the small gluteals.
- Proximal insertions: middle sections of the small gluteals.
- Posterior and proximal insertions: posterior sections of the small gluteals and piriformis.
- Posterior insertions: pelvic-trochanteric muscles (**Fig. 9.93**).

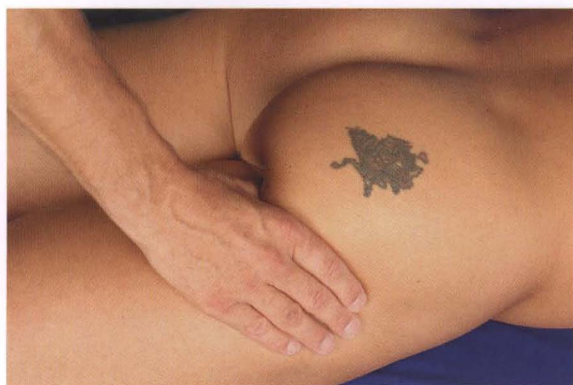

Fig. 9.95 Palpating the ischial tuberosity.

the tuberosity. In both cases the therapist should expect to feel bone.

Ischial Tuberosity and Sciatic Bursa

The beliefs associated with the size and contour of the tuberosity are extracted from anatomical sources that generally present the structure as too small. Its actual dimensions become clear when anatomical specimens are examined or the structure is palpated locally.

The sciatic bursa of the gluteus maximus absorbs friction that could endanger this prominent apophysis. Direct palpation can provoke the patient's symptoms when irritation is present.

Technique—Sciatic Bursa

The thumb pads are placed on the tip of the trochanter using the previously discussed technique for the rough localization of the tuberosity (see section "Ischial Tuberosity" above, p. 217). A possible bursitis can be confirmed through provocation by increasing pressure and moving the thumb back and forth slightly in a superior–inferior or medial–lateral direction.

Technique—Contours of the Ischial Tuberosity

Usually, the neighboring tissue turgor makes it impossible to precisely visualize the contours of the tuberosity. Based on our experience, a circular technique using the maximum surface of the thumb pads or several finger pads is a valid option.

The thumb is placed on the tip of the tuberosity (**Fig. 9.95**):

- The pad of the thumb palpates superiorly and inferiorly. The superior movement is restricted by a very firm structure that is nevertheless elastic when direct

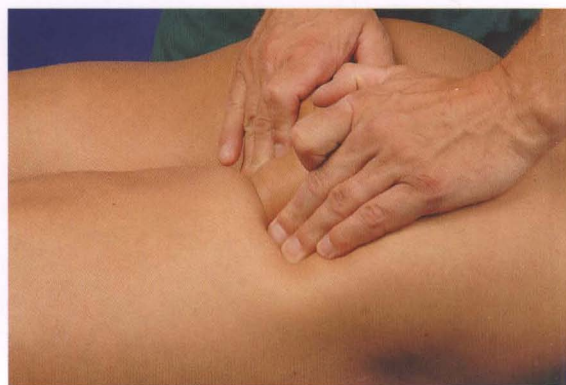

Fig. 9.96 Palpating the communal head of the hamstring muscles.

pressure is placed on it: the insertion of the sacrotuberous ligament. As we know, it connects the tuberosity with the inferolateral angle of the sacrum.

- A similarly firm structure prevents further movement when focusing on the inferior direction of movement. This is the common head of the hamstring muscle group. The individual hamstring muscles merge together at the common head and can therefore not be differentiated from one another. This common tendon of origin tends to be more evident on the lateral side of the tuberosity. The borders of the tendon can be differentiated from the surrounding softer tissues by palpating with the thumbs and the index finger or by palpating with both hands (**Fig. 9.96**). The side borders of the tendon can be precisely palpated (see also Chapter 5, p. 108).

Tip: The assumed position of the hamstring insertion on the tuberosity is confirmed by activating this muscle group through light isometric contraction toward knee flexion. If muscle activity in the gluteus maximus hinders palpation, the patient is instructed to push the knee against the treatment table to reciprocally inhibit the muscle.

Palpating Muscle Activity in the Pelvic Floor Muscles

Muscle activity in the pelvic floor muscles can be palpated without coming near the anal region by starting the palpation at the accessible inferior sections of the ischial tuberosity.

Technique

The therapist stands on the patient's right side when palpating muscle activity on the right side. It is recommended to use flattened finger pads for this technique.

Starting from the tuberosity, the finger pads move medially and follow the bony contours. The pelvic floor muscles are being palpated when further movement of the finger pads is restricted by a firm, elastic structure. This is confirmed by activating the corresponding muscles. The finger pads are pushed posteriorly when the muscle (levator ani) tenses.

Information on Pathology

This palpation is suitable when using feedback in the stimulation or strengthening of the pelvic floor muscles. Patients can also use this tactile confirmation when exercising alone.

Tips for Assessment and Treatment

The **localized height** of the iliac crests, the posterior superior iliac spines, and the anterior superior iliac spines are frequently consulted for the structural analysis of the lower limbs. These palpations are used to reach conclusions about possible differences in leg length or pelvic torsion. The PSIS must be identified exactly when the physician or therapist wishes to examine mobility with the standing flexion test (Figs. 9.97 and 9.98).

SI joint mobilization requires great manual strength, best applied by the largest bony leverage that can work on the pelvis (Fig. 9.99). The necessary reference points can already be found using the quick bony orientation, for example, the iliac crests, the ischial tuberosity, and the edge of the sacrum.

Several ligamentous structures can also cause **sacral pain** when irritated. The long posterior sacroiliac ligament indicates functional disorders in the SI joint. Overstretched ligamentous connections to the coccyx are frequently the source of pain following a fall onto the buttocks.

Local soft-tissue pain is difficult to diagnose. Pelvic pain must first be identified as pain that is not being referred or projected. Now, the attempt is made to locate and identify the affected tissue. Bursitis, peritrochanteric insertion symptoms, a tense piriformis, or even the piriformis syndrome are examples of local sources of pain. An exact palpatory technique identifies the affected structure quite well and supplements the results of the functional assessment wisely.

Exercises for the pelvic floor muscles are widely based on perception. Tactile feedback from the pelvic floor muscles directly medial to the ischial tuberosity helps patients to develop a feel for voluntary activity more quickly.

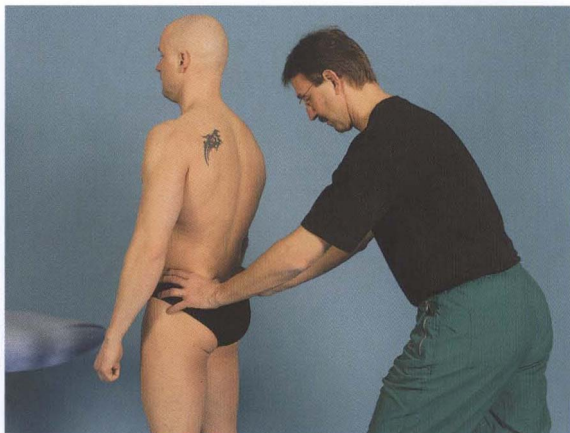


Fig. 9.97 Standing flexion test, SP.



Fig. 9.98 Standing flexion test, final position.

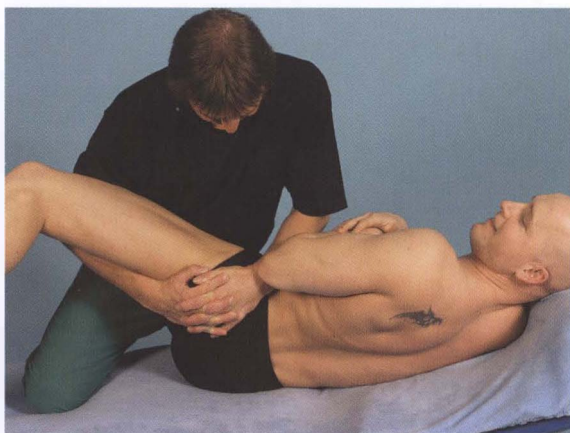


Fig. 9.99 SI joint mobilization.

Study Questions

1. How is the development of the piriformis syndrome described?
2. What are the consequences of the slanted position of the sacrum?
3. Where is the sacral hiatus located and which structures are found between the sacral horns?
4. What is the distinctive feature of the long posterior sacroiliac ligament?
5. Try to explain why the SI joint is held together by a combination of structural shape and tissue strength.
6. What layers is the thoracolumbar fascia made of and what is the posterior diagonal sling?
7. Which bony reference points mark the dimensions of the gluteus muscles?
8. Which structure is being palpated when you place the side of your hand on the side of your waist?
9. How do you accurately palpate the side edges of the sacrum and which structures can be reached from there on?
10. What does the patient need to do to make the gluteus maximus particularly prominent? Consider which commands would be suitable here that patients can understand!
11. Which structures can tense the iliotibial tract?
12. What are the two variations that can be used to find the PSIS and why is accurate localization so important?
13. What structure is located at the inferior end of the median sacral crest and which other structure forms its boundaries?
14. What possibilities exist to correctly differentiate between the sacrum and the coccyx?
15. What makes the exact localization of the inferolateral angle so difficult?
16. What structure is sometimes sensitive to pressure when the therapist locates the inferior edge of the PSIS?
17. How do you reach the SI joint when palpating from an inferior direction?
18. How can the therapist be sure they have really found the point where the sciatic nerve exits from beneath the piriformis?
19. Which structures are found in the pelvic-trochanteric gap?
20. Which structures can be reached by starting out at the tip of the ischial tuberosity?



10 Lumbar Spine

Significance and Function of the Lumbar Spine ...	241
Common Applications for Treatment in this Region ...	242
Required Basic Anatomical and Biomechanical Knowledge ...	243
Summary of the Palpatory Process ...	258
Starting Position ...	258
Difficult and Alternative Starting Positions ...	259
Palpation Techniques ...	259
Tips for Assessment and Treatment ...	264
Study Questions ...	269

THIS PAGE INTENTIONALLY
LEFT BLANK

10 Lumbar Spine

Significance and Function of the Lumbar Spine

The embryonic curves change during early childhood development in two sections of the vertebral column. The lumbar spine represents one of these sections. The mobile sections of the vertebral column (cervical and lumbar spines) become lordotic. The thoracic spine and the sacrum remain in their original kyphosis. The cervical and lumbar spines also possess deep prevertebral muscles (e.g., psoas major).

Supporting the Weight of the Body

From a kinetic point of view, the lumbar spine supports the weight of the upper body, the head, and the arms. As already described, approximately 60% of the body's weight in an upright posture is transmitted from the lumbar spine onto the S1 end plate. The lumbar spine adapts to this loading with wider and more solid material in the bones, collagen, and fibrous cartilage (structural stability / force closure).

Spatial Alignment of the Upper Body

The lordotic sections of the spine provide spatial orientation for the parts of the body they support. The lumbar spine supports, props up, and turns the upper body. The cervical spine supports and aligns the head in relation to its surroundings.

The Importance of Stability for Standing and Lifting

The intervertebral disks, ligaments, and muscles are in particular responsible for stability in the vertebral column and achieve this using compression and tension banding. The erector spinae are not very active in the upright posture. Their activity increases when the body's center of gravity moves anteriorly, for example when:

- The upper body bends forward.
- The cervical spine is flexed.
- An arm is elevated.

It is important that the tissues provide the mobile parts of the chain with force closure to enable controlled movement. For this reason science of human movement states:

“Stiffness is a precondition for movement.” In a multisegmental system such as the vertebral column, stability is maintained by reducing the range of available mobility in individual segments so that the entire system can move harmoniously. The trunk extensors become inactive after approximately 60° of trunk flexion due to the ligamentous structures taking over the job of decelerating movement. The thoracolumbar fascia is the most important ligamentous structure (see Fig. 10.33).

Movement in the Trunk

The lumbar spine is an organ designed for flexion, with movement mainly occurring in the sagittal plane. It is just as natural to move out of the lordosis to bend the trunk backward and forward as it is to develop the lordotic form when standing. The lumbar spine is anatomically constructed and equipped for flexion. It is irrelevant whether the movements are proper “flexion” or just a “straightening out of the lordosis” for palpation.

Certain anatomical structures assist the lumbar spine in its movement in the sagittal plane:

- The alignment of the lumbar vertebral joints superior to L5 makes extensive movement in the sagittal plane possible (Fig. 10.1).
- Thick intervertebral disks make extensive tilting movements possible in the lumbar segments.

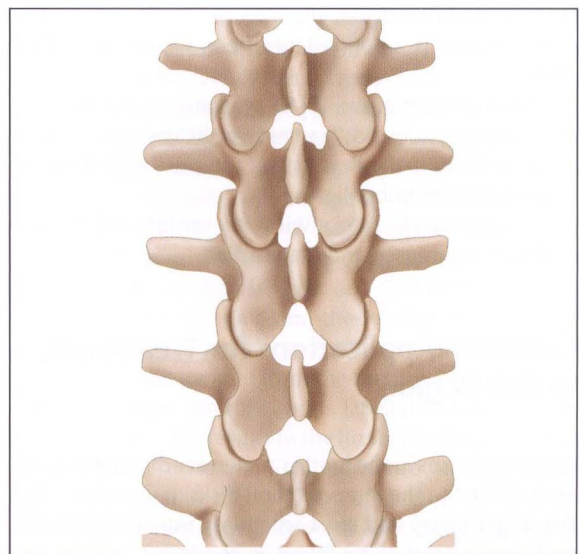


Fig. 10.1 Schematic illustration of the alignment of the lumbar zygapophysial joints (ZAJs). Compare this to Fig. 10.9, p. 245.

- Structures that decelerate movement and absorb forces: ligamentum flava, interspinous ligaments, thoracolumbar fascia.
- The exceptionally strong intrinsic muscles of the lateral tract (iliocostalis, longissimus).

Development of Energy Needed for Locomotion

According to Serge Gracovetsky (1988), the impulse for walking arises in the lumbar spine and is based on the mobility and activity in the muscles that cause rotation (the multifidi and external oblique). The legs only follow and reinforce this movement. Examples from evolution (fish, amphibians) demonstrate how important lateral flexion is for locomotion. In human beings, the lumbar spine uses lateral flexion and coupled rotation to transfer the trigger for locomotion onto the pelvis and the legs, whereby a lumbar lordosis and a certain walking speed are important. The impulse and energy arises solely in the legs when gait is slow; this requires a great deal of strength.

Junction between the Rigid and Mobile Vertebral Column

The junction between the lumbar spine and the sacrum is a region of anatomical and pathological “turbulence.” Anatomical variations in the number of vertebrae (e.g., hemisacralization) as well as a multitude of pathological conditions are frequently found here. This distinctive feature is probably due to typical biomechanical loading in addition to the lumbar spine acting as the junction between the freely mobile vertebral column and the rather rigid pelvis, in particular the sacrum.

This region is supported by different anatomical structures:

- The alignment of the L5–S1 zygapophysial joints.
- Strongly reinforced ligaments or ligaments that have been additionally developed (anterior longitudinal ligament, iliolumbar ligaments).
- Thoracolumbar fascia with its various collagenous layers and muscular dynamization.

Common Applications for Treatment in this Region

Most symptoms in the lumbar region are directly or indirectly related to the intervertebral disks. It is a known fact that the primary and most secondary intervertebral disk pathologies tend to be found in the lower lumbar segments of L4/L5 and L5/S1. The primary intervertebral disk symptoms range from internal rupturing to the dif-

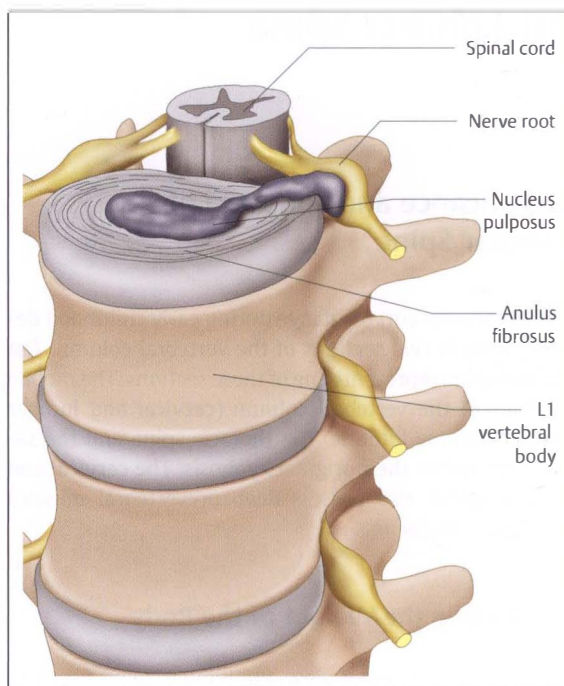


Fig. 10.2 Intervertebral disk prolapse.

ferent forms of protrusions and prolapses of intervertebral disk substance (Fig. 10.2). These symptoms possess a large potential for self-healing. The initial physical therapy management of acute back pain aims to assess the primary pain and relieve affected neural structures, thereby supporting self-healing. The first inflammatory stage ends after a few days. Physical therapy then addresses the increased muscle tension, adaptive postures, immobilization, decreased proprioception, and, when necessary, the repositioning of the intervertebral disk substance.

The therapeutic approaches to treatment always address the entire lumbar spine. Precise palpation techniques only have limited use here. For instance, it is generally not necessary to ascertain which segment is affected by provoking pain with palpation or assessing the local mobility. It is important to assess whether there is excessive muscle tension in the paravertebral muscles for the treatment of subacute disk-related symptoms. This provides therapists with a sensible basis when they are deciding which treatment to use. When patients present with these sets of symptoms, therapists are therefore required to systematically palpate the muscles and have knowledge of *in vivo* anatomy (see the section “Palpating the Consistency of Muscle [Assessment of Muscle Tension]” in Chapter 8, p. 189).

The secondary pathological intervertebral disk conditions behave completely differently. *In vivo* anatomy is often required in this case. Degenerative changes to the lumbar disks cause a surprisingly large range of symptoms. The intervertebral disks can be the source of pain

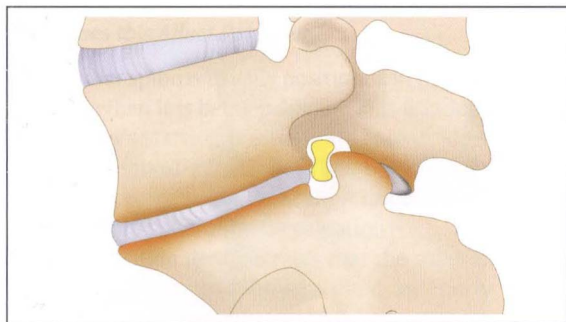


Fig. 10.3 Types of pathological changes possible as a result of intervertebral disk degeneration.

and can be responsible for the involvement of sensitive ligamentous and neural structures (**Fig. 10.3**).

These types of pathological disorders are mainly in the form of local segmental instability, chronic intervertebral disk irritation, disorders and diseases in the zygapophysial joints, and varying degrees of stenoses. Of course, combinations of these pathological conditions are possible. Just think of the neighboring hypermobile and hypomobile segments that are frequently present.

There are several different approaches to therapeutic management. The main aim of these approaches is pain relief and stabilization. Detailed anatomical orientation is an important foundation for segmental assessment and for the reliable use of local segmental techniques.

The role of in vivo anatomy here is:

- To locate the affected segments using provocation.
- To identify the affected segments by differentiating them from the neighboring segments (locating their level).
- To assess the segmental stability and mobility using angled or translation tests.

Competence in palpation is obtained from the consequential use of in vivo anatomy. It enables the therapist to provide exact information on the functional characteristics of the lumbar spine and therefore substantiates the treatment plan and the targeted use of pain relieving and/or mobilizing techniques.

Required Basic Anatomical and Biomechanical Knowledge

The following information represents only a selection of information available on local anatomy and biomechanics. Several areas, such as the construction and function of the intervertebral disks or neuroanatomy, are not discussed in order to stay on the topic of in vivo anatomy. These sections primarily discuss the anatomical details required for palpation. A basic knowledge of movement segments according to Junghanns is of advantage.

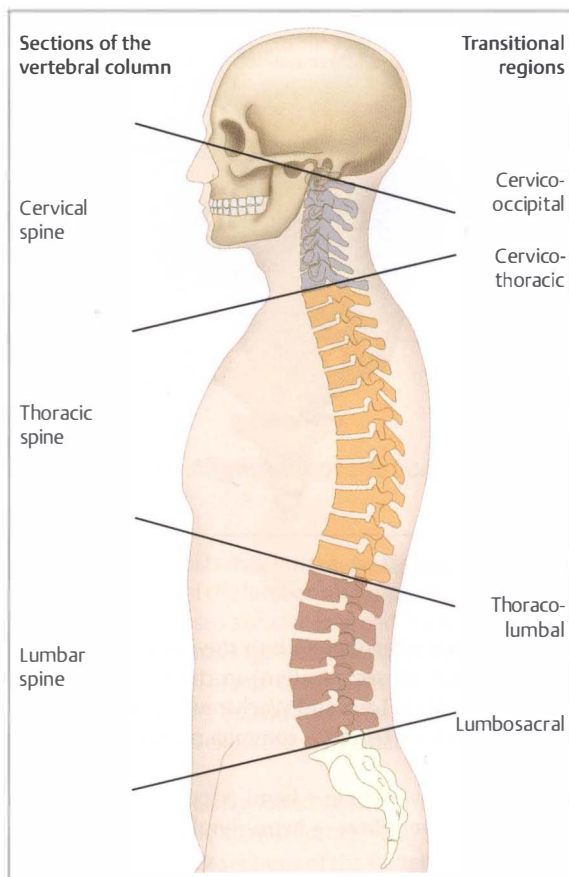


Fig. 10.4 Anatomical sections of the vertebral column.

Anatomical Definitions

The inferior section of the freely moveable vertebral column, the lumbar spine, usually consists anatomically of five freely moveable vertebrae. However, this is not the case in every individual. As already mentioned above, the lumbosacral junction is quite variable and anatomically “turbulent.” Töndury (1968, in Lanz and Wachsmuth, 2004a) wrote about the entire spectrum of variation in the anatomy with respect to the anatomical boundaries of all sections of the vertebral column (**Fig. 10.4**): “Only approximately 40% of all people have their boundaries in the normal location.” The boundaries between the thoracic spine and the lumbar spine as well as the lumbosacral junction are of interest here.

When S1 is separated from the sacrum, it takes on the role of a lumbar vertebra and is labeled anatomically as lumbarization. This results in the lumbar spine possessing six vertebrae. The anatomist defines the superior variation or sacralization as the fusion of L5 with the sacrum. This can be present partially or on both sides (**Fig. 10.5**). In this case, only four freely mobile vertebrae exist. It becomes quite confusing when the therapist considers that there is even more variety in the number of sacral vertebrae.

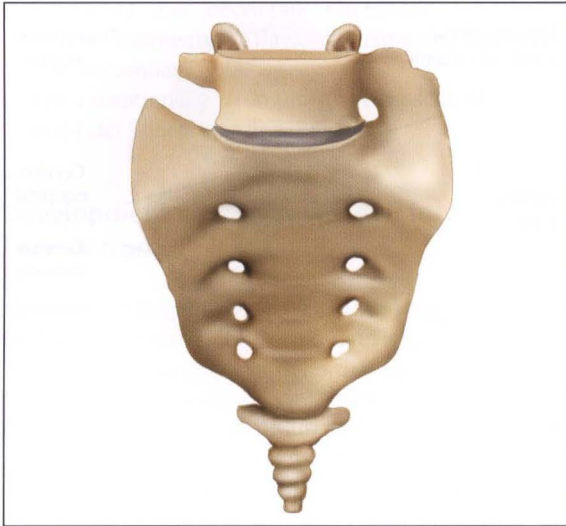

Fig. 10.5 Hemisacralization

rae. The terms refer therefore to the possible variations (lumbarization or sacralization) in the freely moveable lumbar vertebrae (Lanz and Wachsmuth, 2004a):

- Five lumbar vertebrae → common number in the lumbar spine.
- Four lumbar vertebrae → hemi-/sacralization in 3–12%.
- Six lumbar vertebrae → hemi-/lumbarization in 2–8%.

How Does this Affect Palpation?

A focus for in vivo anatomy along the vertebral column is defining the exact location, the level of a structure. Topographical knowledge provides the therapist with expected norms. These norms are transferred onto the living body during palpation. What does it mean when our confidence in topographical orientation—our knowledge of anatomy that we learn during training—becomes lost in the variation?

Variations in the anatomy of the lumbar spine make it difficult to locate the L5 spinous process. When three protruding and pointed spinous processes are found at the lumbosacral junction, it is difficult to differentiate between L5 and S1 by simply looking at their shape. What options exist to confirm the location of a structure when no movement in L5 on S1 can be felt, as is seen when mobility is restricted or when hemisacralization is present? How can therapists remain confident in their palpation when the suspected S1 spinous process moves on S2? Is the localization incorrect or is a lumbarization present?

Fortunately, constants also exist in anatomy. Certain structures have a constantly recurring shape, always react to pressure in the same way, and behave typically when they move (changes due to pathological conditions are not included here):

- The L5 spinous process is always smaller than the L4 spinous process.

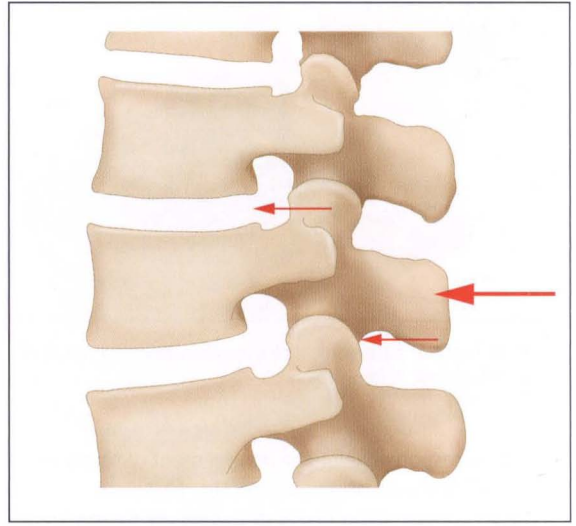


Fig. 10.6 Posteroanterior pressure displaces the vertebra.

- The T12 spinous process is always smaller than the L1 spinous process.
- Posteroanterior pressure applied to a spinous process moves the vertebra slightly anteriorly (Fig. 10.6).
- Rotation (in a coupled movement pattern) in one segment leads to the development of a palpable step between two neighboring spinous processes.

Shape of the Inferior Lumbar Vertebrae and Intervertebral Disks

From an anatomical point of view, the lumbar lordosis is supported by the wedge-shaped construction of the vertebral bodies, especially at L5 and most notably at the L5/S1 intervertebral disk (Bogduk, 2000) (Fig. 10.7).

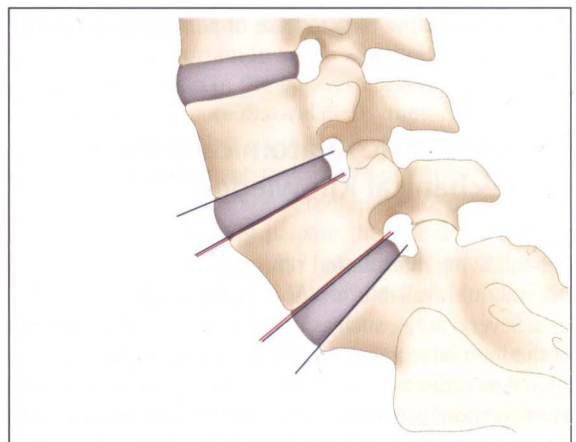


Fig. 10.7 Wedge shape of the vertebrae and intervertebral disks.

How Does this Affect Palpation?

The lumbar spine is usually positioned in its physiological lordosis when it is being palpated. This is independent of the patient's starting position (SP) (prone, side-lying). It may be the most natural position, but it does make the palpatory process more difficult. A lordotic lumbar spine offers certain conditions for palpation:

- The palpation demonstrates that the superior section of the sacrum is definitely tilted anteriorly and its angled surface can be distinguished.
- When the erector spinae are prominent, all spinous processes can only be reached at their tips and somewhat to the side.
- The L5 spinous process is mostly found deep in the tissues and in close proximity to L4 and S1.
- The thoracolumbar fascia and the back extensors are relatively relaxed.

Further sections will explain which lumbar spine positions are favorable or less favorable for precise palpation.

Detailed Anatomy of Bony Structures

The thick vertebral bodies (VBs) are generally shaped like a bean or a kidney. Each VB is a tube made of the bone's cortical substance filled with the bone's spongy substance. The VB is enclosed superiorly and inferiorly by hyaline end plates. These end plates are nowadays included functionally as a part of the intervertebral disk (Bogduk, 2000). The vertebral arch connects immediately posterior onto the vertebral body. All vertebral processes are attached to the arch:

- Spinous process.
- Superior and inferior articular processes.
- Costal processes.

Spinous Processes

These processes point directly posterior and are strongly developed (Fig. 10.8). They are the only osseous structure in the lumbar spine that the palpating finger can reach with certainty. The shape of the lumbar spinous processes is typical and can be well differentiated from the neighboring sections of the vertebral column during palpation.

How Does this Affect Palpation?

The L5 spinous process is smaller and more rounded. It almost "points" posteriorly. It can generally be well located. The therapist may get confused between neighboring spinous processes when the S1 spinous process is pronounced. This can make it more difficult to allocate a segment to a specific level.

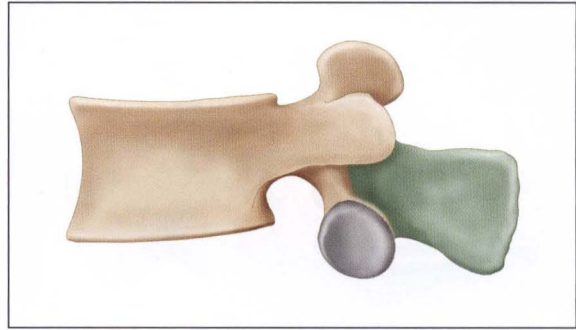


Fig. 10.8 Spinous process

The Shape and Alignment of the Lumbar Spinous Processes

The novice therapists may initially be surprised by the size and morphology of the lumbar spinous processes. The L1–L4 spinous processes are rather broad (superior–inferior dimensions) and have an exceptionally irregular shape with indentations along their posterior aspect, giving them an undulating appearance (Fig. 10.9). The spinous processes are often expected to be smaller than they actually are.

Bursae are regularly found between the neighboring lumbar and thoracic spinous processes.

As with the other sections of the vertebral column, the therapist should not expect the lumbar spinous processes to always form a straight line. The lumbar spinous processes can protrude laterally away from the mid-line by up to a few millimeters and up to one centimeter in the thoracic spine and still be seen as a normal variation in anatomy.

How Does this Affect Palpation?

The palpatory differentiation of spinous processes by locating the interspinal space is made considerably more difficult by their undulating form. Aids must be used once again to ensure that structures have been allocated to the correct level. Provided the condition of tissues does not make palpation difficult in study partners and patients, the long spinous processes can be correctly differentiated from the pointed L5 and the T12 spinous processes after gaining some experience. The T12 spinous process is likewise very thin.

Therapists and physicians often directly connect the position of the spinous processes with a local pathological condition. A spinous process that deviates from the mid-line is mostly interpreted as a rotational malpositioning of the respective vertebra. However, this cannot always be the case due to the large variation in anatomy. A palpatory finding must always be supported by local mobility tests and provocation tests to conclude the presence of a segmental pathological condition.

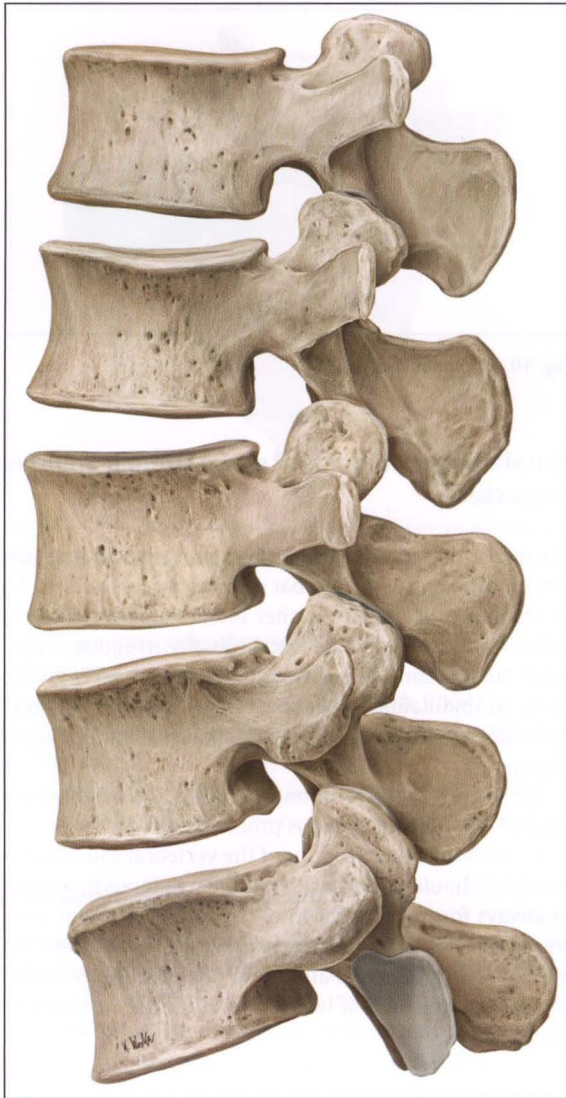


Fig. 10.9 Irregular row of spinous processes (From Thieme Atlas of Anatomy, General Anatomy and Musculoskeletal System, © Thieme 2005, Illustration by Karl Wesker).

Lumbar Transverse Processes

The lumbar transverse processes are remnants of ribs from the times of somitic composition. This arrangement can still be observed in the thoracic spine and is the reason why the transverse process is labeled the costal process. All transverse processes are strongly developed and extend directly sideways from the vertebral arch. According to Lanz and Wachsmuth (2004a), the L3 costal process is the widest. In rare cases (4–8%), L1 can possess an oversized process that is described in literature as a lumbar rib (Lanz and Wachsmuth, 2004a). This makes it more difficult to differentiate the thorax from the lumbar spine when using palpation.

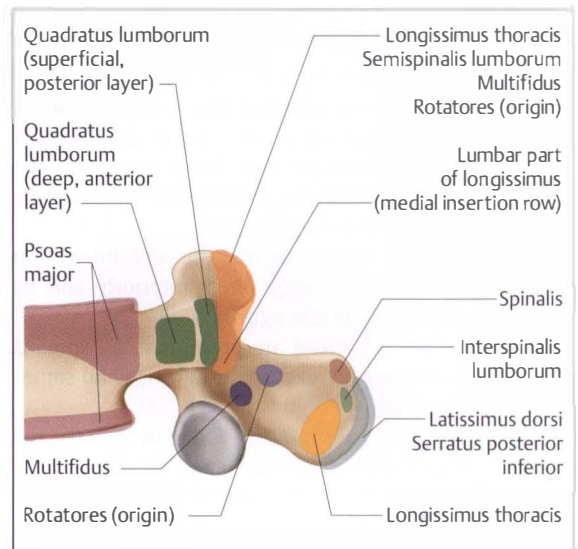


Fig. 10.10 Muscular attachments (from Dvořák).

A multitude of muscles attach onto the transverse processes (Dvořák et al., 2008). As with the spinous processes, the transverse processes are therefore perfect levers for acting forces moving the lumbar vertebrae into lateral flexion and rotation (Fig. 10.10). The transverse processes separate the posterior intrinsic back muscles topographically from the anterior deep abdominal muscles (e.g., psoas major).

Muscular or dynamized connective-tissue structures are currently regarded as functionally very important in the stabilizing treatment of the lumbar spine. These structures insert on the costal processes:

- Transversus abdominis over the middle layer of the thoracolumbar fascia.
- Quadratus lumborum.
- Multifidus.
- Longissimus.

How Does this Affect Palpation?

The attempt to reach the transverse processes using palpation is only conclusive on slender people. The transverse processes are located several centimeters anterior to the superficial surface of the back and are completely covered by the thick, prominent back extensors. Only the tips of the L3 and possibly the L4 transverse processes can be reached. This is achieved by applying significant posteroanterior pressure lateral to the back extensors and superior to the iliac crests, then palpating in a medial direction in the hope of coming across a hard structure.

The purpose of this maneuver is questionable, alongside the technical difficulties associated with this procedure. This technique is not suitable for diagnosing the alignment of the structure or for the selective provocation of pain and will therefore not be discussed later.

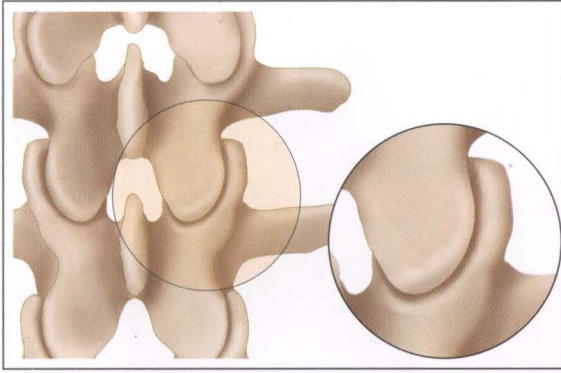


Fig. 10.11 Zygapophysial joint (ZAJ).

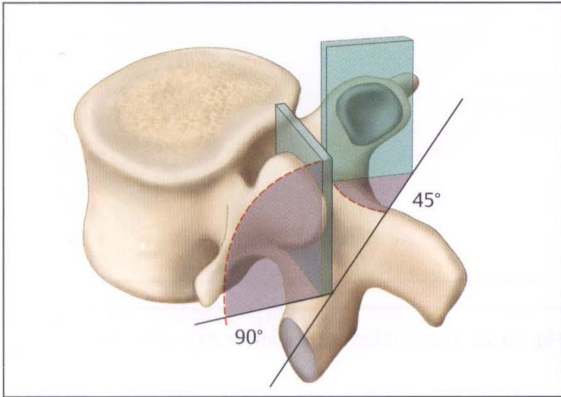


Fig. 10.12 Alignment of the lumbar ZAJs.

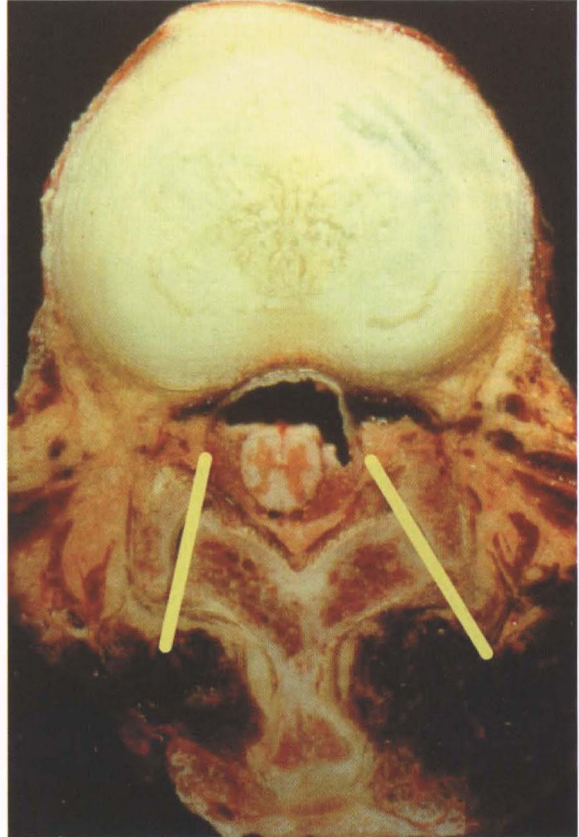


Fig. 10.13 Facet tropism

Zygapophysial Joints

These are some of the most important functional parts of the vertebra. The largest variety of terms is also used to describe these joints (e.g., facet joints, vertebral joints). The thickness and construction of intervertebral disks enable segments to move. In principle, the zygapophysial joints (ZAJs) determine how this potential for movement is used. The alignment of these joints dictates the direction and partially the range of segmental movement. It is well known that the superior articular process of the inferiorly positioned vertebra (more concave) forms a ZAJ with the inferior articular process of the superiorly positioned vertebra (more convex) (Fig. 10.11).

The **position of the lumbar joint facets** between T12/L1 and L4/L5 is uniformly described in manual therapy literature (Dvořák, 2008): In relation to the vertebral bodies, the superior joint surfaces are arranged upright and converge at an average angle of 45° from posterolateral to anteromedial (Fig. 10.12). This angle gradually decreases in the more superior vertebrae (Bogduk, 2000).

This results in the lumbar spine's affinity to movement in the sagittal plane, enables the lumbar spine to laterally flex, and prevents axial rotation. The latter movement can best be visualized by looking at the axes for lumbar move-

ment found in the disk (see the section "Basic Biomechanical Principles" below, p. 256).

The L5/S1 joint facets orient themselves more in the frontal plane, somewhat increasing this segment's ability to axially rotate.

The **principle of anatomical variation** continues in the lumbar ZAJs.

Joint surfaces of the same level can be shaped differently with different spatial alignment without being pathological. Individual differences in the shape of the ZAJs between sides is labeled "facet tropism" (Jerosch and Steinleitner, 2005) (Fig. 10.13). This means that the previously described spatial alignment of the joint surfaces is to be understood as only representing the average and that there are differences between the left and right side in each segment.

How Does this Affect Palpation?

The ability to palpate the vertebral column is mainly used to assess segmental mobility and to ascertain the level of individual structures. To be able to do this, the therapist must be aware of the possible range of motion in the sections of the vertebral column.

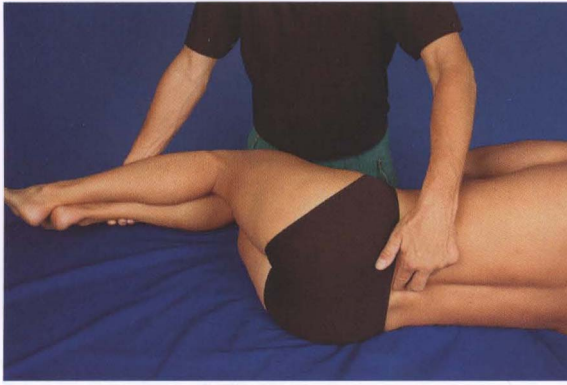


Fig. 10.14 Palpating flexion and extension.

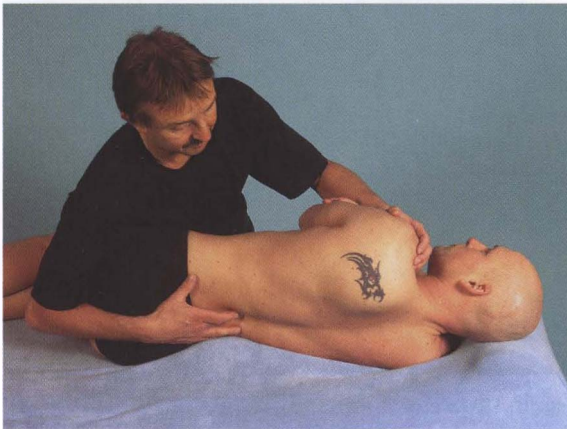

Fig. 10.15 Palpating lateral flexion and rotation.

The influence of differently formed joint facets on the palpation during movement will be clarified later. It can be presumed that facet tropism does not affect the degree of symmetrical movement in the lumbar spine (flexion and extension). When the anterior tilt of the vertebra is different on the left and right side during flexion, this cannot be felt because sagittal movement is simply perceived as an opening or closing of the spinous processes (Fig. 10.14). A difference in movement between the sides where the vertebra moves asymmetrically does not change the palpable range of motion.

This is different for asymmetrical lateral flexion or rotation movements, where the effect of differently formed joint positions and shapes is important. The range of motion in segmental lateral flexion and rotation to the left and to the right can therefore differ, even in “healthy segments.” For this reason, the therapist compares sides when assessing the range of local motion while still being aware of what is happening in the neighboring segments (Fig. 10.15).

The ZAJs and their capsules stand out in anatomical specimens with their astoundingly large ball-like form. Their position is approximately at the level of the inferior

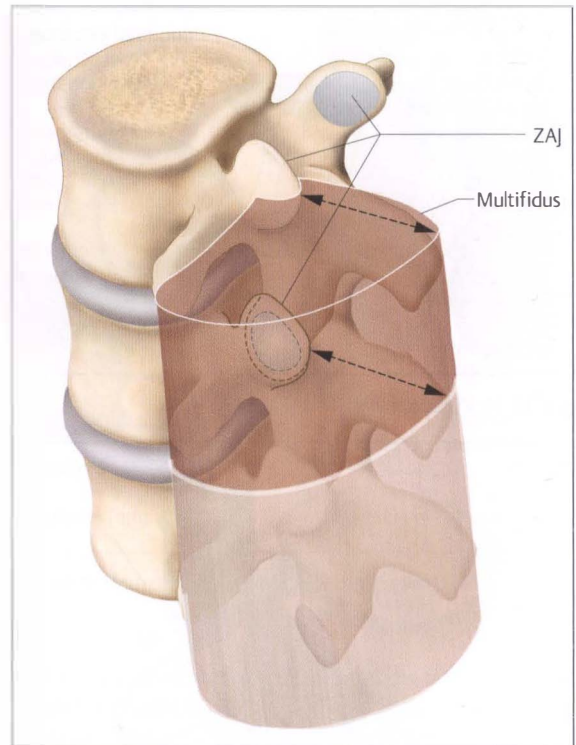


Fig. 10.16 The position of the lumbar ZAJs under the muscles.

edge of a spinous process. To palpate the ZAJs, the therapist must overcome a layer several centimeters thick (25–35 mm) consisting of the thoracolumbar fascia and the multifidus (Bjrdal et al., 2003) (Fig. 10.16). In my opinion, it is not possible to locate the joint by palpating the contours, feeling the different consistencies of the tissues, or through the use of palpation under movement. Pain can be provoked by applying pressure to the soft tissue. However, it is not possible to definitely attribute the pain on pressure to the involvement of the ZAJs.

Detailed Anatomy of the Ligaments

Four ligamentous systems can be differentiated from one another in the lumbar spine:

- Vertebral body ligaments.
- Columns of segmental ligaments.
- Additional lumbar ligaments.
- Thoracolumbar fascia.

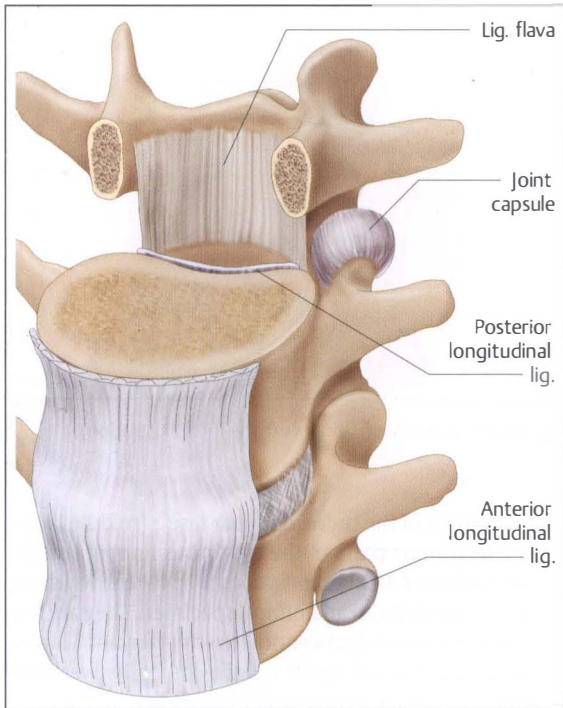


Fig. 10.17 Vertebral body ligaments.

Vertebral Body Ligaments

Both longitudinal ligamentous columns accompany the entire vertebral column: the *anterior and the posterior longitudinal ligaments*. These ligaments are also part of the basic ligamentous structures found in a segment (Fig. 10.17).

The **anterior longitudinal ligament (ALL)** is found anterior to the foramen magnum and extends down to the sacrum where it attaches inseparably onto the periosteum. It becomes increasingly wider more inferiorly. Superficial layers skip over four to five vertebrae. Deeper layers connect two neighboring vertebrae (Bogduk, 2000). All sections of the ligament are attached to the middle of the vertebral body and are not firmly connected to the intervertebral disk's anulus fibrosus. This ligament helps to restrict lumbar extension and prevent an increase in lordosis.

The **posterior longitudinal ligament (PLL)** is also made up of two layers. The superficial layer runs in a longitudinal direction and is thin. The deep layer runs in a transverse direction and is wider. It connects to the anulus fibrosus, reinforcing the disk. This ligament passes from the occiput to the coccyx, just like the anterior longitudinal ligament. The ligament has special nomenclature in its upper cervical section and at the lumbosacral junction. In comparison to the ALL, the PLL possesses a high number of nociceptors and acts as an "alarm bell" for certain pathological conditions in the intervertebral disk.

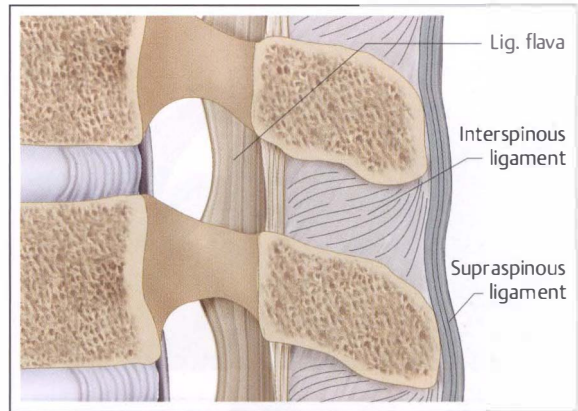


Fig. 10.18 Ligamenta flava and the supraspinous and interspinous ligaments.

Columns of Segmental Ligaments

A row of short ligaments is found between the vertebral arches and the protruding processes, each connecting two vertebrae.

In young people, the **ligamenta flava** (Fig. 10.18) are mainly made of elastic fibers. They extend between the laminae of the vertebral arch and line the posterior side of the vertebral canal. These ligaments are under tension even in an upright posture. When the trunk is flexed, these ligaments are placed under increasing tension, save energy, and help the vertebral column to return to an upright posture, therefore reducing the required muscle power. The anterior section of the zygapophysial joint capsules is formed by the ligamenta flava.

The **intertransverse ligaments** are quite thin and membranous in the lumbar spine. They connect the transverse processes—called the costal processes here—and are placed under tension when contralateral lateral flexion and rotation are performed.

The **interspinous ligaments** (Fig. 10.18) stretch between the spinous processes of two neighboring vertebrae. The literature describes the alignment of the fibers quite differently. The details vary from a vertical alignment, via the anterosuperior course of fibers (Netter, 2004), to the posterosuperior course of fibers (Bogduk, 2000), demonstrating the need for clarification in descriptive anatomy. All authors agree that these ligaments limit flexion and rotation.

The **supraspinous ligament** (Fig. 10.18) is found superficial to the spinous processes and is basically the only ligament that can be palpated in the lumbar spine. This structure should not be seen as a ligament. Rather, it should be viewed as a doubling of the thoracolumbar fascia. Vleeming recently commented on this (personal communication): "The supraspinous ligament is really an anatomical specimen artifact."

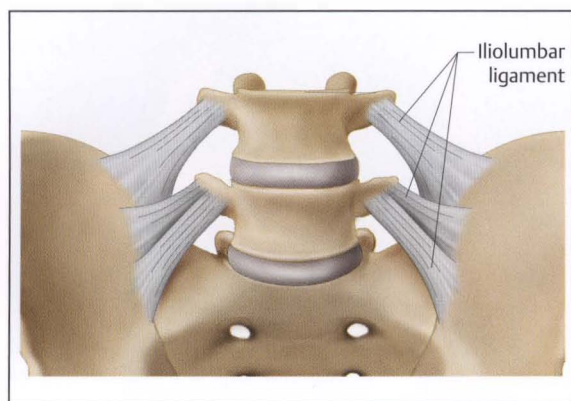


Fig. 10.19 Iliolumbar ligaments (simplified illustration).

The following relationships are currently being discussed:

- The superficial layers of this fascia meet at the midline.
- The connecting line is reinforced with ligamentlike structures.
- A section is attached to the periostium of the spinous processes.
- The other section is found in the interspinous space, forms the interspinous ligaments, and even extends into the ligamenta flava deep inside the movement segment.

How Does this Affect Palpation?

As already described, it is very difficult to palpate the posterior aspect of the spinous processes due to their irregular contours and undulating shape. The presence of the supraspinous ligament makes it even more difficult to feel the interspinous space when searching for the boundaries to the neighboring vertebra using palpation. The supraspinous ligament is absent between L5 and S1 (Heylings, 1978, in Bogduk, 2000). This may contribute to the fact that the lower edge of L5 can be palpated well (see the section “Local Bony Palpation” below, p. 260).

Additional Lumbar Ligaments

The iliolumbar ligaments (Fig. 10.19) are the most important complex of ligaments that have contact with the lumbar spine but arise elsewhere. They run from different points on the L4 and L5 costal processes to the anterior aspects of the iliac crest and the ala of the ilium. The individual sections vary in their construction and are connected to the lumbar segmental ligaments and the sacroiliac ligaments (Pool-Goudzwaard et al., 2001).

The iliolumbar ligaments are also described in the anatomical literature (Lanz and Wachsmuth, 2004a) as a continuation of the intertransverse ligaments, partially as a

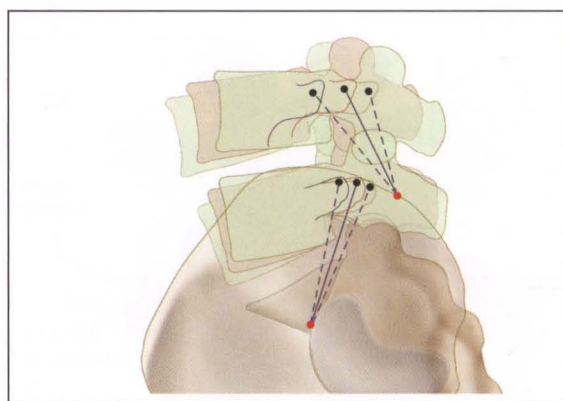


Fig. 10.20 Iliolumbar ligaments (simplified illustration).

reinforcement of the thoracolumbar fascia (middle layer), as well as fibrotic parts of the quadratus lumborum. The position of these structures becomes apparent when the ligament is seen on an anatomical specimen. They are hidden beneath the several-centimeter-thick layer of intrinsic back muscles and lie in a tight corner between the transverse processes and the pelvis.

Individual fibers run along the frontal plane and restrict lateral flexion and rotation at L4–S1. The fibers are also arranged in a variety of ways in the sagittal plane (Figs. 10.19 and 10.20), limiting flexion and extension (Yamamoto et al., 1990) and helping to prevent the lowermost free vertebra from gliding anteriorly (Bogduk, 2000).

Muscle activity can most likely assist the deep lumbar stability to a large extent by placing these ligaments under tension.

How Does this Affect Palpation?

The iliolumbar ligaments help to control lateral flexion and rotation, especially at L5–S1. This action must be considered when palpating during movement.

Some textbooks (Chaitow, 2001) recommend palpating these ligaments for diagnostic purposes.

Readers should form their own opinion as to whether diagnostically conclusive palpation through the thoracolumbar fascia and the erector spinae, 5–7 cm deep, is possible.

Thoracolumbar Fascia

The collagenous fibers of the thoracolumbar fascia define the appearance during the inspection of an anatomical specimen of this region. The significance of the sacroiliac (SI) joint has already been described in Chapter 9 on “Palpating the Posterior Pelvis.” It is mentioned there that the superficial parts of the gluteus maximus radiate into the fascia. The collagenous fibers of the latissimus dorsi and gluteus maximus cross over the midline when they do

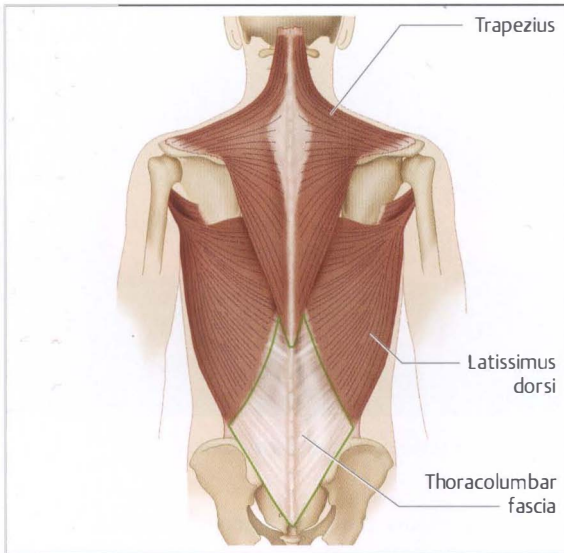


Fig. 10.21 View of the fascia with the latissimus dorsi.

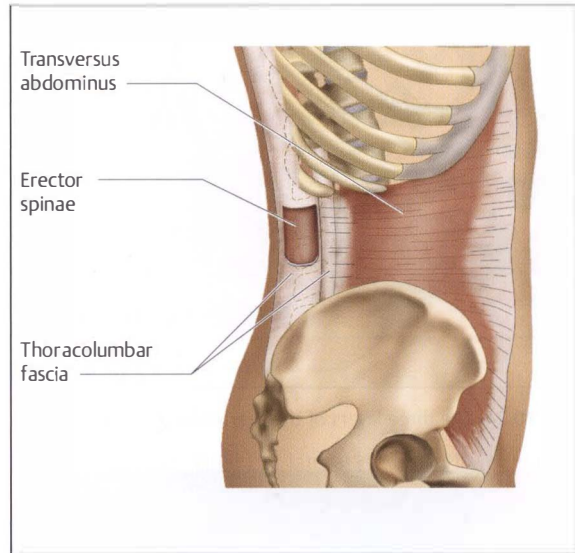


Fig. 10.23 Transversus abdominis

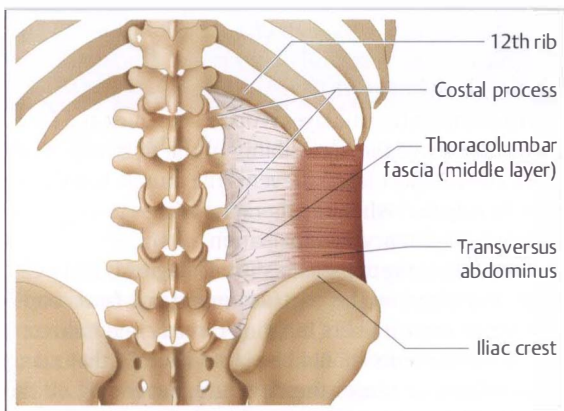


Fig. 10.22 Middle layer of the thoracolumbar fascia with transversus abdominis.

this and are connected diagonally with each other (see the section “Ilium—Posterior Superior Iliac Spine” in Chapter 9, p. 222).

More dynamizing structures are added to this in the lumbar region:

- Superficial layer: serratus posterior inferior.
- Middle layer:
 - transversus abdominis
 - internal oblique
 - quadratus lumborum
 - erector spinae.

The **superficial layer of the fascia**, the aponeurotic area of origin for the latissimus dorsi, extends from the thoracolumbar junction to the iliac crests, covering the entire lumbar spine and sacral areas. The latissimus aponeurosis turns into a solid ligamentous plate (Fig. 10.21). According

to Vleeming, the tensile loading capacity amounts to 500 kg and the plate is up to 1 cm thick.

The fibers within the fascia have a meshlike construction and do not only correspond to the continuation of the latissimus fibers that come from a superolateral position and pointing inferomedially. The fascia is at its widest at the level of L3, where it measures approximately 12 cm in width. It is narrowest at the level of T12.

Below T12, the fibers radiate into the fascial fibers on the contralateral side. They continue over the sacrum as the posterior sacroiliac ligament.

The **middle fascial layer** is also a solid aponeurosis. It stretches between the most inferior ribs, the L1–L4 costal processes, and the iliac crests (Fig. 10.22). It separates the back extensors from the quadratus lumborum. In contrast to the superficial layer, the middle layer appears to be a site of origin for the lateral tract muscles and the quadratus lumborum. The foundation for this strong tendinous plate is the aponeurosis, which is the site of origin for the transversus abdominis (Lanz and Wachsmuth, 2004a). The fibers from the internal oblique, in particular, radiate into this.

Barker et al. (2006) found in a study that the tension in the middle fascial layer significantly increases segmental stiffness and the resistance to flexion. According to their conclusions, tension in the fascia plays a significant role in segmental stability.

Richardson et al. (1999) also state that the multifidus and transversus abdominis provide basic stability for the lumbar spine (Fig. 10.23). They described the relationship between delayed activation of the transversus abdominis and lumbar symptoms.

The muscle is normally activated approximately 4 milliseconds before the trunk or the limbs start moving. Core stability is first built up before proceeding with

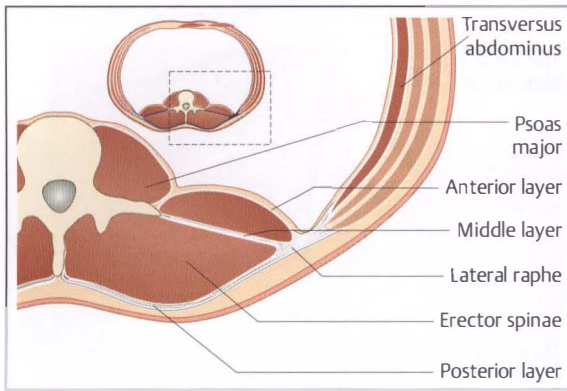


Fig. 10.24 The three layers of the thoracolumbar fascia.

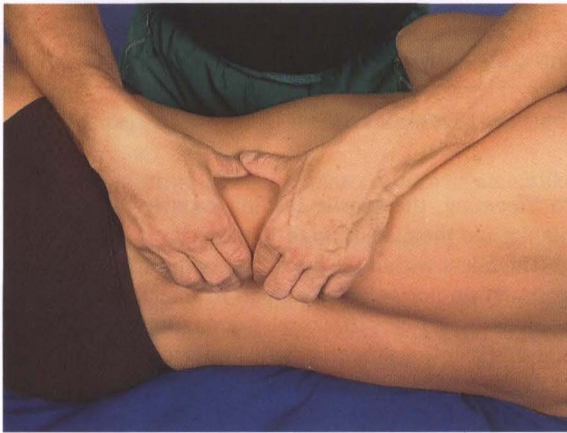

Fig. 10.25 Lumbar functional massage.

further action. The muscle is activated too late in patients suffering from back pain. Based on these results, Richardson developed an exercise program that is currently a source of discussion and used for therapeutic approaches.

Both layers of the thoracolumbar fascia are connected immediately lateral to the back extensors at the lateral raphe (Fig. 10.24). Both of the fascial layers and the serratus posterior inferior form an osteofibrous channel with the vertebral arch and the processes. This channel is the guiding sheath for the erector spinae. The anatomy of this can be recognized by looking at the loose connective tissue superior to the sacrum positioned between the back extensors and the fascia. The osteofibrotic guiding sheath bundles up the back extensors and holds these muscles on the vertebral column when the muscles contract.

How Does this Affect Palpation?

The back extensors protrude more than the spinous processes. Together with the firm sheath of fascia on both sides, they form a type of depression over the row of spinous processes. The depth of this can differ depending on the lumbar lordosis form and the bulk of the back exten-

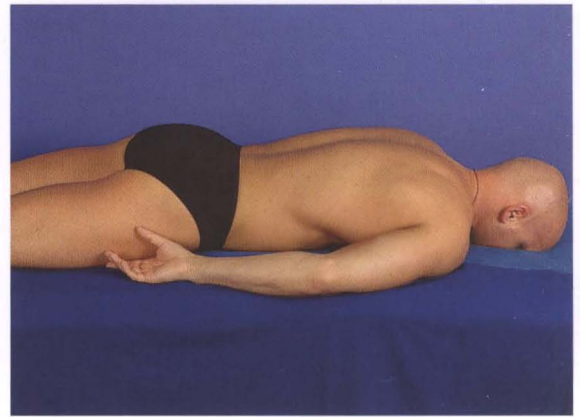


Fig. 10.26 Suitable SP in the prone position.

sors. This means that the spinous processes can be reached here quite easily.

The osteofibrotic sheath turns the back extensors into a uniform muscle packet. Its medial side can be completely pushed away from the row of spinous processes and displaced laterally. This characteristic is taken advantage of in the different classical massage and functional massage techniques (Fig. 10.25).

The compact fibrotic layer is up to 1 cm thick and raises a question about the accessibility of the muscular structures. The compact fascia prevents the muscle from being directly palpated when the therapist wishes to assess the muscles' consistency with palpation.

The positioning of patients during diagnosis and treatment is affected by the compact superficial fascia and a number of muscle fibers merging directly and indirectly into it. The patients should be placed in an SP that maximally relaxes or tenses the structure, depending on the aim. The minimal requirements for relaxation in the lumbar region are the physiological lordosis and not allowing the arms to be fully raised in the prone (Fig. 10.26) or side-lying positions.

Detailed Anatomy of the Muscles

Only the muscles that are important for the palpation of the lumbar region will be described in the following text:

- Latissimus dorsi.
- Intrinsic back muscles—medial tract.
- Intrinsic back muscles—lateral tract.
- Action of the lumbar muscles.

Latissimus Dorsi

This muscle was ontogenetically a gill muscle. The site of origin of the latissimus dorsi has been relocated quite inferiorly. As a consequence, its innervation from the thoracodorsal nerve (C6–C8) was relocated with the muscle.

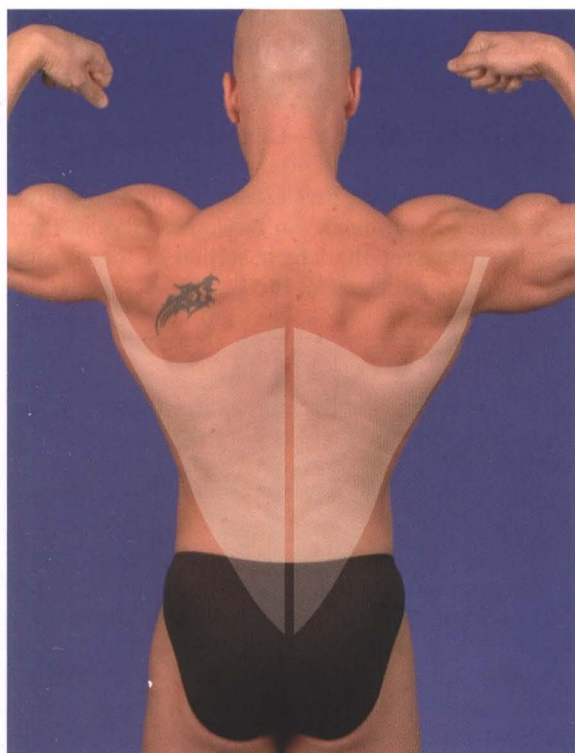


Fig. 10.27 Latissimus dorsi on an athlete.

The nomenclature for its sites of origin is divided into thoracic, lumbar, iliacal, costal, and scapular areas. Its aponeurosis of origin is identical to the superficial layer of the thoracolumbar fascia (Fig. 10.27). The thoracic site of origin is generally stated to be at the T7–T8 level, but can vary greatly. The iliacal origin is likewise very variable. The side edge of the site of origin is generally sought at the level of the most superiorly protruding part of the iliac crest (Lanz and Wachsmuth, 2004a), though it may also be found further medial or lateral.

The 3–4 cm-wide and approximately 8–10 cm-long tendon of insertion travels together with the teres major's tendon of insertion toward the crest of the lesser tubercle at the humerus.

Its function is not limited to the open kinematic chain; it also acts as a strong adductor to move the body around a fixed point in a closed chain (e.g., when a person supports themselves on parallel bars). Together with the teres muscles, it decelerates the forward swing of the arms during gait. Activity in the latissimus dorsi dynamizes the superficial layer of the thoracolumbar fascia and can therefore affect lumbar stability.

How Does this Affect Palpation?

Aside from toned and very slender people (Fig. 10.27), most people have a thin latissimus dorsi. This means that the muscle belly rarely presents itself with a clearly

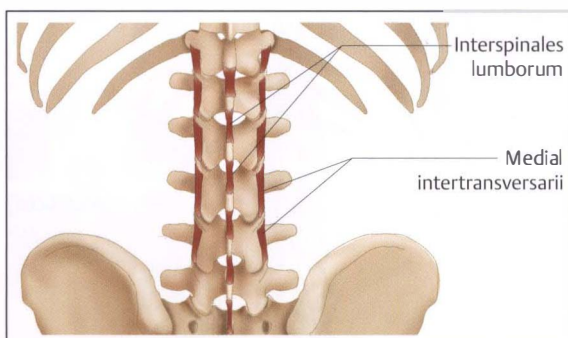


Fig. 10.28 Medial tract

definable contour. Only the lateral edge can be palpated in the thoracic area during contraction (see the section “Tips for Assessment and Treatment” in Chapter 11, p. 310).

Intrinsic Back Muscles—Medial Tract

The medial tract consists of sections that run over one segment and sections that are multisegmental. It lies close to the vertebral column in the triangular depression between the spinous and transverse processes (Fig. 10.28). The muscles originate and insert into the processes of the lumbar vertebrae. The posterior aspect of the sacrum is the only exception here. The medial tract muscles are mostly covered by voluminous muscle bellies and the aponeuroses of origin for the muscles in the lateral tract (longissimus). The muscle groups belonging to the medial tract are typically innervated by the medial branch of the dorsal rami arising from the spinal nerve that belongs to the segment.

The small muscles mostly run over **one segment**. They can finely position the lumbar vertebrae and assist in the development of the necessary axial compression for the approximation of vertebrae with the use of tissue strength. The transversospinales appear to be functionally more important than the straight system. Lanz and Wachsmuth (2004a, p. 86) have commented on this: “The transversospinales muscle strand represents the most important tensile system in the vertebral column.”

The muscular sections of this system extend over three to six segments and are most clearly developed in the lumbar region. They are labeled the multifidus lumborum (Fig. 10.29). The origin can be followed to the third sacral vertebra in the space between the median sacral crest and the intermedial sacral crest. As described in the section “Sacrum—Insertion of the Multifidus” in Chapter 9 (p. 225), contractions in this muscle can also be palpated there. In Lanz and Wachsmuth (2004a, p. 89) it is further said: “Its mass of flesh represents a slab oriented in the sagittal plane. Its side surfaces are rounded and appear as a swelling bulge as soon as the aponeurosis of origin for longissimus is separated from the spinous processes.”

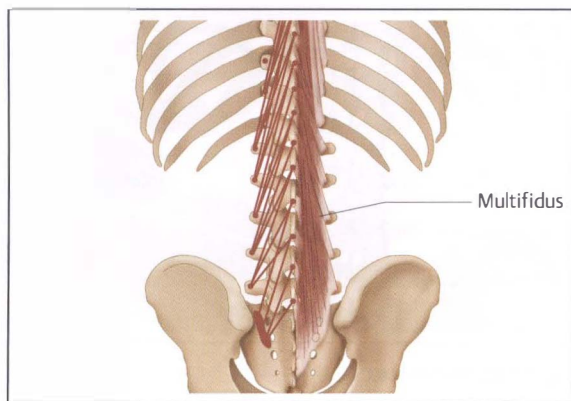


Fig. 10.29 Multifidus lumborum

How Does this Affect Palpation?

The sections of the longissimus are quite thin and tendon-like in the lower lumbar and sacral regions. The multifidus can therefore be palpated very well and is sometimes visible directly paravertebrally (approximately 1.5 cm adjacent to the spinous process) from the sacrum up to the level of L3 (Fig. 10.30). It becomes more difficult superior to this as the covering muscle becomes thicker.

The advantage of the muscle being palpable becomes obvious when the stabilizing function of the multifidus is being trained. The patient can attempt to selectively contract the multifidus using palpation for feedback. Hoch-

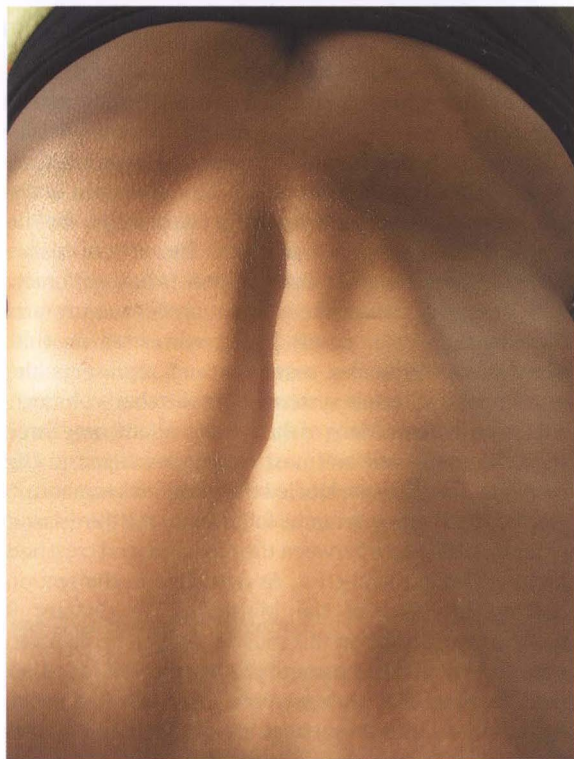


Fig. 10.30 Activity in the multifidus.

schild (2001, p. 37) labels the multifidus as the “key muscle for the segmental stabilization of the lumbar spine.”

Intrinsic Back Muscles—Lateral Tract

The lateral tract of the back extensors is made up of two strong individual muscles in the lumbar region. These muscles represent the largest section of the palpable paravertebral muscles (Fig. 10.31):

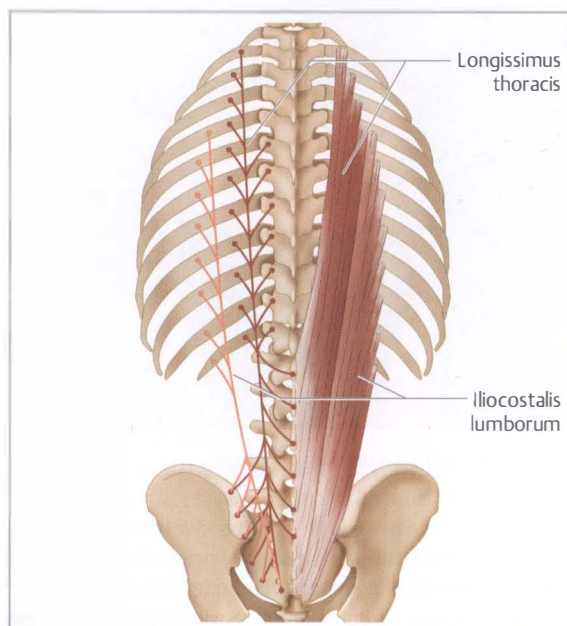


Fig. 10.31 Lateral tract of the intrinsic back muscles.

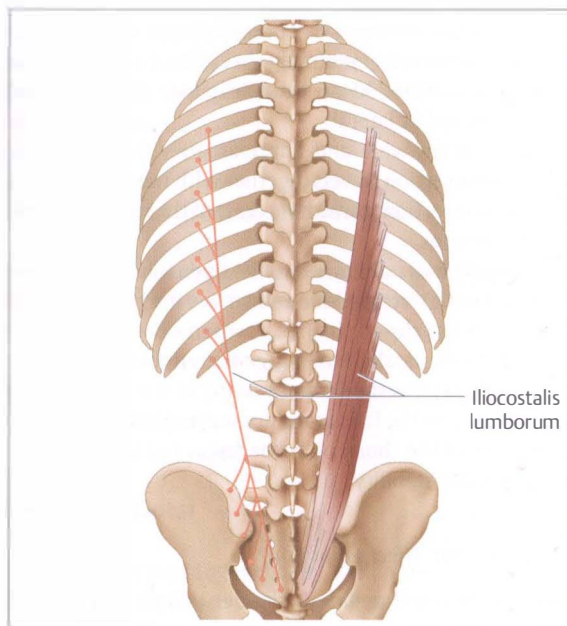


Fig. 10.32 Iliocostalis

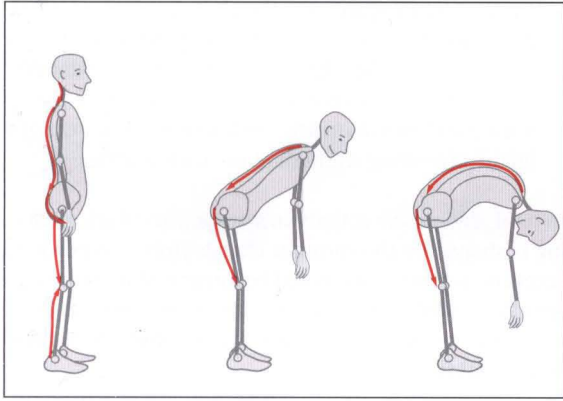


Fig. 10.33 Bending the trunk forward / slings of muscles shown during trunk flexion. The thoracolumbar fascia and the posterior ligaments carry the weight of the upper body in the right figure.

- Longissimus (lumbar part, thoracis, cervicis, capitis).
- Iliocostalis (lumbar part, thoracic part, cervicis).

The layout of both of these lateral tract muscles in the individual sections of the vertebral column results in the muscles being divided into many sections. The longissimus is the only muscle that extends with one section to the skull. This muscle group is typically innervated by the lateral branch of the dorsal rami arising from the spinal nerve that belongs to the segment.

The **longissimus** is found more medial and inserts with spikes only. These spikes are noticeable on the ribs. It lies on top of the medial section of the multifidus. It forms a thin tendinous plate in the lower lumbar region, which allows activity in the multifidus to be felt directly adjacent to the vertebral column. Its origin extends over the posterior surface of the sacrum between the intermedial sacral crest and the lateral sacral crest.

The **iliocostalis** (Fig. 10.32), on the other hand, is located lateral and more superficial. Its origin extends from the lateral aspect of the sacrum to the iliac crest, covering the medial section of the quadratus lumborum. The muscle originates and inserts further onto the ribs and the rudiments of the ribs only. Both layers of the thoracolumbar fascia meet lateral to the muscle belly.

The Actions of the Lumbar Muscles

Bilateral activity in the back extensors controls and moves the trunk in the sagittal plane. The back extensors tense quickly on both sides when the trunk is displaced anteriorly and work eccentrically until approximately 60° flexion (Fig. 10.33). The gluteus maximus helps to control **trunk flexion**. The back extensors do not have any active function beyond 60° flexion. The back extensors' passive resistance to stretch, the thoracolumbar fascia, and the li-

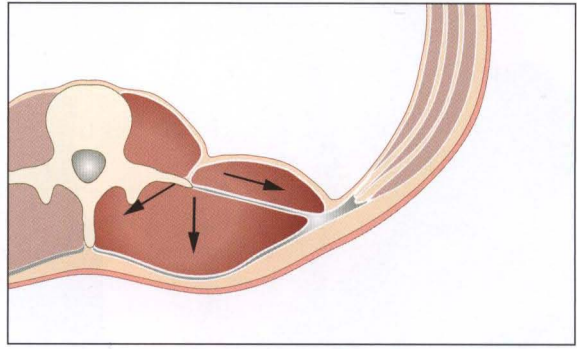


Fig. 10.34 Pumping up the thoracolumbar fascia.

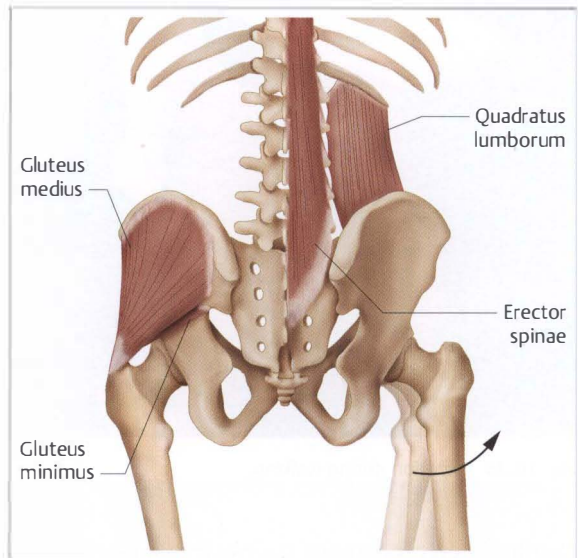


Fig. 10.35 The synergism of the back extensors—small gluteal muscles. The trunk is displaced to the left, the right trunk muscles and the left gluteals work together.

gaments found posterior to the movement axis now take over the action of stabilizing the trunk.

Activity, especially activity arising from the medial tract and the tension in passive structures, results in a build up of axial compression. This should be seen as the approximation of the vertebrae using tissue strength. This activity increases the stability in the vertebral column, which is intrinsically a mobile chain. The psoas stabilizes anteriorly when the trunk is extended, especially in the upper lumbar section.

One of the most important functions of the intrinsic back muscles is to tighten up the **thoracolumbar fascia** from inside outward (personal communication, Vleeming). This can be compared with pumping up a bicycle tube (Fig. 10.34) and is achieved when the muscle belly becomes thicker during contraction. This illustrates the therapeutic use of hypertrophic back extensors.

The intrinsic back muscles are only slightly active in the **upright standing** position when the body weight is

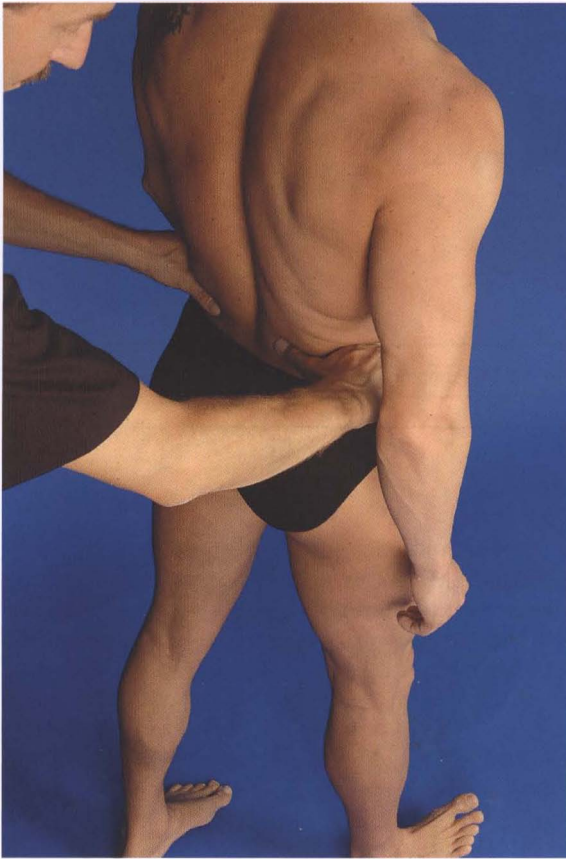

Fig. 10.36 Palpation during walking.

distributed evenly between the two legs. It is only in the thoracic region that constant activity is necessary to prevent falling. This is due to the weight of the thorax always pulling the vertebral column into flexion (Klein-Vogelbach, 2000).

Shifting the body's weight from both legs onto one leg, for example, onto the left leg, results in unilateral activity in an entire synergy on the right side (Fig. 10.35):

- Erector spinae.
- Quadratus lumborum from the deep abdominal muscle group.
- Internal and external obliques from the side trunk wall muscles.

This activity in the muscles aims to prevent the pelvis from lowering on the right side. This occurs in cooperation with the small gluteals on the weight-bearing side (on the left here).

The back and the lateral trunk wall muscles have several functions during walking:

- They provide the impulse for walking (according to Gracovetsky, 1988) using rotation and lateral flexion. Alternating concentric (start of the swing phase) and eccentric (end of the swing phase) activity causes lateral flexion in particular.

- They act as antagonists to the abdominal muscles. The arms swing during walking and give the upper body a rotational impulse. This movement has to be decelerated by the abdominal muscles. The tendency to flex during abdominal muscle contraction is counteracted by the extending strength of the back muscles.

In total, the muscle activity in standing and during walking is shaped by the constant change from concentric to eccentric activity. This should be integrated into the therapeutic concept for stabilizing treatment: vertical position and alternating activity with impulses for rotation and lateral flexion.

How Does this Affect Palpation?

The energy-efficient contractions in the back and trunk wall muscles during weight-shift in standing and walking can be palpated bilaterally above the iliac crests (Fig. 10.36). In cases of central nervous system disorders, such as hemiplegia, the eccentric activity needed to lower the pelvis at the end of the swing phase is impaired.

It is technically very simple to palpate activity in the muscles. Both hands are placed directly superior to the iliac crests using a pinch grip and push slightly into the lateral trunk wall. The therapist then follows as the patient walks with normal speed. Through the alternating muscle activity, the hands feel more or less pressure and the changing consistency between soft and very firm.

Basic Biomechanical Principles

The **lumbar segment** is a kinematic chain consisting of three links—one intervertebral disk and two zygapophysial joints. The three components all affect each other.

In a healthy segment, the axes for movement are found in the disk (Fig. 10.37). This results in little translational movement and a lot of tilting. A loss of height in the intervertebral disk shifts the axes and more shear forces develop (White and Panjabi, 1990).

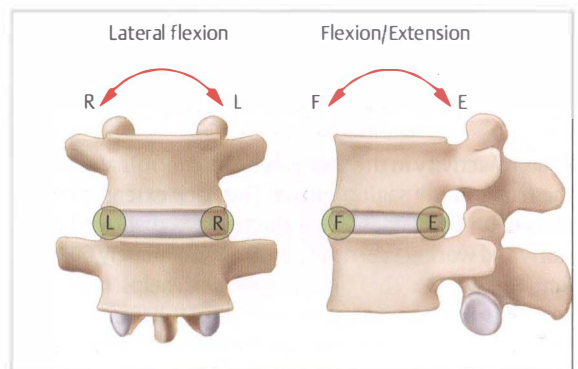


Fig. 10.37 Position of the movement axes.

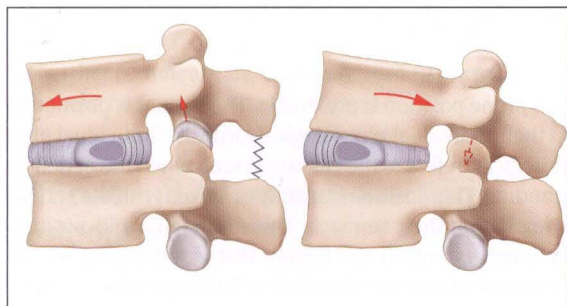


Fig. 10.38 Divergence and convergence.

Symmetrical Movement

The joint surfaces glide together (convergent movement) during extension (extension, lordosis) and away from each other (divergent movement, Fig. 10.38) during flexion (flexion, flattening out of the lordosis).

Asymmetrical Movements

Lateral flexion is inevitably combined with rotation in all sections of the vertebral column. Rotation likewise always occurs with simultaneous lateral flexion. This is known as a coupled movement. The direction of the associated movement in the lumbar spine changes according to

whether the vertebral column is positioned in flexion or extension.

Coupled and Combined Movements

When the functional section from T10/T11 to L5/S1 is flexed, lateral flexion is automatically accompanied by an ipsilateral axial rotation:

- Flexion and lateral flexion to the right with rotation to the right (Fig. 10.39).
- Flexion and lateral flexion to the left with rotation to the left.

In the extended position (e.g., physiological lordosis), lateral flexion is automatically accompanied by contralateral axial rotation. This applies to all segments:

- Extension and lateral flexion to the right with rotation to the left (Fig. 10.40).
- Extension and lateral flexion to the left with rotation to the right.

Movements are always coupled in the same direction in older patients.

This coupling of movements occurs automatically during active and passive movements unless the therapist decides to consciously position the lumbar spine differently. Every other combination of rotation and lateral flexion is

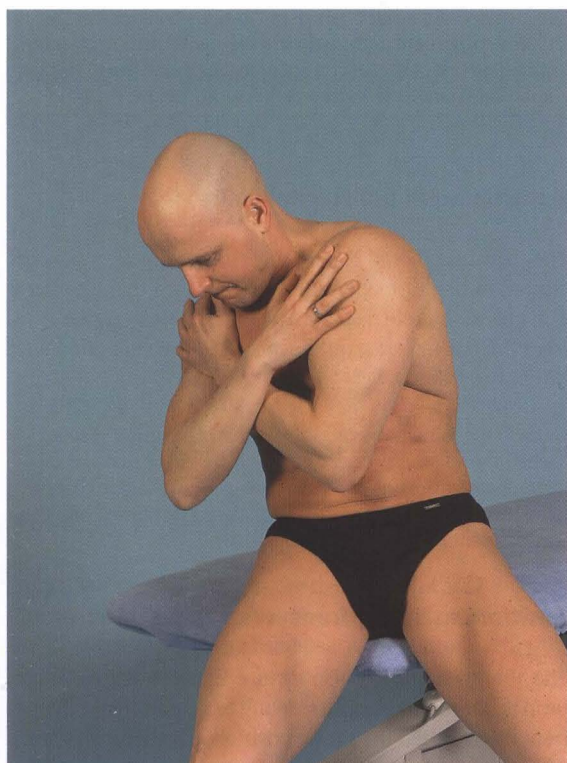


Fig. 10.39 Coupled position in flexion.

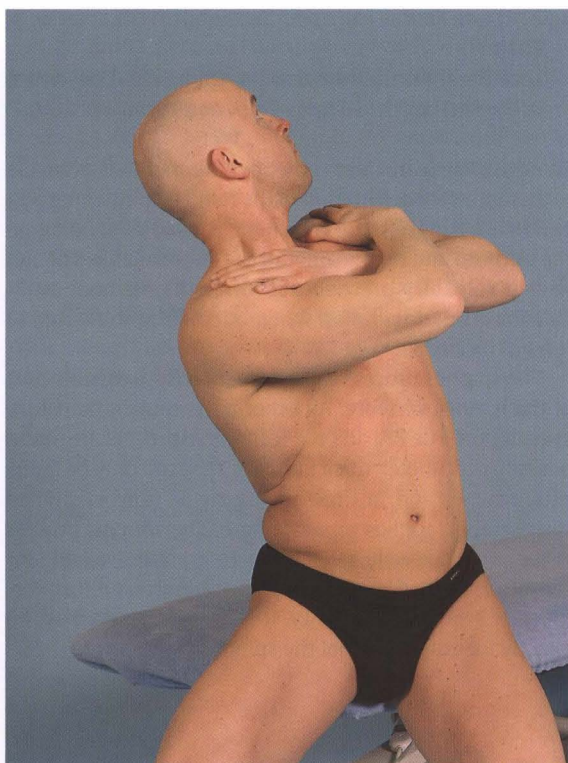


Fig. 10.40 Coupled position in extension.

labeled as combined, or not coupled. Manual therapy uses combined positioning in the vertebral column to lock a joint as firmly as possible.

How Does this Affect Palpation?

Symmetrical and coupled movements can be used to assess segmental movement and to diagnose a restriction in mobility (see the section “Local Segmental Mobility Using Coupled Movements” below, p. 267).

Summary of the Palpatory Process

Determining the exact level of an affected segment is vital for some tests and treatment techniques. Therapists can only orient themselves in the lumbar region when the spinous processes have been palpated correctly. This is, and will always be, no simple task, even after the therapist has gained some experience. The therapist should therefore know how to approach the palpation of the lumbar spinous processes. It helps to be able to visualize the expected form and consistency of structures and to use a couple of aids to confirm the correct localization.

To correctly and specifically locate lumbar structures, several techniques are needed that have already been described in Chapter 9:

- Locating the iliac crest, described in “Palpatory Techniques for Quick Orientation on the Bones” (Chapter 9, p. 214) and “Local Palpation Techniques” (Chapter 9, p. 221).
- Locating the posterior sacroiliac spine (PSIS), described in the section “Local Bony Palpation” below, p. 260).

There are vague but also rather precise methods available to therapists for orientation in the lumbar spine using palpation. The appropriate technique is used depending on the purpose and on the amount of time available. The following palpatory procedure involves the methods available for quick orientation when attempting to locate the level of L3 and S1.

The spinous process is the only directly accessible part of the lumbar vertebra. All other parts remain palpatory speculation. The ZAJ and the transverse process are found beneath centimeter-thick muscles. They can only be indirectly reached and, at times, pain may be provoked when the therapist applies pressure here. The spinous process is therefore the only reliable starting point available for the localization of levels, pain provocation, and the assessment of segmental mobility. It is therefore necessary to exactly identify and label the spinous process.

Starting Position

The prone position is preferable. The patient is positioned in their individual physiological lordosis. “Individual physiological” refers to the curvature seen when the patient is standing. This position is mainly achieved with the patient lying flat on their stomach. This results in a mid-position between extension and flexion that is suitable for the assessment of segmental mobility. Padding underneath the abdomen and pelvis flex the lumbar spine, and the spinous processes are moved further away from one another. This opens up the interspinous space, and the posterior soft tissues (supraspinous ligament and multifidus) are placed under more tension. The palpation tends to become more difficult depending on the amount of padding used.

Positioning the lumbar spine in an extreme lordosis, for example, with the patient supporting themselves on their elbows, approximates the spinous processes to an extent that makes it almost impossible to differentiate individual spinous processes to determine the level of a structure.

Tip: When in the prone position, it is generally not recommended to place padding underneath the abdomen before starting to palpate. It will not always facilitate localization of the spinous processes. The interspinous spaces are very narrow and extremely difficult to differentiate from one another. A narrowing of the interspinous spaces by additionally increasing the lordosis before starting palpation is therefore to be avoided. All other types of patient positioning alter the typical movement pattern during segmental tests such as the springing test or the test for rotation (see the section “Test for Rotation [Transverse Vertebral Pressure]” below, p. 264).

Positioning in the Frontal Plane

The therapist should ensure that the patient's pelvis is not shifted to one side when they are lying on their stomach. The pelvic shift corresponds to a lateral flexion that is initiated from inferior and particularly involves the lower lumbar segments.

Tip: The neutral prone position in this plane is not essential when the spinous processes are only being located and differentiated from one another. A non-neutral position changes the movement pattern when palpation is combined with the assessment of segmental mobility.

Positioning in the Transverse Plane

The therapist should also ensure that the vertebral column is not rotated before starting to palpate. Once the patient has adapted the prone position, the therapist checks whether both of the anterior superior iliac spines (ASISs) are in contact with the treatment table or are found with

at least the same distance to the table. Rotation in the pelvis can be corrected if necessary.

Further comments and figures related to the prone position can be found in Chapter 8.

Difficult and Alternative Starting Positions

Neutral Side-lying

The most painful side is usually positioned uppermost for assessment and treatment. The therapist must ensure that the entire vertebral column is positioned with its natural or individually determined curvature. The presence of lateral flexion should be corrected using padding.

Vertical Body Positions

The sitting or standing SP always compounds the palpation of the spinous processes or the deep-lying structures due to activity in the muscles. The advantage of these SPs is the greater variety of coupled movements possible compared with the prone position. When the spinous processes can be palpated well in sitting, accurate information regarding segmental mobility can be gained.

Please refer to Chapter 8 for further information and figures.

Palpation Techniques

Overview of the Structures to be Palpated

Projections are used for orientation by defining the level of a structure and using connecting lines in the prone SP:

- Connection between the iliac crest and the PSIS.
- Lumbosacral cross.

Local bony palpation is used for the localization of the lumbar spinous processes:

- Palpating from an inferior position via the S2 onto L5 spinous processes.
- Locating additional lumbar spinous processes.
- Palpating from a superior position via the T11 spinous process.

Orienting Projections

Only a few reference points are needed to locate a level relatively precisely when the therapist wishes to quickly orient themselves at the lumbosacral junction.

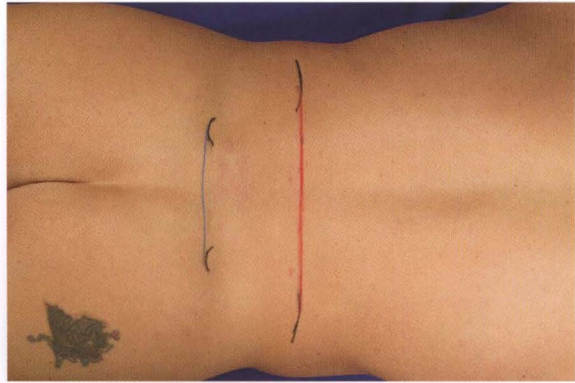


Fig. 10.41 Connecting the iliac crests and the PSISs.

Connection between the Iliac Crest and the Posterior Sacroiliac Spine

The iliac crest is located on one side using one of the two previously described techniques (Chapter 9, p. 214 or p. 221). The technique variation using the perpendicular palpation from superior is recommended. The most superior point on the iliac crest is marked on the skin to secure the palpation results. This step is repeated on the other side.

Both marks are then connected. An interspinous space is sought at the point where the connecting line meets the body's mid-line.

The specifications regarding the spinous process that will be found here are documented very differently in the literature. For example, Kapandji (2006) states that the line connecting both iliac crests intersects the area between L4 and L5 on a radiograph. My experience shows that the most common result when palpating on the male pelvis is the lower edge of the L3 spinous process.

The next step involves locating the PSIS and marking its most inferior boundary (lower edge) on the skin. The techniques for this have been described in Chapter 9, page 222. The lower edges of both PSISs are connected with a line. This line always passes over the S2 spinous process (Fig. 10.41).

Tip: The individual and gender-related differences in the height of the anatomical pelvis explain the large variety seen in the detected height of the iliac crests. Males generally have a higher and more slender pelvis. This is the reason why the L3 spinous is most likely to be found here. The L4 spinous process is often reached in females when this technique is used because the female pelvis is shorter and wider. This technique is quick to carry out but does not deliver particularly reliable results.

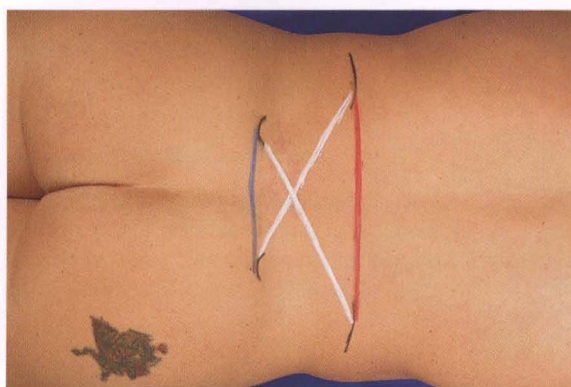

Fig. 10.42 Lumbosacral cross

Lumbosacral Cross

A line is drawn between the right iliac crest and the left PSIS and another line between the left iliac crest and the right PSIS (Fig. 10.42). In most cases, the point where these two lines meet indicates the position of the L5 spinous process. This quick method for orientation delivers more reliable results than locating the level by connecting the two iliac crests.

Local Bony Palpation

The aim is to correctly locate the lumbar spinous processes. This is achieved by following the steps below:

1. Coming from an inferior position via the S2 spinous process.
2. Locating additional lumbar spinous processes.
3. Coming from a superior position via the T11 spinous process.

All spinous processes of the functional section of the lumbar spine will be located. This extends from T10/T11 to L5/S1.

Palpating from an Inferior Position via the S2 Spinous Process

Locating the lumbar spinous process from an inferior position is the most common and reliable method. The reliability of the palpatory findings, especially for L5 and L4, depends on the exact localization of the PSIS and the S2 spinous process. This has been described in detail in Chapter 9, page 224. The palpation is now continued in a more superior direction.

Step 1: The inferior edges of both PSISs are located. The line connecting these two points marks the position of S2 (Fig. 10.43). This rudimental spinous process is usually perceived as a significant elevation when palpated. The

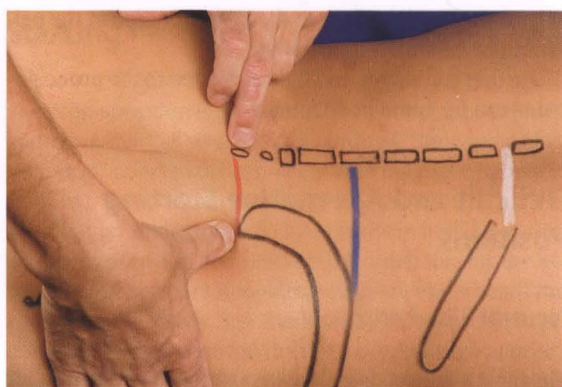


Fig. 10.43 Localization of the S2 spinous process.

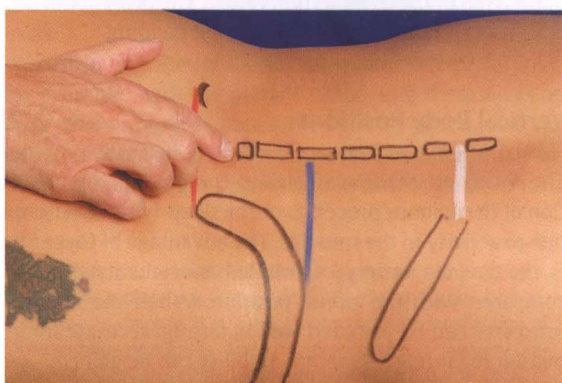


Fig. 10.44 Localization of the S1 spinous process.

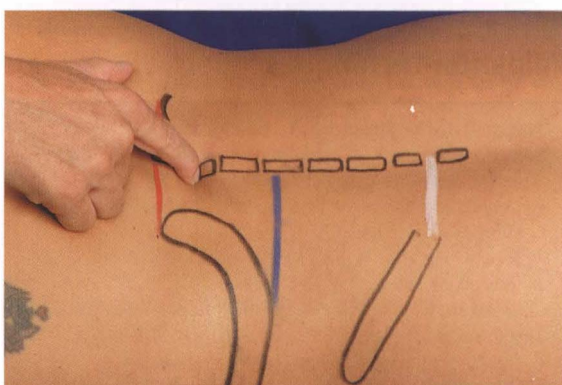


Fig. 10.45 Inferior edge of the L5 spinous process.

technique used here is where the finger pads palpate using slightly circulating movements.

Step 2: The finger pads slide approximately 1 cm superiorly and search for a small, rounded elevation that represents the remainder of the S1 process (Fig. 10.44). In doing so, the fingers move anteriorly down a slanting slope. A large amount of variation is seen in S1; everything is possible. S1 can be as large as S2, it can be only a minimally palpable elevation, or be completely absent.

Step 3: The L5 spinous process is found approximately one finger-width (patient's index finger) superior to S1. Its lower edge is reached by sliding the finger pads superiorly over the slanting sacrum until the tips of the fingers come across an explicitly hard object (**Fig. 10.45**). The inferior edge of L5 is mostly felt to be a step superior to the L5–S1 interspinous space.

Tip: This palpatory step is imperative and must be confirmed through further information and using palpatory aids.

Comments on Pathology

In cases of severe spondylolisthesis in L5–S1, a local increase in the lordosis with the formation of a step can be palpated between L5 and S1 on slim patients (ski jump phenomena; Wittenberg et al., 1998). This palpatory result can be reached in the prone or standing SP. **Caution:** these conclusions may not be reversed! Not every palpated step has to indicate the presence of a spondylolisthesis.

Confirming the Palpation Using the Shape and Size of Structures

Based on the anatomy described, it is normally expected that the L5 spinous process has a smaller and rounded shape that juts out posteriorly. The L1–L4 spinous processes are very long (superior–inferior dimensions). Despite this anatomical knowledge, it may be confusing and difficult to locate L5, especially when the S1 spinous process has a distinct form. In this case, its shape and size are similar to L5.

Confirmation Using the Assessment of End Feel

Using anteriorly directed pressure to differentiate between L5 and S1 is diagnostically conclusive. The medial side of the hand is placed on the point where the therapist assumes S1 to be. The other hand is placed on top of it (**Fig. 10.46**). The therapist then pushes their hand in an anterior direction using slow oscillations. If pain is not provoked by this, the therapist pushes down firmly one more time to clearly assess the posteroanterior end feel.

The same maneuver is performed over the point where the therapist assumes L5 to be. The thumb is first placed over the point to emphasize the pointed spinous process (**Fig. 10.47**). The thumb is then reinforced using the medial side of the other hand or the thenar eminence (**Fig. 10.48**). Rhythmical posteroanterior pressure is then reapplied and finishes with the end feel being assessed by firm pressure.

The results of both of the posteroanterior pushes are now compared. It is expected that S1 will only minimally yield to pressure and that its end feel will be almost hard. L5 usually yields significantly more to pressure and has a firm-elastic end feel.

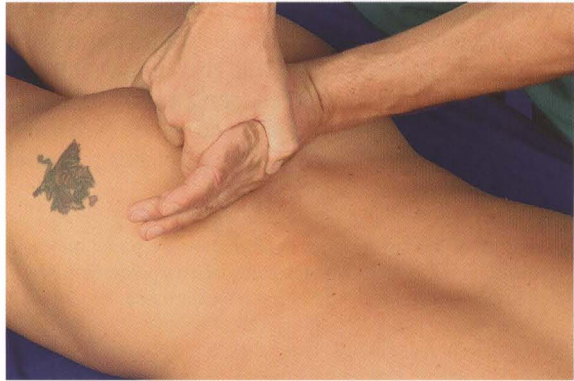

Fig. 10.46 Posteroanterior pressure on S1.

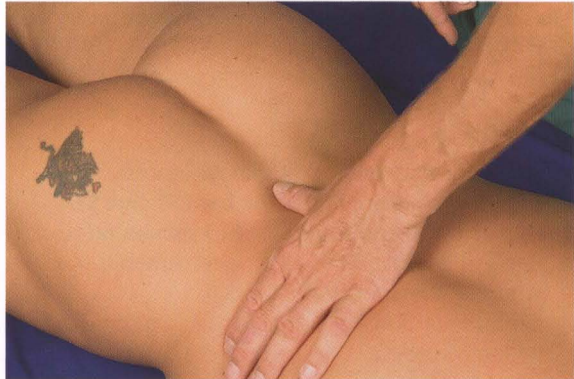

Fig. 10.47 Assessment of end feel at L5—phase 1.

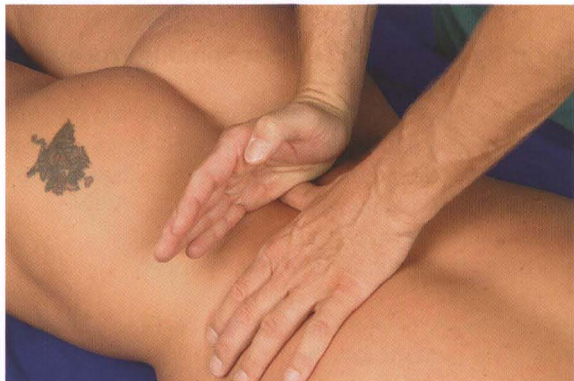

Fig. 10.48 Assessment of end feel at L5—phase 2.

Tip: Naturally, this differentiation technique should not be performed if the therapist suspects it will provoke pain.

Confirmation Using Movement

Another option is to feel the way L5 moves when posteroanterior pressure is applied. The therapist starts by searching for the assumed position of the L5/S1 interspinous space with their finger tip. Both of the neighboring spinous processes should be felt. The thumb or the hypothenar eminence is then used to apply pressure to the

superiorly located spinous process. It is expected that the superiorly lying spinous process moves anteriorly and the inferior spinous process stays still. This attempt at differentiation between the assumed localization of S1 and S2 results in no movement. This technique is also used to differentiate between the other lumbar spinous processes and is also illustrated below.

Tip: Both of the last tests for confirmation are based on the presumption that L5 moves anteriorly when a posteroanterior pressure is applied and that S1 remains immobile. Regardless of how helpful and informative both of these tests may be, some inaccuracy remains. These tests are not useful when variations in the anatomy are present in terms of hemisacralization or restriction in segmental movement at L5/S1. In this case, the position of L5 can only be confirmed by comparing its size to L4 and L3. These spinous processes are usually significantly longer than L5.

Summary

1. Locate the PSIS and the S2 spinous process.
2. Palpate in a superior direction from S2 onto S1.
3. Palpate the inferior edge of the L5 spinous process.
4. Confirm its position using a posteroanterior pressure with the assessment of end feel.
5. Confirm its position using posteroanterior pressure with movement.
6. When necessary, confirm its position by locating the first long spinous process (L4).

Locating Additional Lumbar Spinous Processes

The other lumbar spinous processes can be sought after the L5 spinous process has been located as correctly as possible. The therapist can be sure that they have located the respective spinous process correctly by:

- Examining its shape and size.
- Using movement to confirm the position.

As has already been mentioned, the L1–L4 spinous processes are rather broad and have an extremely irregular shape with indentations along their posterior aspect, giving them an undulating appearance. The waves formed by the spinous processes are found on the sides and posteriorly and imitate the presence of an interspinous space. To precisely locate the interspinous space, the therapist palpates along the side of the spinous process until a gap becomes apparent. It is less reliable to palpate posteriorly as the supraspinous ligament is solid, fibrotic, and may be tensed, preventing the therapist from gaining access to the expected gap.

Step 1: The inferior edge of L5 is marked using a short line. The therapist palpates to the side of this in a superior direction. The space between the L4 and L5 spinous processes is felt after a few millimeters (Fig. 10.49). For

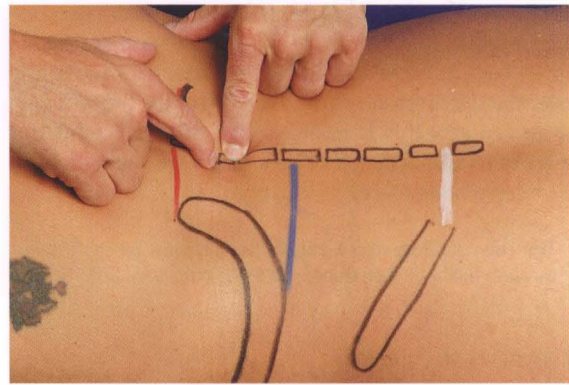


Fig. 10.49 Palpating L4/L5

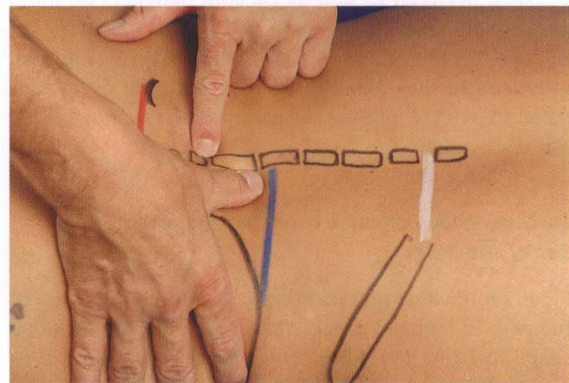


Fig. 10.50 Palpating L3/L4

good measure, the finger should be kept on the inferior edge of L5 for the moment. If the therapist is unable to find the inferior edge of L4, they can always start the procedure again from L5. The suspected location of the inferior edge of L4 is marked.

Step 2: The same technique is used to locate the L3 spinous process: the finger remains over L4/L5 and the next superiorly lying interspinous space is sought (Fig. 10.50). All further spinous processes can be found using this method.

Tip: Therapists should not let the length of the L4–L1 spinous processes unsettle them. They should trust their instincts.

Step 3—Confirmation with movement: To confirm the correct localization of an interspinous space, the therapist moves the segment. The movement can be felt by the palpating finger. An interspinous space has been correctly located when the superiorly lying spinous process moves and the inferior spinous process remains immobile. This is achieved by placing a finger pad posteriorly over the interspinous space. The confirmation of the L3/L4 interspinous space is demonstrated in Fig. 10.51. The thumb pad applies oscillating posteroanterior pressure to the L4 spinous process superior to the position where the therapist assumes the interspinous space to be. The pal-

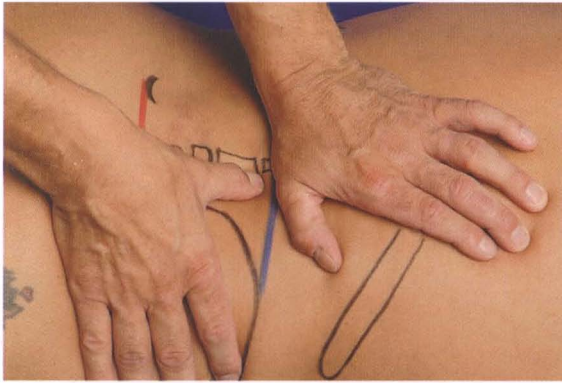


Fig. 10.51 Confirmation with movement.

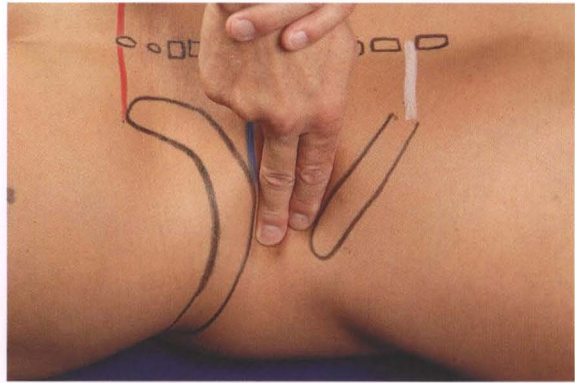


Fig. 10.52 Iliac crest and the 12th rib.

palpating finger pad can feel the superior spinous process moving up and down in the interspinous space.

Tips: The posteroanterior push does not have to be particularly strong. It is the returning movement, not the downward movement, that can be felt best. The posteroanterior push should therefore be released very quickly to ensure that the tip of the palpating finger can gain clearer information. When the anatomy of a patient makes localization difficult, this technique may have to be repeated several times to confirm the correct palpation of the interspinous space. It is helpful to mark the superior and inferior edges of the spinous process so that the therapist can always proceed from a confirmed point. All spinous processes in the functional section of the lumbar spine can principally be found and marked on the skin using this method.

The thoracolumbar junction is reached when the size of the spinous processes changes abruptly. The spinous processes are more pointed again superior to T12.

Palpating from a Superior Position via the T11 Spinous Process

Locating the T11 spinous process via the 12th rib is ideal for quick orientation in the thoracolumbar region. The tips of the 12th rib hang freely in the posterolateral trunk wall.

Step 1: To find the 12th rib, the therapist first orients themselves on the lumbar back extensors and then moves laterally in the space between the iliac crest and the inferior costal arch. This space usually measures only two finger-widths (Fig. 10.52).

Step 2: A perpendicular technique is used next to confirm the position of the iliac crest (Fig. 10.53). The therapist then turns their palpating fingers in a superior direction, attempts to locate the inferior edge of the 12th rib (Fig. 10.54), and encounters a very firm structure relatively quickly.

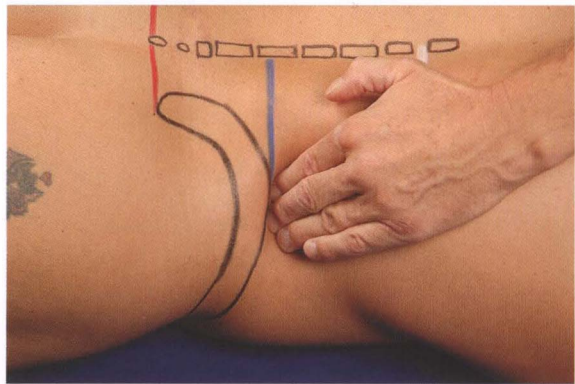


Fig. 10.53 Confirming the position of the iliac crest.

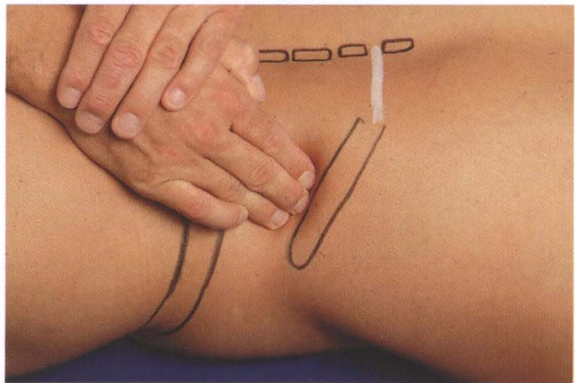


Fig. 10.54 Locating the 12th rib.

Tip: It is important that the therapist palpates rather medially, near the back extensors. The therapist will palpate the 11th rib if they palpate too laterally. On pressure, the 12th rib does not have the typical hard osseous consistency. As already mentioned, this rib is relatively mobile and hangs freely in the trunk wall, making it more mobile than the ribs with direct or indirect contact to the sternum (1st–10th ribs). The 12th rib must be able to move out of the way of the iliac crest when extensive lateral flexion is being performed.

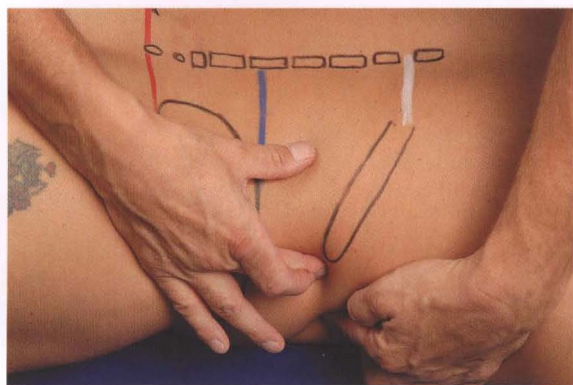


Fig. 10.55 Tip of the 12th rib.

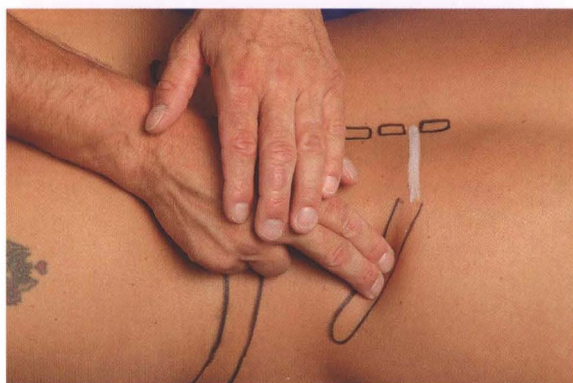


Fig. 10.56 Palpating in a medial direction.

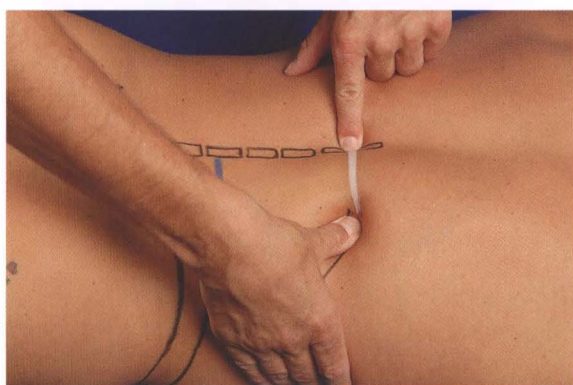


Fig. 10.57 Locating the level of the T11 spinous process.

Step 3: This step involves confirming the location of the 12th rib. The inferior edge of the palpated rib is followed laterally along its length until the end of the rib is felt (Fig. 10.55). The palpable end of the next superiorly lying rib should be located more laterally in the trunk wall.

Step 4: The palpating finger slides medially over the rib until the muscle mass of the erector spinae prevents the finger from maintaining direct contact with the rib (Fig. 10.56). This point corresponds to the level of the T12 transverse process. The T11 spinous process is seen to

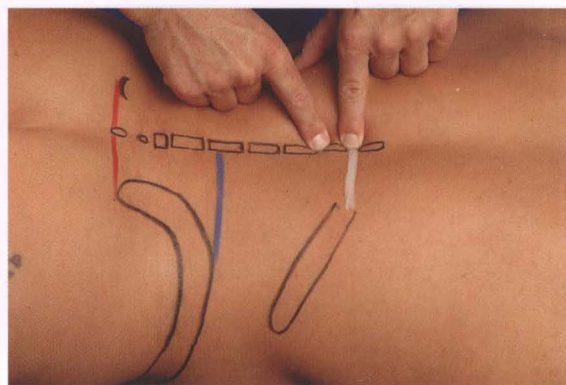


Fig. 10.58 Continuing palpation in the thoracolumbar region.

be correctly located when the next superiorly lying spinous process above the level of the 12th rib and the T12 transverse process is found (Fig. 10.57).

Step 5: Moving from here, the therapist can orient themselves more inferiorly into the lumbar region or further superior into the thoracic spine (Fig. 10.58).

Tip: Reliably locating the level depends very much on whether the 12th rib has been followed far enough medially. If this is not done accurately, the therapist will arrive at one level lower than expected. When the T11 spinous process has been correctly found, the next inferiorly located spinous process (T12) is pointed and short and the L1 spinous process is, in turn, very long.

Tips for Assessment and Treatment

Therapists and physicians use pain provocation and the assessment of stability and mobility as part of their diagnostic repertoire in the clinical assessment of the lumbar spine. Several reliable local segmental tests have emerged from this. The techniques, criteria, and interpretation of these tests will be described in the next section.

Test for Rotation (Transverse Vertebral Pressure)

The lumbar test for rotation (also called transverse vertebral pressure) is used in the local assessment of segments to assess the mobility and, in particular, the presence of hypermobility in axial rotation.

Technique

One thumb pad stabilizes the inferior spinous process from the side. The superior spinous process is pushed in the opposite direction (Fig. 10.59), resulting in rotation.

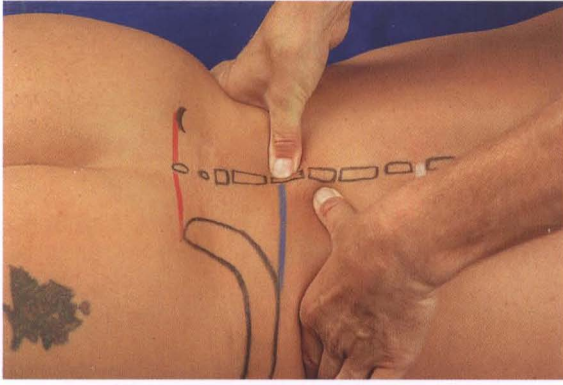


Fig. 10.59 Segmental test for rotation (transverse vertebral pressure).

The test is concluded with the assessment of end feel. All spinous processes are tested on one side first, followed by the other side. This test is the most important for segmental hypermobility as axial instability is also the primary form of segmental instabilities.

Criteria

Is it possible to move the superior spinous process, and what type of end feel does it have? Does pain appear during this test and can this then be used to locate to the painful segment?

Interpretation

T10–T12: Slight rotation is expected here. The end feel is firm-elastic. A lack of rotational mobility is to be classified as restricted range of motion.

T12–L5: No rotation should be possible here. A hard-elastic end feel is to be evaluated as normal. Rotational movement is to be interpreted as hypermobility.

L5–S1: Due to the different position of the joint facets, some rotation is possible in this segment. The end feel is firm-elastic. Loss of mobility represents hypomobility in the segment.

Posteroanterior Segmental Joint Play

The posteroanterior push applied to a vertebra is one of the most common manual therapy techniques. It can be applied either to the spinous process or to the transverse process. Two segments always move when the therapist pushes the vertebra anteriorly (Fig. 10.60). The pressure on the spinous process results in the ZAJ superior to the spinous process opening up and the capsule is placed under tension. The inferior ZAJ surfaces are compressed.

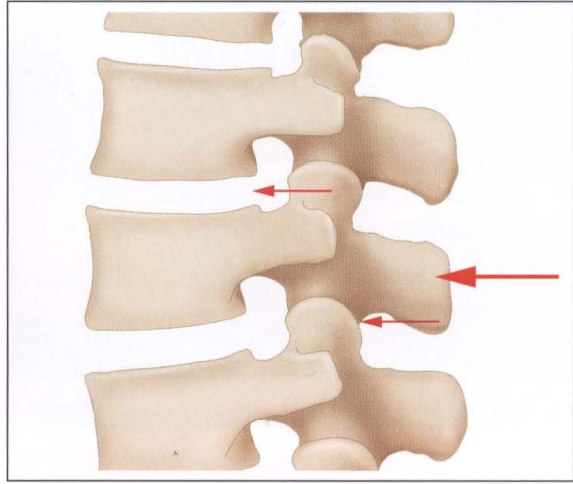


Fig. 10.60 The effect of posteroanterior pressure applied to the spinous process.

Aim

The assessment of segmental mobility, especially the presence of hypermobility, and pain provocation.

Criteria

The therapist pays attention to the range of motion, the quality of the end feel, and the aggravation of pain.

Procedure

The medial edge of the hand is usually placed perpendicular to the lordosis when pressure is applied to the spinous process (Fig. 10.61). The L5 spinous process can be reached locally using a thumb (see Fig. 10.47).

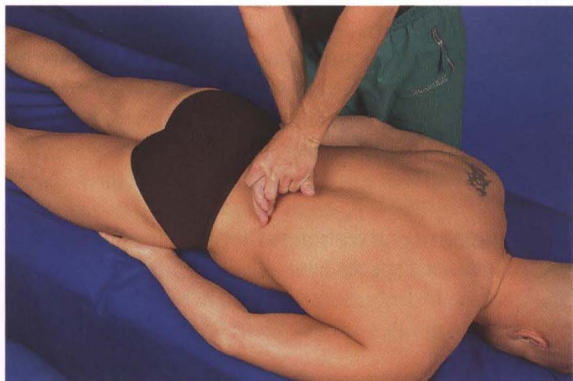


Fig. 10.61 Posteroanterior segmental joint play.

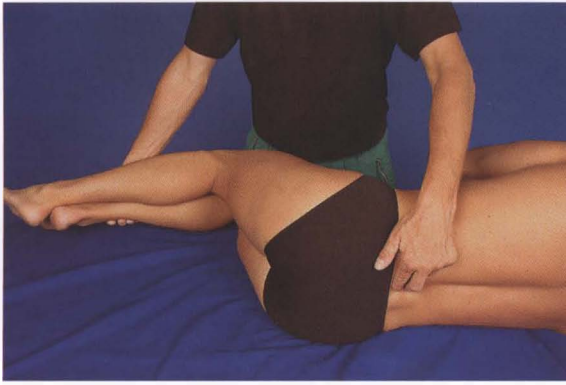


Fig. 10.62 Opening and closing of the interspinous spaces.

Interpretation

The vertebra is expected to move a certain distance when posteroanterior pressure is applied to it. Healthy segments do not react to pressure, and the assessment of end feel is not sensitive. Some experience is required to allocate the yielding of a vertebra to pressure to a pathological condition in the neutral prone position. When the patient supports themselves on their elbows and adopts end range lumbar extension, a hard-elastic end feel is classified as normal.

Palpation during Flexion and Extension Movements

This test addresses a variety of ways to palpate in side-lying. The patient is placed in neutral side-lying in preparation for these tests. Generally, the lumbar spine requires some padding; it is advantageous when the pelvis and legs are lying on a slippery surface.

Aim

To palpate how the segment moves when the hips are bilaterally moved into flexion and extension.

Criteria

The therapist pays attention to the opening and closing of the interspinous spaces.

Procedure

The therapist locates the L5 spinous process from an inferior position, as previously described. A finger pad is placed in the L5/S1 interspinous space and another in the L4/L5

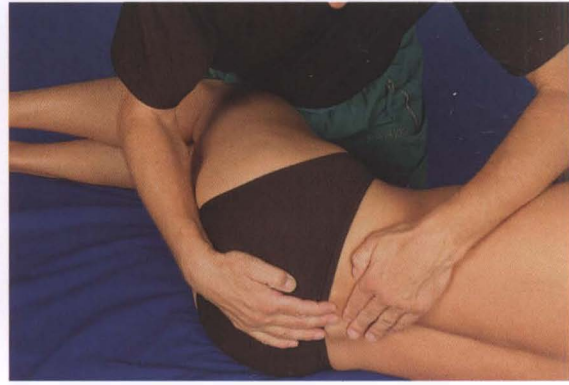

Fig. 10.63 Anteroposterior segmental joint play.

interspinous space. It is possible to place the finger pads directly on top of or adjacent to the interspinous space. Starting with moderate hip flexion, the patient is moved gradually into more or less hip flexion. Both finger pads palpate the movement in the spinous processes at the same time (Fig. 10.62).

Interpretation

The therapist pays attention to the interspinous spaces, for example, by palpating the interspinous spaces from inferior to superior (i.e., L5/S1 first, followed by L4/L5) as they open up during hip flexion and close during hip extension. When two neighboring vertebrae move simultaneously and no opening of the interspinous space can be detected, this is classified as hypomobility. This technique is suitable for finding the resting position of a segment. In this case the spinous process is positioned so that the interspinous space is neither fully opened nor fully closed. The resting position is most often found at approximately 70° flexion for L5/S1 and approximately 90° for L3/L4.

Anteroposterior Segmental Joint Play

Aim

This test attempts to slide two vertebrae on each other using translation.

Criteria

The range of translation movement, especially the sudden increase in mobility in one segment. This test primarily assesses segmental hypermobility.

Procedure

The segment to be tested is located and placed in its resting position using the previously described technique.

Both of the neighboring spinous processes are located posteriorly using the finger pads and are stabilized by applying slight posteroanterior pressure. The fingertips on the inferior spinous process extend into the interspinous space (Fig. 10.63).

The therapist's forearms stabilize the trunk and pelvis. Their hip comes into contact with the patient's knee joint. A straight movement is then made several times by alternately pushing the legs posteriorly and pulling the inferiorly placed spinous process and the pelvis anteriorly.

The position of the neighboring spinous process at the interspinous space is then palpated during the pull and the push. Can a distinct step be found here?

The segments L5/S1, L4/L5, and L3/L4 are assessed. It is possible to limit the translation movement to one segment by positioning the vertebral column. This is achieved by pushing the uppermost shoulder posteriorly until this movement reaches the segment directly superior to the segment to be tested. The segment is now locked in a coupled position.

Interpretation

Approximately 1 mm of translation movement from maximal posterior to maximal anterior is classified as normal. The L5/S1 segment is expected to be somewhat firmer due to the stabilizing function of the iliolumbar ligaments.

Local Segmental Mobility Using Coupled Movements

The best option to assess the presence of hypomobility in one segment is to evaluate how a segment moves using coupled movements. This can be used to test all segments of the functional lumbar spine (T10/T11 to L5/S1).

Aim

To use a coupled movement in lordotic side-lying by sliding the uppermost shoulder backward. A finger tip is used to palpate the interspinous spaces during this, starting with T10/T11.

Criteria

The coupled movement results in rotation with a palpable displacement of the spinous processes in relation to each other. The therapist observes whether the rotation causes

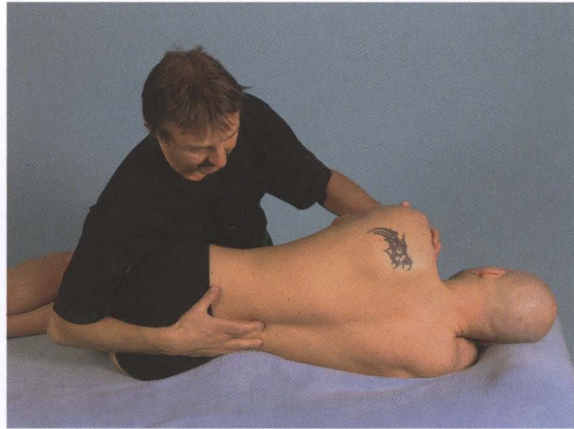

Fig. 10.64 Palpation with coupled movement—SP.

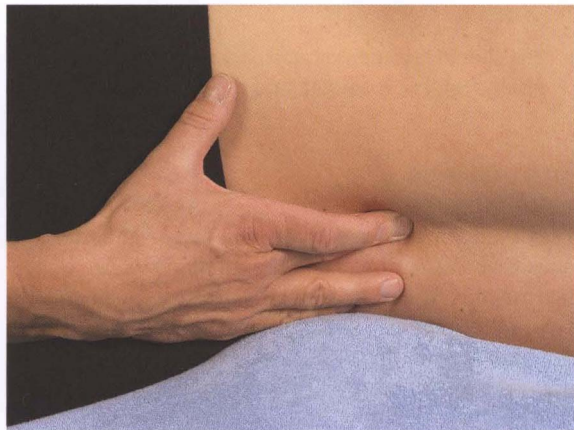

Fig. 10.65 Palpation with coupled movement—detailed view.

the development or the increase of an interspinous step at the segment being assessed.

Procedure

- The patient lies in neutral side-lying with a slight lordosis. Sufficient padding is placed under the lumbar spine so that slight lateral flexion is present. The index or middle finger of one hand is placed over an interspinous space. The fingertip extends past the interspinous space, and the finger pad stabilizes the inferior spinous process (Figs. 10.64 and 10.65).
- The other hand is used to push the uppermost shoulder posteriorly and introduces the coupled movement. The example shown in the figures demonstrates rotation to the left with lateral flexion to the right in an extended lumbar spine (Fig. 10.66).
- As soon as the inferior process starts moving beneath the finger pad, the therapist stops moving the shoulder and assesses whether a step has developed between the spinous processes.

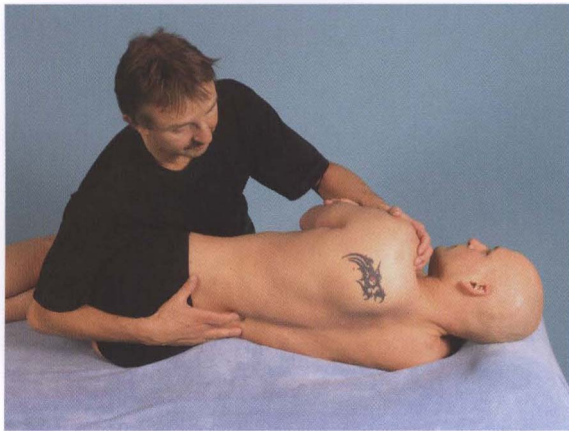

Fig. 10.66 Palpation with coupled movement—end position.

- The shoulder is then rotated back to neutral, a more inferior segment is sought, and the test is repeated.

Interpretation

The development of a step between two neighboring spinous processes at the end of the rotation is a sign of normal mobility. The superior spinous process usually rotates before the inferior spinous process. Experienced therapists can attempt to conduct the segmental mobility assessment in the sitting SP. Coupling is stronger in the weight-bearing position than in an SP without loading. This position, however, makes it considerably more difficult to feel how the structures move. Tension in the paravertebral muscles impedes the clear palpation of the interspinous spaces. It is also possible to assess how the vertebrae move in a coupled movement with flexion.

Training the Multifidus

According to current physical therapy concepts, the multifidus, in combination with the transversus abdominis and the thoracolumbar fascia, plays a decisive role in the stabilization of lumbar segments and the SI joint.

Treatment may therefore aim to recruit and train the multifidus. It makes sense to initially stimulate only the lumbar multifidus without stimulating the lateral-lying large sections of the erector spinae. Muscles can only be consciously contracted when the person is able to perceive the contraction. Tactile feedback regarding the degree of contraction is helpful.

Procedure

The muscle belly can be palpated paravertebrally from its origin on the posterior aspect of the sacrum (Chapter 9, p. 225) to approximately the level of L3 when it is slightly tensed and the lumbar lordosis is increased (Fig. 10.67). It measures one to two finger-widths, depending on how well trained it is. Its contours can be visually differentiated from the neighboring longissimus and iliocostalis in slender people.

To comprehend the real dimensions of the multifidus, the significantly larger lateral tract of the erector spinae (iliocostalis and longissimus) can be made palpable for comparison. The head and, when necessary, a small section of the upper body, is raised so that the compact consistency of the tense back extensors can be palpated from medial to lateral until the soft tissue next to the back extensors is palpated. The therapist can see the actual width of the back extensors by placing the thumb and index finger on either side of the muscles at the approximate level of L3 (Fig. 10.68).

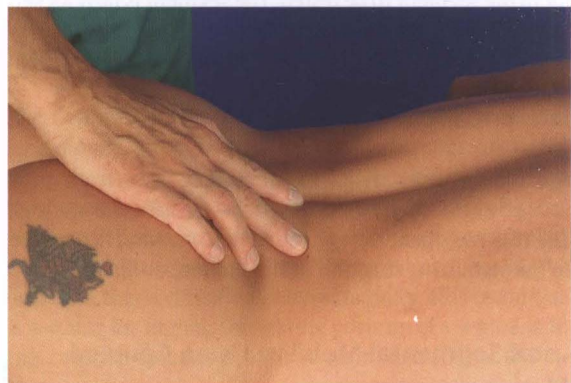


Fig. 10.67 Palpating the contraction of the lumbar multifidus.

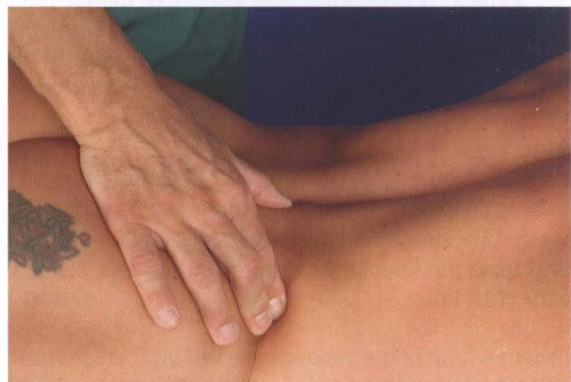

Fig. 10.68 Palpating the width of the entire erector spinae.

Study Questions

1. Which structures stabilize the vertebral column with the strength of their tissues?
2. What role does the lumbar spine play in locomotion according to Gracovetsky?
3. What is lumbarization and sacralization?
4. What is the typical shape of the L5 spinous process?
5. Anatomical literature describes the term "lumbar rib." What is this?
6. The anatomical variation in lumbar ZAJs has its own anatomical name. What is this?
7. Why is it not possible to directly palpate the lumbar ZAJs?
8. Which muscles in the lumbar region additionally tense the thoracolumbar fascia?
9. How do the ZAJs react to symmetrical movement in a segment?
10. What is meant by the coupling of two movements?
11. Which guiding lines are used as orienting projections when starting with the *in vivo* anatomy of the lumbar spine?
12. What options are available to confirm the correct localization of the L5 spinous process?
13. Which technique is the best to palpate an interspinous space in the lumbar spine?
14. What procedure do therapists use to correctly locate the position of the 11th and 12th ribs?
15. Where exactly can the muscle belly of the multifidus be palpated?

THIS PAGE INTENTIONALLY
LEFT BLANK



11 Thoracic Spine and Thoracic Cage

- Significance and Function of the Thoracic Region ... 273**
- Common Applications for Treatment in this Region ... 274**
- Required Basic Anatomical and Biomechanical Knowledge ... 275**
- Summary of the Palpatory Process ... 284**
- Starting Position ... 284**
- Difficult and Alternative Starting Positions ... 284**
- Posterior Palpation Techniques ... 284**
- Anterior Palpation Techniques ... 302**
- Study Questions ... 313**

THIS PAGE INTENTIONALLY
LEFT BLANK

11 Thoracic Spine and Thoracic Cage

Significance and Function of the Thoracic Region

The thoracic region is one of the stable and comparatively rigid sections of the vertebral column. Initially, this may appear to be more of a disadvantage. However, on taking a closer look at the functions of the thoracic region it becomes clear that stiffness is actually an advantage.

The thoracic spine and the thorax have the following functions:

- Protective function.
- Supportive function.
- Junction between the cervical and lumbar spines.
- Respiration.

Protective Function

The thoracic spine, combined with the thoracic cage and the sternum, provides a stable bony cage that protects the heart, lungs, and other important organs. Small and large mechanical stresses can be absorbed by this stable, yet elastic construction. The vertebral canal is very narrow, almost completely enclosed by bones, and home to a large section of the spinal cord.

Supportive Function

In addition to maintaining our upright posture, this section of the body must be stable enough to absorb all impulses arising in the arms. Large muscles, such as the latissimus dorsi and pectoralis major, and the scapulothoracic joint surfaces transmit large compressive and tensile loads. Without this central stability we would be unable to carry the weight of our arms, let alone that of larger loads. At the same time, the lateral tract of the erector spinae muscles is very strong in the lumbar region, but gradually loses its effectiveness more superiorly. Other strong muscles such as the spinalis provide the strength for thoracic extension.

Junction between the Cervical and Lumbar Spines

The thoracic mobility supports extensive arm movements—though not to the same extent as in the lumbar spine where mobility optimizes leg movement. Nevertheless, full arm elevation is only possible up to approximately

150° when the thoracic region is unable to move into extension. The expected range is generally 180°. Arm elevation causes movement from the cervicothoracic junction down to approximately T6/T7:

- in the form of extension (with bilateral arm elevation); or
- in the form of extension with rotation (when one arm is elevated).

This knowledge is useful when locating the level of thoracic symptoms. Can thoracic symptoms also be provoked using extensive arm elevation?

Extensive external and internal rotation at one shoulder joint is transmitted onto the thoracic spine as rotation. Bilateral rotation causes the thoracic spine to flex (with internal rotation) or extend (with external rotation).

From a biomechanical point of view, the thoracic spine has to act as a connection, passing on movement between the cervical spine and the lumbar spine:

- The predominant functional movement in the cervical spine is rotation.
- Flexion and extension are the dominating movements in the lumbar spine.

The cervical spine and the lumbar spine couple lateral flexion and rotation in their own specific way.

Anatomically, the mobile sections of the vertebral column can be well differentiated from one another. The thoracic spine stands out as the section that supports the ribs. Functionally, there is a fluent transition between its sections. Both lordotic sections extend functionally into the thoracic section of the vertebral column. It is therefore expected that extensive cervical movements can be palpated down to approximately T4–T5. Lumbar movements are carried over to approximately the level of T10–T11. The real thoracic spine is found between these points.

Respiration

In healthy people, quiet respiration is completely controlled by activity in the diaphragm. Forced respiration is supported by movement in the thorax. Respiratory movements are the result of:

- Elasticity in the thoracic cage.
- Mobility in the costovertebral joints.
- Supportive movements in the thoracic spine.
- Activity in different intrinsic muscles and the accessory muscles of inhalation.

The extensive costal joint movements associated with forced respiration are very important for the diagnostic process. Does deep inhalation or exhalation provoke back pain?

How Does this Affect Palpation?

The upper thoracic segmental movement associated with extensive arm elevation can be palpated well. An example of this is seen when the therapist places several finger pads over the cervicothoracic junction on the left side of the spinous process. The therapist can then feel the spinous process's rotation to the left when the right arm moves into full elevation.

Respiratory movements can also be palpated. The opening and closing of the intercostal spaces provides information on the mobility of the ribs at their articular connections to the vertebral column and the flexibility of the intercostal muscles.

Different techniques can be used to palpate the thoracic segments during movement to assess the presence of restricted mobility. While clear rules exist explaining the relationship between lateral flexion and rotation in the lumbar spine and the cervical spine, it is not possible to set fixed rules for the mid-thoracic region. There is so much variation between individuals that functional relationships have to be newly assessed every time.

Common Applications for Treatment in this Region

The thoracic spine and the thorax are the home for the sympathetic nervous system. It is well known that the central region of the sympathetic nervous system is found in the lateral horn of the thoracic spinal cord. Important thoracic organs are represented in the large Head zones. This close relationship between viscerotomes and dermatomes can be used for diagnosis. Treatment can not only affect these organs via the reflexes; it can also affect the neurovegetative control of the head and arms. Preganglionic fibers extend from the upper thoracic segments into the cervical sympathetic chain ganglions. The thoracic spine and the thorax are therefore an ideal location to apply mechanical (Swedish massage, connective-tissue massage, manual therapy), thermal, or electrical stimuli to affect sympathetic nervous system activity. These forms of intervention are the recurring topic of discussion in the treatment of chronic musculoskeletal pain.

The thoracic spine and the thorax are also often directly affected by the almost violent interventions used in open thoracic surgery. In older patients, these joints are becoming rigid as part of the adaptive aging process. During this type of surgery, thoracic segments and costal joints are placed in extreme positions and are then forced

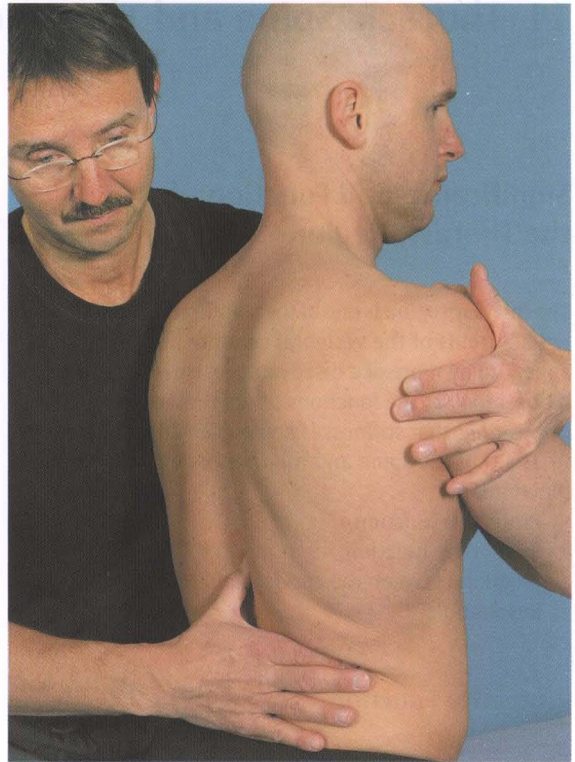


Fig. 11.1 Assessment of local mobility.

into inactivity for weeks on end. In such a case, it takes a lot of effort to train a thorax to breathe properly again. A variety of respiratory parameters are used here for diagnosis: the frequency, rhythm, and direction of respiration, as well as the range of thoracic motion between maximal inhalation and expiration. The compression of the thorax and the mobilization of soft tissues are important manual techniques used in respiratory therapy that require certain basic palpatory dexterity.

Pain and restricted mobility in the costal and vertebral joints not only lead to restrictions in respiration; they also strongly interfere with daily tasks. Hypomobility in connection with pain plays an important role here. In no other section of the vertebral column is the assessment of segmental mobility and extremely localized mobilization as important as in the thoracic spine (Fig. 11.1).

Three large groups of pain origin are observed:

- Acute and chronic internal ruptures of the intervertebral disk.
- Painful hypomobility in the zygapophysial joints (ZAJs).
- Painful hypomobility in the costovertebral joints (costal joints).

Hypermobility is rarely seen to be a cause of symptoms. For a long time intervertebral disks were not considered a possible source of thoracic symptoms until it became clear that not only protrusions and prolapses, but also in-

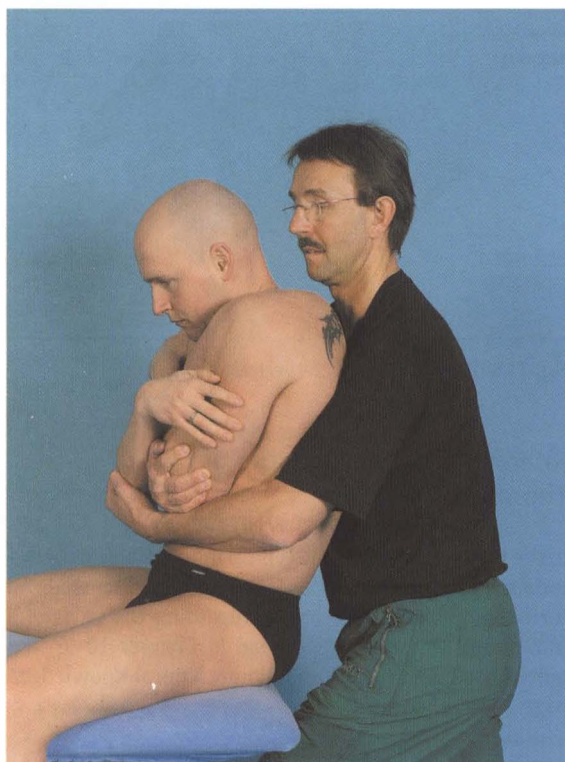


Fig. 11.2 Axial traction

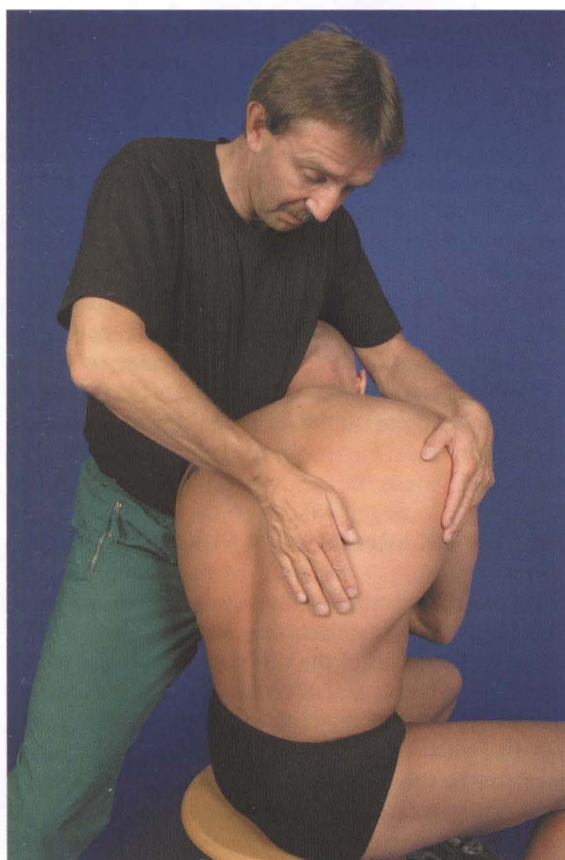


Fig. 11.3 Diagnosing the position of the ribs.

ternal rupturing of the anulus fibrosus, may be a possible source of symptoms. It is recommended that the sudden development of thoracic pain first be treated as an intervertebral disk problem. Axial unloading techniques have been successfully used here (Fig. 11.2).

Specific regions display a higher frequency of certain pathological conditions (personal correspondence from the IAOM study group):

- T1–T4: costovertebral joints > acute problem with the intervertebral disk > pathological ZAJ.
- T5–T8: acute problem with the intervertebral disk > pathological ZAJ > costovertebral joints.
- T9–T12: acute problem with the intervertebral disk > costovertebral joints > pathological ZAJ.

The first four costovertebral joints are very rigid and tend to be more hypomobile. A link to strenuous arm activity, or a one-off exertion of force, for example, carrying a very heavy weight, or sudden shortness of breath, is often seen as a cause of symptoms. The role of palpation is to accurately locate a level to provoke the costovertebral joints and to ascertain the position of structures during inhalation and expiration (Fig. 11.3).

Symptoms arising from the costovertebral joints are often felt “between the shoulderblades.” They are also often felt on top of the shoulder. A large portion of the pain in the trapezius probably arises from the first rib being blocked in a position of inhalation.

Required Basic Anatomical and Biomechanical Knowledge

Functional Divisions in the Thoracic Spine

The thoracic spine differs anatomically from the other sections of the vertebral column due to its connection to the 1st to 12th ribs on each side. The functional thoracic spine is not a single unit:

- The upper thoracic spine belongs to the cervical spine. Extensive cervical movements are carried on down to T4/T5.
- The lower thoracic spine belongs to the lumbar spine. Lumbar movements are carried on up to T10/T11. Flexion and extension are especially possible in this section.
- Based on this, the “real” thoracic spine is only found between T5 and T10.

On further inspection, these sections can also be differentiated from one another morphologically (Fig. 11.4). The shape of the two upper thoracic vertebrae is more similar to a cervical vertebra while the lower thoracic vertebrae gradually take on the shape of a lumbar vertebra. Only the spinous processes in the middle section of the thoracic spine slant down typically at a steep angle.

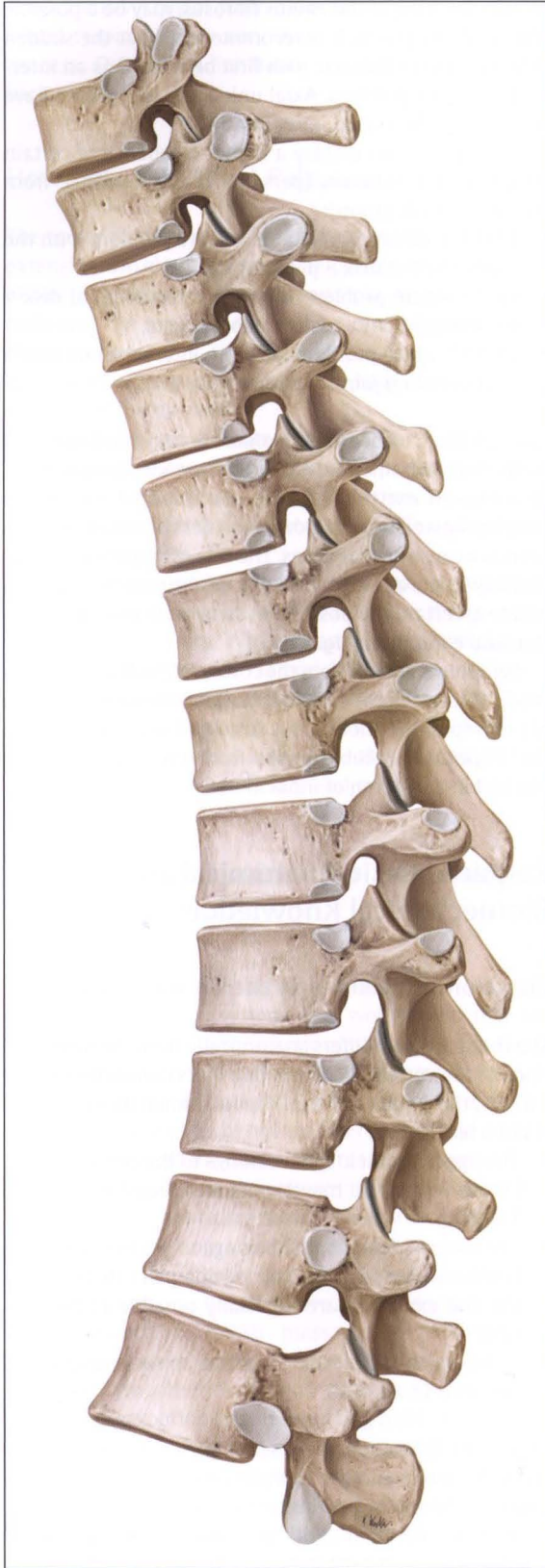

Fig. 11.4 View of the thoracic spine (From Thieme Atlas of Anatomy, General Anatomy and Musculoskeletal System, © Thieme 2005, Illustration by Karl Wesker).

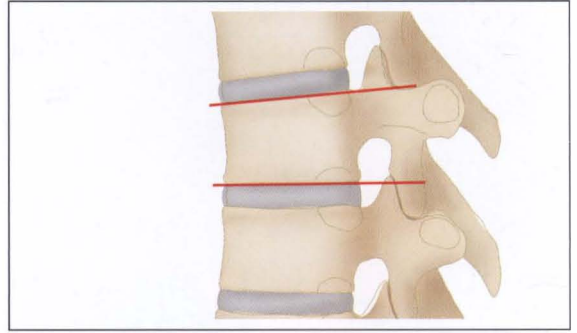


Fig. 11.5 Wedge shape of the vertebral body.

Anatomical Characteristics of the Thoracic Spine

In the next section, only the typical morphological characteristics of the thoracic vertebra will be discussed. All further important information regarding the parts of a movement segment can be read in Chapter 10 in “Required Basic Anatomical and Biomechanical Knowledge,” page 243.

The Thoracic Vertebral Body

The thoracic kyphosis is not only a result of posture; it is also caused by anatomy. The lumbar lordosis is directly related to the wedge-shaped construction of the intervertebral disks at L4/L5 and L5/S1 and the L5 vertebral body. It is the wedge shape of the vertebral body that causes the kyphotic form (Fig. 11.5). The superior and inferior end plates of the vertebrae are always parallel to one another in one segment. When examined, it can be seen that the vertebral body is more “heart shaped.” This is probably an adaptation to the very anteriorly located center of gravity for this section of the body.

Most thoracic vertebrae have two articular surfaces on each side that form a joint with the head of the ribs via the disk in the socket (joint of head of rib or costovertebral joint).

The Thoracic Intervertebral Disk

The thoracic intervertebral disks are quite thin and therefore adjust to the comparatively small movements in a segment. The heads of the ribs stabilize the disk on the sides. The posterolateral direction for a thoracic prolapse (not likely) is therefore occupied by bone. It is very unlikely that intervertebral disk substance will cause nerve-root compression. The intervertebral foraminae, with their exiting spinal nerves, are found significantly superior to the intervertebral disk. This is another reason why spinal nerves are rarely affected by a thoracic prolapse.

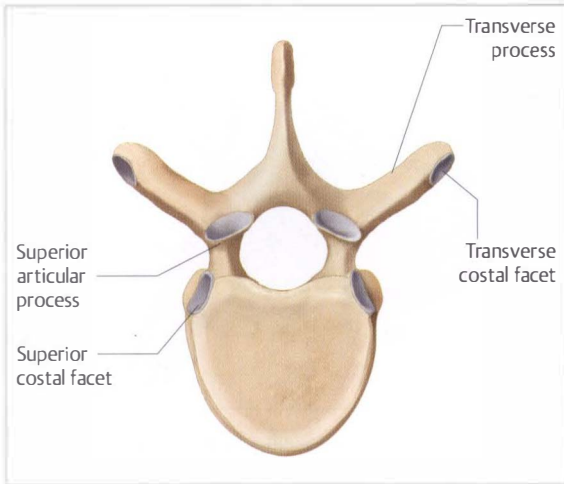


Fig. 11.6 View of a thoracic vertebra.

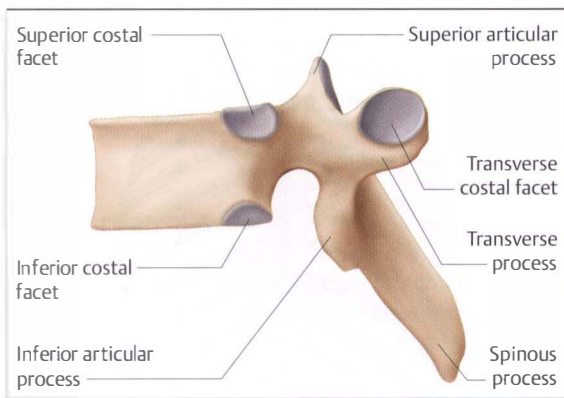


Fig. 11.7 Thoracic vertebra (lateral view).

The Vertebral Foramen

The vertebral foramen is round and, in comparison to the other sections of the vertebral column, very narrow (Fig. 11.6). As the laminae of the thoracic vertebral arch are very high, the foramen is almost completely enclosed by bone from all sides. The spinal cord takes up almost the entire diameter of the foramen and cannot make way for other masses that may intrude on this space (e.g., fracture, bleeding, or intervertebral disk prolapse). The dura mater and the spinal cord have a particularly high chance of being compressed when these pathological conditions are present in the thoracic spine.

Spinous Process

The thoracic spinous process is known to be very long and points in an inferior direction (Fig. 11.7). Its shape is the typical characteristic of a thoracic vertebra.

The length and the angle of the spinous process vary between the upper, middle, and lower thoracic sections. The slant results in a significant difference in the level between the tip of the spinous process and the corresponding transverse process. This difference is summarized in the “finger rule.” This rule is used to locate the structures belonging to the same vertebra that can be reached using palpation.

The spinous processes overlap, especially in the mid-thoracic spine. This means that when the thoracic spine is brought into extension, the spinous processes come into contact with each other quickly here and compression increases. Small bursae absorb the friction while the spinous processes slide a little over one another and restrict extension. The thoracic spine is locked in this position.

How Does this Affect Palpation?

In a neutral starting position (SP), the very long **spinous processes** can be easily palpated and differentiated from one another. It is very simple to draw the outline of the tips on the skin. The sitting position is the only position where the active, tensed muscles may make it harder to access the spinous processes. Furthermore, the therapist must be aware that no spaces exist between the spinous process. The tip of the superior spinous process lies on the posterior side of the inferior spinous process.

The **locked position of the thoracic spine** resulting from the overlapping thoracic spinous processes in extension is not a suitable SP to palpate segmental mobility. The segments are able to move better when the thoracic spine is slightly flexed—the resting position for the thoracic spine. The therapist should therefore ensure that the thoracic spine is always positioned in a slight kyphosis for all SPs.

The “**springing test**,” the posteroanterior pressure on the spinous processes, is not suited to assessing mobility in the thoracic spine. Pressure on these long processes does not result in translation movement. The vertebra tilts backward instead.

Transverse Process

Inferiorly, the transverse processes become gradually shorter and point more posteriorly. The length of the T1 transverse process is of particular interest when searching for the costovertebral joint between the first rib and T1. The T1 transverse process is approximately as long as the patient’s index finger when it is projected onto the skin.

Each transverse process has a small joint facet on its anterior aspect that forms the costotransverse joint with a rib. The spatial orientation of the transverse process determines the position of the communal axis for both costovertebral joints (see also “Mechanics of the Costovertebral Joints,” below).

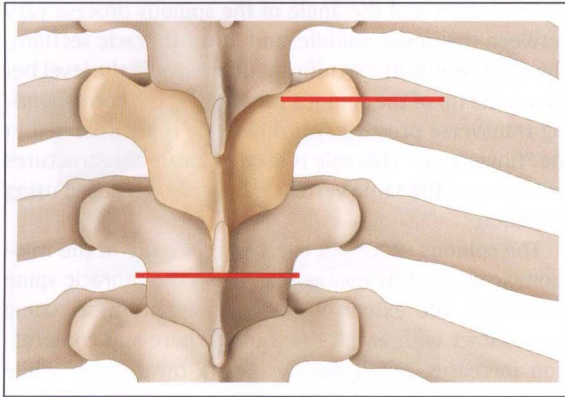


Fig. 11.8 Difference in height between the spinous process and the transverse process.

How Does this Affect Palpation?

The direct paravertebral area is covered by less muscle mass in the thoracic spine than in the lumbar spine. This enables the therapist to confidently access the transverse process and provides an extra lever to affect segmental mobility. The question is, how does the therapist find the transverse process belonging to a specific vertebra? This is achieved using two different methods:

- Each transverse process is found at the level of the accessible medial end of a rib.
- The difference in position between the spinous process and the transverse process conforms to the “finger rule.” The therapist can reliably locate the level of a transverse process by first palpating the localized tip of the corresponding spinous process.

Tip: Finger rule: The typical thoracic vertebrae is constructed with a difference in height between the spinous process and the transverse process. The extent of this difference varies almost from segment to segment. The therapist attempts to determine this difference by using the patient’s index finger during palpation (**Fig. 11.8**).

When the therapist wishes to access the corresponding transverse process, they move a specific number of finger-widths in a superior direction from the lower edge of the spinous process:

- T1, T2 spinous processes: plus one finger-width.
- T3, T4 spinous processes: plus two finger-widths.
- T5–T8 spinous processes: plus three finger-widths.
- T9, T10 spinous processes: plus two finger-widths.
- T11, T12 spinous processes: plus one finger-width.

Facet Joints

The alignment of the thoracic ZAJs is quite different from that seen in the lumbar region. In relation to the end plates, the superior joint processes are tilted upright at an average angle of 70° and are tilted 20° anteriorly on the sides (**Fig. 11.9**). This means that the processes lie in a perfect circular arc around the rotation axis found in

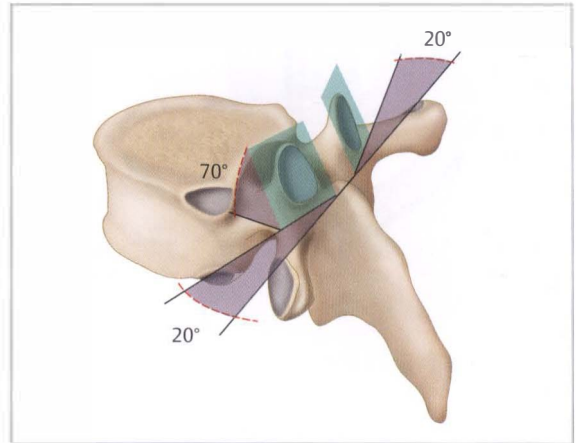


Fig. 11.9 Alignment of the thoracic ZAJ.

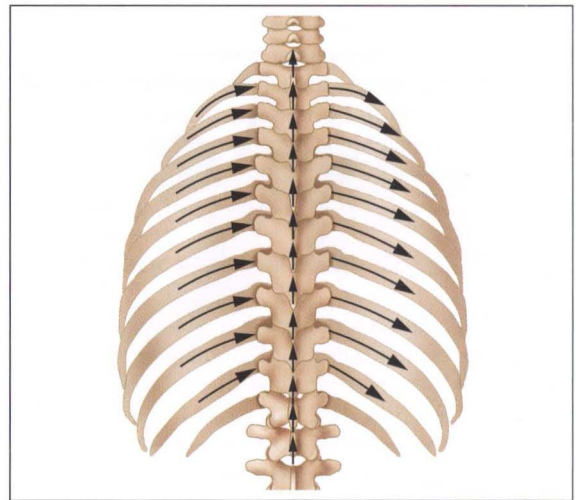


Fig. 11.10 Kinematic chains: thoracic spine and thorax.

the disk. Rotation is therefore not significantly restricted by either the ZAJ or the ribs and is evenly distributed between all segments (excluding the thoracolumbar junction) (White and Panjabi, 1990).

How Does this Affect Palpation?

Segmental rotation is suitable for the assessment of segmental mobility and also for restoring this mobility with the use of appropriate techniques.

Thorax

The bony thorax is formed by 12 pairs of ribs and the sternum. Two kinematic chains meet at the point where the ribs connect to the vertebrae (**Fig. 11.10**):

- Vertical kinematic chain = thoracic spine.
- Horizontal kinematic chain = costovertebral joints.

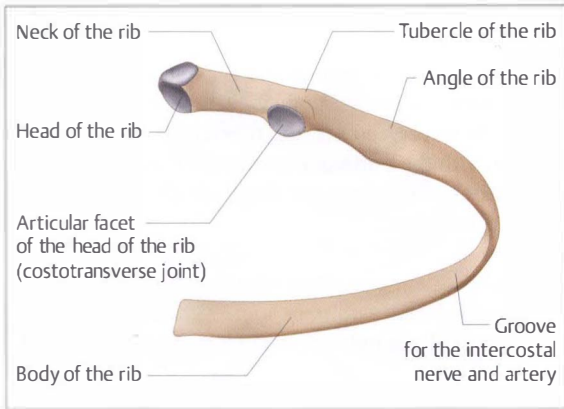


Fig. 11.11 Construction of a rib.

The two kinematic complexes affect one another with their mobility and stability. The thorax affects the thoracic spine by increasing its stiffness and reducing its range of motion, for example, during lateral flexion (White and Panjabi, 1990). This is advantageous when concentrating on the protective and supporting functions of the thoracic spine.

Construction of a Rib

A rib is a curved long bone that seeks contact with the sternum as it turns downward from posterior to anterior. It is made up of different sections (Fig. 11.11).

How Does this Affect Palpation?

- The tubercle of the rib can sometimes be palpated. It is found directly adjacent to the tip of the transverse process.
- The angle of the rib is the largest curve in the rib and extends the most posteriorly. The easiest point to feel the rib is at its angle near the vertebral column.
- The superior edge of the body of the rib is rounded; the inferior edge is more sharp-edged. With this knowledge, the therapist can assess whether malpositioning is present in fixed inhalation or expiration during the palpation of the thorax.

Articulations between the Ribs and Sternum

The ribs are divided into three groups based on the different types of contact with the sternum (Fig. 11.12):

- Direct contact with the sternum: the “true” ribs—1st to 7th ribs.
- Indirect contact with the sternum: the “false” ribs—8th to 10th ribs.
- No contact with the sternum: the floating ribs (“mobile” ribs)—11th and 12th ribs.

The 11th and 12th ribs end without bony contact in the wall of the trunk and demonstrate a firm-elastic consistency on direct pressure. Their length varies considerably.

The connecting cartilage of the 8th to 10th ribs forms the costal arch. Both costal arches meet at the epigastric

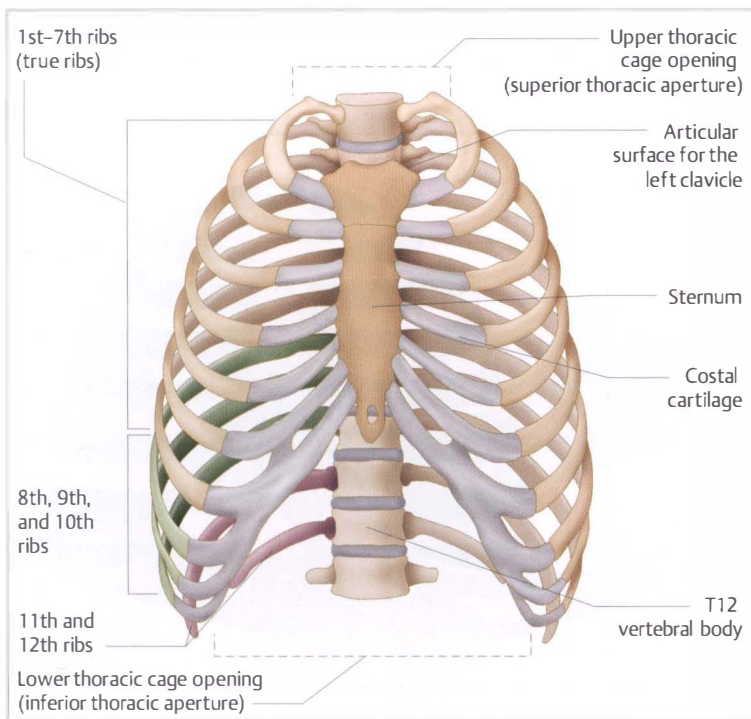


Fig. 11.12 Divisions of the ribs.

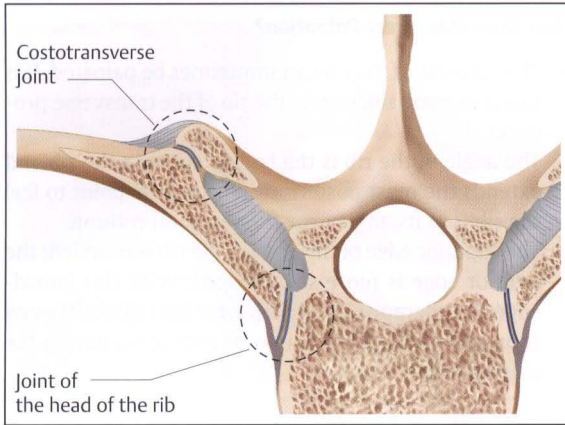


Fig. 11.13 The joints between the ribs and the vertebrae.

angle on the xiphoid process of the sternum. The distance between the costal cartilages of the 10th ribs demonstrates the size of the inferior thoracic aperture. The connection between the costal cartilage and its superior neighbor is not particularly stable. Subluxations can occur due to trauma (“slipping ribs”).

Most of the costosternal junctions to the true ribs are small true joints, very firm and resilient. The second rib is usually attached to the sternal angle (junction between the manubrium and the body of the sternum). Hardly any variations in anatomy are evident here.

Articulations between the Ribs and the Vertebrae

Differences are made depending on which parts of the rib or the vertebra articulate (Fig. 11.13):

- Costovertebral joints (joint of the head of the rib): the head of the rib articulates with two vertebral bodies and the disk. Exceptions are the 1st, 11th, and 12th ribs. Only a vertebral body is seen here.
- Costotransverse joints: the tubercle of the rib forms a joint with the transverse process of the corresponding vertebra. Exceptions are the 11th and 12th ribs. No joints exist here.

The superior four ribs share very firm articulations with the vertebrae and tend to be more hypomobile. The first rib in particular stands out in clinical practice.

Mechanics of the Costovertebral Joints

The axis of movement couples both joints functionally and passes through the neck of the rib. The transverse process differs in length and spatial alignment in the upper, middle, and lower thoracic spine. It determines how far posterior and lateral the costotransverse joint is located. Lastly, it determines the position of the rotational axis for movements of the ribs during inhalation and expiration (Fig. 11.14).

The length and alignment of the transverse processes in the upper thoracic spine (T1–T7) causes the rotational axis to be aligned more in the frontal plane. This results in elevation and expansion of the thorax in the sagittal plane due to the mechanics of the ribs. The more sagittally oriented axes in the middle and lower thoracic spines enable the thorax to expand in a lateral direction.

Forced inhalation (Fig. 11.15) always results in intercostal spaces widening in every section of the thorax. The intercostal spaces become narrower during expiration (Fig. 11.16). This movement pattern allows diagnosis-

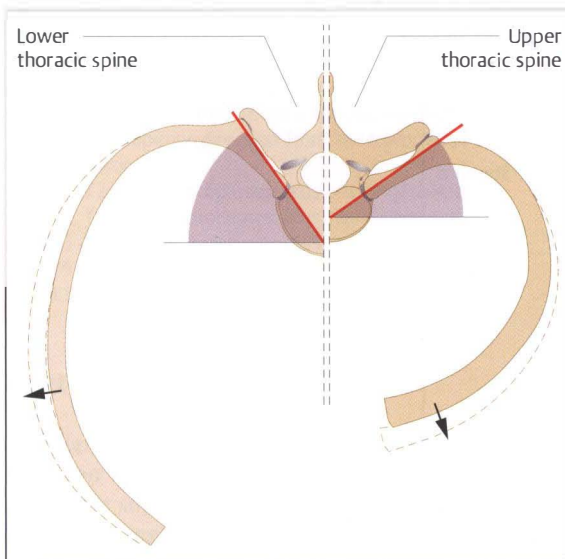


Fig. 11.14 Costovertebral joint mechanics.

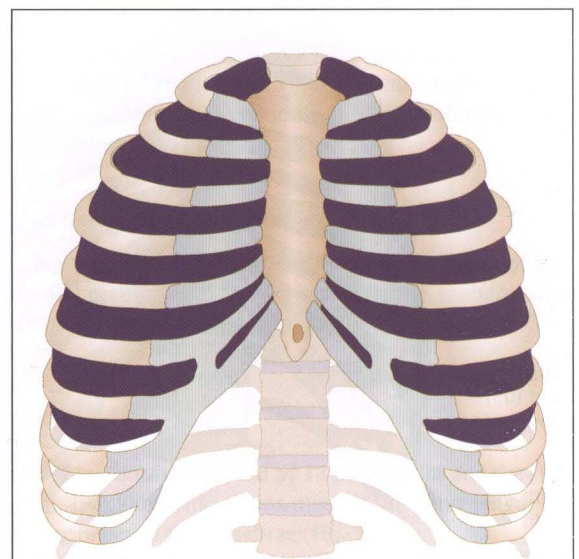


Fig. 11.15 Thorax in the position of inhalation.

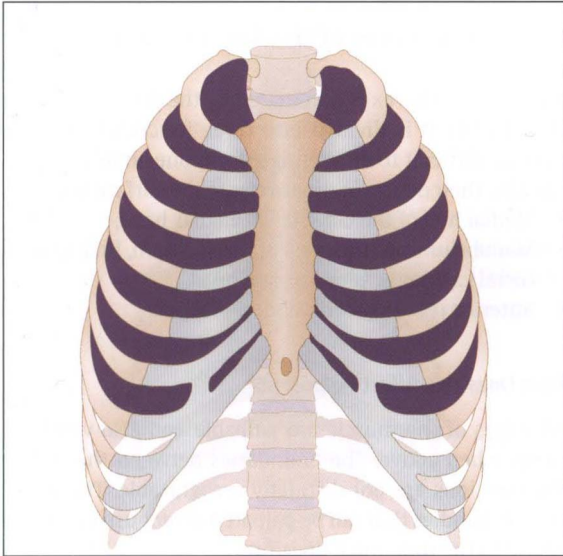


Fig. 11.16 Thorax in the position of expiration (source: Kapandji, 2006).

ing through palpation with movement. Movements of the arm have similar effects on the intercostal spaces:

- Arm elevation with flexion raises the upper thorax in a more anterior direction and opens up the upper intercostal spaces.
- Arm elevation with abduction raises the lower thorax in a more lateral direction and opens up the lower intercostal spaces.

The rotation of the ribs around the longitudinal axis in the neck of the rib during deep inhalation and expiration results in the inferior or superior edges of the ribs facing slightly outward.

How Does this Affect Palpation?

The inferior or superior edges can be felt at the end of forced inhalation and expiration. The edges are not palpable during quiet respiration. The relationship of structures to one another is interesting when the ribs are pathologically fixed in a position of inhalation or expiration. When the therapist assesses the position of structures, it is noticeable that the blocked rib has another form in comparison to its neighboring mobile ribs (see the section “Assessment of the Costovertebral Joints” below).

Detailed Anatomy of the Anteriorly Positioned Bones

Figure 11.17 is used in many anatomy books and shows the anatomy of the manubrium as the superior section of the sternum with its articular connections. The edge of the manubrium is equipped with many notches. The jugular notch is the most superior-lying notch. The medial ends of the clavicles form the sternoclavicular (SC) joints lateral to this. The cartilage of the first rib has an articular connection to the manubrium immediately inferior to the SC joint. The sternal angle is found at the level of the connection to the second rib. This connection is described at times in anatomical literature as an articulation or as a synchondrosis. The manubrium moves on the body of the sternum as the thorax moves during respiration.

How Does this Affect Palpation?

The jugular notch is a reliable orientation point to access the manubrium from a superior position. The level of the notch also corresponds to the level of T2 (see the section “Anterior Palpation Techniques” in Chapter 12,

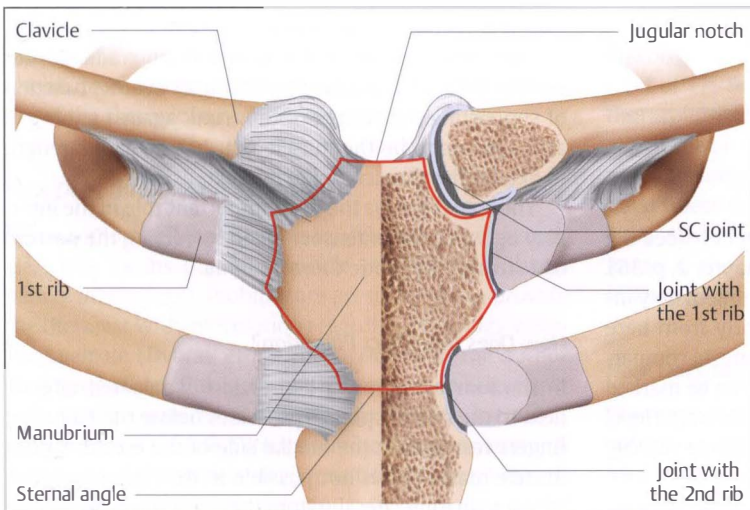


Fig. 11.17 Manubrium of the sternum.

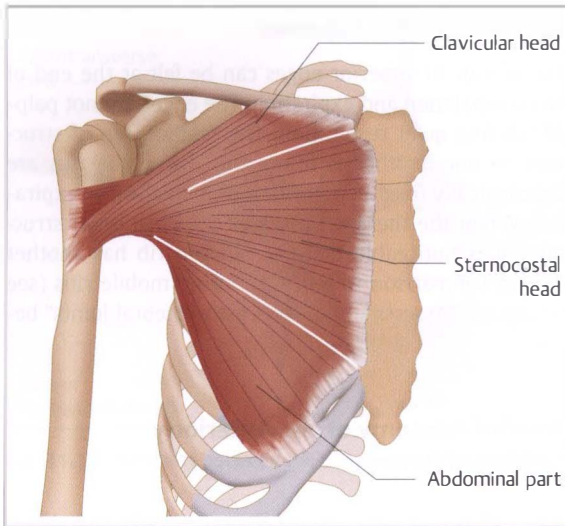


Fig. 11.18 Pectoralis major

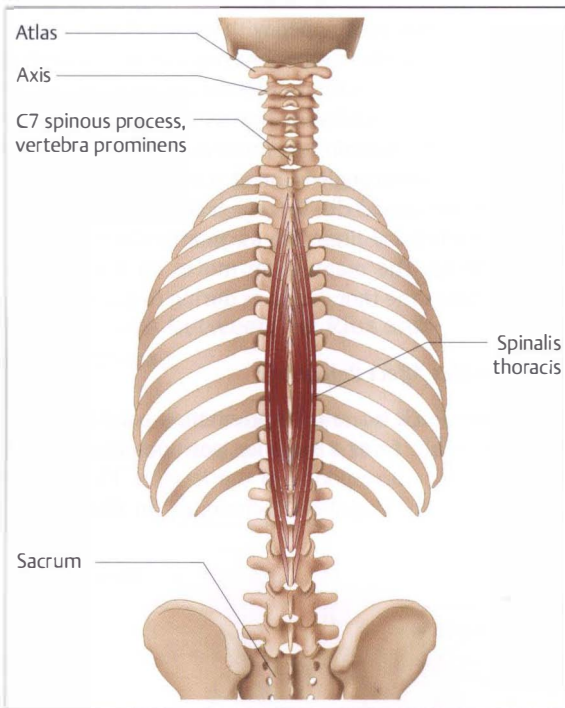


Fig. 11.19 Spinalis thoracis

p. 365). It is easy to reach the SC joint from here (see the section “Sternoclavicular Joint Space” in Chapter 2, p. 36).

The medial end of the first rib is found immediately inferior to the clavicle and extends posteriorly from here with a tight curve. It is very difficult to palpate. In comparison, the sternal angle is easy to reach and can be marked with confidence. The second rib is found at the same level without fail. The first five intercostal spaces can be reliably reached from here.

Detailed Anatomy of the Anterior Muscles

The anterior thorax is dominated by the pectoralis major (Fig. 11.18). It is divided into three functional sections that are difficult to differentiate from one another anatomically. Their denominations refer to the surface of origin:

- Medial half of the clavicle: clavicular head.
- Manubrium and the body of the sternum, first to sixth costal cartilages: sternocostal head.
- Anterior rectus sheath: abdominal part.

How Does this Affect Palpation?

All edges of the muscle are palpable and also visible at times when active. The boundaries between the individual sections are not distinctly recognizable. The rough muscle bundles that can be palpated do not usually correspond to the functional divisions.

Thoracic Back Muscles

Intrinsic Back Muscles

Within this group arising from the medial tract of the intrinsic back muscles, two muscle systems are unique to this region:

- Spinalis thoracis: represents the straight, spinal system.
- Rotatores thoracis: from the oblique, transversospinal system.

The interspinales muscles from several segments unite to form the spinalis thoracis (Fig. 11.19). This muscle can only be found in the thoracic part of the vertebral column. It extends from L1–L3 to C7–T1 and is found directly adjacent to the row of spinous processes. The transition to the semispinalis cervicis is almost completely smooth. It forms the bulge of paravertebral muscles in the neck region and is consciously disregarded here.

The cross-section of the lateral tract gradually decreases here. The spinalis thoracis takes over its function of supporting the weight of the trunk against gravity. It also appears to be the muscle that has enough strength to extend the thoracic spine into extension.

The spinalis plays the most important role in the interplay between the extensors when correcting the posture of a strongly kyphotic thoracic spine.

How Does this Affect Palpation?

In the lumbar region, a depression is palpated directly next to the row of spinous processes before the palpating fingers rest against the medial side of the erector spinae muscle mass. This is not possible in the thoracic region. When palpating laterally from the tip of the spinous pro-

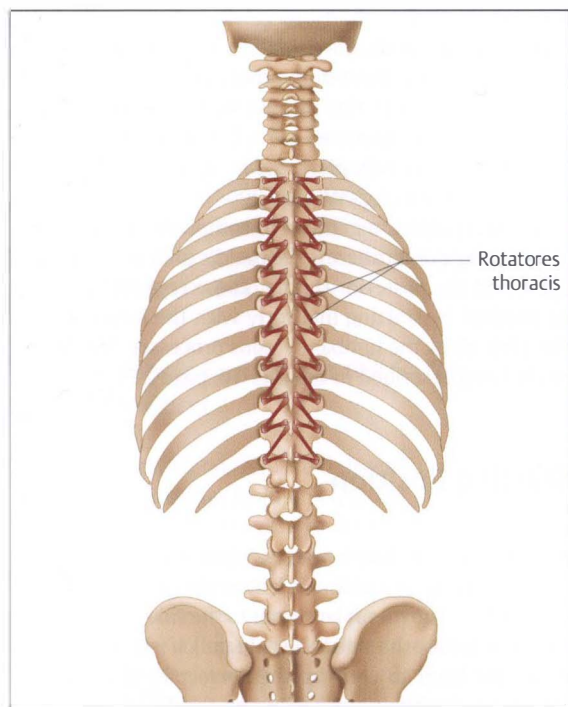


Fig. 11.20 Rotatores thoracis

cesses, the therapist immediately encounters a spinalis muscle approximately one finger-breadth wide. Enormous muscle tension is frequently found here, which often feels unpleasant when direct pressure is applied to it.

The **rotatores thoracis muscles** (Fig. 11.20) are short muscles found very deep in the tissue. They are in close contact with the ZAJs (from Lanz and Wachsmuth, 2004a). The decisive factor for the exact terminology used for the muscles is their length:

- Extending over one segment: rotatores brevis.
- Extending over two segments: rotatores longus.

Their prominence corresponds well to the ability to rotate to almost the same extent in all thoracic segments. The actions of the rotatores thoracis include the extremely differentiated fine adjustment of position and the local stability of the thoracic movement segments.

How Does this Affect Palpation?

Some authors call the rotatores muscle “monitoring muscle.” This means that this muscle tenses when disturbances in segmental mobility are present and can provide the therapist with information regarding pathology when they palpate (Dvořák et al., 2008). However, the author doubts whether clinicians are actually able to selectively palpate the rotatores and to clearly perceive increased tension in this muscle. When examined on an anatomical specimen, the muscle’s deep position hidden beneath several other muscles is revealed.

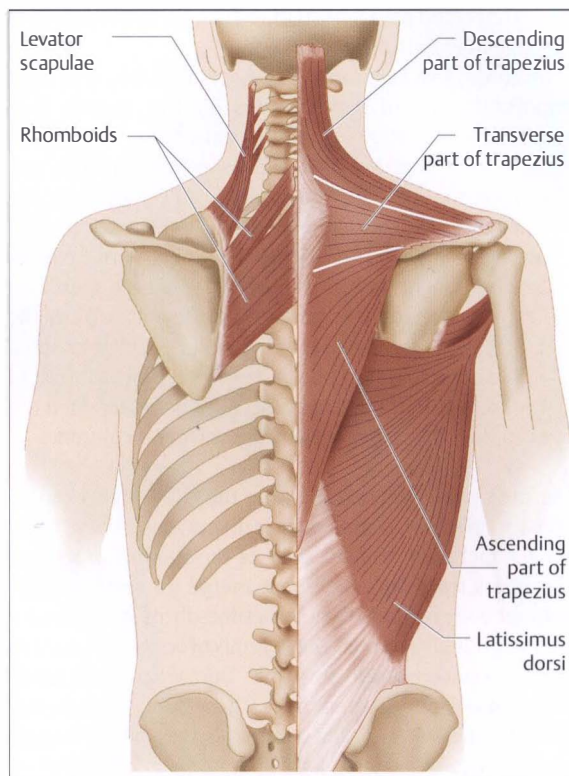


Fig. 11.21 Extrinsic back muscles.

Extrinsic Back Muscles

The thoracic section of the back is dominated superficially by the latissimus dorsi and the most important representatives of the thoracoscapular muscle group. The latter muscle group extends from the trunk (from the row of spinous processes) to the scapula and belongs functionally to the upper limb. These are, in particular:

- The descending and transverse parts of the trapezius.
- The rhomboids.

The originating fibers of the **latissimus dorsi** extend to the level of T7–T8 (see Fig. 11.21), and therefore also to the thoracolumbar fascia. The thoracolumbar fascia additionally receives fibers from the serratus posterior at this point. In comparison to the lumbar region, the latissimus dorsi fibers do not cross the mid-line in the thoracic region. All further information about this muscle can be found in the section “Detailed Anatomy of the Muscles” in Chapter 10, page 252.

How Does this Affect Palpation?

The superior sections of the muscles can be recognized only in very muscular and very slim people. It is highly unlikely that this muscle can be reliably differentiated from other structures. Generally, the lateral edge can be de-

monstrated and palpated on toned people when their arm is active in extension.

According to Lanz and Wachsmuth (2004), the most important parts of the **trapezius** for this section (Fig. 11.21) have the following anatomical course:

- Ascending part: the fibers converge from their origin on the T4–T11/T12 spinous processes onto the medial end of the spine of the scapula, where they are evident posteriorly. Here they meet with the posterior fibers of the spinal part of the deltoid muscle.
- Transverse part: this part generally passes from the C7–T3 spinous processes to the upper edge of the spine of the scapula (lateral half). This is the thickest part of the trapezius. It becomes a prominent bulge when the scapula is adducted toward the vertebral column.

The therapist can generally note that the origins of this very superficially located muscle do not always have to involve attachment to both sides of the spinous processes. The fibers from both sides can merge into one another without bony contact; they sometimes form an aponeurosis that glides freely over the spinous processes, especially at the cervicothoracic junction. Bursae are frequently found on anatomical specimens. These bursae reduce friction. The question is: Could bursitis also be a possible cause for gradually developing local symptoms in this area?

How Does this Affect Palpation?

The junction between both parts of the muscle can only rarely be identified as a gap on anatomical specimens and is therefore not of interest for palpation. The inferior edge of the ascending part can be palpated when the muscle is active. The superiorly running fibers angled from medial to lateral become distinct when this part of the trapezius pulls the scapula posteriorly and inferiorly against resistance. Therefore, the hand palpates from an inferior position, perpendicular to the edge of the muscle, and hooks onto the muscle.

Summary of the Palpatory Process

The aim of the palpatory process is to reliably locate all relevant bony structures and several important muscles. That includes all accessible spinous processes and transverse processes as well as the ribs. A variety of SPs are used here for palpation. The treatment examples should demonstrate how useful it is to apply in vivo anatomy precisely and to link this in with the daily clinical practice.

The cervicothoracic junction is located in the sitting SP first and later with the patient pronated. All further sections of the thoracic segments and the ribs will be described after this. The sections of the sternum and the ribs are the subject of local palpation techniques anteriorly. The spatial alignment of some of the ribs will now

become clear. The ability to conduct these techniques, especially the intercostal palpation, is the basis for the assessment of movement in the thorax during respiration.

The palpation of the scapula with its individual sections will not be discussed here. Explanations of this can be found in earlier chapters and in books on in vivo anatomy of the limbs (e.g., Winkel, 2004).

Correct palpation in the cervicothoracic region is used as a starting point to access the middle area of the thoracic spine and the posterior thorax. These regions could also be reached by starting inferiorly with the localization of the 12th rib or the lumbar spinous processes. This has already been described in Chapter 10, page 263.

Starting Position

All SPs used here have been described in detail in Chapter 8. The therapist is a new element in the description of the SP in sitting. The therapist stands to the side of the patient, mostly opposite the side to be palpated. If it is necessary to move the head to confirm the correct localization of a structure, the therapist facilitates the head movement with one hand and the other hand is used to palpate.

Difficult and Alternative Starting Positions

The SPs are always classified as difficult when access to the sought structure is obstructed, strong muscle activity prevents the therapist from being able to recognize a bony point precisely, or when the supportive surface is not large enough to provide a stable position for the patient. These positions can be encountered during clinical work with patients.

Examples:

- Palpating the cervicothoracic junction in the supine or side-lying position.
- Palpating the segmental thoracic mobility in sitting during movement.

Posterior Palpation Techniques

Overview of the Structures to be Palpated

- Cervicothoracic junction in the sitting SP.
- Cervicothoracic junction in the prone SP.
- Posterior palpation in the prone SP.

The exact palpation of the cervicothoracic junction is equally as important as the correct localization of the posterior sacroiliac spine (PSIS) on the pelvis or the C2 spinous process in the upper cervical spine. It enables thor-

acic structures to be reliably accessed from a superior position and the lower cervical spine from an inferior position. The aim is to precisely visualize the C6–T1 spinous processes as well as the position of the first rib from posterior. This is followed by the localization of all thoracic spinous processes and their relationship to their transverse processes and the corresponding ribs. This section concludes with several examples of assessment and treatment of the thoracic spine and the ribs that demonstrate how useful hands-on palpation is.

Cervicothoracic Junction in the Sitting Starting Position

The following technique aims to differentiate the thoracic and the cervical spines from one another. This cannot be done by locating the longest spinous process. The presumption that the longest spinous process corresponds to the vertebra prominens (C7) is misleading. The T1 spinous process is often the longer of the two.

Several of the following techniques require extensive cervical spine movement, which is not possible with every patient. They are only helpful when a certain amount of movement is available in the cervicothoracic region. When there are enormous restrictions in mobility in this region, differentiation is almost impossible. The only option that remains for differentiation is the palpation of the different contours felt on the spinous processes (e.g., C5 and C6).

Localization of the Spinous Processes Using Cervical Extension

One or two finger pads are placed over the middle of the posterior lower cervical spine. The anterior hand controls the position of the head (Fig. 11.22).

The position of the C6 spinous process can often be recognized by simply feeling its shape. When using moderate pressure to palpate from superior to inferior along the cervical mid-line, the therapist often feels the finger pads moving down onto a type of platform. The sides of the fingers come from a superior position and encounter the C6 spinous process. The finger pads are then lying on top of the C5 spinous process. As this method of localization is not reliable enough, another aid is needed to confirm that it is correct.

Confirmation with Movement

The anterior hand is in contact with the patient's head and facilitates cervical extension by tilting the head backward. The C5 and C6 spinous processes behave typically during this movement. The upper cervical vertebrae move posteriorly during cervical extension. C5 and C6 shift anteriorly (Fig. 11.23). C5 starts moving when extension is

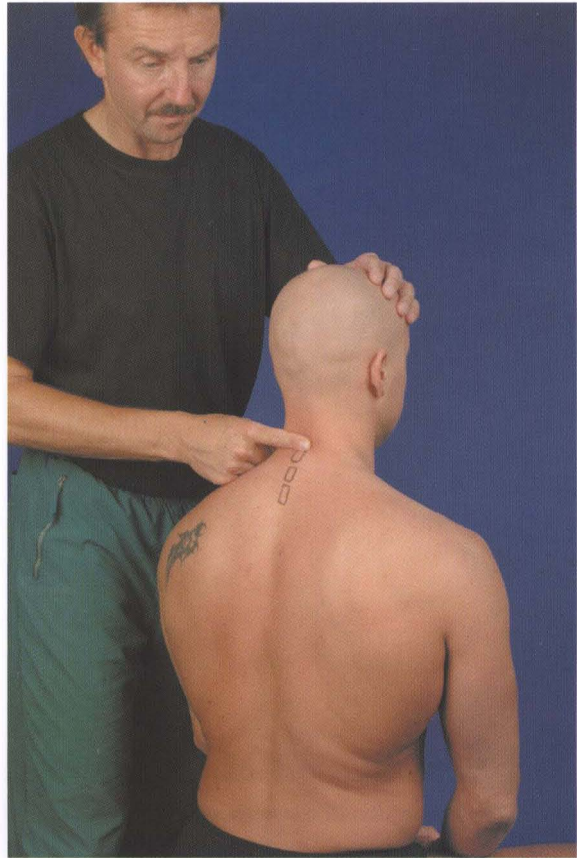


Fig. 11.22 Cervicothoracic palpation in the sitting SP.

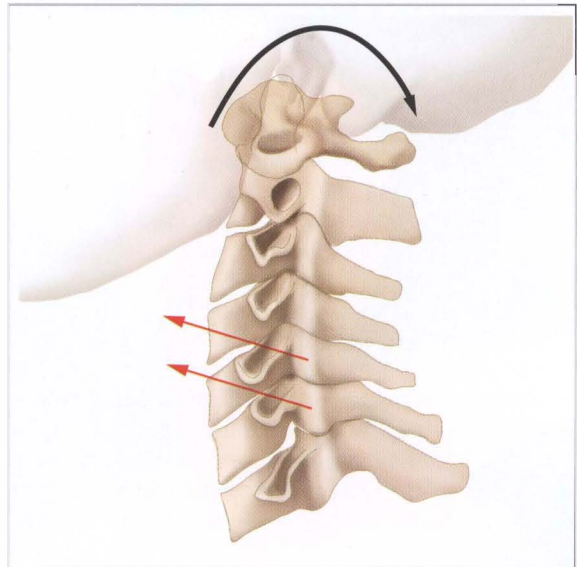

Fig. 11.23 Paradoxical translation of C5 and C6.

minimal, C6 at the end of the extension. These movements are clearly perceived as a spinous process disappears beneath the palpating finger pads.

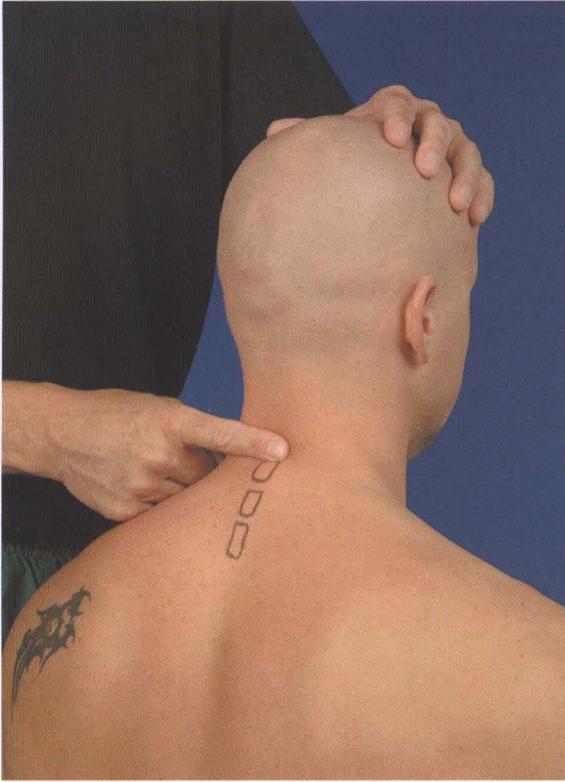


Fig. 11.24 Palpating the C5 spinous process—phase 1.

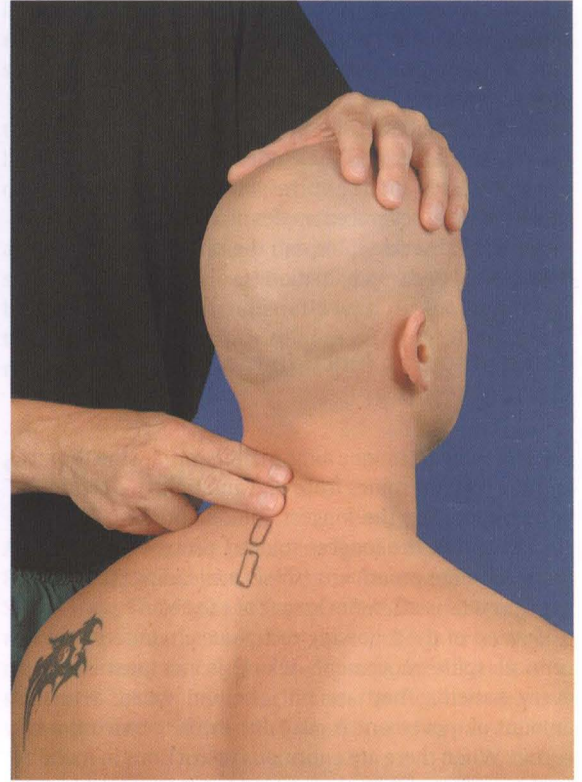


Fig. 11.26 Palpating the C6 spinous process—phase 1.

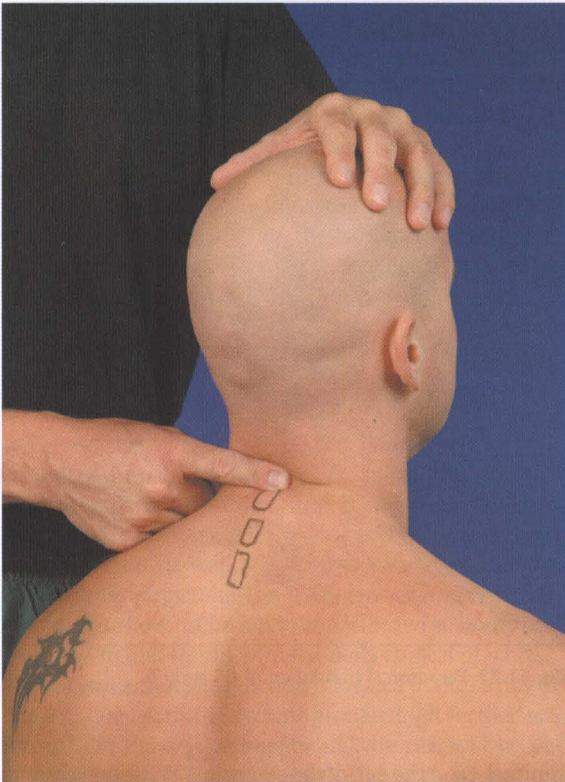


Fig. 11.25 Palpating the C5 spinous process—phase 2.

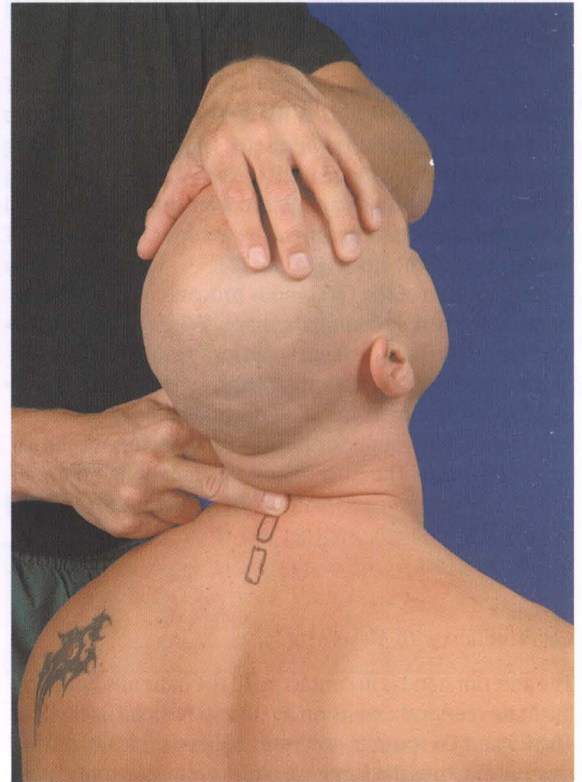


Fig. 11.27 Palpating the C6 spinous process—phase 2.

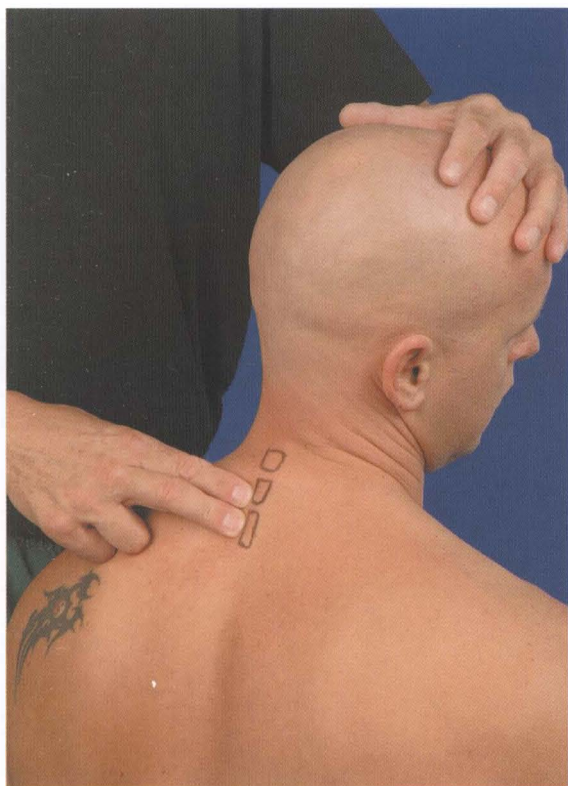


Fig. 11.28 Palpating the C7 and T1 spinous processes.

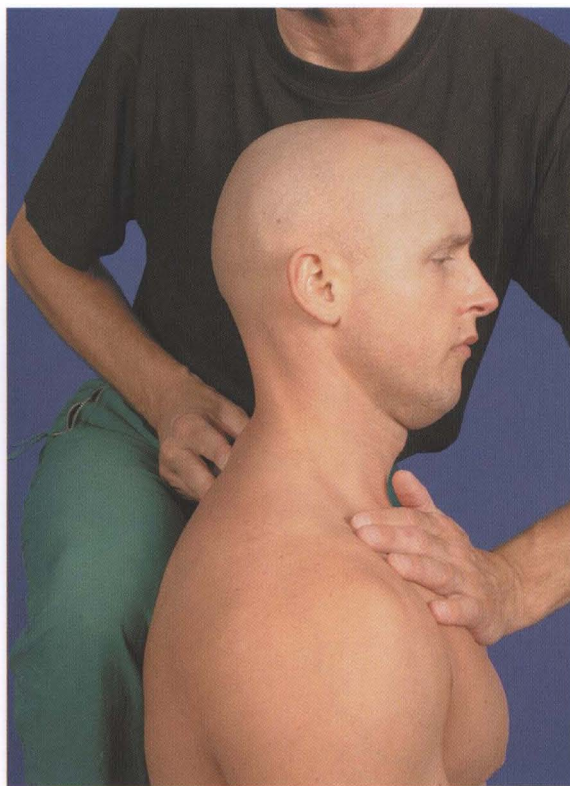


Fig. 11.29 Palpating T1 using posterior shift.

The index finger pad remains on the assumed location of the C5 spinous process (**Fig. 11.24**) and feels it disappearing anteriorly when extension is minimal (**Fig. 11.25**). The middle finger pad palpates the next inferior spinous process, most likely that of C6.

Cervical extension is repeated thoroughly (**Fig. 11.26**). It is only at the end of extension that the spinous process moves anteriorly underneath the middle finger pad (**Fig. 11.27**). This is the method used to precisely determine the position of the C6 spinous process.

The C7 spinous process is sought. It demonstrates a sudden decrease in movement during extension. The C7 spinous process remains more immobile in comparison to C5 and C6. Accordingly, the next inferior spinous process belongs to T1. This method enables the therapist to locate C5, C6, C7, and T1. However, this requires the patient to be able to extend the cervical spine without aggravating pain.

Localizing the Spinous Processes Using Cervical Rotation

The movement pattern of the lower cervical spine is always composed of lateral flexion associated with ipsilateral rotation. This coupling is very strong and develops independent of the facilitation of rotation or lateral flexion.

These movements continue onto the upper thoracic spine, to approximately T4–T5. Extensive rotation or lateral flexion in the cervical spine can therefore be used to palpate movement at the cervicothoracic junction.

End-range cervical rotation or lateral flexion to the right always results in all spinous processes down to and including T4 rotating to the left. This occurs to different degrees. T1 and the vertebrae inferior to it are fixed by the ribs and the range of motion is reduced. It is therefore expected that rotation can only be detected down to the C7 spinous process.

The therapist is positioned next to the patient. When the therapist wishes to facilitate cervical rotation or lateral flexion to the right, two palpating fingers must be placed paravertebrally to the left of the cervicothoracic region.

They are placed against the left side of the assumed C7 and T1 spinous processes. When rotation or lateral flexion is facilitated, C7 is expected to move significantly further than the more slowly reacting T1 spinous process (**Fig. 11.28**).

Localizing T1 Using a Posterior Shift

So far, T1 has been characterized as a rigid vertebra with little mobility. The following differentiation method uses the intensive contact between T1 and the first rib ring seg-

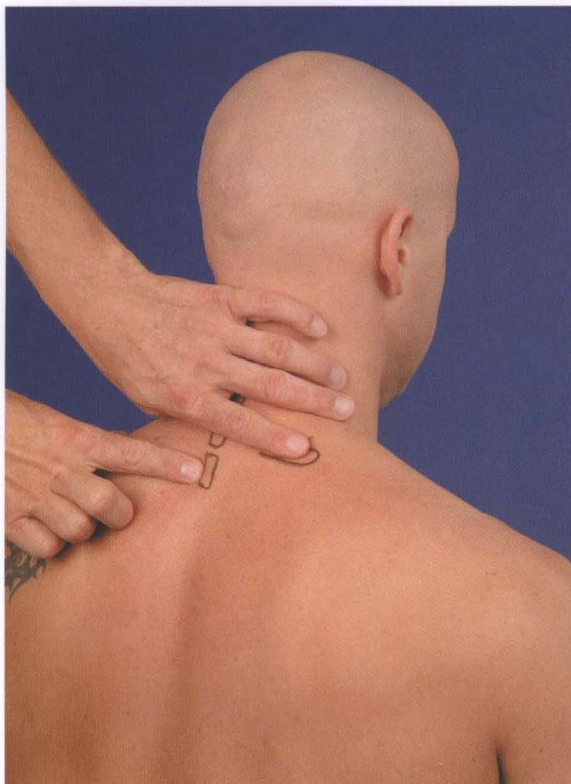


Fig. 11.30 Projection of the T1 transverse process.

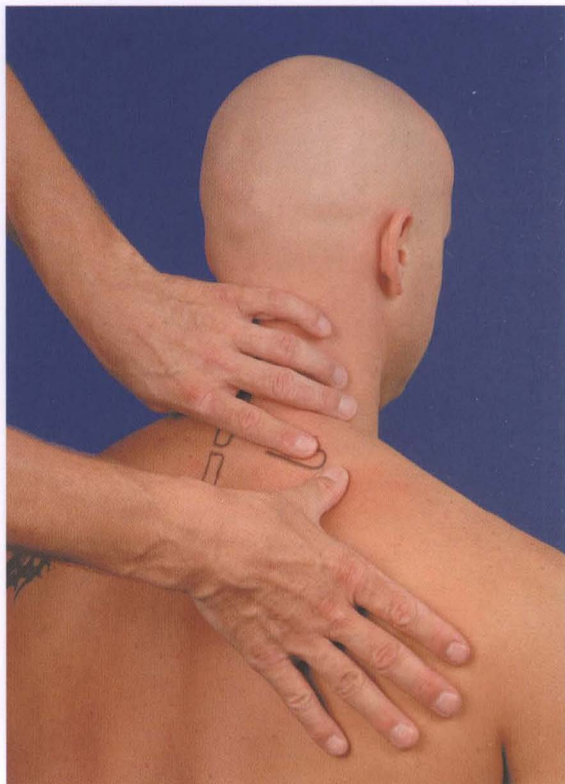


Fig. 11.31 Locating the first rib—phase 1.

ment. A translation movement of the first rib applied from anterior is felt posteriorly on the spinous process (**Fig. 11.29**).

Two finger pads are placed posteriorly in the C7/T1 and T1/T2 interspinous spaces. The thenar eminence of the anterior hand applies a posterosuperiorly directed pressure onto the manubrium. This pressure is transmitted onto T1 via the first rib. The return movement of the T1 spinous process is palpable. The C7 spinous process tends to remain still. Up to three spinous processes move in flexible patients, with T1 moving the furthest.

Projection of the T1 Transverse Process

The T1 spinous process is located using the previously described options available for differentiation. Its inferior edge is marked on the skin. Starting from the inferior edge of the spinous process, the therapist now measures a patient's index finger-width in a superior direction and approximately one patient's index finger-length laterally (**Fig. 11.30**).

This usually corresponds to the width of the T1 transverse process. The width of both T1 transverse processes is comparable to the distance between the tips of both C1 transverse processes (see the palpation techniques in the cervical spine).

Tip: The tip of the transverse process is always found in a muscular gap formed by the descending and transverse parts of the trapezius. The muscles (e.g., levator scapulae) nevertheless prevent direct contact with the transverse process and the rib.

However, therapists should always ensure that they are not mistakenly on the superior angle of the scapula by slightly elevating the scapula (see the section “Superior Angle of the Scapula” in Chapter 2, p. 23).

Localizing the First Rib from Posterior

On the posterior aspect, the first rib can only be found directly adjacent to the assumed tip of the T1 transverse process. It changes its course from here onward, moves anteriorly, and cannot be palpated anymore posteriorly. It can only be palpated through a layer of muscles by placing a thumb directly adjacent to the tip of the T1 transverse process (**Figs. 11.31** and **11.32**).

Confirmation Using the Assessment of Consistency and Movement

Aim: The junction between the tip of the transverse process and the first rib can only be correctly identified by assessing the end feel of both structures.

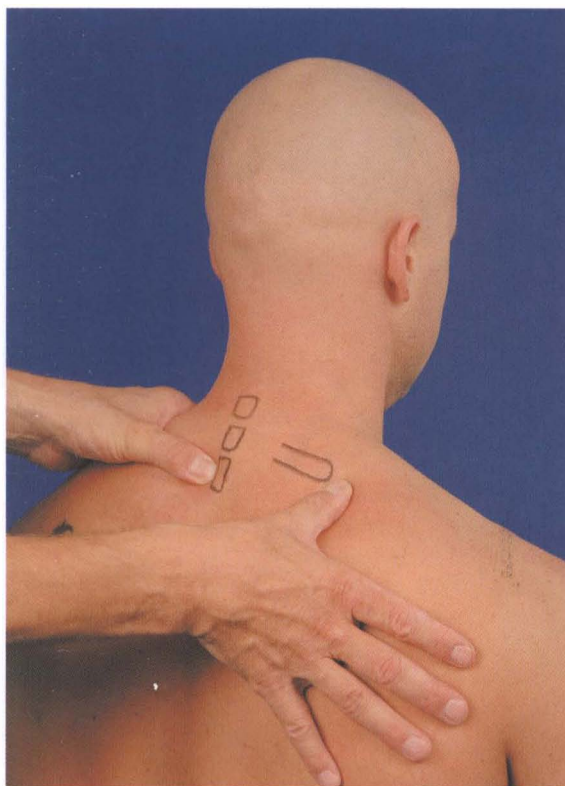


Fig. 11.32 Locating the first rib—phase 2.

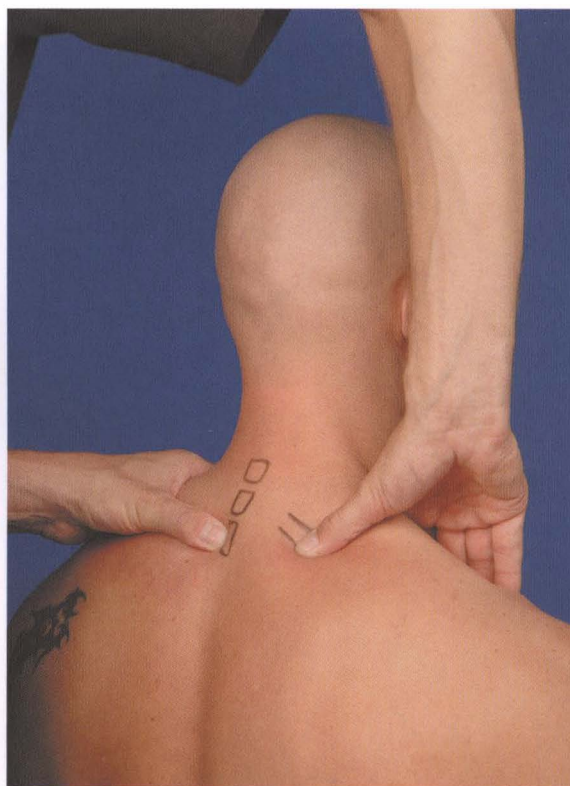


Fig. 11.33 Confirming the position of the T1 transverse process.

Criteria: The thumb applies pressure onto the first rib and the T1 transverse process in an anterior and slightly medial direction. The first rib feels less firm than the transverse process. Naturally, the spinous process moves more clearly when pressure is applied onto the transverse process compared with pressure on the first rib. Some energy is absorbed by the costovertebral joints here.

Procedure: A thumb is placed over the T1 transverse process (right here). The other thumb braces itself against the T1 spinous process from the left side (Fig. 11.33). Pressure on the transverse process rotates T1 to the left and the spinous process to the right. This is clearly felt as a decrease in pressure at the spinous process.

When the thumb is placed adjacent to the tip of the transverse process on the first rib and posteroanterior pressure is applied again, the therapist will feel the structure yielding slightly to pressure and resisting movement, not as firmly as is felt when pressure is applied to the transverse process. Associated T1 spinous process movement is still felt to a small extent (Fig. 11.34).

Tip: Firm pressure must be applied to a layer of muscle that is frequently sensitive to pressure when this technique is used for differentiation. This difficulty is only slightly reduced by pressure being applied to the gap in the trapezius and the fact that the muscle layer is not particularly thick.

This differentiation technique requires a minimal amount of mobility in the costotransverse joint of the first rib.

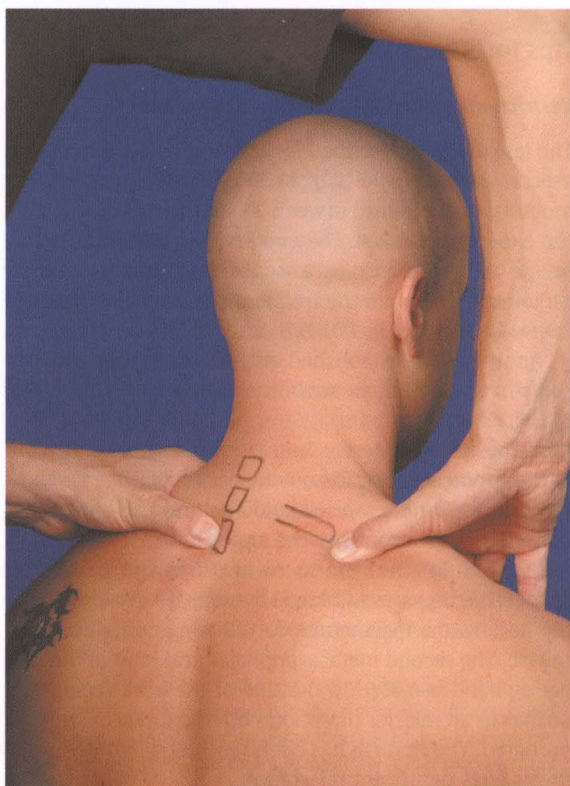


Fig. 11.34 Confirming the position of the first rib.

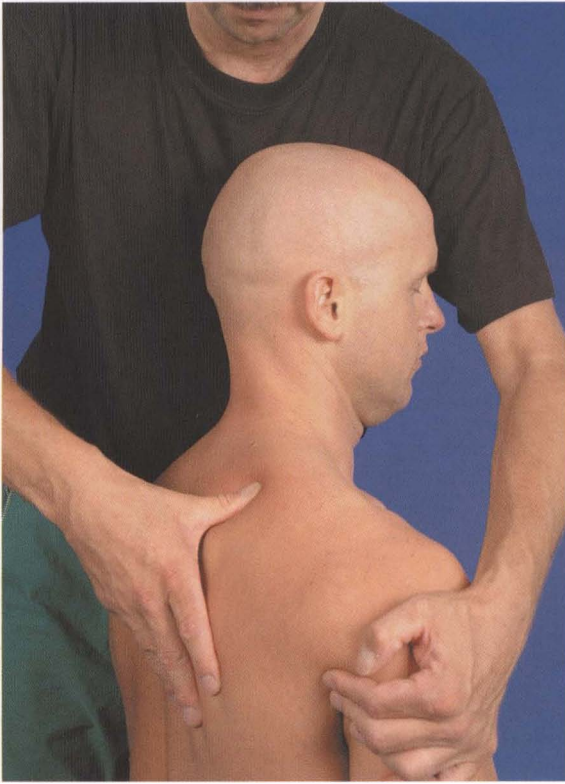


Fig. 11.35 Pain provocation of the first rib from posterior.

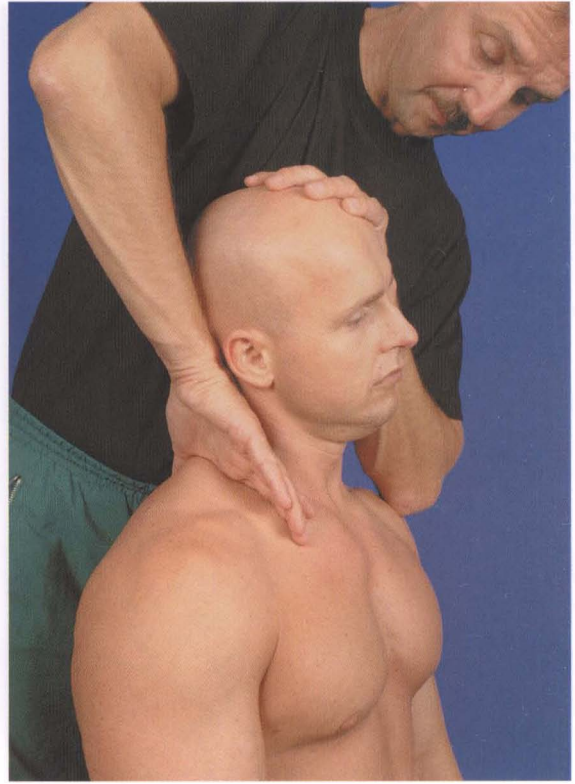


Fig. 11.36 Springing test

Tips for Assessment and Treatment

Restrictions in First Rib Mobility—Assessment

The last method described for differentiation can also be used to provoke pain (Fig. 11.35). Painful restrictions in mobility in the joint between T1 and the first rib affect the expected end feel. The end feel is harder and is perceived as painful in most cases. Restrictions in the first rib joint mobility are the frequent cause of a persistently “tensed trapezius.”

Another, well-established test—the springing test—can confirm restriction in mobility during inhalation (Fig. 11.36).

Aim: The springing test assesses movement in the first rib in the supraclavicular fossa with a sitting SP.

Procedure: The therapist stands behind the sitting patient. An elbow controls the upper body. The hand is used to position the head. In the next step, the descending part of the trapezius is relaxed by slightly laterally flexing the neck to the ipsilateral side, allowing easier access to the rib. The second metacarpophalangeal joint of the palpating hand is placed to the side of the neck region and pushes in an inferior direction with the forearm strongly pronated. The first rib has been reached when the index finger feels significant resistance.

Criteria: Repeated pressure indicates how much inferior movement is possible and how the rib resists movement

as it “springs” up and down. The first rib is expected to have a firm-elastic feel. The rib only moves slightly, or not at all, when the rib is blocked in a position of inhalation. It resists movement very strongly. In most cases, the patient indicates that their symptoms are being aggravated during this procedure.

Restrictions in First Rib Mobility—Treatment

Aim: To relieve pain or mobilize the costovertebral joints between T1 and the first rib in a neutral supine position.

Procedure: The T1 transverse process is located in the supine position. The junction to the first rib is identified once again by assessing tissue consistency. The index finger is strongly flexed and its proximal interphalangeal (PIP) joint is placed on the posterior aspect of the first rib. The other fingers are also flexed and support the index finger. The thumb may be placed anteriorly, but should not apply pressure. The PIP of the index finger is now found in the gap in the trapezius, superior to the superior angle of the scapula in most cases. To ensure that the fingers are not mistakenly in contact with the superior angle, the therapist assesses the localization by moving the scapula into elevation and depression (Fig. 11.37). No movement is expected to be felt beneath the index finger joint. Otherwise, the localization must be assessed again.

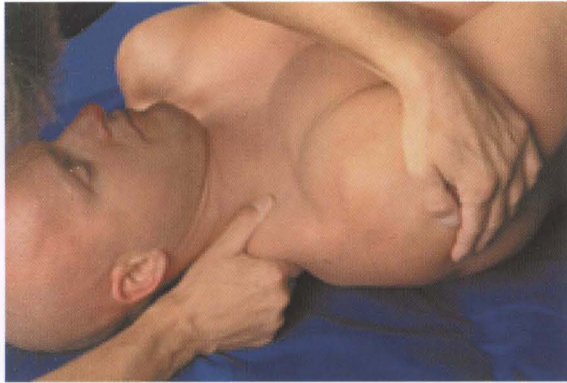

Fig. 11.37 Treating the first rib—phase 1.

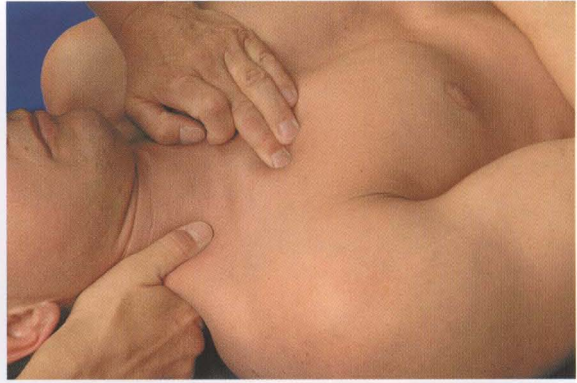


Fig. 11.38 Treating the first rib—phase 2.

The PIP joint of the index finger now applies pressure in an anterior and slightly medial direction. The necessary strength is obtained by abducting the wrist. The therapist may feel slight movement anteriorly on the first rib on some patients. To feel this, the therapist places the fingers of the second hand anteriorly over the first rib (Fig. 11.38). The force used and the speed of movement depend on the aims of treatment:

- Pain relief: oscillations are used with quick, very small movements that should not provoke pain.
- Mobilization: pressure is applied until the tissue becomes taut. Pressure is repeatedly applied using small intensive movements every second for several minutes.

Functional Massage of the Descending Part of the Trapezius

The functional massage in side-lying is one of the most effective methods available to reduce tension in the frequently tense descending part of the trapezius. This technique is integrated into massage therapy after large surface techniques (stroking and kneading) have been used. As changing position can be troublesome for patients, only one technique should be conducted per treatment. The technique combines a longitudinal stretch (shoulder girdle movement) with a transverse stretch (pressure applied by the hand).

Starting position: The patient lies on the stomach and slides to the side of the treatment table. They then roll over into side-lying and move as far as possible toward the edge of the treatment table, with their back to its edge. The therapist stands at this edge and stabilizes the patient with their body (Fig. 11.39).

Preparation: The technique starts with the passive movement of the shoulder girdle, for which both hands are placed on the shoulder. This exercise is used to help the patient learn to perceive movement in the shoulder girdle and to relax their muscles. This is possibly all that will be achieved in the first treatment session. The shoulder girdle is facilitated first into elevation and depression as

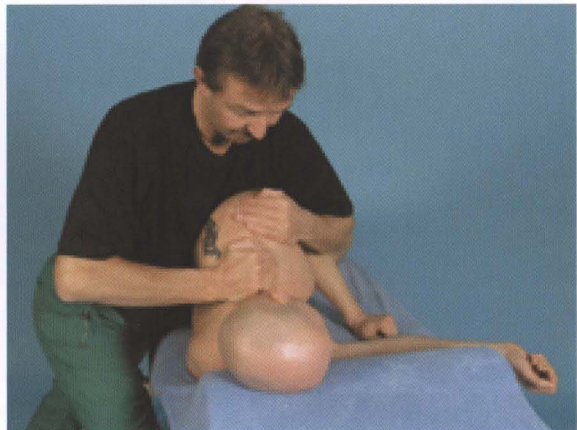


Fig. 11.39 Functional massage of the trapezius—SP.

well as protraction and retraction. Diagonal movements follow.

Variation 1—with depression and retraction:

- **Hand placement:** one hand is placed on top of the shoulder joint and facilitates the shoulder girdle. The second hand holds onto the descending part of trapezius using a “palmar grip.”
- **Technique:** the muscle is approximated somewhat by slightly elevating and protracting the shoulder girdle (scapula moves forward and upward). The thenar eminence is used to push the muscle anteriorly without allowing the hand to slide over the skin. The shoulder girdle is facilitated into extensive depression and retraction (“scapula moves downward and backward”) (Fig. 11.40). The stretch should be stopped if the muscle belly slides out from underneath the hand.

Tip: If the base of the hand constantly rubs against the superior angle of the scapula during the previously described technique, extensive external rotation of the scapula can be used to move the superior angle inferiorly out of the way. This is achieved by elevating the arm extensively through flexion of the shoulder joint. This position must be maintained. There is

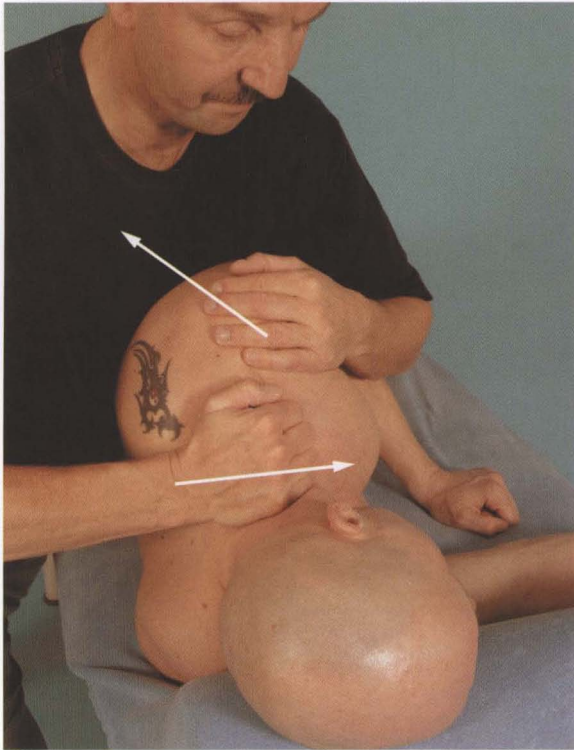


Fig. 11.40 Functional massage of the trapezius—variation 1.

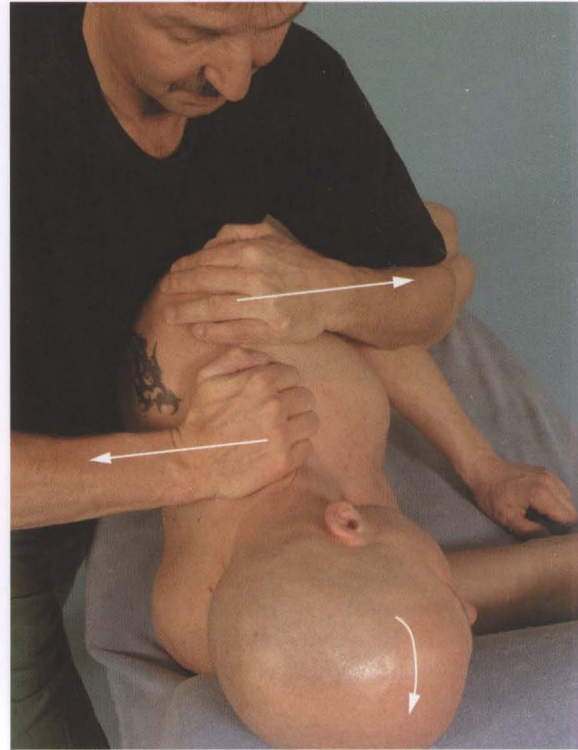


Fig. 11.42 Functional massage of the trapezius—variation 2.

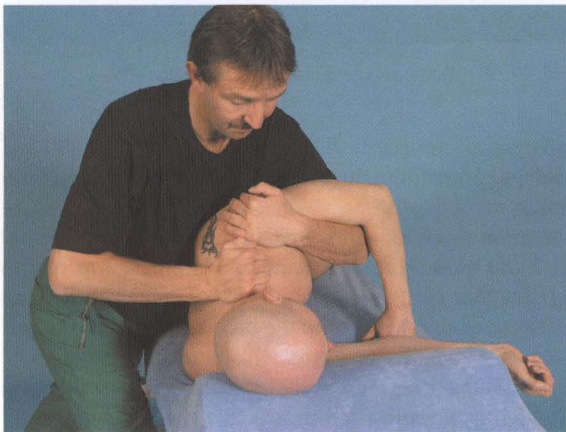


Fig. 11.41 Functional massage of the trapezius—variation in the SP.

then more space for the molding hand over the trapezius (Fig. 11.41).

This technique is more effective when the cervical spine is positioned in lateral flexion away from the side to be treated (by lowering the head end of the treatment table or by not using a pillow). This results in the muscle being placed in a position of high preliminary stretch, improving the stretching effect considerably. *Caution:* The patient must be able to laterally flex without aggravating pain. This must be assessed before applying the technique.

Variation 2—with depression and protraction:

- *Hand placement:* the same hand placement is used here as with variation 1.
- *Technique:* the muscle is approximated somewhat by slightly elevating and retracting the shoulder girdle (scapula moves backward and upward). The slightly flexed fingers pull the muscle posteriorly without allowing the fingers to slide over the skin. The shoulder girdle is facilitated into extensive depression and protraction (“scapula moves forward and downward”) (Fig. 11.42). The stretch should be stopped if the muscle belly slides out from underneath the hand. The therapist should exercise caution when using the fingertips to palpate, as sensitive structures are found in the supraclavicular fossa (brachial plexus and vessels). This technique variation can also be conducted by initially positioning the cervical spine in lateral flexion.

Cervicothoracic Junction in the Prone Starting Position

If more precise assessment or treatment is going to be conducted in the prone position, it makes sense to also differentiate the vertebrae in the cervicothoracic junction in this SP. When switching to the prone position, it is not advisable to use the marks on the skin showing the spi-

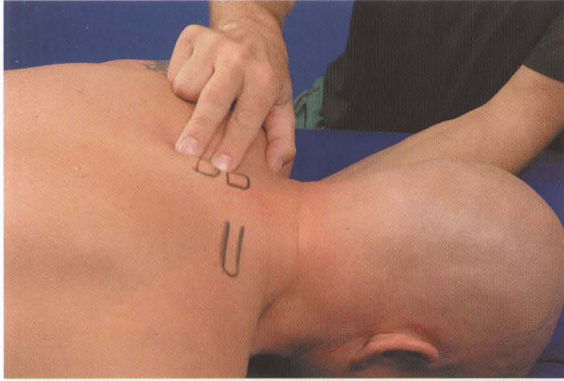


Fig. 11.43 Locating the T1 spinous process.

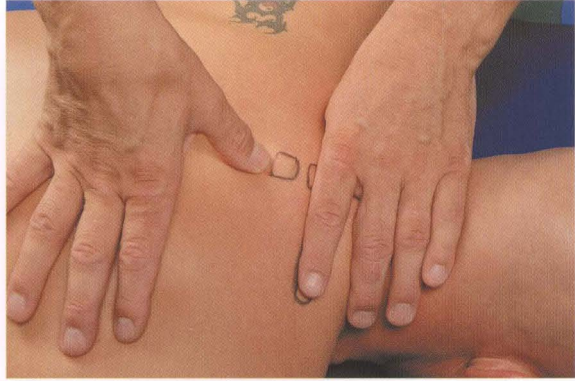

Fig. 11.44 Locating the T1 transverse process.

nous processes found during the palpation in sitting. The skin is subject to the effects of gravity and sags in sitting. This is different in the prone position. If the therapist were to use the markings from sitting in the prone position, the markings would be approximately one segment too high!

Localization of the T1 Spinous Process Using Posterior Shift

The previously described localization techniques using cervical extension and rotation or lateral flexion are difficult to conduct in the prone position. The technique of choice is the anteroposterior pressure via the manubrium. The procedure and criteria basically correspond to the description for sitting.

Without the weight of the head, the applied pressure results in a larger and significantly more palpable posteriorly directed movement in the T1 spinous process (Fig. 11.43). This technique is therefore a recommended method for localization.

It is only in cases of severe restrictions in segmental mobility in this region that the use of this method for localization will not be successful. If the C6 “platform” can be felt in sitting or in the prone position (see above), the inferior edges of the C6 to T1 spinous processes can be counted.

Tip: Only a few finger pads can be used to apply the very local pressure onto the manubrium. Therapists should ensure that they are not pushing against the patient's throat. Patients often hold their sternum and shoulders in a posterior position, even when the pushing fingers have taken up their position. If necessary, the patient must be instructed to relax the shoulders and upper body and rest them on the treatment table.

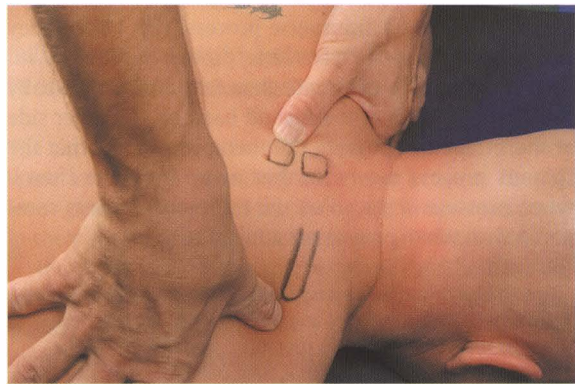


Fig. 11.45 Locating the first rib.

Projection of the T1 Transverse Process in the Prone Position

The T1 transverse process is found one index finger-width superior to the spinous process. The inferior edge of the T1 spinous process is located first and a finger-width is measured superior to the tip of the spinous process (Fig. 11.44). The width of the transverse process corresponds again to the entire length of the (patient's) index finger. The tip of the index finger points to the gap in the muscles between the upper and middle sections of the trapezius.

Locating the First Rib from Posterior

The tip of the T1 transverse process is marked on the skin. The accessible section of the first rib lies immediately lateral to this. The junction between the transverse process and the rib can only be palpated on very slim people. This is also the case in the sitting SP. The position of the structures projected onto the skin must therefore be assessed (Fig. 11.45). Again, the tissue resistance felt on direct pressure and the associated movement of the T1 spinous process play decisive roles. When the therapist applies pressure alternately to the assumed position of the

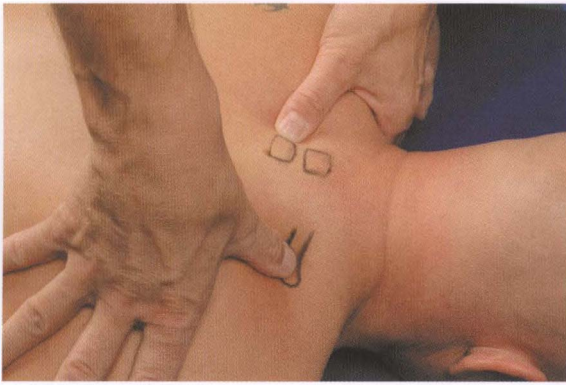


Fig. 11.46 Confirmation by assessing the consistency.

first rib and the T1 transverse process (Fig. 11.46), they realize again that the transverse process responds with considerably more resistance than felt in the first rib. By placing the thumb of the second hand on the other side of the T1 spinous process, the therapist can feel that the spinous process moves further away from the thumb when pressure is placed on the transverse process compared with when pressure is applied to the rib.

Tip: The costotransverse junction is usually found to be more superior than the superior angle of the scapula. It is nevertheless recommended that therapists passively move the shoulder slightly to ensure that their palpating hand is not mistakenly positioned over the angle of the scapula. After the therapist has gained some experience, the gap in the trapezius can be used for vague orientation to infer the level of the T1 spinous process. To do this, the gap in the muscle is located first, its level is transferred onto the vertebral column and the therapist palpates one index finger-width superior to this position. It is highly likely that the T1 spinous process can be found here.

Posterior Palpation in the Prone Starting Position

Locating the Other Thoracic Spinous Processes

There are principally three methods available to determine the position of the thoracic spinous processes:

- Identifying the level by using the structures of the scapula for orientation.
- Palpating from an inferior position by correctly locating the lumbar spinous processes or locating T11 via the 12th rib (see the section “Local Bony Palpation” in Chapter 10, p. 263).
- Palpating from a superior position by locating the position of the spinous processes at the cervicothoracic junction (see the section “Cervicothoracic Junction in the Prone Starting Position” above, p. 292).

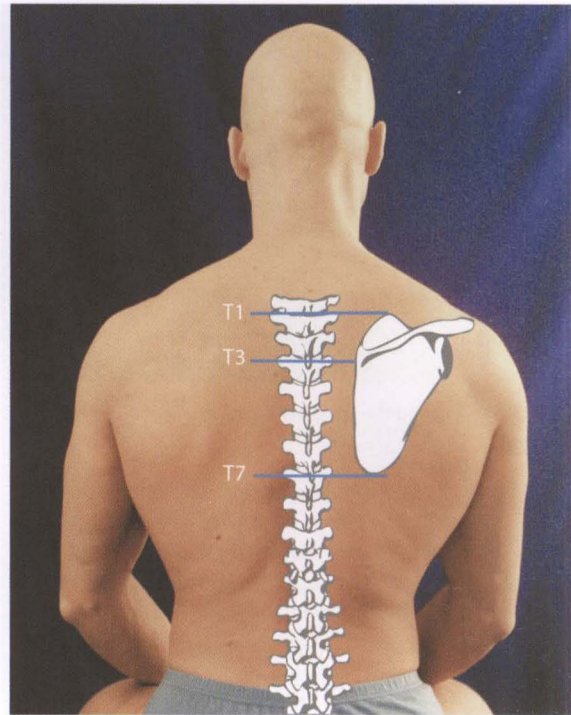


Fig. 11.47 Using scapular structures to locate a level.

When locating the spinous processes, the use of scapular bony landmarks for orientation is fairly unreliable as the size and position of the scapula vary between individuals. It is nevertheless suitable for rough orientation (Fig. 11.47). The following classifications are recommended by Hoppenfeld (1992), Kapandji (1985), and Winkel (2004):

- The T1 spinous process and the second rib are found at the level of the superior angle of the scapula.
- The base of the spine of the scapula is found at the level of the T3 spinous process.
- The inferior scapular angle is found at the level of the T7 spinous process.

These classifications only apply to the vertical body posture. They do not apply to patients positioned in lying.

The palpatory process following the localization of T1 is called the superior access. All further thoracic spinous processes can be located from here. The individual spinous processes are followed inferiorly. The lower edge of the processes should be used if the therapist wishes to correctly mark the location of the spinous processes on the skin.

Starting position: It is possible to palpate in sitting, in the prone position, and in side-lying. The prone and side-lying SPs are easier for palpation than the sitting SP. The tension in the intrinsic muscles near the mid-line (especially

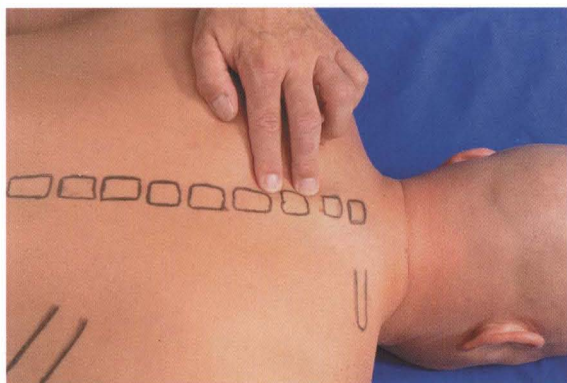


Fig. 11.48 Locating the levels using palpation starting from a superior position.

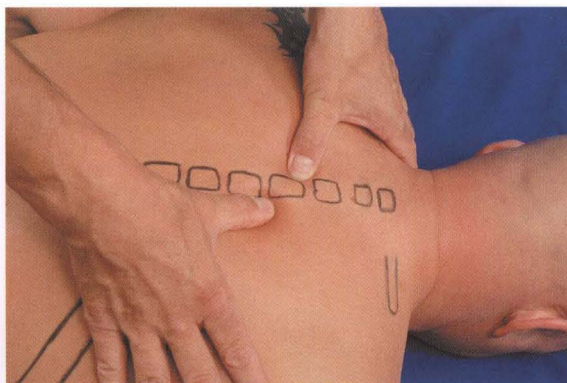


Fig. 11.49 Alternating palpation from the left and the right.

spinalis) makes it more difficult to gain access to the bony contour of a spinous process in the sitting SP.

Lowering the head end of the treatment table significantly should be avoided when positioning the patient in prone position, as this places the interspinous ligaments under too much tension and makes localization more difficult. Prepositioning in a slight kyphosis approximates the spinous processes and also hinders the palpation.

Technique: The finger tips are placed perpendicular along the inferior edge of the spinous process. It is recommended that the interspinous space be found again using palpation. Interspinous spaces can be most skillfully palpated from the side and not from posterior (**Fig. 11.48**). The tensed supraspinous ligament, covering the interspinous space, often makes it more difficult to palpate the contours of the spinous processes. Once the interspinous space has been palpated, the inferior edge of the more superiorly located spinous process can be marked with certainty.

All spinous processes can be marked using this method. This technique is reliable at the thoracolumbar junction when the area is accessed from an inferior position. Furthermore, it is helpful to know what changes are to be expected in the shape of the spinous processes. Once the therapist has reached L1, the pointed and rounded forms of T11 and T12 change into long processes with larger dimensions.

Tip: The interspinous space can be palpated from both sides if the therapist needs further reassurance that the correct structure is being palpated. The most reliable method is to search for the interspinous spaces alternatively from the left and the right (**Fig. 11.49**). With this method, the palpating finger from one hand maintains contact with the correctly located interspinous space until the next inferior interspinous space has been located.

Difference in Height between the Spinous Process and Transverse Process of a Vertebra

The aim is to locate a spinous process in the mid-thoracic spine and its corresponding transverse process. The following exercise provides therapists with more confidence in their ability to exactly locate at every thoracic level.

It is typical for the thoracic vertebrae that there is a difference in height between the spinous process and the transverse process. The extent almost varies from segment to segment. This method of palpation uses the width of the patient's index finger in an attempt to specify the difference in height.

When the therapist wishes to access the transverse process of a specific vertebra, they calculate the superior distance using a certain number of finger-widths from the spinous process (**Fig. 11.50**). The transverse process and its corresponding rib are found at the same height. The procedure described here can therefore also be used to correctly locate the ribs.

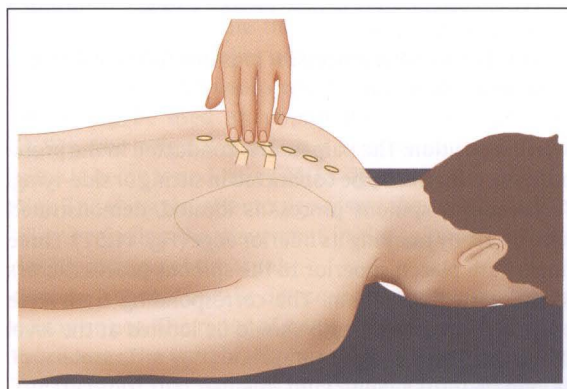


Fig. 11.50 Using the finger rule.

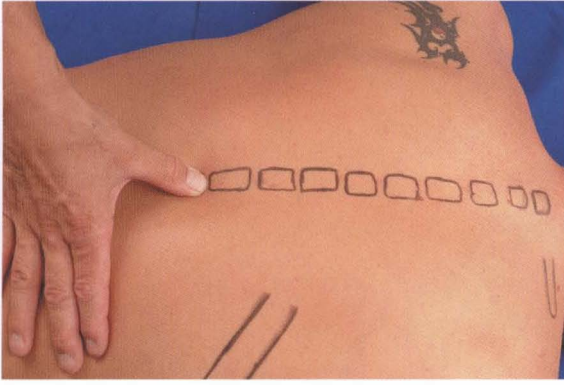


Fig. 11.51 Locating the T8 spinous process.

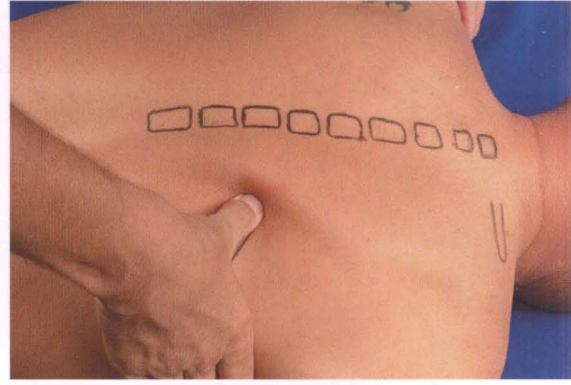

Fig. 11.53 Palpating the tip of the transverse process.

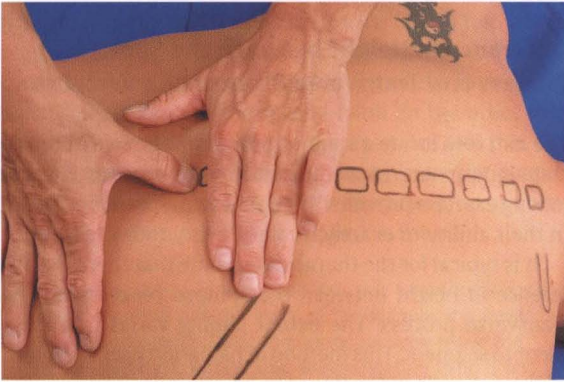

Fig. 11.52 Searching for the transverse process.

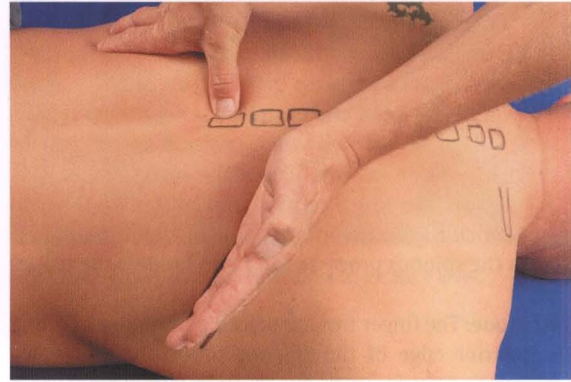

Fig. 11.54 Confirmation using movement.

Finger rule:

- T1, T2 spinous processes: plus one finger-width in a superior direction.
- T3, T4 spinous processes: plus two finger-widths in a superior direction.
- T5 → T8 spinous processes: plus three finger-widths in a superior direction.
- T9, T10 spinous processes: plus two finger-widths in a superior direction.
- T11, T12 spinous processes: plus one finger-width in a superior direction.

Starting position: The palpation is conducted in the prone position, but can also be conducted in sitting or side-lying.

Technique: A spinous process is located, demonstrated here on T8, by marking its inferior edge (Fig. 11.51). Three fingers are placed superior to the spinous process across to the vertebral column. The corresponding transverse process and the eighth rib should be located at the level of the third finger (Fig. 11.52).

Tip: The width of the fingers used should correspond to the patient's fingers. Measurements should be made to be on the safe side.

The correct localization is confirmed using the corresponding palpable rib found at the same level. After using the finger rule, the rib is searched further laterally with a transverse palpation technique. The transverse process is found at the level of the most medial palpable aspect of the rib (angle of the rib). A step can often be felt between the rib and the tip of the transverse process when using the fingertips to palpate perpendicular to the skin (Fig. 11.53).

Confirmation Using the Assessment of Consistency and Movement

The link between the spinous process and the transverse process can be observed during segmental movement. This involves applying pressure to the transverse process while palpating the corresponding spinous process from the opposite side. The palpating finger can also be placed in an interspinous space. Posteroanterior pressure applied to the transverse process rotates the vertebra, for example, using the medial edge of the hand (Fig. 11.54). The corresponding spinous process then rotates to the side of pressure and moves away from the palpating finger. It is recommended that pressure be released quickly as the return movement is often easier to feel than the movement into rotation.

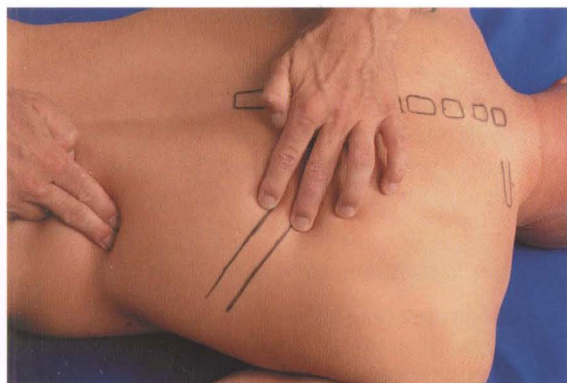


Fig. 11.55 Palpating the ribs from inferior.

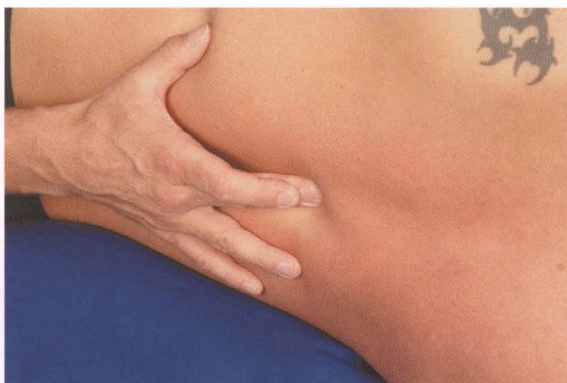

Fig. 11.57 Position of the palpating fingers.

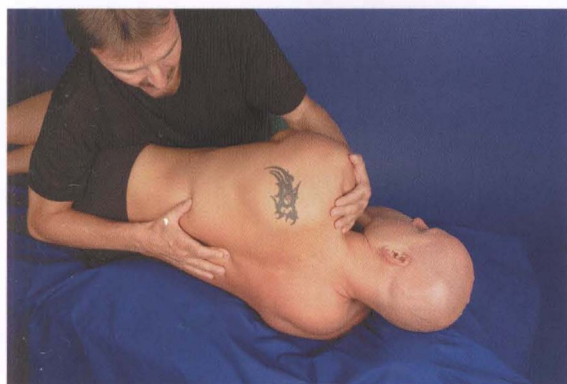


Fig. 11.56 Segmental mobility test, thoracic—SP in side-lying.

The transverse process can be differentiated from the rib using the same technique. In this case, the medial border of the hand is placed more laterally on the rib and posteroanterior pressure is repeated. The rib demonstrates an elastic form of resistance, the movement in the spinous process is somewhat delayed and smaller than was previously seen when pressure was applied to the transverse process.

Confirming the Palpation of the Ribs from an Inferior Position

The reverse process can also be successfully used (locating a spinous process from the rib via the transverse process). The ribs are palpated one by one from the 12th rib upward (Fig. 11.55), the level for the corresponding transverse process is located, and the finger rule is used in an inferior direction to find the respective spinous process. This method is recommended for use in the area between approximately T7 to T12. The scapula covers a large part of the ribs more superiorly.

Tips for Assessment and Treatment

There are a large number of options for treating the thoracic spine. Tactile perception and very exact anatomical orientation are of great use. The following section includes several descriptions of thoracic spine and costovertebral joint assessment and treatment techniques frequently seen in the daily clinical practice. This listing is certainly not complete.

Segmental Assessment of the Thoracic Spine

One example of a local segmental assessment technique is the assessment of mobility combined with a coupled pattern of movement. Contralateral rotation (left) and lateral flexion (right) are coupled here in combination with extension.

Technique in the Side-lying Starting Position

The patient lies in neutral side-lying (here, on the right) near the side of the therapist. The therapist places one hand on the upper-lying side of the thorax. The other hand is used to palpate the thoracic spine (Fig. 11.56). The middle finger applies pressure from an inferior direction into the interspinous space. If necessary, the index finger may be used to support the middle finger (Fig. 11.57). The original functional section of the thoracic spine is being tested here (T4/T5–T9/T10).

Aim: The therapist attempts to assess the segmental mobility by feeling the movement in the spinous processes during rotation of the trunk.

Criteria: It should only be determined whether movement occurs or not. The range of motion is not assessed.

Procedure: The vertebral column is in a neutral position. The therapist first palpates interspinally from an inferior position and assesses the shape and alignment of the spinous processes compared with each other. Therapists should remind themselves at this point that the spinous processes may deviate up to half a centimeter from the

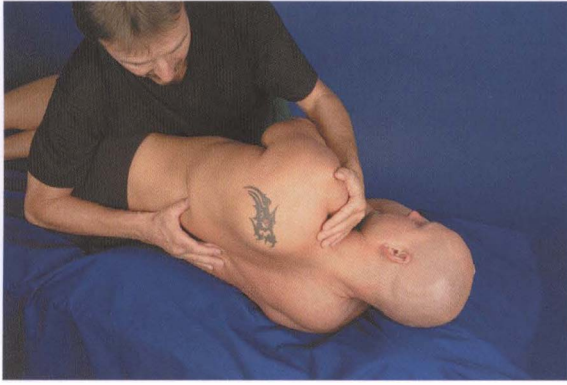


Fig. 11.58 Segmental mobility test, thoracic—final position.

midline due to a “normal” variation in shape. The position of the spinous processes should therefore only be palpated at this stage and not evaluated further.

The therapist facilitates rotation of the trunk from superior until the movement reaches the palpating finger (Fig. 11.58). The therapist immediately repeats palpation of the position of the spinous processes in this segment. The upper body is then returned to a neutral position. Next, the palpating finger locates the inferior segment. The test is repeated.

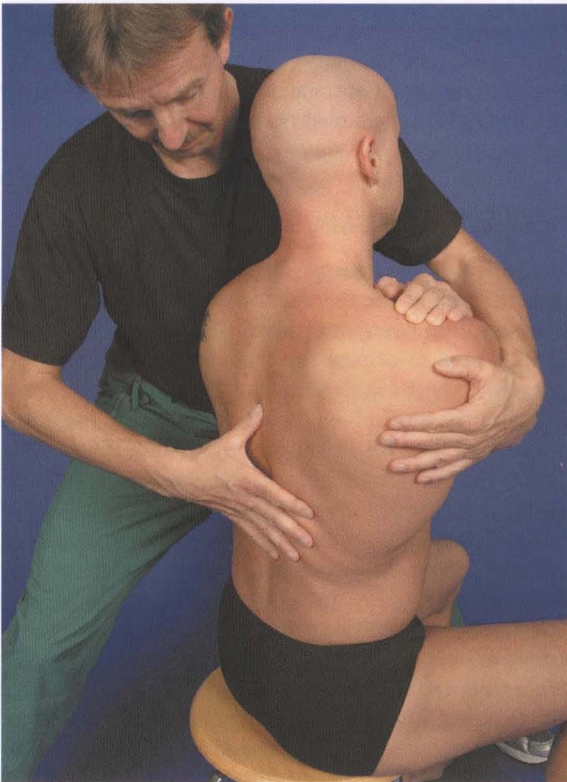


Fig. 11.59 Segmental mobility test, thoracic—SP in sitting.

Interpretation: Segmental mobility is classified as normal in this test when the superior spinous process in the segment first moves (spatially downward) and the inferior spinous process remains immobile. The palpating finger feels a clear step between both spinous processes. In cases of restricted segmental mobility, no step is formed and both spinous processes move simultaneously.

Technique in the Sitting Starting Position

This mobility test can also be conducted in a position with loading, that is, in sitting. Compared with side-lying, this SP has considerable advantages and disadvantages. One advantage is that segmental mobility under loading is more obvious in this position. A disadvantage is that the patient is not relaxed and the paravertebral muscles are permanently active to a small extent. As the intrinsic thoracic muscles are found directly adjacent to the row of spinous processes (spinalis) at times, the access to the interspinous space can only be obtained by palpating with firm pressure (Fig. 11.59). This makes the palpation not as exact. Conclusion: therapeutically useful, but palpation is significantly more difficult.

The aims, criteria, procedure, and interpretation are the same as for the previous description. The procedure described here involves the same coupling of lateral flexion (here left) and rotation (here right) in opposite direc-

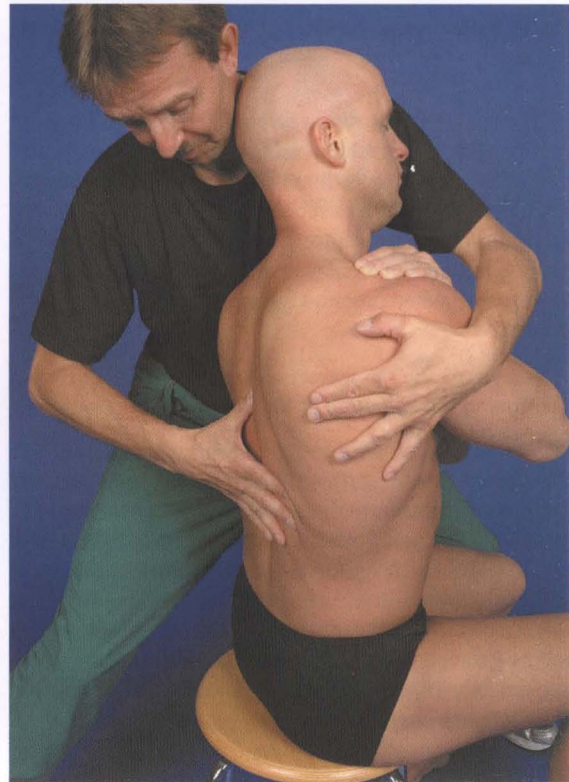


Fig. 11.60 Segmental mobility test, thoracic—final coupled position in extension.

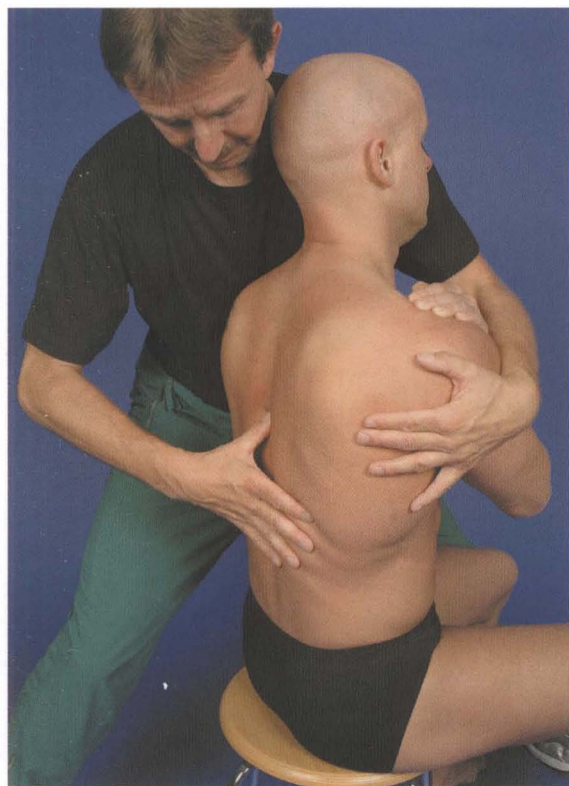


Fig. 11.61 Segmental mobility test, thoracic—SP in sitting.

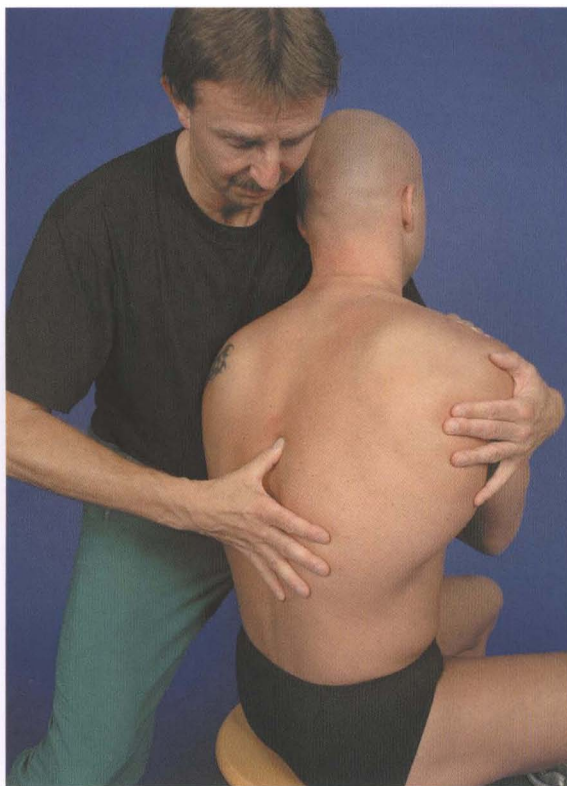


Fig. 11.62 Segmental mobility test, thoracic—final coupled position in flexion.

tions combined with the extended position. The palpating thumb is placed over the interspinous space on the therapist's side (here the left side). The spinous processes rotate to this side. The other hand facilitates the upper body from a neutral and upright sitting position into rotation and lateral flexion (Fig. 11.60).

Only two points have to be altered if the mobility test is used to assess the segmental mobility during coupled movements of lateral flexion and rotation in the same direction (here to the left) in a flexed position:

- The thumb of the palpating hand is placed on the right side of the interspinous space as rotation to the left causes the spinous processes to turn to the right.
- The hand on the upper body holds the thoracic spine in flexion while bending and turning the upper body out of the neutral sitting position (Fig. 11.61) toward the therapist until the movement reaches the palpating thumb (Fig. 11.62) and a step can be felt between the neighboring spinous processes.

Treatment of the Thoracic Spine

A variety of physical-therapy methods form the basis for techniques that treat thoracic symptoms and are applied directly onto the thoracic spine. The total technique incorporates the entire thoracic section of the vertebral col-

umn. Local segmental techniques focus more on a single segment. All variations are based on the exact localization of affected segments that cause pain or are "responsible for" restrictions in mobility.

Axial Traction

One of the total techniques is the axial traction (longitudinal technique) (Fig. 11.63). The therapist applies a "longitudinal" traction in a superior direction to the vertebral column superior to the affected segment.

Procedure: The therapist's sternum is in direct contact with the vertebra that forms the superior boundary to the affected segment. A folded towel may be placed between sternum and the vertebra, if needed. Both arms pull the thorax toward the therapist. By extending both legs, the therapist lifts the patient up slightly and the affected segment is relieved of load. This technique is successfully used to treat symptoms arising directly from the intervertebral disk (e.g., acute internal intervertebral disk rupture).

Local Segmental Treatment Techniques

Local segmental treatment techniques of manual therapy are used to relieve pain and increase mobility, especially in the ZAJs. The variations in these techniques are enor-

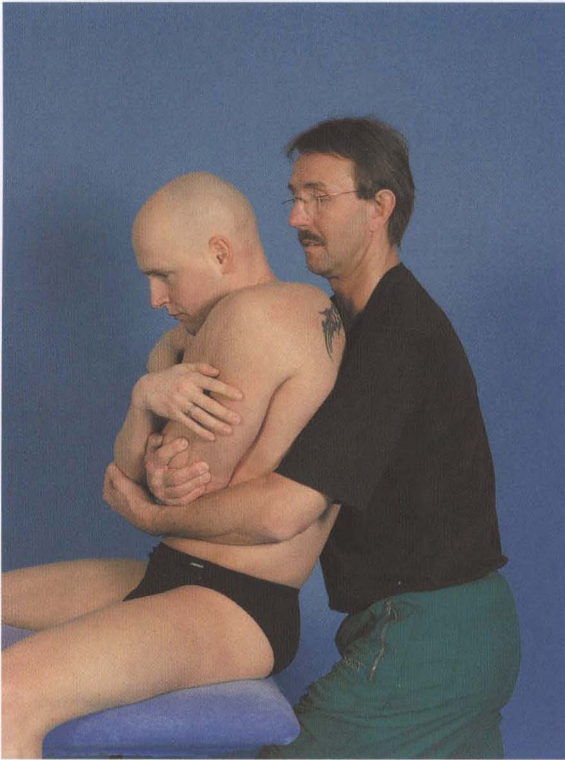


Fig. 11.63 Axial traction

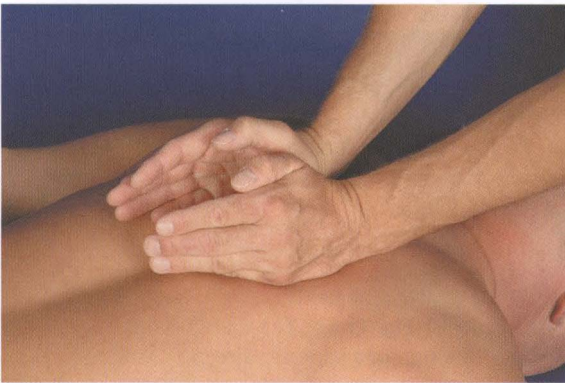


Fig. 11.64 Segmental traction

mous. A traction technique is described here as an example (Fig. 11.64).

Procedure: The patient is positioned in prone, taking their kyphosis into account. The transverse processes of the vertebra forming the inferior boundary to the affected segment are located. The pisiform on the medial border of the hand rests on the transverse process. Gentle, rhythmic pressure is applied in an anteroinferior direction to relieve pain. This results in the articular surfaces of the inferior vertebra separating from the superior vertebra. A small gap is formed between the articular surfaces.

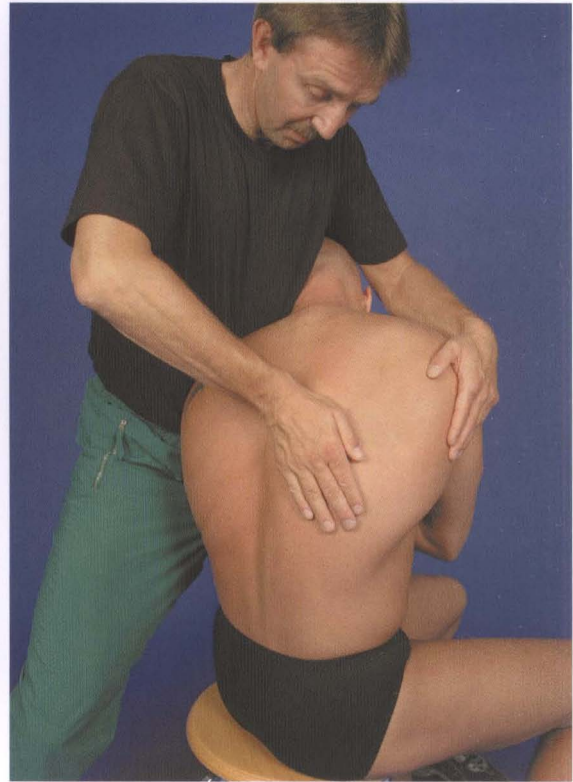


Fig. 11.65 Assessing the position of the ribs.

Assessment of the Costovertebral Joints

By precisely locating each rib, the therapist is able to assess the costovertebral joints for mobility and pain. The common symptoms patients complain of are based on a painful restriction in mobility with blocking in a neutral, expiration, or inhalation position. The assessment aims to determine whether symptoms are actually caused by a costovertebral joint, whether there is a change in mobility, and whether the thorax is blocked in an end position of movement.

Assessing the Position of the Ribs

Aim: To determine whether a rib is fixed in a position of inhalation or expiration.

Procedure: The vertebral column is placed in end-range flexion with rotation and lateral flexion away from the side to be palpated. The shoulder girdle is protracted on the side of palpation (Fig. 11.65). The therapist can then easily access the ribs while movement in the vertebral column is reduced. The flattened hand is used to gently palpate the thorax at the level of the 2nd to 10th ribs and attempts to feel the contours of the ribs. The patient moves the thorax into the end range of movement using forced

inhalation and expiration. All ribs should move in the same manner.

The side of the thorax is palpated from superior to inferior and back at the end range of forced respiration.

Criteria: We speak of a normal rib position when a regular gap between the ribs and intercostal spaces can be felt and each rib has almost the same contour. Winkel (2004, p. 52) describes the expected feeling as a “regular wave-shaped pattern.”

Interpretation: The therapist can start by developing a sense of whether the intercostal spaces are generally very narrow or very wide. When the intercostal spaces are generally narrow, the thorax may be in expiration position. A constantly widened gap indicates that the entire thorax is in inhalation position. This interpretation is based on a fair amount of experience, as no “concrete” specifications exist. The therapist should also keep in mind that all intercostal spaces are already widened on the side to be palpated due to the position of the upper body in flexion combined with lateral flexion and rotation to the opposite side.

Furthermore, the therapist can reach very concrete conclusions regarding the position of the individual ribs. Dautzenroth (2002) describes this as “position diagnosis.”

A rib is fixed in a **position of expiration** when an edge is palpated during forced inhalation. In this case, the rib is fixed in an expiration position and it cannot move as required for inhalation. This results in an edge being clearly palpable. Further evidence for this fixed position is changes in the neighboring intercostal spaces. When the eighth rib is fixed in an expiration position, the distance to the ninth rib decreases and the space to the seventh rib increases. This can be clearly palpated once the therapist has practiced a little.

A rib is fixed in a **position of inhalation** when an edge is palpated during forced expiration. In this case, the rib is fixed in a position of inhalation. It cannot move as required for expiration, which results in an edge being clearly palpable. The intercostal spaces also change in a typical manner. When the eighth rib is blocked in an inhalation position, the intercostal space to the seventh rib is narrower while the space to the ninth rib is wider.

Tip: Individual variations are also seen in the shape of the ribs. Stroking the thorax with the flattened hand may demonstrate that the ribs are protruding posteriorly in an almost odd manner on one or both sides. The palpatory results should only be viewed as pathological when these ribs are painful under pressure (see the section “Springing Test for One Rib” below) or when changes are felt in the intercostal spaces.

Springing Test for All Ribs

Aim: Pain provocation and mobility test.

Procedure: The patient is positioned in the same SP and the therapist uses the same hand position. The therapist does not palpate with a flattened hand, but rather applies

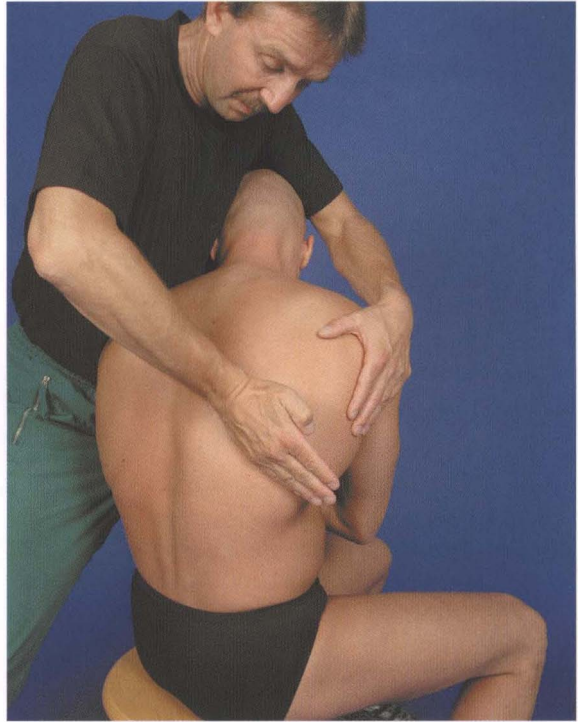


Fig. 11.66 Springing test for a single rib.

firm pressure to the rib using the thenar eminence or the hypothenar eminence (see Fig. 11.65). The hand is placed along a line from superomedial to inferolateral running along the costal angle.

Criteria: Does pressure provoke pain? Do the ribs move anteriorly when pressure is applied?

Interpretation: The test results are viewed as normal when the hand applies pressure and the ribs yield somewhat in an anterior direction, and when the ribs are not sensitive to pressure. A blocked rib cannot yield to pressure and the pressure may cause pain.

Springing Test for One Rib

It is not always possible to clearly identify the affected rib during the first springing test as the hand moves over the entire thorax. A variation of this test is therefore needed to find the affected rib. It is also important for the documentation to precisely identify which level is affected, for example, whether the ninth rib is involved.

Aim: To precisely locate the level of a rib and to confirm its position using the medial side of the hand to apply local pressure to a rib.

Procedure: The patient is in the same SP and the medial border of the hand is now used to emphasize the pressure on one rib (Fig. 11.66). Firm, anterolateral-directed pressure is applied rhythmically to the rib. End feel is assessed.

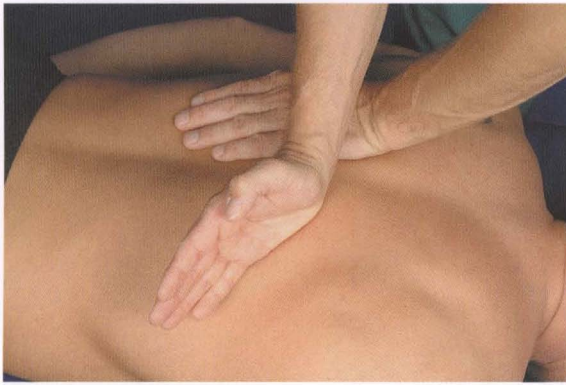


Fig. 11.67 Traction at the costovertebral joint.

Criteria: Pain provocation and end feel.

Interpretation: Again, the rib normally moves somewhat anteriorly when local pressure is applied to it. A blocked rib cannot move. Its end feel is hard. Firm and elastic resistance is normally felt here.

Tip: Altering the recommended SP (see Fig. 11.65) by adding contralateral lateral flexion (here to the right) results in a locked position in the vertebral column. If the springing test provokes pain, this variation can be used to better exclude the involvement of thoracic segments.

Treatment of the Costovertebral Joints

Traction of the costovertebral joint is described here as an example of one of the many techniques available to treat the costovertebral joints. It is used to assess joint play and also to relieve pain or improve mobility.

Procedure: The patient is in a neutral prone SP. The medial side of the hand is placed over the affected rib. The other hand stabilizes the vertebral column on the opposite side at the level of the transverse process (Fig. 11.67). The medial side of the hand always applies pressure perpendicular to the thoracic spine's convexity. This generally means that pressure is applied in an anterolateral direction for the second to sixth ribs and an additional, slightly superior direction for the 7th to 10th ribs.

The 11th and 12th ribs do not possess a costovertebral joint and therefore do not have to be treated.

This technique can be used as a traction test using the same criteria as described in the springing test for a single rib in the sitting SP. It can be used to relieve pain using oscillating movements and to improve mobility when the technique is conducted with force.

Tip: It is wise to position the vertebral column so that it moves as little as possible during treatment and so that the mobilizing force remains in the costovertebral joint. A good way of locking involves shifting the pelvis significantly to the contralateral side.

Anterior Palpation Techniques

Overview of the Structures to be Palpated

- Anterior palpation in the sitting SP.
- Anterior palpation in the supine SP.
- Thoracic palpation in the side-lying SP.

The aim of this palpatory procedure is to systematically search for the most important accessible bony "landmarks." The positions of these structures will be clarified to create the technical basis for the assessment of movement in the thorax or in each individual rib during respiration and movements of the arm. This is followed by several treatment examples related to thoracic palpation. Of course, the palpatory procedure can also be conducted with the patient in supine.

Anterior Palpation in the Sitting Starting Position

Jugular Notch

This shallow depression forms the superior boundary of the sternum. It is bordered by both tendons of the sternal sections of the sternocleidomastoid bilaterally and by both of the SC joints. The tendons can also be placed under

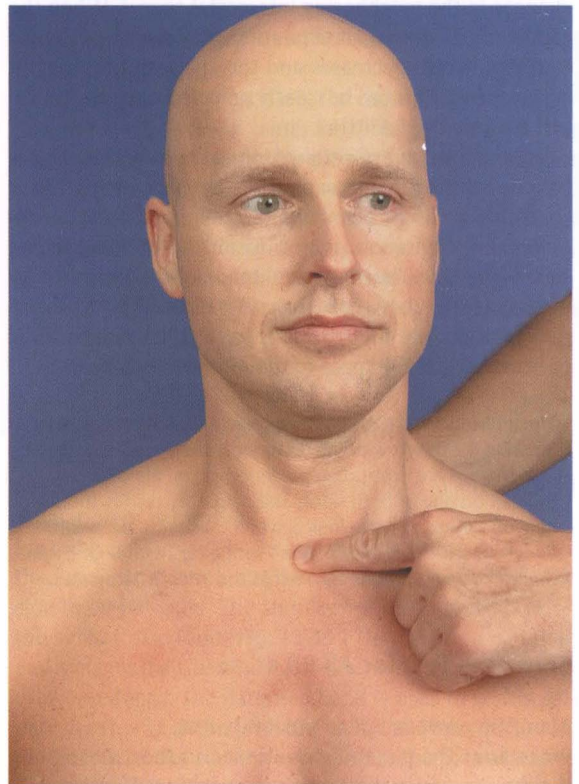


Fig. 11.68 Jugular notch

tension by rotating the cervical spine extensively. The medial end of the clavicle and the SC joint space is found immediately lateral to these tendons (see Chapter 2, pp. 35 ff.).

The jugular notch can be palpated using two different methods (Fig. 11.68): the first method involves sliding the flattened finger pads superiorly from the middle of the sternum until a depression is reached after palpating a rounded edge. The second method involves sliding the finger pads inferiorly from the larynx using less pressure until the therapist encounters the distinctly palpable edge of the manubrium.

Tip: Many people are very sensitive to touch in the region of the throat and some demonstrate strong sympathetic reactions (e.g., profuse perspiration, quick pulse). The therapist should therefore exercise caution in this region and only approach the throat after the patient has given their permission.

The jugular notch is usually found at the level of the T2 spinous process.

Sternal Angle

The therapist uses one or two finger pads to palpate from the jugular notch inferiorly onto the surface of the manubrium. A transverse bulge is felt after a distance of two to three finger-widths. This is the sternal angle, the point where the manubrium is connected to the body of the sternum. The bulge is palpated transversely in a superior and inferior direction using small finger movements to register the total size of the angle (Fig. 11.69). The angle is the most reliable point of orientation to start the palpation of the anterior ribs and intercostal spaces (ICSs).

Tip: Inflammation at the sternal angle, characterized by visible swelling, is commonly connected to rheumatic diseases, for example, ankylosing spondylitis (Winkel et al., 1993).

Locating the Second Rib

The second rib's costal cartilage is always fixed on the junction between the manubrium and the body of the sternum. The palpation is conducted using two vertically positioned fingers (e.g., using the index and middle-finger pads) and palpating laterally from the sternal angle onto the superior and inferior edges of the costal cartilage (Fig. 11.70). The index finger is then positioned in the first ICS and the middle finger in the second. When locating the second rib for the first time, therapists are generally surprised at how inferiorly it is positioned. The entire course of the second rib can now be visualized. It extends posteriorly from the superior angle of the scapula to the height of the sternal angle.

The correct localization of the first two ICSs enables the therapist to search for all inferior-lying ICSs that are acces-

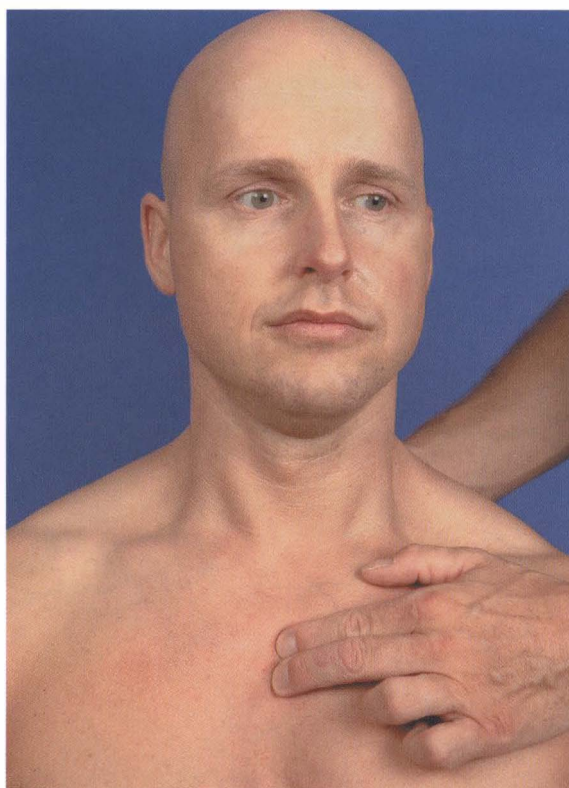


Fig. 11.69 Sternal angle

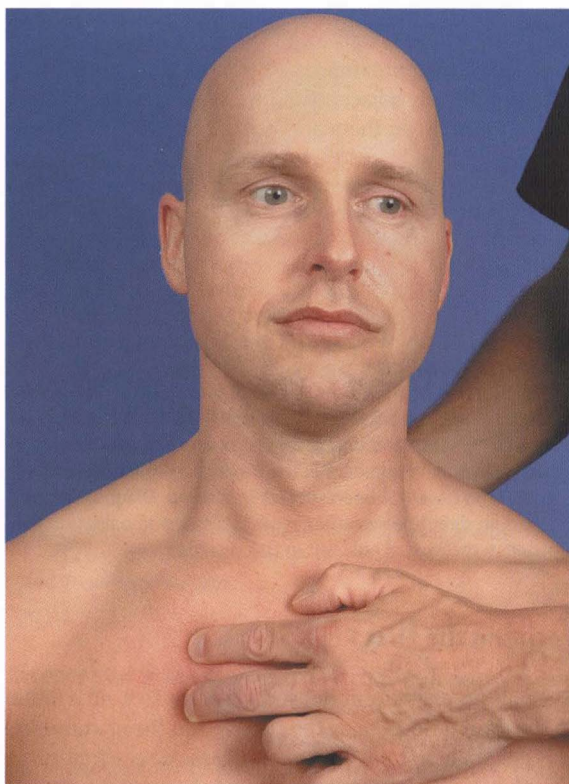


Fig. 11.70 Second rib

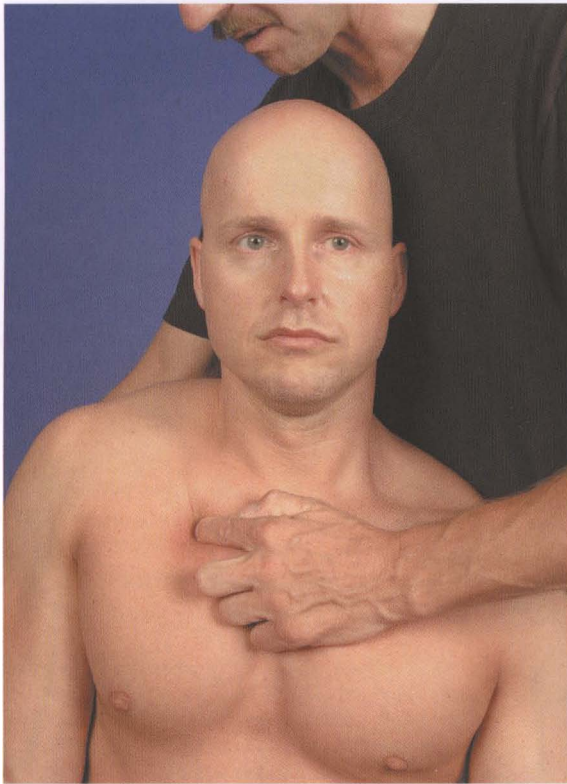


Fig. 11.71 First rib

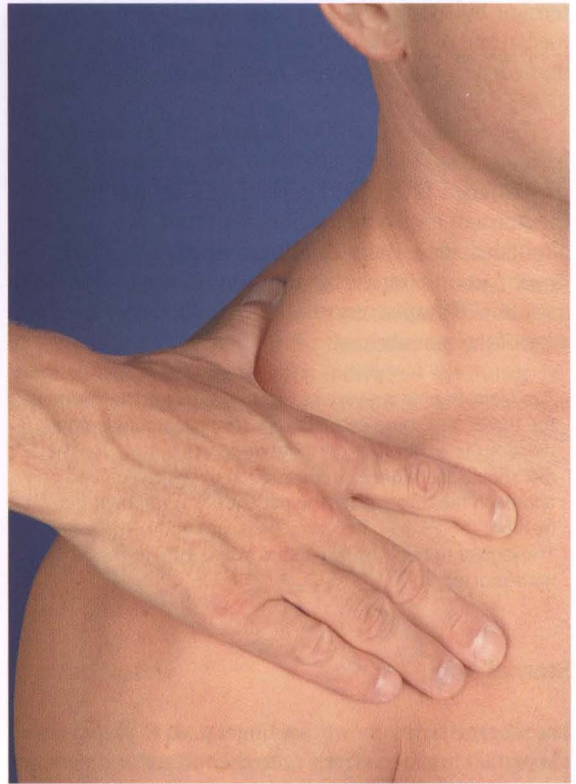


Fig. 11.72 Position of the first rib.

sible on the anterior side of the body. This should be possible down to approximately the sixth ICS. The therapist palpates directly adjacent to the sternum as the ribs and the space between them are most clearly palpable here.

Tip: Swelling of the costosternal joints, especially at the second and third ribs, can indicate the presence of a Tietze syndrome. Diethelm (2005) has described the Tietze syndrome in his review on chest pain: "Its symptoms are hard to define. Its etiology has not been explained and it has a benign, self-limiting course with symptoms disappearing again mostly within one year." Patients with costochondritis, an alternative label for Tietze syndrome, frequently complain of acute chest pain (Freeston et al., 2004). This set of symptoms is seen quite frequently (Wise et al., 1992; Disla et al., 1994). It is, alongside coronary disease and breast cancer, one of the most important differential diagnoses in the medical examination of patients who have not been subject to trauma. Diagnostics are based on direct provocation in particular, using palpation to produce the typical pain felt in this disorder.

Locating the First Rib

The only accessible anterior section of the first rib is found in the triangle formed by the clavicle and the manubrium. It is generally not possible to clearly locate the first rib as the rib disappears directly posteriorly beneath the clavicle after only a short distance.

Initially, the second rib and the first ICS, directly superior, are located. The palpating finger tips point in a slightly superior direction and push against the rib.

Tip: The length of the rib that can be palpated is increased by passively elevating the shoulder girdle (Fig. 11.71).

The entire length of the first rib can be correctly visualized by looking at the localization of the first rib combined with the results of the springing test (Fig. 11.72). The tip of the thumb from one hand is placed over the end of the transverse process. The tip of the index finger is placed in the triangle formed by the clavicle and the manubrium. The thumb, the web, and the index finger demonstrate the position of the first rib.

Anterior Palpation in the Supine Starting Position

Intercostal Palpation during Respiration

The localization of the ICS is used diagnostically to assess its constant opening and closing during thorax movements with forced respiration and large arm movements. As the upper thorax lifts up anteriorly during inhalation, the intercostal movements will also follow this movement anteriorly. This palpation can also be conducted with the

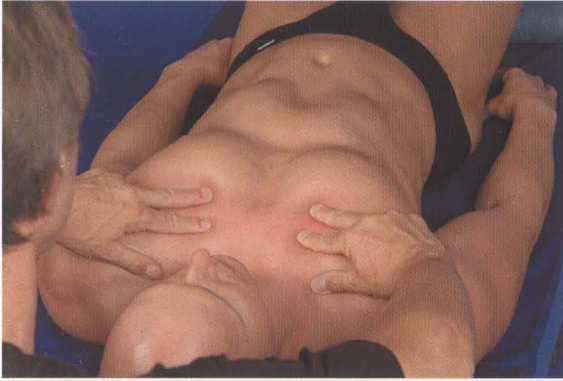

Fig. 11.73 Palpating the second rib.

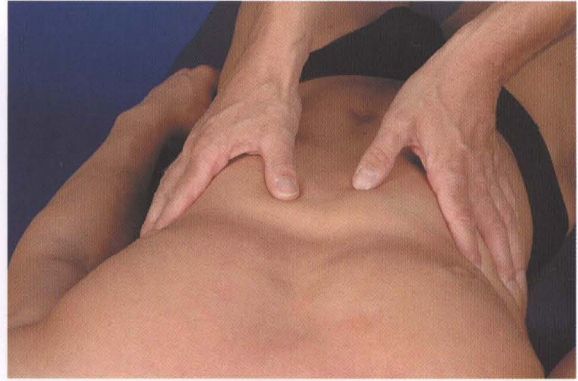


Fig. 11.75 Palpating the inferior intercostal spaces.

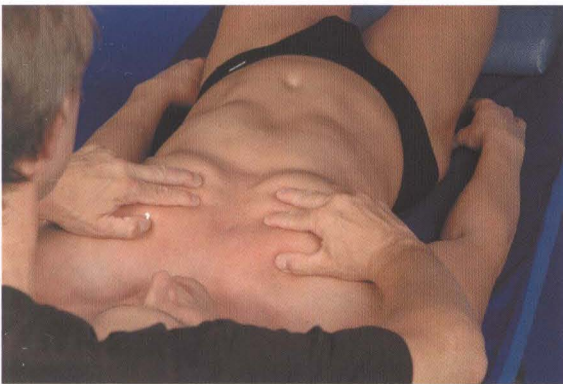


Fig. 11.74 Palpating the third to fourth intercostal spaces.

body placed in an upright position. Extensive arm movements with movement in the thorax are easier to conduct in the supine position, as the inhibitory action of gravity is less.

The palpation is conducted using two or more finger pads, which are first placed adjacent to the sternum in the ICS. The second rib and the superior two ICSs are located first to ensure that the orientation is reliable (Fig. 11.73). The finger pads can be placed parasternally down to the sixth ICS (Fig. 11.74). The opening to the inferior ICSs in the inferior thorax is found more on the side. Therefore, the palpating finger pads are placed on the side of the thoracic cage as well (Fig. 11.75).

The patient is now instructed to breathe deeply into the anterior section of the thorax five to six times before taking a break and breathing normally. The ICSs are expected to open and close uniformly. This applies when comparing the left and right sides and when comparing neighboring spaces on one side of the body. Mobility is limited in one or more ribs when the opening and closing movements cannot be felt at all or the movement is only minimal.

Tip: Tension in all three sections of the pectoralis major can be identified in this SP by using the transverse finger friction technique. A global increase in tension in several fiber bundles

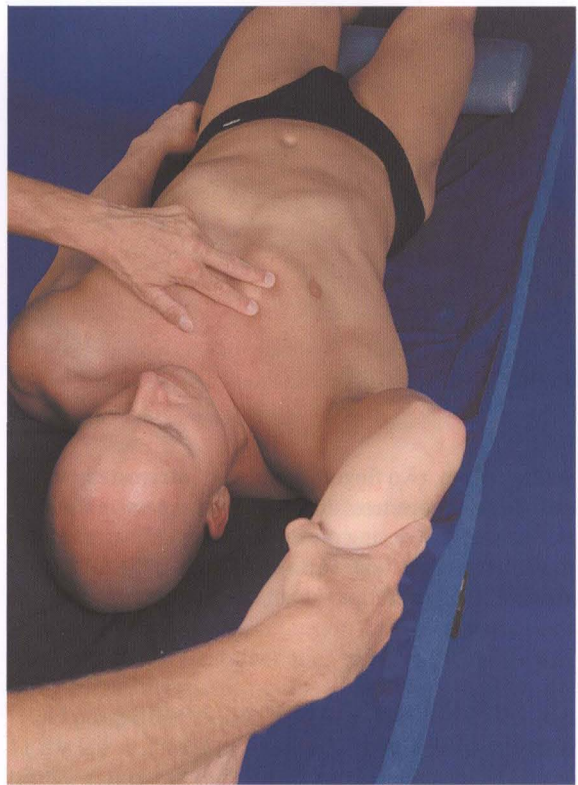


Fig. 11.76 Palpation of the anterior ribs during movement—initial position.

is an indication for manual treatment, including the use of functional massages (see the section “Tips for Assessment and Treatment” below).

Intercostal Palpation with Arm Elevation

The aim here is to use extensive arm elevation to assess the transmission of movement onto the thorax and therefore the mobility of the costovertebral joints using palpation. The superior ICSs are assessed by flexing the arm in



Fig. 11.77 Palpation of the anterior ribs during movement—end position.

supine. Again, two fingers are placed intercostally to feel the opening movement during extensive passive shoulder flexion and the closing movement when the arm returns to the neutral position (Figs. 11.76 and 11.77). All ICSs accessible on the anterior side of the body are examined in this manner.

Thoracic Palpation in the Side-lying Starting Position

The use of arm elevation to widen the inferior thorax is not practical. It is significantly more favorable to use extensive elevation of the arm to the side (abduction). It is recommended that the patient be placed in a neutral side-lying position to easily reach all ICSs. One of the therapist's hands facilitates the patient's arm; several finger pads from the other hand are placed in the ICS. The arm is positioned in moderate abduction (Fig. 11.78) and then moved into extensive elevation until the movement is transmitted onto the ribs (Fig. 11.79). The ICSs are expected to open uniformly as the arm moves more into elevation and close uniformly as the arm is returned to the SP. The interpretation of results is the same as previously described: mobility is limited in one or more

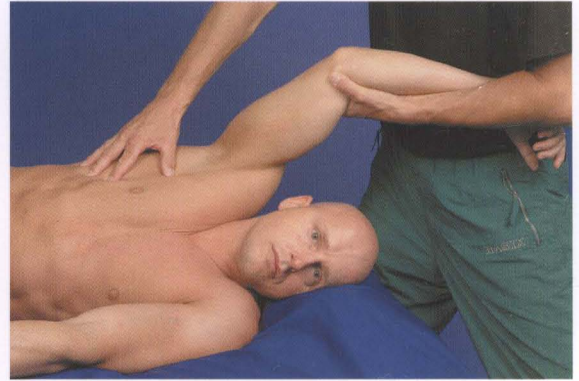


Fig. 11.78 Palpation of the lateral ribs during movement—initial position.

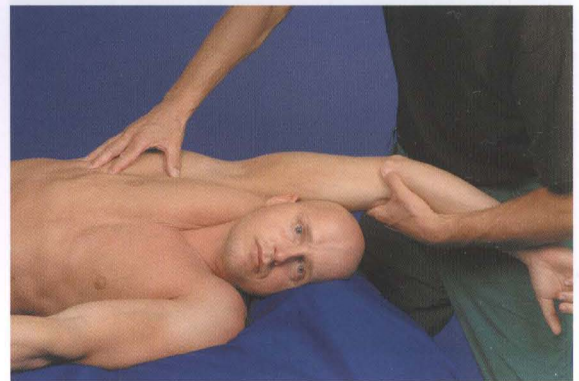


Fig. 11.79 Palpation of the lateral ribs during movement—final position.

ribs when the opening and closing movements cannot be felt at all or the movement is only minimal.

Tip: The mobility required for arm elevation must naturally be pain-free in the kinematic chain of the “neck–shoulder–arm region.” It is therefore very important to assess these movements beforehand. Based on experience, the movement is quickly completed when the arm is facilitated directly along the frontal plane of the patient. The range of motion is larger when the arm is facilitated slightly in an anterior direction during elevation.

Tips for Assessment and Treatment

Manual Techniques in Respiratory Therapy

Respiratory therapy techniques are divided according to their effect on the patient. These divisions include exercises with verbal instructions, the adoption of more advantageous body postures, and the use of manual techniques with different aims of treatment. The following section is an overview of techniques emphasizing the impor-

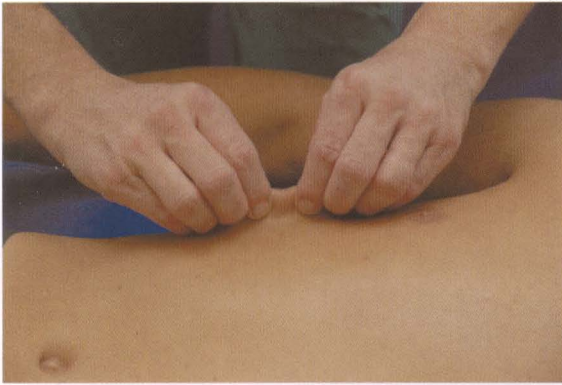


Fig. 11.80 Skin rolling

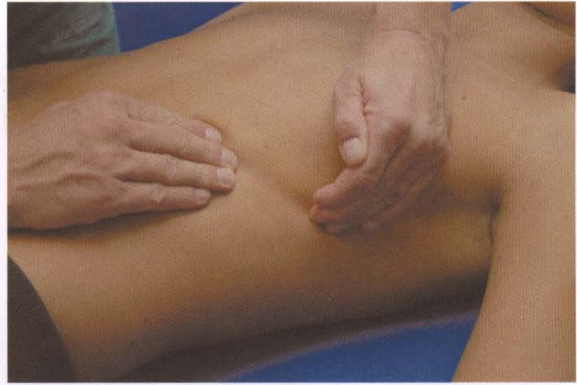

Fig. 11.81 ICS stroking

tance of good manual orientation on the thorax, the assessment of resistance and consistency, and the evaluation of the position of the ribs.

Tissue Release Methods

All manual interventions that decrease the resistance of skin and muscles are found in this group. This refers to the “intrinsic” muscles of the thoracic wall. Adhesions or increased muscular tension in the extrinsic, large muscles mainly belonging to the movement complex of the shoulder tend to be released using other manual techniques such as classical or functional massage.

The areas of skin with excessive turgor are stretched; the therapist’s hand releases adhesions with the body’s fascia using lifting, rolling, displacement, and circular movements (Ehrenberg, 1998). These techniques result in a decrease in the elastic resistance to respiration and patients can inhale significantly more easily after these forms of treatment have been applied. These techniques are used in patients with restrictive respiratory disorders and with patients who have developed a large amount of tension in their respiratory muscles due to difficulty breathing. The latter causes increased tension in skin and muscles, or the development of reflex zones of skin with low elasticity.

Skin rolling: Skin rolling (Fig. 11.80) is a dynamic technique. It is conducted in an identical manner to the skin rolling used in the palpatory assessment of turgor in the Swedish massage (see Chapter 8, “Palpating the Quality of the Skin Turgor,” p. 188). An example of this in the supine SP is grasping a skin fold along the anterior axillary line and rolling it toward the sternum along the course of the ribs.

Intercostal stroking: Intercostal stroking (Fig. 11.81) can be conducted in a variety of ways depending on the quality of the patient’s tissues and the indications. On the one hand, it is known as the Swedish massage stroking technique along the course of the ICS. On the other hand, it is recommended in literature that local intensive tensile movements be applied that are more along the lines of

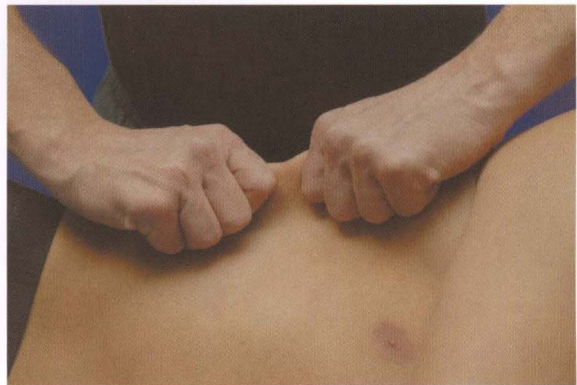

Fig. 11.82 Hold-grasp technique.

the stroking technique used in connective-tissue massage (Ehrenberg, 1998). One or two fingers pull intensively in the ICS. This is the only really intensive manual technique that reaches the intercostal muscles. The other hand may have to keep the skin under tension if adhesions are affecting the skin or if treatment aims to affect the reflexes by using connective-tissue massage.

“Hold-grasp” techniques: “Hold-grasp” techniques (Fig. 11.82) are sustained techniques. They are conducted in a similar manner to the skin-lifting technique used for the palpatory assessment of skin consistency in the Swedish massage (see Chapter 8, “Palpating the Quality of the Skin,” p. 188). Both hands are used to lift up sections of the skin and pull the skin strongly away from the thorax while the patient breathes in and out several times. With regard to the SP, it is important that the therapist can easily access the tight sections of the skin. Lying or sitting positions can be used.

Interventions to Loosen Secretions

Vibration: To mobilize and transport secretions and to affect the reflex-based increase in tension in the smooth muscles. This includes the treatment of obstructive bron-

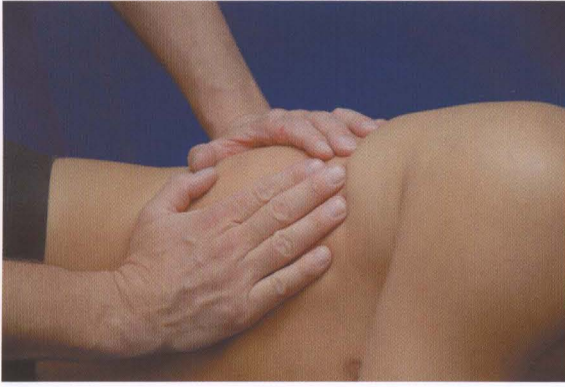

Fig. 11.83 Vibration with the diamond grip.

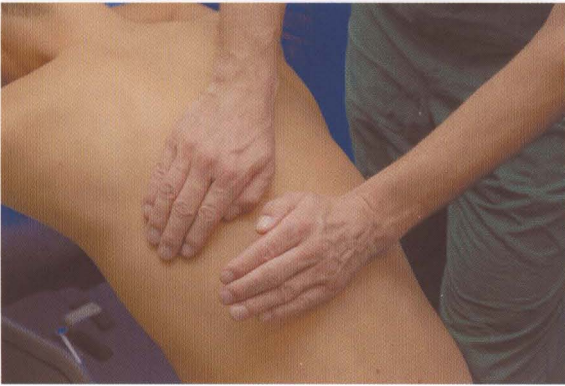

Fig. 11.84 Percussion with cupped hands.

chial diseases. The technique is applied for several minutes over different sections of the thorax:

- Superior thorax = subclavicular, sternal, between the scapulae.
- Inferior thorax = lateral, posterior (Fig. 11.83).

The optimal frequency is stated as 8–12 Hz in the literature (Edel, 1999). Vibration is often combined with postural drainage, for example, lowering the head end of the bed (Dautzenroth, 2002).

Percussion with the fist or cupped hands: Tapotement (tapping) techniques are used to mobilize and loosen secretions. A loose fist or a firmly cupped hand moves downward at the wrist onto the thorax (Fig. 11.84). The use of this technique must first be clarified using palpation. The therapist has to identify the area to be treated and the area that is not allowed to be percussed. The following structures must be palpated: spinous processes, edges of the scapula, inferior costal arch, xiphoid process. This technique should not be applied to the spinous processes the kidney region (in the angle between the 12th ribs and the intrinsic back muscles), or the upper abdomen.

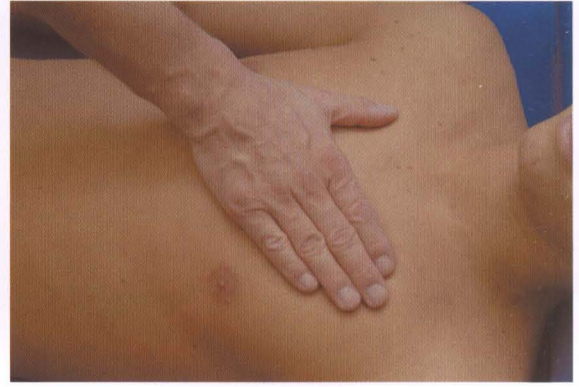

Fig. 11.85 Costosternal contact breathing.

Contact Breathing

This is used to facilitate inhalation and to improve the relationship between ventilation and perfusion. Manual contact is used in respiratory therapy to train body awareness so that breathing can be directed to areas of low ventilation, for example, following operative interventions in the thorax. Once patients have practiced abdominal breathing, they are taught how to use thoracic movements during respiration to include areas of the lungs that have previously not been reached well and to ensure that all sections of the lung are evenly ventilated. The therapist positions the hands flat and applies only gentle pressure. The pressure is increased as the patient inhales so that the patient is aware of the direction of resistance. While breathing in, the patient tries to increase lung excursion toward the therapist's hands. The points of contact are:

- Sternum → costosternal direction for respiration (Fig. 11.85).
- Epigastric angle → costoabdominal direction of respiration.
- Anterolateral on the inferior thorax → costolateral direction of respiration.
- Posterolateral on the inferior thorax → costoposterior direction of respiration.

Contact breathing is especially effective when the patient is instructed to adopt different SPs in terms of repositioning or atelectasis prophylaxis.

Mobilization of the Thorax

A mobile thorax guarantees sufficient respiratory minute volume with the deep drawing of the breath. Self-applied postural drainage and supportive interventions to loosen secretions can only be successful when the thorax is sufficiently mobile. Exercises can be used to improve mobility, for example, using stretching positions, where the thoracic spine is placed in a specific position and the large thoracic wall muscles are stretched. This alters the ability

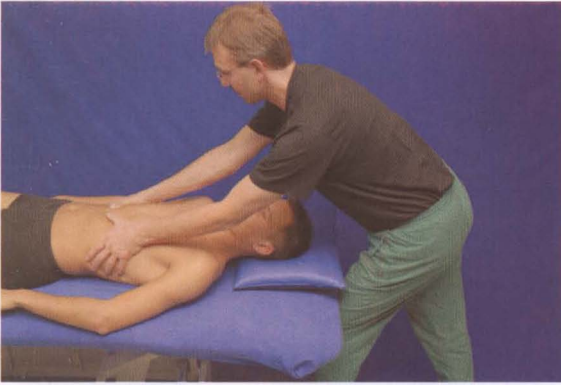


Fig. 11.86 Thorax compression

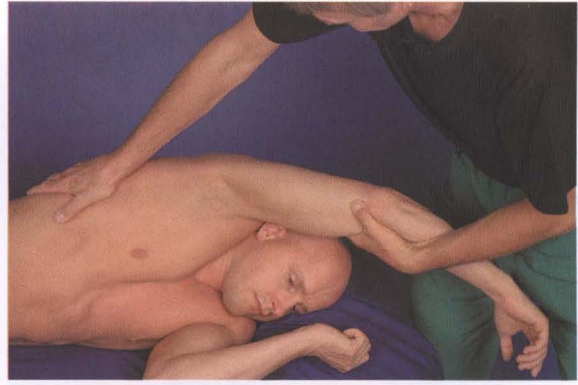


Fig. 11.88 Functional massage of the latissimus dorsi—final position.

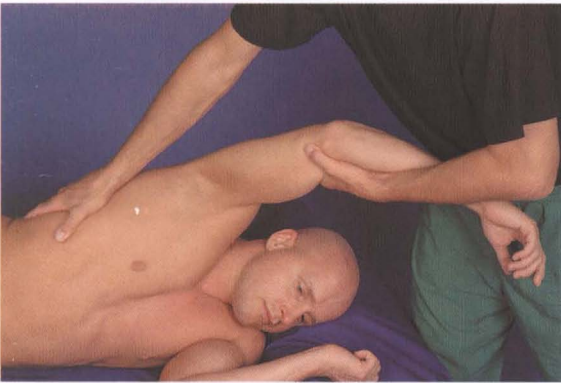

Fig. 11.87 Functional massage of the latissimus dorsi—initial position.

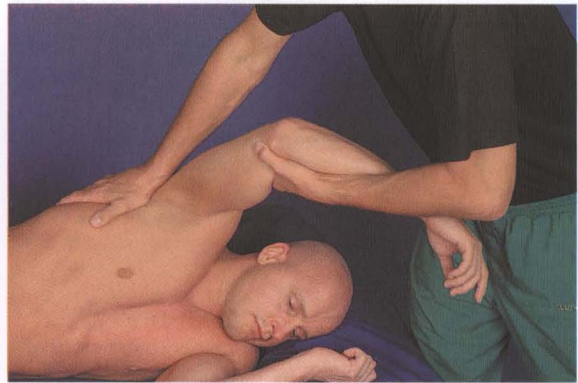


Fig. 11.89 Functional massage of the teres major and minor—initial position.

of the intercostal spaces to open up. Manual techniques can also be used, though in a much more differentiated fashion, to selectively treat affected areas. Palpation aims to feel out movement disorders in the region of the thorax and to restore mobility using targeted techniques. **Thorax compression (Fig. 11.86):** In this technique, both hands are placed on the same area as during contact breathing. However, pressure is significantly increased during expiration (the “expiratory thorax compression” according to Ehrenberg, 1998). This technique supports the transportation of secretions and mobilizes the thorax, for example, when the respiratory muscles do not function properly or when inflammatory pleuritis is present. Thorax compressions act regionally on the costovertebral joints and the connection to the sternum, but have no mobilizing effect on the ICSs.

Mobilization of the costovertebral joints: As described above (“Tips for Assessment and Treatment”) these techniques act on the joints between the ribs and the vertebrae. It is easiest to affect the costotransverse joints. The techniques also affect the joint of the head of the rib. The advantage of this manual-therapy technique is the very selective treatment of individual malfunctioning movements of the ribs. The disadvantage is that improv-

ing the mobility of the entire thorax takes an enormous amount of time.

Functional Massage

A variety of soft-tissue mobilization techniques can be successfully used to specifically support the treatment of restrictions and to improve arm elevation. Techniques will be presented that relieve muscle tension and loosen adhesions:

- Latissimus dorsi.
- Teres major and minor.
- Pectoralis major (sternal and abdominal heads).

Latissimus Dorsi

The positioning and handling is almost identical to the thoracic palpation in side-lying (see the section “Thoracic Palpation in the Side-lying Starting Position” above). The palpating hand merely emphasizes the different muscle groups. The technique starts with a moderate approximation of the latissimus dorsi (Fig. 11.87) and finishes with a stretch (Fig. 11.88). The flat, free hand rests inferiorly on

the scapula, covers the muscle, and pushes the muscle against the thorax. The arm is brought into extensive arm elevation until tension can be felt in the muscle belly of the latissimus dorsi beneath the hand. As with all functional massages, contracting a certain part of the muscle isometrically lengthens the section of the muscle found between the joint and the hand opposing the movement. The technique is conducted in a slow rhythm and frequently repeated.

Teres Major and Minor

To emphasize the teres major and minor on the lateral edge of the scapula, the inferior hand is placed closer to the shoulder joint laterally on the edge of the scapula. Initial and final positions (Figs. 11.89 and 11.90) remain the same as described previously. This technique generally requires less mobility to effectively stretch the tissue.

Tips:

- Classical massage techniques in the prone position should be used in this region first to optimize the effectiveness of the functional massage.
- It is important that the inferior hand does not slide over the skin while the muscle is being stretched further as this may cause unpleasant skin reactions.
- If the latissimus dorsi is already quite flexible, extensive arm flexion may not be sufficient to stretch the muscle further. If the therapist wishes to intensify the effect, they should stretch the muscle from its inferior side before starting with the above functional massage. This can be achieved by placing a large amount of padding underneath the thorax. The hip and knee joints can also be flexed to 90°. The lower legs then hang over the edge of the treatment table. Both of these methods result in contralateral lateral flexion of the thoracic spine or the lumbar spine.
- The latissimus dorsi, teres major, and teres minor can be stretched by elevating the arm with abduction or flexion. Therapists must find out for themselves which of these movements is the most effective during treatment.
- The side-lying SP lends itself to this technique. The muscles are easy to reach in this position and the thorax offers good support for the different parts of the muscles that are opposing movement. The therapist can take advantage of this and apply vertical pressure to the thorax with the hand. The muscles are also accessible in the prone position (Fig. 11.91). However, the required arm movement cannot be performed well in this position. If the therapist wishes to make the latissimus dorsi and teres major and minor visible, the patient is instructed to move the arm from a slightly elevated (abducted) position toward the body. By conducting this maneuver isometrically with significant force, at least the outer borders of the muscles can be seen and followed for some distance inferiorly using palpation.

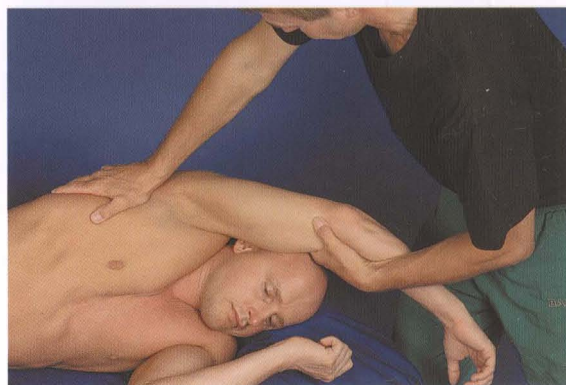


Fig. 11.90 Functional massage of the teres major and minor—final position.

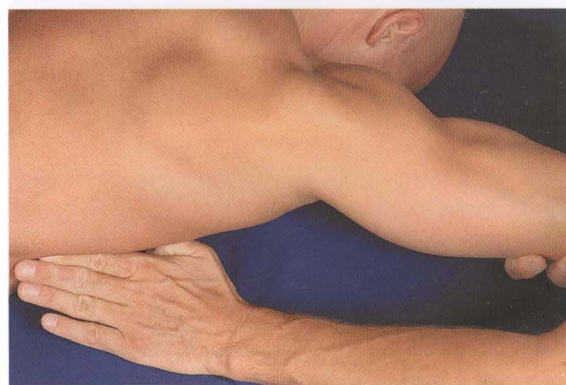


Fig. 11.91 Palpating the latissimus dorsi in the prone position.

The Sternal Head of the Pectoralis Major

The pectoralis major is a muscle that develops a lot of tension and low elasticity when painful or persistent symptoms are present in the shoulder joint, when the shoulder girdle is held in a habitual posture of protraction, and when a variety of respiratory system symptoms are present. The position of this section of the muscle can often be made visible or palpable by using isometric contraction (horizontal adduction and internal rotation) when the muscle is strongly approximated (Fig. 11.92).

The previously described principles for functional massage remain the same:

- Moderate approximation of the muscle (Fig. 11.93).
- Manually opposed isometric contraction of specific muscle groups.
- Passive stretching.

To stretch the muscle, the shoulder is positioned first in external rotation and the arm is moved in horizontal adduction until the build up of tension is felt in the therapist's opposing hand (Fig. 11.94). All the information provided for the procedure involved in the previously described functional massage techniques applies here as well. It is advantageous to position the patient near the

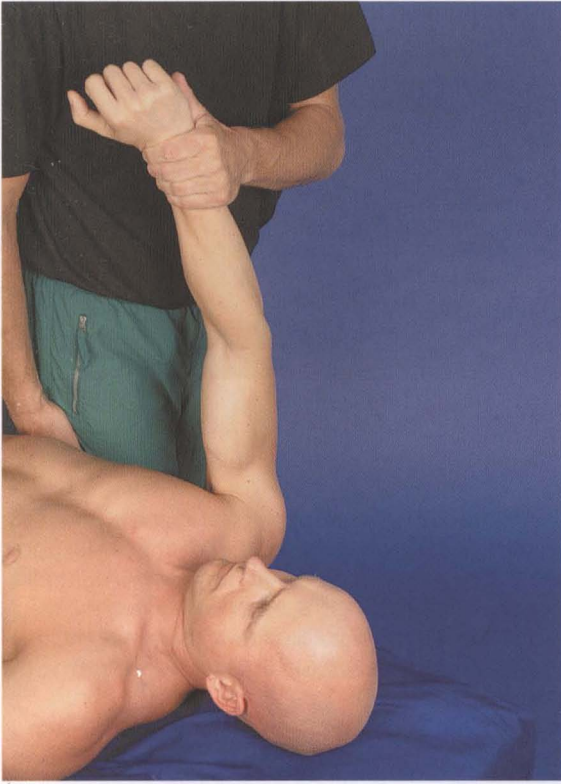


Fig. 11.92 Sternal head of the pectoralis major—contraction.

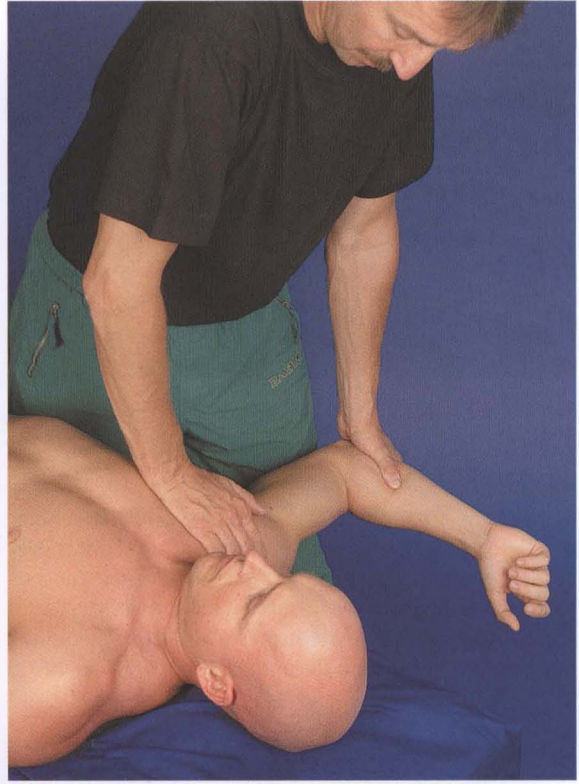


Fig. 11.94 Functional massage of the sternal head of the pectoralis major—final position.

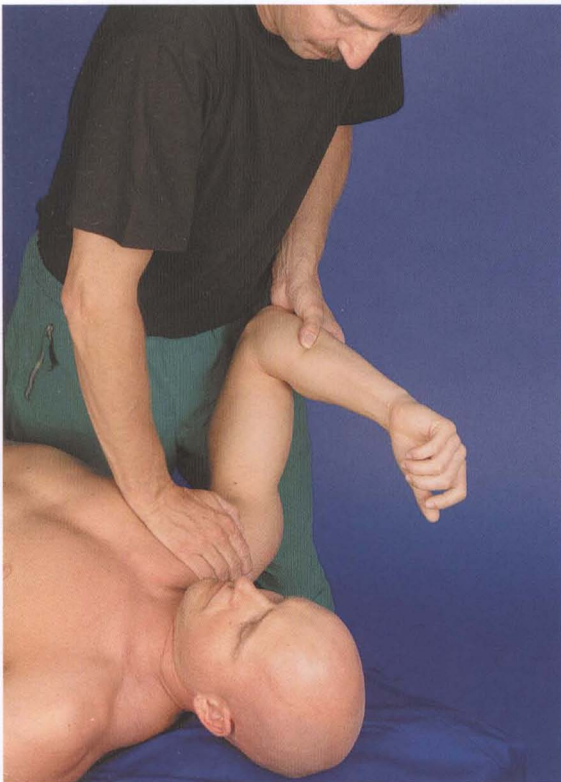


Fig. 11.93 Functional massage of the sternal head of the pectoralis major—initial position.

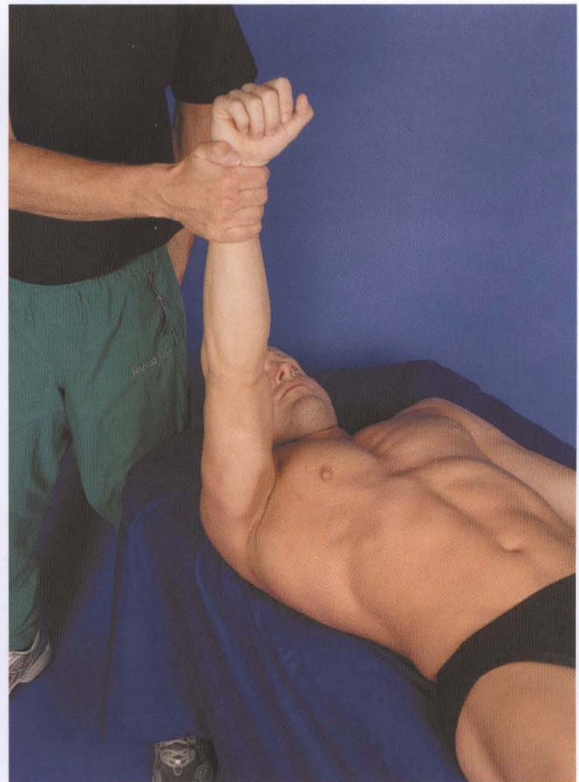


Fig. 11.95 Abdominal head of the pectoralis major—contraction.

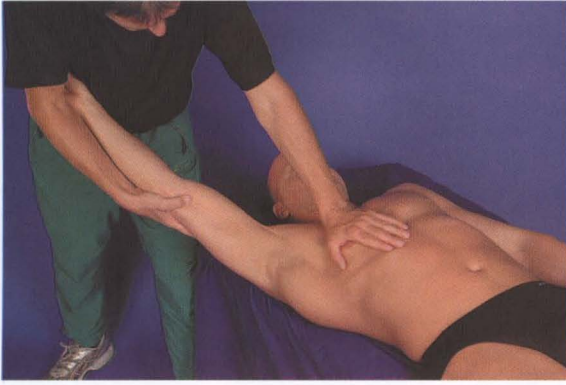


Fig. 11.96 Abdominal head of the pectoralis major—initial position.

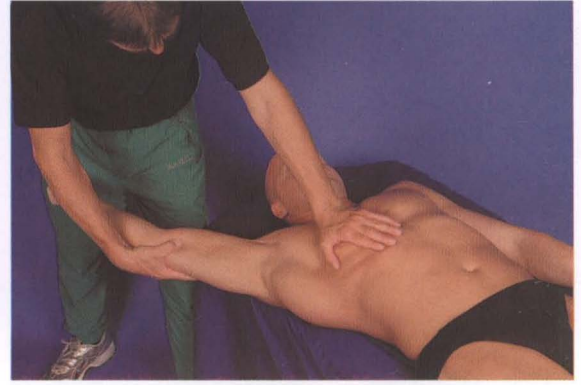


Fig. 11.97 Abdominal head of the pectoralis major—final position.

edge of the treatment table so that the shoulder joint hangs somewhat freely over the edge. Only slight movement is needed for stretching when the isometric contraction is targeting muscles near the joint. The required mobility in the shoulder joint increases when the therapist's hand moves toward the sternum.

The Abdominal Head of the Pectoralis Major

To make the abdominal head of the pectoralis major more prominent, the muscle is moderately approximated and the patient is asked to isometrically contract into shoulder extension combined with adduction and internal rotation (**Fig. 11.95**).

Before starting the functional massage, the pain-free range of motion is assessed to ascertain how much arm elevation is possible in the functional massage procedure.

The arm is positioned in moderate approximation or in a position of slight stretch and the therapist again places one hand over a specific part of the muscle (**Fig. 11.96**). The muscle-fiber bundle is stretched between the therapist's hand and the joint. The parts of the muscle found beneath the hand or closer to its origin are excluded from the stretch.

The hand placement is maintained and the arm is moved further toward the maximal range of arm elevation until the muscle is in danger of sliding away from underneath the therapist's opposing hand (**Fig. 11.97**). The arm elevation can be stopped here. Further stretch is not possible. The technique is repeated several times slowly and rhythmically. Different parts of the abdominal head of the muscle are accentuated. All other previously described tips for functional massage also apply here.

Study Questions

1. What are the functions of the thoracic spine and the thorax?
2. How are extensive cervical movements and arm elevation transmitted onto the thoracic spine and to which thoracic segments are these movements transmitted?
3. What does the finger rule say?
4. Why is rotation suitable to assess segmental mobility in the thoracic spine?
5. Which two kinematic chains meet at the thoracic region?
6. Around which axis do the ribs in the upper and lower thoracic regions rotate during arm movements?
7. Which movement of the arm is used to open up the lower intercostal spaces?
8. What is the relationship between the sternal angle and the second rib?
9. How does the spinalis affect the palpation of the thoracic row of spinous processes?
10. How is the C6 spinous process normally found when the cervical mid-line is being palpated in an inferior direction? Why does the therapist still need to use other techniques to precisely locate the position of C5 and C6?
11. How do C5 and C6 move during cervical extension?
12. The position of C7 and T1 can also be determined using extensive cervical rotation and lateral flexion. Why does the therapist need to place the palpating finger against the spinous processes on the contralateral side?
13. What options are available to differentiate the first rib from the T1 transverse process?
14. What is the difference between pain relieving and mobilizing techniques in the treatment of a painful restriction in mobility at the first rib?
15. How can the therapist further increase the effectiveness of the functional massage of the descending part of the trapezius in side-lying?
16. Which parts of the scapula are found at the level of the T1, T3, and T7 spinous processes?
17. How can the therapist reliably confirm the correct allocation of a spinous process and a transverse process to a vertebra in the mid-thoracic spine?
18. What are the advantages and disadvantages of the assessment of segmental mobility in the sitting SP compared with side-lying?
19. How do the sixth and seventh intercostal spaces behave when the seventh rib is blocked in a position of inhalation?
20. Which spinous process is found at the level of the jugular notch?
21. How does the therapist reach the anterior first and second intercostal spaces using palpation?
22. What options are available to palpate the opening and closing of the upper intercostal spaces?
23. Which aspects are to be kept in mind when conducting a functional massage of latissimus dorsi and teres major and minor?

THIS PAGE INTENTIONALLY
LEFT BLANK

12 Cervical Spine

- Significance and Function of the Cervical Spine ... 317**
- Common Applications for Treatment in this Region ... 317**
- Required Basic Anatomical and Biomechanical Knowledge ... 318**
- Summary of the Palpatory Process ... 332**
- Starting Position ... 332**
- Difficult and Alternative Starting Positions ... 334**
- Posterior Palpation Techniques ... 334**
- Lateral Palpation Techniques ... 350**
- Anterior Palpation Techniques ... 361**
- Study Questions ... 366**

THIS PAGE INTENTIONALLY
LEFT BLANK

12 Cervical Spine

Significance and Function of the Cervical Spine

The cervical spine supports the head (approximately 10% of the weight of the body). The head's center of gravity is found at the level of the sella turcica (**Fig. 12.1**) and is therefore positioned slightly anterior to the C0/C1 and C1/C2 joints so that the neck muscles are always slightly tensed when in an upright posture (Kapandji, 2006).

The cervical spine assists the sense organs (eyes, ears, nose) by positioning the head in space and should always keep the line connecting the eyes horizontal. Penning (2000, p. 83) commented on this: "The head is continually moving in relation to the trunk in the awake state so that the eyes, ears, nose, and skin sense organs can take in the surroundings."

The cervical spine is particularly designed for rotation. During evolution, the cervical spine became vertical and resulted in rotation being the most important movement for human beings and the movement with the largest range. In comparison, the most important movement for quadrupeds is lateral flexion. The human head has to turn very precisely and often quickly. This requires fine coordination as well as strength to accelerate and decelerate movements.

The cervical region has other functions in addition to these extremely mechanical tasks. The superior vertebral canal protects vitally important centers in the elongated spinal cord. Hollow, pipelike organs (pharynx, larynx, trachea, and esophagus) are found anterior to the cervical spine. These organs belong to the digestive system and the upper respiratory tract. According to Hoppenfeld (1992), the cervical spine also protects the vertebral arteries.

Common Applications for Treatment in this Region

In addition to the lumbar spine, the cervical spine is the most frequent symptomatic region seen in physical therapy practices. Cervical structures cause differing degrees of pain and neurological symptoms in the periphery (shoulder and arm), as well as direct symptoms in the cervical spine. Similar observations have already been made in the thoracic and lumbar spines. New to this is a set of symptoms that is only seen in this section of the vertebral column and is consolidated in the general term "cervicocephalic symptoms":

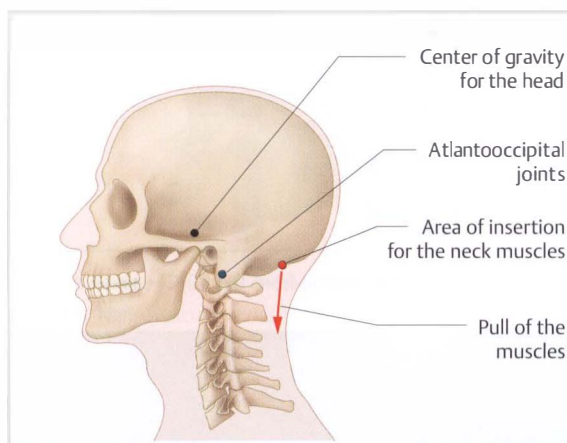


Fig. 12.1 Center of gravity for the head.

- Headache.
- Tinnitus-like symptoms.
- Difficulty swallowing.
- Vegetative disorders in the face.
- Nausea and dizziness.

The neuroanatomical relationship between the nuclei of various cranial nerves and the enormous proprioceptive innervation of the upper cervical muscles and joints is an essential aspect linking the cervical spine to symptoms in the head.

Symptoms associated with the cervical spine are a special challenge for therapists when planning and conducting treatment. Therapists must be well versed in anatomy and biomechanics if they wish to work professionally and effectively.

Manual therapeutic assessment and treatment of this region is divided into global and local techniques, as is also the case in the other sections of the vertebral column. Local assessment techniques that provoke pain and assess mobility are of great importance in the cervical spine due to the difficulties in relating, for example, a restriction in rotational mobility to the proper level.

Long-term irritation of a facet joint causes pain felt in other areas (referred pain). It is not possible to link the patient's reported area of referred pain with a specific level in the cervical spine. In 1994, Dreyfuss et al. wrote that referred pain arising from the C0/C1 segment can extend quite a way up onto the occiput (**Fig. 12.2**).

A good knowledge of topography and the ability to palpate reliably are the basis for confident hand placements during local assessment and treatment.

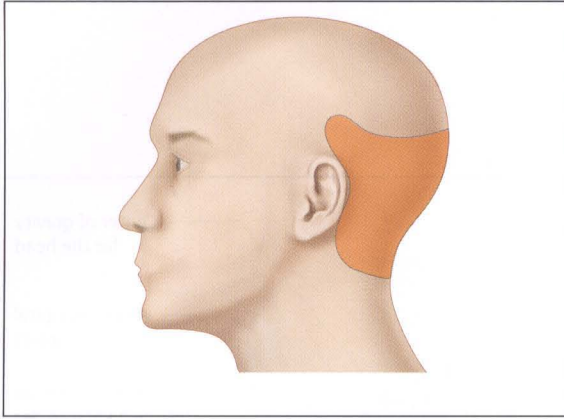


Fig. 12.2 Referred pain arising from the C0/C1 segment.

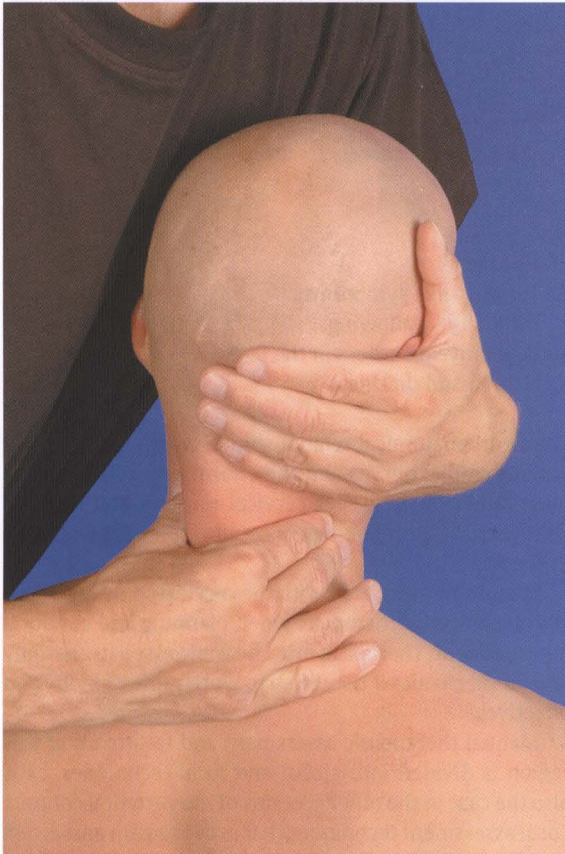


Fig. 12.3 Functional massage of the lower cervical spine.

In addition to the manual techniques for the cervical joints, a range of cervical soft-tissue treatment techniques also exists. Classical massage and functional massage (Fig. 12.3) are important forms of treatment used to obtain localized and general relaxation. Neck, head, and face massages belong to the most effective manual techniques available for relaxation. Functional massage is the first,

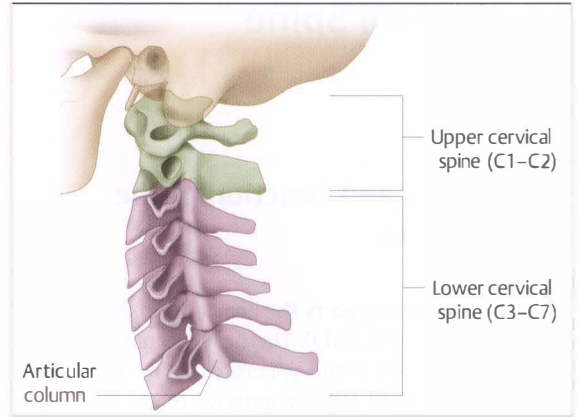


Fig. 12.4 Sections of the cervical spine.

and often initially the only, form of treatment that can be applied to a painful neck.

Manual lymphatic drainage targets the large number of lymph nodes in the head and throat region. It can be used to generally stimulate the motor function in lymph vessels or to drain fluid in the neck, face, and head. The sternocleidomastoid, the descending part of the trapezius, and the supraclavicular fossa are important guiding structures here.

Required Basic Anatomical and Biomechanical Knowledge

Sections of the Cervical Spine

Due to its morphology, biomechanics, and the presence or absence of intervertebral disks, the cervical spine is divided anatomically and functionally into (Fig. 12.4):

- Upper cervical spine:
 - anatomically: atlas and axis
 - functionally: C0/C1 and C1/C2 segments; also called the segments without intervertebral disks.
- Lower cervical spine:
 - anatomically: C3–C7
 - functionally: C2/C3 to T3/T4 segments; also called the segments with intervertebral disks.

Anatomy of the Lower Cervical Spine

The physiological curvature of the cervical spine is lordotic, with the C3/C4 segment usually positioned horizontally (White and Panjabi, 1990).

The vertebral body's end plate is very narrow, favoring rotation. The vertebral foramen is very large due to the long laminae of the vertebral arches. The spinal cord only occupies approximately 50% of the vertebral foramen's very wide diameter. The large vertebral foraminae

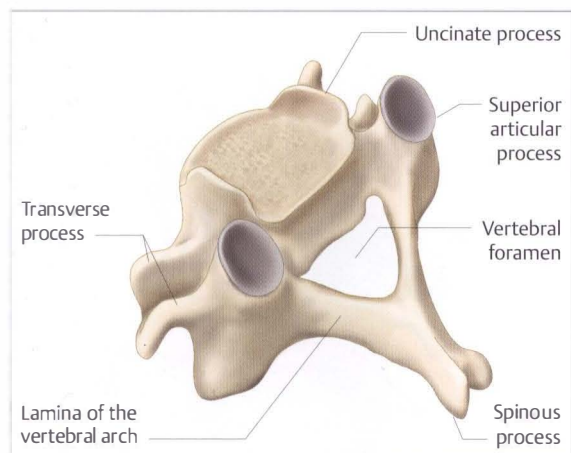


Fig. 12.5 Typical vertebra in the lower cervical spine.

provide the dural sac with a generous amount of space to move in during large cervical movements (White and Pandjabi, 1990).

The wide laminae are well developed (being approximately as wide as an index finger) and can be palpated underneath the muscles. They are located at the level of the spinous processes. The articular processes protrude from the end of the laminae.

The zygapophysial joints (ZAJs) form the “articular column” (see Fig. 12.4) that is almost as wide as the row of transverse processes. The vertebrae, as a whole, have very wide bases due to the extremely lateral position of the joints, which results in the lower cervical spine being not particularly ideal for movement into lateral flexion. A narrow base (less distance between the left and right ZAJs), as is seen in the lumbar spine, is more conducive to lateral flexion.

The spinous processes are bifurcated down to C6. The bifurcation at C2 is very large and extremely asymmetrical. The spinous processes decrease in size down to C6. A large spinous process is seen again at C7 and is not bifurcated at this level. The asymmetrical bifurcations in the spinous processes interlock during extension and optimize the range of motion for the lordosis.

The transverse process is composed of two tubercles that connect laterally and form a hole at one point. This foramen transversarium has a diameter of approximately 4.5–5 mm, which almost corresponds to the diameter of the vertebral artery.

The anterior tubercle is a rudiment of a rib, while the posterior tubercle represents the actual transverse process. These two tubercles turn the transverse process into more of a groove than a process. The groove runs diagonally and is oriented anterolaterally (Fig. 12.5).

The groove is at its narrowest in its medial section and is bordered by bones on all sides. The uncinete process forms the anterior border; the superior articular process of the ZAJ the posterior border.

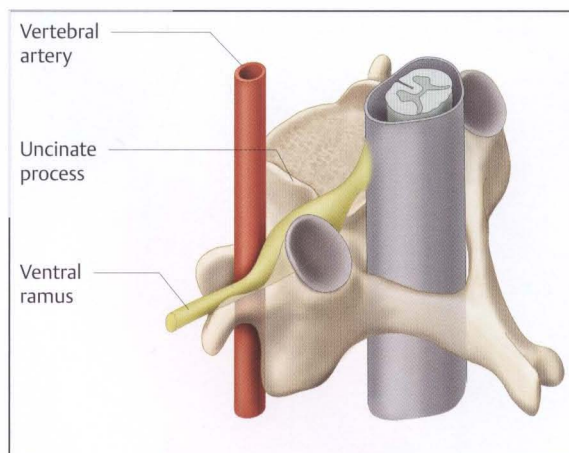


Fig. 12.6 Neurovascular cross

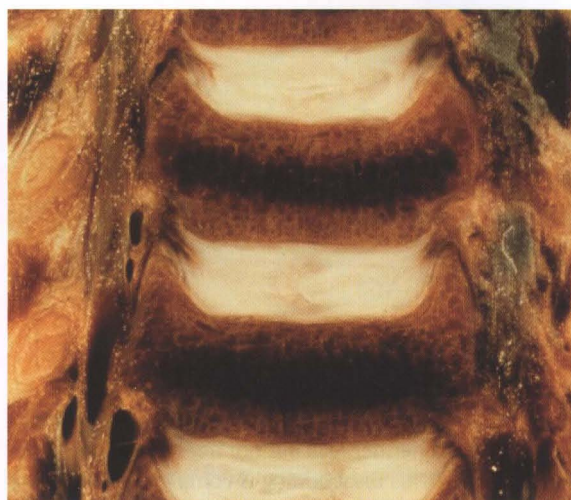

Fig. 12.7 Formation of horizontal tears in the cervical intervertebral disk.

The artery and the ventral ramus of the spinal nerve cross paths at this bony constriction (Fig. 12.6). Both of these conductive pathways can be compressed and irritated by protruding osteophytes associated with severe degenerative changes in the segment. Of all the sections of the vertebral column, stenosis of the intervertebral foramen most often irritates nerves in the cervical spine.

The uncinete process (also called the uncus of body) deserves a special mention. This process forms the side rim of the vertebral body's end plate and its size increases in the more superior vertebrae. The uncinete processes are the largest on the C3 end plate. They develop between the ages of 2 and 24 and later form the uncovertebral joint with the more superiorly positioned vertebral body. During this development, the intervertebral disks tear on the outer sides from approximately the age of 10 onward (Fig. 12.7). This can lead to bisection of the disk (Raubert and

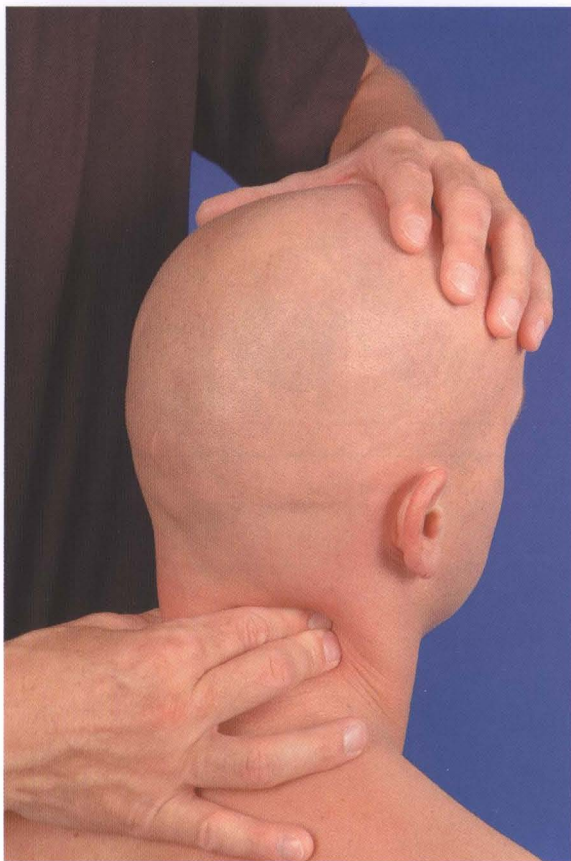


Fig. 12.8 Palpating a ZAJ.

Kopsch, 1987). When this occurs, the contents of the nucleus pulposus neither leak out nor does the segment become thinner. This bisectioning is complete between the ages of 45 and 50. This is a natural adaption of the intervertebral disks in response to the large translation of the vertebra during cervical spine flexion and extension. The uncinat processes act as rails and guide this translation movement. The bisectioning of the disk is the reason why whiplash can cause height to increase by up to 2.5 cm (abnormal ability to separate) within seconds and is especially seen in the C2/C3 segment.

How Does this Affect Palpation?

In the cervical spine, a relatively large number of bony structures, joints, and muscles can be reached and differentiated from one another using palpation. Important reference points include the accessible spinous processes (C2, C5–C7) and the laminae of every cervical vertebra inferior to C2. The fact that the spinous process and laminae of a vertebra are located at the same level is very convenient for palpatory orientation.

This is of assistance when the exact level of structures, for example, the ZAJ and the transverse process, is being

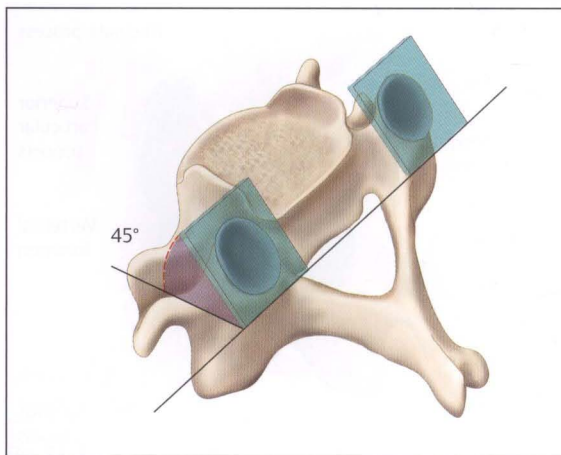


Fig. 12.9 Alignment of the ZAJs in the sagittal plane.

determined. The laminae can be used to fix a vertebra during certain manual-therapy techniques.

When all accessible ZAJs (articular column) are palpated from superior to inferior, the protruding processes and the more concave sections between the processes have an undulating shape (**Fig. 12.8**).

The cervical transverse processes are aligned diagonally in an anterolateral direction so that the ventral rami and the brachial plexus can be palpated between the sternocleidomastoid and the descending part of the trapezius (see “Supraclavicular Triangle of the Neck” below, p. 358).

Lower Cervical Spine Biomechanics

The range of motion in the cervical spine is dependent on age and gender (Penning, 2000). Young women are the most mobile. The largest range of motion is seen with rotation, followed by flexion and extension. Lateral flexion has the smallest range of motion. Lateral flexion is quite complicated in the cervical spine and is mainly used in association with rotation (coupled movement).

The alignment of the ZAJ surfaces is crucial for determining how rotation and lateral flexion are conducted. The joint surfaces are large and flat and are aligned at an average angle of 45° anteriorly and superiorly toward the end plate (**Fig. 12.9**; Dvořák, 2008). Penning (2000, p. 89) reported a large variation in angles. In connection with cervical lordosis, therapists can note that the joint surfaces are generally aligned anteriorly and superiorly toward the eye socket.

Almost all lower cervical joint spaces are aligned horizontally in the frontal plane. Only the C2/C3 segment is angled in a superior direction (**Fig. 12.10**).

Due to the alignment of the joint surfaces, rotation is inevitably coupled with lateral flexion and the axis of rotation is tilted (**Fig. 12.11**). Corresponding to this, rotation to the right is accompanied by lateral flexion to the right,

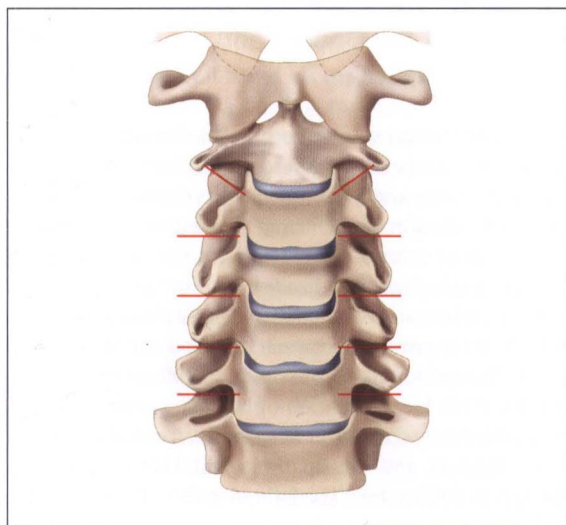


Fig. 12.10 Alignment of the ZAJs in the frontal plane.

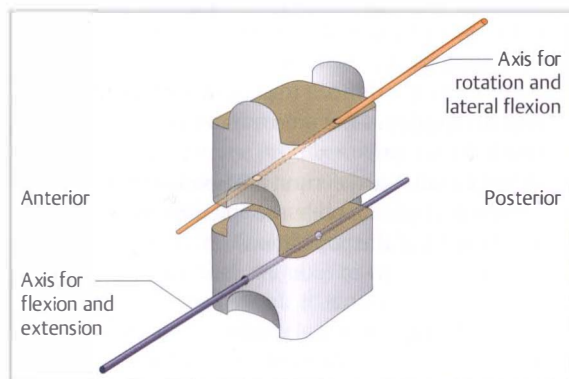


Fig. 12.11 Position of the axes of rotation.

regardless of whether the cervical spine is positioned in flexion or extension. Lateral flexion to the right is also accompanied by rotation to the right. The range of of the coupled motion is surprisingly large in the cervical spine. Lysell (1969) has stated that approximately 8° of lateral flexion at the C2/C3 segment is connected with approximately 6° of coupled rotation.

During lateral flexion to the right and the associated ipsilateral rotation, the joint surfaces on the right glide together (convergence), just as they do during extension. The joint surfaces on the left glide away from one another (divergence), similar to the movement during flexion (Fig. 12.12).

How Does this Affect Palpation?

Therapists use the two previously described relationships to their advantage when palpating the lower cervical facet joints (inferior to C2/C3) during movement: the degree of

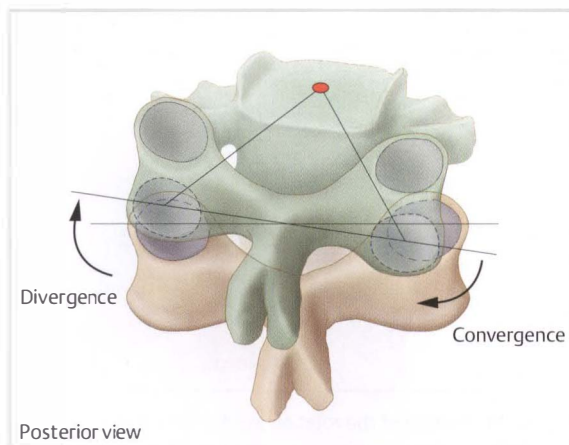


Fig. 12.12 Movement of the joint surfaces during lateral flexion and rotation to the right.

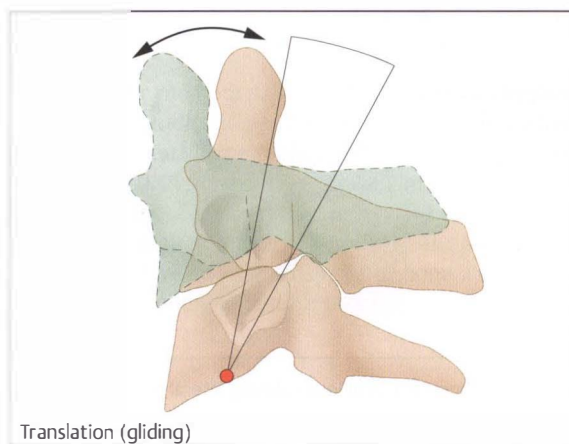


Fig. 12.13 Position of the rotation axis for flexion and extension at C2/C3.

coupling and the movement of the joint surfaces as they converge.

Therapists aim to feel the posteroinferiorly directed swaying of the joint processes as the ZAJ moves (see "Facet Joints" below, p. 339). They therefore facilitate lateral flexion with rotation to the right when they are palpating the right side, so that the joint process moves toward the palpating finger. Movement is facilitated via lateral flexion and causes the segment to rotate extensively. If rotation was facilitated first, it would take quite a while for C1/C2 to reach end-range rotation and for rotation to be transferred onto the inferior segments.

Penning (2000) has explained the kinematics during flexion and extension very well. His study results describe the momentary rotation axes for flexion and extension and were radiologically determined for every 5° of movement. The investigators discovered a relationship between the superior joint processes and the end plate, which determines the position of the axis for rotation. In the upper intervertebral disk segments the axis is lo-

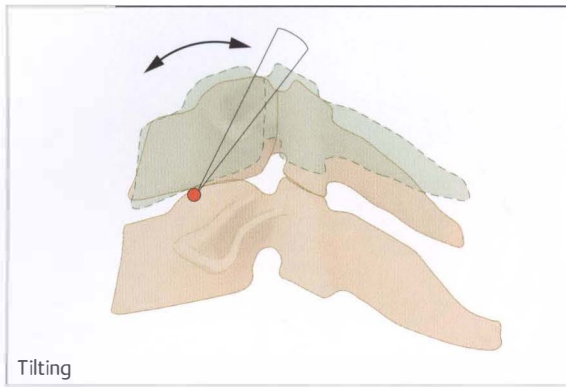


Fig. 12.14 Position of the rotation axis for flexion and extension at C6/C7.

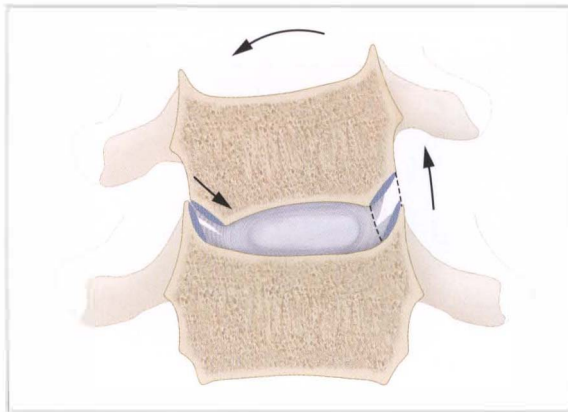


Fig. 12.15 Uncovertebral joints during lateral flexion.

cated in the inferior vertebra and results in the superior vertebra undergoing a large translation movement in addition to tilting during flexion and extension (Fig. 12.13). In the lower intervertebral disk segments, the axis is found near the intervertebral disk. The tilting movement is therefore very large and the translation minimal (Fig. 12.14).

The large translation, for example, in the C2/C3 segment, produces strong shear forces that act on the intervertebral disk. These forces must be seen as having a direct relationship with the bisectioning of the intervertebral disk and the development of the uncinat process.

The uncovertebral joints control lateral flexion and ensure that the coupling of segmental rotation and lateral flexion is transferred quickly onto the next inferiorly located segment (Fig. 12.15). As joints that develop with age, the uncovertebral joints can also cause local lateral cervical symptoms during lateral flexion when disorders are present.

Anatomy of the Occiput and the Upper Cervical Spine

The upper cervical spine is responsible for supporting the sense and balance organs (Herdmann, 2000), for example, by coupling eye and head movements (cervico-ocular reflex) with the aim of stabilizing the field of vision.

The upper cervical spine “contains the most complex, unique, and highly specialized structures” in the vertebral column (White and Panjabi, 1990, p. 82). Anatomy varies greatly at the junction between the head and the cervical spine. These deviations from the norm affect the expected results of the local palpation of bony structures to a limited extent only. The effect of some anatomical variations is so extreme, and even pathological, that they are described as deformities. The following deformities directly influence palpation:

- Minimal development of the occipital condyles causes the dens to protrude into the inner skull. The malformations are labeled “primary basilar impressions” (Lanz and Wachsmuth, 1979, p. 309) and may result in neurological deficits. When condyles have a flattened form, it is difficult to palpate the transverse process of the atlas as the process is found directly underneath the occiput.
- When the atlas and occiput are fused together, the C0/C1 segment is immobile (occipitalization; present in less than 1% of the population).

Occipital Bone

The occiput is composed of two large areas:

- Posterior section: squamous part of the occipital bone.
- Inferior section: lateral and basilar parts.

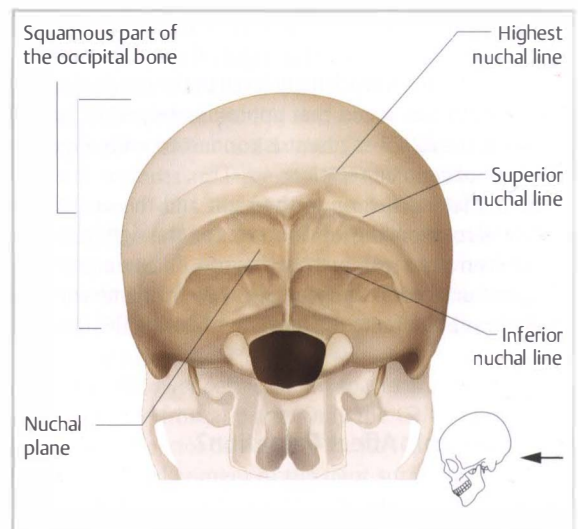


Fig. 12.16 Posterior aspect of the occipital bone.

The squamous part of the occipital bone (Fig. 12.16) is the rounded posterior region of the roof of the skull. It is connected to the parietal bones via the lambdoid suture and the temporal bones via small lateral sutures. It is divided into two flat areas called the occipital plane and the nuchal plane. Each area has a different function. The nuchal plane is covered by the neck muscles and is separated from the occipital plane by the superior nuchal line. The transverse lines and ridges, protrusions, and areas found on the nuchal plane can be palpated particularly well.

The external occipital protuberance is the most prominent point. It represents the end of a medium-sized crest that travels in a posterosuperior direction from the foramen magnum and also marks the site of insertion for the ligamentum nuchae. Lanz and Wachsmuth (1979, p. 314) describe this reference point very precisely. The shape of the protuberance varies greatly and it often tapers downward. It is only well developed in approximately 11% of all individuals. The point protruding the most is called the "inion." This elevation is more developed in pets (e.g., dogs and cats) than in humans. This is due to larger loads being applied to the ligamentum nuchae of these animals, which in turn places more tension on the site of insertion.

The position of the three transverse ridges can be described in relation to the protuberance:

- **Highest nuchal line.** This convex line starts directly on the protuberance and extends laterally and somewhat superiorly. It is the line of insertion for the extensive mimic muscles that are able to move the scalp and the ears to some extent. It is rarely well developed and may also be completely absent.
- **Superior nuchal line.** This widely arched, convex line also travels laterally, extending from a position slightly inferior to the protuberance. Lanz and Wachsmuth (1979, p. 314) estimate that approximately 37% of all superior nuchal lines are well developed. The large intrinsic muscles are noticeable directly below this line: semispinalis cervicis, splenius capitis, and the descending part of the trapezius.
- **Inferior nuchal line.** This line is found one finger-width inferior to the protuberance. It first travels transversely and later bends anteriorly, almost at a right angle. The transverse section meets with the superior nuchal line laterally. Together, both of these lines can form a palpable elevation: the retromastoid process (Lanz and Wachsmuth, 1979, p. 315). The inferior nuchal line marks the site of insertion for the deep neck muscles (rectus and obliquus muscles).

The inferior aspect of the occipital bone is divided into two sections (Fig. 12.17). The lateral part is characterized by the area surrounding the foramen magnum. With its diameter of 3–3.5 cm and its bulging rim, the foramen magnum forms a passage for the spinal cord and other structures. Two biconvex condyles are found laterally and are divided into two separate parts in 5% of the popu-

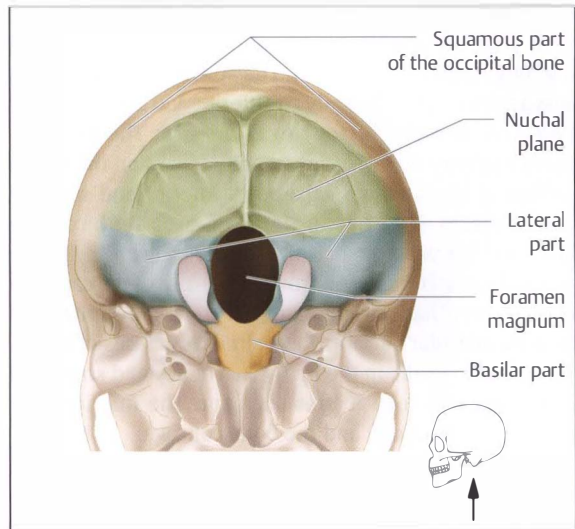


Fig. 12.17 Inferior aspect of the occipital bone.

lation (Raubert and Kopsch, 1987). The division of the joint cartilage is an indication of the different types of loading applied to the cartilage surfaces during flexion and extension at the C0/C1 segment. As already mentioned, anatomy also varies considerably here. The condyles are aligned so that they converge anteriorly. The basilar part is similar to a wedge-shaped piece of bone and is connected to the sphenoid bone anteriorly.

Atlas

The atlas has the special function of an adaptor or intermediate plate by transmitting the predominant movements of flexion and extension in the C0/C1 segment onto the C1/C2 segment in the form of rotation.

The first cervical vertebra consists of a ring with delicate anterior and posterior arches (Fig. 12.18). The earlier

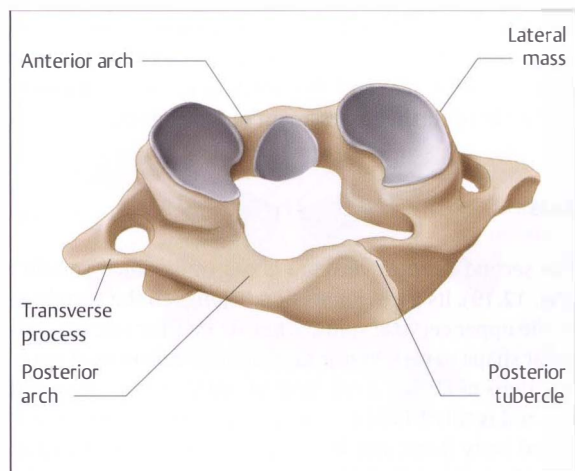


Fig. 12.18 Atlas

C1 vertebral body is now the C2 dens. The dens forms a joint with the anterior arch and is fixed at this point by a strong transverse ligament. The atlas also does not possess a spinous process. Only an anterior and a posterior tubercle can be found on the ring of the atlas. The atlas supports two very well-developed bony blocks on the lateral section of the ring, which support inferior and superior joint surfaces. The superior joint surfaces are biconcave and together with the occipital condyles form the upper cervical joints (C0/C1). Approximately 30% of the cartilage coating here has variable gaps in it. The occipital and atlantal articular surfaces have similar radii of curvature, which results in the high congruency and structural approximation seen in this segment. The inferior joint surfaces are rounded and the bone concave.

A special feature of the atlas is its wide transverse processes. This makes the atlas the widest of all cervical vertebrae. Lanz and Wachsmuth (1979) state that the distance between the tips of the transverse processes in male Central Europeans amounts to approximately 8.5 cm. This distance is approximately the same as the distance between the T1 transverse processes. The tip of a transverse process can be felt between the mastoid process and the ramus of the mandible. The variations in shape and length of the transverse processes can lead to incorrect conclusions when sides are compared during palpation. Dörhage et al. (2004) have once more confirmed the large variation in the anatomy of the upper cervical region in a large radiological study: "We evaluated 212 X-rays of the entire vertebral column and assessed the upper cervical joints and the cervical spine of test subjects who reported being free of symptoms. The asymmetrical position of the participating joint partners varied considerably. Symmetrical positioning of the occiput, atlas, and axis in relation to each other could only be observed in 6% of all cases." They also discovered that the difference in cervical mobility to the left and the right "did not correlate with the anatomical position of the upper cervical joints as radiologically determined." Naturally, this knowledge also influences the results expected when palpating the C1 transverse process. It is not expected that the transverse processes will be of the same length on both sides and should not be classified as abnormal without further assessment of movement.

Axis

The second cervical vertebra is the transitional vertebra (Fig. 12.19). Its superior section belongs to the vertebrae of the upper cervical spine, while its inferior side has a similar shape to vertebrae found in the lower cervical spine. The dens of C2 is 1.5 cm long on average, has a rounded tip, and is tilted 11–14° posteriorly in relation to the vertebral body (Lanz and Wachsmuth, 1979). It is the most reliable bony orientation point in radiographs of the

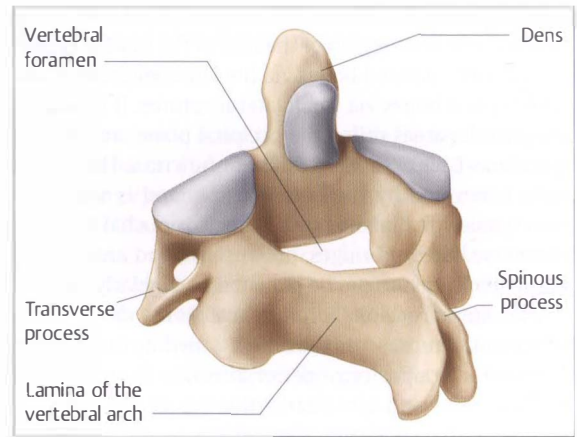


Fig. 12.19 Axis

upper cervical spine. The axis for extensive rotation at C1/C2 is found here.

The anterior side of the dens articulates with the anterior arch of the atlas. Its posterior side articulates with the transverse ligament of the atlas. The superior joint surfaces are found directly adjacent to the dens. They have a biconvex shape and, together with the inferior joint surfaces of the atlas, form the lateral atlantoaxial joints, the real facet joints of C1/C2. The most important feature of the axis for palpation is its particularly prominent bifid spinous process. This is the most important reference point in the upper cervical region. It is found at the level of the laminae of the vertebral arches and the vertebral body. The transverse processes are considerably shorter when compared with the atlas.

The vertebral foraminae of the atlas and axis are large and offer a large amount of space for the dural sac and the spinal column to move in during extensive cervical movements. The dural sac is located near the axis for rotation at C1/C2 and is therefore only mildly deformed during large rotational movements and is not compressed by bone (White and Pandjabi, 1990).

Ligaments of the Cervical Spine

Of the large number of ligamentous structures in the cervical spine, only a few ligaments are of crucial importance in this context.

Ligamentum Nuchae

This long ligament extends from the C7 spinous process to the occipital protuberance and assumes the role of the supraspinous ligament (Fig. 12.20). It has deep laminal and superficial funicular (ligamentlike) sections and connects the occiput directly with the C5–C7 spinous processes.

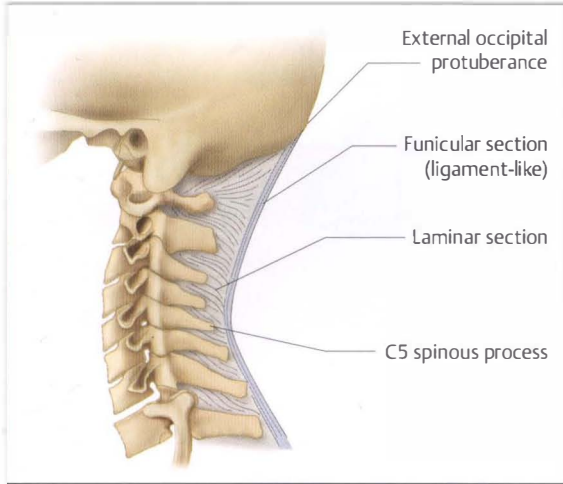


Fig. 12.20 Ligamentum nuchae

The laminar section is a thin partition (septum) made of elastic fibers. The funicular, thin, superficial section is shaped like a ligament. It is formed by the following muscles as they merge to form an aponeurosis:

- Trapezius.
- Splenius capitis.
- Serratus posterior superior.
- Rhomboid minor.

It can be palpated during extensive cervical flexion. The ligamentum nuchae pulls the head back slightly when the cervical spine is maximally flexed, preventing the upper cervical joints from moving into their maximal end position. This presumably helps to protect the spinal cord. It is also placed under tension when the head is retracted and pulls the more inferior vertebra posteriorly so that real extension is produced.

Transverse Ligament of the Atlas

This ligament forms the transverse part of a cross-shaped ligament (**Fig. 12.21**). It originates from the inner side of the lateral mass of the atlas and is 2 cm long. It is approximately 2 mm thick in the middle and approximately 1 cm in height. It is made of very taut connective tissue and is very firm. In the past, anatomists have performed studies demonstrating that this ligament has a tensile strength of approximately 130 kg (Macalister, 1893 in Lanz and Wachsmuth, 1979). It is covered by thin hyaline cartilage on its anterior side and forms part of the median atlantoaxial joints with the dens.

It is found on the posterior aspect of the dens in a circular depression beneath the tip (similar to a scarf wrapped around the neck). The dens is therefore positioned in an osteofibrotic funnel that tapers downward. Even massive tensile forces (up to 40–50 kg) are not able

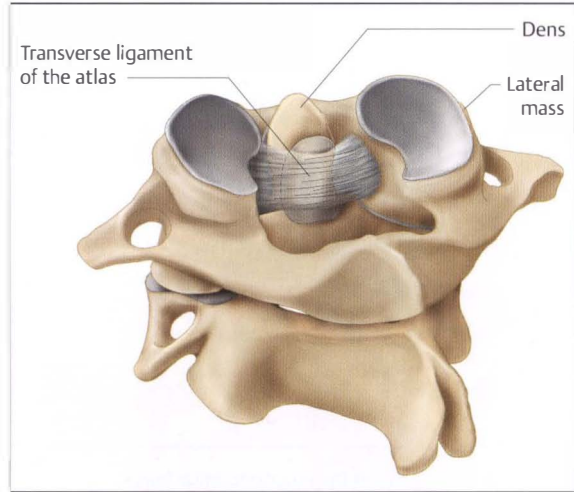


Fig. 12.21 Transverse ligament of the atlas.

to separate C1 from C2 when the ligament is intact. This means that it is impossible to apply traction therapeutically at this joint.

The main function of the ligament is to keep the dens away from the dural sac (with the spinal cord). Physical therapists are familiar with several tests assessing the stability of this important ligament. The ligament also controls the biomechanics between the atlas and axis during flexion and extension and stabilizes the atlantoaxial joints by approximating the joint surfaces with the strength of its tissues.

Alar Ligaments

The four alar ligaments are also very firm (stiff and rigid) and are mostly comprised of type I collagen. The ligamental columns are divided into two groups (**Fig. 12.22**):

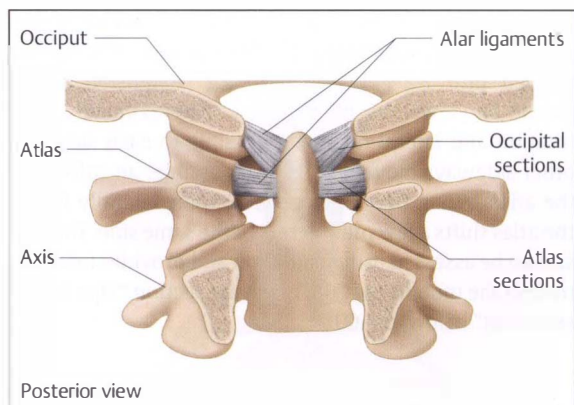


Fig. 12.22 Alar ligaments

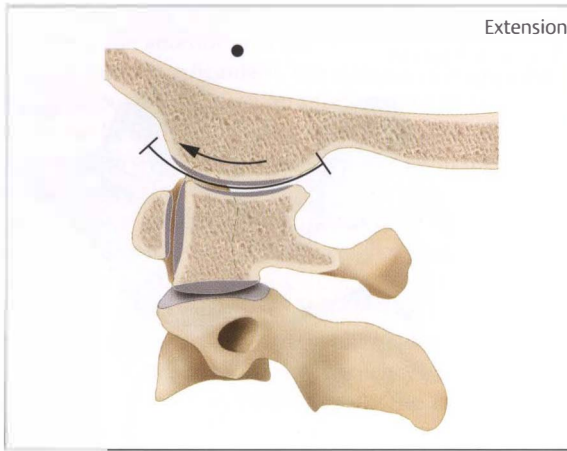

Fig. 12.23 Movement in the atlantooccipital joints.

- **Alar ligaments, occipital sections.** These sections directly connect the posterior upper side of the dens with the occiput. They are 11–13 mm long, 3.5–6 mm thick, and approximately 8 mm wide. These sections transfer lateral flexion of the head directly onto C2.
- **Alar ligaments, atlas sections.** These are found at the level of the transverse ligament of the atlas. They connect the side of the dens with the anterior arch and are therefore only approximately 3 mm long.

Their functions include moving the dens during cervical flexion and extension, limiting the atlantoaxial rotation, and passing lateral flexion of the head onto the axis by rotating C2. The alar ligaments therefore control the central biomechanics in the upper cervical region.

Biomechanics of the Upper Cervical Spine

Atlantooccipital Joints (C0/C1)

The atlantooccipital joints mainly move in the sagittal plane (Fig. 12.23). The range of flexion and extension amounts to approximately 27°. This range can be further divided into 7.2° flexion and 20.2° extension. C0/C1 should be viewed as an “extensor.” Approximately 5° of rotation and lateral flexion is possible to each side. Another sideways movement is also possible: an “offset” of the atlas. When the upper cervical spine laterally flexes, the atlas shifts a few millimeters to the same side. This offset can be assessed using palpation and provides information on the mobility of C0/C1 (see the section “Tips for Assessment” below, p. 360).

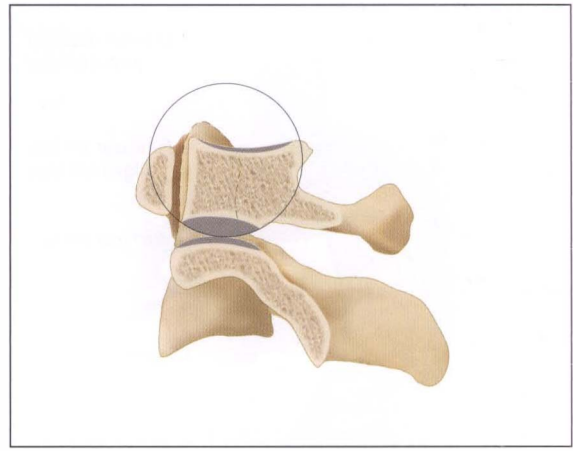

Fig. 12.24 Lateral atlantoaxial joints.

Lateral Atlantoaxial Joints

The lateral osseous atlantoaxial joint surfaces tend to be either flatter in the sagittal plane or have a concave shape (Fig. 12.24). The cartilage is particularly thick in the middle, forming two convexities that face each other and only come into contact with each other in places. This unstable position results in low friction and allows movements to be performed quickly. However, tissues must be quite strong to maintain joint surface contact. The joint capsule is very large as a whole, allowing all movements to be performed. The incongruent joint surfaces are balanced out by the meniscal invagination of the joint capsule.

It is well known that axial rotation is the main movement performed at the C1/C2 segment. Details regarding axial rotation and lateral flexion vary in the literature. When C2 is fixed, approximately 20° of rotation is available to each side. When C2 is free to move, the range of motion amounts to approximately 40°.

The range of flexion and extension adds up to approximately 20°, with this range being evenly divided between flexion and extension. If this were not the case, the range of rotation would differ. The documented range of lateral flexion varies between 0° and 6.5°.

Coupling of Movements during Lateral Flexion of the Upper Cervical Spine

Lateral flexion to the left initially places the occipital section of the right alar ligaments under tension (Fig. 12.25). This causes the posterior side of the dens to move simultaneously and the axis rotates immediately to the left. This transmission of movement is the strongest form of coupling in the musculoskeletal system. It can be recognized by observing the C2 spinous process as it moves to the right. The movement of the spinous process is used to assess the stability of the alar ligaments (see the section “Test for the Alar Ligaments” below, p. 347).

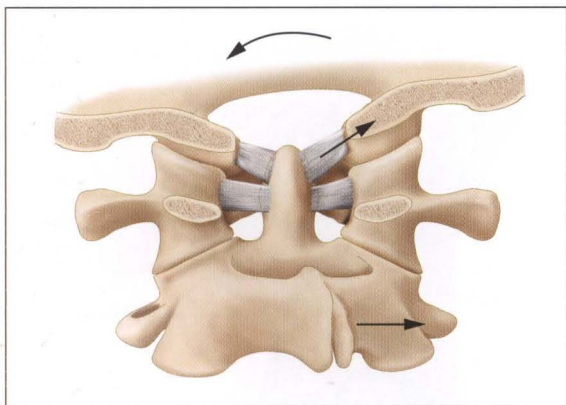


Fig. 12.25 Functions of the alar ligaments, posterior view.

However, therapists are not allowed to draw conclusions regarding the coupling of movements at individual segments based on the relationship between movements at the occiput and C2. The coupling of lateral flexion and rotation is individual here and must therefore be assessed on each patient separately. The variable anatomical shape of the joint surfaces is the presumed cause of these differences.

Posterior Muscles

The medial tract intrinsic muscles are the most important stabilizers and mobilizers in the cervical spine and protrude from the bony depression located between the transverse process and the spinous process (e.g., semispinalis cervicis and capitis).

Extrinsic Muscles

The extrinsic muscles of the cervical spine are also defined as muscles that can no longer be found in their original position and are supplied by the ventral rami of the spinal nerves.

The following muscles are of importance (Fig. 12.26):

- **Descending part of the trapezius.** Extends from the superior nuchal line and ligamentum nuchae onto the lateral third of the clavicle.
- **Levator scapulae.** Extends from the C1–C4 transverse processes onto the superior angle of the scapula.
- **Scaleni muscles.** See the section “Anterior and Lateral Muscles” below, page 329 for a description of their course.
- **Sternocleidomastoid.** Extends from the mastoid process to the manubrium of the sternum and to the medial third of the clavicle.

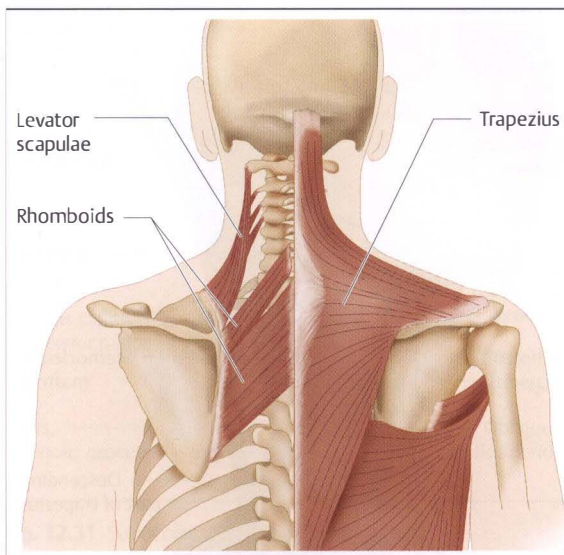


Fig. 12.26 Extrinsic muscles of the neck.

Intrinsic Muscles

When considered from an evolutionary point of view, we observe that a number of elementary muscles also exist in the cervical spine, which are innervated by the dorsal rami of the spinal nerves.

The following large intrinsic muscles (cervical or occipital) are of importance:

- **Semispinalis cervicis and capitis (Fig. 12.27).** The course of the semispinalis capitis: from the C3–T3 transverse processes to the insertion between the superior and inferior nuchal lines. According to Lanz and Wachsmuth (1979) this area is approximately 3 cm wide and 2 cm high.
- **Splenius cervicis and capitis (Fig. 12.27).** The course of splenius capitis: from ligamentum nuchae and the C3–T3 spinous processes to the superior nuchal line.

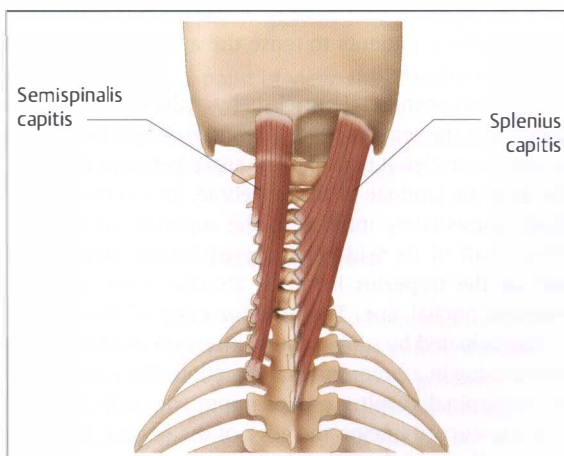


Fig. 12.27 Semispinalis capitis and splenius capitis.

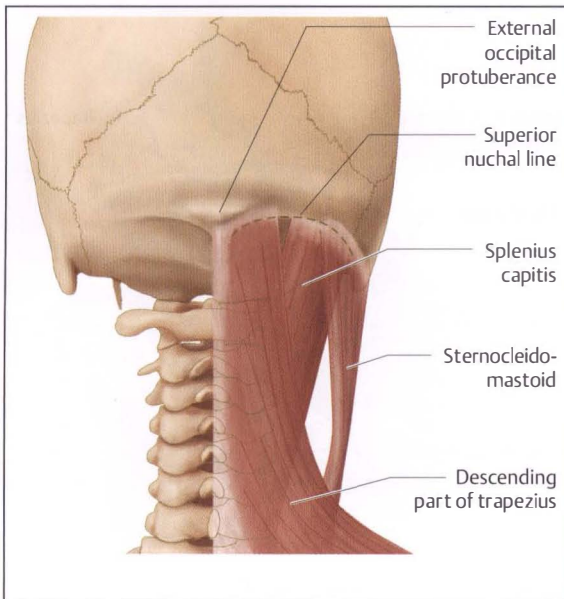


Fig. 12.28 Posterior view of the superficial muscles of the neck.

- **Longissimus cervicis and capitis.** The course of the longissimus capitis: transverse processes of the lower cervical spine and the upper thoracic spine up to the mastoid process.
- **Longus colli and capitis.** See the section “Anterior and Lateral Muscles” below, page 330 for a description of their course.

How Does this Affect Palpation?

An entire group of muscles is encountered when therapists use palpation for orientation. The superficial muscles are the only muscles that can be palpated reliably (Fig. 12.28). Therapists are able to do this by orienting themselves either immediately adjacent to the row of spinous processes or on the edge of the occiput and by instructing their patients to tense the appropriate muscle to confirm its position.

The multisegmental muscle belly of the **semispinalis** is found near the spinous processes and is one of the oblique intrinsic muscles. It occupies the space between the mid-line and the laminae of the vertebrae. Its insertion is located immediately inferior to the superior nuchal line, where half of its width is covered by the **descending part of the trapezius** before it attaches itself onto the superior nuchal line. The anterior edge of the muscle can be palpated by starting at its insertion on the clavicle and moving in a superomedial direction. The insertion of the semispinalis capitis occupies approximately a third of a widely curved line on the edge of the occiput between the mid-line and the tip of the mastoid process.

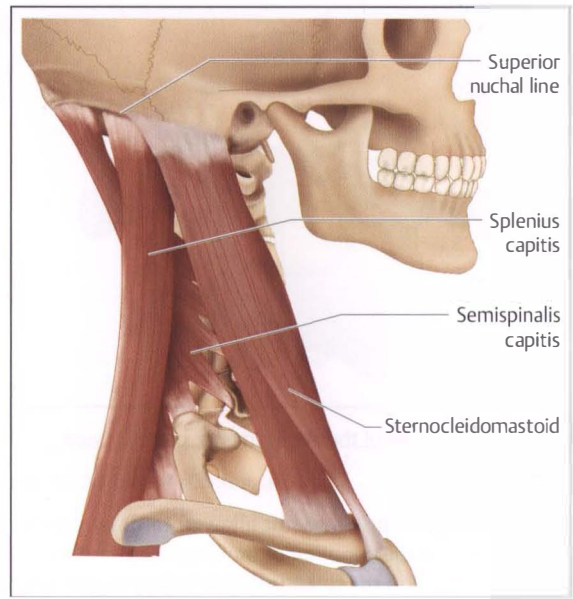


Fig. 12.29 Lateral view of the superficial muscles of the neck.

The **splenius capitis** inserts into the middle third of this line. This strong rotator and extensor belongs to the superficial layer of the intrinsic muscles of the back. The lateral third of the line is occupied by the **sternocleidomastoid**. This muscle does not only insert onto the mastoid process, but also somewhat posterior to it. This can be easily recognized in the lateral view of this region (Fig. 12.29). The sternocleidomastoid aids orientation when the C1–C3 transverse processes are being palpated. The C1 **transverse process** is usually found anterior to the muscle, the C2 transverse process directly posterior to the muscle, and the C3 transverse process along its posterior edge. This muscle is a helpful guiding structure for therapists who wish to correctly locate the transverse processes. The sternocleidomastoid must often be pushed to the side so that therapists can palpate closer to the transverse processes.

Upper Cervical Muscles

The following deep, short suboccipital muscles are of importance:

- **Rectus capitis posterior major and minor:**
 - Rectus capitis posterior major extends from the C2 spinous process and travels obliquely in a superior direction where it inserts into the inferior nuchal line.
 - Rectus capitis posterior minor extends from the C1 posterior tubercle to the inferior nuchal line.
- **Obliquus capitis superior and inferior:**
 - Obliquus capitis inferior extends from the anterior surface of the C2 spinous process, travels in a super-

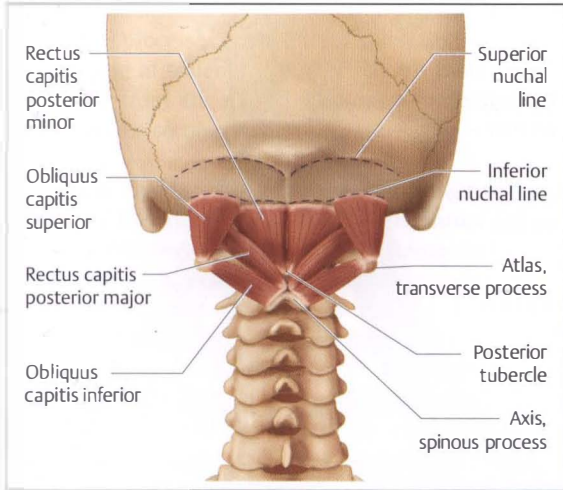


Fig. 12.30 Suboccipital muscles, posterior view.

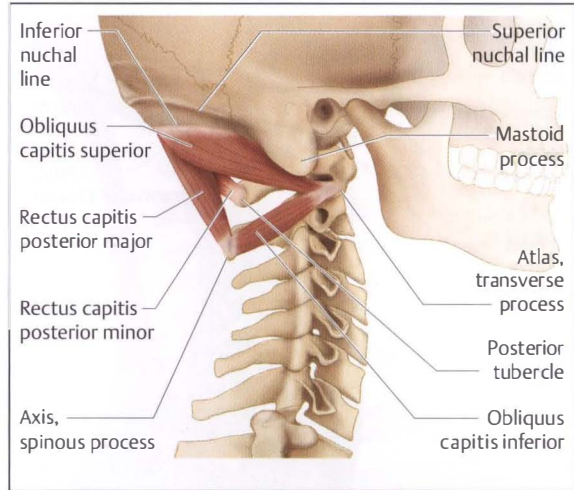


Fig. 12.31 Suboccipital muscles, lateral view.

ior and quite lateral direction, and inserts onto the C1 transverse process.

- Obliquus capitis superior extends from the C1 transverse process in an almost lateral direction in the sagittal plane and inserts into the inferior nuchal line (retromastoid process, see the section “Anatomy of the Occiput and the Upper Cervical Spine” above, p. 322).
- **Rectus capitis lateralis and anterior:**
 - See the section “Anterior and Lateral Muscles” below for a description of their course.

The upper cervical muscles (Figs. 12.30 and 12.31) are supplied by a very large proprioceptive innervation and are important for the fine control of upper cervical movements. These muscles, in combination with the short anterior muscles, form the upper cervical spine's own muscle apparatus. This muscle apparatus takes advantage of the special anatomical features (e.g., using the long lever of the C1 transverse process and the C2 spinous process) and the special biomechanics found in the upper cervical region, and ensures that the upper cervical joints are approximated using the strength of their tissues. Together with the mechanoreceptors in the C0/C1 to C2/C3 joint capsules, the muscle spindles of these muscles form the third organ for balance.

How Does this Affect Palpation?

The upper cervical muscles are covered completely by superficial muscles, making it difficult to reliably locate these structures using palpation. The deep transverse deformation of the functional massage techniques (see the section “Functional Massage” below, p. 349) can be used to easily access the muscles and to relieve tension.

Anterior and Lateral Muscles

The anterior muscles in the cervical spine are divided into two systems according to their position:

- Superficial, prevertebral muscles found anterior to the organs of the throat.
- Deep, prevertebral muscles found directly anterior to the vertebral bodies.

The **superficial prevertebral muscles** are further divided topographically into the following:

- **Suprahyoid muscles:** these muscles are found in the floor of the mouth and connect the hyoid bone with the mandible. They belong functionally to the muscles of mastication (Raubert and Kopsch, 1987, p. 659).
- **Infrahyoid muscles, also called the strap muscles:** these muscles connect the hyoid bone with the larynx (thyroid cartilage) and the sternum. According to Raubert and Kopsch (1987, p. 659), they participate in complex actions such as “chewing, swallowing, and phonation.”

From a mechanical point of view, they form a kinematic flexor chain when the mouth is closed and the jaw closers (masseter and temporalis) are active, producing some strength when the cervical spine is flexed.

How Does this Affect Palpation?

The correct localization of the hyoid bone and the prominent sections of the larynx is used to confirm the level of the cervical vertebrae. The palpation of posterior structures is very difficult in the supine position, for example, when locating the exact position of the C4 lamina. The anterior structures are used as a further aid here.

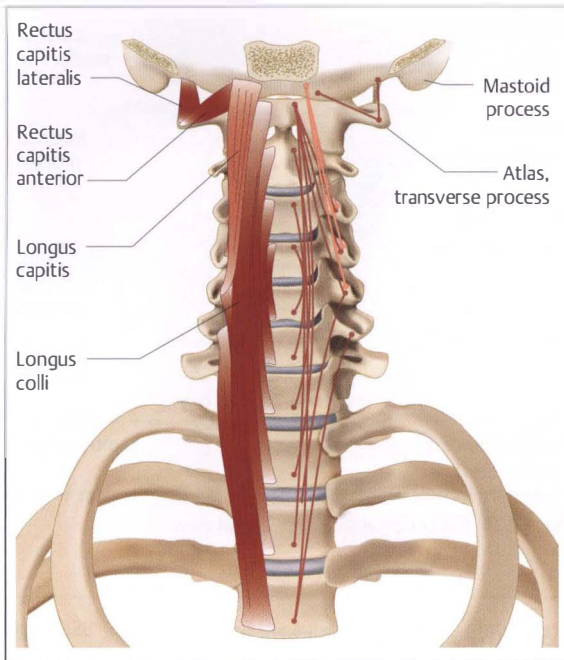


Fig. 12.32 Deep prevertebral muscles.

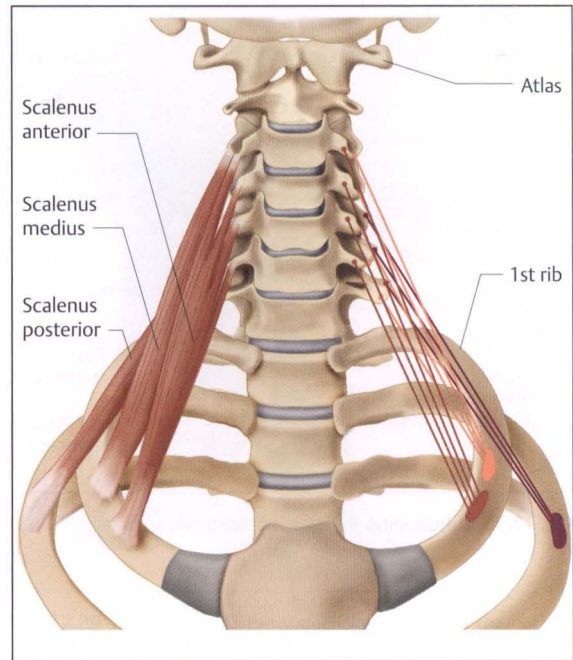


Fig. 12.33 Scaleni muscles

The hyoid bone is mostly found deep in the angle between the floor of the mouth and the vertical surface of the throat, at approximately the level of C3. Its position varies a lot. It is quite often found at the level of the mandible and is then difficult to reach. Please refer to the section “Anterior Palpation Techniques” below, page 362.

The **deep prevertebral muscles** include:

- **Rectus capitis lateralis and anterior:**
 - Rectus capitis lateralis extends superiorly from the C1 transverse process onto the lateral part of the occiput.
 - Rectus capitis anterior extends in a superomedial direction from the anterior aspect of the C1 transverse process to the basilar part of the occiput.
- **Longus colli and capitis:**
 - Course of longissimus capitis: this muscle is divided into several sections. Its vertically and transversely oriented fibers extend from approximately T3 to the atlas and rest against the vertebral bodies on both sides.
 - Course of longus capitis: from the C3–C6 transverse processes, traveling in the depression between the transverse process and vertebral bodies, and inserting onto the basilar part of the occiput.

The recti muscles and longus capitis, in combination with the short posterior muscles of the neck, ensure that the upper cervical joints are approximated. These muscles should be trained when the upper cervical region is unstable.

The “longus group” of muscles is known clinically as the stabilizers of the cervical spine. Physical therapy treatment for instability, particularly in the lower cervical spine, should aim to recruit the longus colli muscle. Falla et al. (2004) proved in their EMG study how important the longus colli and longus capitis muscles (deep flexors of the neck) are. These muscles were shown to be less active during craniocervical flexion in patients with chronic cervical symptoms compared with people who were free of symptoms. The patients’ symptoms responded positively to the training of these muscles.

The deep prevertebral muscles (Fig. 12.32) cannot be palpated. They have only been included in this chapter due to their great importance in clinical practice.

- **Scaleni muscles.** According to Rauber and Kopsch (1987, p. 665), these muscles belong to the deep lateral muscles of the neck and are the continuation of the intercostal muscles in the cervical region. Due to this, the scaleni muscles also originate on the anterior tubercle of the transverse process, the rudiments of the cervical ribs. Their muscle bellies form a cone-shaped covering over the pleural dome, with nerves and vessels being able to pass through two gaps in the muscles (scalenus gaps) (Fig. 12.33). It is obvious that their suitability as respiratory aid muscles is based on their position and their site of origin:

- Course of scalenus anterior: extends anterolaterally from the C3–C4 transverse processes onto the first rib. The phrenic nerve accompanies it for part of its course.

- Course of scalenus medius: from the C3–C7 transverse processes down onto the first rib.
- Course of scalenus posterior: travels more posteriorly from the C5–C7 transverse process down onto the second rib.

The scaleni muscles can be reached well using palpation. They cover the anterolateral region of the throat and are only partially covered by the sternocleidomastoid.

The **anterior scalenus gap** (Fig. 12.34) is formed by the sternocleidomastoid and scalenus anterior. The subclavian vein and the phrenic nerve pass through here.

The **posterior scalenus gap** (Fig. 12.34) is formed by the scalenus anterior and scalenus medius. The subclavian artery and the brachial plexus pass through this gap. The constriction of these structures as they pass through this gap in the muscles is known as “scalenus syndrome” or a form of “thoracic outlet syndrome.”

Nerves and Blood Vessels

The nuchal fascia extends superiorly from the upper edge of the serratus posterior superior. In contrast to the thoracolumbar fascia, the nuchal fascia is generally weak. It encloses the intrinsic muscles, lying on top of the semispinalis capitis and splenius, and, together with these muscles, is noticeable along the superior nuchal line. It merges with the ligamentum nuchae medially and is connected anteriorly with the deep layer of the cervical prevertebral fascia that surrounds the scaleni muscles, longissimus cervicis, and longissimus capitis. A stabilizing action, as seen in the corresponding fascia in the lumbar spine, has not been attributed to the nuchal fascia.

A variety of neural and vascular structures travel posteriorly, through the superficial neck muscles and the posterior fascia (nuchal fascia and the trapezius fascia), and onto the skull, where they supply the posterior aspect of the head (Fig. 12.35).

Splenius capitis is the **guiding structure** used to comprehend the course of the vessels and nerves in this region.

The lesser occipital nerve emerges from an **angle** formed by the lateral edge of splenius capitis and the posterior edge of the sternocleidomastoid and travels up onto the posterior aspect of the head. It is a branch of the cervical plexus and therefore has an anterior origin.

The occipital vessels (occipital artery and accompanying veins) and the greater occipital nerve exit the fascia of the neck via a **triangle** formed by the medial edge of the splenius capitis, the lateral edge of the semispinalis, and the occiput. They emerge on the surface and also travel to the occiput. The greater occipital nerve passes through the muscle bellies of the semispinalis capitis and the descending part of the trapezius beforehand (Lanz and Wachsmuth, 2004a).

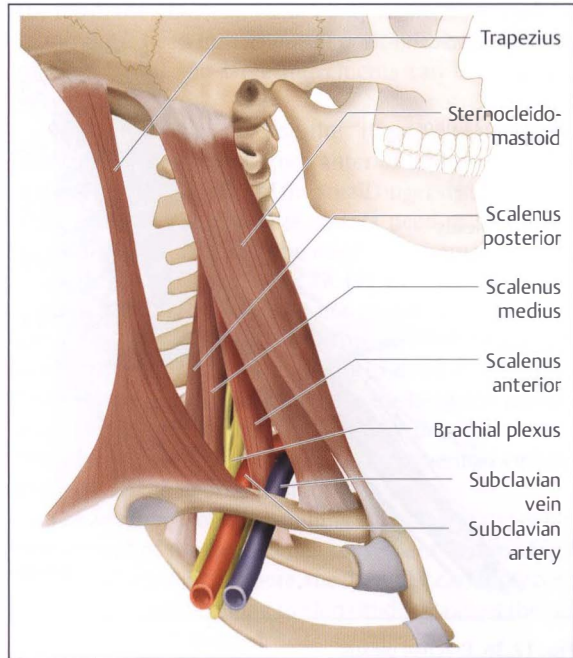


Fig. 12.34 Scalenus gaps

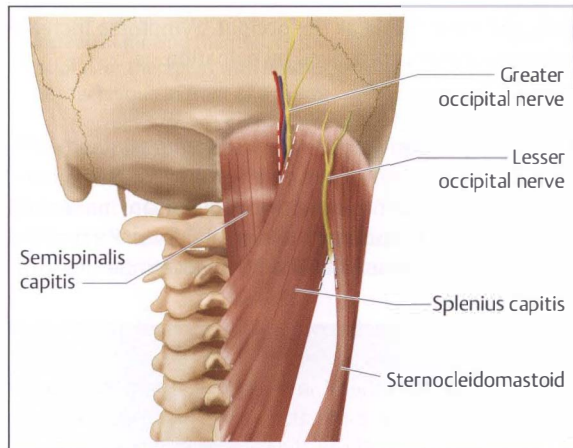


Fig. 12.35 Nerves and blood vessels at the occiput.

The position of the nerves and blood vessels mentioned here appears to be variable as common anatomy textbooks describe and illustrate their position and course quite differently.

How Does this Affect Palpation?

The clinical consequence of neural structures passing through fascia and muscles in the limbs is known as compression neuropathy (entrapment neuropathy). Similar pathological conditions have also been described for the pathway of the greater occipital nerve, which lead to

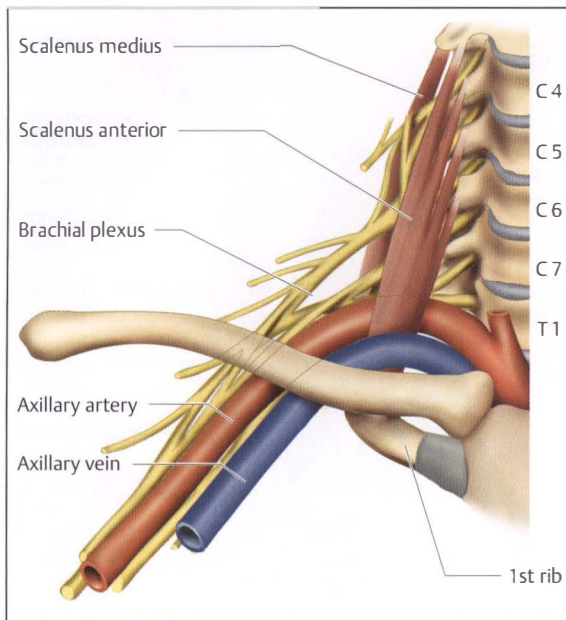


Fig. 12.36 Brachial plexus

pain and dysesthesia at the occiput. Symptoms increase when the nerve is provoked by palpation.

Brachial Plexus

The muscles in the neck and throat region are innervated by the cervical plexus and the cranial nerves. Parts of the brachial plexus innervate the shoulder girdle and arm muscles.

The anterior branches of the C5–T1 spinal nerves unite at the brachial plexus via three trunks and cords and form a number of peripheral nerves. The main peripheral nerves that innervate the arm muscles are well known: the median, ulnar, and radial nerves. Due to the alignment of the transverse processes, the branches that merge into the brachial plexus travel anteriorly at an angle. Together with the subclavian artery, they pass through the scaleni muscles at the posterior scalenus gap and follow the artery through the subsequent narrow gap between the clavicle and the first rib (Fig. 12.36). They can be palpated at the scalenus gap by moving the arm and placing the branches under tension (see the section “Supraclavicular Triangle of the Neck” below, p. 358).

Summary of the Palpatory Process

The aim of palpation is to lay the technical foundations for the local assessment and treatment of the cervical spine. Therapists concentrate on the cervical region as a whole.

Instructions are provided individually for the posterior, lateral, and anterior sections of the cervical spine. The anatomical division of the upper and lower cervical spines is not practical enough for the palpatory procedure.

The palpation of the **posterior** side is the first of the four palpatory procedures that will be conducted. Protrusions and contours from the occiput to the mastoid process will become distinct first. In addition, all bony and muscular structures on the line connecting the occiput to the C7 spinous process will be located as well as possible. The posterolateral ligaments and the ZAJs (facet joints) are palpated next. We finish by returning to the occiput and locating the accessible muscles, nerves, and blood vessels.

Palpation of the **lateral** aspect allows therapists to locate the C1–C3 transverse processes. Additionally, the localization of structures will be described, varying from the soft tissues in the posterior triangle of the neck to the structures found in the posterior scalenus gap.

The **anterior** structures allow therapists to determine the level of individual vertebrae with great certainty. It is for this reason that the hyoid bone and the larynx are included in the palpatory orientation.

It is necessary to discuss the starting positions (SPs) beforehand to ensure that the same conditions are present for each and every palpation.

Starting Position

It is recommended that patients be positioned in neutral, unsupported sitting when the cervical spine is being palpated. The advantage of this SP is that all posterior, lateral, and anterior structures can be easily reached. The slight resting tension in the neck muscles is acceptable. The positioning of the cervical spine in neutral is described very precisely. This position should always be used, except when mobility is clearly restricted or when the patient's current symptoms do not allow this position:

- The head is not shifted forward (protraction) or backward (retraction) in relation to the trunk. In other words, the occiput (most posterior aspect) should be found in the same plane as the upper thoracic spine.
- The cervical spine is also placed in neutral lateral flexion and rotation. Therapists should check the distance between the ears and the upper part of the shoulders as well as the position of the nose in the sagittal plane.
- The upper cervical spine should be positioned in neutral flexion/extension (Fig. 12.37):
 - **Option 1—Frankfort plane.** This reference plane is ascertained using the upper edge of the bony outer opening of the ear (external acoustic aperture or pore) and the most inferior part of the eye socket (orbit) (Greiner, 2000). Penning (2000, p. 159) used the term orbitomeatal plane. It is very easy for therapists to place the head in a neutral position.

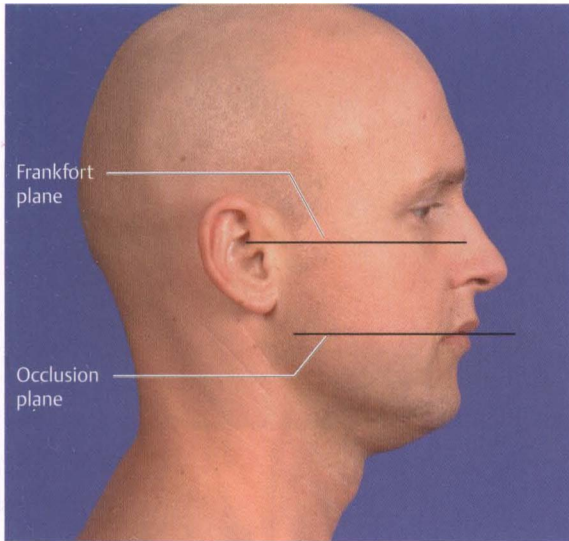


Fig. 12.37 Neutral SP in unsupported sitting.

- **Option 2—optimal occlusion.** When the head is raised and lowered repeatedly in an upright sitting position, the two rows of teeth come into contact when the head is found at a certain position. This is the point of occlusion: the neutral flexion/extension position for the upper cervical spine. This method of positioning in neutral is not particularly practical for therapists.

The therapist usually stands next to the patient. The palpating hand comes from anterior. The other hand controls the patient's head position by placing a flattened hand on

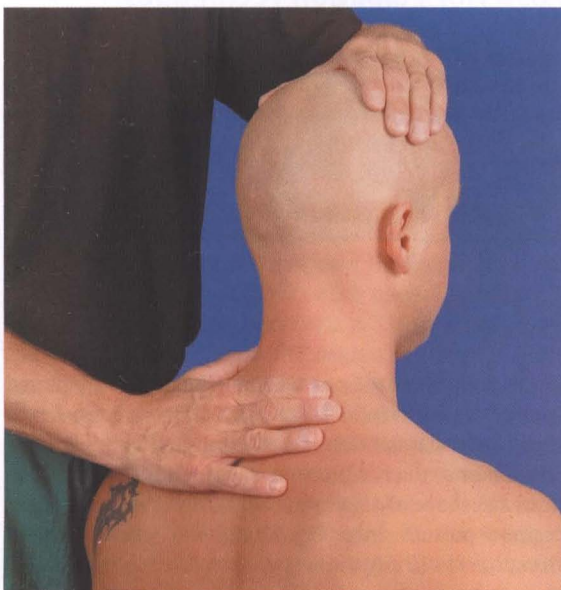


Fig. 12.38 Therapist position and handling—variation 1.

the top of the head (Fig. 12.38). Only slight effort is needed to move the head into a neutral position when using this method. Small and large movements can be facilitated very easily.

Another option is to use the “therapeutic ring.” The therapist's hand comes from anterior and encircles the patient's head. The edge of the small finger rests on the occiput, unless low cervical segments need to be emphasized. If this is the case, the edge of the small finger is placed lower in the neck (Fig. 12.39). The therapist should make sure that the hands do not compress the patient's ear or mandible excessively. The patient's head rests against the therapist's sternum or ipsilateral shoulder. A folded towel can be placed between the head and the sternum or shoulder so that the therapist does not have to bend forward too much to reach the patient's head and to maintain the neutral position.

The advantage of this handling technique is the extensive control of the head. Small movements can be facilitated precisely. Furthermore, the therapist can apply compression or traction along the longitudinal axis of the cervical spine when needed.

Tip: As simple as this hand placement technique may appear, therapists are tempted to move the cervical spine out of the neutral position by pulling the patient's head toward them instead of moving themselves toward the head. It is therefore helpful for therapists with little experience to initially practice this technique in front of a mirror.

The therapist must change position when palpating anteriorly. This SP will be described in the section “Anterior Palpation Techniques” below, page 361. Please read the section “Neutral Starting Position: Sitting”, page 187, for further information on the SP in unsupported sitting.

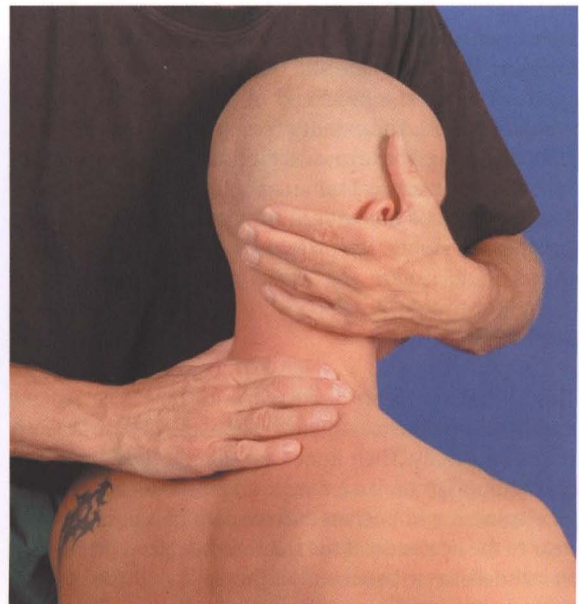


Fig. 12.39 Handling—variation 2.

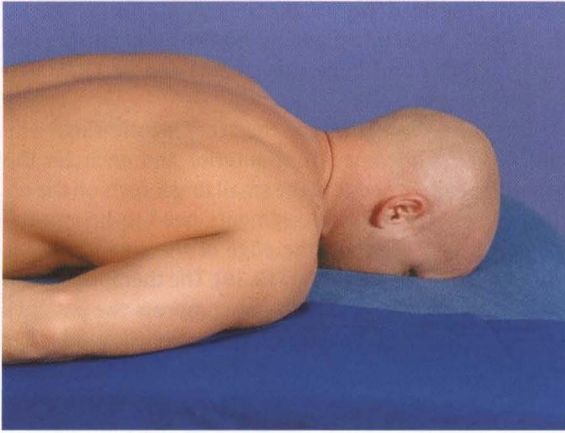


Fig. 12.40 Neutral SP in prone position.

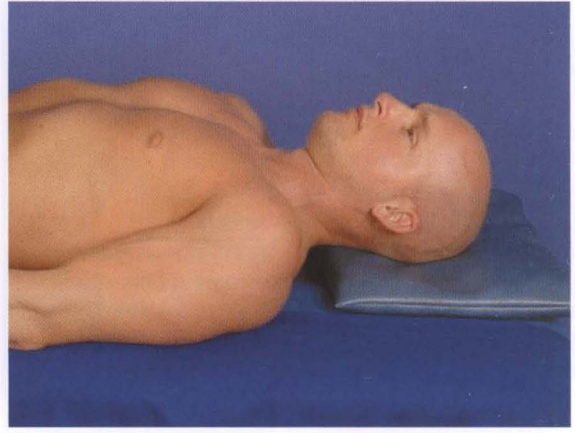


Fig. 12.41 Neutral supine SP.

Difficult and Alternative Starting Positions

Several treatment techniques require patients to be positioned in the supine or prone SP. Cervical spine techniques in side-lying are rare. In the lying SPs, the cervical spine should also be positioned as neutral as possible providing the patient's symptoms do not require another position.

Prone-lying

The prone SP has already been described extensively in Chapter 8. The position of the body on the treatment table is crucial for the positioning of the cervical spine when the nose is positioned in the table's face hole, as is usually the case. Once again, the patient should lie in the middle of the treatment table so that the cervical spine is not positioned in lateral flexion. The thoracic spine is placed in a kyphosis when the head end of the treatment table is slightly lowered. The extent of cervical lordosis can be altered by sliding a little toward the foot-end or head-end of the table. If the cervical spine cannot be positioned in neutral, as described above, it must at least be placed in the position seen when the patient is upright (Fig. 12.40).

Supine Position

This SP has not been discussed until now. The patient usually lies on the treatment table with the arms placed next to the body. Their knees are slightly flexed and rest on padding. For the assessment and treatment of the cervical spine, it is important that the patient is positioned as near to the head-end of the treatment table as possible so that the distance between the therapist and the cervical spine is not too large. The cervical spine is often positioned in too much flexion by using too much padding.

This places the posterior soft tissue under passive tension and positions the lower and upper cervical joints in flexion. This in turn reduces the range of a variety of movements and changes the results of local assessment. It is therefore recommended not to use padding underneath the occiput or to use only a small amount of padding if the lordosis is too extreme (Fig. 12.41).

Note: Place padding only under the occiput and not under the cervical spine!

Certain pathological conditions are painful, for example, an acute wry neck, and require other positions. Of course, the patient's perception has priority over the desire to position the cervical spine in neutral.

Posterior Palpation Techniques

Overview of the Structures to be Palpated

- Occiput.
- Suboccipital fossa and ligamentum nuchae.
- C2 spinous process.
- Spinous process of the lower cervical spine.
- Facet joints.
- Muscles, suboccipital nerves, and blood vessels.

Occiput

The finger pads of the second and third fingers are placed flatly over the occiput. Using a palpation technique with slightly circular motion, the therapist searches for the raised part of the occiput that corresponds to the dimensions and shape of a well-developed tubercle: the external occipital protuberance (Fig. 12.42). The ligamentum nuchae attaches firmly to this point.

Tip: The protuberance is often found higher than expected.

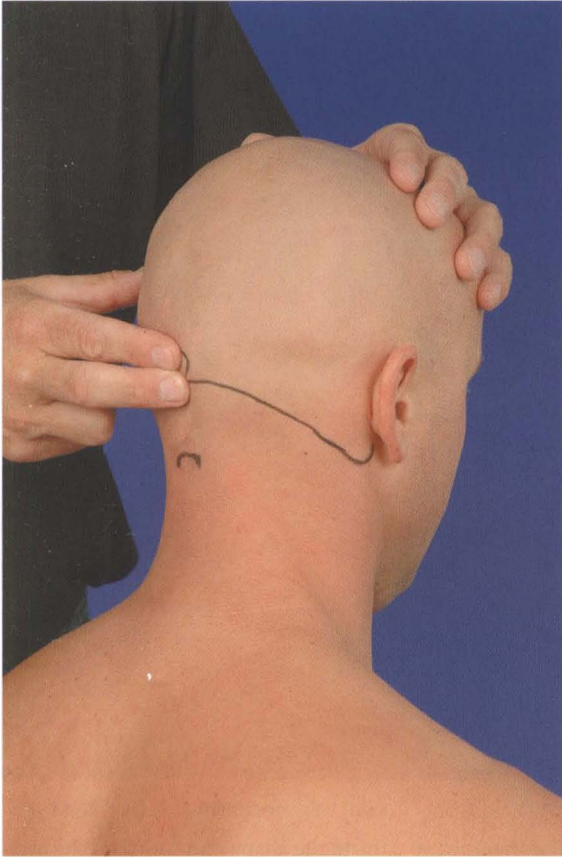


Fig. 12.42 Palpating the external occipital protuberance.

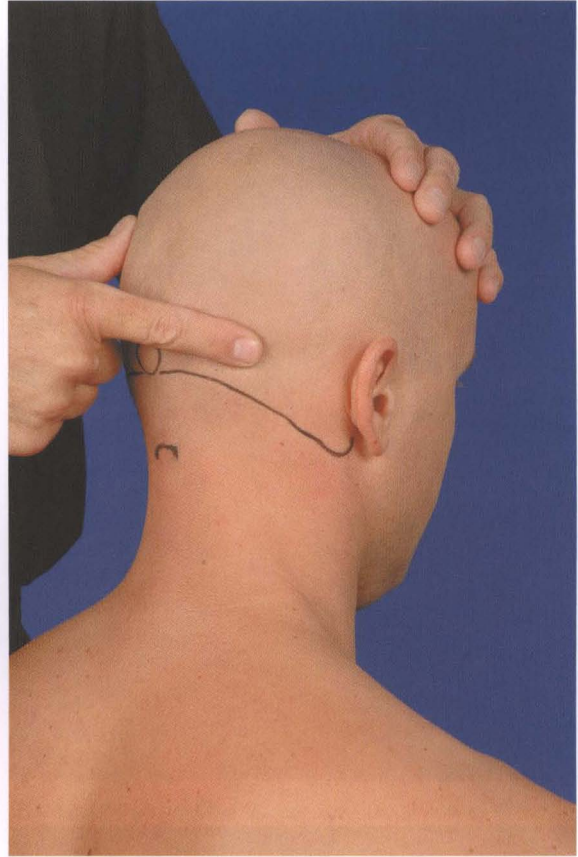


Fig. 12.43 Highest nuchal line.

The uppermost line of the neck, the highest nuchal line, can be visualized from this point by placing a finger across the occiput immediately above the protuberance (Fig. 12.43). The line extends laterally from here in a large arch and is only rarely felt as a raised ridge.

The actual palpation of the edge of the occiput starts now. Starting at the external occipital protuberance, the therapist palpates more inferiorly and laterally until the rounded edge of the occiput can be clearly felt. A perpendicular palpatory technique is used here with the pads of the index fingers pushing against the edge of the occiput from an inferior position (Fig. 12.44a).

From an anatomical point of view, the fingers are at approximately the level of the superior nuchal line. According to Lanz and Wachsmuth (1979, p. 315), the muscles of this area are coarse, with the degree of coarseness depending on the individual. This coarseness bulges out (torus occipitalis) in athletes who have to lean forward and hold their head upright (speed skaters, cyclists).

The insertions of the semispinalis capitis and the descending part of the trapezius (Fig. 12.44a) are found medial and directly inferior to this point. As the therapist moves laterally, the edge of the occiput can be palpated more clearly at two points. These points correspond to the gaps between neighboring muscles and allow the

therapist to access deeper-lying structures. More detailed information can be found in the section "Muscles, Suboccipital Nerves, and Blood Vessels" below, page 342.

A slightly rounded elevation can be felt further laterally (Fig. 12.44b). The superior and inferior nuchal lines meet at this retromastoid process. The obliquus capitis superior attaches here.

Finally, the palpating finger encounters the posterior aspect of the mastoid process as it moves laterally (Fig. 12.44c). The edges of the mastoid process are palpated to measure its dimensions. This process is no longer found on the occipital bone. Instead, it is positioned on the temporal bone. The suture connecting the occipital and the temporal bones runs immediately posterior to the mastoid process.

Suboccipital Fossa and Ligamentum Nuchae

The therapist returns to the external occipital protuberance. The pads of the index or middle fingers are placed flat on the surface of the skin for palpation.

The occiput is palpated by starting at the protuberance, then moving inferiorly. The palpating finger is pressed repeatedly against the bone during this process, enabling

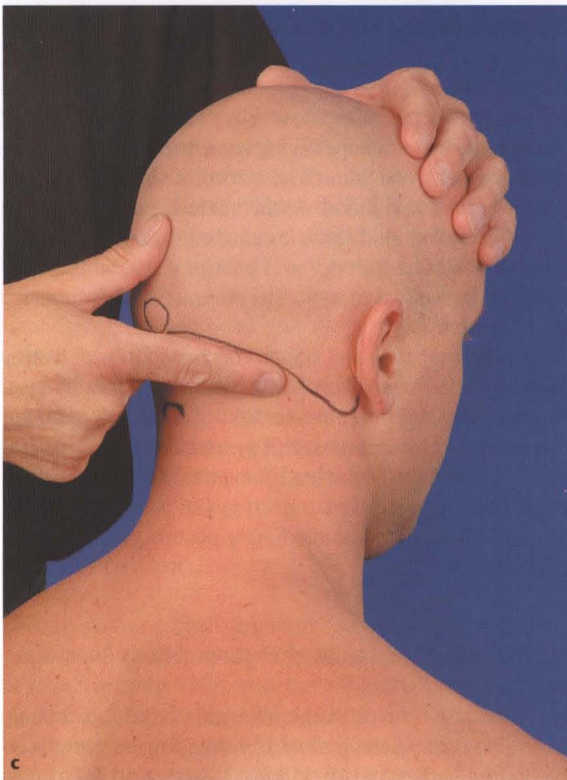
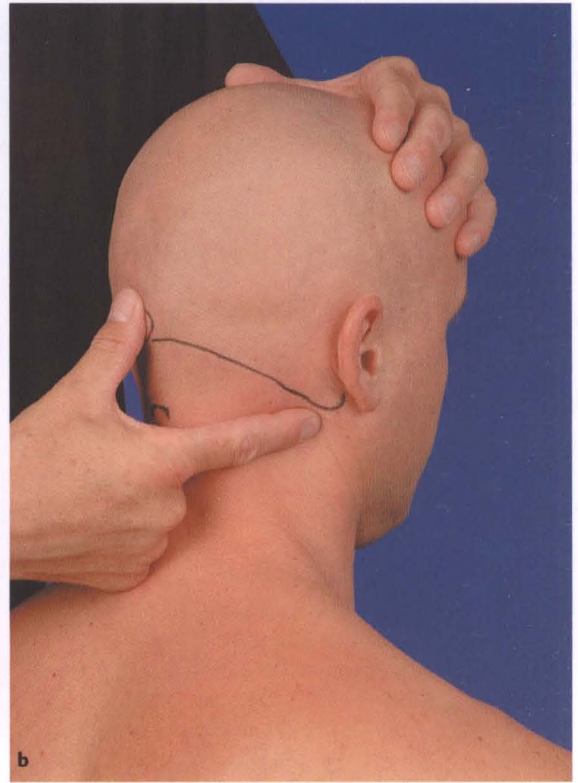
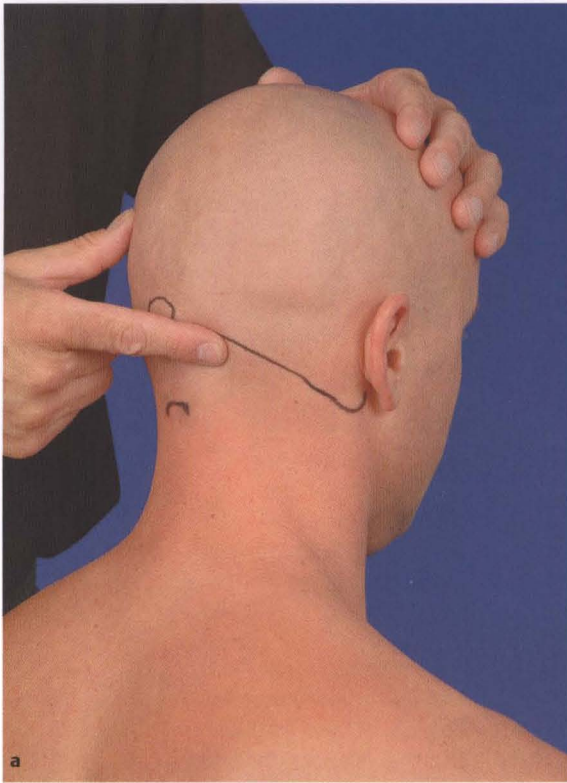


Fig. 12.44a–c Superior nuchal line. **a** Medial. **b** Lateral. **c** Palpating the mastoid process.

the therapist to palpate the shape and course of the occiput.

Important: The therapist should pay special attention to the neutral position of the cervical spine. Every nodding movement, no matter how small, makes it more difficult to palpate the edge of the bone.

When the last point of bony contact with the occiput is felt, the palpating finger pad is located in a large fossa approximately 1 cm in size (**Fig. 12.45**), which is bordered by a variety of structures (**Fig. 12.46**):

- The occiput forms the superior boundary, as has already been palpated.
- The C2 spinous process forms the inferior boundary.
- The strong muscle bellies of the semispinalis capitis and the descending part of the trapezius form the lateral boundaries.
- The ligamentum nuchae forms the anterior boundary.

The therapist feels an extremely elastic form of resistance when applying posteroanterior pressure using the finger pad. By moving the cervical spine into extensive flexion or extension, the therapist can feel the increase and decrease in tension in the ligamentum nuchae more clearly.

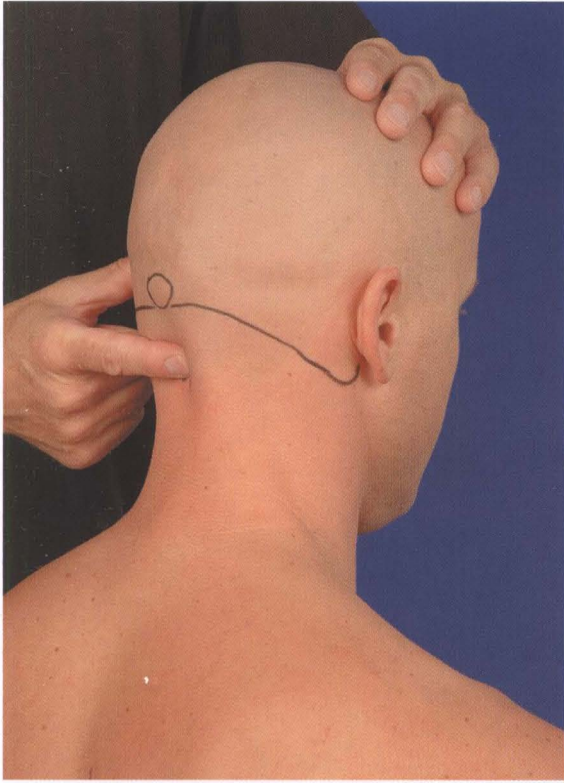


Fig. 12.45 Palpating the suboccipital fossa.

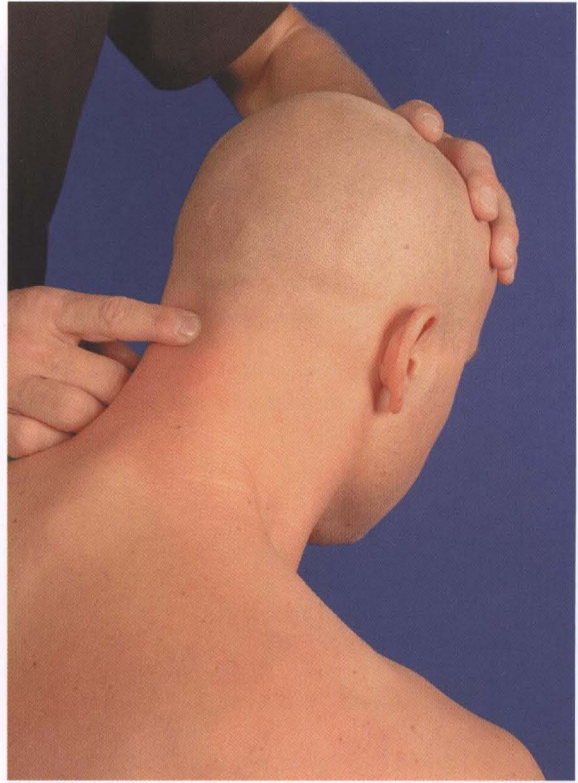


Fig. 12.47 Palpating the ligamentum nuchae—phase 1.

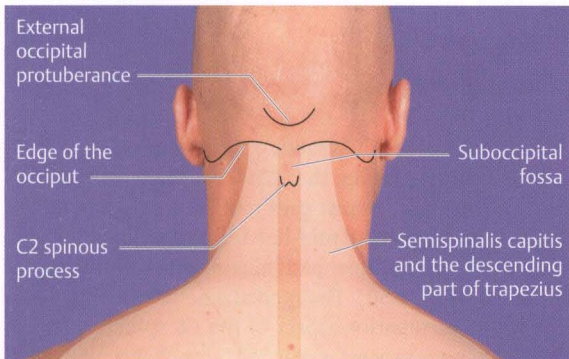


Fig. 12.46 Boundaries to the suboccipital fossa.

Ligamentum Nuchae

The therapist continues to palpate the suboccipital fossa, applying gentle pressure, and moves the cervical spine into full-range flexion (Fig. 12.47).

The upper cervical spine is then moved into alternating extension and flexion (Fig. 12.48). The patient can help by moving their chin forward or by making a double chin.

Expectations

When the head is retracted, the whole ligament is placed under tension and pushes the palpating finger out of the fossa (Fig. 12.48). During active extension, the therapist can feel the tense muscle bellies of both semispinalis capitis muscles on the right and left side.

The therapist can follow the ligamentum nuchae as it extends superiorly up to its point of attachment on the skull by alternately placing the ligament under tension and relaxing it. This method is ultimately used to verify the exact position of the external occipital protuberance.

C2 Spinous Process

The cervical spine is again placed in a neutral position. The palpating finger is positioned in the suboccipital fossa and pushes inferiorly. The hard, bony resistance of the C2 spinous process can be felt immediately. The thumb and index finger are used to palpate the posterior aspect of the asymmetrical bifurcated spinous process (Fig. 12.49).

Tip: Therapists will be surprised by the position of the C2 spinous process if they do not have experience in palpating cervical structures. They will often expect to find the process more superiorly.

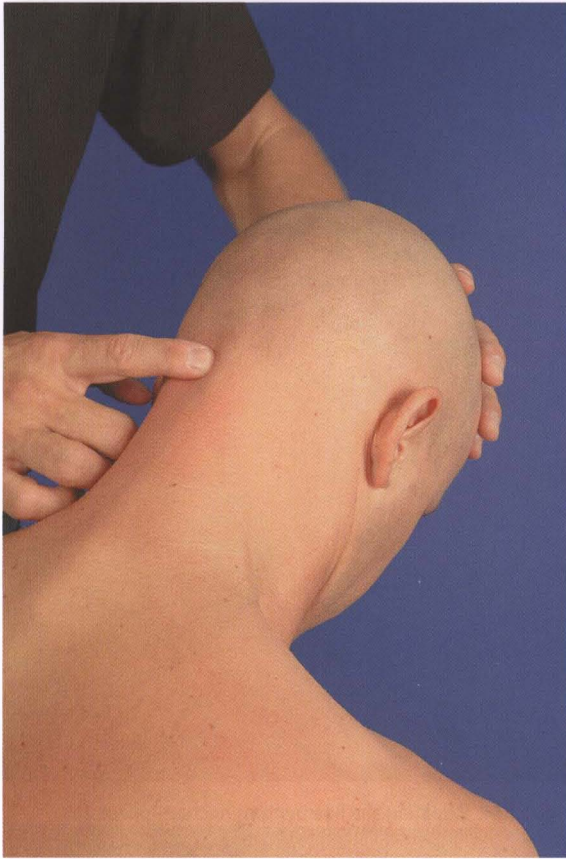


Fig. 12.48 Palpating the ligamentum nuchae—phase 2.

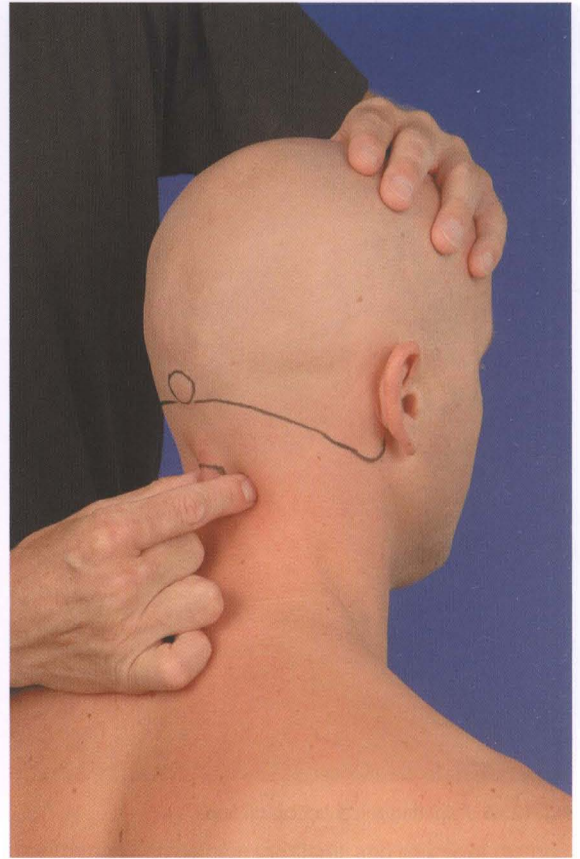


Fig. 12.49 Palpating the C2 spinous process.

The C2 spinous process has to be palpated precisely and even be fixed for local assessment and treatment techniques in the upper cervical region. Fixation is only possible laterally via the laminae of C2 (see the section “Test for the Alar Ligaments” below, p. 347).

Spinous Processes of the Lower Cervical Spine

The identification of the spinous processes at the cervicothoracic junction has already been described in detail in Chapter 11. The methods involved are therefore only summarized here.

In general, it is not possible to accurately identify the C3 and C4 spinous processes. Occasionally, the spinous processes can be felt in patients whose cervical spines have an extremely reduced lordosis. Again, it is not possible to precisely locate the level here. If the therapist wishes to locate the C2/C3 segment, for example, the corresponding posterolateral laminae are used to help define the level. Only the spinous processes from C5 to C7 can be felt reasonably well and can be differentiated from one another.

Unreliable Method

The position of the C5 spinous process can often be recognized by simply feeling the shape of the C6 spinous process. When the therapist uses moderate pressure to palpate along the cervical mid-line from superior to inferior, they often feel the finger pads moving down onto a type of platform (Fig. 12.50). The medial side of the fingers encounters the superior aspect of the C6 spinous process. The C5 spinous process is reached by applying gentle posteroanterior pressure with the finger pad. Since this method is not reliable enough, another aid is needed to improve reliability.

Reliable Method

The patient's cervical spine is placed in a lordosis by tilting the head backward (Fig. 12.51). During this movement, the C5 and C6 spinous processes typically translate anteriorly. This phenomenon has already been commented on in Chapter 11.

The C5 spinous process first moves in an anterior direction, moving clearly away from the palpating finger after only slight lordosis has been achieved. The C6 spinous

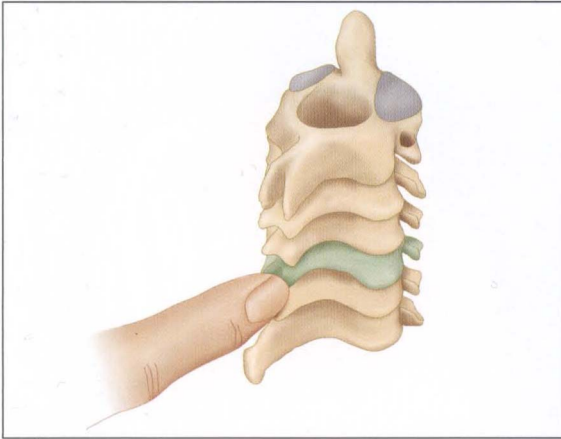


Fig. 12.50 C6 spinous process—unreliable method.

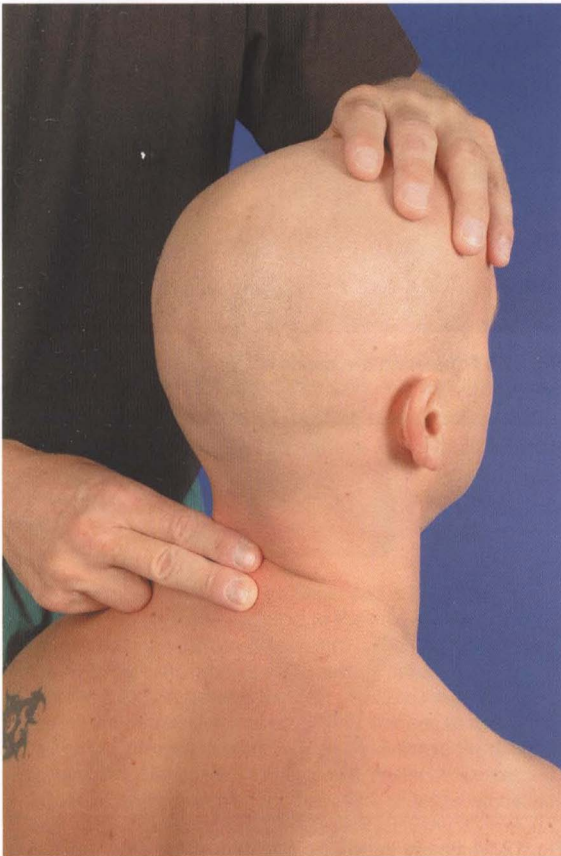


Fig. 12.51 Palpating the spinous processes of the lower cervical spine.

process is then sought. The movement into cervical lordosis is repeated and conducted over a large range. The C6 spinous process starts moving anteriorly at the end of the lordotic range. In contrast, the C7 spinous process tends to remain stationary. It is a prerequisite that the pa-

tient or study partner can extend the neck over a large range without feeling pain.

Facet Joints

The ZAJs, the precise anatomical term for the facet joints, can only be clearly identified in the cervical section of the vertebral column. They are located for diagnostic and therapeutic purposes. Restrictions in joint mobility can be palpated, and irritated capsules are very sensitive to the pressure of palpation.

The following palpatory procedure emphasizes the steps involved when locating the ZAJ between C2 and C3 (see Fig. 12.54):

- C2 spinous process.
- C2 lamina.
- C3 lamina.
- C3 superior articular process.
- Posterior tubercle of the C3 transverse process.
- Palpating movement in the C2/C3 ZAJ.

Identifying a Level via the Laminae

To find the C2/C3 ZAJ, the palpating finger must first be placed over the lamina of C3.

The C2 spinous process is located next (Fig. 12.52). This has already been successfully achieved in previous palpations. Starting at the spinous process, the therapist palpates in an anterolateral direction around the semispinalis capitis. The paravertebral muscles are pushed out of the way posteromedially and posteroanterior pressure is applied. The tissue responds with very firm resistance. The therapist is now palpating the lamina of C2 (Fig. 12.53). The laminae of each further cervical vertebra are found approximately one index finger-width (of the patient) inferiorly.

Tip: All cervical vertebrae can be identified with high reliability when this rule is followed. Reliability can be further increased by identifying the level anteriorly (see “Anterior Palpation Techniques” below, p. 361).

Locating the Articular Column

The lamina of C3 is located (Fig. 12.55). The palpating finger increases the pressure applied to the lamina and follows its course further anterolaterally (Fig. 12.54, phase 1). After a short distance, the palpating finger encounters increased resistance and the palpation changes in a more lateral direction (Fig. 12.54, phase 2). The superior articular process, the C3 component of the “articular column,” is located here.

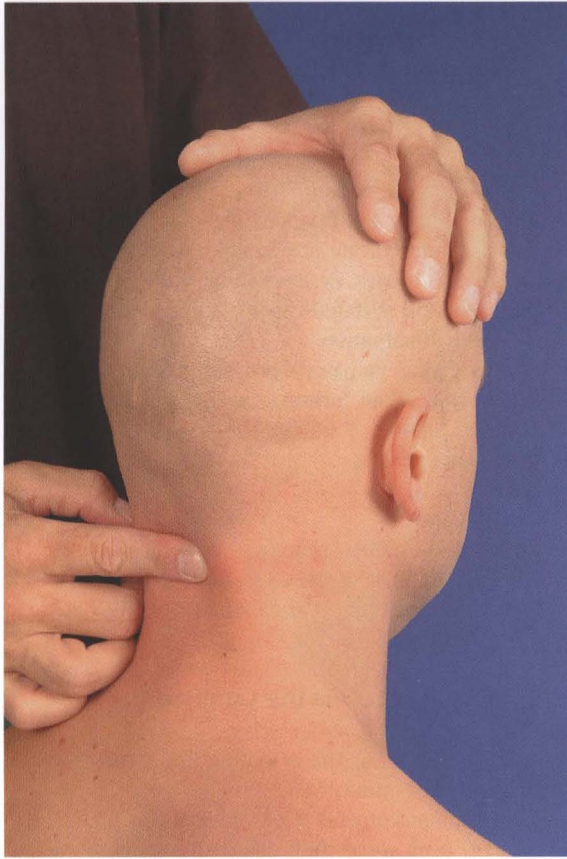


Fig. 12.52 Palpating the C2 spinous process.

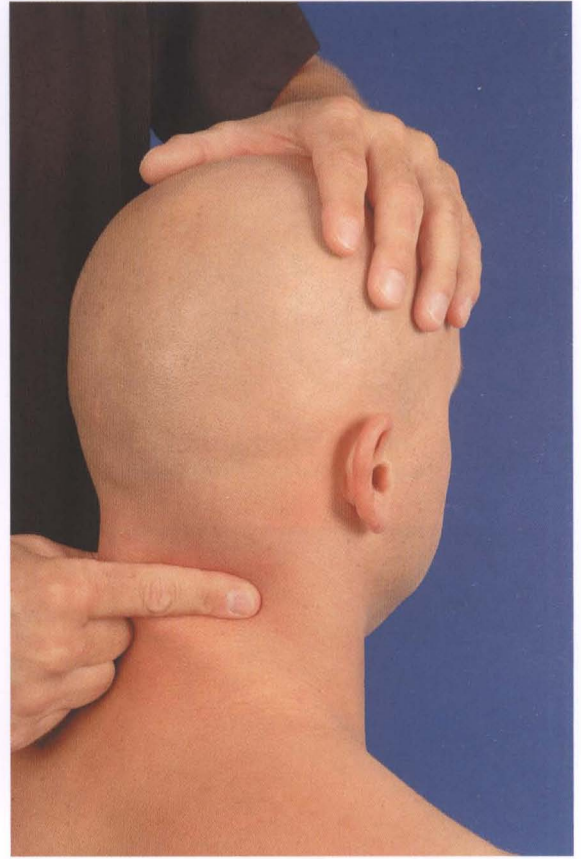


Fig. 12.53 Palpating the lamina of C2.

Confirming the Correct Localization

Three methods are available to confirm the correct localization of the C2/C3 ZAJ:

- The articular column's unfulating shape can be felt underneath the palpating finger as the finger moves extensively in a superior and inferior direction. The ZAJ bulges out posteriorly. The area between neighboring ZAJs is somewhat flatter. Irritated joint capsules are sensitive to pressure when the technique is performed as a provoking palpation.
- The palpation is continued in a lateral direction. The bony resistance decreases and the finger moves anteriorly, with the finger movement depicting a sudden curve (Fig. 12.54, phase 3). The finger has now slid down laterally from the articular column and is located on the posterior boundary of the transverse process (posterior tubercle).
- Confirmation with movement. The finger moves back onto the articular column (Fig. 12.56). The finger pad is located slightly inferior to the C2/C3 ZAJ. This joint is formed by the C3 superior articular process and the C2 inferior articular process. By moving the joint at a very local level, it is possible to feel joint movement

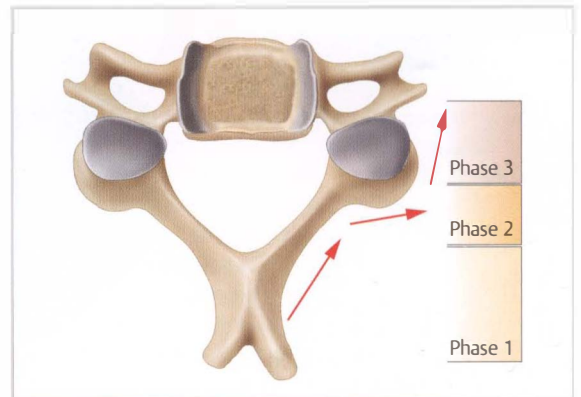


Fig. 12.54 Phases during the palpation of the ZAJ.

as the articular surfaces “glide together” or “glide apart”:

- Convergence—gliding together (Fig. 12.57). The movement preferred here is a very localized lateral flexion toward the side of palpation, with the head being used to facilitate this movement. The therapist can also introduce rotation by rotating the C1/

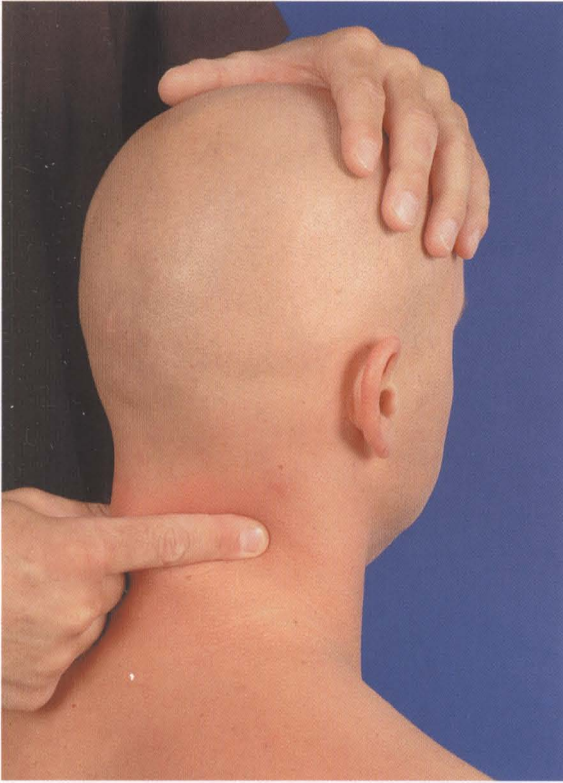


Fig. 12.55 Palpating the lamina of C3.

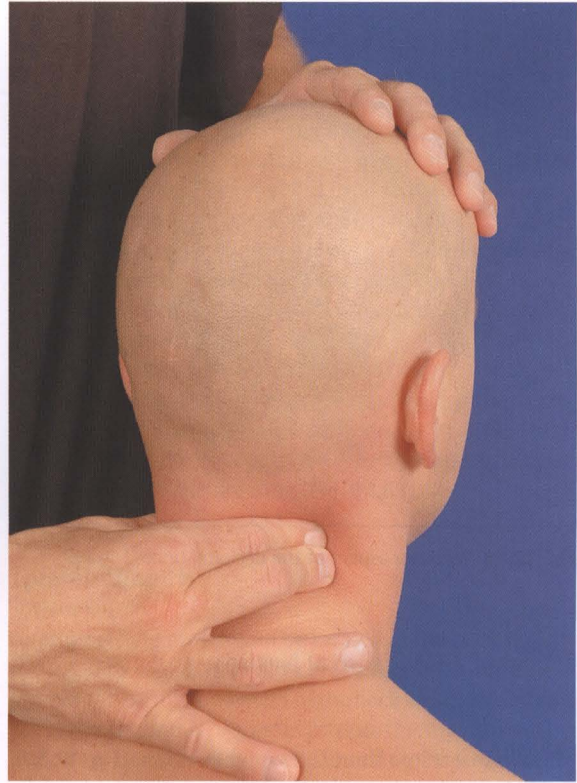


Fig. 12.56 Palpating the C2/C3 ZAJ.

C2 segment for approximately 40° until the movement is passed onto the target segment of C2/C3. When the therapist introduces slight lateral flexion, C2 rotates immediately toward the side of lateral flexion. Movement can be felt at the C2/C3 ZAJ rather quickly.

Tip: The resistance felt by the finger pad is expected to increase when pressure is applied to the inferior articular process of C2. If the expected resistance is not immediately felt, the procedure must be repeated several times.

When the therapist places the joint at its end range via lateral flexion and/or rotation and uses the finger pad to apply rhythmical pressure toward the orbit (parallel to the alignment of the joint space), a firm-elastic resistance is expected. This maneuver can also be conducted for all further ipsilateral ZAJs as the “springing test.” Joints with local restrictions in mobility resist pressure with an almost hard resistance.

- Divergence—gliding apart. C2 moves away from the finger pad during contralateral lateral flexion and, if necessary, slight flexion.

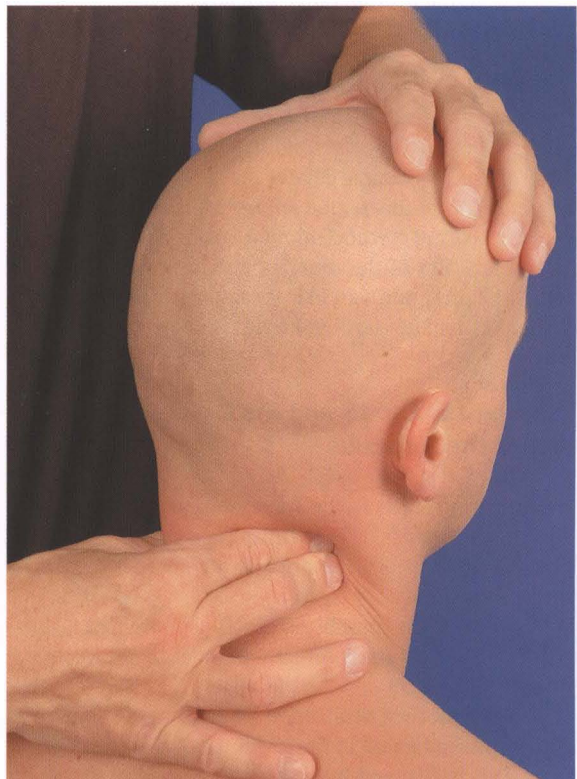


Fig. 12.57 Confirmation with movement.

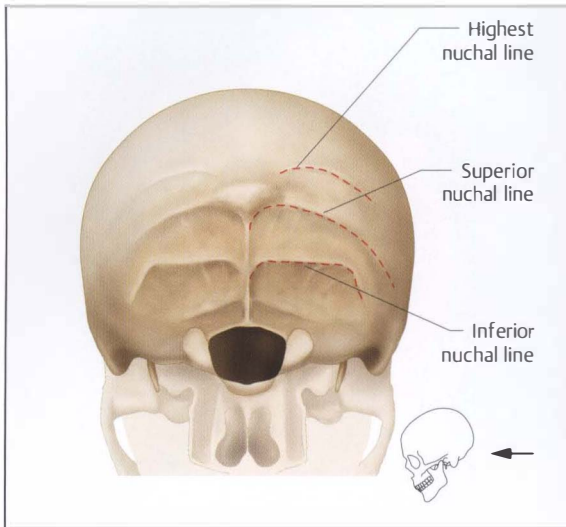


Fig. 12.58 Posterior aspect of the occipital bone.

Muscles, Suboccipital Nerves, and Blood Vessels

Muscles insert into three lines on the occiput (Fig. 12.58):

- Highest nuchal line: extends superiorly and laterally from the external occipital protuberance.
- Superior nuchal line: extends laterally from the external occipital protuberance in a large arc.
- Inferior nuchal line: the deep neck muscles insert into this difficult-to-reach line.

The accessible superficial muscles are evident on the superior nuchal line approximately two finger-widths superior to the palpable edge of the occiput. The predominant muscles in this region are semispinalis capitis, splenius capitis, and sternocleidomastoid.

The position of the muscles, the intermuscular gaps, and the neural and vascular structures passing through these gaps will be clarified in the following palpation.

Semispinalis Capitis and the Descending Part of the Trapezius

The palpation starts in the suboccipital fossa. This is bordered on both sides by the semispinalis capitis and trapezius muscles. The muscles are activated to make their position and dimensions clearer.

The pads of the thumb and two fingers are first used to grasp the muscle mass directly parallel to the vertebral column (Fig. 12.59).

The patient then bends their head forward completely. This results in flexion of the lower cervical spine in particular. This is followed by active upper cervical extension where the patient pushes against the therapist's hand

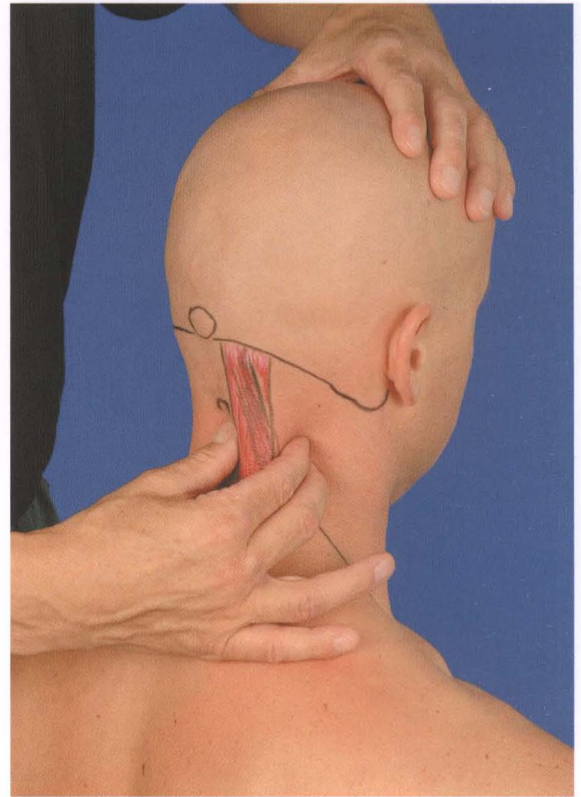


Fig. 12.59 Palpating the semispinalis capitis.

(Fig. 12.60). It is very helpful to instruct the patient to “move the chin forward” during this step.

The semispinalis capitis can now be palpated and observed as a firm, distinct muscle mass directly adjacent to the vertebral column. Its course can be followed up to the superior nuchal line when the muscle remains active.

The anterior edge of the descending part of the trapezius forms the posterior boundary for the fossa superior to the clavicle. Its position is generally well known and it is easy to palpate its anterior edge. The palpatory technique involves placing the tips of the fingers perpendicular to the edge of the muscle (Fig. 12.61a, phase 1).

Gentle pressure is applied and the edge of the muscle is followed superomedially. The palpating finger then encounters the superior nuchal line exactly in the middle of the insertion of the semispinalis capitis (Fig. 12.61b, phase 2).

Sternocleidomastoid

The position and the edges of the sternocleidomastoid can be clearly identified. If the muscle cannot be easily recognized in upright sitting, the muscle must be contracted to make its position more distinct. A suitable method to activate the muscle is for the therapist to place a hand

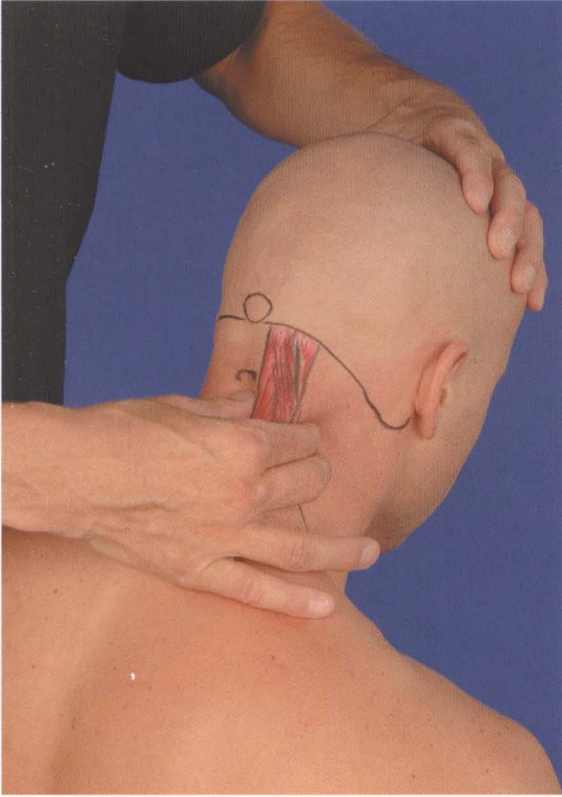


Fig. 12.60 Contraction of the semispinalis capitis.

on the patient's head and resist contralateral isometric rotation or ipsilateral isometric lateral flexion (Fig. 12.62a, phase 1).

The posterior edge is followed superiorly until the insertion directly posterior to the mastoid process at the level of the superior nuchal line is reached (Fig. 12.62b, phase 2). The same technique is used to palpate the anterior edge of the sternocleidomastoid, that is, by palpating perpendicular to the edge of the muscle. The anterior edge ends at the anterior edge of the mastoid process.

To aid orientation during the next steps, the therapist marks the edges of the muscles that have already been palpated on the skin (Fig. 12.63): semispinalis capitis, the descending part of the trapezius, and sternocleidomastoid. The therapist can additionally transfer their knowledge of the topography of nerves and vessels in this region onto the drawing (Fig. 12.63).

Splenius Capitis

Another strong muscle can be located in the neck region: the splenius capitis. This muscle belongs to the superficial layer of the intrinsic muscles of the back and extends from the cervical spinous processes up onto the superior nuchal line. It can be observed directly lateral to the semispinalis capitis and directly medial to the mastoid process and sternocleidomastoid. It is not as easy to accurately locate

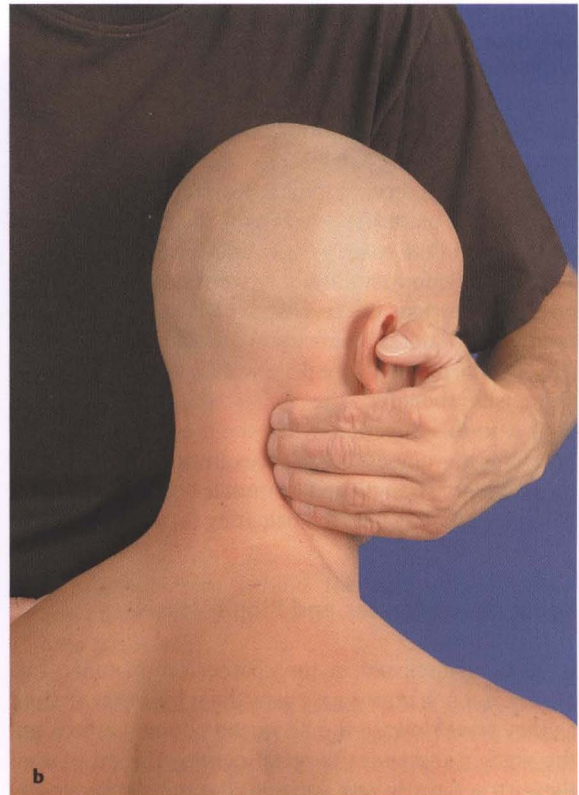
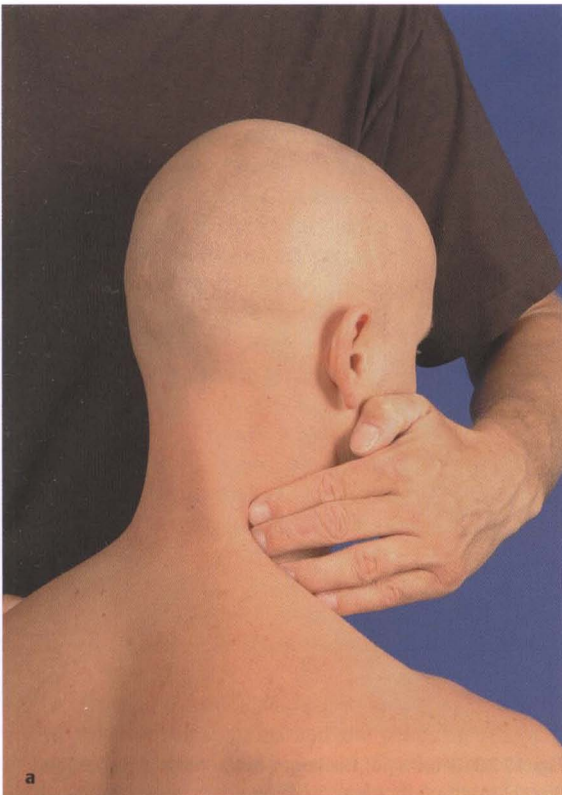


Fig. 12.61a, b Palpating the descending part of the trapezius. a Phase 1. b Phase 2.

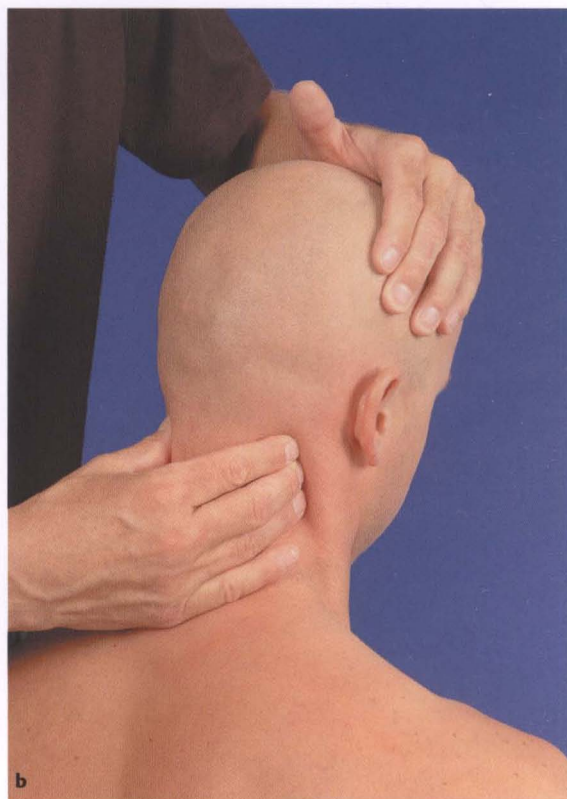
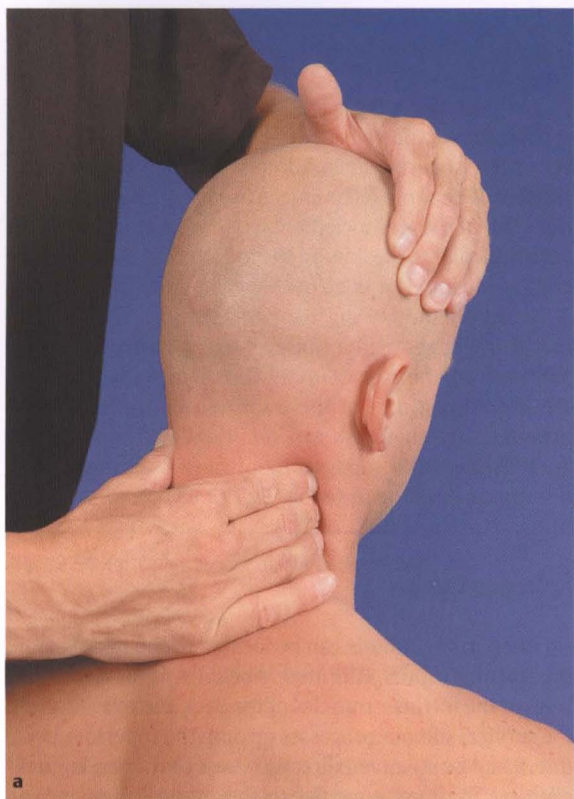


Fig. 12.62a, b Palpating the sternocleidomastoid. a Phase 1. b Phase 2.

this muscle compared with the localization of the sternocleidomastoid. The muscle often has to be strongly contracted to make its position clear. Its muscle belly becomes distinct during extensive active movements of the cervical spine into extension, rotation, and lateral flexion toward the side being palpated.

The patient's cervical spine is positioned in neutral and the therapist places the finger pads flat over the edge of the occiput in the space between the semispinalis capitis and sternocleidomastoid (Fig. 12.64a, phase 1). The therapist then positions the cervical spine in slight extension, rotation, and lateral flexion toward the side to be palpated (Fig. 12.64b, phase 2). The patient is now looking over the therapist's shoulder. The patient pushes their head further in this direction, while the therapist's hand opposes this movement. The splenius, in particular, provides the necessary strength and its muscle belly can be clearly felt as it pushes against the palpating fingers.

Suboccipital Nerves and Blood Vessels

As already discussed in the chapter on anatomy, two nerves and one artery pass over the edge of the occiput as they travel toward the head: the occipital artery and the greater and lesser occipital nerves. The position of these structures is very variable. The most accurate de-

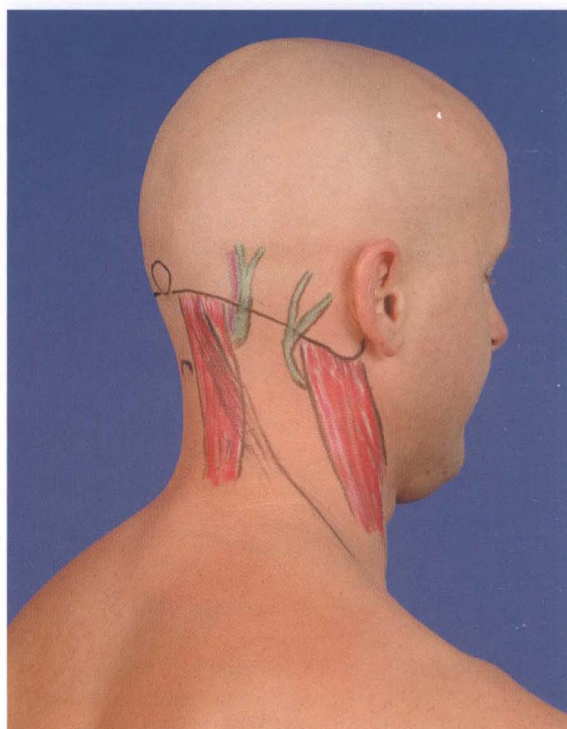


Fig. 12.63 Drawing of the edges of the muscle, nerves, and blood vessels on the skin.

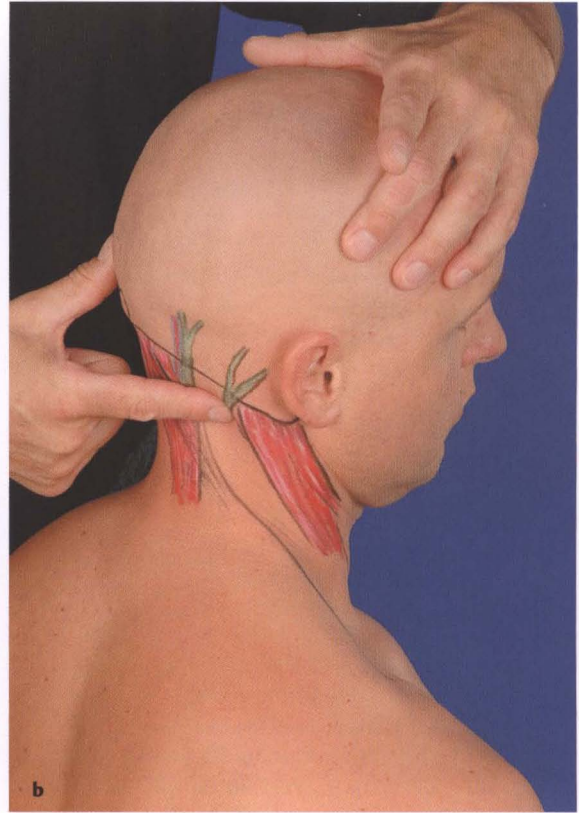
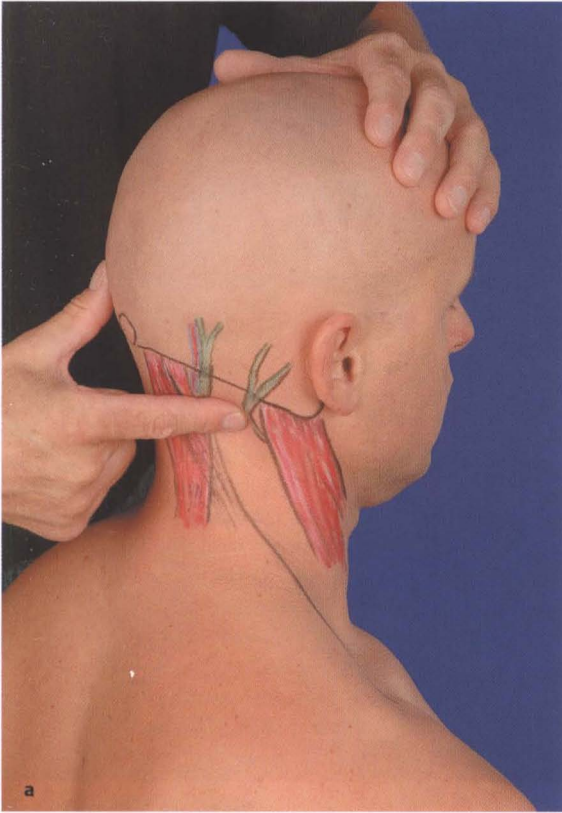


Fig. 12.64a, b Palpating the splenius capitis. a Phase 1. b Phase 2.

scription of their course can be found in Lanz and Wachsmuth (1979). The course described in this book represents the accepted average. These structures can be identified very precisely using palpation once therapists have practiced a lot and gained experience. Two areas on the occiput exist that are covered by less firm muscles. These areas will be named the intermuscular gaps on the occiput in the following text; they aid therapists in locating the nerves and the artery. These intermuscular gaps can be clearly felt at two points when palpating from medial to lateral along the occiput. Each gap is located in the space between two neighboring muscles (Fig. 12.65):

- **Medial intermuscular gap:** lateral edge of the semispinalis capitis and medial edge of the splenius capitis. The occipital artery and the greater occipital nerve pass through the fascia at this point and travel subcutaneously onto the occiput. At this point, the posterior arch of the atlas can be indirectly reached when firm pressure is applied. This is of great importance for a variety of mobility and stability tests as well as for manual therapeutic treatment techniques targeting the C0/C1 segment.
- The lateral intermuscular gap is found between the lateral edge of the splenius and the posterior (medial) edge of the sternocleidomastoid. The lesser occipital nerve passes over the edge of the occipital bone here.

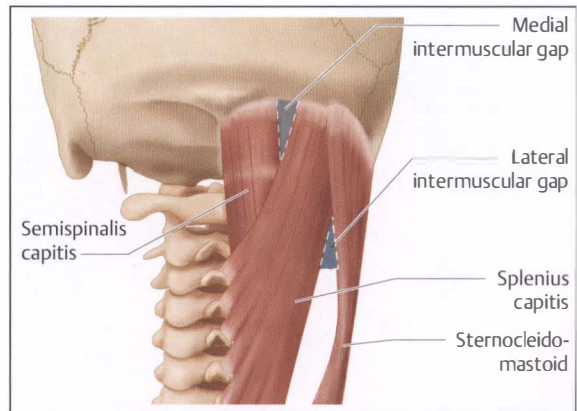


Fig. 12.65 Suboccipital intermuscular gaps.

It juts out from behind the sternocleidomastoid around the level of C2 and travels in a straight line up onto the occiput.

To locate the **occipital artery**, a finger pad is gently placed flat over the edge of the occiput at the level of the medial intermuscular gap (Fig. 12.66a). It usually takes a while before the arterial pulse can be felt. If the pulse cannot

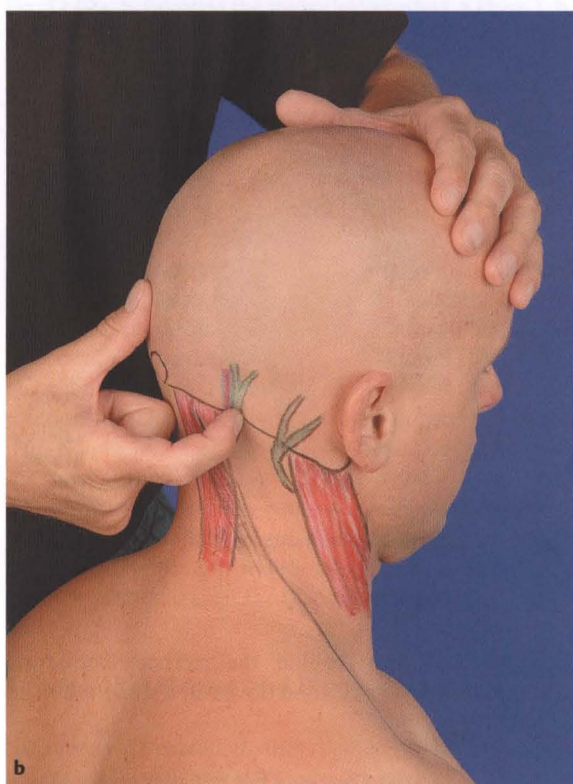
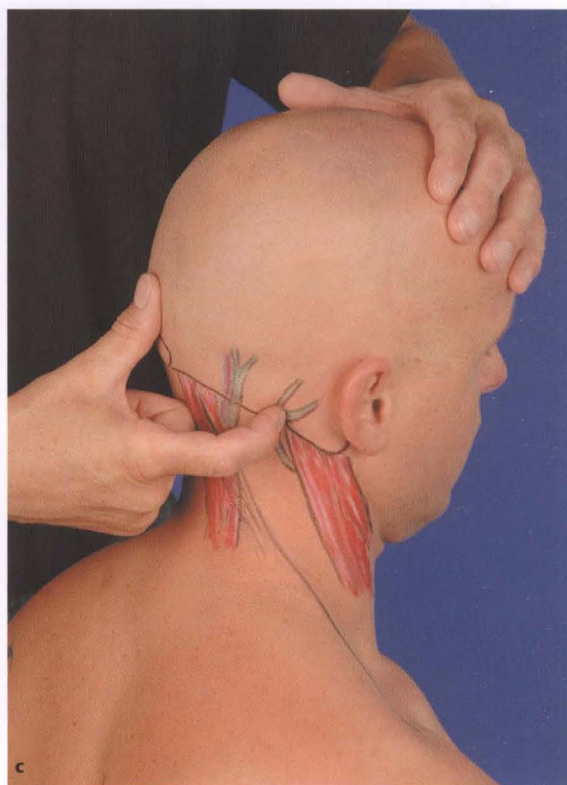
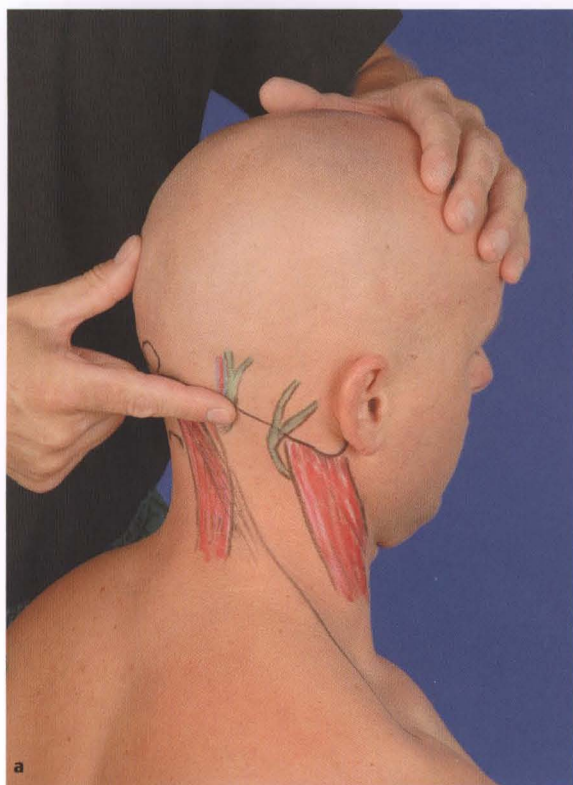


Fig. 12.66a–c Palpation. **a** Occipital artery. **b** Greater occipital nerve. **c** Lesser occipital nerve.

be felt, the therapist should continue palpation more medial or lateral to this point.

The **greater occipital nerve** is found directly adjacent to the artery. To locate the nerve, the correct technique involves holding the finger vertically and using the finger tip for palpation (**Fig. 12.66b**). A peripheral nerve can be plucked especially well on top of this hard underlying surface. This is similar to plucking a guitar string and is achieved by applying firm pressure and quickly moving the finger back and forth. The nerve rolls underneath the finger tip during this movement.

The therapist attempts to find the **lesser occipital nerve** in the lateral suboccipital intermuscular gap using the same technique (**Fig. 12.66c**).

Tips for Assessment and Treatment

These first palpations on the posterior aspect of the cervical spine have shown options that can be implemented well when working with patients. The level of structures can now be determined reliably. Posterior muscles and posterolaterally positioned ZAJs can be palpated well.

The groundwork for the local mobility tests at the ZAJ has been laid. The “Facet Joints” section above (p. 339) has already described how movement is felt in the ZAJs. The springing test is one of the quickest and most conclusive tests available to assess the mobility of a ZAJ. A variety of manual therapeutic techniques use the laminae to influ-

ence segmental mobility (traction and gliding). Therapists should refer to specialist literature on this topic.

Three techniques will be presented in the following sections that are of importance within and outside the field of manual therapy. This includes the assessment of upper cervical stability.

In addition to the tests assessing the stability of the transverse ligament of the atlas, testing of the alar ligaments belongs to the crucial skills providing information on the important ligaments of this region (see the section “Test for the Alar Ligaments” below).

In the lower cervical spine, age-related degenerative processes in the movement segment play an important role. A simple technique is used for the important provocation of the affected segment and to determine its level (see “Identifying the Level of Chronically Irritated Intervertebral Disks” below, p. 349).

This section finishes with an extremely pleasant, functional, and effective type of muscle technique that is used to relieve muscle tension. All therapists can carry out these functional massages on the paravertebral muscles with some aptitude. These techniques are often used as the initial treatment of painful symptoms or to prepare patients for local assessment or treatment (see the section “Functional Massage” below, p. 349).

Test for the Alar Ligaments

Several local upper cervical assessment and treatment techniques require the C2 spinous process to be well palpated and, in some cases, even fixed. The test for stability in the occipital parts of the alar ligaments demonstrates how important local palpation is for assessment techniques.

Aim

To assess the stability of the occipital parts of the alar ligaments.

Criteria

C2 moves immediately when the upper cervical spine moves into slight lateral flexion (bending the head to the side). Hard end feel when the elasticity of the ligaments is tested.

Procedure

The following procedure is taught at the IAOM manual therapy study group and the VPT (German Physical Therapy Association) Academy in Fellbach, Germany. The test is performed on both sides and for both occipital alar ligaments.

Preparation: The C2 spinous process is first located and held onto by the thumb and the index finger. Contact is made with the laminae on both sides (Fig. 12.67a). The head is then stabilized in the therapeutic ring and the index finger is removed from one of the laminae (right in Fig. 12.67b). The thumb should now clearly be in contact with the side of the lamina of C2.

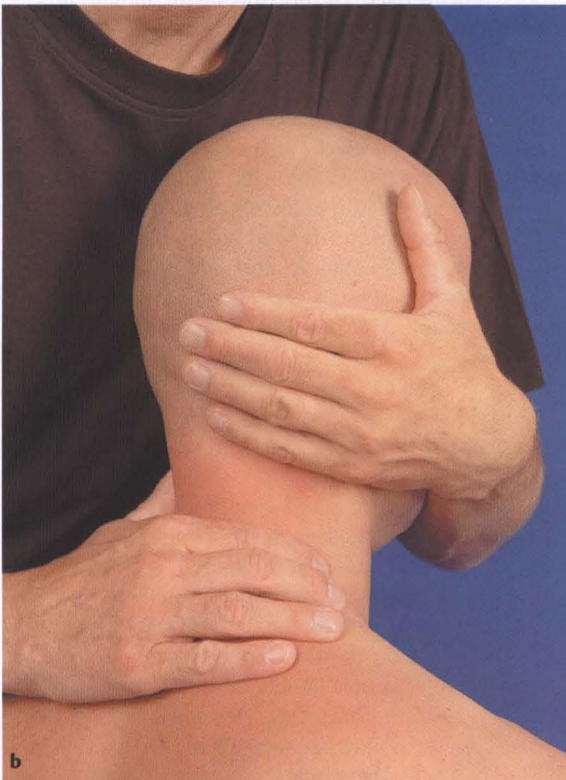
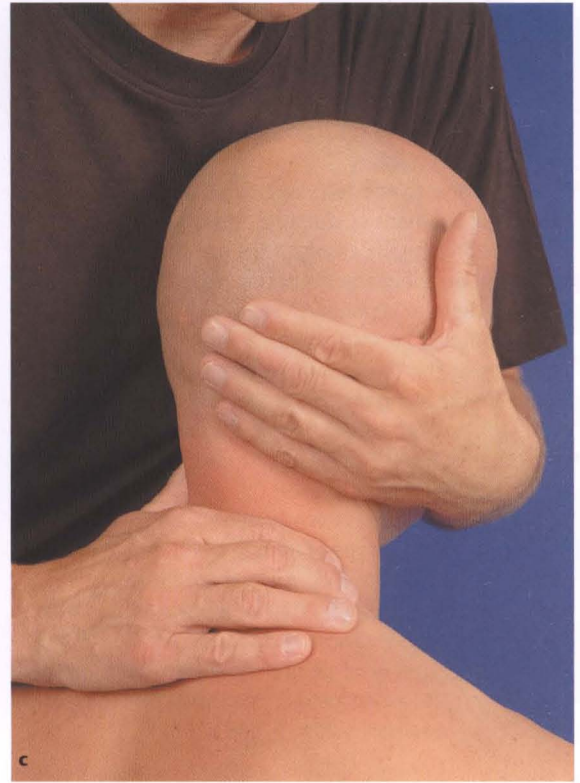
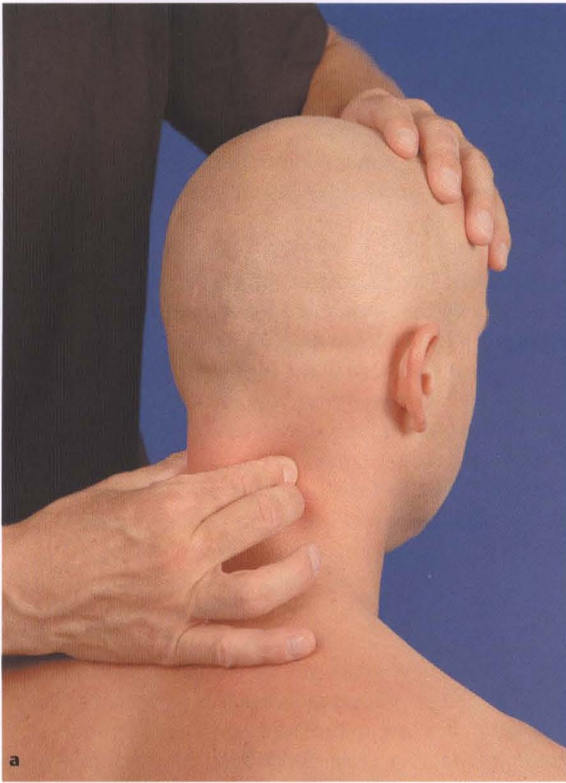
Phase 1—Mobility Test: Using gentle axial pressure, the head is now facilitated into slight local lateral flexion (to the right in this example) away from the therapist (Fig. 12.67c). Because of the direct coupling of movements, C2 immediately rotates to the right with C2’s spinous process moving to the left. This result is expected when the alar ligaments are intact and C2 is able to move freely on C3. The spinous process movement is perceived immediately as an increase in pressure against the thumb.

Phase 2—Mobility Cross-check Test: An attempt is now made to laterally flex the cervical spine when the spinous process is being fixed. The pressure on the spinous process is increased again so that the process can no longer move. The therapist applies slight axial traction to the cervical spine and attempts to facilitate lateral flexion using the therapeutic ring. Normally no movement occurs.

Phase 3—Test for End Feel: Finally, a quick test for the elasticity of the ligaments is conducted. Slight lateral flexion is first facilitated. The thumb resting on the spinous process allows this movement. The head is then held in this position and the thumb applies short but intensive pressure onto the rotated spinous process, pushing it back in a medial direction. A hard end feel proves that the ligament is intact.

Interpretation

Phase 1: The test is positive when the rotation of the spinous process is delayed for even a minimal amount of time. The hand placement at the spinous process is therefore the most essential component of this test. The most common mistake when conducting this test is that too little contact is made with the spinous process. This means that movement cannot be felt immediately and results in false positives that are interpreted as a laxity in the ligament. Limited mobility between C2 and C3 can also limit rotation at C2. It is therefore recommended that the mobility of the C2/C3 segment be first assessed using the springing test (see “Facet Joints” above, p. 339).



Phase 2: Ligament laxity is also confirmed when the C2 spinous process is being fixed and lateral flexion is possible. It is important that movement of the hand via the skin of the face moving against the skull should not be mistaken for lateral flexion.

Phase 3: The alar ligaments are only proven to be intact when the end feel is hard. The test is positive when the thumb pushes on the spinous process and an elastic end feel is felt.

Therapists may only claim that the alar ligaments are stable when all three of these tests do not demonstrate laxity of the ligament on both sides. If the alar ligaments are lax, treatment techniques may not be used where strong cervical traction is applied or where large rotational movements are conducted.

Fig. 12.67a–c Test for the alar ligaments. **a** Locating the laminae of C2. **b** Fixating one of the laminae. **c** Lateral flexion away from the therapist.

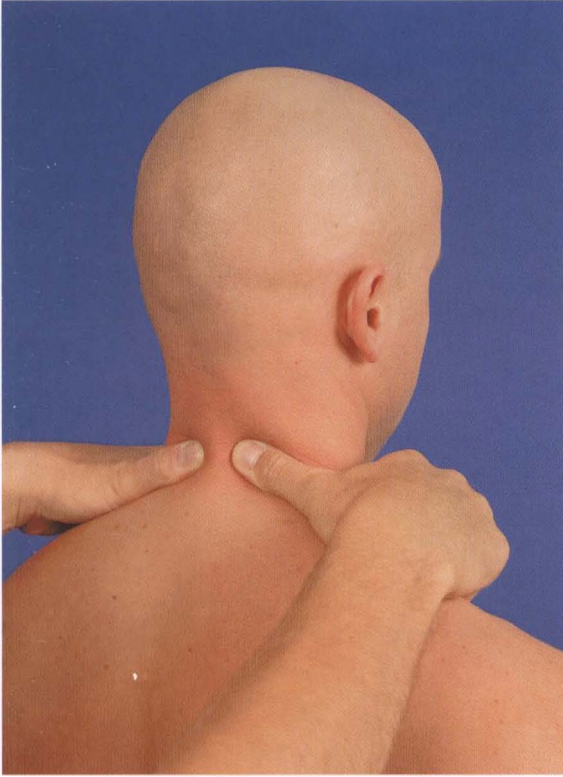


Fig. 12.68 Identifying the level of a chronically irritated intervertebral disk.

Identifying the Level of Chronically Irritated Intervertebral Disks

Another good example of the use of *in vivo* anatomy in the posterior cervical spine is an extremely simple test that is used to identify the level of chronically irritated intervertebral disks in patients suffering from persistent neck symptoms (Fig. 12.68).

The cervical intervertebral disks control the translation movement occurring in the upper vertebra during real extension (tilting the head backward with the chin pulled in). This movement is painful when an intervertebral disk is irritated. The irritated intervertebral disk segment must be located before it can be treated locally. The principle of this test is to stabilize the lamina of the lower vertebra in the segment and conduct real extension above this point.

Aim

To locate the irritated segment.

Criteria

Patient reporting pain.

Procedure

Starting at the C2 spinous process, the lamina of C2 is located, followed by the lamina of C3. This is the first intervertebral disk segment. Both thumbs are placed flatly over the laminae. They hold onto the laminae tightly and by applying pressure in an anterior direction they prevent movement in a posterior direction. The patient extends the lower cervical spine by tilting the head backward and pulling the chin in (real extension). C3 cannot move as it is fixed by the thumbs. Extension only takes place at the C2/C3 level. If the test is negative, the next inferiorly located laminae are stabilized and the test is repeated.

Interpretation

The test is positive and the segment found when the patient indicates their typical type of pain. The test is expected to be positive in the lower intervertebral disk segments, if anywhere, as these segments, similar to the lowermost lumbar segments, are expected to suffer from intervertebral disk degeneration more often.

Functional Massage

Several types of functional massage in the sitting SP will also be demonstrated here to supplement those presented at the end of Chapter 8. To successfully relieve tension in the neck muscles, it is important that the head is held securely in the therapeutic ring so that the patient can allow the therapist to support the majority of the weight of the head.

The technique aims to displace the muscles transversely and is combined with a longitudinal stretch via movement in the cervical spine. One hand is placed over the neck and is used for the massage by transversely displacing tissue. Movement is controlled via the therapeutic ring. In the illustrated example, the paravertebral neck muscles are held in a wide "V-grip" and displaced posteriorly while the head is being flexed.

The cervical spine is placed in a neutral SP and one hand grasps around the area just above the region to be treated. This means that the following flexion movement does not need to be too large to stretch the tissue longitudinally (Fig. 12.69a, phase 1). The massage hand is placed posteriorly over the neck muscles with the thumb splayed out widely. The hand comes into contact with the underlying muscles and pinches the muscles, pulling them medially and posteriorly. This transverse stretch is maintained and a longitudinal stretch is added by flexing the cervical spine (Fig. 12.69b, phase 2).

- This functional massage can be varied in several ways:
- Slowly repeating the stretch rhythmically or stretching statically.

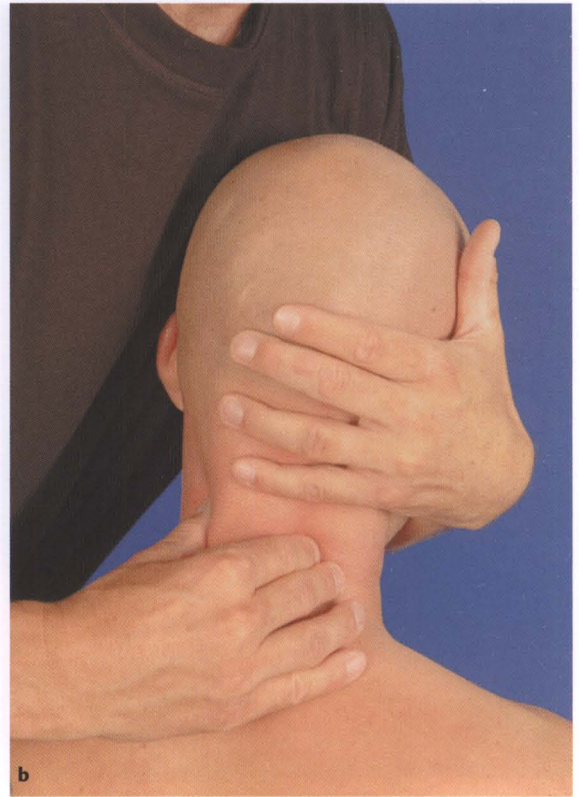
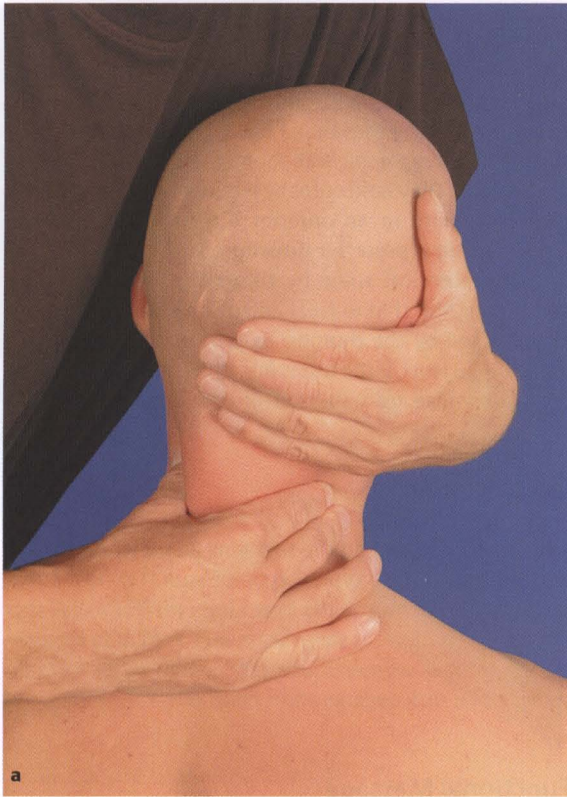


Fig. 12.69a, b Paravertebral functional massage. a Initial position. b Final position.

- Repeating the transverse displacement at one segment or working systematically from superior to inferior along the entire neck musculature.
- Wider V-grip = semispinalis, trapezius, splenius, and longissimus (Fig. 12.70).
- Narrower V-grip = semispinalis and trapezius.
- Moving the cervical spine symmetrically into flexion and stretching the muscles evenly on both sides, or coupling flexion with lateral flexion and rotation toward the therapist while stretching the muscles more on the opposite side.

Lateral Palpation Techniques

Overview of the Structures to be Palpated

- Angle of the mandible.
- C1 transverse process.
- C2 and C3 transverse processes.
- Boundaries of the posterior triangle of the neck.
- Occipital triangle of the neck.
- Supraclavicular triangle of the neck.

The sternocleidomastoid crosses the side region of the neck diagonally. In the area above the muscle belly, only

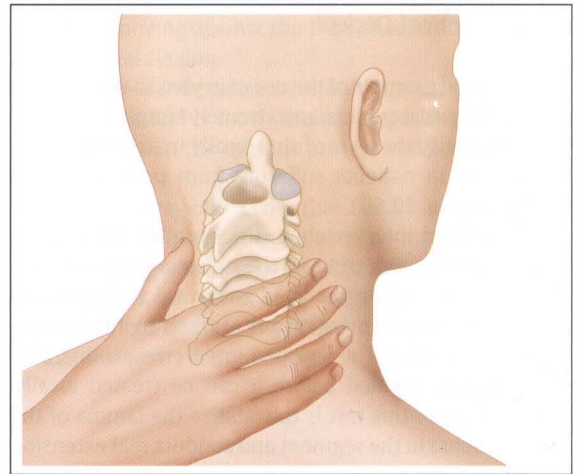


Fig. 12.70 Functional massage using a wide V-grip.

the localization of the C1 transverse process is of interest for palpation. All other accessible structures are located inferior to the muscle, in the posterior triangle of the neck, and superior to the supraclavicular fossa. When practicing the localization of these structures, the most suitable SP is once again the neutral sitting position. Other SPs (e.g., supine lying) can also be selected later on.

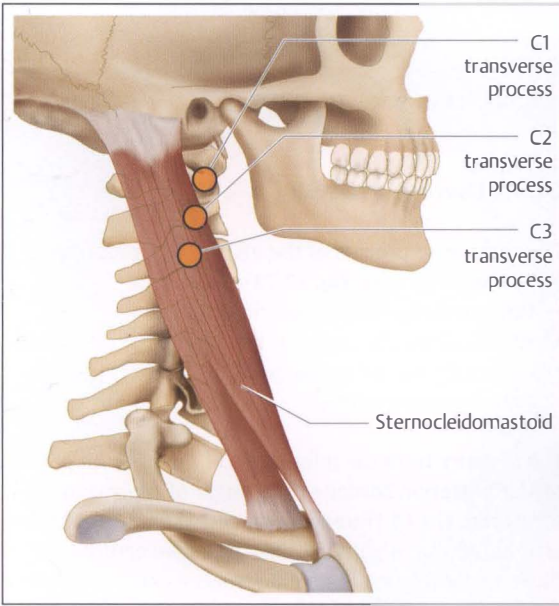


Fig. 12.71 Transverse processes and the sternocleidomastoid.

The position of the transverse processes must be viewed in relation to the sternocleidomastoid in particular. The C1 transverse process is found anterior to the sternocleidomastoid, the C2 transverse process directly beneath the muscle, and the C3 transverse process more posterior to the muscle belly (Fig. 12.71). The shape expected to be felt is also crucial:

- The C1 transverse process is very long and varies greatly in length and form. In rare cases it can point posteriorly or be positioned close to the occiput. The variation in shape and length of the transverse process can lead to incorrect conclusions being made when comparing sides using palpation. Making a diagnosis based on the position of structures alone is therefore very unreliable.
- All transverse processes inferior to and including C2 tend to be shorter. It is therefore expected that when the palpating finger moves down from the tip of the C1 transverse process it will slide deep into the tissue until the transverse process of C2 is reached. Again, topographical anatomy and expectations related to consistency and shape form the foundations for precise palpation.

Angle of the Mandible

The edge of the occiput is followed laterally until the mastoid process is reached. A perpendicular technique is applied using one or two finger tips so that the fingers push against the posterior aspect of the mandible (Fig.

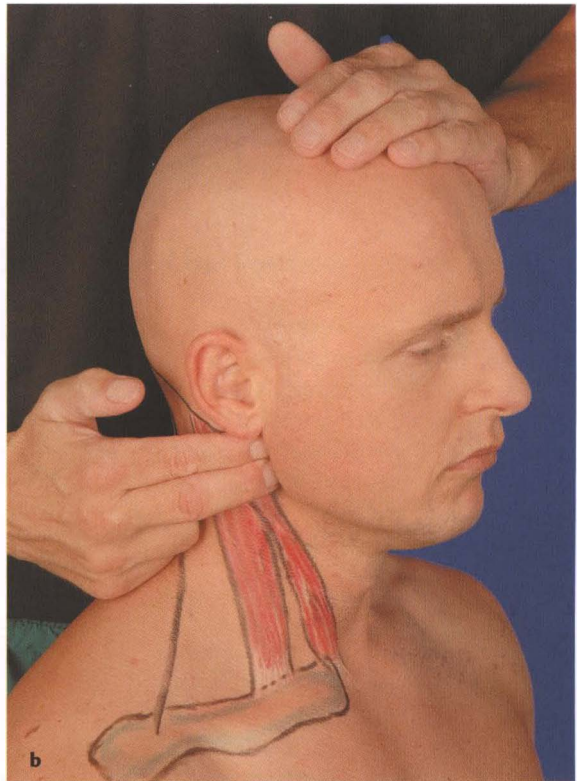
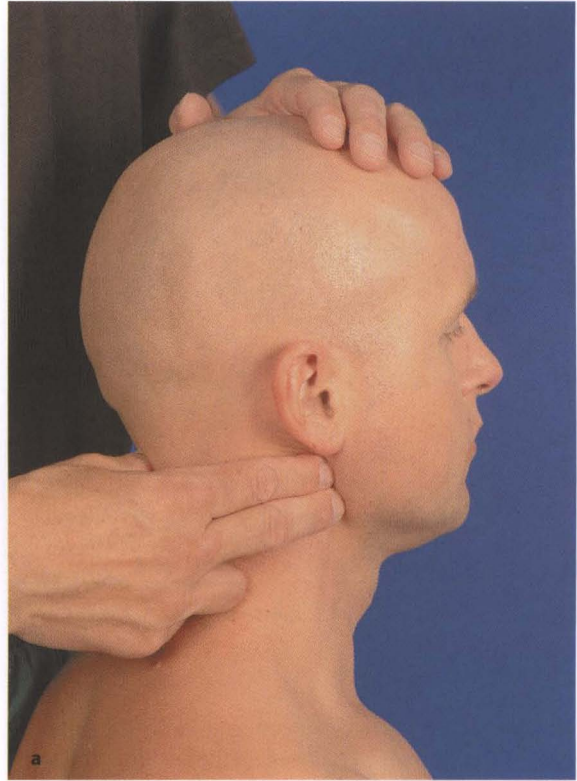


Fig. 12.72a, b Angle of the mandible. a Palpatory technique. b Alternative view.

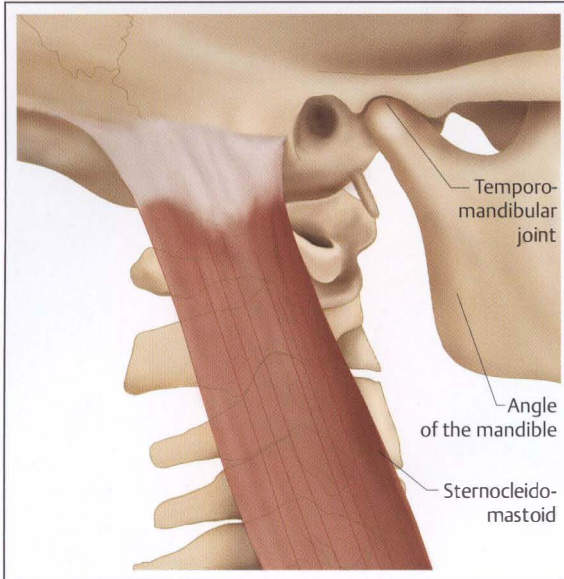


Fig. 12.73 Position of the C1 transverse process.

12.72a). The patient can open and close their mouth slightly if the therapist is unsure of the position. The angle of the mandible pushes against the palpating finger when the mouth opens. The most important bony reference

points for this region have now been found. The search for clinically relevant structures can begin. The palpating finger is always positioned anterior to the sternocleidomastoid at this stage (**Fig. 12.72b**).

C1 Transverse Process

The transverse process of the atlas is surrounded by the following structures (**Fig. 12.73**):

- Posteriorly by the sternocleidomastoid.
- Anteriorly by the angle of the mandible.
- Superiorly by the cartilage of the auricle. The TMJ is found anterior to this.

The distance from the inferior tip of the mastoid process to the posterior border of the angle of the mandible is measured. The C1 transverse process is found about half-way along the slightly sloping line connecting both of these reference points and is always located anterior to the sternocleidomastoid. Palpability varies according to the individual. Its tip is rounded.

A circular technique with the pad of the index finger is used for the palpation (**Fig. 12.74**). The hand should rest on the patient's cervical spine and/or occiput so that the finger pad can palpate smoothly and surely. The therapist should always expect to feel hard resistance deep in the tissue when applying direct pressure.

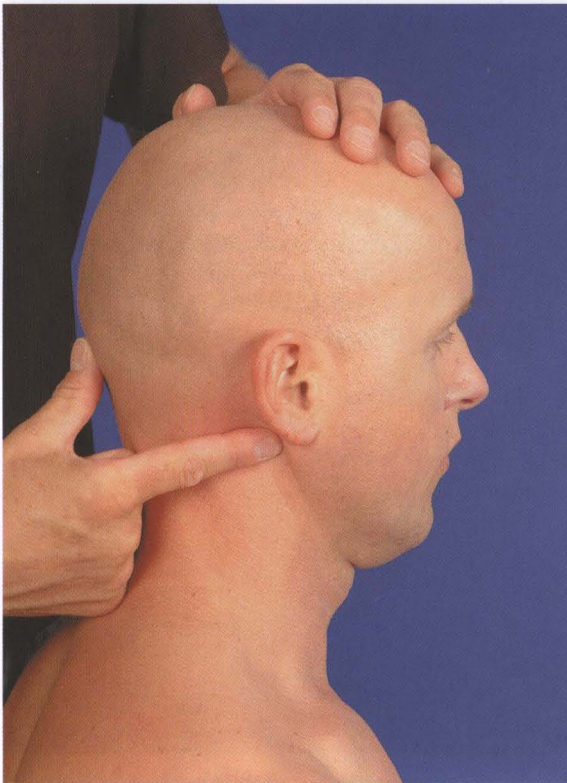


Fig. 12.74 Palpating the C1 transverse process.

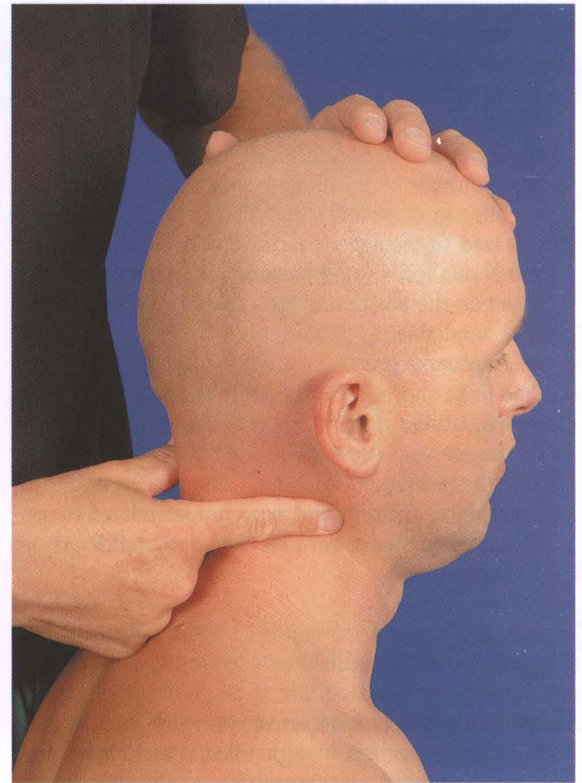


Fig. 12.75 Palpating the C2 transverse process.

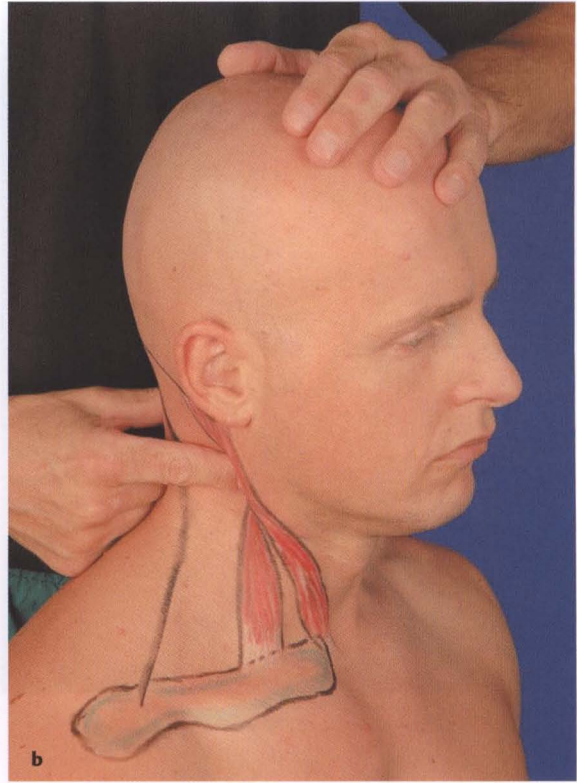
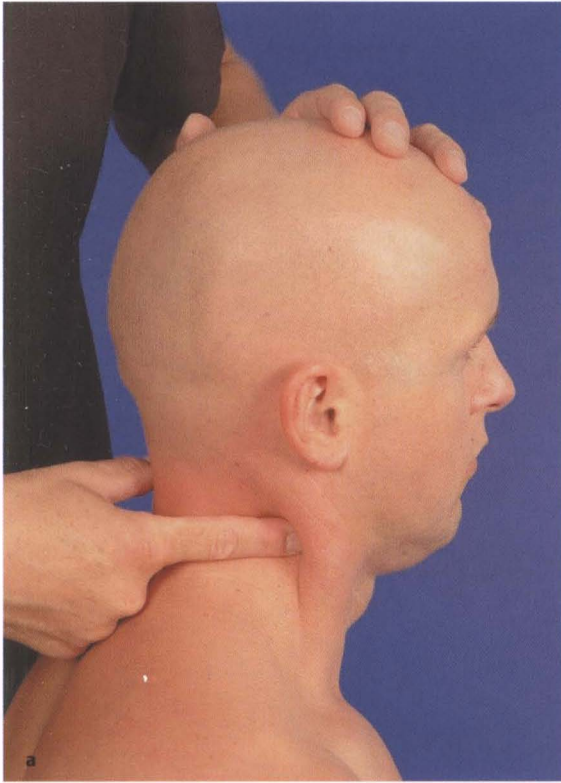


Fig. 12.76a, b C3 transverse process. a Palpation. b Alternative view.

Tip: Differences between the sides are easily recognizable in an individual. The length of the C1 transverse processes can vary, as can the shape of its tip and the location of the surrounding bony structures. It is important to know that differences between the sides do not imply segmental malpositioning in the segment between the atlas and the axis.

Tip: The following points should be considered to aid orientation: all spinal nerves in the mid-cervical spine are reached anterior to the respective transverse process and posterior to the sternocleidomastoid. The facet joints are found postero-medial to the corresponding transverse process.

C2 and C3 Transverse Processes

The C2 transverse process is considerably shorter than the C1 transverse process. It is found in a depression one finger-width inferior to the C1 transverse process. As it lies underneath the sternocleidomastoid, it is difficult to palpate directly. To reach the process, the muscle belly is moved posteriorly (or anteriorly) and the pressure applied deep into the tissues is increased (Fig. 12.75). The C2 transverse process can now be clearly palpated.

The tip of the C3 transverse process is expected to be found one finger-width further inferior. The sternocleidomastoid can partially cover the process when the muscle is well developed. To be on the safe side, the muscle belly is shifted slightly in an anterior direction before applying more pressure deep into the tissue (Fig. 12.76a, b). This transverse process is expected to be rather short. The time it takes to push deep into the tissue until bone is felt depends on the thickness of the tissue.

Boundaries of the Posterior Triangle of the Neck

The lateral region of the neck posterior and inferior to the sternocleidomastoid has a triangular form with the base of the triangle located inferiorly. This triangle is named the “posterior triangle of the neck” in the following sections (Fig. 12.77). The following structures form its boundaries:

- Posterior: anterior edge of the descending part of the trapezius.
- Inferior: superior edge of the clavicle.
- Anterior: posterior edge of the sternocleidomastoid.

It is necessary to subdivide this region into the upper (occipital) and lower (supraclavicular) triangles of the neck for the following descriptions (see also Fig. 12.86). The bellies of the following muscles are found in the occipital triangle:

- Levator scapulae.
- Scalenus posterior.

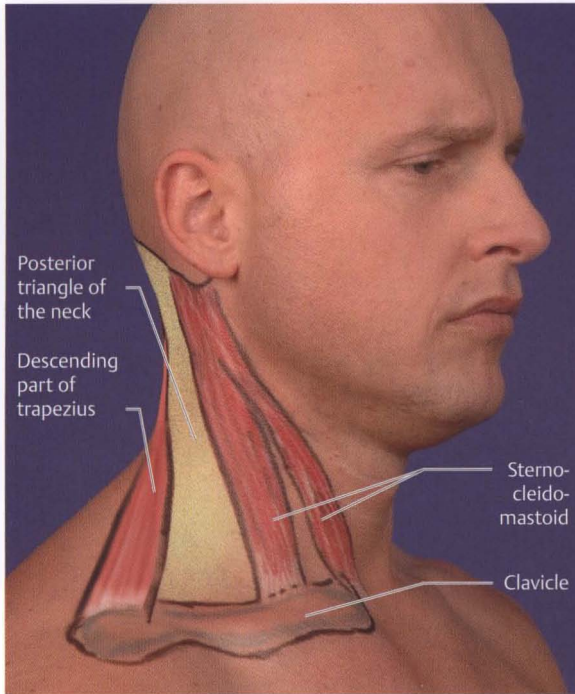


Fig. 12.77 Posterior triangle of the neck.

The flattened depression directly superior to the clavicle forms the supraclavicular triangle of the neck and is anatomically labeled the supraclavicular fossa. The following structures are found here:

- Scalenus anterior and medius.
- First rib.
- Subclavian artery.
- Brachial plexus.

Sternocleidomastoid

Usually, this strong muscle can be easily found in the lateral region of the neck. The sternal head on the right side becomes prominent when the head rotates to the left over a large range. The posterior edge of the muscle is followed inferiorly until the insertion is reached. A perpendicular palpatory technique is used with two finger tips resting against the posterior aspect of the mastoid process, the site of muscular insertion (Fig. 12.78).

From the mastoid process, the posterior edge of the muscle is followed inferiorly and anteriorly until the tips of the fingers feel the tendon and eventually land on the manubrium of the sternum. Its relationship to the sternoclavicular joint is described in Chapter 2, page 35.

The anterior edge of the muscle belly can be felt by palpating the tendon of the sternal head from inferior to superior. Finally, the edges of the sternal head can be visualized to determine how wide the muscle is (Fig. 12.79).

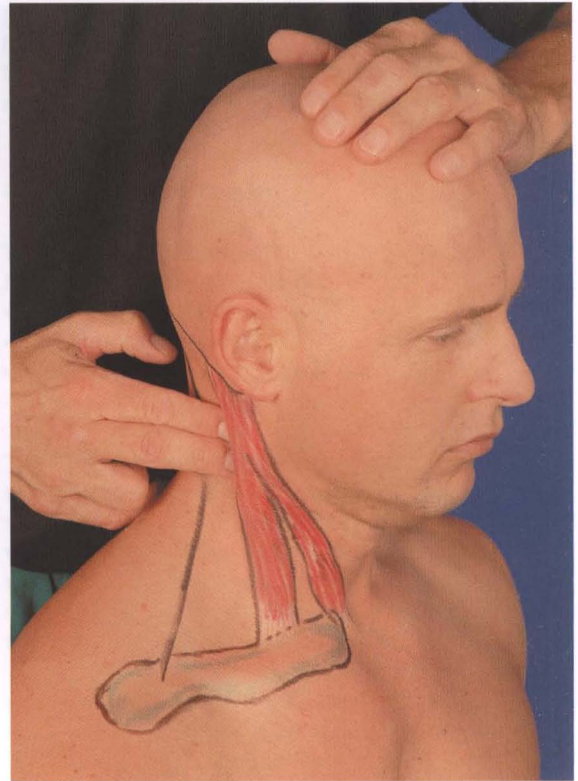


Fig. 12.78 Posterior edge of the sternocleidomastoid.

Tip: If the therapist does not feel confident with the localization, the patient is instructed to contract the muscle isometrically by pushing against resistance applied in a specific direction (Fig. 12.80). For this purpose, the therapist places one hand on the contralateral side of the forehead and the other hand on the ipsilateral side of the head. The patient is then instructed to turn their head toward the contralateral side or to laterally flex to the same side.

The muscle belly of the clavicular head is often only visible when the muscle isometrically contracts into ipsilateral lateral flexion. It is notably wider, but also weaker, than the sternal head. Using the same perpendicular palpatory technique, the therapist begins again at the mastoid process and follows the muscle inferiorly until its insertion into the middle third of the clavicle (Fig. 12.81). Its posterior edge forms the anterior boundary of the posterior triangle of the neck.

The gap between the two heads can be felt, and even observed, in the inferior region when the muscle is strongly contracted or when the therapist has gained some experience. It enables the therapist to palpate the anterior edge of the clavicular head and to visualize its width (Fig. 12.82).

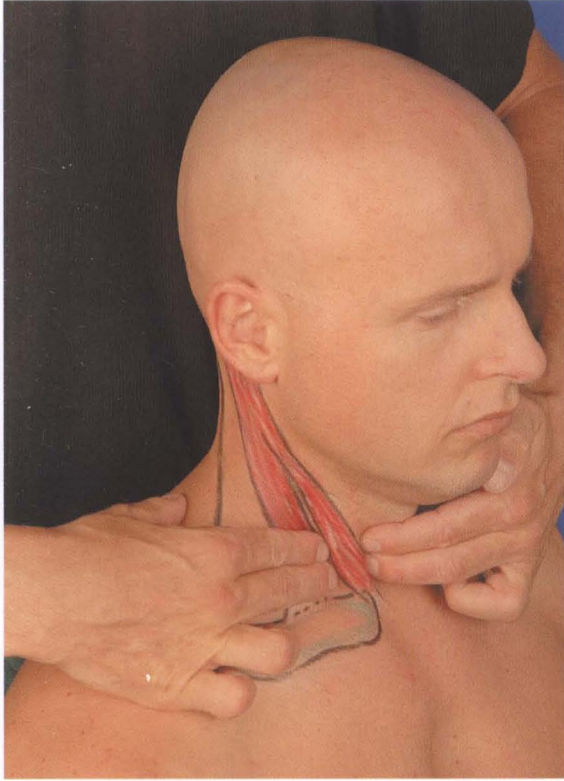


Fig. 12.79 Borders of the sternal head.

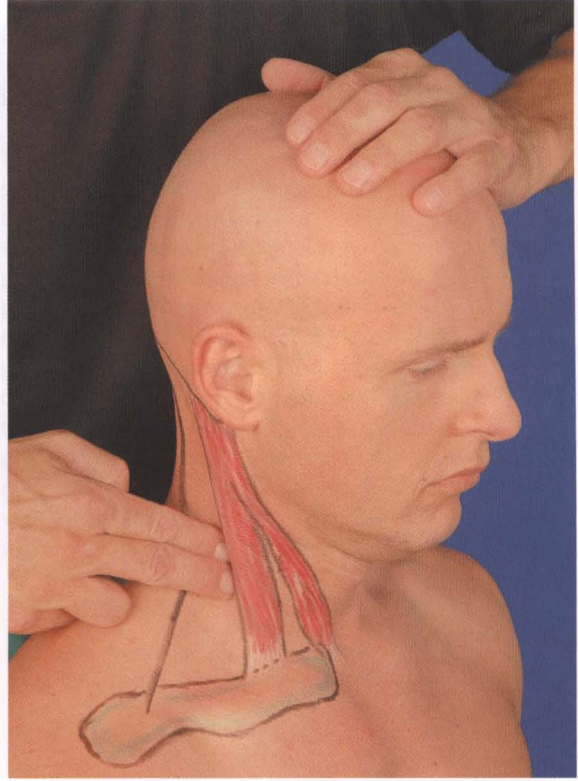


Fig. 12.81 Posterior edge of the clavicular head.

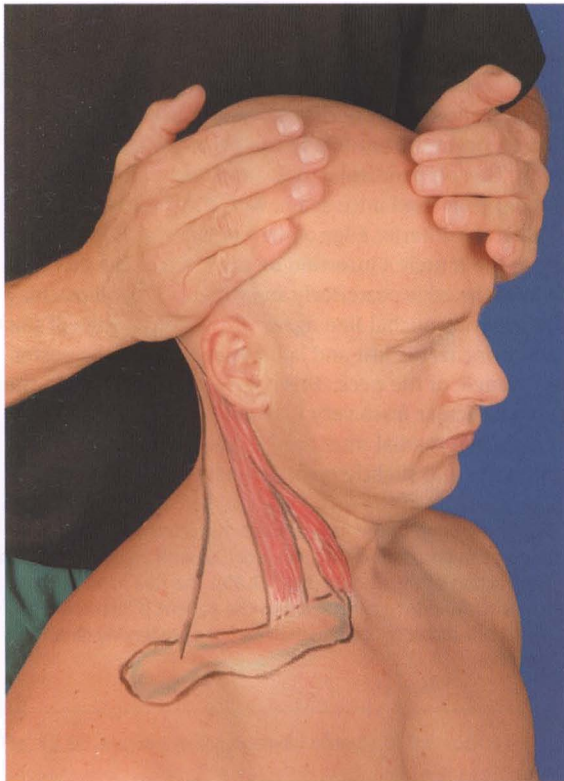


Fig. 12.80 Contraction of the sternocleidomastoid.

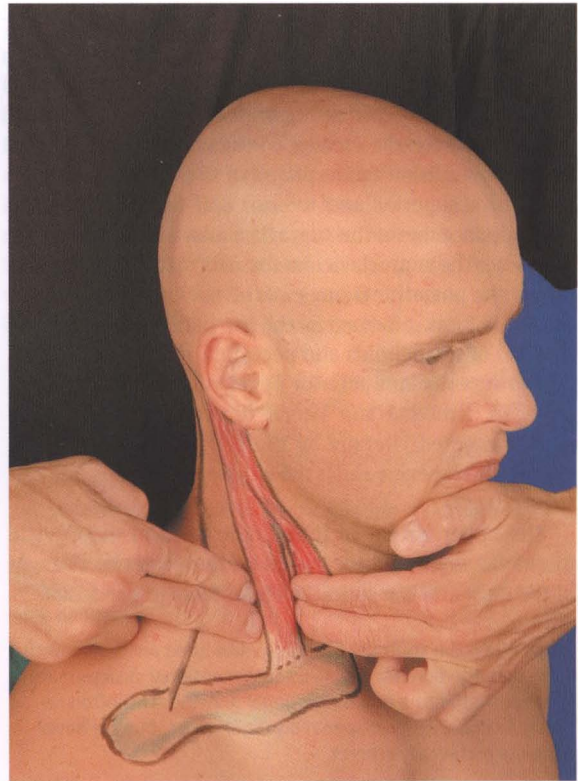


Fig. 12.82 Width of the clavicular head.

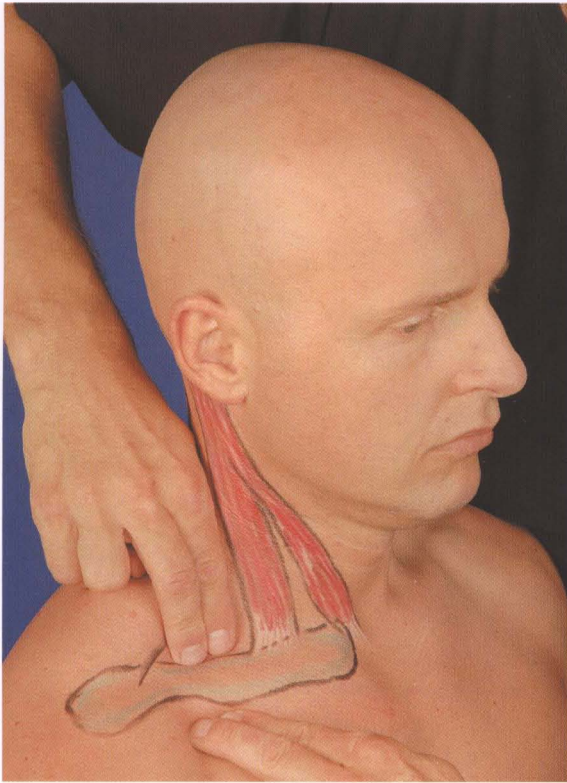


Fig. 12.83 Borders of the clavicle.

Clavicle

The borders of the clavicle are most clearly felt in the middle third, where the convex bone bends anteriorly (Fig. 12.83). In addition to the shape of the clavicle, the presence of a superior and inferior soft-tissue depression aids palpation here: the supraclavicular and infraclavicular fossae. The supraclavicular fossa forms the inferior section of the posterior triangle of the neck, while the infraclavicular fossa is formed by the gap between the clavicular head of the deltoids and pectoralis major.

The superior and inferior edges can be followed very easily in a medial and lateral direction. The posterior edge is covered laterally by the belly of the descending part of the trapezius and is the only section that is difficult to palpate.

The upper border of the middle third of the clavicle marks the wide inferior border of the posterior triangle of the neck and the supraclavicular fossa in particular.

Tip: When the contours of this pipelike bone are drawn onto the skin, the borders of this three-dimensional structure are transferred onto a two-dimensional drawing. This often results in drawings that appear strangely large, but are nevertheless technically correct.

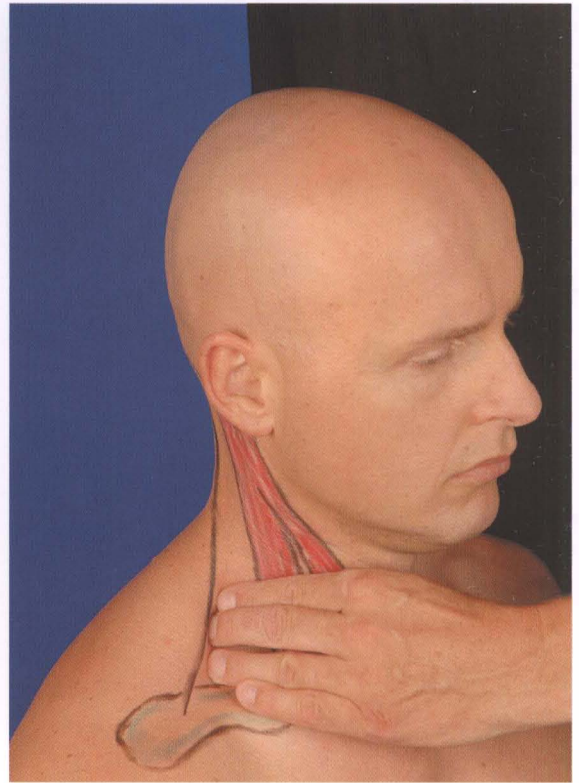


Fig. 12.84 Anterior edge of the descending part of the trapezius.

Descending Part of the Trapezius

The descending part of the trapezius must now be identified to locate the borders of the posterior triangle of the neck. The perpendicular palpatory technique with two finger tips is used once again, with the finger tips resting against the anterior edge of the muscle (Fig. 12.84): starting at the muscle's insertion on the clavicle, the therapist follows the edge posteriorly and superiorly until reaching the superior nuchal line again. The anterior edge of this muscle forms the last and lateral boundary of the posterior triangle of the neck. This edge can be palpated in the supraclavicular fossa very easily, where it extends transversely in a medial direction. Its course then changes in a superior and slightly medial direction.

Tip: If the edge of the muscle cannot be clearly felt, the palpation can be conducted in conjunction with an isometric contraction of the muscle (Fig. 12.85). The free hand is used to resist shoulder movement and the patient is instructed to push their shoulder "behind their ear" in a posteriorly directed elevation.

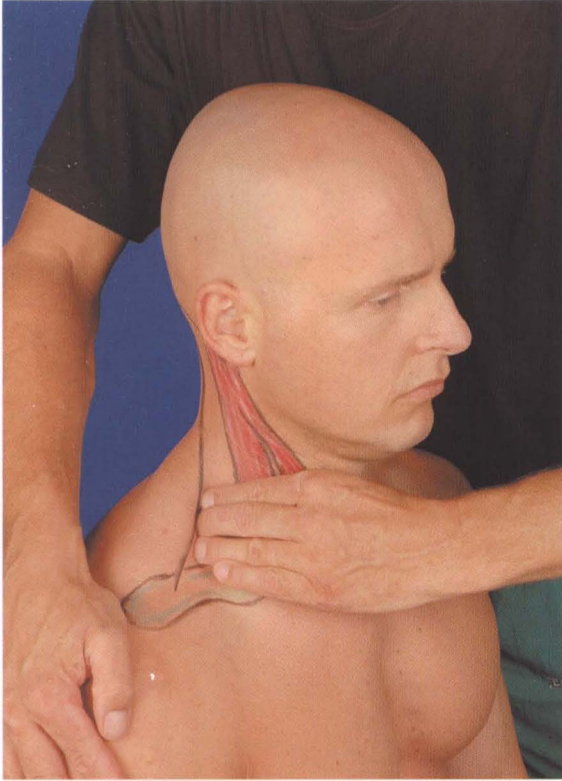


Fig. 12.85 Palpating with muscle contraction.

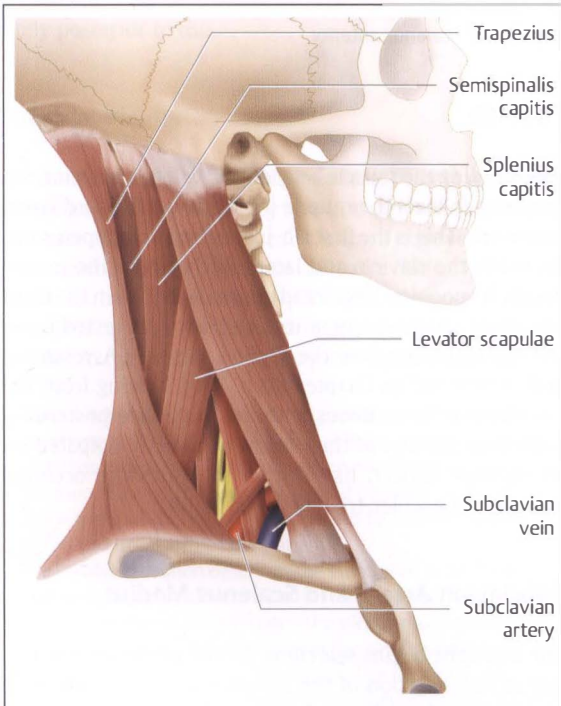


Fig. 12.86 Muscles in the occipital triangle of the neck.

Occipital Triangle of the Neck

Levator Scapulae

This thick muscle belly is found anterior to the descending part of the trapezius at the point where its medially directed course changes in a superior direction (Fig. 12.86). The same technique is used as for locating the edges of the trapezius, the only difference being that the finger pads now palpate deep into the tissue. To confirm that the localization was correct, the patient should elevate their shoulder girdle and move it anteriorly. The contraction in the muscle belly can now be felt clearly. While maintaining this tension, the muscle can be followed superiorly and anteriorly all the way to its insertion at the transverse processes. The inferior section of the muscle covers the transverse processes of the lower cervical spine. These processes can also be palpated when the muscle is relaxed.

Tip: The levator scapulae is differentiated from the descending part of the trapezius by tensing the muscle and following its course superiorly and posteriorly. Directly superior to the muscle belly of the levator scapulae is the splenius capitis. This muscle has already been located in the palpation of the posterior aspect.

Scalenus Posterior

The scalenus posterior is found directly inferior to the muscle belly of the levator scapulae, with both muscles traveling in almost the same direction. The localization begins in the triangle formed by the inferior border of the levator scapulae and the posterior border of the sternocleidomastoid. When the palpating finger is positioned in this triangle, the finger automatically rests on the scalenus posterior. This muscle is approximately as wide as one finger (Fig. 12.87). The muscle is also easier to palpate when contracted. This is achieved by inhaling deeply or by using isometric lateral flexion to the same side.

Tip: To differentiate this muscle from the levator scapulae and sternocleidomastoid, the muscle bellies are again made more prominent using muscle contraction:

- Levator scapulae: isometric elevation and protraction of the shoulder girdle.
- Sternocleidomastoid: isometric rotation of the neck to the opposite side.

It is difficult to differentiate this muscle from the scalenus medius because both muscles are positioned very close to one another.

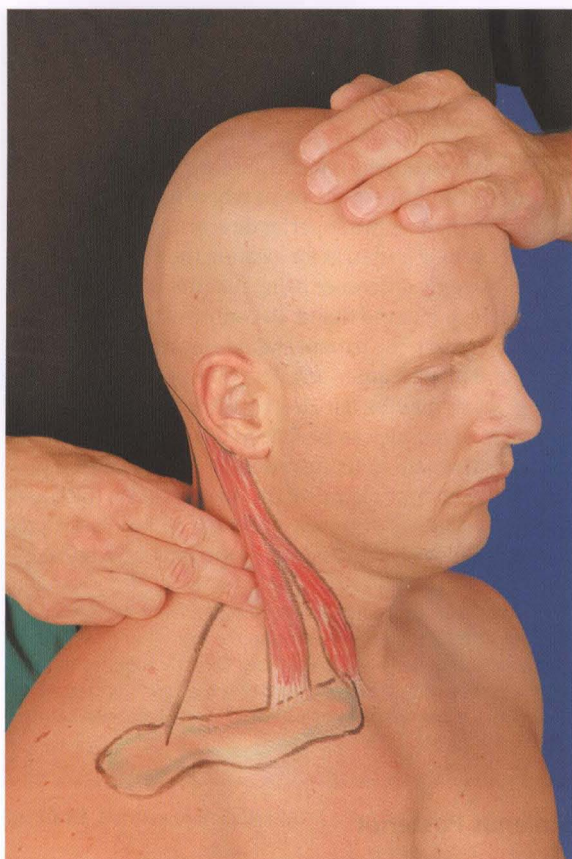


Fig. 12.87 Scalenus posterior

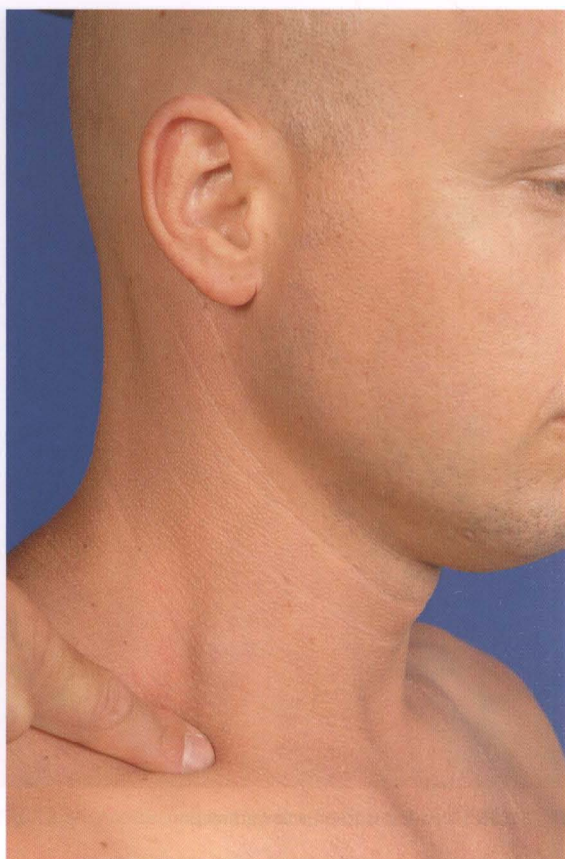


Fig. 12.88 Scalenus anterior

Supraclavicular Triangle of the Neck

Scalenus Anterior

The sternocleidomastoid covers most of the scalenus anterior. It can first be easily palpated in the supraclavicular fossa. The muscle belly and its insertion on the first rib can be palpated directly lateral to the clavicular insertion of the sternocleidomastoid.

The therapist starts by clarifying the insertion and palpates laterally from this point so that the finger is positioned in the angle formed by the borders of the clavicle and the sternocleidomastoid (Fig. 12.88).

Tip: The therapist should not feel a distinctly pulsating artery here. If this is the case, the finger is positioned too posteriorly. This finger-wide muscle belly also becomes distinct during forced inhalation or an isometric contraction into lateral flexion to the same side. The anterior scalenus gap is found between the scalenus anterior and sternocleidomastoid.

First Rib

After finding the muscle belly of the scalenus anterior, the therapist follows the muscle inferiorly until a hard structure is felt. This is the first rib, just before it disappears underneath the clavicle and later attaches onto the manubrium. Its position has already been described in the thoracic spine chapter, where its flexibility was tested using the springing test (see the section “Tips for Assessment and Treatment” in Chapter 11, p. 290). Moving from the insertion of the scalenus anterior, the entire posteriorly extending portion of the rib can be directly palpated on its superior aspect. Its position separates the occipital and supraclavicular triangles (Fig. 12.89).

Subclavian Artery and Scalenus Medius

The therapist begins searching for the posterior scalenus gap at the insertion of the scalenus anterior on the first rib. Moving from here, the therapist palpates approximately 2 cm posteriorly, applies gentle pressure, and very quickly feels the pulsating subclavian artery, confirming the correct localization of the posterior scalenus gap. The brachial plexus accompanies the artery as it

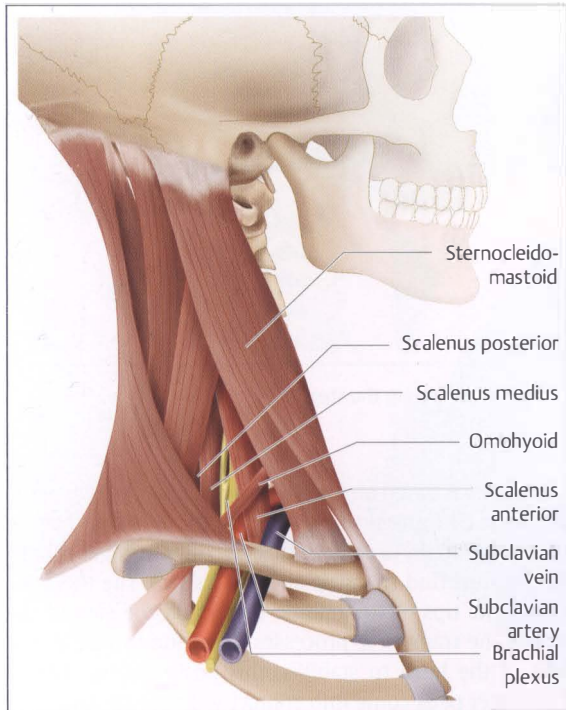


Fig. 12.89 Position of the first rib.

passes through this intermuscular gap. The almost vertical muscle belly of the scalenus medius is found immediately posterior to this.

Brachial Plexus

The branches of the brachial plexus can be palpated in the area surrounding the artery and immediately superior to it. These thin strands can be felt using a transverse palpation, even without the use of extra aids. When the branches have been correctly located, they can typically be rolled back and forth underneath the palpating finger, similar to the plucking of a very loose guitar string.

Tips: If it is impossible to find the plexus using the above-mentioned method, the following aids are recommended to place the plexus under tension and enable the branches to be felt more clearly. The therapist's hand palpates in the posterior scalenus gap and the other hand facilitates movement in the ipsilateral arm of the patient.

The following section describes the steps used to position the arm and the cervical spine so that more tension is placed on the median nerve, which makes the plexus more prominent. Each of the phases described places the nerves under tension, enabling easy palpation of the plexus. The therapist need not be afraid of palpating the plexus or conducting this maneuver as peripheral neural structures are usually insensitive to moderate direct pressure that is applied slowly:

- Phase 1: the ipsilateral arm is extensively abducted in the frontal plane (90° is optimal) and rests on the therapist's

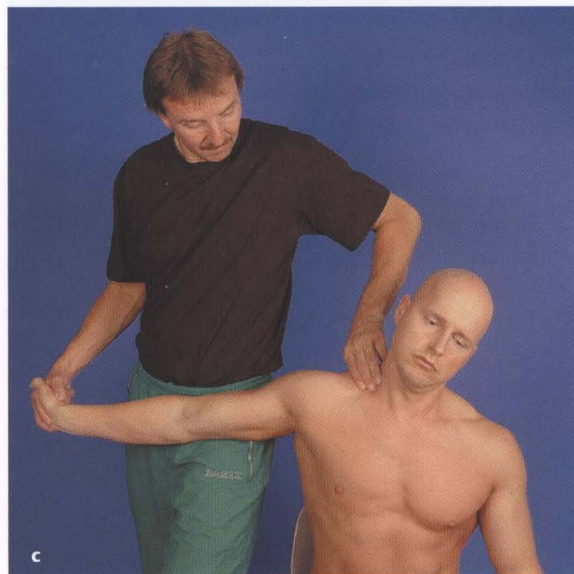




Fig. 12.90a–c Palpating the brachial plexus. a Phase 1. b Phase 2. c Phase 3.

thigh. The elbow is slightly bent and the hand almost positioned in neutral (Fig. 12.90a, phase 1).

- Phase 2: the elbow and wrist are extended. This places the median nerve under considerable tension. The correct localization of the plexus can be confirmed by alternatively

tensing and relaxing the plexus and is achieved by extending and flexing the hand and elbow (Fig. 12.90b, phase 2).

- Phase 3: if the plexus still cannot be palpated, tension can be further increased by laterally flexing the cervical spine to the opposite side (Fig. 12.90c, phase 3). Further tension can only be achieved by depressing the shoulder girdle.

Tips for Assessment

Palpation during Movement at C1 (“Offset”)

The localization of the C1 transverse process can be used in several ways for assessment. The following section describes how to feel movement at the atlas during upper cervical lateral flexion. These movements have already been mentioned in the section “Biomechanics of the Upper Cervical Spine” above, page 326. When the cervical spine laterally flexes, the atlas moves a few millimeters toward the side of lateral flexion. This offset can be assessed using palpation and provides information on the normal pattern of movement at the atlas that is expected when lateral flexing to both sides.

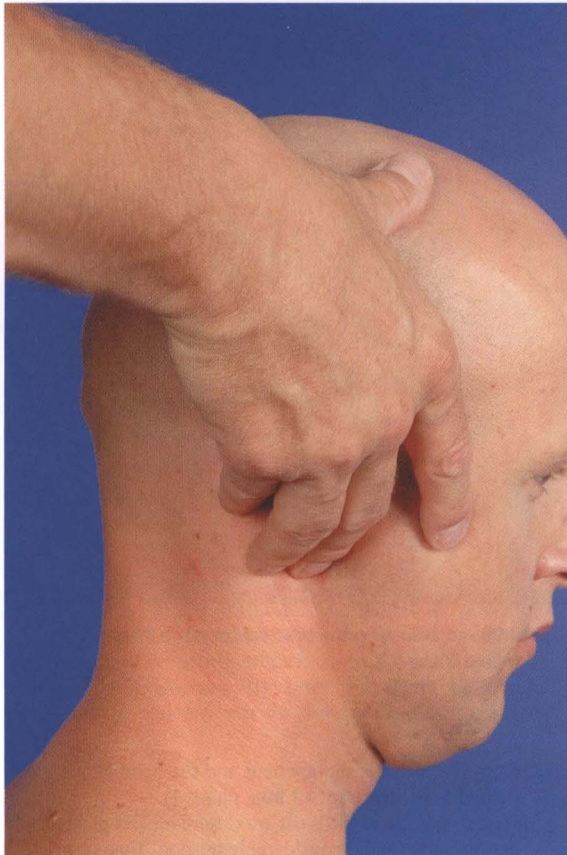


Fig. 12.91 Hand placement for the offset test.

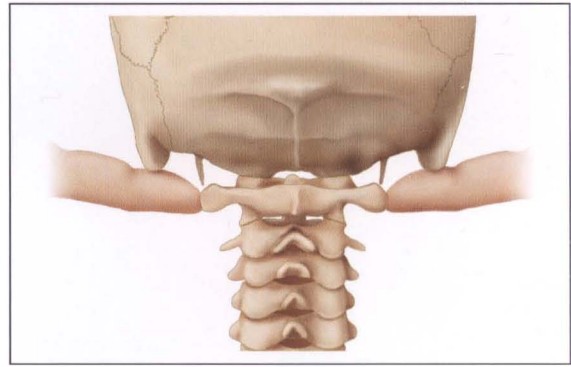


Fig. 12.92 Palpating the step.

The test is based on the palpation of a step between the tip of the C1 transverse process and the lateral end of the mastoid process. To achieve this, the middle finger of both hands must find this step and feel its size. The therapist places the tips of the middle fingers on the side of the tips of the transverse processes. The thumbs rest on the side of the head to stabilize this position (Fig. 12.91). The finger pads come into contact with the posterior aspect of the mastoid process and feel the distance between the tip of the transverse process and the side edge of the mastoid process (Fig. 12.92).

Aim

To assess mobility in the atlantooccipital joints (C0/C1).

Criteria

Change in the size of the step following positioning in lateral flexion to the same side.

Procedure

- Phase 1: palpating the size of the step in a neutral SP. It is important that the upper cervical spine is positioned in a completely neutral position (Fig. 12.93a, phase 1).
- Phase 2: the head is moved into maximal upper cervical lateral flexion and the size of the step is palpated once again (Fig. 12.93b, phase 2).

Interpretation

When mobility at the atlantooccipital joints is normal, the step is expected to decrease in size. If no difference can be observed between the size of the step before and after lateral flexion, this is an indication of a hypomobile segment. With normal mobility, it is also expected that the size of the step on the other side will decrease when laterally flexing in the opposite direction. It can only be assumed that the mobility of C0/C1 is normal when both offset tests demonstrate a decrease in step size. If the offset does not

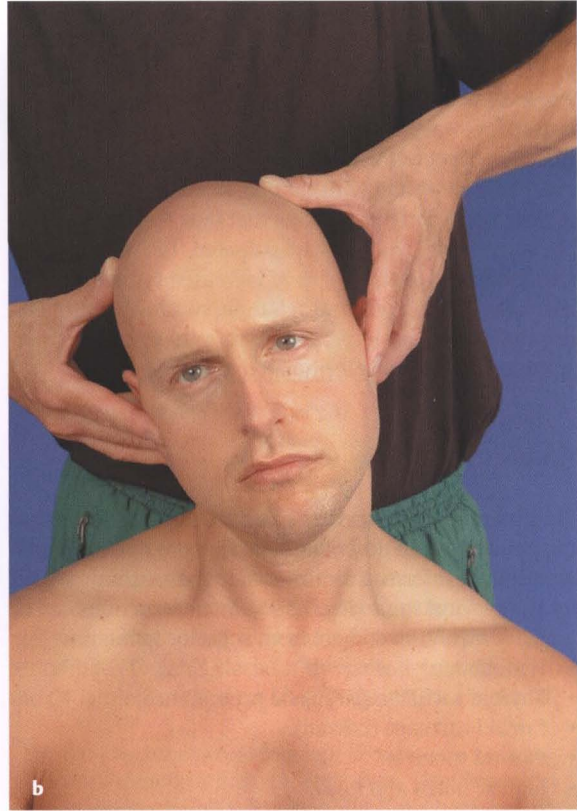
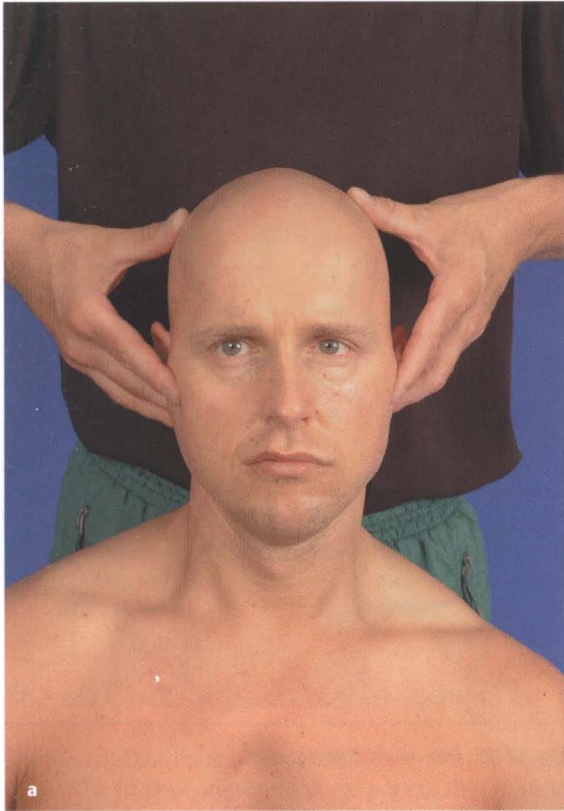


Fig. 12.93a, b Offset test. a Phase 1. b Phase 2.

decrease in one or both of these tests, the side of restricted mobility must be documented.

Anterior Palpation Techniques

Overview of the Structures to be Palpated

- Hyoid bone—lamina C3.
- Thyroid cartilage (indentation)—lamina C4.
- Thyroid cartilage (lateral surfaces)—lamina C5.
- Cricoid cartilage—lamina C6.
- Carotid tubercle.
- Jugular notch—T2 spinous process.

Anterior structures allow therapists to identify the level of individual vertebrae with more confidence. It is for this reason that the hyoid bone and the larynx are included in the palpatory orientation. If it is difficult to locate the lamina of a vertebra and the therapist wants to ensure that structures have been correctly located, an anterior structure of the same level can be located. It is impossible to identify the level of a vertebra using the usual techniques (in the sitting SP) when treating the patient in supination. Palpation of the anterior aspect can now be used as a crucial aid in identifying the vertebra being sought.

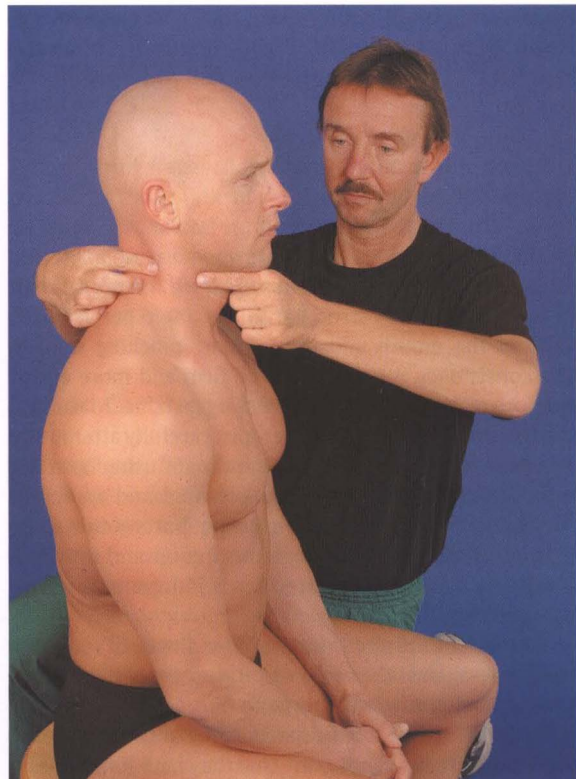


Fig. 12.94 Patient and therapist SPs.

The patient is positioned in erect sitting with the cervical spine in neutral (see the section “Starting Position,” p. 332). The therapist is positioned next to the patient at eye level with the anterior region of the neck. One hand is used for local palpation and the other hand for the identification of posterior structures (Fig. 12.94). The therapist proceeds slowly and with caution when approaching this region. Many patients indicate that they feel uncomfortable when these structures are palpated. The therapist will frequently notice clear signs of increased sympathetic activity, for example, general agitation, swallowing more often than usual, an increased pulse rate, or distinct perspiration. Palpation is terminated in this case.

Anatomy

The anterior structures of the neck needed for the following palpations are described here in more detail, supplementing the information provided in the anatomy chapter for the cervical spine (Fig. 12.95). Some structures can be accessed easily, listed here from superior to inferior:

- Hyoid bone.
- Thyroid cartilage (laryngeal prominence).
- Cricoid cartilage (cricoid).
- Carotid tubercle.
- Jugular notch and fossa.

The following palpation describes how these structures clarify the identification of the cervical vertebral level. Hoppenfeld (1992) and Winkel (2004) have already described this classification. These structures are always found at the same level in each person, with only one exception.

Hyoid Bone—Lamina C3

The thumb and index finger are spread wide apart and slide along the floor of the mouth. Both fingers attempt to hold onto a firm structure in the angle between the floor of the mouth and the neck by pinching slightly. The consistency is expected to be firm and more elastic than the resistance felt when pressing on bone. To confirm the correct localization, the therapist carefully attempts to move the hyoid bone to the left and right using both fingers. The firm lateral edges are palpated and are felt to curve slightly outward. When the patient swallows, the therapist feels the hyoid bone moving up and down, as is the case with all structures that will be sought in this palpation.

Observed from the side, the index finger of the other hand rests against the posterolateral aspect of the cervical spine and applies gentle pressure (Fig. 12.96). When the index fingers of both hands are located at the same level, the therapist can be fairly sure that they have found the level of the C3 lamina (Fig. 12.97). Compared with the other

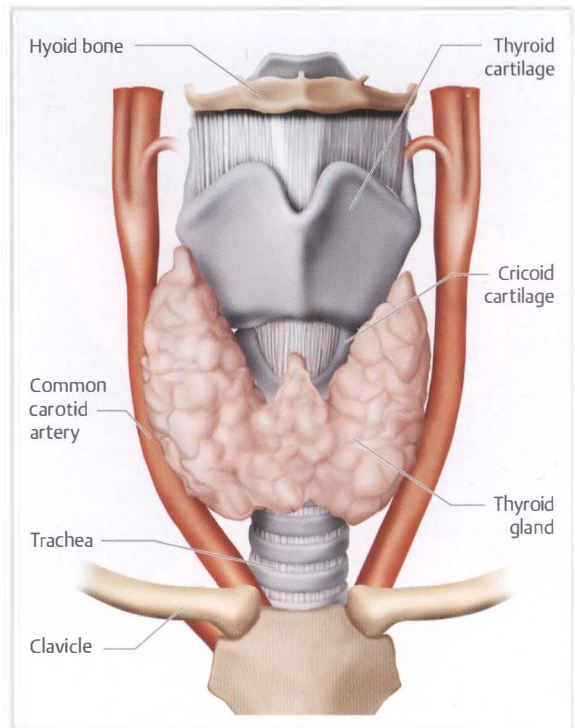


Fig. 12.95 Anterior anatomy

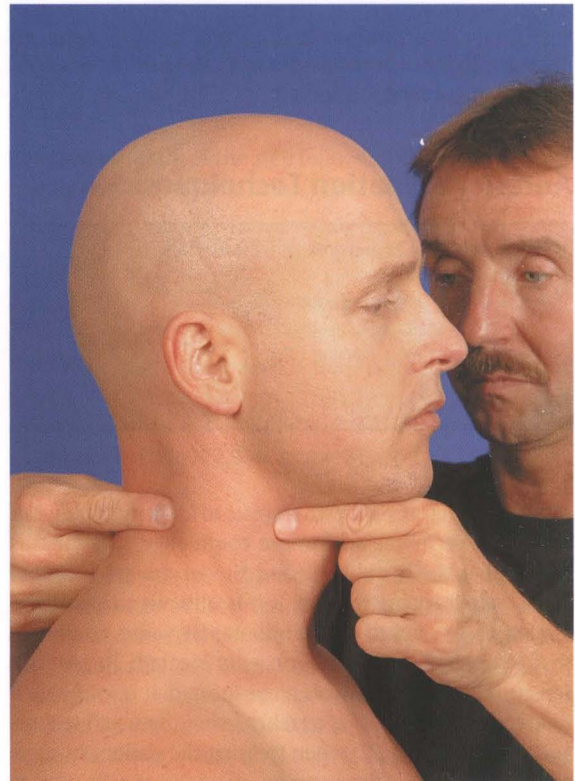


Fig. 12.96 Palpating the hyoid bone.

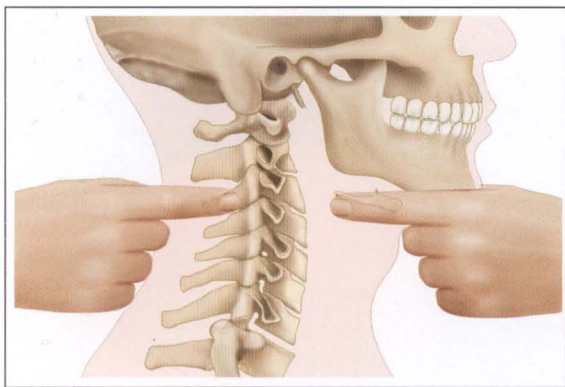


Fig. 12.97 Identifying the level of C3.

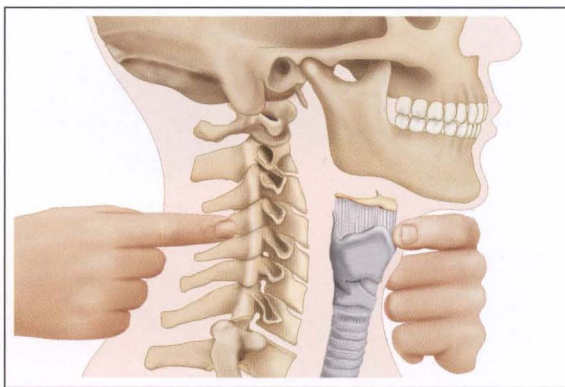


Fig. 12.99 Identifying the level of C4.

anterior structures, the position of the hyoid bone varies considerably. It can be found somewhat more superior or inferior to the floor of the mouth, meaning that there is no exact determination of the level of C3.

Thyroid Cartilage (Indentation)—Lamina C4

The therapist continues the palpation using the pad of one finger. The anterior, most prominent edge of the larynx is sought first. This point is used for orientation and the pal-

pation continues by moving superiorly a short distance until a distinct indentation can be felt that opens up superiorly. This indentation is found directly superior to the prominent tip commonly known as the “Adam’s apple” and is particularly noticeable in men. When the posterior index finger is placed at the same height, the level of the C4 lamina has been marked (Figs. 12.98 and 12.99).

Tip: If the hyoid bone could not be found using the previously described technique, it can be alternatively identified by palpating superior to this indentation. The hyoid bone and the thyroid cartilage are only separated from each other by a ring-shaped depression.

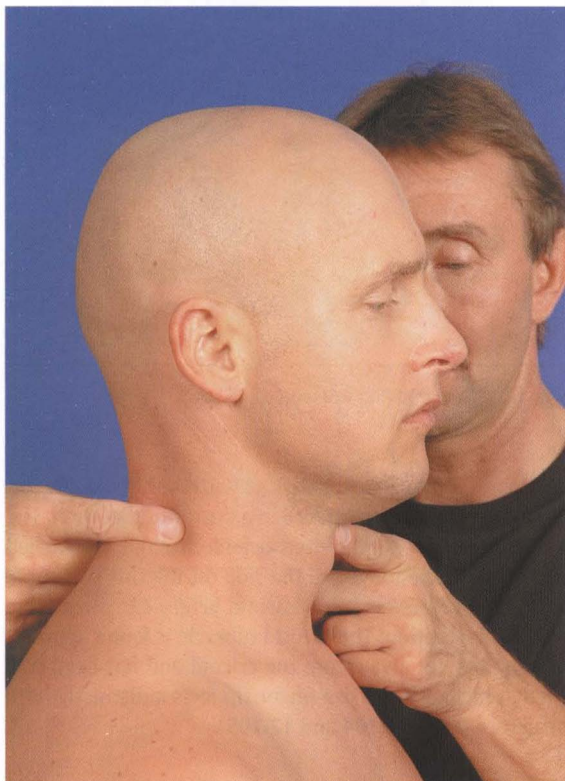


Fig. 12.98 Palpating the indentation.

Thyroid Cartilage (Lateral Surfaces)—Lamina C5

The palpating finger slides inferiorly again for a short distance onto the middle of the anterior ridge of the thyroid cartilage. Two lateral surfaces can be felt from this point. When the finger pads are positioned in the middle of these surfaces, this corresponds to the level of the C5 lamina (Figs. 12.100 and 12.101).

Cricoid Cartilage—Lamina C6

Starting from the anterior ridge of the thyroid cartilage, the palpation continues in an inferior direction. The finger pad slides into a depression that is bordered inferiorly by the cricoid cartilage (cricoid) (Fig. 12.102). The therapist is now palpating the uppermost boundary of the trachea, which is the only complete ring of the cartilage clasp surrounding the trachea. The correct localization of the cricoid cartilage is characterized by its typical convex form when it is palpated in a superior/inferior direction. It is found at the height of the lamina of C6 (Fig. 12.103). The tracheotomy incision site is found superior to the cricoid. Good knowledge of anatomy is critical when applying first

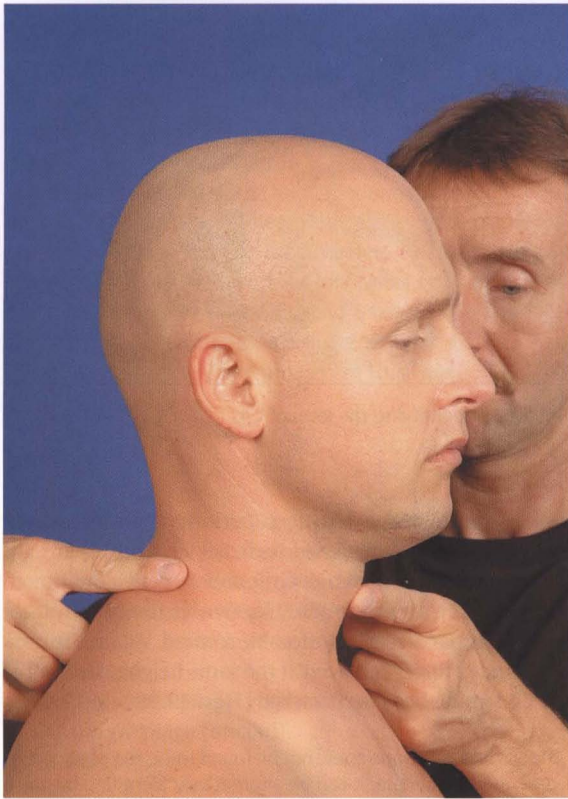


Fig. 12.100 Palpating the larynx.

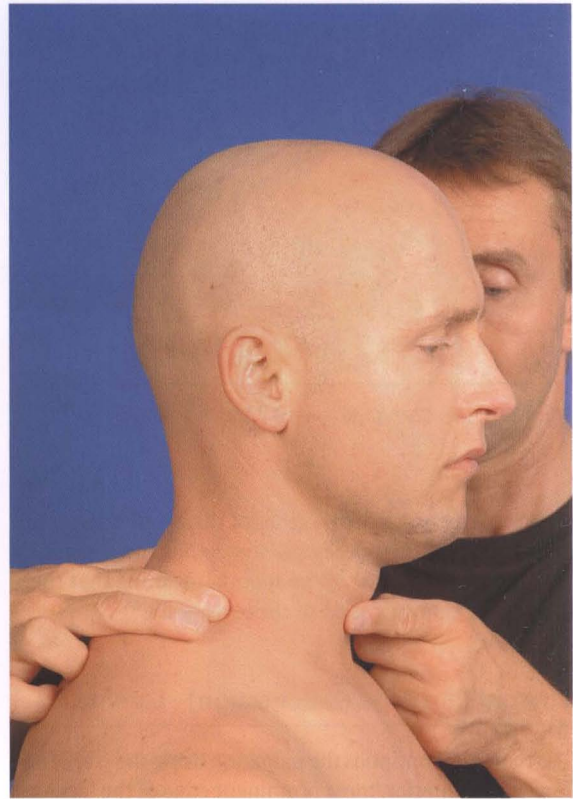


Fig. 12.102 Palpating the cricoid cartilage.

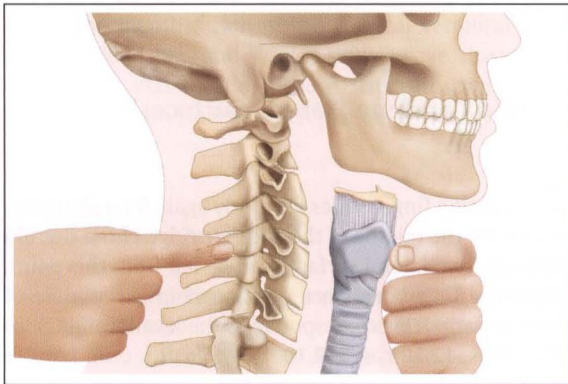


Fig. 12.101 Identifying the level of C5.

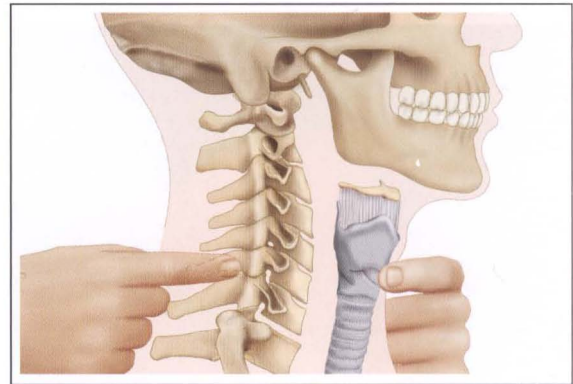


Fig. 12.103 Identifying the level of C6.

aid at accident sites. The thyroid gland is found on both sides of the cricoid and can rarely be felt as a structure in its own right due to its very soft consistency.

Carotid Tubercle

The common carotid artery and the anterior tubercle of the C6 transverse process (carotid tubercle) can be easily reached lateral to the cricoid. For this purpose, a finger pad palpates the anterior aspect of the cricoid and moves posteriorly over the cricoid, applying pressure with care.

Once the finger pad loses contact with the cricoid, the finger tips apply more pressure in a posterior direction. The anterior border of the sternocleidomastoid is reached here and can be moved to the side during this palpation. The pulse of the common carotid artery can already be felt at this location. The carotid tubercle is found approximately 2–3 cm away from the cricoid and has been correctly reached when the finger tip feels a distinctly hard structure (Figs. 12.104 and 12.105).

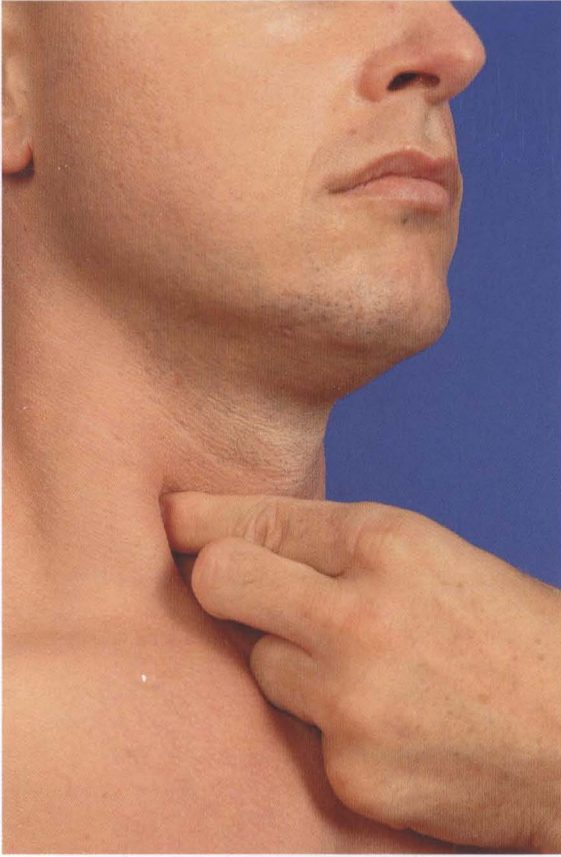


Fig. 12.104 Palpating the carotid tubercle.

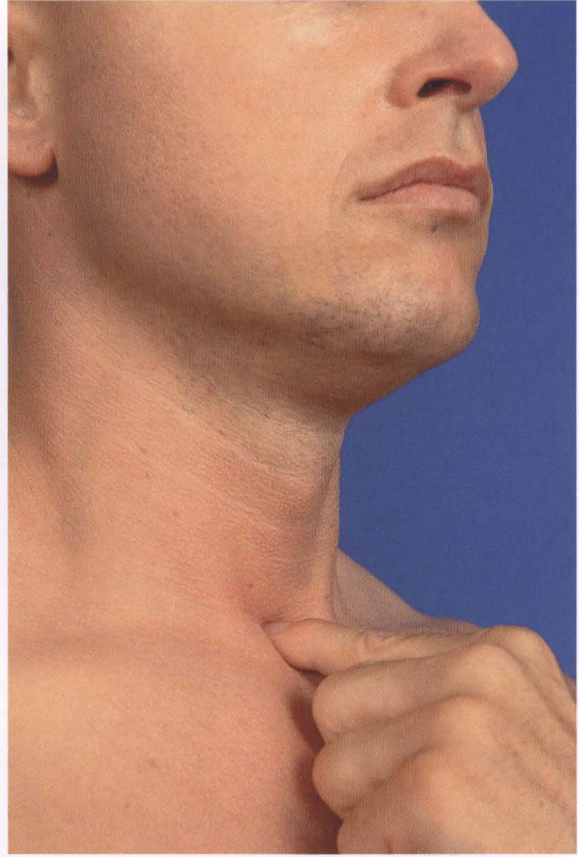


Fig. 12.106 Jugular notch and fossa.

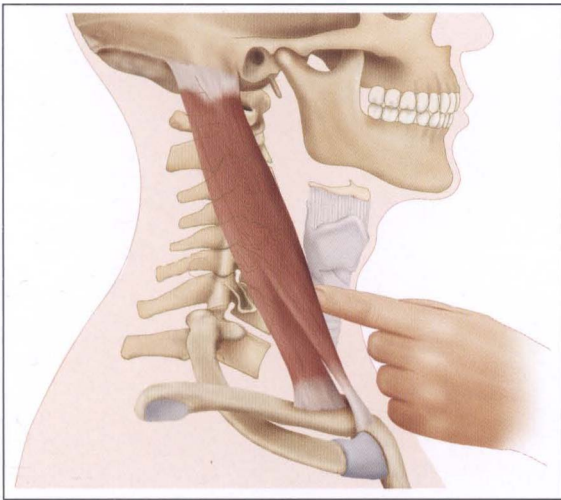


Fig. 12.105 Identifying the level of the carotid tubercle.

Note: Only one side may be palpated at a time to make sure that both carotid arteries are not pinched off simultaneously! Additionally, the palpation must not be conducted on people over 60 years of age when the person is suspected or known to suffer from arteriosclerosis. Otherwise, there is the risk of the sclerotic plaques found on the walls of the artery detaching and causing a cerebral embolus.

Jugular Notch—T2 Spinous Process

Starting at the anterior aspect of the cricoid, the finger palpates inferiorly for approximately two finger-widths until it reaches the superior border of the manubrium. This point is bordered bilaterally by the sternocleidomastoid tendons and the protruding medial ends of the clavicles. This fossa corresponds to the level of the T2 spinous process. The finger tips extend into the superiorly lying soft-tissue fossa (jugular fossa) when a finger pad rests on the superior aspect of the jugular notch. Further sections of the trachea can be reached by carefully applying pressure deeper into the tissue (Fig. 12.106).

Study Questions

1. What are the functions of the cervical spine?
2. Why does it make sense to divide the cervical spine into two sections?
3. What is the neurovascular cross at the cervical vertebra?
4. Why do the cervical intervertebral disks split during the aging process?
5. What are the biomechanical consequences of the alignment of the cervical facet joints?
6. How are lateral flexion and rotation coupled in the upper and lower cervical spines?
7. Which bones form the uncovertebral joint?
8. The occipital bone is composed of which sections?
9. What are the courses of the individual lines on the occiput?
10. Which parts of the atlas and axis can be reached directly using palpation?
11. What functions does the ligamentum nuchae have?
12. Which structures are located anterior or posterior to the transverse ligament of the atlas?
13. Which ligaments have the most important control function in the upper cervical spine?
14. Name four intrinsic neck muscles and four extrinsic neck muscles.
15. Describe the position of the insertion site for the semispinalis capitis, splenius capitis, and sternocleidomastoid.
16. What does the term intermuscular gap mean here?
17. Describe the course of the brachial plexus from the scalenus gap to the upper arm.
18. How does the therapist position the cervical spine in neutral in a sitting SP?
19. What are the most important bony landmarks for orientation on the posterior and lateral skull?
20. Into which cervical position should the patient move to make tension in ligamentum nuchae easily palpable?
21. From which bony landmark does the therapist start looking for the cervical laminae?
22. What does the therapist expect to feel when palpating the articular column?
23. Which structures travel through the medial and lateral intermuscular gaps on the occiput?
24. Where is the C2 transverse process in relation to the sternocleidomastoid?
25. Which structures form the boundaries to the posterior triangle of the neck and how can the triangle be subdivided?
26. Where does the therapist start looking for the scalenus anterior?
27. Describe the three positions where the first rib is palpable.
28. Why is palpation of the throat helpful?
29. What is the "Adam's apple" and which cervical vertebra is found at the same height?

13 Head and Jaw

- Introduction ... 369**
- Significance and Function of the Temporomandibular Joint ... 369**
- Common Applications for Treatment in this Region ... 369**
- Required Basic Anatomical and Biomechanical Knowledge ... 369**
- Anatomy of the Bony Skull ... 370**
- Palpation of the Bony Skull ... 370**
- The Jaw—Temporomandibular Joints ... 371**
- Palpating the Temporomandibular Joints ... 374**
- Palpatory Examination of the Jaw Muscles ... 375**
- Study Questions ... 385**

THIS PAGE INTENTIONALLY
LEFT BLANK

13 Head and Jaw

Wolfgang Stelzenmueller

Introduction

Of all the structures in the head region, physical therapists are best able to treat the jaw (temporomandibular joint or TMJ) and the atlantooccipital joint, which have already been described in Chapter 12, page 326 f. The special feature of the TMJ is that one joint never moves alone and the interaction with the contralateral joint must always be considered.

Symptoms arising in the head/jaw/facial region are integrated into the general term craniomandibular dysfunction (CMD). This literally describes the suboptimal functioning of the cranium (condylar path on the skull) and the mandible (the head[s] of the lower jaw) joint partners. The term temporomandibular joint disorder (TMD) is more commonly used in English. It more precisely describes the suboptimal functioning of the head of the mandible (including the articular disk located in the joint) and the temporal bone and names the bones that contribute anatomically to the TMJ.

Many of these craniomandibular symptoms present as different types of headache or as ear, tooth, jaw, or face pain. This frequently involves “referred pain” arising from structures such as muscle trigger points (where pain is projected from sections of muscle into other regions).

In addition to the systematic subjective and objective assessments, precise palpation of the muscles and, as much as possible, the articular structures, is of importance. This enables the therapist to differentiate symptoms arising from referred pain (from muscular trigger points), and other causes, such as arthrotic changes in a joint or articular damage.

Significance and Function of the Temporomandibular Joint

The TMJ is not only needed for the function of mastication; it is also used for speaking, singing, yawning, kissing, etc. These are generally movements involving the opening and closing of the mouth.

The biomechanics of the TMJ enables movement in all three spatial axes (vertical, transverse, sagittal). Mandibular movements are never purely translational and are also never purely rotational.

The main movements in the mandible are:

- Elevation and depression (opening and closing the mouth).
- Protrusion and retrusion (translation movement of the mandible anteriorly and posteriorly).
- Lateral and medial deviation (movement of the mandible to the side away from or toward the median plane).

Common Applications for Treatment in this Region

As with other joints in our body, the TMJ also suffers from:

- Capsular and noncapsular restrictions in mobility.
- Hypermobility or instability.
- Pathological conditions in the disk–condyle complex (the relationship between the “head of the lower jaw” and the buffering articular disk as well as the opposing joint surface).
- Injuries to ligaments or ligamental overuse syndromes.
- Injuries to muscles or muscular overuse syndromes.
- Arthrotic changes.

In dental literature, TMDs are commonly subdivided as follows:

- Myogenic, that is, symptoms originating in the muscles.
- Arthrogenic, that is, direct joint symptoms.
- Myoarthropathic symptoms, that is, a combination of muscular and joint symptoms.

It is difficult to directly differentiate the above-mentioned symptoms in practice, as a TMD arising from muscular symptoms is usually directly followed by the involvement of articular structures.

Required Basic Anatomical and Biomechanical Knowledge

Often, there is not enough time available in physical therapy training to intensively address the head and the TMJ, in particular. A summary of the fundamental (palpable) structures is included in the next section to improve anatomical orientation. Therapists should initially practice on a plastic skull to obtain more confidence, before palpating the corresponding structures on patients.

Tip: When studying the biomechanics of the TMJ, rubber bands or a Thera-band can simulate and illustrate the pull of muscles very well.

Anatomy of the Bony Skull

Dividing the Head into Regions

To aid orientation, the skull is divided into 11 regions (Fig. 13.1):

- Frontal region.
- Parietal region.
- Occipital region.
- Temporal region.
- Zygomatic region.
- Orbital region.
- Infra-orbital region.
- Buccal region.
- Mental region.
- Oral region.
- Nasal region.

The following 11 bony structures found in these regions can be palpated well (Fig. 13.2):

- Occipital bone.
- Parietal bone.
- Frontal bone.
- Lacrimal bone.
- Nasal bone.
- Temporal bone.
- Styloid process.
- Sphenoid.
- Zygomatic bone.
- Maxilla.
- Mandible.

Now that rough anatomical orientation is possible, the more specific palpation of bony structures on the skull follows.

Overview of the Frontal Aspect of the Viscerocranium

The viscerocranium is divided into:

- The upper face with the squamous part.
- The middle face, mainly characterized by the maxilla (upper jaw).
- The lower face, dominated by the mandible (lower jaw).

The following structures are found in the viscerocranium:

- Orbits.
- Nasal cavities.

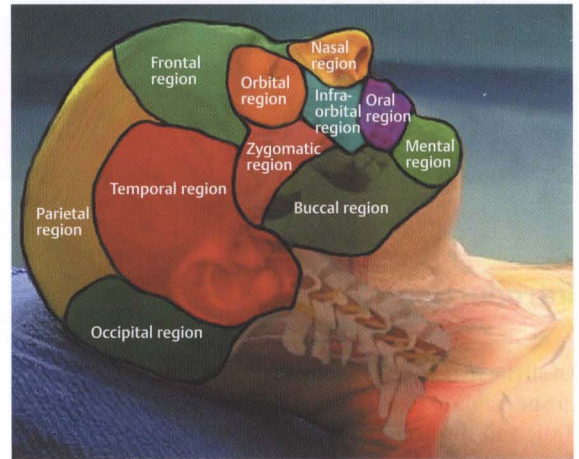


Fig. 13.1 Regions of the head.

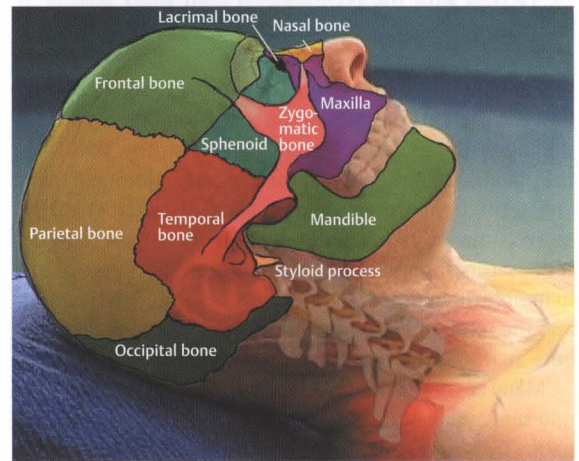


Fig. 13.2 Palpable bony structures of the head.

- Paranasal sinuses.
- Oral cavity.

Palpation of the Bony Skull

Frontal Aspect of the Viscerocranium

Overview of the Structures to be Palpated

In addition to the structures mentioned above, prominent, palpable bony structures include the following (Fig. 13.3):

- Pressure points of the trigeminal nerve:
 - supraorbital foramen: exit point for the lateral branch of the supraorbital nerve (first pressure point of the trigeminal nerve) (1)
 - infraorbital foramen: exit point for the infraorbital nerve (second pressure point of the trigeminal nerve) (2)

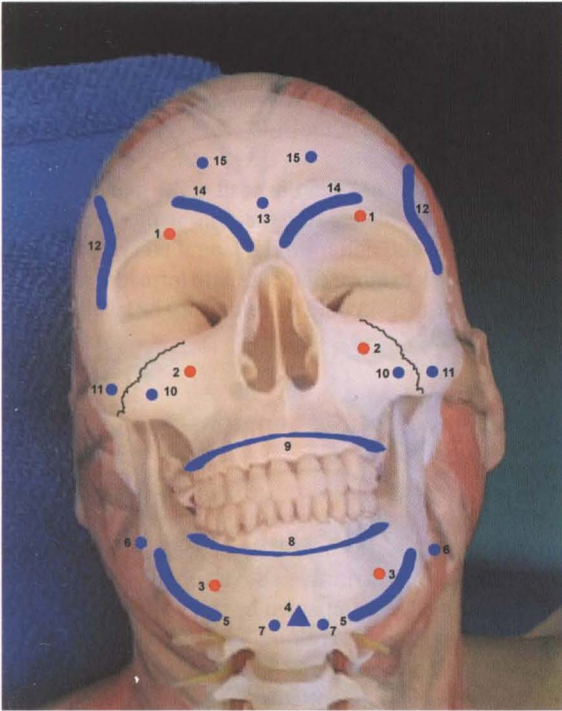


Fig. 13.3 Additional prominent, palpable bony structures of the head.

- mental foramen: exit point for the mental nerve (third pressure point of the trigeminal nerve) (3).
- The structures that can be palpated via the lower jaw (mandible) include the following:
 - mental protuberance (4)
 - body of the mandible (5)
 - angle of the mandible (6)
 - mental tubercle (7)
 - alveolar part of the mandible (8)
 - alveolar process of the maxilla (9)
 - zygomatic process of the maxilla (10)
 - zygomatic bone (11)
 - temporal line (12)
 - glabella (13)
 - superciliary arch (14)
 - frontal tuber (15).

Lateral Aspect of the Skull

The dominating section of the lateral skull is formed by the side wall of the skull, the parietal bone. The temporal bone is the central bone in the lateral skull. Its surface forms a joint with the articular disk and the head of the mandible, forming the TMJ.

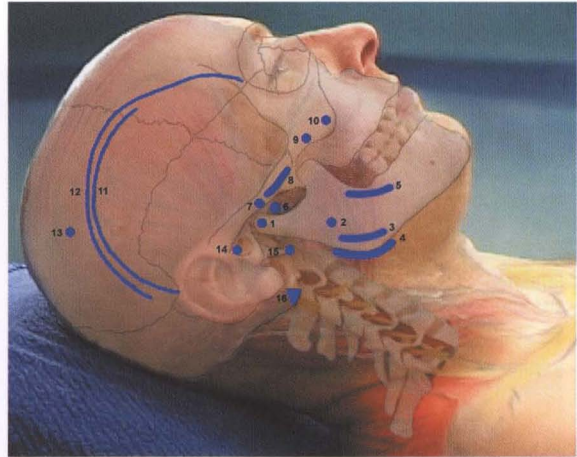


Fig. 13.4 Additional prominent, palpable bony structures of the lateral aspect of the head.

Overview of the Structures to be Palpated

Once again, orientation begins with the mandible (Fig. 13.4):

- Head of the mandible (1).
- Ramus of the mandible (2).
- Masseteric tuberosity (3).
- Angle of the mandible (4).
- Oblique line (5).
- Articular tubercle (eminence) (6).
- Zygomatic process of the temporal bone (7).
- Zygomatic arch (8).
- Temporal process of the zygomatic bone (9).
- Lateral surface of the zygomatic bone (10).
- Inferior temporal line (11).
- Superior temporal line (12).
- Parietal tuber (13).
- Suprameatal spine (14).
- Styloid process (15).
- Mastoid process (site of insertion for the sternocleidomastoid) (16).

The Jaw—Temporomandibular Joints

Compared with other joints such as the knee, many of the ligamentous and bony structures in the TMJ cannot be palpated directly and therapists must use a variety of “knacks” to test these structures. It is important that therapists have good spatial sense as well as comprehensive knowledge in biomechanics of one or, more precisely, both TMJs, as movement in one TMJ causes simultaneous movement in the other TMJ.

In actual fact, the jaw should be called the temporo (disco)mandibular joint, as the temporal bone and the mandible do not articulate with one another alone.

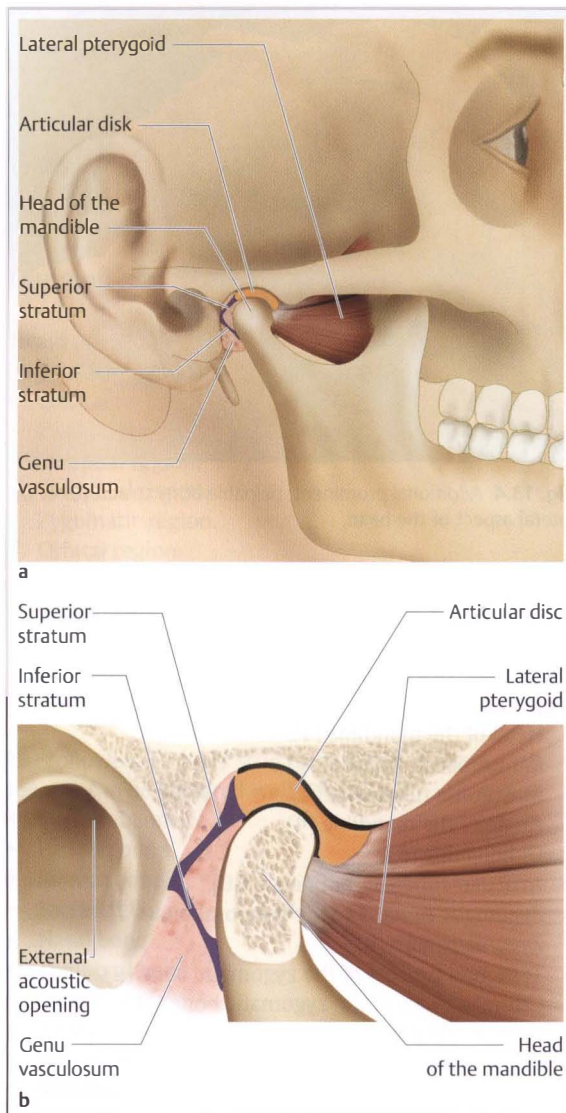


Fig. 13.5a, b Overview of the TMJ. **a** Overview. **b** Enlarged sectional view.

Required Basic Knowledge of Topography and Morphology

The articular disk, the meniscus or joint buffer, divides the jaw into superior and inferior compartments. The superior compartment, otherwise known as the upper joint, is formed by the temporal bone and the articular disk (discotemporal), while the inferior compartment or lower joint is the articulation between the mandible and the disk. The superior compartment functions as a gliding joint, while the inferior compartment acts as a “mobile” hinge joint.

The basic shape of the articular disk is similar to a horizontal figure eight. It is thinnest in the middle, approximately 1–2 mm thick, and can be approximately

3–4 mm thick at the ends. It is made of taut connective tissue, with cartilaginous cells still found at the edges. The disk is fibrocartilagenous in the area lying over the head of the mandible, where it resembles a cap (Fig. 13.5a, b).

The true function of the disk is to even out existing differences in articulating surfaces, namely the condylar path (temporal bone) and the head of the mandible. During movements of the jaw, rotation of the head of the mandible and the pull from the lateral pterygoid muscle causes the disk to move along the path formed by the temporal bone. The disk could therefore also be labeled a mobile joint socket.

Biomechanics of the Temporomandibular Joint

TMJ movements essentially consist of combined rotation and gliding. When the mouth is opened, a hingelike rotation occurs around a transverse axis running through both condyles. This is accompanied by translation in a sagittal direction, moving anteroinferiorly when the mouth is opened and posterosuperiorly when the mouth closes.

We primarily differentiate between:

- movements associated with the opening and closing of the mouth; and
- the required grinding movements associated with mastication.

Let us now take a more precise look at the movements that occur when the mouth is opened. The rotational-translational movement pattern at the TMJ is flowing, but will be divided here into three phases to make the complex biomechanics easier to understand.

Opening the Mouth

Muscles: Presented simply, mouth opening involves rotation initiated by the pull of the lateral pterygoid and the suprahyoid muscles and controlled by the mouth closure muscles that decelerate movement.

Joint: In **phase 1 (first phase of rotation)**, the condyles in the inferior compartment rotate slightly. This movement is initiated by the pull of the lateral pterygoid and the suprahyoid muscles and acts to overcome the occlusion of the teeth. This causes the head of the mandible to briefly rotate anteriorly. Following the mobile joint socket “principle,” the articular disk ideally moves in an anterior direction along the condylar path in a similar manner to the action of a pasta machine. Its movement is decelerated by the superior stratum of the bilaminar zone and the posterior fibers of the temporalis muscle and the lateral ligament. The inferior stratum, secured onto the condyle, relaxes (Fig. 13.6a).

The first phase flows over into **phase 2**, where more gliding occurs at the head of the mandible. The lateral

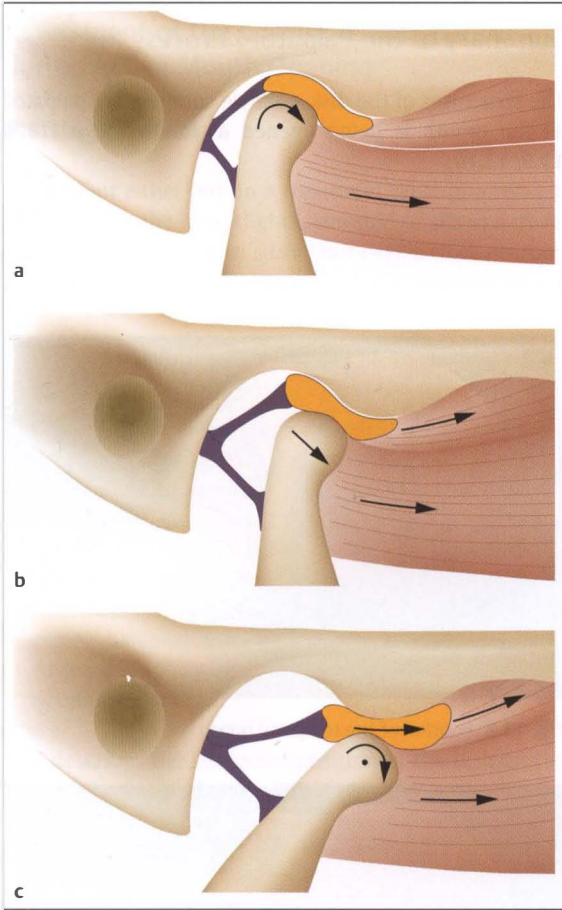


Fig. 13.6a–c Phases of opening the mouth. **a** Phase 1: rotational phase/opening phase. **b** Phase 2: gliding phase. **c** Phase 3: second rotational phase.

pterygoid muscle pulls the disk, acting as a mobile joint socket, in an inferoanteromedial direction beneath the articular tubercle. This is also defined as protrusion. This movement is produced by the pull of the lateral pterygoid, assisted and controlled by the muscles mentioned above, and is essentially decelerated by the **superior stratum of the bilaminar zone**, the posterior fibers of temporalis, and the lateral ligament (**Fig. 13.6b**). To open the mouth as wide as possible, the condyles must rotate once again at the end of the condylar path in **phase 3 (second phase of rotation)**.

The disk was pulled underneath the articular tubercle in the second phase and is now “pulled along” anteriorly, as the head of the mandible rotates, and pulled up onto the articular tubercle with the assistance of the lateral pterygoid muscle and the above-mentioned muscles. Only then can the mouth open up fully by further rotating. The movement of the disk is decelerated again by the superior stratum of the bilaminar zone. The inferior stratum, secured onto the condyle, is now placed under tension (**Fig. 13.6c**).

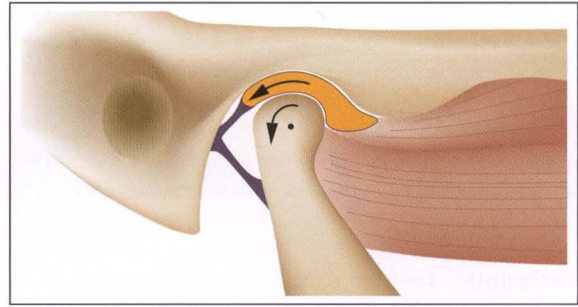


Fig. 13.7 Jaw closure

Closing the Mouth

The closure movement will now be addressed. The “returning rotation” of the head of the mandible moves the disk back to its original position (posterior direction of rotation for the head of the mandible) (**Fig. 13.7**).

The disk moves posteriorly at the same time and its movement is “decelerated” by the lateral pterygoid muscle.

Grinding Movements

The movements associated with mouth opening involve simultaneous contraction of the respective muscle groups and result in a relatively symmetrical and simultaneous movement of the two joints in the same direction. In comparison, grinding movements require muscles and joints to act differently.

While the chin remains in the median plane when the mouth is opened or closed, the tip of the chin moves to the right or the left during grinding movements. We differentiate between the working side and the balancing side. Food is reduced to small pieces on the working side while the other side (balancing side) carries out the required anteroinferior translation.

Therapists can only recognize, interpret, and treat abnormalities when they understand the biomechanics discussed above.

Assessing Deviations from the Mid-line during Mouth Opening

As not all structures of the jaw can be palpated directly, therapists have to use a variety of tests when palpating the bony and capsular–ligamentous structures of the jaw and the articular disk to recognize possible pathological conditions in these structures.

The two TMJs are always observed at the same time, making significant deviations from the mid-line, during mouth opening for example, immediately apparent.

*Deflection = deviation of the incisor point (or the middle of the tip of the chin) to one side when the lower jaw opens the mouth **without** returning to the median plane.*

*Deviation = deviation of the incisor point (or the middle of the tip of the chin) to one side when the lower jaw opens the mouth **with** a return movement to the median plane.*

Technique: Test for Active Mouth Opening

The first test used to assess the presence of deviations or deflections is active mouth opening. It provides information on eventual restrictions in mobility caused by, for example, problems in the capsule or a unilateral blocking in the condylar path (opposing joint surface formed by the temporal bone). To assess active mouth opening, the patient is requested to open their mouth as wide as possible. This instruction is repeated several times as the mouth usually opens up more when the movement is repeated. The maximal mouth opening possible (incisal edge distance, IED) is measured using a caliper or a ruler where the scaling starts with 0 directly at its edge and this value is added to the vertical anterior teeth overbite. Once the symmetry and the degree of mouth opening possible have been determined, the clicking phenomenon will be assessed using palpation and is described in the following section.

Tip: According to the Helkimo index, normal mouth opening amounts to ≥ 40 mm. If this is not possible, possible deviations to the side can be discovered by measuring the degree of respective mandibular lateral deviation. If a deviation is not present, that is, with a lateral deviation to the right and left side of, for example, 10 mm, the 10 mm of lateral deviation is multiplied by 3 and 4 and the mouth is expected to be able to open up approximately 30–40 mm. If lateral deviation to one side (e.g., to the left) is not possible, a mechanical blocking of the right TMJ is the most likely cause, possibly due to anterior displacement of the disk. If the movement to one side is restricted, but nevertheless possible (e.g., only 5 mm to the left, but 10 mm to the right), the shorter distance is multiplied by 3 and 4 and the expected amount of mouth opening is calculated.

Palpating the Temporomandibular Joints

Overview of the structures to be palpated

- Temporal bone.
- Head of the mandible.
- Articular disk (indirectly “palpable” via the clicking “sound”).

Summary of the Palpatory Process

The structures of the disk–condyle complex are palpated as the mouth is being opened as follows (Figs. 13.8, 13.9, 13.10).

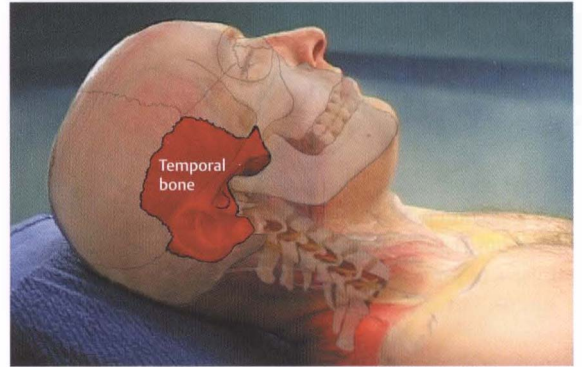


Fig. 13.8 Position of the temporal bone.

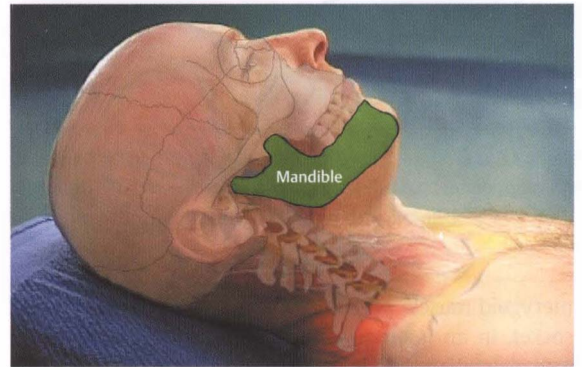


Fig. 13.9 Position of the mandible.

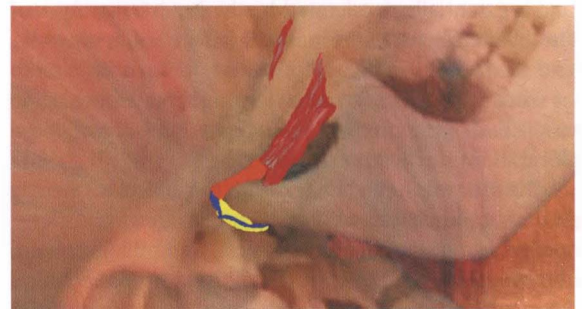


Fig. 13.10 Disk–condyle complex.

Assessment of the Clicking Phenomenon during Active Mouth Opening

Starting Position

The patient either lies on a treatment table in a relaxed position with the head slightly elevated or sits in a treatment chair. The therapist sits at an 11–12 o'clock position at the head end of the patient.

Technique

During mouth opening, the therapist palpates the indentation of the TMJ approximately one finger-width anterior and inferior to the auditory canal. In some cases, clicking or crepitation can be felt underneath the fingertips as the mouth actively opens. This can occur:

- Initially, as the mouth starts to open.
- Intermediately, when the mouth has opened approximately half-way to maximal opening.
- At the end of movement, just before maximal mouth opening is reached.

This describes the suspected position of the disk on the head of the mandible (Figs. 13.11, 13.12, 13.13).

Tip: As already mentioned, the TMJ essentially consists of the temporal bone and the head of the mandible. It is divided into the superior and inferior compartments by the articular disk. The articular disk ideally lies on top of the head of the mandible as a horizontal figure of eight. If the condyle strongly compresses the posterior pole of the disk, this can result in morphological changes in the disk and cause the disk to displace anteriorly. The attached superior stratum is then overstretched and the clicking phenomenon occurs. The previously described biomechanics of the disk–condyle complex worsens the pathological situation when the disk is displaced anteriorly and the jaw starts to click.

Palpatory Examination of the Jaw Muscles

Overview of the Structures to be Palpated

- Masseter.
- Medial pterygoid muscle.
- Lateral pterygoid muscle.
- Temporalis.
- Anterior and posterior bellies of the digastric.

Summary of the Palpatory Process

Practical aspects should also be considered when deciding how to proceed with the palpation. The orofacial muscles can be palpated intraorally and extraorally. It is recom-

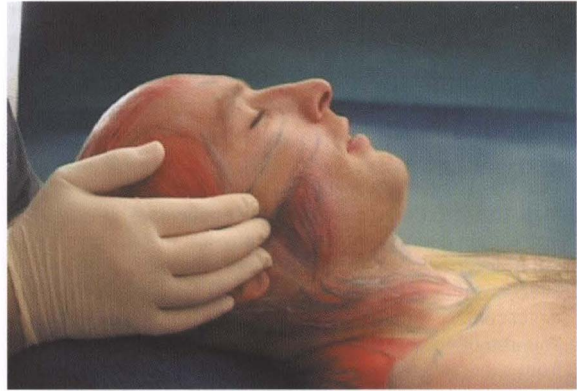


Fig. 13.11 Palpating the TMJ indentation with the mouth almost closed.

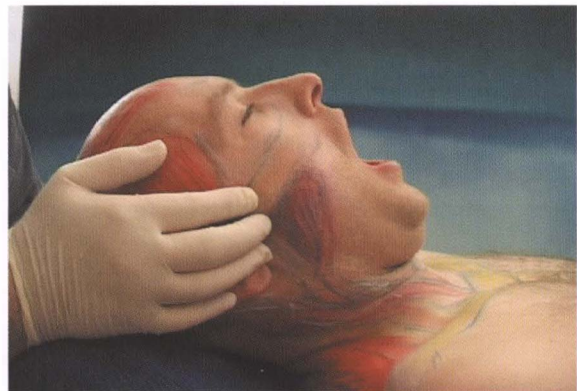


Fig. 13.12 Palpating the TMJ indentation with the mouth opened wide.

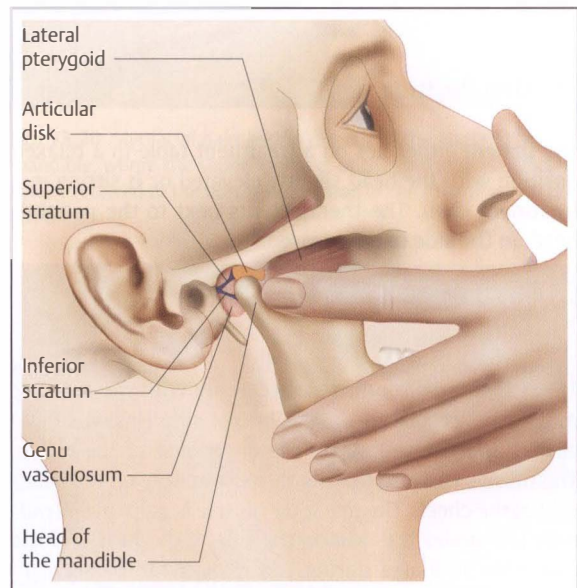


Fig. 13.13 Position of the palpating fingers on the jaw.

mended that gloves be removed or at least cleaned after the intraoral palpation is completed before continuing with the extraoral palpation. To aid understanding, the palpation of the muscles will be presented based on the action of the muscles.

Tip: It is essential that therapists wear gloves and especially a mask to protect themselves and their patients. This may be uncommon during treatment in a physical therapy practice, but is nevertheless necessary as there is an increased risk of infections during the treatment of CMD patients due to the direct contact with patients' saliva and, in some cases, blood. This also offers therapists and patients additional protection from airborne infections. As muscles are palpated extraorally (on the face) and intraorally (in the oral cavity), the esthetic question is raised as to whether the fingers, obligatorily gloved and moistened with the patient's saliva, should immediately continue to palpate extraorally on the patient's face. It is also not pleasant for patients when the intraoral palpation is conducted after the extraoral palpation on their face if they wear make-up.

Masseter

The masseter muscle is one of the most distinct and easy-to-palpate muscles of the masticatory system and is also frequently visible to the naked eye. It is divided into a superficial part and a deep part. It originates on the zygomatic arch and extends over a large area onto the masseteric tuberosity on the angle of the mandible.

It forms a muscle sling at the angle of the mandible together with the medial pterygoid muscle. Both of these muscles are responsible for approximately 55% of mouth closure.

Starting Position

The patient either lies on a treatment table in a relaxed position with the head slightly elevated or is sitting in a treatment chair. The therapist sits next to the patient's head on the side to be assessed.

Technique

The palpation is conducted intraorally with the index or middle finger placed on the buccal side (inside of the cheek) and the thumb on the outer side of the cheek. The muscle can also be palpated extraorally on the outer side of the cheek. The masseter muscle is palpable intraorally just under the skin on the side of the ramus of the mandible. Its bulge during contraction can be seen on the side at the angle of the mandible. The patient can be requested to gently press the teeth together to facilitate differentiation of the individual structures. By doing so, the contracting sections of the masseter are easy to palpate and differentiate (Figs. 13.14, 13.15, 13.16, 13.17).

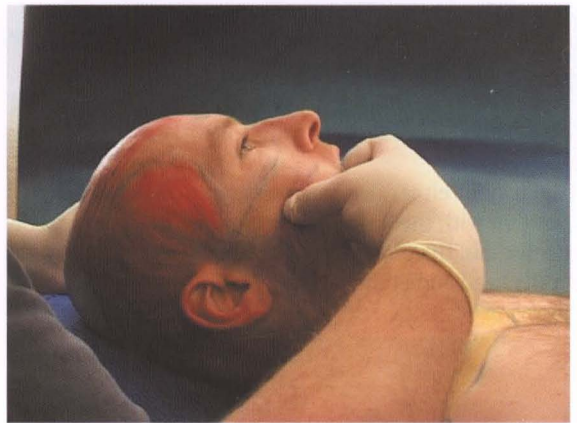

Fig. 13.14 Palpating the superficial part of the masseter.

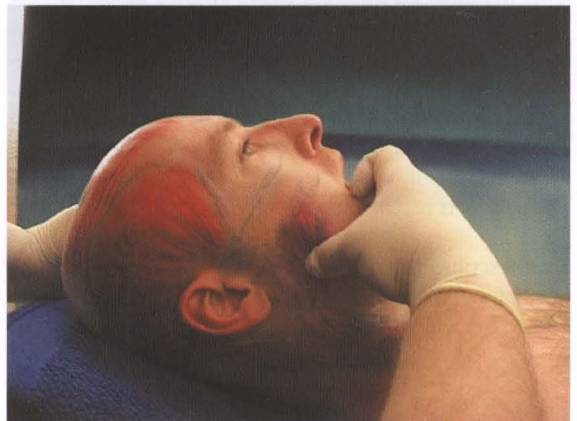

Fig. 13.15 Palpating the deep part of the masseter.

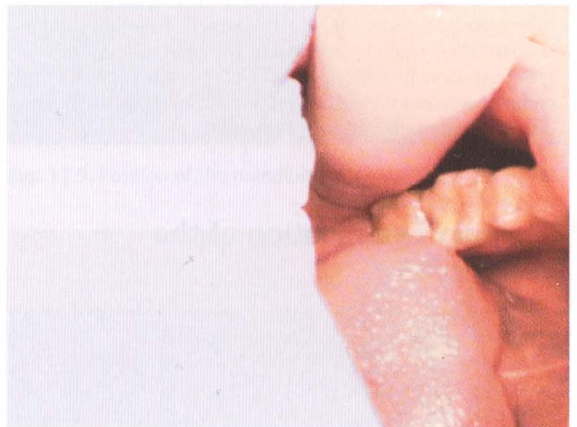

Fig. 13.16 Intraoral palpation of the masseter.

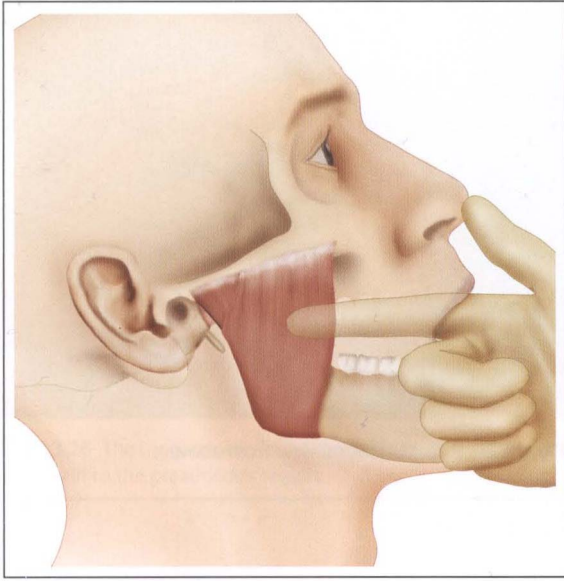


Fig. 13.17 Schematic illustration of the intraoral palpation of the masseter.

Tips for Assessment and Treatment

Ear and tooth pain in the lateral area of the teeth can be caused by referred pain originating in trigger points, for example, in the masseter (Figs. 13.18, 13.19, 13.20, 13.21).

Medial Pterygoid Muscle

The medial pterygoid muscle originates in the pterygoid fossa, extends almost parallel to the masseter found on the outer side of the jaw, and inserts into the angle of the mandible. It attaches to the pterygoid tuberosity here.

Together with the masseter, it forms a muscle sling at the angle of the mandible. Both of these muscles are responsible for approximately 55% of mouth closure.

Tip: The intense loading on the TMJ is obvious when observing the pressure applied during mastication. The pressure of mastication can amount to 700–950 N when biting, but may

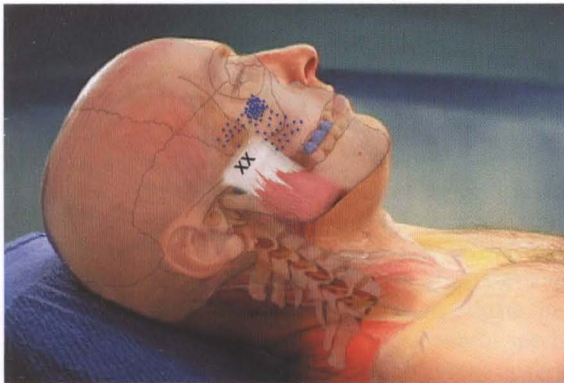


Fig. 13.18 The trigger points in the superior section of the superficial part of the masseter refer pain to the upper molar region and the maxillary sinuses.

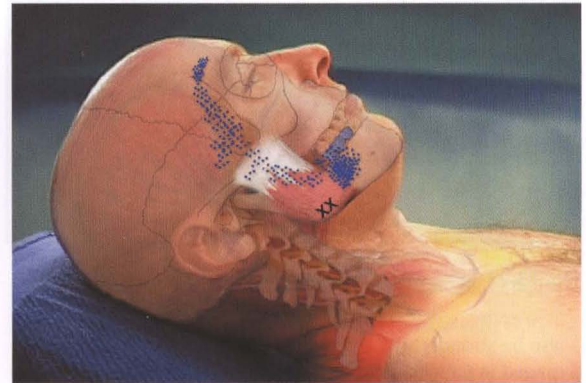


Fig. 13.20 Myofascial pain arising directly in the angle of the mandible, where the superficial part of the masseter is noticeable, is referred to the horizontal section of the mandible and the temples.

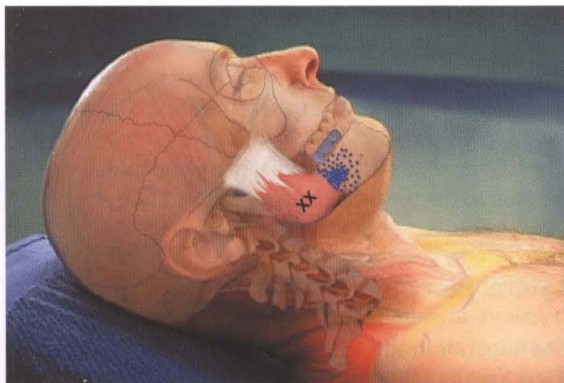


Fig. 13.19 Myofascial pain arising in the inferior section of the superficial part of the masseter is referred to the lower molar region and the horizontal section of the mandible.

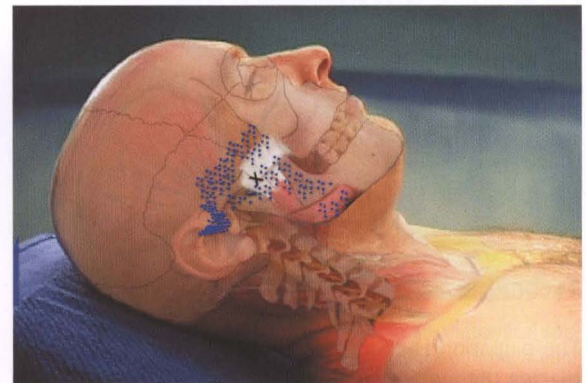


Fig. 13.21 The trigger points in the deep part of the masseter refer pain mainly to the ear and the preauricular region.

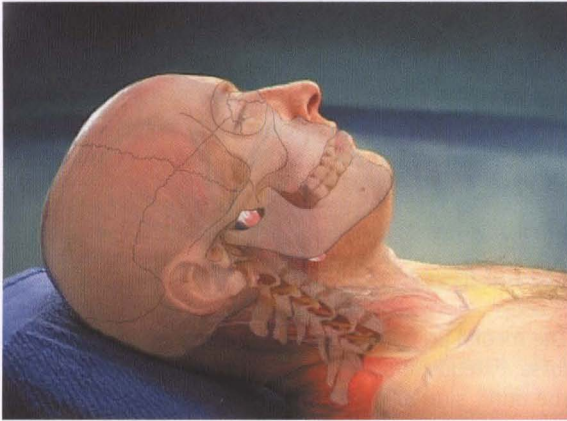


Fig. 13.22 Position of the medial pterygoid muscle.

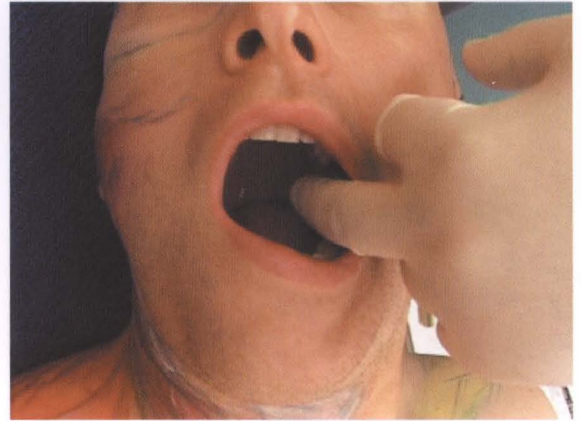

Fig. 13.24 Palpation route, view from above.

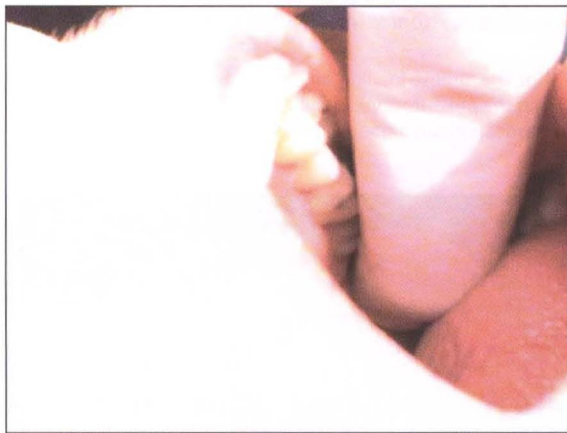

Fig. 13.23 Intraoral palpation of the medial pterygoid muscle.

also be stronger. The teeth and bite can be changed or damaged in patients who clench their teeth together or grind their teeth (bruxism); this is due to the intense pressure applied during mastication. The muscular dysbalances seen here can also cause pain in the face and other symptoms, for example, in the sacroiliac (SI) joint, by affecting the entire statics of the body.

Starting Position

The patient either lies on a treatment table in a relaxed position with the head slightly elevated or sits in a treatment chair. The therapist sits next to the patient's head on the side to be assessed.

Technique

The palpation is conducted intraorally and lingually by placing the index or middle finger on the medial side of the ramus of the mandible at the point where the ramus extends from the maxillary tuberosity to the angle of the mandible. It can also be palpated extraorally via the

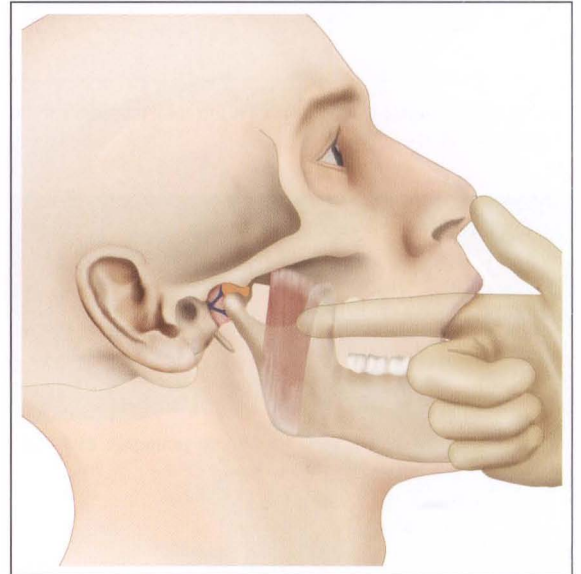


Fig. 13.25 Schematic illustration of the intraoral palpation of the medial pterygoid muscle.

inner side of the medial tip of the angle of the mandible (Figs. 13.22, 13.23, 13.24, 13.25).

Tips for Assessment and Treatment

The trigger points in the medial pterygoid muscle can refer pain to the preauricular region (Fig. 13.26).

Lateral Pterygoid Muscle

The superior head of the lateral pterygoid muscle originates on the infratemporal crest of the sphenoid bone. The inferior head comes from the lateral plate of the pterygoid process. The superior head is attached to the articular disk, pulls the disk anteriorly, and initiates mouth

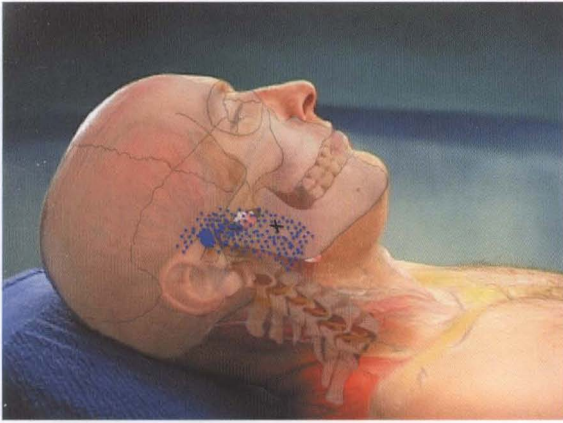


Fig. 13.26 The trigger points in the medial pterygoid muscle can refer pain to the preauricular region.

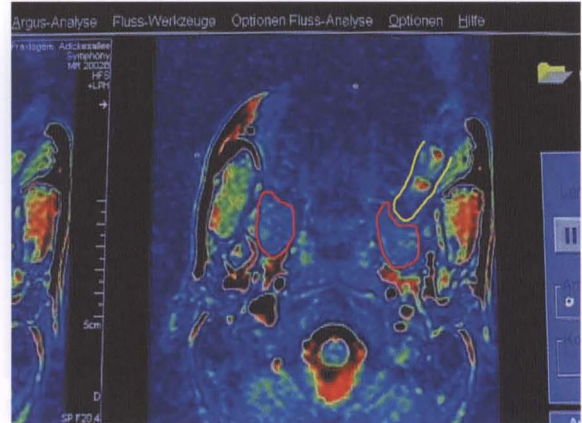


Fig. 13.27 Illustration of the access path on an MRI. Red: lateral pterygoid muscles. Yellow: palpating finger.

opening. The inferior head inserts onto the condylar process of the mandible. When acting alone, it displaces the lower jaw to the contralateral side (medial deviation). When the two inferior heads act together, they move the lower jaw anteriorly (protrusion).

The kinematics initiated by the lateral pterygoid muscle continue with the suprahyoid muscles. Recent studies (Schindler, 2004) have shown that the lateral pterygoid muscle is involved in almost all movements of the TMJ in one way or another.

The lateral pterygoid muscle is one of the muscles of the jaw that causes the most pain. As it was not clear whether this muscle could be palpated at all, we conducted our own study (Stelzenmüller et al., 2004) and proved for the first time that it is possible to palpate this muscle. This is necessary as this muscle can only be specifically treated when direct digital palpation of the quality of muscular tissue, the assessment of pain, and the following functional massage (opening and closing the mouth while palpating with the fingers) is possible. The inclusion criterion for the study was that patients must have healthy TMJs. The palpation was confirmed beyond doubt using MRI and EMG. The method for palpation was simulated on five anatomical specimens with differing dimensional relationships. Prerequisite for this palpation is that therapists are familiar with the exact palpatory method and have the necessary experience (Figs. 13.27, 13.28, 13.29).

Starting Position

The patient either lies on a treatment table in a relaxed position with the head slightly elevated or sits in a treatment chair. The therapist sits next to the patient's head on the side to be assessed.

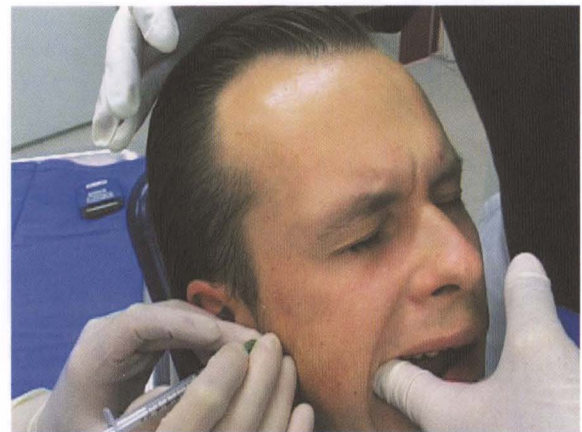


Fig. 13.28 Palpating the lateral pterygoid muscle with EMG monitoring.

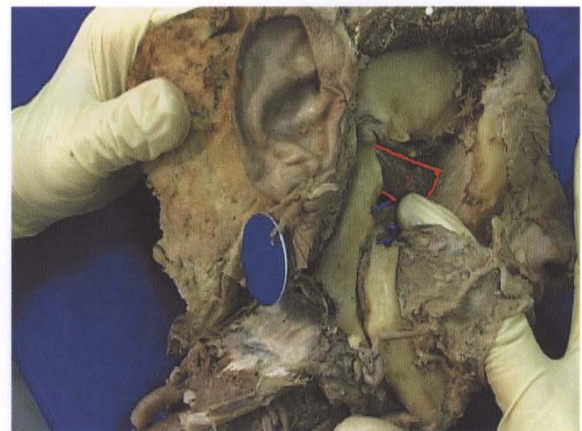


Fig. 13.29 Illustration of the access path on an anatomical specimen. Red outline: lateral pterygoid muscle. Blue outline: medial pterygoid muscle.

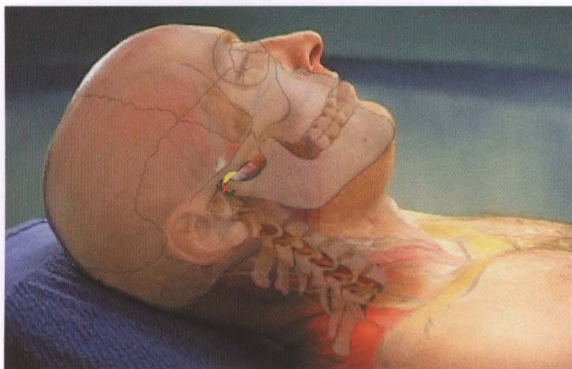


Fig. 13.30 Position of the lateral pterygoid muscle.

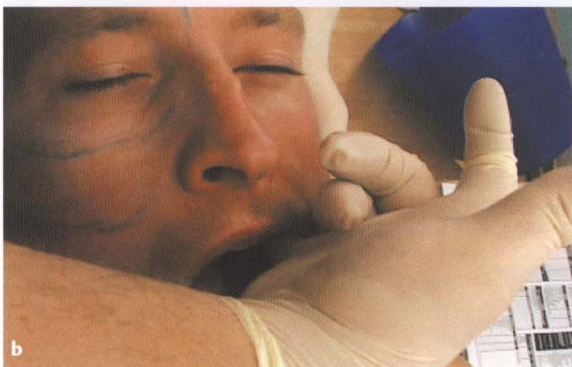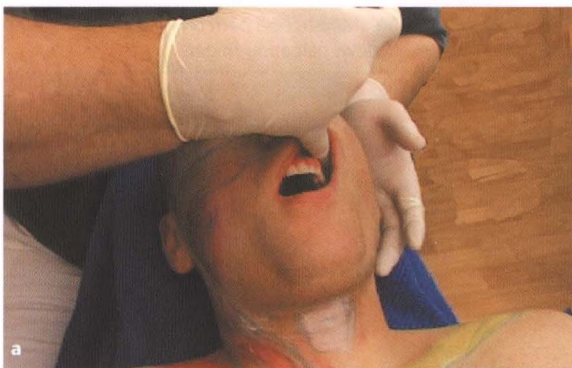


Fig. 13.31a, b The mandible is laterally deviated and the lateral pterygoid muscle then palpated intraorally. **a** The small finger moves parallel to the superior section of the alveolar process here and **b** then moves along the oral vestibule onto the maxillary tubercle, followed by the lateral plate of the pterygoid process.

Technique

The digital palpation of the lateral pterygoid muscle takes place intraorally in the cheek using either the small finger or the index finger. The patient deviates their mandible laterally (shifts the lower jaw sideways, away from the mid-line) toward the side to be assessed. The therapist's small finger or index finger then palpates along the oral vestibule parallel to the superior section of the alveolar

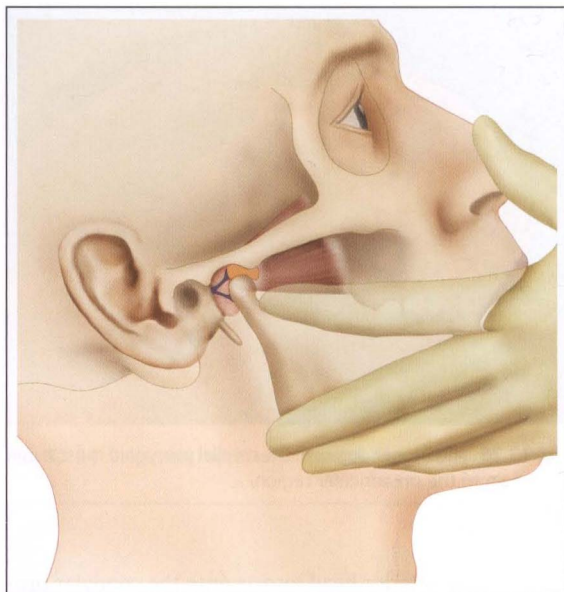


Fig. 13.32 Schematic illustration of the intraoral palpation of the lateral pterygoid muscle (orange: articular disk).

process of the maxilla, onto the maxillary tuberosity, and then further, until the lateral plate of the pterygoid process is reached. The palpation crosses over the superior section of the medial pterygoid muscle during this step. The final part of the palpation moves in a superomedial direction.

This muscle can also be tested isometrically outside the mouth. This test is not as informative as the digital palpation. To conduct this test, the patient is instructed to open their mouth slightly and then move their lower jaw to the side, for example, to the left. This movement is decelerated using submaximal resistance applied to the left side of the mandible. This tests the strength and presence of pain in the right lateral pterygoid muscle.

Up until the palpation of the lateral pterygoid muscle was proven, this technique was also used as treatment to relax the lateral pterygoid muscle using the contract-relax technique (Figs. 13.30, 13.31, 13.32).

Tips for Assessment and Treatment

Trigger points in the lateral pterygoid muscle refer pain to the jaw. This can be confused with arthrogenic problems and maxillary sinuses symptoms (Fig. 13.33).

Temporalis

The temporalis is divided into three segments: the anterior, medial, and posterior parts. The palpatory assessment of this muscle is essential due to its extensive size

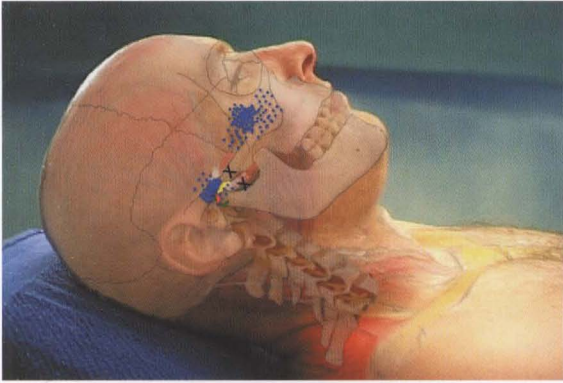


Fig. 13.33 Trigger points in the lateral pterygoid muscle cause referred pain in the jaw. This can be confused with arthrogenic problems and symptoms in the maxillary sinuses.

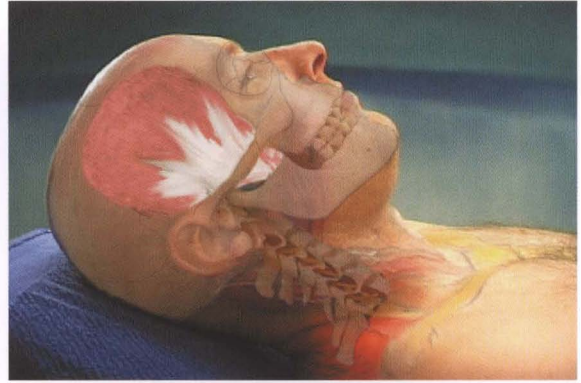


Fig. 13.34 Position of the temporalis.

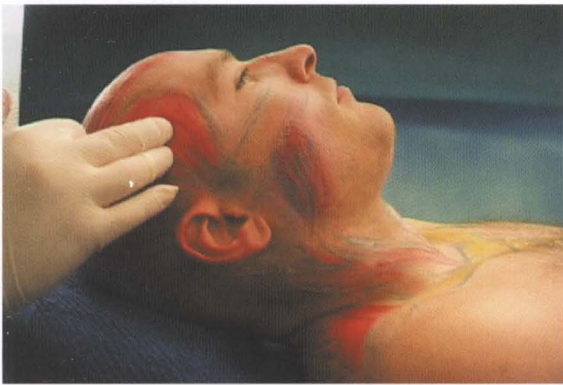


Fig. 13.35 The extraoral palpation starts in the anterior region of the temples.

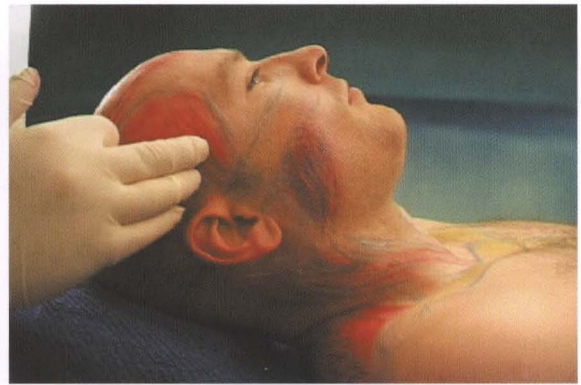


Fig. 13.36 Continuing to palpate the medial part of the temporalis muscle.

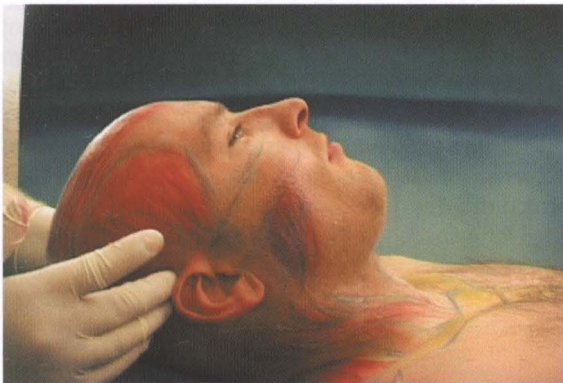


Fig. 13.37 Palpating the posterior part of the temporalis.

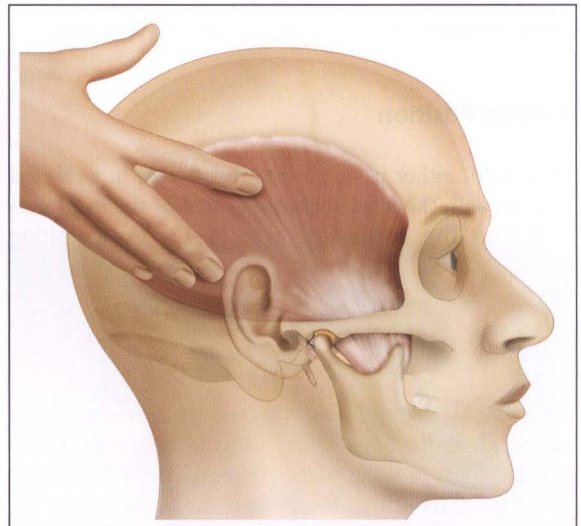


Fig. 13.38 Schematic illustration of the area of palpation for the temporalis.

and the different actions of the individual parts of the muscle and their referral of pain (Figs. 13.34, 13.35, 13.36, 13.37, 13.38, 13.39, 13.40, 13.41, 13.42). It originates on the temporal line of the squamous part of the temporal bone and the parietal bone. It inserts into the coronoid process of the mandible. When both temporalis muscles are active, they produce approximately 45% of mouth closure. The posterior section of the mandible

moves posterosuperiorly at the coronoid process during this. The anterior parts contribute to protrusion and opening of the mouth.

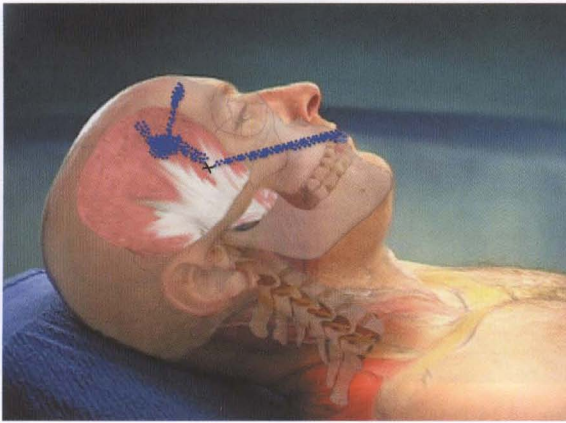


Fig. 13.39 The trigger points in the anterior part of the temporalis refer pain to the upper front teeth.

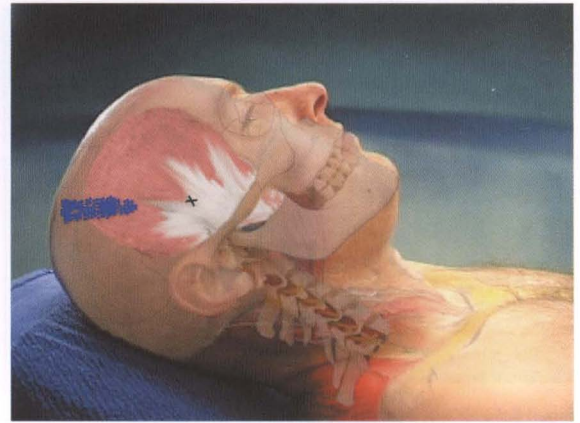


Fig. 13.41 Myofascial pain originating in the medial part of temporalis can radiate into the middle region of the parietal bone.

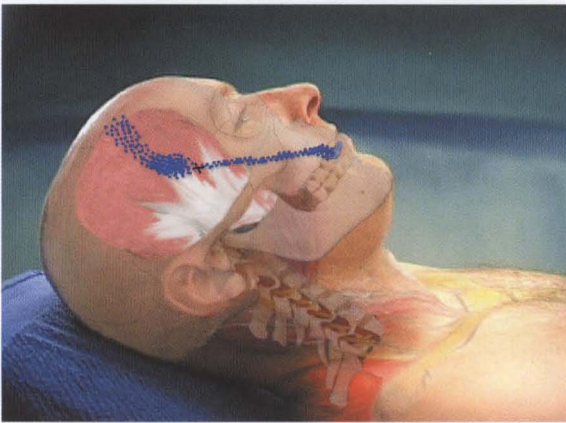


Fig. 13.40 The trigger points in the medial part of the temporalis radiate symptoms into the canine teeth and the premolars.

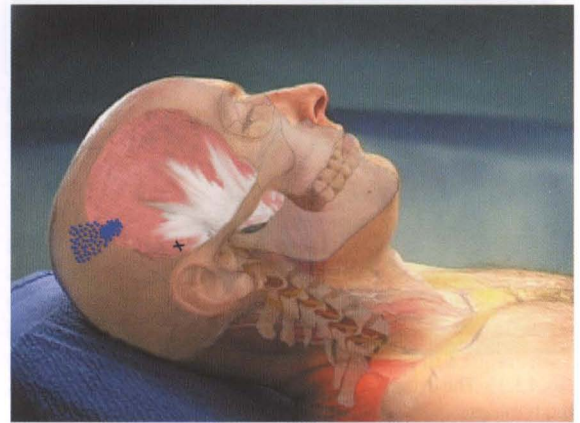


Fig. 13.42 Myofascial pain originating in the posterior part can be referred onto the parietal bone.

Starting Position

The patient either lies on a treatment table in a relaxed position with the head slightly elevated or sits in a treatment chair. The therapist sits at an 11–12 o'clock position at the head end of the patient.

Technique

The extraoral palpation starts in the anterior region of the temples. The therapist starts palpating with moderate pressure perpendicular to the course of fibers. The palpation of the anterior part begins on the temporal line of the temporal squamous part of the parietal bone. The therapist palpates this part of the muscle from anterior to posterior, then continues toward the muscle's insertion at the zygomatic arch. This method is especially necessary to localize trigger and/or tender points in the different parts of the muscle segments. The medial and posterior segments are palpated in a similar manner.

It can be helpful when the patient is instructed to briefly open the mouth or press the teeth together during palpation to facilitate differentiation of the individual structures. The index, middle, or ring fingers can be used for palpation in the temple region of the patient.

Anterior and Posterior Bellies of the Digastric

The posterior belly of the digastric originates on the mastoid notch of the temporal bone and, together with the anterior belly, is connected to the lesser horn of the hyoid bone via the intermediate tendon. The anterior belly inserts into the digastric fossa.

One of the most important actions of the digastric is to raise the hyoid bone during swallowing. It also helps to open the mouth.

Tip: The therapist should always assess the floor of the mouth for pain and/or changes at specific intervals in all patients suffering from head/jaw symptoms. The motor activity in the

tongue is assessed by instructing the patient to place the tip of their tongue on their nose, on the point of the chin, and to move the tongue as far as possible to the left and to the right. If these motor function tests demonstrate differences between the sides, further examination of the floor of the mouth and the tongue region should be performed by dentists, oral surgeons, oral and maxillofacial surgeons, or neurologists. These deviations may simply be due to a lack of body awareness or may be caused by changes in the floor of the mouth, for example, an ulcer in the mouth (aphthous ulcer), swelling in the lymph nodes, a stone in the salivary gland (sialolith), tumors, organic processes arising in the brain, etc. The complete floor of the mouth is therefore palpated (taking care that only minimal pressure is applied intraorally as this region is very sensitive to pain).

Starting Position

The patient either lies on a treatment table in a relaxed position with the head slightly elevated or sits in a treatment chair. The therapist sits next to the patient's head on the side to be assessed.

Technique (Intraoral)

The middle or index finger is used to palpate sublingually (underneath the tongue) in the floor of the patient's mouth. The therapist's intraoral finger pushes the anterior belly of the digastric lightly into the floor of the mouth and the muscle can now be easily palpated intraorally and extraorally.

To better differentiate the anterior belly of the digastric from the other suprahyoid muscles in the floor of the mouth, it has proven useful to oppose mouth opening with slight resistance applied to the point of the chin. The V-form of the anterior belly of the digastric then becomes distinct as it travels to the point of the chin.

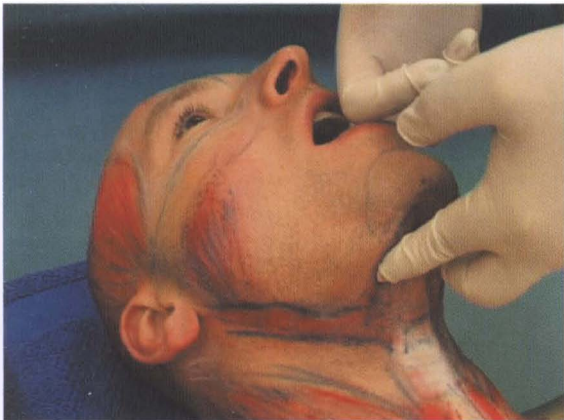


Fig. 13.43 Intraoral palpation of the anterior belly of the digastric.

Technique (Extraoral)

The extraoral technique used to palpate the posterior belly of the digastric is an alternative to the intraoral procedure. The therapist grasps around the angle of the mandible and palpates the soft tissue posterior to the ramus of the mandible.

The posterior belly of the digastric can be felt in the soft tissue as the hand grasps around the angle of the mandible and gentle pressure is applied posterior to the ramus of the mandible.

Ideally the patient is asked to briefly swallow during the palpation. The posterior belly of the digastric then slides directly against the palpating finger. The intraoral treatment of the anterior belly of the digastric should take priority (Figs. 13.43, 13.44, 13.45, 13.46).

Tip: Suprahyoid muscles: the suprahyoid muscles include the digastric, as well as stylohyoid, mylohyoid, and geniohyoid. Geniohyoid, mylohyoid, and the anterior belly of the digastric help to form the floor of the mouth. The suprahyoid muscles are involved in mastication and swallowing as well as articulation when speaking and singing. When the mandible is fixed, the mylohyoid can elevate the base of the tongue, pushing it against the roof of the mouth. The hyoid bone and the larynx are then pulled anterosuperiorly. When the infrahyoid muscles fix the hyoid bone, the mylohyoids participate in mouth opening and the sideways movement of the mandible (Raubert and Kopsch, 1987).

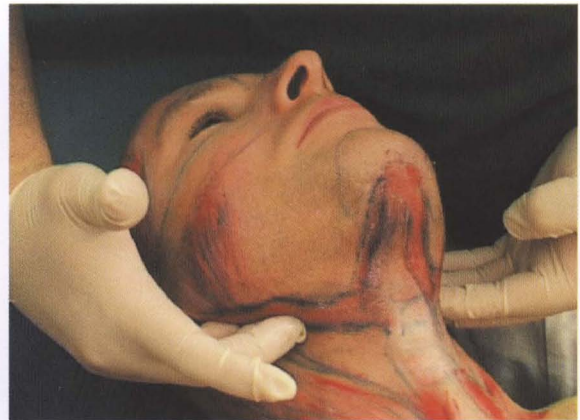


Fig. 13.44 Extraoral palpation of the posterior belly of the digastric.

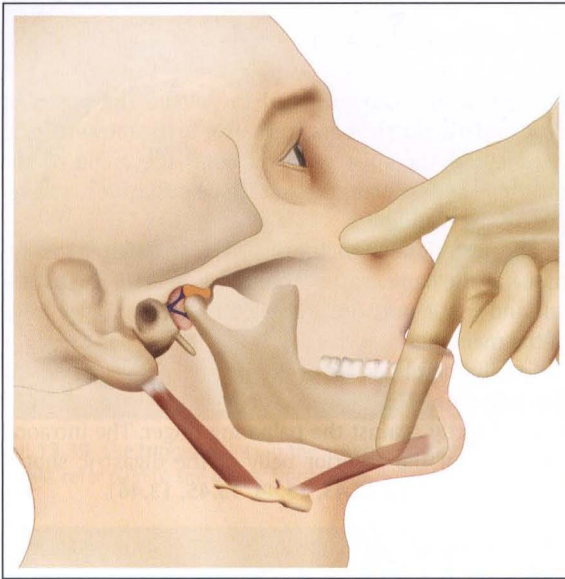


Fig. 13.45 Schematic illustration of the intraoral palpation of the anterior belly of the digastric.

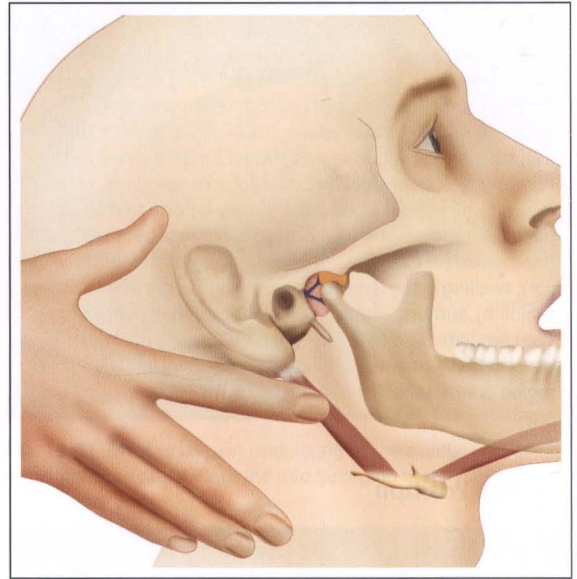


Fig. 13.46 Schematic illustration of the extraoral palpation of the posterior belly of the digastric.

Study Questions

1. The skull is divided into 11 regions. What are their names?
2. Name the pressure points of the trigeminal nerve.
3. Which bony structures form the jaw together with the articular disk?
4. Why is it wise to wear gloves and a mask when palpating the TMJ intraorally?
5. Which muscle originates on the zygomatic arch, extends over a large area, and inserts into the masseteric tuberosity on the angle of the mandible?
6. What are the main muscles involved in the closure of the mouth?
7. Which muscle initiates mouth opening?
8. What is the digastric's most important action?

THIS PAGE INTENTIONALLY
LEFT BLANK

Bibliography

- Aland RC, Kippers V. Addressing interindividual variation within a science dissection-based anatomy course. Department of Anatomy & Developmental Biology, School of Biomedical Sciences, The University of Queensland, Australia, 2005. Available at: http://www.anzaca.co.nz/ANZACA05/ANZACA05_abstracts.pdf. Accessed October 6, 2009
- Barker PJ, Guggenheimer KT, Grkovic I, et al. Effects of tensioning the lumbar fasciae on segmental stiffness during flexion and extension: Young Investigator Award winner. *Spine (Phila Pa 1976)* 2006;31(4):397–405
- Bjordal JM, Couppé C, Chow RT, Tunér J, Ljunggren EA. A systematic review of low level laser therapy with location-specific doses for pain from chronic joint disorders. *Aust J Physiother* 2003;49(2):107–116
- Bogduk N. *Klinische Anatomie von Lendenwirbelsäule und Sakrum*. Berlin: Springer; 2000
- Brooke R. The sacro-iliac joint. *J Anat* 1924;58(Pt 4):299–305
- Bumann A, Lotzmann U. *Funktionsdiagnostik und Therapieprinzipien*. Farbatlanten der Zahnmedizin, Vol 12. Stuttgart: Thieme; 2000
- Butler D, Moseley L. *Explain Pain*. Minneapolis: Orthopedic Physical Therapy Products; 2003
- Chaitow L. *Palpationstechniken und Diagnostik*. Munich: Urban & Fischer; 2001
- Dautzenroth A. *Cystische Fibrose*. Stuttgart: Thieme; 2002
- Diethelm M. Brustschmerz—nicht vom Herz. *Schweiz Med Forum* 2005;5:51–58
- Disla E, Rhim HR, Reddy A, Karten I, Taranta A. Costochondritis. A prospective analysis in an emergency department setting. *Arch Intern Med* 1994;154(21):2466–2469
- Dörhage K, Knopf H, Graumann-Brunt S, Koch SE. Asymmetrie der Kopfgelenke: Physiologische Lateralität. *Manuelle Medizin*. 2004;42(2):122–128
- Dreyfuss P, Michaelsen M, Fletcher D. Atlanto-occipital and lateral atlanto-axial joint pain patterns. *Spine (Phila Pa 1976)* 1994;19(10):1125–1131
- Dunn T, Heller CA, McCarthy SW, Dos Remedios C. Anatomical study of the “trochanteric bursa”. *Clin Anat* 2003;16(3):233–240
- Dvořák J, Dvořák V, Gilliar W, Schneider W, Spring H, Tritschler T. *Musculoskeletal Manual Medicine. Diagnosis and Treatment 5th ed.*, Stuttgart–New York: Thieme; 2008
- Edel H. *Atemtherapie*. 6th ed. Munich: Urban & Fischer; 1999
- Ehrenberg H. *Atemtherapie in der Physiotherapie/ Krankengymnastik*. Munich: Pflaum; 1998
- Falla DL, Jull GA, Hodges PW. Patients with neck pain demonstrate reduced electromyographic activity of the deep cervical flexor muscles during performance of the craniocervical flexion test. *Spine (Phila Pa 1976)* 2004;29(19):2108–2114
- Freemeyer WB. *Zahnärztliche Funktionstherapie*. Munich: Hanser; 1993
- Freeston J, Karim Z, Lindsay K, Gough A. Can early diagnosis and management of costochondritis reduce acute chest pain admissions? *J Rheumatol* 2004;31(11):2269–2271
- Frisch H. *Programmierte Therapie am Bewegungsapparat*. Berlin: Springer; 1995a
- Frisch H. *Programmierte Untersuchung des Bewegungsapparates*. 6th ed. Berlin: Springer; 1995b
- Gifford L. *Topical Issues in Pain Vol. 5: Treatment, Communication, Return to Work, Cognitive Behavioural Pathophysiology*. CNS Press [online] 2006. Available at: <http://www.achesandpainonline.com/cnspress.php>. Accessed October 20, 2009
- Goode A, Hegedus EJ, Sizer P, Brismee JM, Linberg A, Cook CE. Three-Dimensional Movements of the Sacroiliac Joint: A Systematic Review of the Literature and Assessment of Clinical Utility. *The Journal of Manual & Manipulative Therapy*. 2008;16(1):25–38
- Gracovetsky S. *The spinal engine*. Berlin: Springer; 1988. Available at <http://www.somatics.de/Gracovetsky/Interview.pdf>. Accessed October 17, 2009
- Greiner P. *Die Frankfurter Horizontale. Eine anatomisch-röntgenkephalometrische Untersuchung zur Lageveränderung von Porion und Orbita während des Wachstums*. Marburg: Univ. Diss. 2000. Available at http://www.med.uni-marburg.de/stpg/ukm/ob/kieferorthopaedie/abstract_greiner.htm. Accessed October 19, 2009
- Hansson TL, Honée W, Hesse J. *Funktionsstörungen im Kausystem*. 2nd ed. Heidelberg: Hüthig; 1990
- Hansson TL, Christensen Minor CA, Wagnon Taylor DL. *Physiotherapie bei craniomandibulären Funktionsstörungen*. Berlin: Quintessenz; 1993
- Hecker U, Steveling A, Peuker E, Kastner J, Liebchen K. *Color Atlas of Acupuncture. Body Points, Ear Points, Trigger Points*. 2nd ed. Stuttgart–New York: Thieme; 2008
- Hempfen CH, Wortman Chow V. *Pocket Atlas of Acupuncture*. Stuttgart–New York: Thieme; 2006
- Herdman SJ. *Vestibular Rehabilitation*. 2nd ed. Philadelphia: FA Davis; 2000
- Hesse JR. *Craniomandibular Border Characteristics and Orotacial Pain. A Clinical and Experimental Investigation*. Amsterdam: Ridderprint Offsedrukkereij b. v., Ridderkerk; 1996
- Hochschild J. *Funktionelle Anatomie—Therapierelevante Details*. Vol 1. Stuttgart: Thieme; 1998
- Hochschild J. *Funktionelle Anatomie—Therapierelevante Details*. Vol 2. Stuttgart: Thieme; 2001

- Hoppenfeld S. Klinische Untersuchung der Wirbelsäule und Extremitäten. 2nd ed. Stuttgart: Fischer; 1992
- Jerosch J, Steinleitner W, eds. Minimalinvasive Wirbelsäulen-Intervention. Aktuelle und innovative Verfahren für Praxis und Klinik. Cologne: Dt. Ärzteverlag; 2005
- Kapandji IA. Funktionelle Anatomie der Gelenke. Vol 3, 5th ed. Stuttgart: Enke; 1985
- Kapandji IA. Funktionelle Anatomie der Gelenke. 4th ed. Stuttgart: Thieme; 2006
- Kares H, Schindler H, Schöttl R. Der etwas andere Kopf- und Gesichtsschmerz. International College of CMD—Sektion Deutschland (ICCMD-Deutschland ICCHO), 2001
- Kieser JA, Groeneveld HT. Relationship between juvenile bruxing and craniomandibular dysfunction. *J Oral Rehabil* 1998;25(9):662–665
- Klein-Vogelbach S. Funktionelle Bewegungslehre. Rehabilitation und Prävention. Vol 1. Berlin: Springer; 2000
- Kraemer J. Intervertebral Disk Diseases. Causes, Diagnosis, Treatment, and Prophylaxis. 3rd ed. Stuttgart–New York: Thieme; 2009
- Kubik S. Anatomie der Lumbalregion und des Beckens. Fortbildungskurse für Rheumatologie. Vol 6. Basel: Karger; 1981:1–29
- Lanz T von, Wachsmuth W. Praktische Anatomie, Part 1B, Kopf–Gehirn- und Augenschädel. Berlin: Springer; 1979.
- Lanz T von, Wachsmuth W. Praktische Anatomie, Rücken. Berlin: Springer; 1982
- Lanz T von, Wachsmuth W. Praktische Anatomie, Part 1A, Kopf–Übergeordnete Systeme. Berlin: Springer; 1985
- Lanz T von, Wachsmuth W. Praktische Anatomie, Rücken. Berlin: Springer; 2004a
- Lanz T von, Wachsmuth W. Praktische Anatomie, Part 1A, Kopf–Übergeordnete Systeme. Berlin: Springer; 2004b.
- Lanz T von, Wachsmuth W. Praktische Anatomie, Part 1B, Kopf–Gehirn- und Augenschädel. Berlin: Springer; 2004c
- Lanz T von, Wachsmuth W. Praktische Anatomie, Bein und Statik. Berlin: Springer; 2004d
- Lysell E. Motion in the cervical spine. An experimental study on autopsy specimens. *Acta Orthop Scand* 1969;123, 1
- Marx G. Über die Zusammenarbeit mit der Kieferorthopädie und Zahnheilkunde in der manuellen Medizin. *Manuelle Med.* 2000;38:342–345
- Mercer SR, Cullen B, Lau P, Govind J, Bogduk N. Anatomy in Practice: Palpation of Piriformis. Abstract Booklet. Australian Association of Anatomy and Clinical Anatomy. Department of Anatomy and Cell Biology. University of Melbourne; 2004
- Mooney V, Pozos R, Vleeming A, Gulick J, Swenski D. Exercise treatment for sacroiliac pain. *Orthopedics* 2001;24(1):29–32
- Netter FH. Atlas of Human Anatomy. 3rd ed. Teterboro, New Jersey: Icon Learning Systems; 2004
- Niethard FU, Pfeil J. Duale Reihe “Orthopädie.” 4th ed. Stuttgart: Thieme; 2003
- Okeson JP. Bell’s Orofacial Pains. 5th ed. Berlin: Quintessenz; 1995
- Okeson JP. Orofacial Pain. Guidelines for Assessment, Diagnosis, and Management. Berlin: Quintessenz; 1996
- Pauling C. Skriptum zur Atemtherapie, VPT Akademie—staatl. aner. Massage-/Physiotherapeuten-Schule. Fellbach.
- Penning L. Hals- und Lendenwirbelsäule. Munich: Pflaum; 2000
- Pool-Goudzwaard AL, Kleinrensink GJ, Snijders CJ, Entius C, Stoeckart R. The sacroiliac part of the iliolumbar ligament. *J Anat* 2001;199(Pt 4):457–463
- Pool-Goudzwaard AL, Hoek van Dijke G, Mulder P, Spoor C, Snijders C, Stoeckart R. The iliolumbar ligament: its influence on stability of the sacroiliac joint. *Clin Biomech (Bristol, Avon)* 2003;18(2):99–105
- Rauber A, Kopsch F, eds. Anatomie des Menschen. Vol 1, Anatomie des Bewegungsapparates. 3rd ed. Stuttgart: Thieme; 2003
- Reichel HS. Personal communication: Lehrgruppe Manuelle Therapie der VPT Akademie Fort- und Weiterbildungs GmbH, Fellbach
- Richardson C, Jull G, Hodges PW, Hides JA. Therapeutic Exercise for Spinal Segmental Stabilisation in Low Back Pain. Edinburgh: Churchill Livingstone; 1999
- Richter P, Hebgen E. Trigger Points and Muscle Chains in Osteopathy. Stuttgart–New York: Thieme; 2009
- Rocabado M. Biomechanical relationship of the cranial, cervical, and hyoid regions. *J Craniomandibular Pract* 1983;1(3):61–66
- Sashin D. A critical analysis of the anatomy and the pathological changes of the sacroiliac joints. *J Bone Joint Surg.* 1930;12:891–910
- Schindler HJ. Lecture at the 37th Annual Convention of the Working Group for Function Diagnostics and Therapy (AFDT) [In German]. Bad Homburg; November 2004
- Schünke M. Topographie und Funktion des Bewegungssystems. Stuttgart: Thieme; 2000
- Schünke M, Schulte E, Schuhmacher U. Prometheus series, Thieme Atlas of Anatomy, General Anatomy and Musculoskeletal System. Stuttgart: Thieme; 2005
- Stelzenmüller W, Wiesner J. Therapie von Kiefergelenkschmerzen—Ein Behandlungskonzept für Zahnärzte, Kieferorthopäden und Physiotherapeuten. 2nd ed. Stuttgart: Thieme; 2004
- Stelzenmüller W, Weber D, Özkan V, Umstadt H. Is the lateral pterygoid muscle palpable? A pilot study for determining the possibilities of palpating the lateral pterygoid muscle. Best awarded poster presentation. AFDT der DGZMK (Deutsche Gesellschaft für Zahn-, Mund- und Kieferheilkunde). November 28, 2004. *Int. Poster J Dent Oral med.* 2006;8(1):301. Available at: <http://ipj.quintessenz.de>. Accessed October 20, 2009
- Stewart TD. Pathologic changes in aging sacroiliac joints. A study of dissecting-room skeletons. *Clin Orthop Relat Res* 1984;183(183):188–196
- Theodoridis T, Kraemer J. Spinal Injection Techniques. Stuttgart–New York: Thieme; 2009

- Tillmann B. Farbatlas der Anatomie, Zahnmedizin—Humanmedizin. Stuttgart: Thieme; 1997
- Tillmann B, Töndury G. Bewegungsapparat. In: A Rauber, F Kopsch (eds). Anatomie des Menschen. Vol 1. 2nd ed. Stuttgart: Thieme; 1998
- Tittel K. Beschreibende und funktionelle Anatomie des Menschen. 11th ed. Stuttgart: Fischer; 1989
- Tixa S. Atlas d'anatomie palpatoire du membre inférieur. Paris: Masson; 1997
- Tixa S. Atlas der Palpationsanatomie. Stuttgart: Hippokrates; 2002
- Travell JG, Simons DG. Myofacial Pain and Dysfunction. The Trigger Point Manual. Baltimore: Williams & Wilkins; 1983
- Travell JG, Simons DG. Myofascial Pain and Dysfunction, The Trigger Point Manual. Vol 2, The Lower Extremities. Baltimore: Williams & Wilkins; 1998
- Valerius KP, Frank A, Kolster BC, Hirsch MC, Hamilton C, Lafont EA. Das Muskelbuch. Stuttgart: Hippokrates; 2002
- Van den Berg F, ed. Angewandte Physiologie, Vol 4: Schmerzen verstehen und beeinflussen. Stuttgart: Thieme; 2003
- Wingerden JP van, Vleeming A, Buyruk HM, Raissadat K. Stabilization of the sacroiliac joint in vivo: verification of muscular contribution to force closure of the pelvis. *Eur Spine J* 2004;13(3):199–205
- Vleeming A, Pool-Goudzwaard AL, Stoeckart R, van Wingerden JP, Snijders CJ. The posterior layer of the thoracolumbar fascia. Its function in load transfer from spine to legs. *Spine (Phila Pa 1976)* 1995;20(7):753–758
- Vleeming A, Pool-Goudzwaard AL, Hammudoghlu D, Stoeckart R, Snijders CJ, Mens JM. The function of the long dorsal sacroiliac ligament: its implication for understanding low back pain. *Spine (Phila Pa 1976)* 1996;21(5):556–562
- White AA, Pandjabi MM. Clinical Biomechanics of the Spine. 2nd ed. Philadelphia: Lippincott; 1990
- Winkel D. Das Sakroiliakalgelenk. Stuttgart: Urban & Fischer; 1992
- Winkel D, Vleeming A, Meijer OG. Nicht operative Orthopädie und Manualtherapie, Part 4/2. Stuttgart: Urban & Fischer; 1993
- Winkel D, Aufdemkampe G, Matthijs O, Meijer OG, Phelps V. Diagnosis and Treatment of the Spine: Nonoperative Orthopedic Medicine and Manual Therapy. New York: Aspen Publishers; 1996
- Winkel D, Matthijs O, Phelps V, Vleeming A. Diagnosis and Treatment of the Upper Extremities: Nonoperative Orthopedic Medicine and Manual Therapy. New York: Aspen Publishers; 1997
- Winkel D. Nicht operative Orthopädie und Manualtherapie, Anatomie in Vivo. 3rd ed. Munich: Urban & Fischer; 2004
- Wise CM, Semble EL, Dalton CB. Musculoskeletal chest wall syndromes in patients with noncardiac chest pain: a study of 100 patients. *Arch Phys Med Rehabil* 1992;73(2):147–149
- Wittenberg RH, Willburger RE, Krämer J. [Spondylolysis and spondylolisthesis. Diagnosis and therapy]. *Orthopäde* 1998;27(1):51–63
- Yamamoto I, Panjabi MM, Oxland TR, Crisco JJ. The role of the iliolumbar ligament in the lumbosacral junction. *Spine (Phila Pa 1976)* 1990;15(11):1138–1141
- Zahnd F. Einführung in manuelle Techniken: Oberflächen- und Röntgenanatomie, Palpation und Weichteiltechniken. Stuttgart: Thieme; 1988

THIS PAGE INTENTIONALLY
LEFT BLANK

Index

Page numbers in *italics* refer to illustrations and tables

A

abdominal muscles 212
 abductor pollicis longus 76, 80, 81
 Achilles tendon 152, 175, 175, 176
 borders of 175–176, 176
 acromial angle 20, 24, 25, 33
 acromioclavicular (AC) joint 20, 31–34, 31, 32, 33
 anterior approach 30
 joint capsule 32, 33
 posterior approach 30–31, 30, 31
 acromion 19, 20, 24, 25
 lateral edge 29–30, 29, 30, 33
 spine 20, 29–30, 33
 adductor longus 105, 113, 114, 116, 116, 121
 proximal insertion 115
 adductor magnus tendon 133, 133
 adductor tubercle 132
 anatomical snuffbox 80, 85–86
 anconeus 48, 61
 ankle joint 171
 joint space 170
 ankylosing spondylitis 303
 anteroposterior segmental joint play 266–267, 266
 annulus fibrosus 242
 arcuate line 206
 arteries, palpation 13, 13
 see also specific arteries
 arthritis
 foot 152
 hand 72
 tibiofibular joint 144
 articular disc 372, 372, 375
 atlantooccipital joint 369
 atlas 282
 axial traction 299–300, 300
 axis 282

B

ballotable patella 124
 basilic vein 51
 biceps brachii 48, 51, 51
 biceps femoris 106, 121, 123, 141, 142, 142, 145, 146
 biceps tendon 51
 bicipital aponeurosis 51, 52

blood vessels, palpation 13, 13
 see also specific vessels
 bony edges, palpation 7–8, 8
 bony prominences, palpation 8, 8
 brachial artery 51, 51, 52, 52
 brachialis 48
 brachioradialis 48, 51, 53, 53, 62–63
 bursae, palpation 11–12, 12
 bursitis
 knee 129
 pelvic 205

C

calcaneocuboid (CC) joint 165–166, 166
 test of joint play 170, 170
 calcaneofibular ligament 153, 167, 168, 168
 calcaneonavicular ligament, plantar 153, 157
 calcaneus 153, 165
 capitate 74, 78, 85, 87–88, 87, 88
 capitulum 48, 59
 capsules, palpation 11, 11
 carpal ligament, transverse 74, 76, 95, 97–98, 99
 carpal tunnel 74–75, 74, 76, 97–98, 97, 99
 carpal tunnel syndrome 73
 carpometacarpal joint 86, 87
 joint line 78–79
 joint space 86
 carpus 73, 74
 distal boundary 78–79, 79
 proximal boundary 77–78, 77, 79
 central column of the hand 73, 74, 87–88
 cephalic vein 83
 cervical rotation 287
 cervical spine 243
 cervical spinous processes
 see spinous processes
 cervicothoracic junction palpation
 prone starting position 292–294, 293–294
 sitting starting position 285–292, 285–292
 chest percussion 308, 308
 clavicle 20, 281
 anterior border 31, 31

 medial end 35–36, 36
 posterior border 30, 30, 31
 coccygeal cornu 209
 collateral ligament, lateral 123, 141–142, 141, 142, 143, 143, 144
 medial 133–134, 134, 137, 137
 contact breathing 308, 308
 coracoid process 20, 36–37, 37, 38
 borders 38, 38
 exercises 39
 costal facet *see facet joints*
 costochondritis 304
 costosternal joints 280
 swelling 304
 costotransverse joint 280, 294
 traction 302
 costovertebral joints 191, 192, 274
 assessment 300
 mechanics 280–281, 280, 281
 mobilization 309
 treatment 302, 302
 coxal bone 206, 207, 207
 craniomandibular dysfunction (CMD) 369
 cubital fossa 49, 49
 cubital tunnel 55, 55
 cubital tunnel syndrome 59
 cuboid 153, 167
 dimensions 167
 cuneiforms 153

D

dancing patella test 124
 deltoid ligament 153, 157
 digastric 382–383, 383, 384
 extraoral technique 383, 383, 384
 intraoral technique 383, 383, 384
 discus articularis ulnae 74
 dorsalis pedis artery 172, 172

E

effusion, knee 123–125
 large 124, 124
 medium 124, 124
 minimal 124–125, 125
 elbow complex 47
 anatomy 47–49, 48, 49, 59
 joint capsule 66
 orientation, anterior 49

palpation, anterior 49–53
 lateral 59–65
 medial 54–59
 treatment applications 47
 epicondylitis
 treatment 57–58, 57
 types of 57
 erector spinae 184, 251, 255, 256
 experience 6
 extensor carpi radialis brevis 48, 62,
 63–64, 63, 76
 longus 48, 62, 63, 63, 76
 extensor carpi ulnaris 48, 62, 64–65,
 64, 74, 76, 82
 extensor digiti minimi 76, 82, 82
 extensor digitorum 48, 62, 64, 64, 76,
 82
 longus 153
 extensor hallucis longus 153
 extensor indicis 76, 81
 extensor pollicis brevis 76, 80, 81
 longus 76, 81
 extrinsic back muscles 283–284,
 283

F

facet joints 278
 inferior costal facet 277
 superior costal facet 277
 transverse costal facet 277
 facet tropism 247, 247
 fasciae
 tension in 9
 thickness of 9
 femoral artery 105, 114–115, 115
 femoral neck anteversion (FNA)
 angle 104, 104
 measurement 107–108, 107, 234,
 234
 femoral nerve 105, 114–115, 115
 femoral triangle
 lateral 105, 105, 110, 110, 111,
 112
 medial 105, 105, 113, 113
 femoral vein 105, 114–115
 femorotibial joint 122–123, 122,
 123
 femur 122
 condyle, lateral 139, 139
 medial 131–132, 131, 132
 epicondyle, lateral 122, 141,
 141
 medial 122, 132, 132
 fibula 122
 head 122, 123, 141, 141
 finger rule 278, 278, 295–296, 295

finger/thumb opposition 71–72, 71
 first metatarsal 159
 flexor carpi radialis 48, 55, 58, 58, 76,
 91, 92, 92, 96, 97
 flexor carpi ulnaris 48, 55, 58, 58, 92,
 93–94, 93
 flexor digitorum longus 153, 158,
 158
 profundus 75, 75, 76
 superficialis 58, 75, 75, 76, 93
 flexor hallucis longus 153, 158,
 158
 flexor pollicis longus 75, 76, 91, 92
 foot 151–152
 anatomy 152–153, 153
 biomechanics 151–152
 joint spaces 159–162, 159–162
 palpation, posterior 175–178
 dorsum 170–175
 ulnar border 162–170
 symptoms 152
 forearm orientation 58–59, 58
 frontal bone 370, 370

G

gastrocnemius 121
 genu vasculosum 372, 375
 Gerdy tubercle 122, 140, 140
 glenohumeral (GH) joint 19
 glenoid cavity 41–42, 41
 gluteal muscles 184, 205
 gluteal nerve, inferior 231, 233
 superior 231, 232–233, 233
 gluteus maximus 108, 212,
 217–220, 220, 250
 area of origin 218, 219, 219
 lateral edge 219–220, 219, 220
 medial edge 219
 muscle belly 217–219, 218
 gluteus medius 217, 220, 220, 255
 gluteus minimus 255
 golfer's elbow 57, 59
 gracilis 116, 116, 123, 135, 147,
 147
 greater trochanter 104, 106–107,
 107, 184, 214, 215–216, 215, 216,
 233, 233
 gap between pelvis and greater
 trochanter 235–236, 235
 insertions 234–235, 235
 groin 103
 treatment applications 103
see also hip; pelvis
 guiding structures 13–14, 14
 Guyon canal 93, 94, 95

H

hamate 74, 85, 89, 90, 90
 hook of 74, 93, 95, 96, 96, 97
 hamstring muscles 106, 108–109,
 108, 109
 head 236, 236
 hand 71, 71
 anatomy 73–75, 73–76
 functional diversity 71–72
 muscular control 72, 72
 orientation, dorsal 76–79
 palmar 90–91
 palpation
 dorsal 79–90
 carpal bones 84–90
 soft tissues 79–84
 palmar 91–99
 carpal bones 94–99
 soft tissues 91–94
 treatment applications 72–73
 handlebar palsy 94
 head 369
 regions 370, 370
 heel spur 152
 Helkimo index 374
 hemisacralization 244
 hip 103
 anatomy 103–106, 104–106
 palpation, anterior 109–116
 posterior 106–109
 treatment applications 103
 'hold-grasp' technique 307, 307
 humeroradial joint (HRJ) 47
 joint space 61, 61
 humeroulnar joint (HUJ) 47, 59
 humerus 48, 59
 condyle, lateral 60–61, 60
 epicondyle, lateral 48, 59, 60
 medial 48, 55–56, 55, 56
 greater tubercle 19, 20, 40–41
 head 19, 20
 lateral border 60, 60
 lesser tubercle 20, 39, 39
 medial shaft 50–51, 50, 54, 54
 posterior 65–67
 hyperalgesia 185
 hyperesthesia 185
 hypermobility, foot 152

I

iliac crest 104, 184, 206, 206, 214–215,
 214, 215, 221, 222, 223, 251
 posterior sacroiliac spine
 connection 259, 259

- iliac spine
 anterior inferior 104
 anterior superior (ASIS) 104, 110, 114, 114, 206, 206
 posterior inferior (PIIS) 229, 229
 posterior superior (PSIS) 221, 222–224, 222, 223, 224
- iliocostalis lumborum 254, 255
- iliolumbar ligaments 212, 250, 250
- iliopectineal bursa 114
- iliopsoas 114
- iliotibial band friction syndrome 143–144
- iliotibial tract 123, 139–140, 140, 141, 220–221, 220
- ilium 211
 ala 203
 see also sacroiliac (SI) joint
- in vivo anatomy 3
 applications 3–4
 see also specific body regions
- incisal edge distance (IED) 374
- inferolateral angles of the sacrum 227–228, 227
- infraclavicular fossa 34, 34, 36, 37, 38
- infraspinalis muscle 27–28, 27, 28
- inguinal ligament 105, 113, 114, 114
- instability
 foot 152
 hand 72
- intercostal palpation
 during respiration 304–305, 305
 with arm elevation 305–306, 305, 306
- intercostal spaces 300–301, 304–305, 305
- intercostal stroking 307, 307
- intermuscular septum of the arm,
 lateral 60
 medial 55, 55
- interosseus ligaments 209–210, 212
- interspinalis lumborum 246, 253
- interspinous ligaments 249, 249
- interspinous spaces 266, 266, 295
- intertransversarii, medial 253
- intertransverse ligaments 249
- intertubercular sulcus 40–41, 40
- intervertebral disks 242, 274–275
 degeneration 242–243, 243
 lumbar 244–245, 244
 prolapse 242, 242
 thoracic 276
- intrinsic back muscles
 lateral tract 254–255
 medial tract 253–254, 253
 thoracic 282–283, 282, 283
- ischial tuberosity 104, 108, 108, 184, 206, 214, 217, 217, 233, 236, 236
- J**
- jaw 369
 see also temporomandibular joint (TMJ)
- joint assessment 3–4
- jugular notch 281, 281, 302–303, 302
- K**
- knee joint 121–148
 anatomy 122–123, 122, 123
 joint space 131, 135–137, 136, 138, 143
 palpation, anterior 125–130
 lateral 137–144
 medial 130–137
 posterior 144–147
 treatment applications 122
- L**
- lacrimal bone 370, 370
- lateral ligaments 167–168, 167
- latissimus dorsi 246, 251, 252–253, 253, 283
 functional massage 309–310, 309, 310
- lazertus fibrosus 48
- levator scapulae 23, 283
- lifting 241
- ligamenta flava 249, 249
- ligaments, palpation 10–11, 11
 see also specific ligaments
- Lister tubercle 76, 81, 81
- local treatment 4
- longissimus thoracis 246, 254, 255
- longitudinal ligament, anterior (ALL) 249, 249
 posterior (PLL) 249, 249
- lumbar functional massage 252
 prone position 193–194, 193, 194
 side-lying 194–196, 194, 195
- lumbar spine 241–242, 241, 243
 anatomy 243–255, 243–255
 anteroposterior segmental joint play 266–267, 266
 local segmental mobility using
 coupled movements 267–268, 267, 268
 lumbar muscle actions 255–258
 asymmetrical movements 257
 coupled and combined movements 257, 257
 symmetrical movement 257
 palpation 258–268
 posteroanterior segmental joint play 265–266, 265
 rotation test 264–265, 265
 treatment applications 242–243
- lumbar spinous processes
 see spinous processes
- lumbar test for rotation 264–265, 265
- lumbarization 243–244
- lumbopelvic-hip (LPH) region 103, 203
 see also hip; pelvis
- lumbosacral cross 260, 260
- lumbosacral junction 195, 195
- lunate 74, 85, 88, 88, 89
 scaphoid boundary 88
- M**
- malleolus, lateral 163, 163
 medial 154–155, 155
- mandible 370, 370, 374, 375
 head 372
- manubrium 281
- masseter 376, 376, 377
 trigger points 377, 377
- maxilla 370, 370
- medial cuneiform 159
- medial cuneiform–metatarsal joint space 160, 160
- medial ligaments 157, 157
- medial tubercle 156
- median nerve 47–49, 49, 51, 51, 52, 75, 76, 95, 98, 99
- meniscotibial ligaments 137, 137
- meniscus, lateral 143
- metacarpals 78, 79
- metacarpus 73, 89
- metatarsal, fifth 164, 166
- metatarsal–cuboid joint space 166–167
- metatarsophalangeal joint space 160, 161
- metatarsus 153
- mobility restrictions
 foot 152
 hand 72
- mouth
 closing 373, 373
 grinding movements 373
 opening 372–373, 373
 assessment 373–374, 375, 375
 clicking phenomenon 375, 375

movements, asymmetrical 257, 257
 coupled and combined 257–258, 257
 symmetrical 257
 multifidus 184, 212, 225, 225, 246, 254
 training 268, 268
 muscles 183
 consistency (muscle tension) 185, 192–193
 assessment 189–191, 190
 palpation 185–187, 185
 muscle bellies 8–9, 8
 muscle edges 9–10, 9
 pressure sensitivity 185
 treatment applications 183
see also specific muscles

N

nasal bone 370, 370
 navicular 159
 navicular 153, 159
 tuberosity 157, 159
 navicular–medial cuneiform joint space 160
 nerve compression
 hand 73
 provocation 99
see also specific compression syndromes
 nerves, palpation 12–13, 12
see also specific nerves
 neurovascular bundle
 elbow 51–52, 51
 groin 105, 105
 popliteal fossa 145, 145
 nucleus pulposus 242
 nutation restrictors 210, 210

O

occipital bone 370, 370
 olecranon 48, 59, 66
 orientation 4

P

palm pliancy 72
 palmar ligaments 74
 palmaris longus 48, 55, 58, 58, 59, 93, 93
 palpation 4–5, 5
 anatomical background 5
 blood vessels 13, 13
 bony edges 7–8, 8
 bony prominences 8, 8

bursae 11–12, 12
 capsules 11, 11
 central aspects 6–7
 connecting lines 14, 14
 experience 6
 guiding structures 13–14, 14
 localization 6
 marking structures 15
 muscle bellies 8–9, 8
 muscle edges 9–10, 9
 neural structures 12–13, 12
 practice starting positions (SPs) 15
 preparation 5–6
 pressure applied 6–7
 skin 7
 supporting measures 14
 tendons 10, 10
 parietal bone 370, 370
 patella 122, 123
 apex of 126–128, 127
 transverse friction 130, 130
 base of 126–127, 126
 edges of 127, 127
 tap test 124
 patellar ligament 123, 127–128, 128
 transverse friction 129–130, 129
 patellofemoral joint 123, 123, 129
 Patrick test position 142, 142
 pectineus 115, 115
 pectoralis major 282, 305
 abdominal head 311, 312, 312
 sternal head 310–312, 311
 pelvic floor muscles 236–237
 exercises 237
 pelvic ligaments 209–210, 209, 210
 pelvis 203, 203
 anatomy 205–213, 206–213
 gender-based differences 206, 206
 gap between pelvis and greater trochanter 235–236, 235
 palpation 213–214, 221–237
 bone orientation 214–217
 muscle orientation 217–221
 orienting projections 229–233
 sacrum as part of 210
 treatment applications 203–205
 percussion, chest 308, 308
 peroneal nerve
 common 106, 142–143, 143, 145
 posterior 145–146, 146
 deep 172–173, 173
 superficial 152, 173, 173, 174–175
 peroneal trochlea 163–164, 164
 peroneus brevis 153, 164–165, 164, 165
 transverse frictions 169, 169

peroneus longus 153, 164–165, 164
 peroneus tertius 164
 pes anserinus muscles 135, 135, 146–147
 phalanges 73, 153
 piriformis 106, 212, 230–231, 230, 231, 233
 compression syndrome 204–205
 pisiform 74, 89, 93–94, 93, 95, 95, 96, 97
 plantar calcaneonavicular ligament 157–158, 157
 plantar nerve, lateral 158
 medial 158
 popliteal artery 145
 popliteal fossa 147
 neural structures 145, 145
 popliteal vein 145
 popliteus 121, 141
 posterior pelvis *see* pelvis
 posteroanterior segmental joint play 265–266, 265
 pronator teres 48, 51, 52, 52, 55, 58, 58
 insertion 56, 56
 psoas major 246
 pterygoid
 lateral 372, 375, 378–380, 379, 380
 trigger points 380, 381
 medial 377–378, 378
 trigger points 378, 379
 pubic arch 206
 pubic rami, inferior 206
 pubic tubercle 104, 116

Q

quadratus lumborum 246, 255, 256
 quadriceps femoris 121, 123

R

radial artery 83, 83, 91, 92, 92
 radial column of the hand 73, 73, 85–87, 85
 radial fossa 80, 80
 radial nerve 47, 49, 62–63, 62, 82–83, 83
 radiocarpal joint
 joint line 77–78, 79, 91
 joint space 78, 78
 radioulnar joint
 joint space 81–82
 proximal (PRUJ) 47, 53, 53
 radius 48, 59, 74
 edge of 91
 head 48, 53, 59, 61, 62

- neck 61
tuberosity 48
- rectus femoris 105, 110, 112–113, 112, 123
- respiration 273–274
costovertebral joint mechanics 280–281, 280, 281
intercostal palpation during 304–305, 305
- respiratory therapy 306–309
interventions to loosen secretions 307–308, 308
mobilization of the thorax 308–309, 309
tissue release methods 307
- rhomboids 283
- ribs 279, 279, 281, 297, 297
articulations with vertebrae 280, 280
costosternal joints 280, 304
first rib
localization 288–290, 288, 289, 293–294, 293, 294, 304, 304
mobility assessment 290–291, 290
position assessment 300–301
second rib localization 303–304, 303
springing test 277, 290, 290
all ribs 301
single rib 301–302, 301
- rotatores thoracis 283, 283
- S**
- sacral crest 208
median 225
- sacral hiatus 209, 209, 226, 226
- sacral horn 209, 226, 226
- sacral spinous processes
see spinous processes
- sacralization 243–244
- sacrococcygeal ligaments
deep posterior 209
lateral 209
- sacrococcygeal transition 208, 209, 226–227, 226, 227
- sacroiliac (SI) joint 203, 210–211, 211, 229–230, 229, 230
biomechanics 211–212, 211, 212
ligament dynamization 212–213
mobilization 204, 237, 237
- sacroiliac (SI) ligaments 212
anterior 209
long posterior 210, 210, 228–229, 228, 229
- sacroiliac spine, posterior 259, 259
- sacroteruberous ligament 212–213, 213, 228, 228
- sacrum 203, 207–209, 208, 211, 214, 216–217, 216, 282
apex 208, 208
edge of 184
inferolateral angles 227–228, 227
see also sacroiliac (SI) joint
- saphenous nerve 123, 133, 133
- sartorius 105, 110–111, 110, 111, 113, 113, 123, 135, 147
- scaphoid 74, 85, 85, 87, 89, 96–97, 96, 97, 98
lunate boundary 88
tubercle 74, 92, 92, 95, 97
- scapula 19, 20, 197
acromial angle 20, 24, 25, 33
inferior angle 19, 22–23, 22
medial border 19, 21, 23, 23
rotation 21, 22, 291
assessment 22–23, 22, 23
spine of 19, 20
inferior edge 23–24, 24
superior edge 20, 25, 25
superior angle 19, 23, 24
topographical position 21, 21
- sciatic bursa 236
- sciatic nerve 106, 145, 204, 231–232, 231, 232, 233
- secretions, loosening 307–308, 308
- segmental mobility test
lumbar spine 267–268, 267, 268
anteroposterior segmental joint play 266–267, 266
posteroanterior segmental joint play 265–266, 265
thoracic spine 297–299, 297, 298, 299
- segmental traction 299–300, 300
- semimembranosus 106, 121
- semispinalis cervicis 184
lumborum 246
- semitendinosus 106, 123, 135, 146, 147, 147
- serratus posterior inferior 246
- shoulder complex 19
anatomy 19–20, 19, 20
orientation, anterior 34, 34
posterior 20–21, 21
palpation, anterior 35–37
anterolateral 37–43
lateral 28–34
posterior 21–28
treatment applications 19
- skin 183
consistency 7, 7, 185, 188, 192
displacement test technique 188, 189
skin-lifting test 189, 189
skin-rolling technique 189, 189
palpation 7, 185–191, 185
pressure sensitivity 185
sensation 185
surface of 184, 192
temperature assessment 188
treatment applications 183
- skin rolling 189, 189, 307, 307
- skull
anatomy 370–371, 370, 371
palpation 370–371
see also temporomandibular joint (TMJ)
- soft tissues 183
anatomy 183, 184
foot 152
hand 73
palpation 184–191
see also muscles; skin
- sphenoid 370, 370
- spinal assessment 3–4
- spinal cord 242
- spinalis 246
thoracis 184, 282, 282
- spinous processes 245, 245, 246
cervical 285–287
C5 285–287, 285, 286
C6 285–287, 285, 286
C7 282, 285–287, 287
lumbar 245–246, 246, 262
L3 262
L4 262
L5 260, 261, 261
transverse processes 246
- sacral 224, 224, 225, 225
S1 225, 225, 260, 261
S2 224, 224, 225, 260, 260–261, 260
S3 225, 225
- thoracic 277, 277, 294–296, 294, 295
T1 287–288, 287, 288, 293, 293, 294
T3 294
T7 294
T8 296
T11 263–264, 263, 264, 294
transverse processes 277–278, 277, 288, 288, 296
- springing test 277, 290, 290
all ribs 301
single rib 301–302, 301

standing 241, 255
 standing flexion test 237, 237
 Steinmann II sign 136, 136, 137, 143
 sternal angle 281, 303, 303
 sternoclavicular (SC) joint 281, 281
 joint space 36, 36
 sternocleidomastoid 35, 35
 sternum 279
 manubrium 281
 stratum, inferior 372, 375
 superior 372, 375
 styloid process 370, 370
 subpubic angle 206
 subscapularis tendon 39
 subtalar (ST) joint 121, 151
 supraclavicular fossa 34, 34
 supracondylar ridge 48, 59
 lateral 60
 medial 55–56, 55
 suprahyoid muscles 383
 supraspinatus muscle 26, 26
 insertion 42–43, 42, 43
 supraspinous ligaments 249, 249,
 250
 sustentaculum tali 155, 155, 159

T

talocalcaneonavicular (TCN) joint
 121, 151
 range of motion test 174, 174
 talocrural joint 121, 151
 talofibular ligament, anterior 153,
 167, 167, 168
 posterior 153, 167, 167
 talonavicular joint 162, 162
 joint space 160, 160
 talus 153, 159
 anterior–posterior glide
 technique 173, 174
 dorsal 171
 head 171
 neck 155–156, 156, 171
 posterior process 156, 156
 tarsal joints, tests of joint play 170,
 170
 temperature increase, knee 125
 temporal bone 370, 370, 374
 temporalis 380–382, 381, 382
 trigger points 382
 temporomandibular joint (TMJ) 369,
 371–375, 372
 anatomy 369–370
 biomechanics 372–373
 assessment 373–374
 clicking phenomenon 375, 375
 closing the mouth 373, 373

 grinding movements 373
 opening the mouth 372–373,
 373
 disorder (TMD) 369
 palpation 374–383
 treatment applications 369
 tendon compartments
 radial to ulnar 75, 76, 80–84, 81,
 83, 84
 tendons, palpation 10, 10
 see also specific tendons
 tennis elbow 62, 62, 64
 treatment 65, 65
 tensor fasciae latae 105, 110,
 111–112, 111, 220
 teres major 309, 310, 310
 teres minor 309, 310, 310
 Tetro test 99, 99
 thoracic nerve lesion 22
 thoracic spine 243, 273–274
 anatomy 275–278, 276–278
 palpation 284–312
 anterior techniques 302–312
 posterior techniques 284–302
 treatment applications 274–275
 thoracic spinous processes
 see spinous processes
 thoracolumbar fascia 212, 213, 213,
 241, 250–252, 255
 middle layer 251, 251, 252
 superficial layer 251, 251, 252
 thorax 278–284, 278–283
 costovertebral joint mechanics
 280–281, 280, 281
 mobilization 308–309, 309
 compression 309, 309
 throat 303
 thumb/finger opposition 71–72, 71
 tibia 122
 anterior–posterior glide on the
 talus technique 174, 174
 tuberosity 122, 128–129, 128
 tibial artery 158–159, 158
 anterior 172, 172
 tibial nerve 106, 145, 145, 146, 152,
 158–159, 158
 tibial plateau 131, 131, 138–139, 138
 tibialis anterior 153, 159, 159
 posterior 153, 156, 156, 159
 transverse friction 161–162,
 162
 tibiofibular joint 144
 arthritis 144
 tibiofibular ligament, anterior
 168–169, 168
 transverse friction 169
 Tietze syndrome 304

Tinel test 99, 99
 tissue consistency 6
 tissue release methods 307
 tractus iliotibialis 105, 110
 transverse tarsal (TT) joint 151
 transverse vertebral pressure
 264–265, 265
 transversus abdominus 251, 252
 trapezium 74, 85, 85, 86, 97, 98
 tubercle 74, 95, 97
 trapezius 23, 251, 284, 283
 functional massage, side-lying
 196–197, 196, 197, 291–292,
 291, 292
 supine 198, 198
 trapezoid 74, 85
 triangular and fibrocartilage (TFC)
 complex 74, 74
 triceps brachii 48
 triceps surae 153, 175, 177–178,
 177
 insertion 176, 176
 triquetrum 74, 85, 89–90, 89
 trochanteric bursa 233–234, 233

U

ulna 48, 59, 74
 head 82
 ulnar artery 92, 93–94
 ulnar collateral ligament of the wrist
 74
 ulnar column of the hand 73, 74,
 88–90, 89
 ulnar nerve 49, 49, 51, 51, 54–55, 54,
 55, 58, 92, 93–94, 94
 groove for 49, 55, 55
 ulnar trio 91, 92, 93

V

vastus medialis 123
 vertebrae
 articulations with ribs 280, 280
 finger rule 278, 278, 295–296,
 295
 lumbar 244–245, 244
 thoracic 276, 277
 vertebral column 191, 191, 242, 243
 sacrum as part of 210
 see also lumbar spine
 vertebral foramen 277
 vibration therapy 307–308, 308
 viscerocranium 370
 frontal aspect 370–371, 371
 lateral aspect 371, 371

W

- walking 242
- wrist 76
 - extension 97
 - flexion 97
 - see also carpal tunnel

Z

- zygapophysial joints (ZAJs)
 - lumbar 241, 247–248, 247, 248
 - thoracic 274–275, 278, 278
- zygomatic bone 370, 370



CONTACT DETAILS 3B SCIENTIFIC GROUP OF COMPANIES

HEADQUARTERS

GERMANY

3B Scientific Hamburg
Rudorffweg 8
21031 Hamburg
Phone: +49 40 739 66 – 0
Fax: +49 40 739 66 – 100
info@3bscientific.com

SPAIN

España 3B Scientific S.L.
C/ Ronda Narciso Monturiol nº3
Edif. ABM, Torre A, Despacho nº 8
Parque Tecnológico de Paterna
46980 Paterna (Valencia)
Phone: +34 961 31 84 38
Fax: +34 961 31 88 34
alexander.crasemann@3bscientific.com

JAPAN

Nihon 3B Scientific, Inc
2-5-18 Sonoki
Niigata-shi, 950-1135
TEL +81-025-282-3228
FAX +81-025-282-3229
3b@3bs.jp

USA

American 3B Scientific (A3BS)
2189 Flintstone Drive, Unit 0
Tucker
Georgia 30084
Phone: +1 770 492 9111
Fax: +1 770 492 0111
sales@a3bs.com

UNITED KINGDOM

UK 3B Scientific Ltd. (UK3BS)
8 Beaconsfield Rd
Weston-Super-Mare
Weston-super-Mare BS23 1YE
Phone: +44 (0)1934 425333
Fax: +44 (0)1934 425334
uk3bs@3bscientific.com

CHINA

Suzhou 3B Scientific
45 HuoJu Road, Suzhou New District
Suzhou New District S&T Industrial Park
215009 Suzhou, Jiangsu
Phone: +86 512 68081123
Fax: +86 512 68258957
c3bs@3bscientific.cn

BRASIL

Brasil 3B Scientific Ltda.
Rua Landmann, 92 B
Costa e Silva
Cep 89217-420 Joinville, Santa Catarina
Phone: +55 (47) 3464-1818
Fax: +55 (47) 3467-9800
marc.xab@3bscientific.com

THAILAND

Thai 3B Scientific Co., Ltd.
4/12 Moo 7, Soi Bangkae District Office,
Kanchanapisek Rd.,
Bangkae Sub-District/District
10160 Bangkok
Phone: +66 (0) 2 487 0500
Fax: +66 (0) 2 487 0503
Thai3BS@3BSscientific.com

RUSSIA

ООО 3Б Сайнтфик
196128, Россия, Санкт-Петербург
Ул.Благодатная, д.6, лит.А, пом.24Н
Phone: +7 (812) 334 22 23
Fax: +7 (812) 334 71 50
sales.spb@3bscientific.com

FRANCE

France 3B Scientific SARL
8 Rue Jean Monnet
Z.I. Parc 3
68870 Bartenheim (Mulhouse)
Phone: +33 (0)3 89 70 75 20 Fax: +33 (0)3
F3BS@3bscientific.com

HUNGARY

3B Scientific Europe Kft
Kozma u. 9-11
1108 Budapest
Phone: +36 1 431 09 14
Fax: +36 1 262 33 93
EU3BS@3bscientific.com

ITALY

Italia 3B Scientific S.R.L.
Via Progresso 46
Ozzano dell'Emilia
40064 Bologna
Phone: +39 051 790505
Fax: +39 051 4695098
i3bs@3bscientific.com

3B SCIENTIFIC —
ANATOMY
IN
3
DIMENSIONS

