

Muscles of Lower Limb.

I. 3 Gluteal muscles.

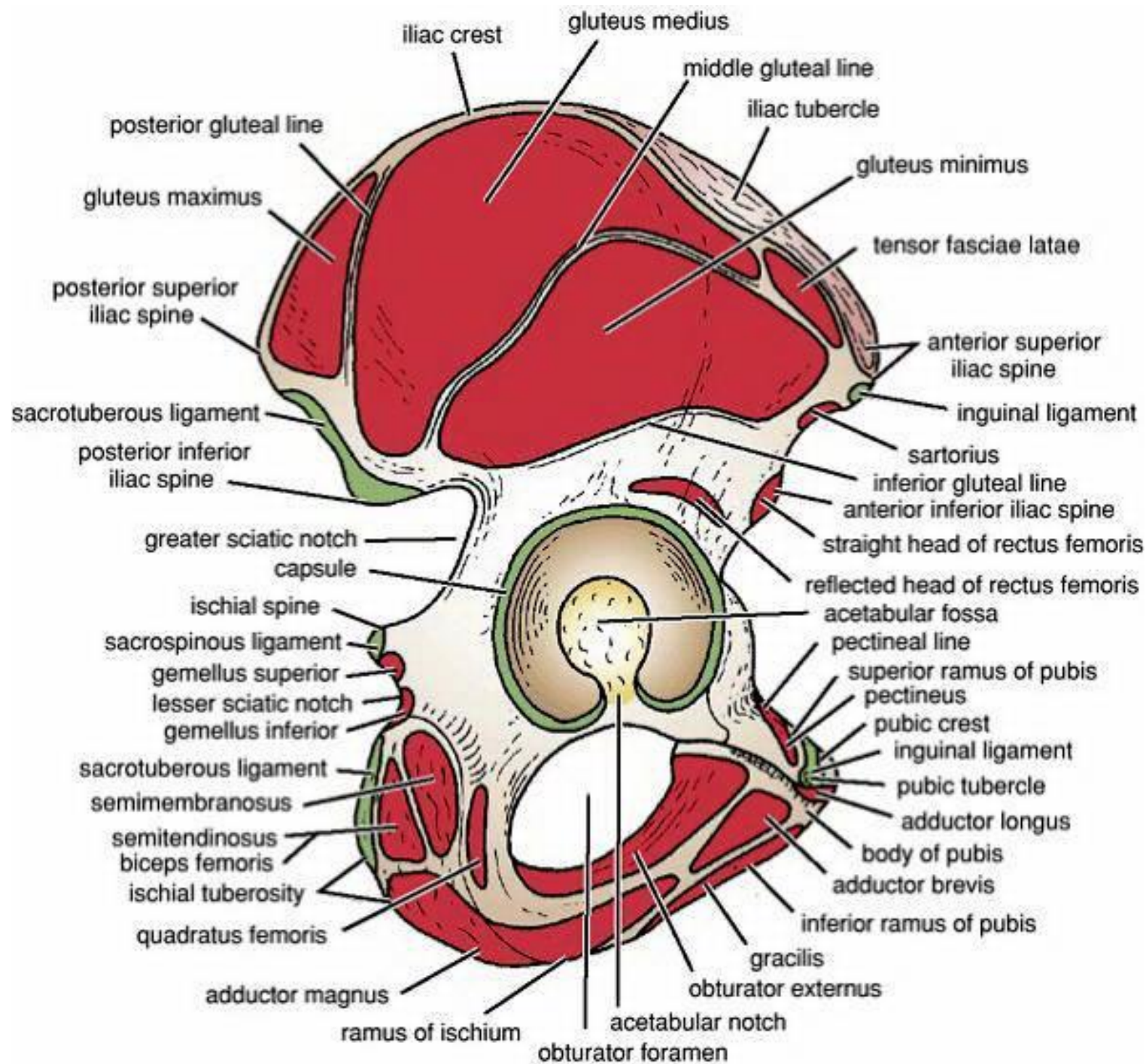
- All muscles are supplied by superior gluteal nerve except gluteus maximus which is supplied by inferior gluteal nerve .

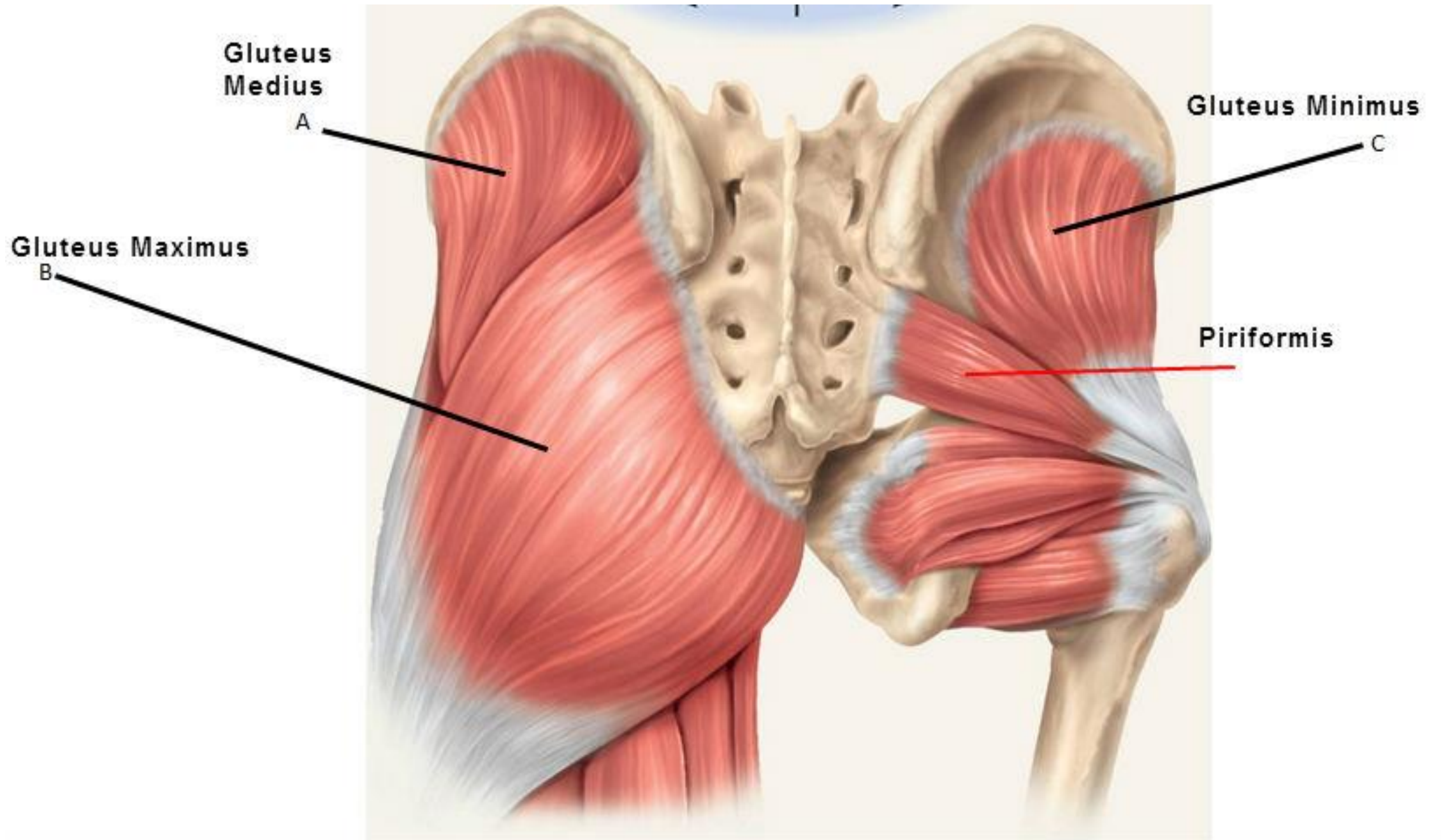
Muscle	Origin	Insertion	Important features
1. Gluteus maximus	<ul style="list-style-type: none"> • Gluteal surface of ilium behind posterior gluteal line, back of sacrum & sacrotuberus ligament . 	<ul style="list-style-type: none"> • The deep $\frac{1}{4}$: inserted into gluteal tuberosity of femur . • The superficial $\frac{3}{4}$: is inserted into the posterior border of iliotibial tract 	<ul style="list-style-type: none"> ❖ It is the main extensor of hip & assist in lateral rotation hip . ❖ Structures deep to the gluteus maximus: <ol style="list-style-type: none"> 1. Bony prominences: greater trochanter and ischial tuberosity. 2. Ligaments: sacro-spinous and sacro-tuberous. 3. Muscles and tendons: gluteus medius, piriformis, tendon of obturator internus and the 2 gemelli, quadratus femoris, the origin of the hamstring and ischeal part of adductor magnus muscles (from ischial tuberosity). 4. Vessels: <ul style="list-style-type: none"> ▪ Above piriformis: superior gluteal vessels. ▪ Below piriformis: inferior gluteal and internal pudendal vessels. 5. Nerves <ul style="list-style-type: none"> ▪ Above piriformis: superior gluteal nerve. ▪ Below piriformis: sciatic nerve, inferior gluteal nerve, posterior cutaneous nerve of the thigh and nerve to quadratus femoris. 6. Two nerves pass from greater to lesser sciatic foramen: pudendal nerve and nerve to obturator internus . * Great thickness of the gluteus maximus muscle makes it ideal for <i>intramuscular injections</i>. To avoid injury to the underlying sciatic nerve, the injection should be given well forward on the <i>upper outer quadrant</i> of the buttock.

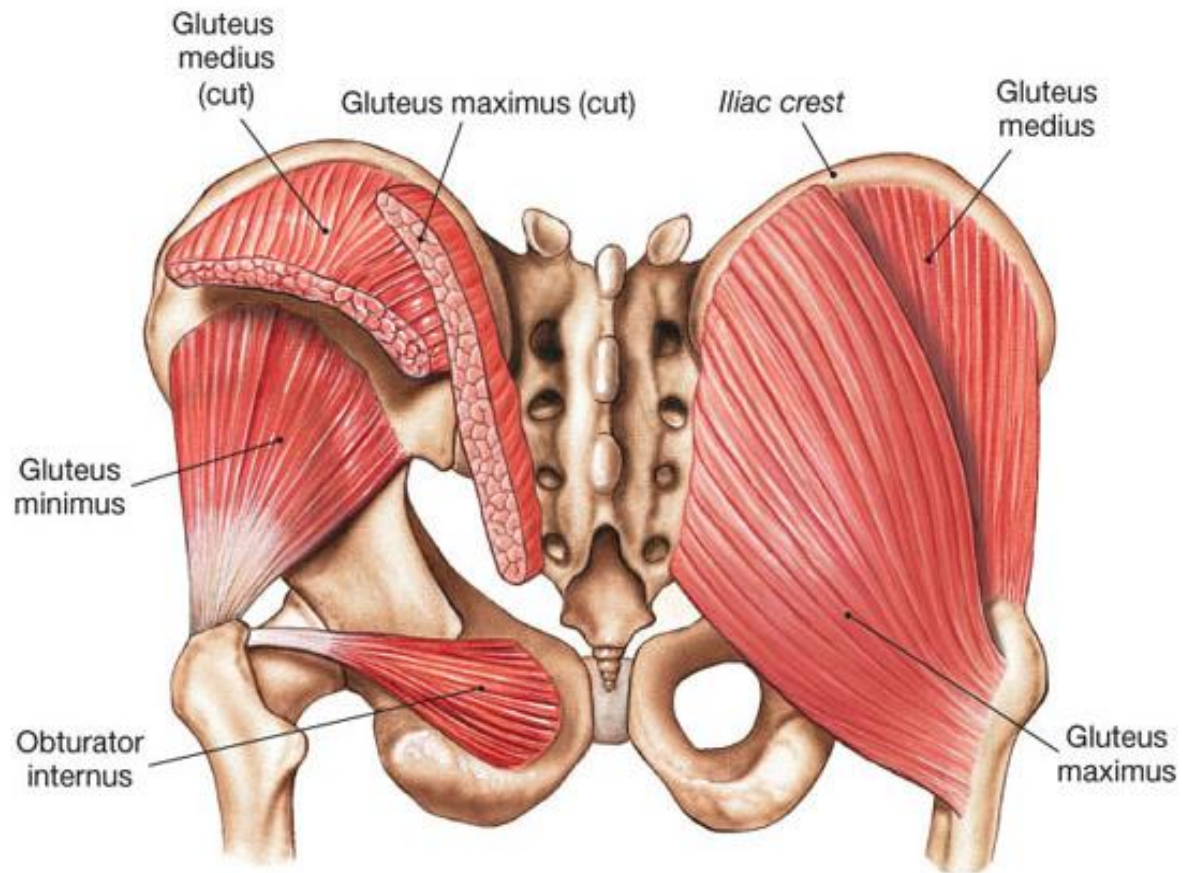
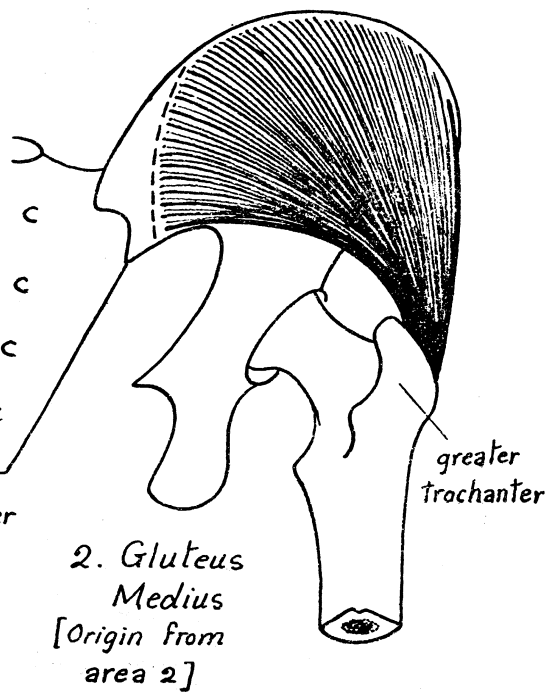
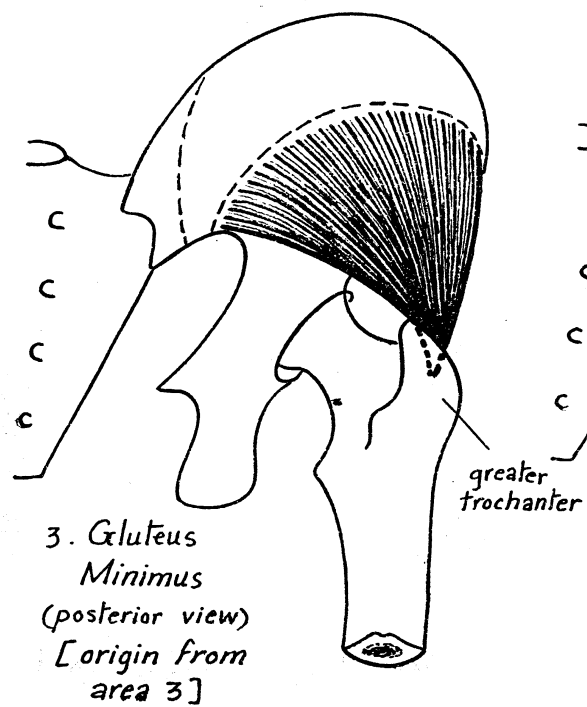
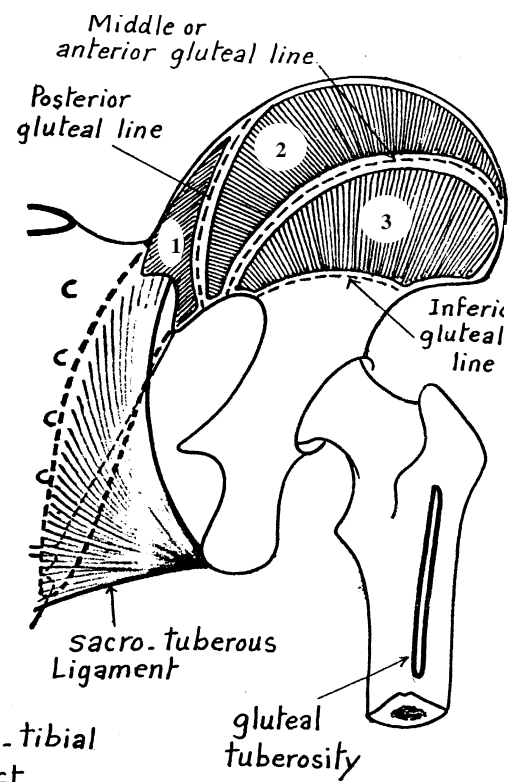

2. Gluteus medius	• Gluteal surface of ilium between posterior & middle gluteal lines .	• oblique ridge on the lateral surface greater trochanter.	a) Middle fibers abduct the thigh while the anterior fibers medial rotators . b) Prevent falling down of the pelvis on the unsupported side during waking. This the basis of Trendelenberg's test in examination of hip joint .
3. Gluteus minimus.	• Gluteal surface of ilium between middle & inferior gluteal lines .	• Anterior surface of the greater trochanter.	
4. Tensor fascia lata	• Outer lip of the iliac crest between the ASIS and tubercle of iliac crest .	• Anterior border of the ilio-tibial tract	<ul style="list-style-type: none"> • Tightens the ilio-tibial tract. • keeping the knee extended through its insertion in the ilio-tibial tract. • Weak abductor and medial rotator of the thigh .

★ **NB : The ilio-tibial tract:**

- * It is a **vertical thickening** of the fascia latae , on the **lateral aspect of the thigh** .
- * It **extends** from the iliac crest (**above**) to the lateral border of the patella, the lateral condyle of the tibia, the capsule of the knee joint and the head of fibula (**below**).
- * **It receives the insertion of 2 muscles:** Tensor fasciae latae(into its anterior border) & Superficial 3/4 of gluteus maximus (into its posterior border) .
- * **Functions of the ilio-tibial tract:**
 - 1- It **extends the insertion** of gluteus maximus and tensor fasciae latae downwards to reach the knee joint; thus inducing a **combined action** on both hip and knee joints.
 - 2- In the erect position, it helps to **steady** the pelvis and acts as a splint for the knee joint by fixing the tibial condyle below the femoral condyle during extension of the limb.







Gluteus Medius
(under fascia)

Gluteus Maximus

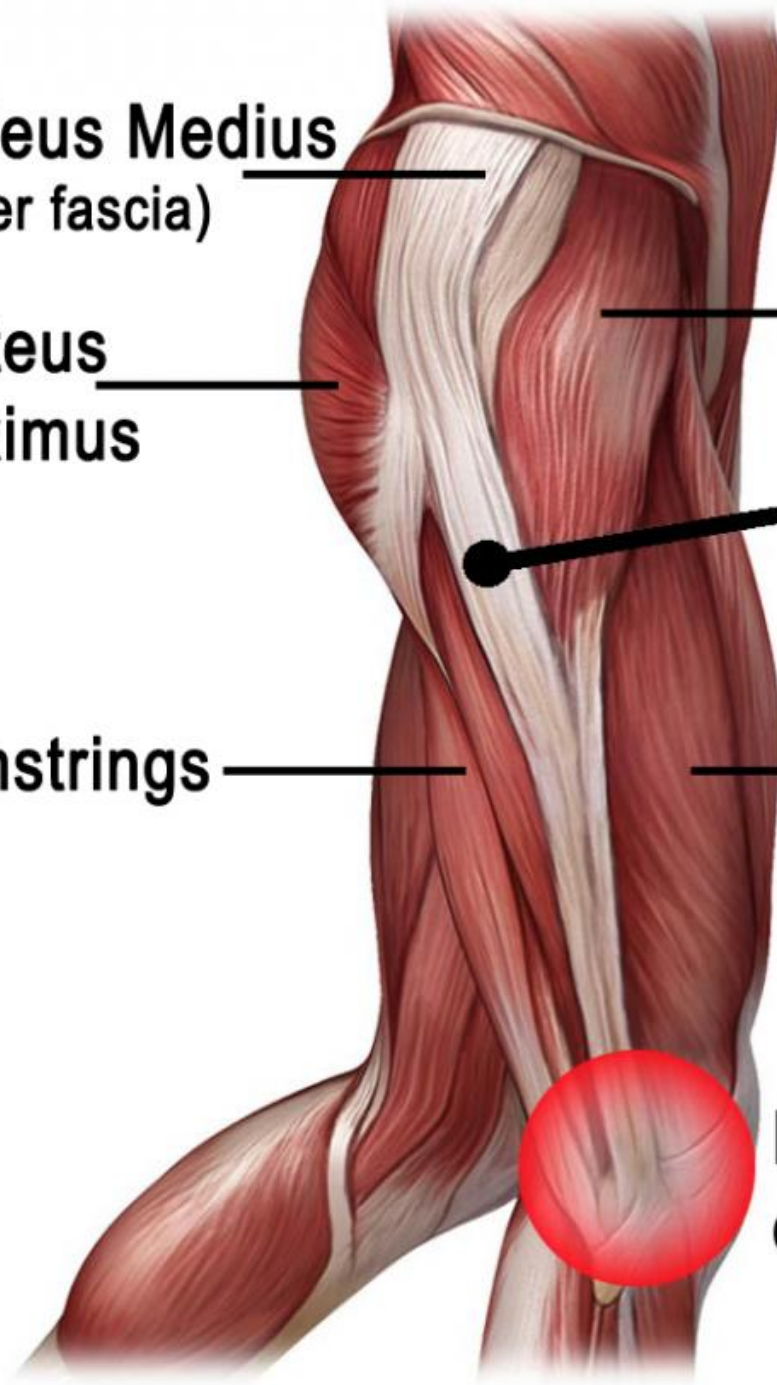
Hamstrings

Tensor Fasciae Latae

Iliotibial Band (ITB)

Quadriceps

Localised pain on outer knee

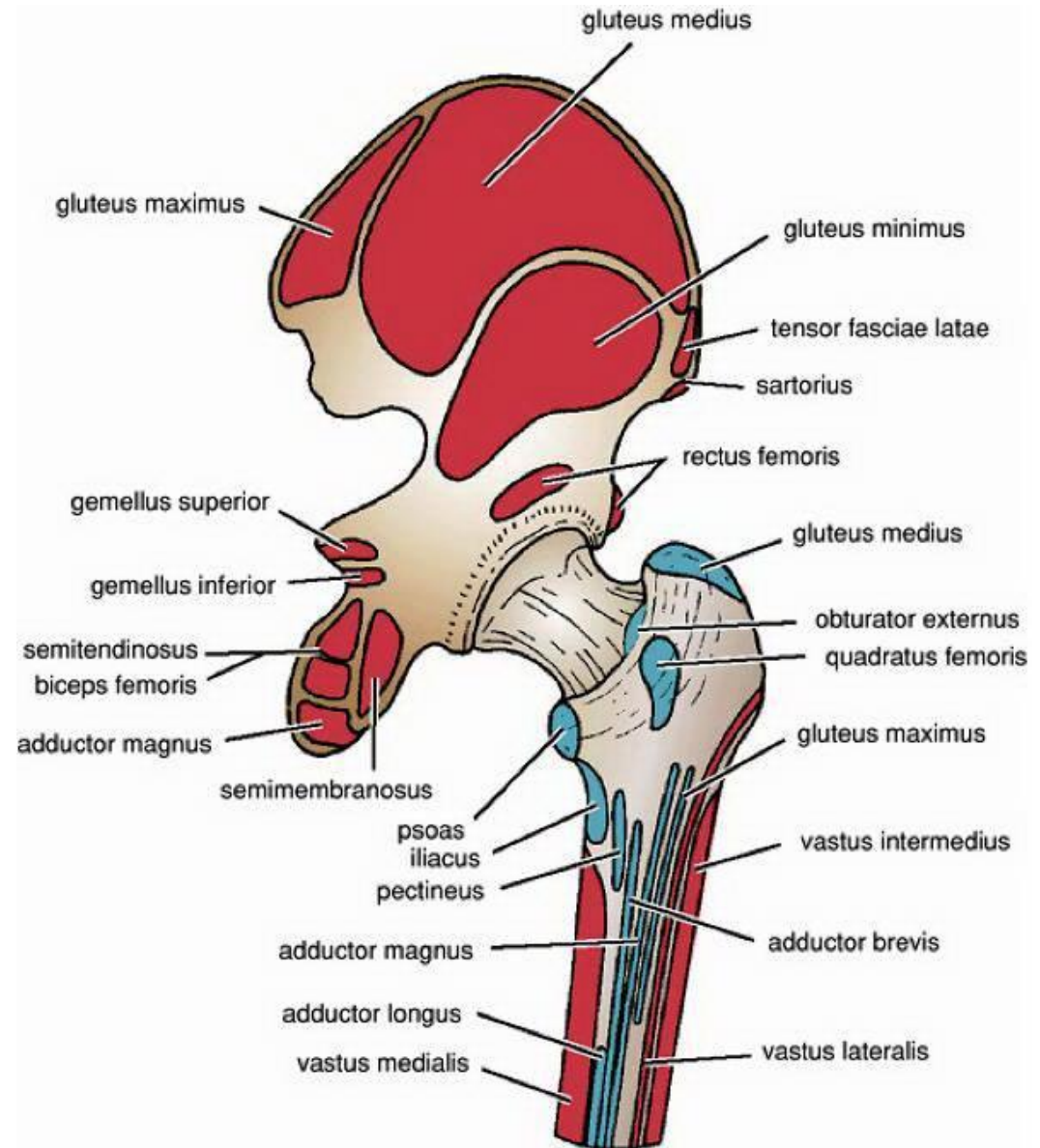
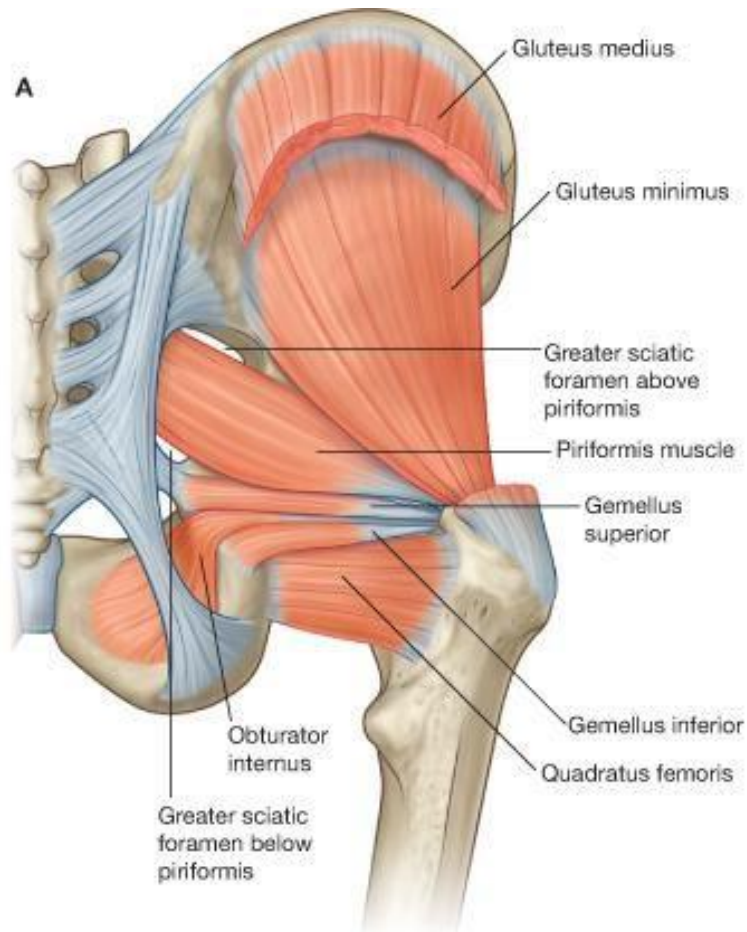


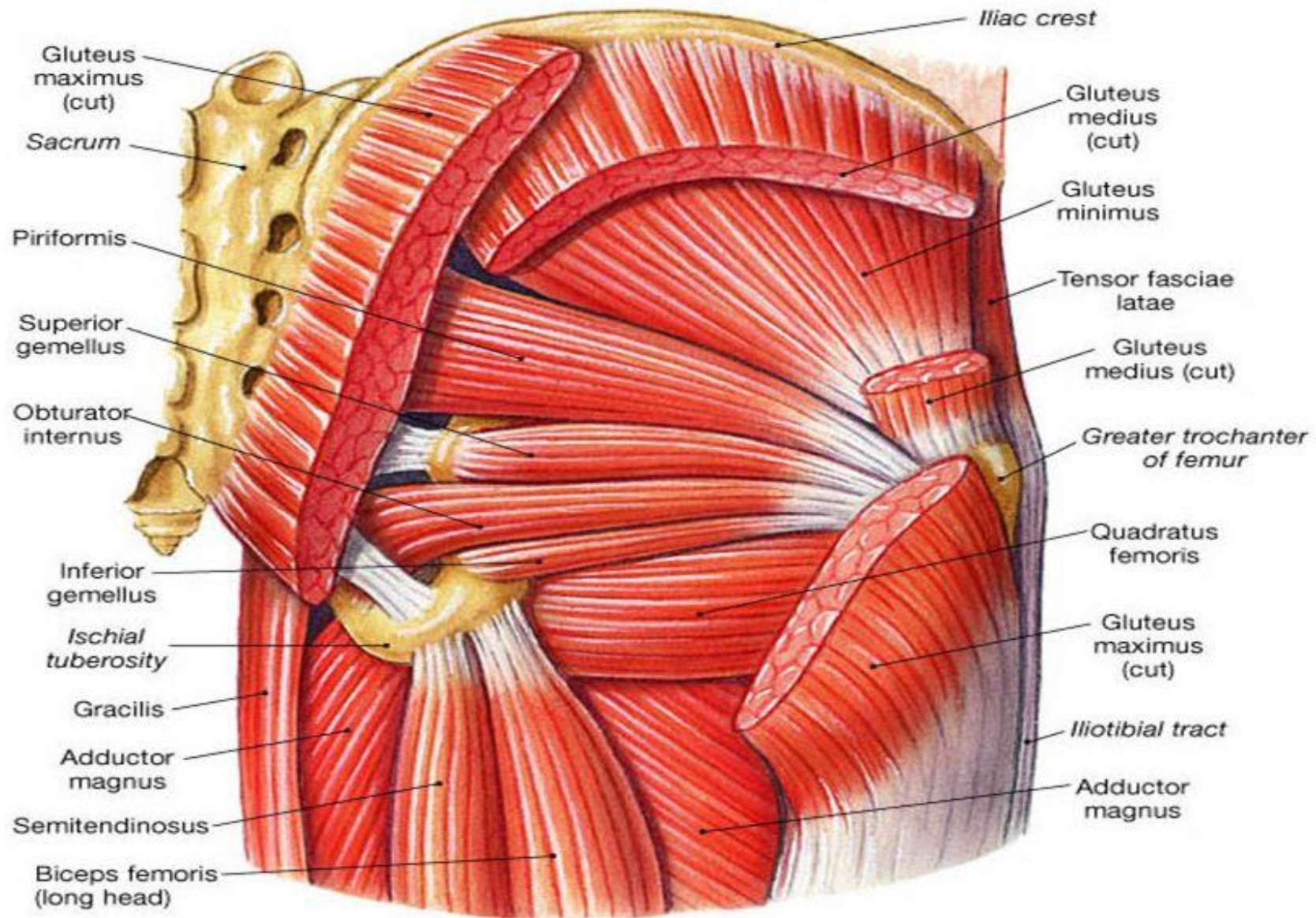
II. 6 Lateral Rotators

* 6 Lateral rotators include the following muscles:

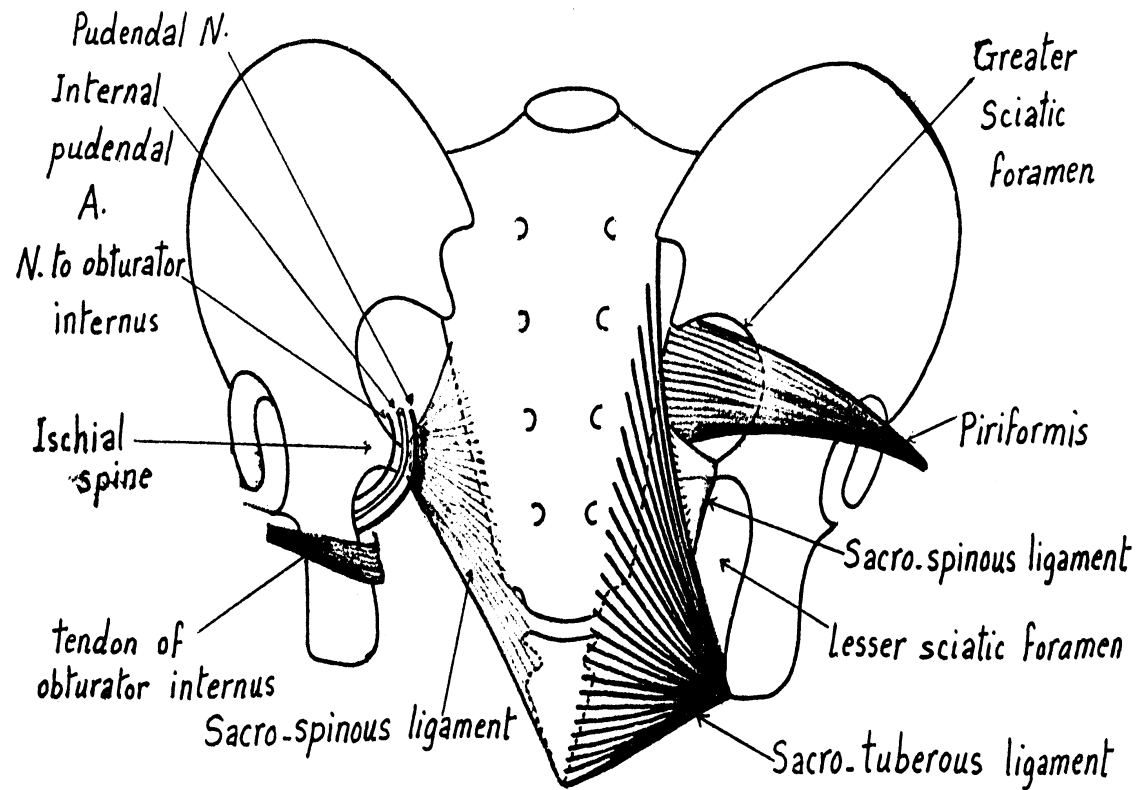
1. Piriformis: Arises in the pelvis & passes in the greater sciatic foramen above the sciatic nerve.
2. Obturator internus: Arises from the lateral pelvic wall & passes in the lesser sciatic foramen.
3. Superior & inferior gemellus above & below tendon of Obturator internus .
4. Quadratus femoris.
5. Obturator externus.

* Common action : lateral rotation of the thigh .

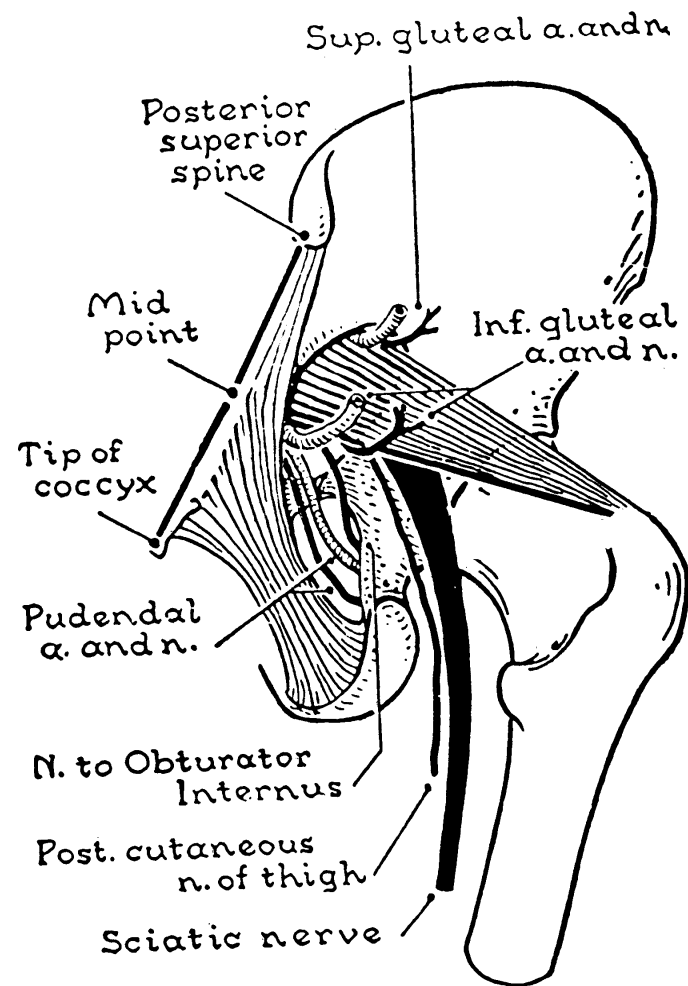




(a) Posterior view, deep muscles

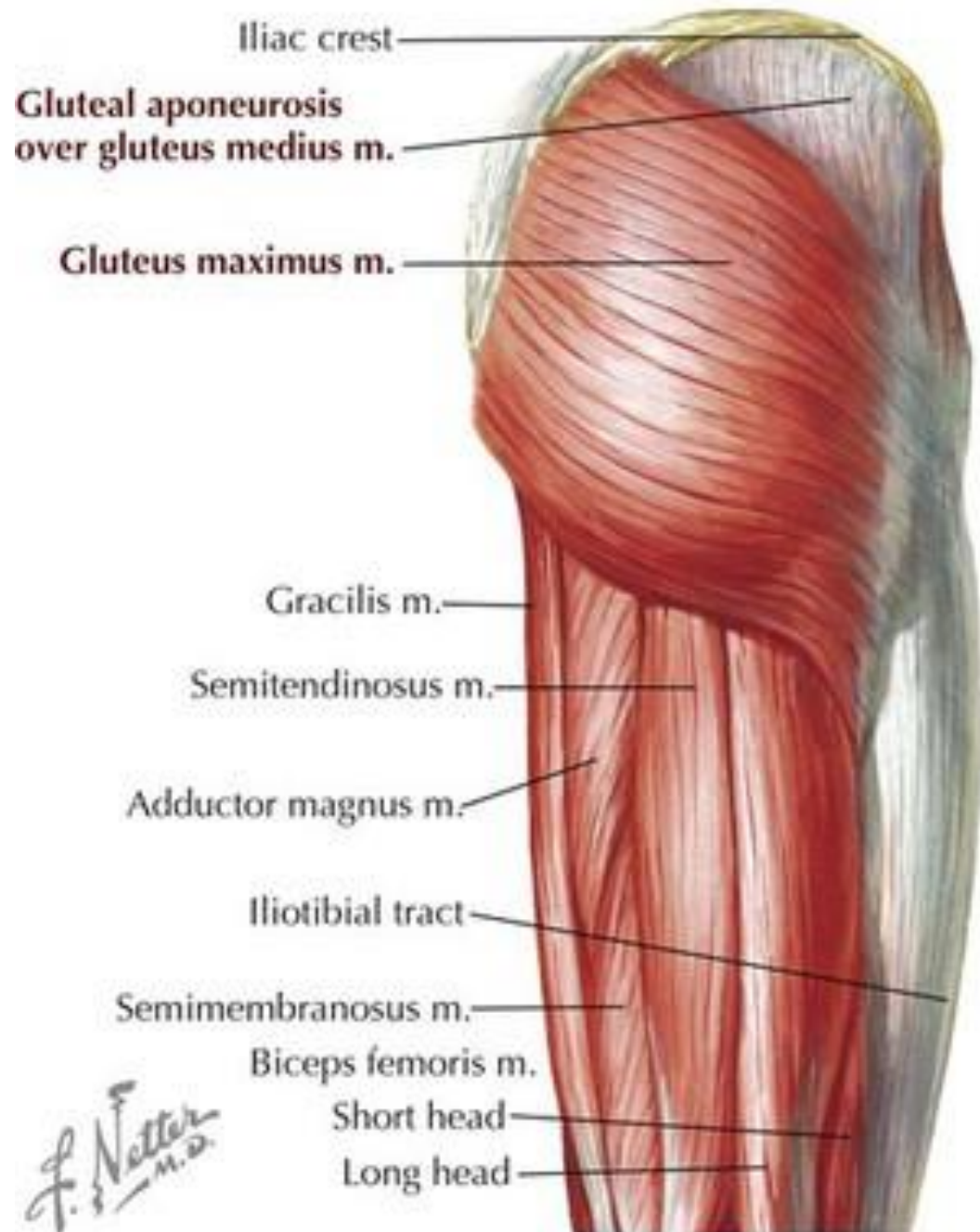

Ligaments and foramina of gluteal region.

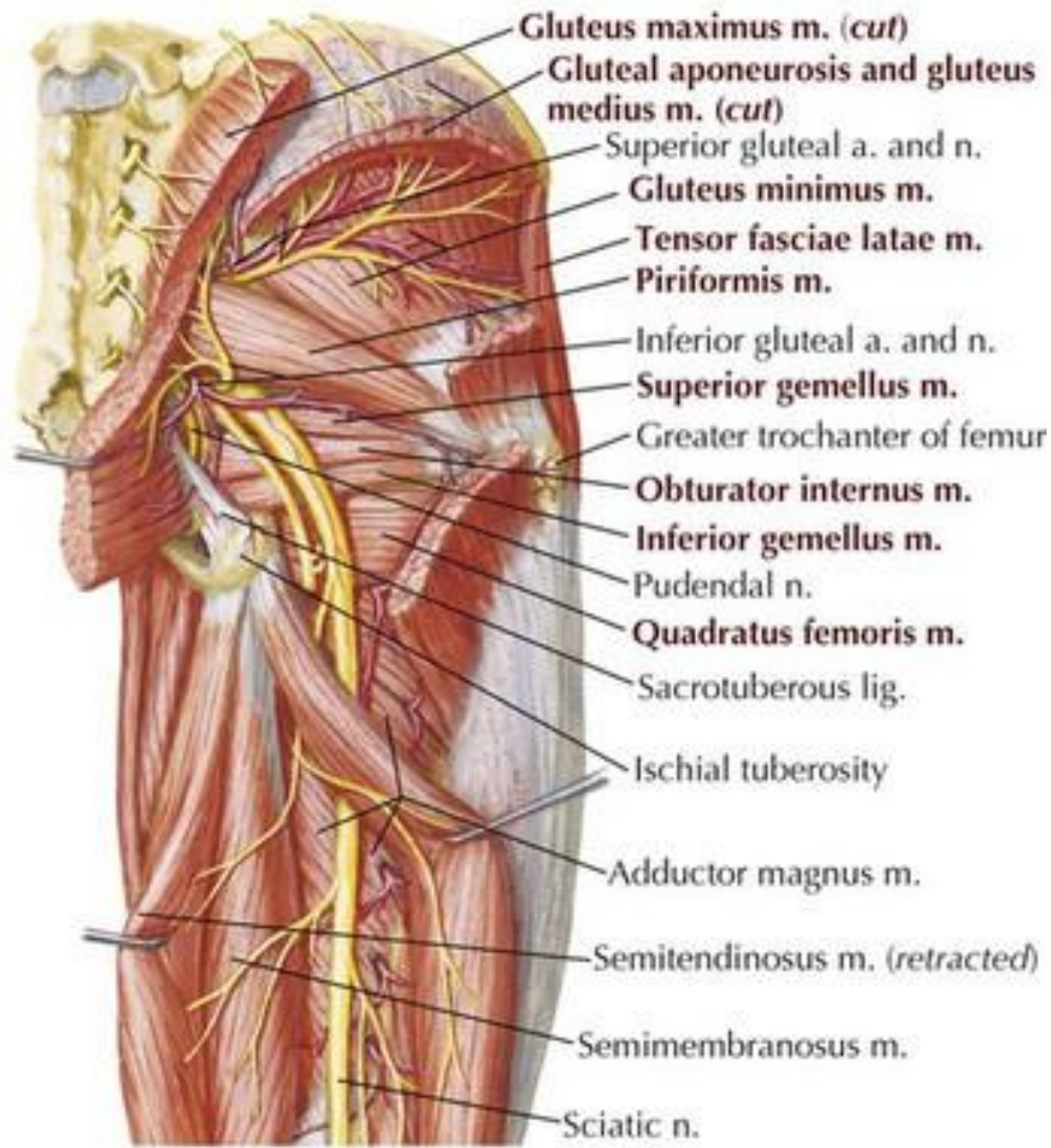


*Structures passing through the sciatic foramina
(deep to the gluteus maximus)*

Superficial dissection

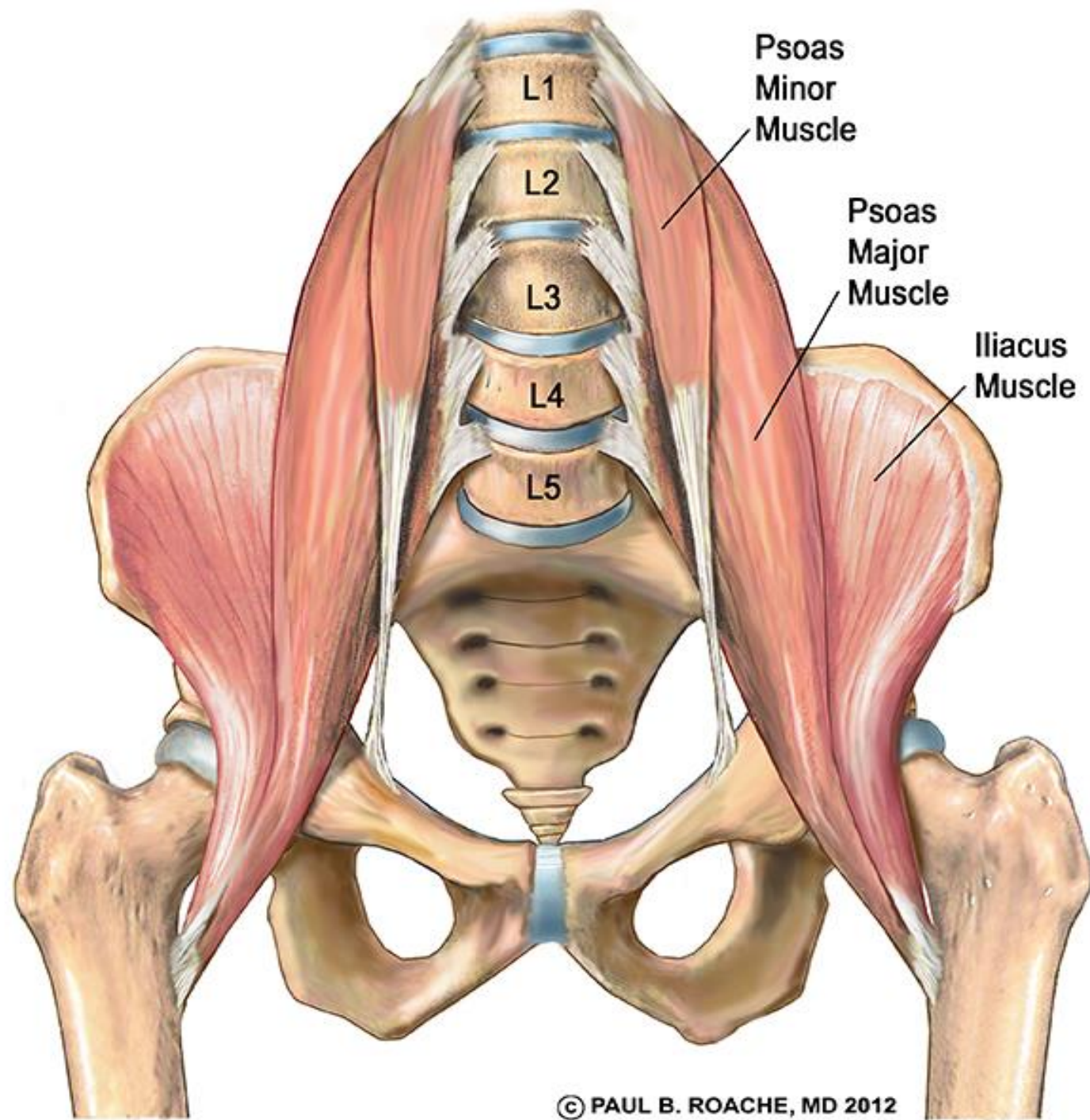


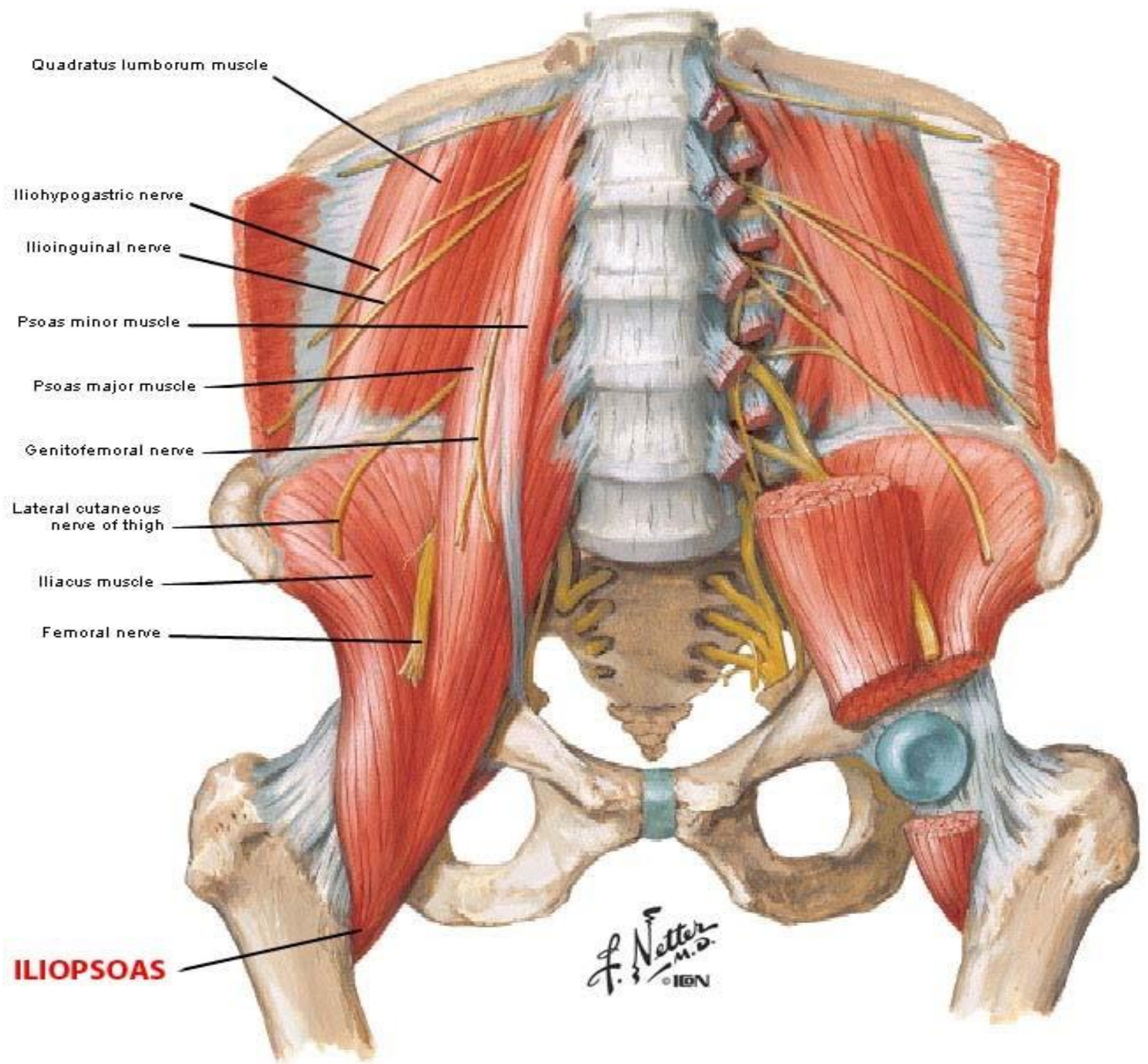
Deep dissection



Muscles of the iliac region

Muscle	Origin	Insertion	Nerve supply	Action
1- Psoas major :	<ul style="list-style-type: none"> • Sides of body & front of transverse processes of T12- L5 vertebrae 	<ul style="list-style-type: none"> • Both muscles form the iliopsoas tendon which is inserted into the lesser trochanter of femur 	<ul style="list-style-type: none"> • L 2,3&4 	<ol style="list-style-type: none"> 1. Main flexor of the hip . 2. Medial rotation of thigh. 3. Contraction of both side produce flexion of vertebral column. 4. Contraction of one side produce lateral flexion of vertebral column.
2- Iliacus :	<ul style="list-style-type: none"> • Iliac fossa . 		<ul style="list-style-type: none"> • Femoral nerve 	



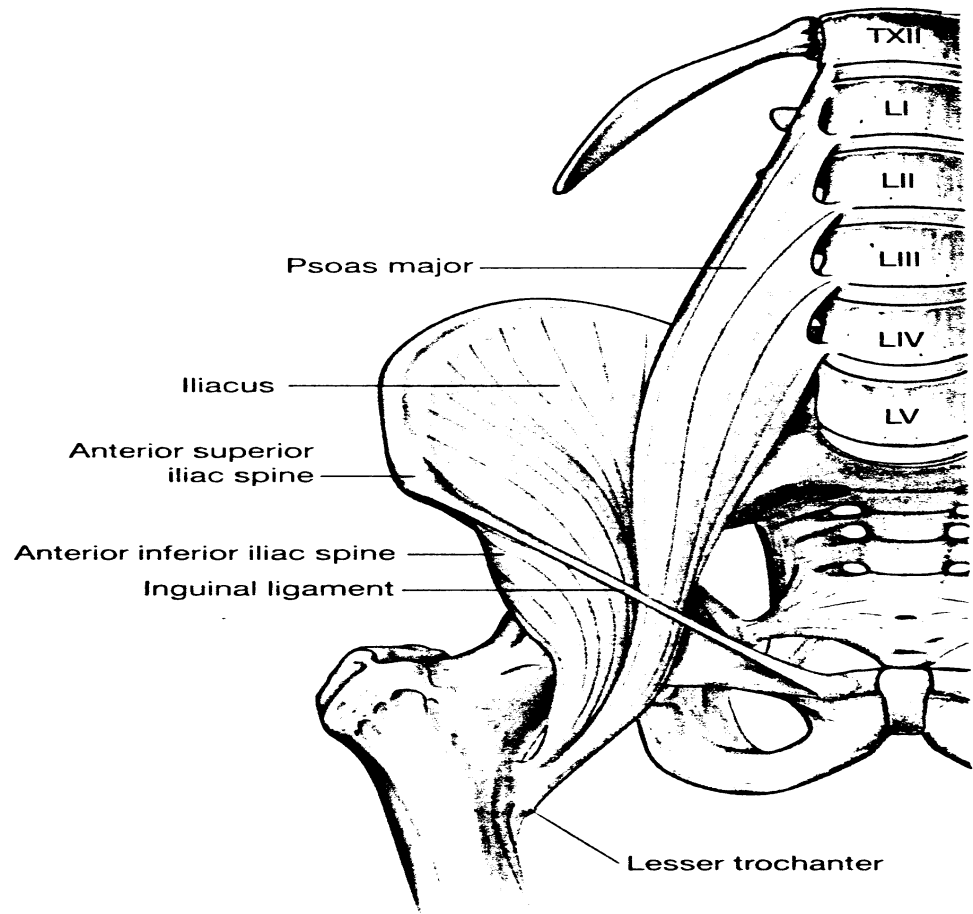


III. Muscle of Thigh

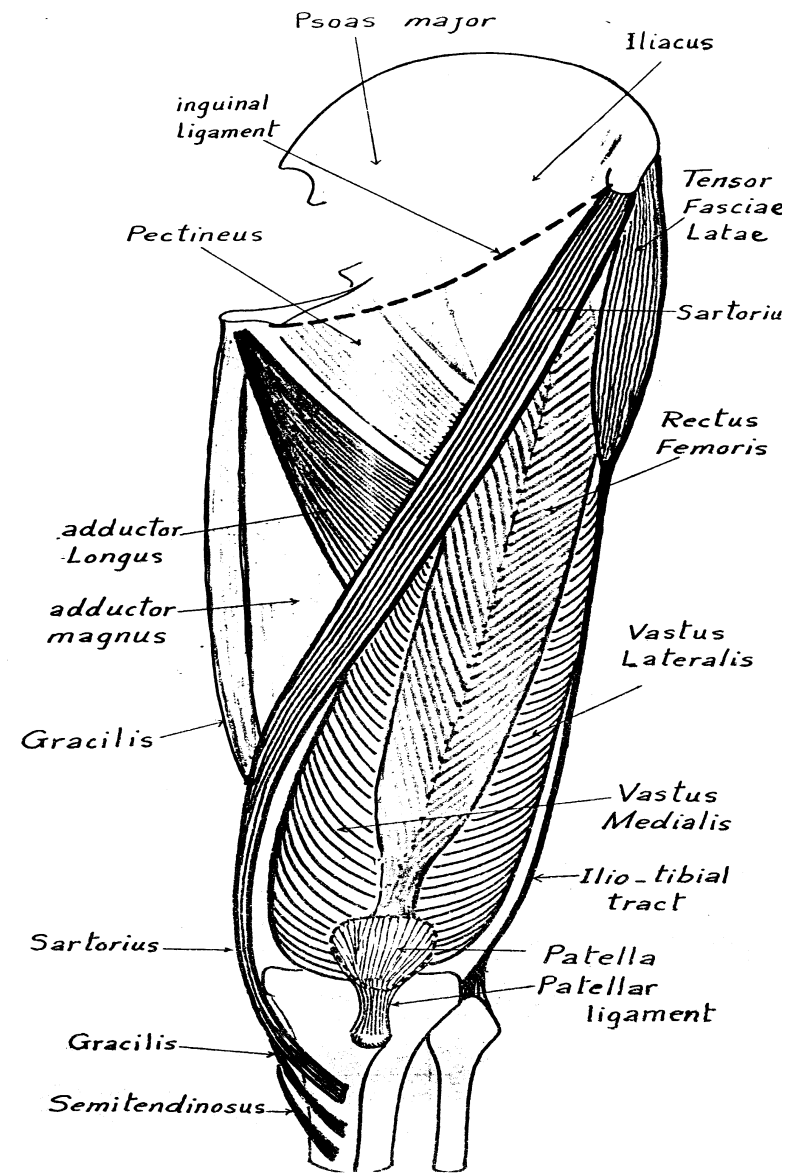
A. Muscles of front of the thigh (Extensors)

- All muscles are supplied by femoral nerve .

Muscle	Origin	Insertion	Main Action
1.Sartorius (but LL in Sartorius position)	<ul style="list-style-type: none"> • A.S.I.S 	<ul style="list-style-type: none"> • Upper part of med. surface of tibia (S.G.S) • It is the longest muscle in the body . 	<ul style="list-style-type: none"> • Flexion , abduction & lateral rotation of hip . • Flexion & medial rotation of knee.
2.Quadriceps femoris	<p>a)Rectus femoris:-by 2 heads</p> <ul style="list-style-type: none"> • Straight head : from A.I.I.S. • Reflected head : from above the acetabulum . <p>b)Vastus lateralis:Upper part of inter-trochanteric line, root of greater trochanter, lateral to gluteal tuberosity, upper ½ of lateral lip of linea aspera.</p> <p>c)Vastus medialis: lower part of inter-trochanteric line , spiral line, linea aspera, upper ½ of medial supracondylar ridge.</p> <p>d)Vastus intermedius :anterior & lateral surface of shaft of femur.</p>	<ul style="list-style-type: none"> • By a common quadriceps tendon into the patella then it extends as ligamentum patellae (which is inserted into tibial tuberosity) and medial & lateral patellar retinacula (which attached to medial & lateral condyles of tibia. 	<ul style="list-style-type: none"> • The only extensor of the knee . • In addition the rectus femoris flexes the hip.

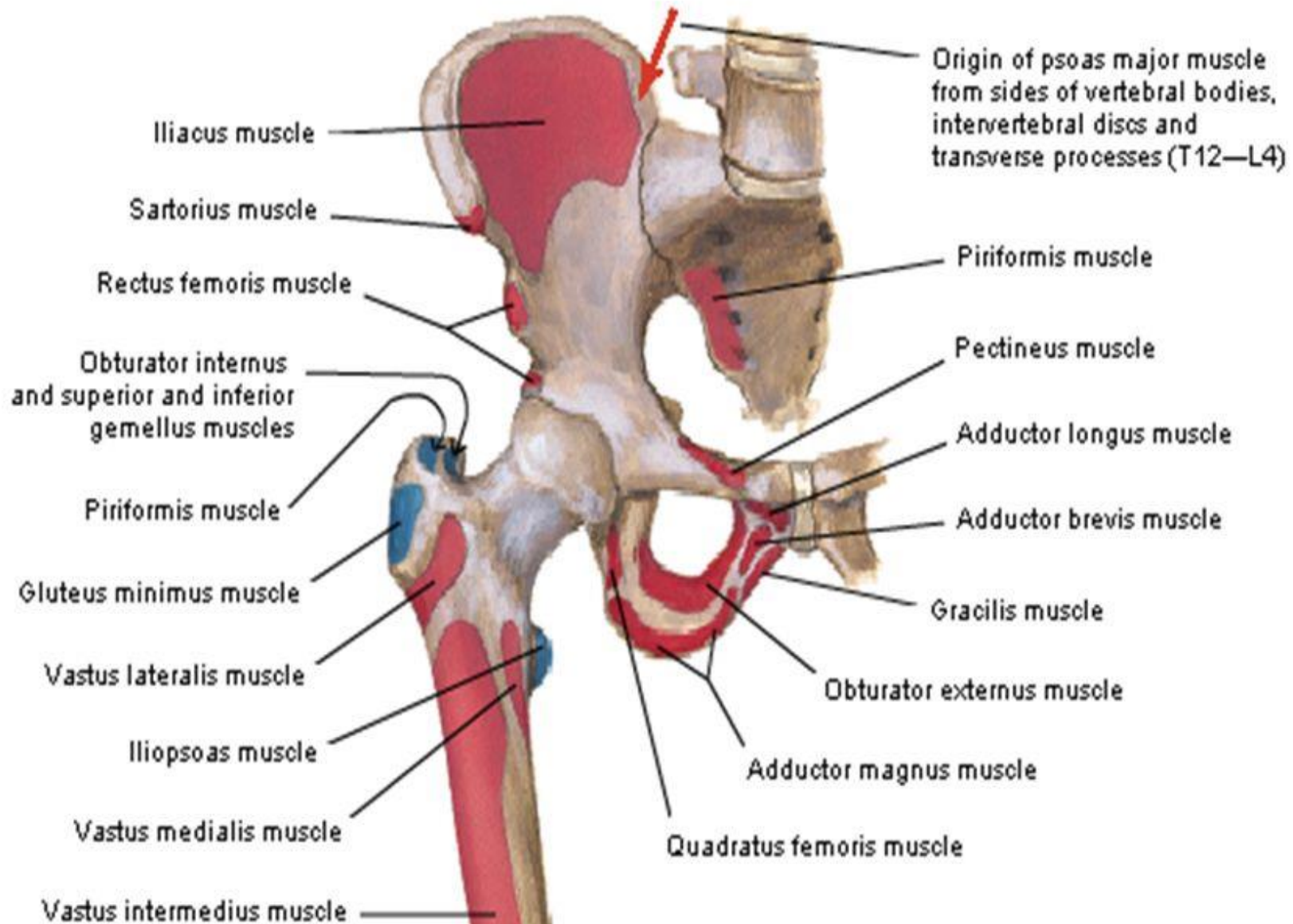


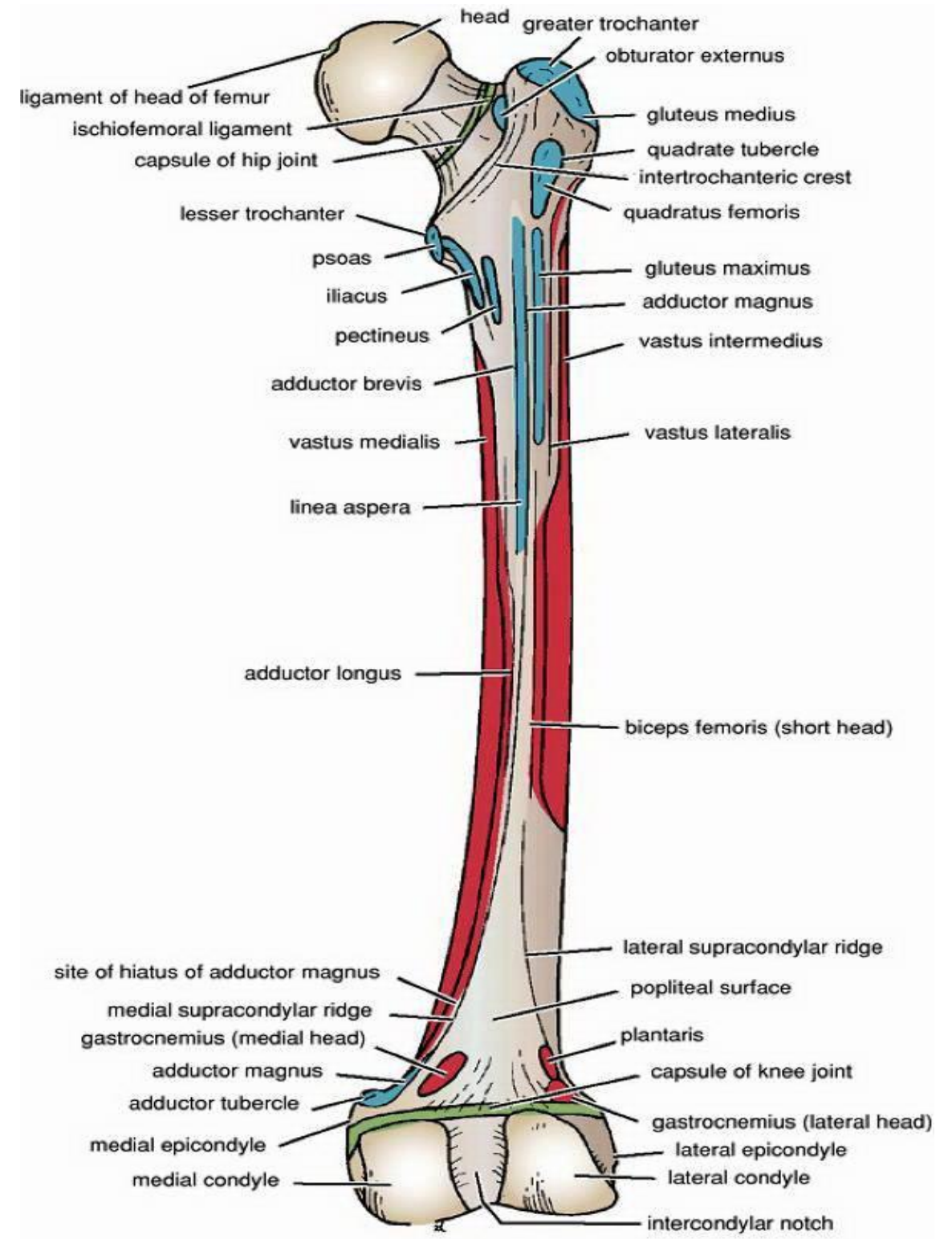
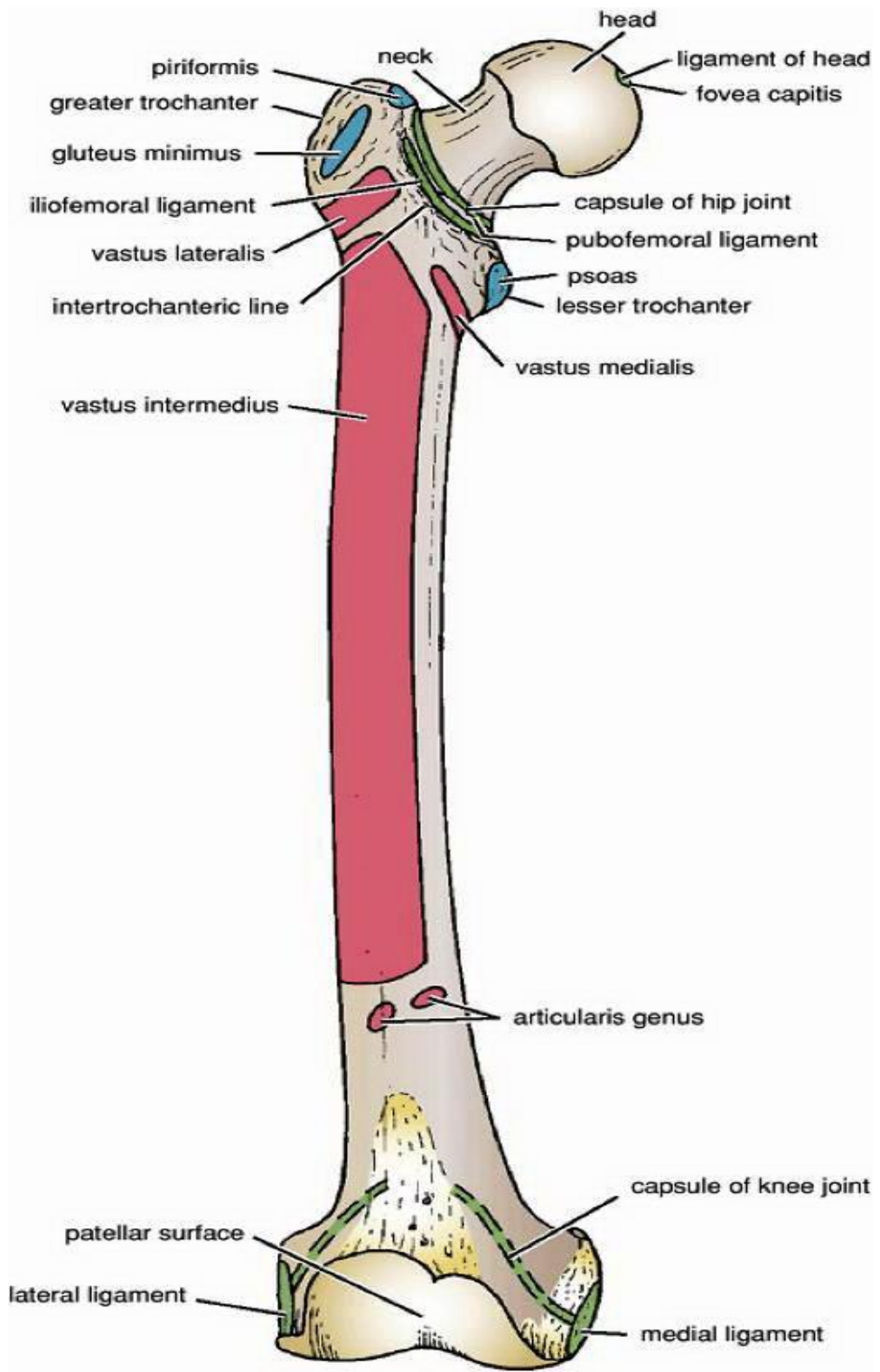
Psoas major and iliacus muscles.





HIP & THIGH MUSCLES ATTACHMENT (ANTERIOR VIEW)





m. tensor fasciae
latae

m. iliopsoas

m. pectineus

m. adductor longus

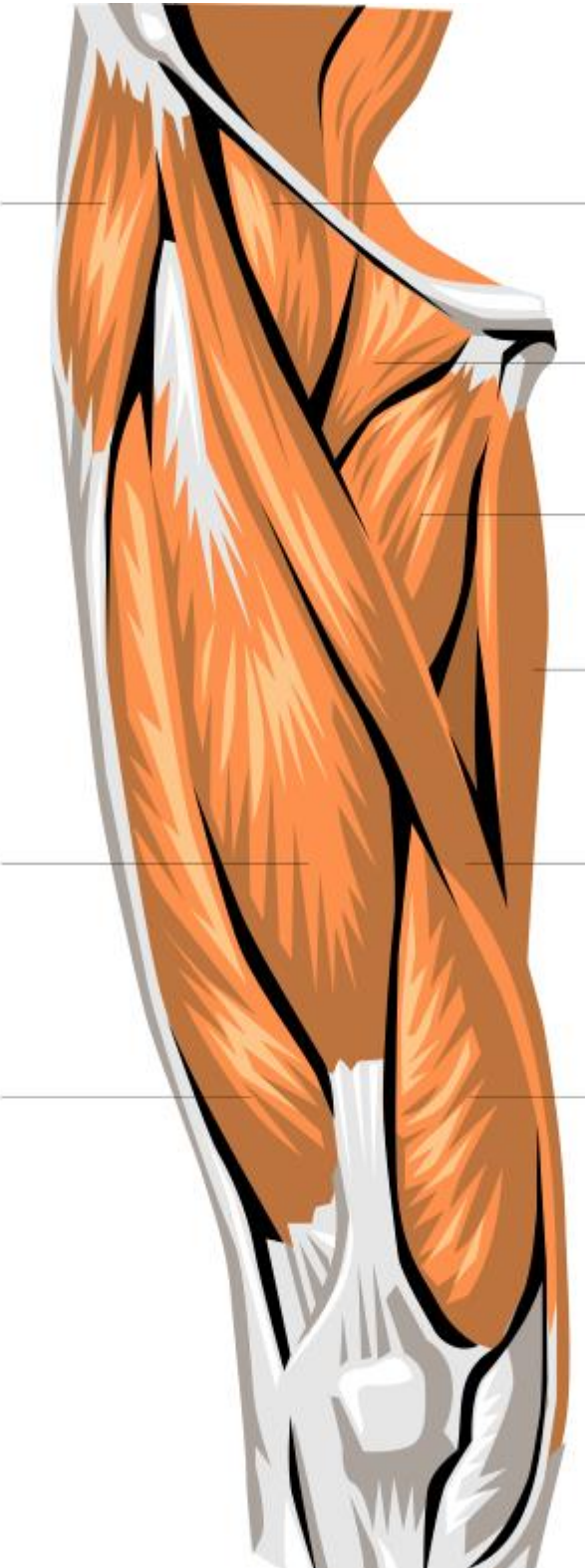
m. gracilis

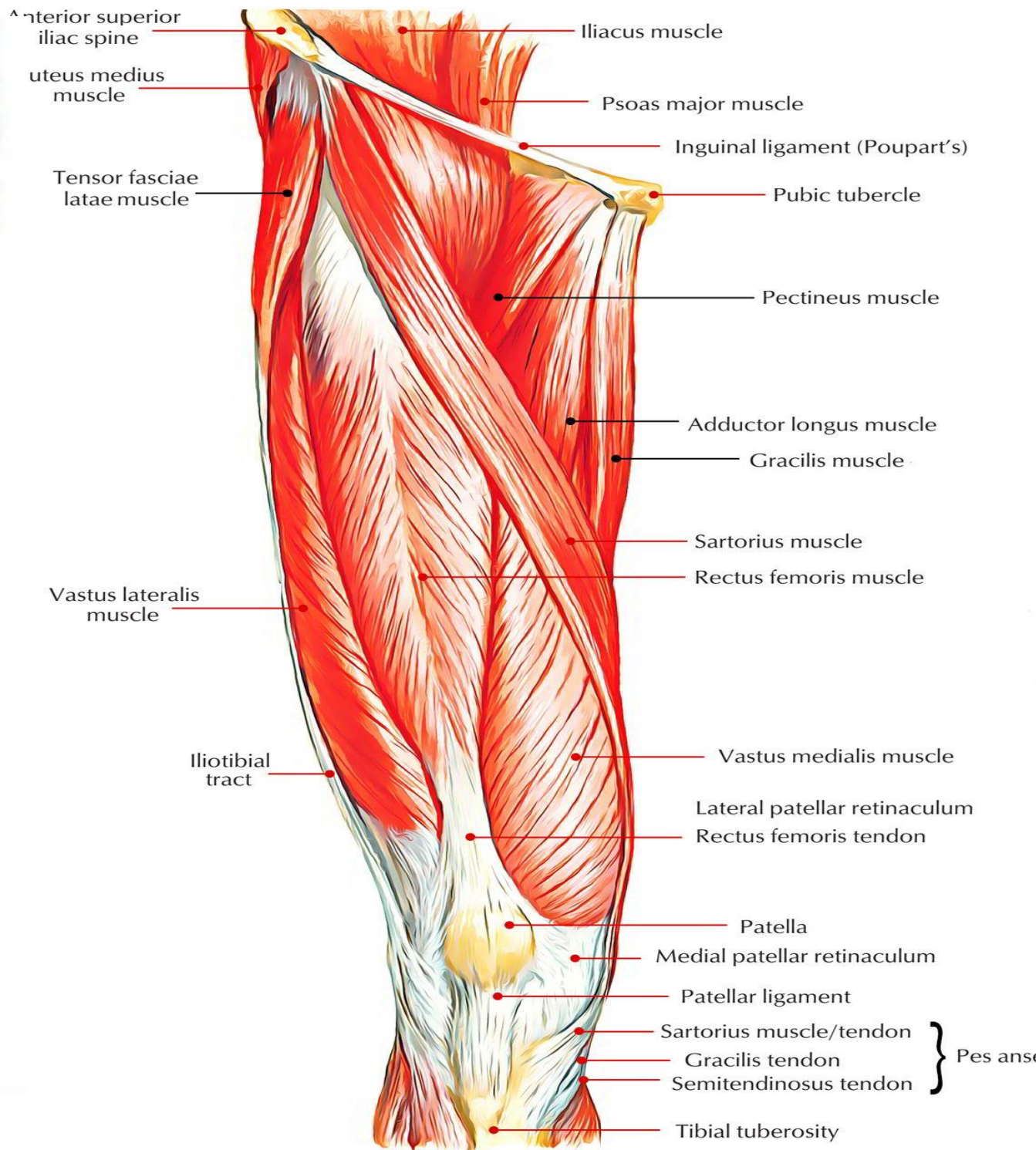
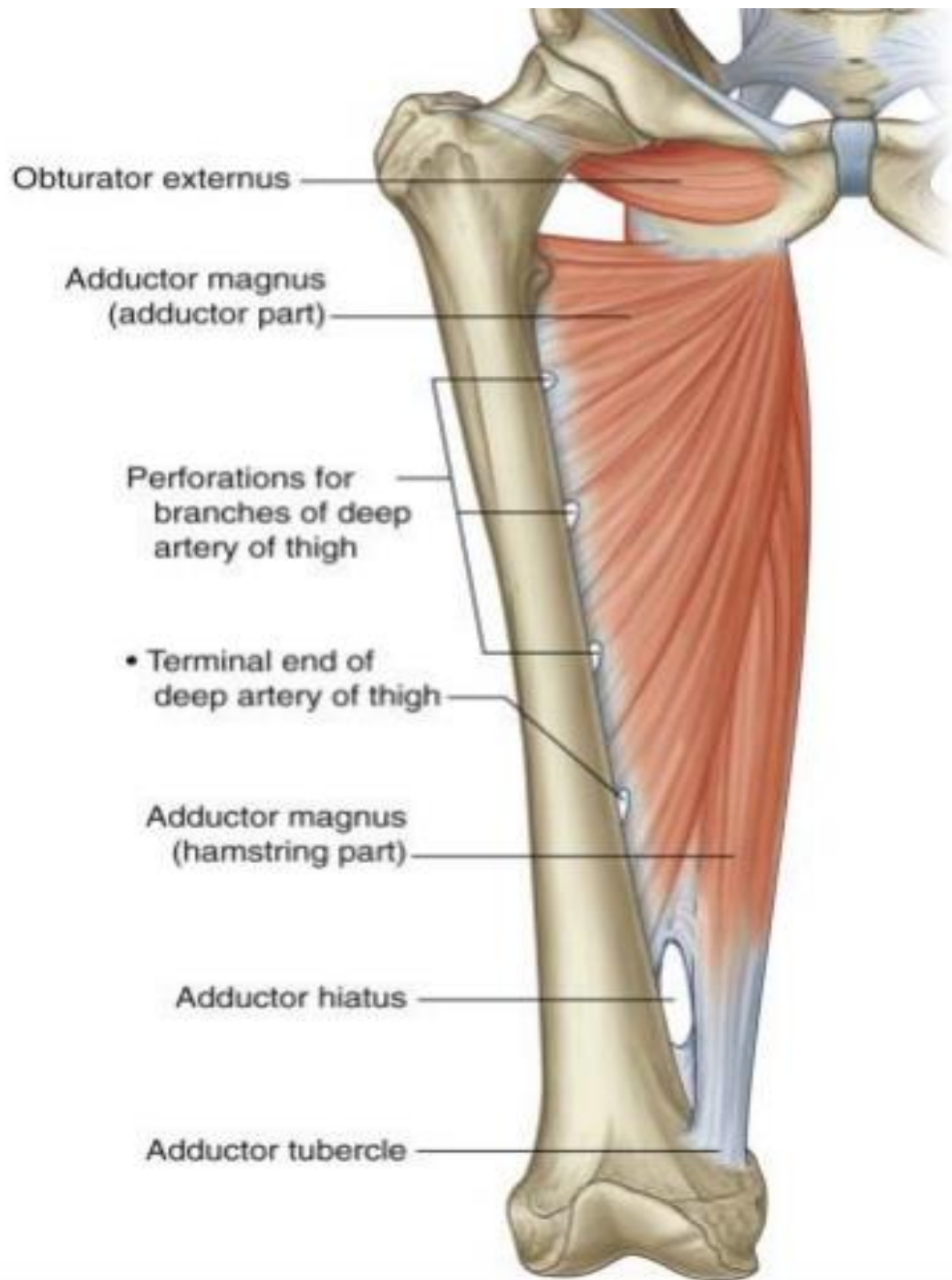
m. rectus femoris

m. sartorius

m. vastus lateralis

m. vastus medialis



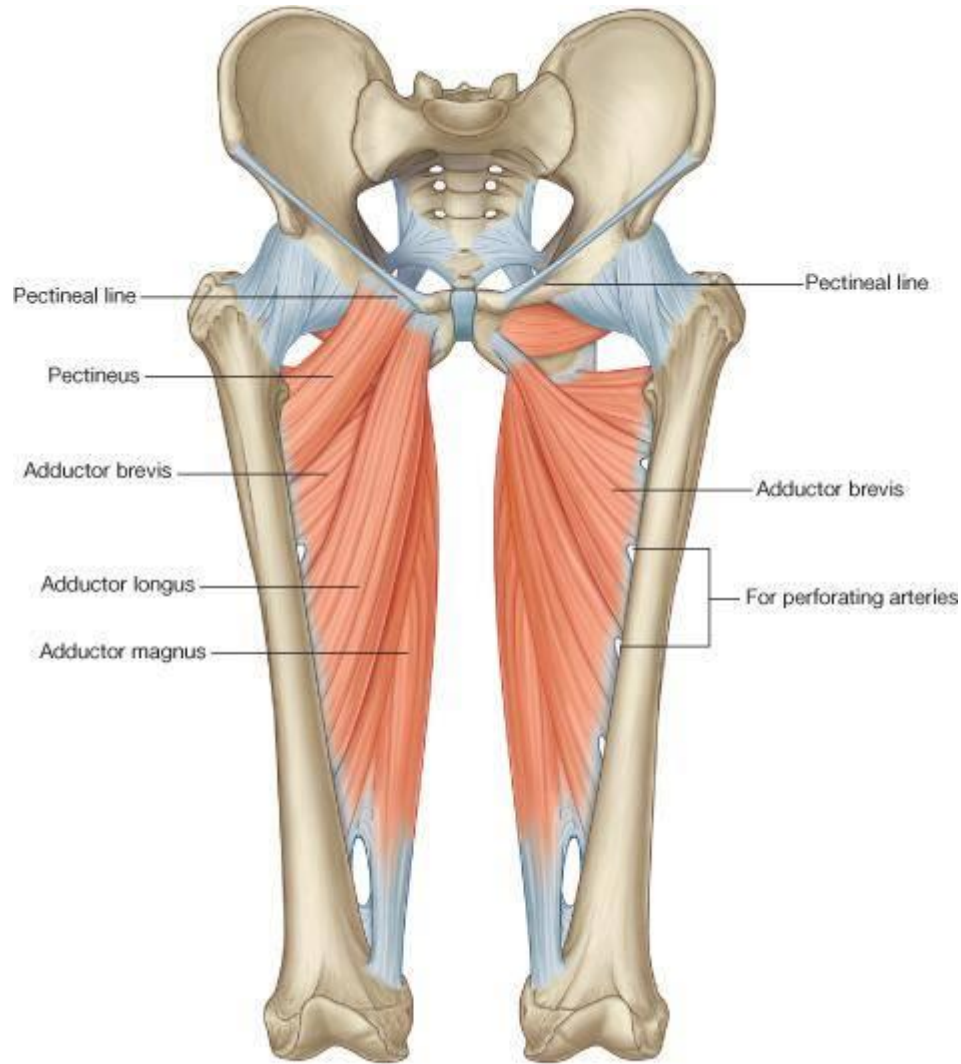


B. Muscles of the Medial Aspect of thigh (Adductors)

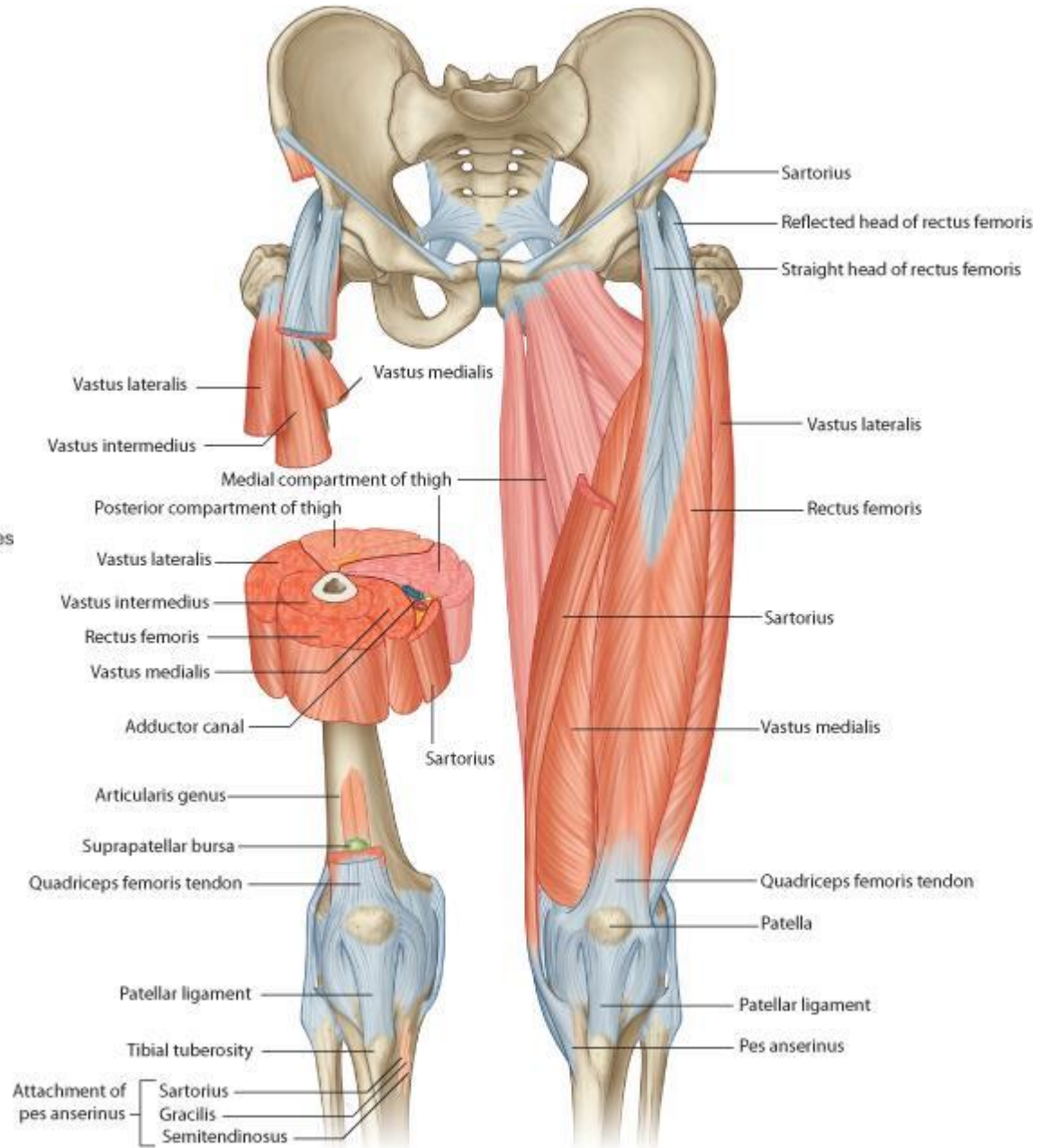
- All muscles are supplied by obturator nerve except the Pectineus (supplied by Femoral nerve) & ischeal part of Adductor magnus (supplied by Sciatic nerve).
- Common origin : Body of pubic bone & inferior pubic ramus (except pectineus & adductor magnus).
- Common action : Adduction of hip joint .

Muscle	Origin	Insertion	Main Action
1- Gracilis	• Body of pubic bone & inferior pubic ramus	• S.G.S behind the sartorius	• Adduction of thigh . • Flexion & medial rotation of leg.
2- Pectineus	• Pectineal line & surface of superior pubic ramus.	• Pectineal line of femur	• Flexion & adduction of hip joint .
3- Adductor Longus	• Body of pubic bone just below the pubic tubercle.	• Linea aspera	• Adduction of thigh. • Its tendon is a landmark for pubic tubercle.
4- Adductor brevis	• Body of pubic bone & inferior pubic ramus.	• Linea aspera	• Adduction of thigh
5- Adductor magnus	a) Pubic part: conjoint ramus b) Ischeal part: from lower triangular part of ischeal tuberosity	a) pubic part: medial aspect of gluteal tuberosity of femur , linea aspera & medial supracondylar ridge. b) Ischeal part: adductor tubercle. *Adductor hiatus lies between the 2 parts (end of femoral artery).	a) Pubic part: adduction of thigh b) Ischeal part: Extend the hip .

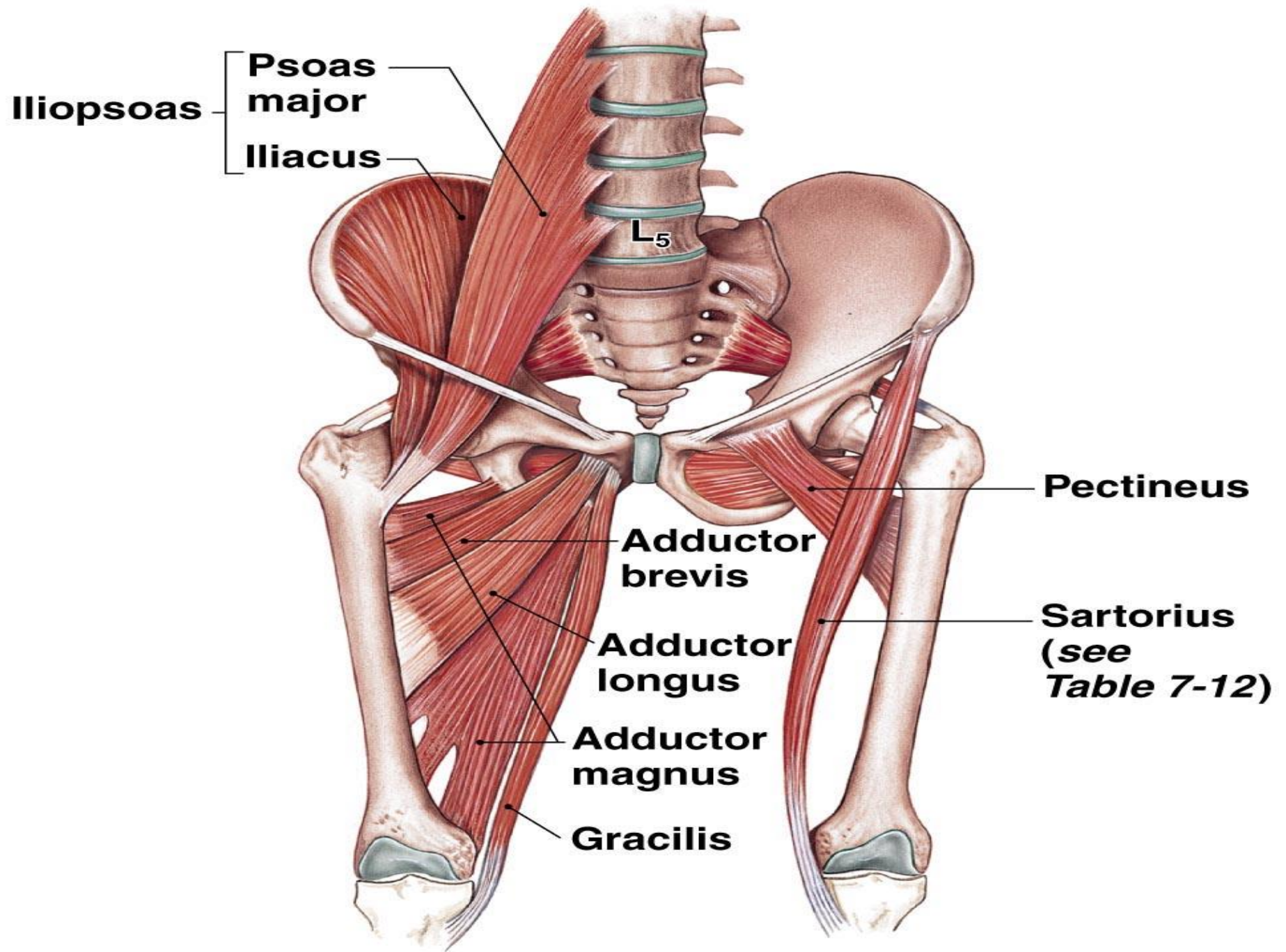
- ★ Gracilis form with shaft of femur a letter V in which other adductors are arranged in 3 layers:
- The first layer: pectineus and adductor longus.
 - The second layer: adductor brevis.
 - The third layer: adductor magnus.



© Elsevier. Drake et al: Gray's Anatomy for Students - www.studentconsult.com



© Elsevier. Drake et al: Gray's Anatomy for Students - www.studentconsult.com



(c) The iliopsoas muscle and the adductor group

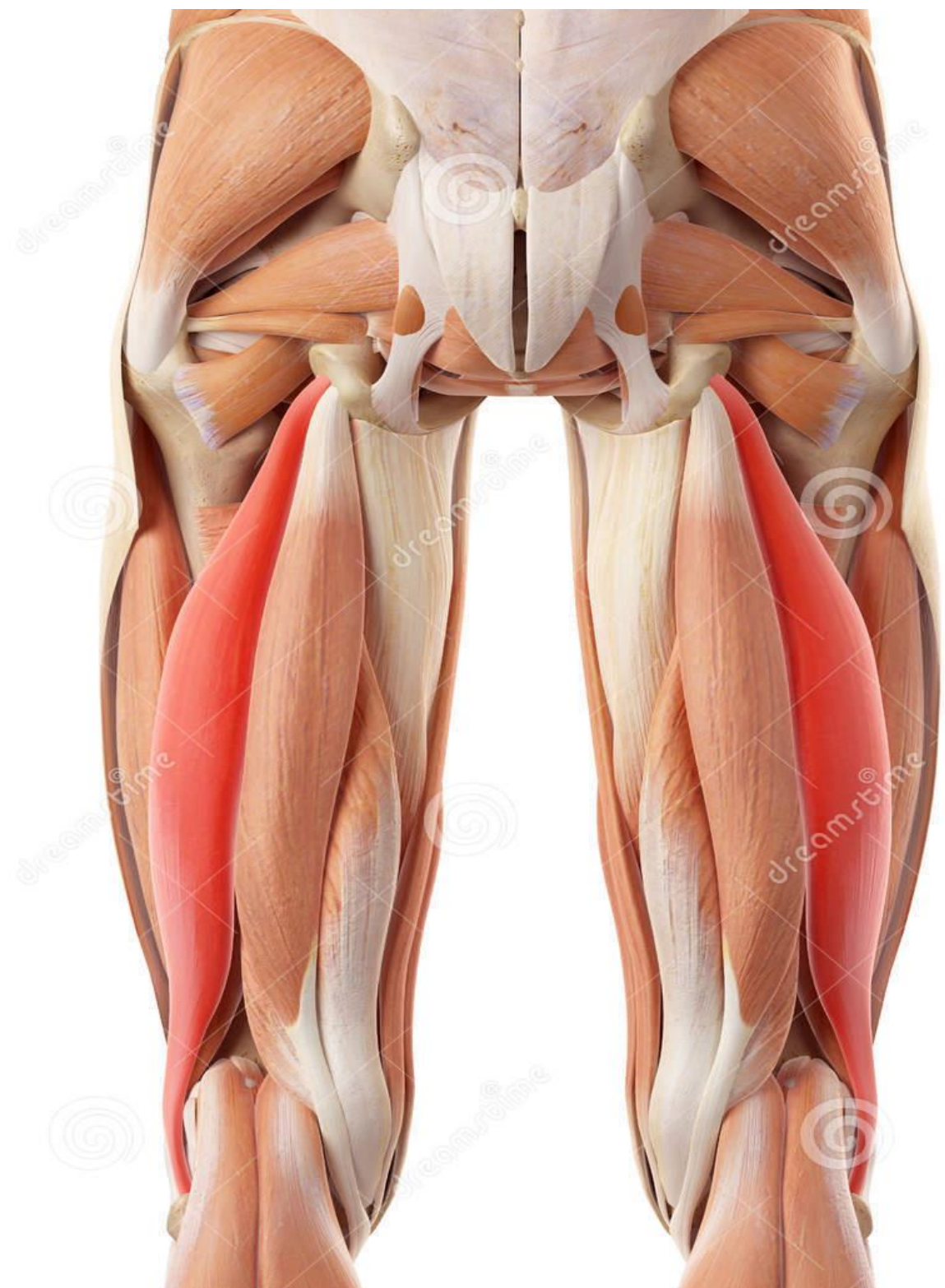
**C. Muscles of Back of Thigh (Flexors)
(Hamstring Muscles)**

- **Common origin : ischeal tuberosity except short head of biceps which originate from linea aspera .**
- **All these muscles are supplied by sciatic nerve .**
- **Common action: Extension of hip (as all muscles originate from ischeal tuberosity) and flexion of knee (main action) .**
- **From lateral to medial they are:**

Muscle	Origin	Insertion	Main Action
1- Biceps femoris	a) Long head: as semitendinosus . b) Short head: Linea aspera	• Head of fibula .	• Common action + lateral rotation of leg (Locking of knee joint).
2- Semitendinosus	• With the long head of biceps from the lower medial part of the upper quadrangular part of ischeal tuberosity.	• S.G.S. behind sartorius & gracilis .	• Common action + medial rotation of the leg . (unlocking of knee joint).
3-Semimembranosus	• Upper lateral part of the upper quadrangular part of ischeal tuberosity	• Back of medial condyle of tibia, capsule of knee joint , popliteal fascia & soleal line .	• As no. 2.

***Important notes :**

- 1- All muscles originate from ischeal tuberosity extend the hip joint .**
- 2- Nearly all muscles originate from ischeal tuberosity are supplied by sciatic nerve .**
- 3- All muscles inserted in upper part of tibia (SGS , Semimembranosus &Popliteus) flex & medial rotate the leg (unlocking of knee joint).**

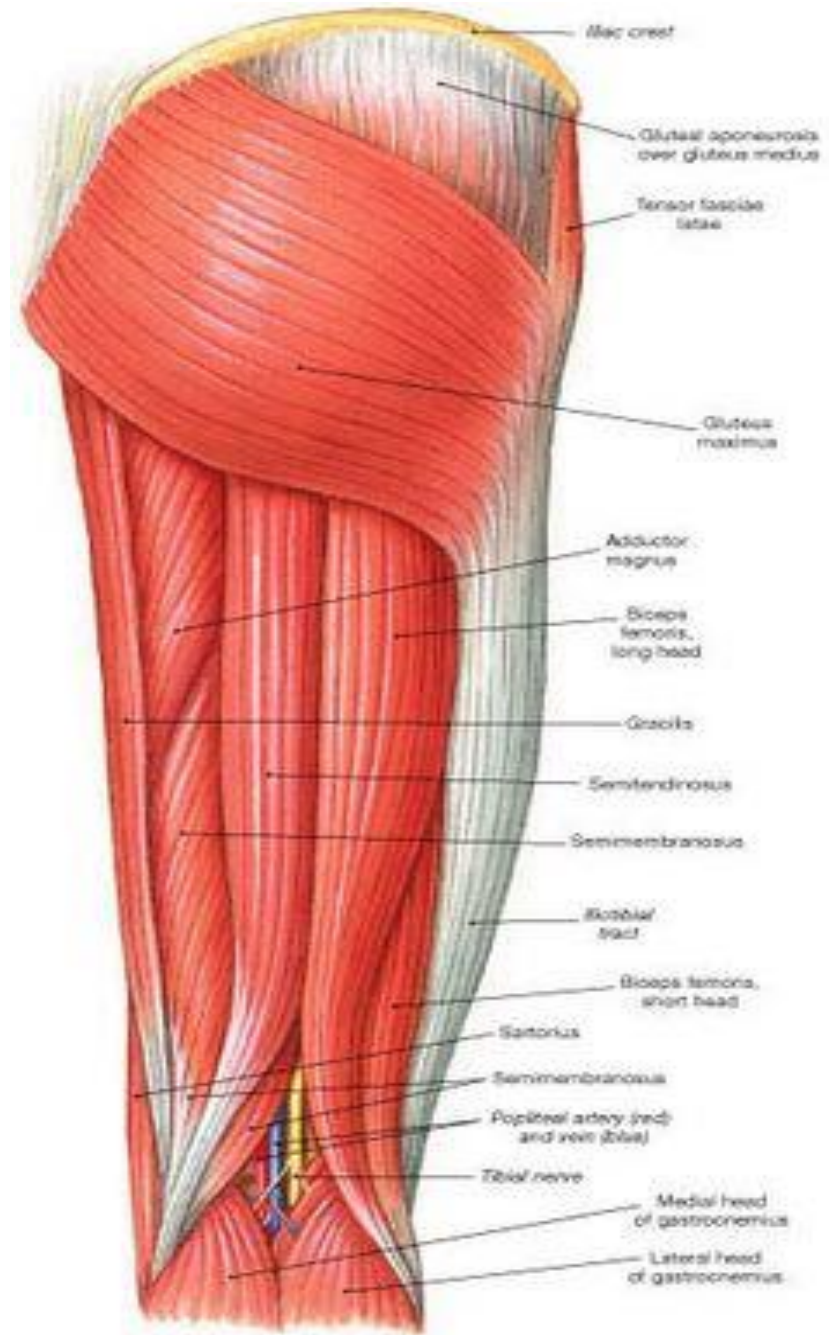
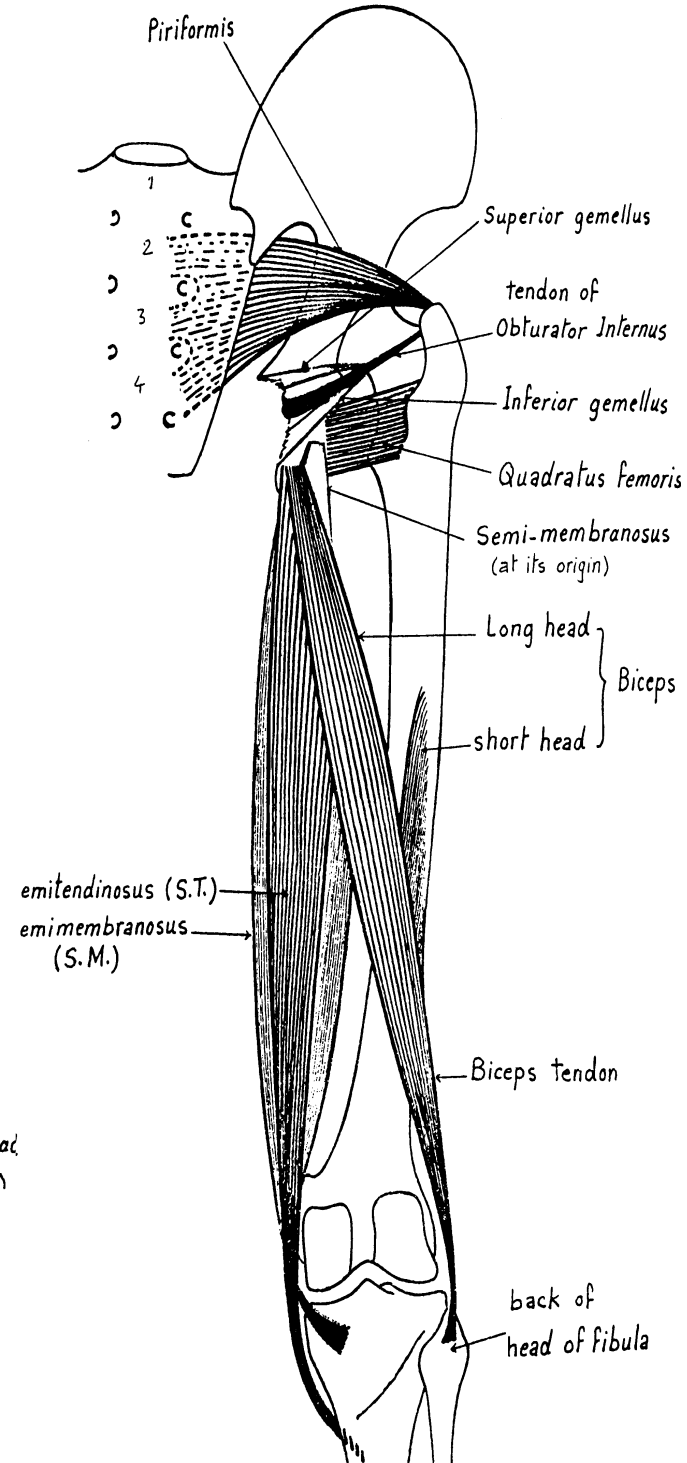
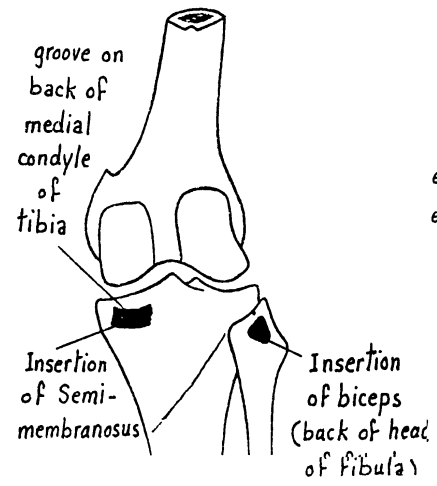
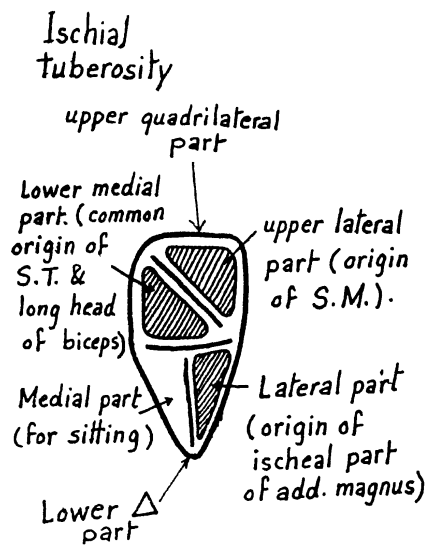


Download from
Dreamstime.com

This watermarked comp image is for previewing purposes only.

ID 58450325

© Sebastian Kaultzki | Dreamstime.com



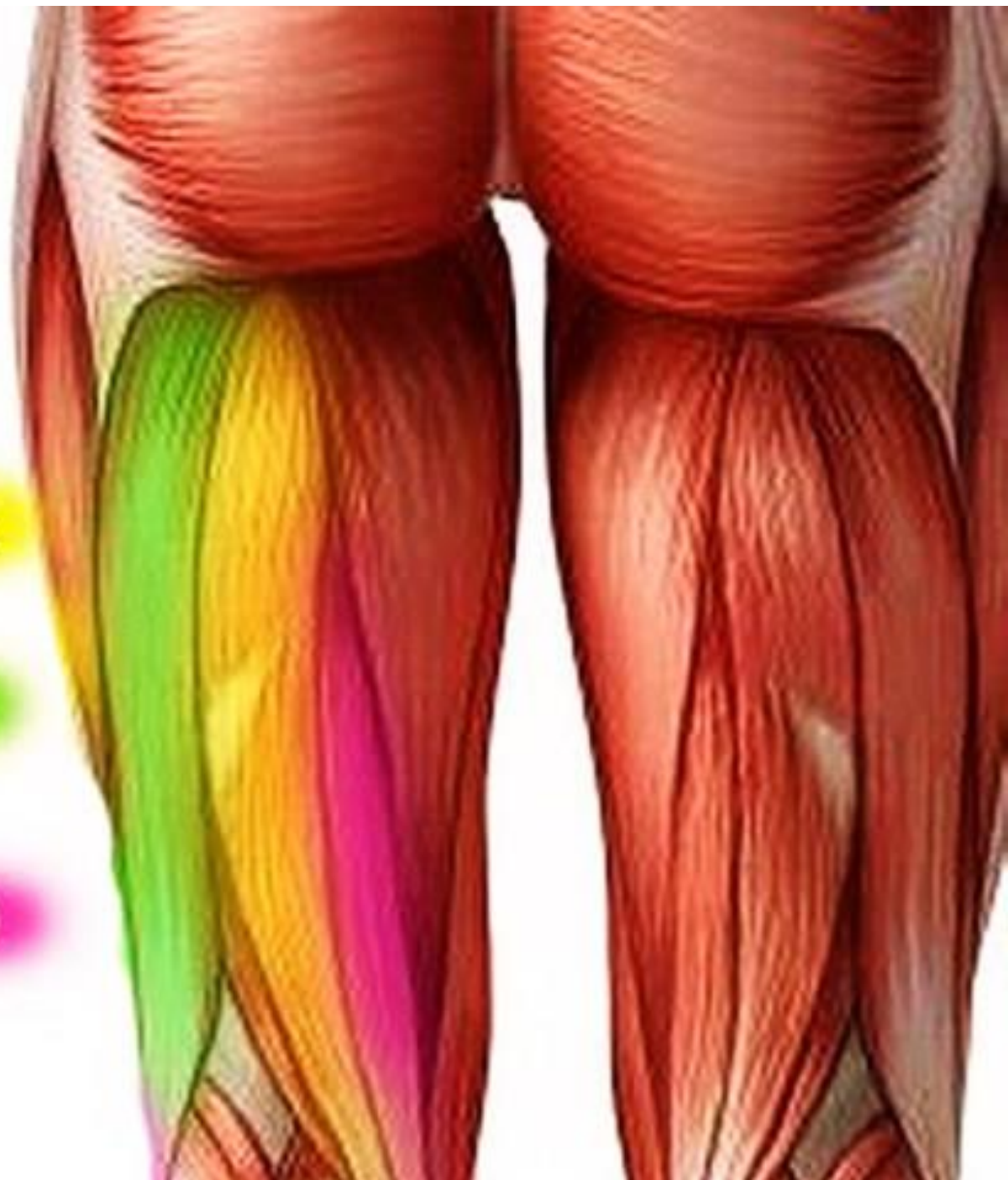(a) Hip and thigh, posterior view

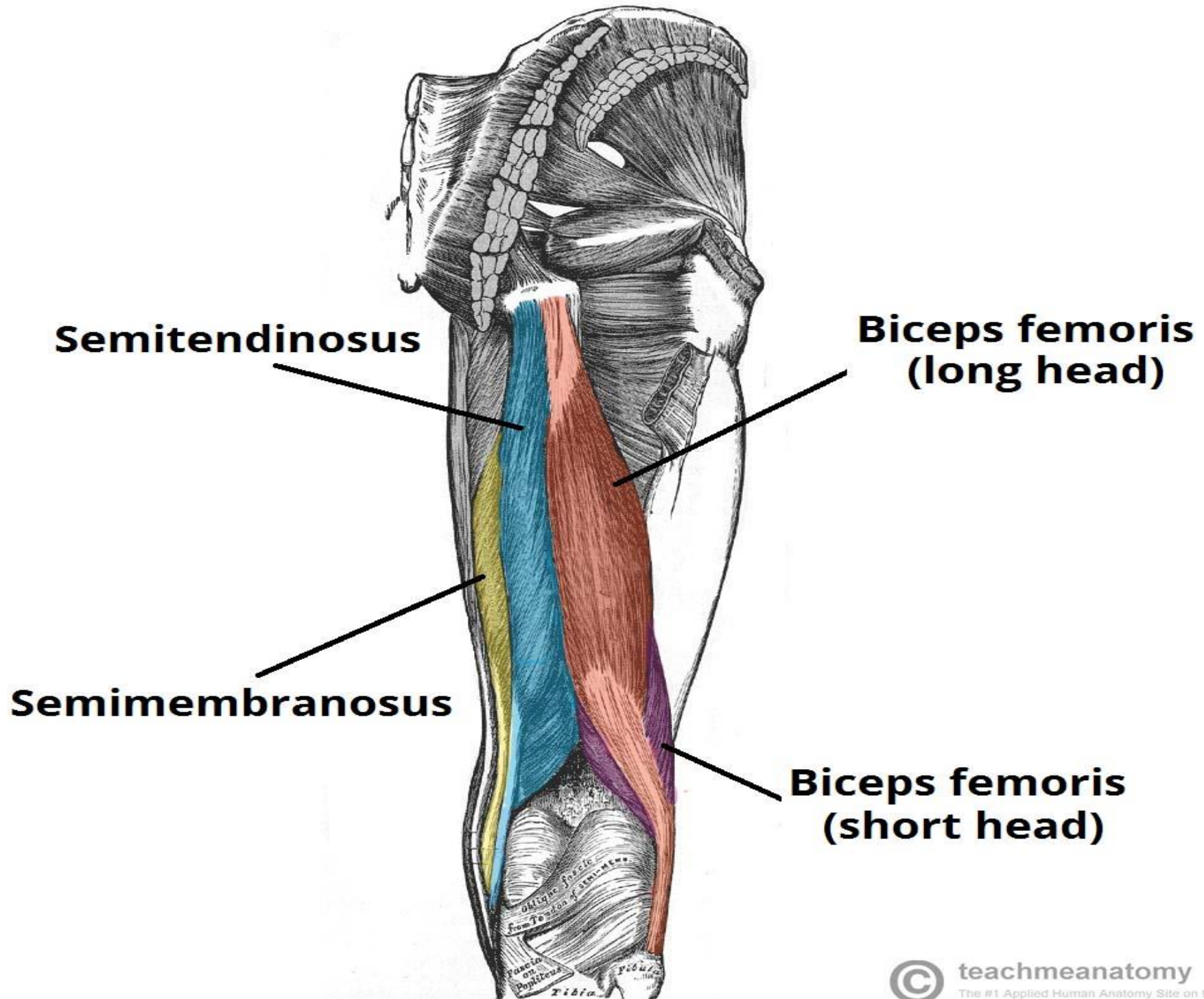
**MUSCOLI
POSTERIORI
DELLA COSCIA**

BICIPITE FEMORALE

SEMITENDINOSO

SEMIMEMBRANOSO





Semitendinosus

**Biceps femoris
(long head)**

Semimembranosus

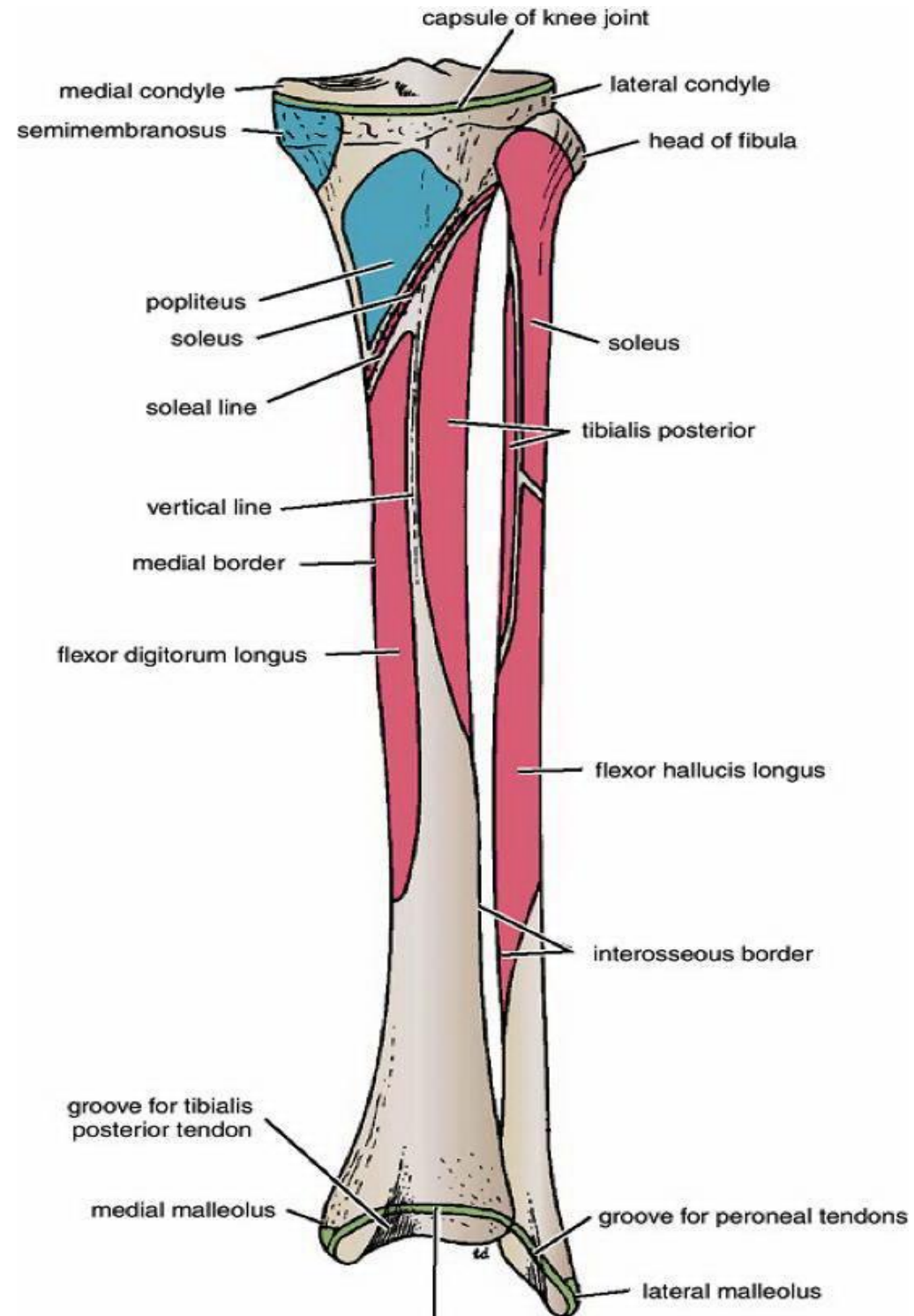
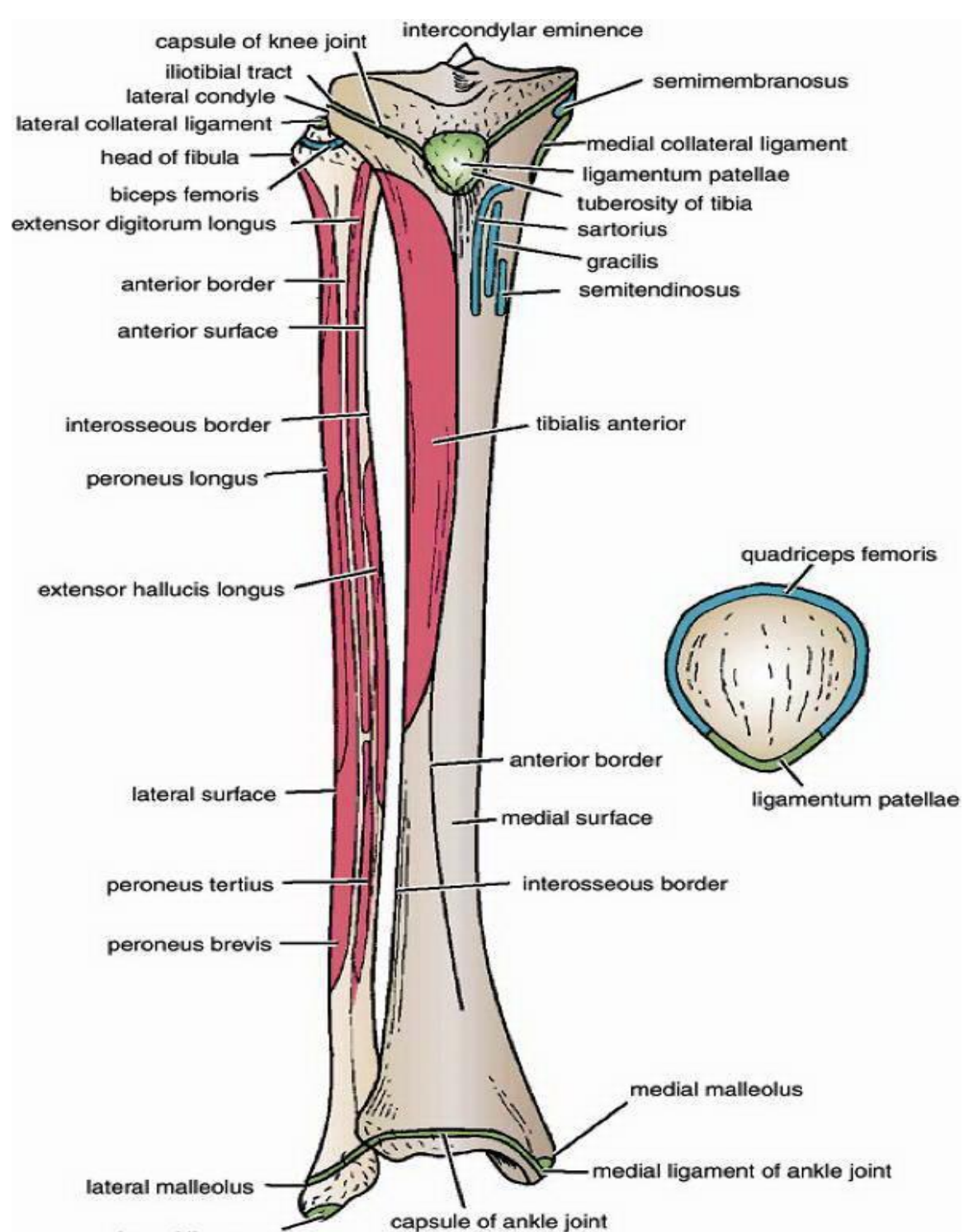
**Biceps femoris
(short head)**

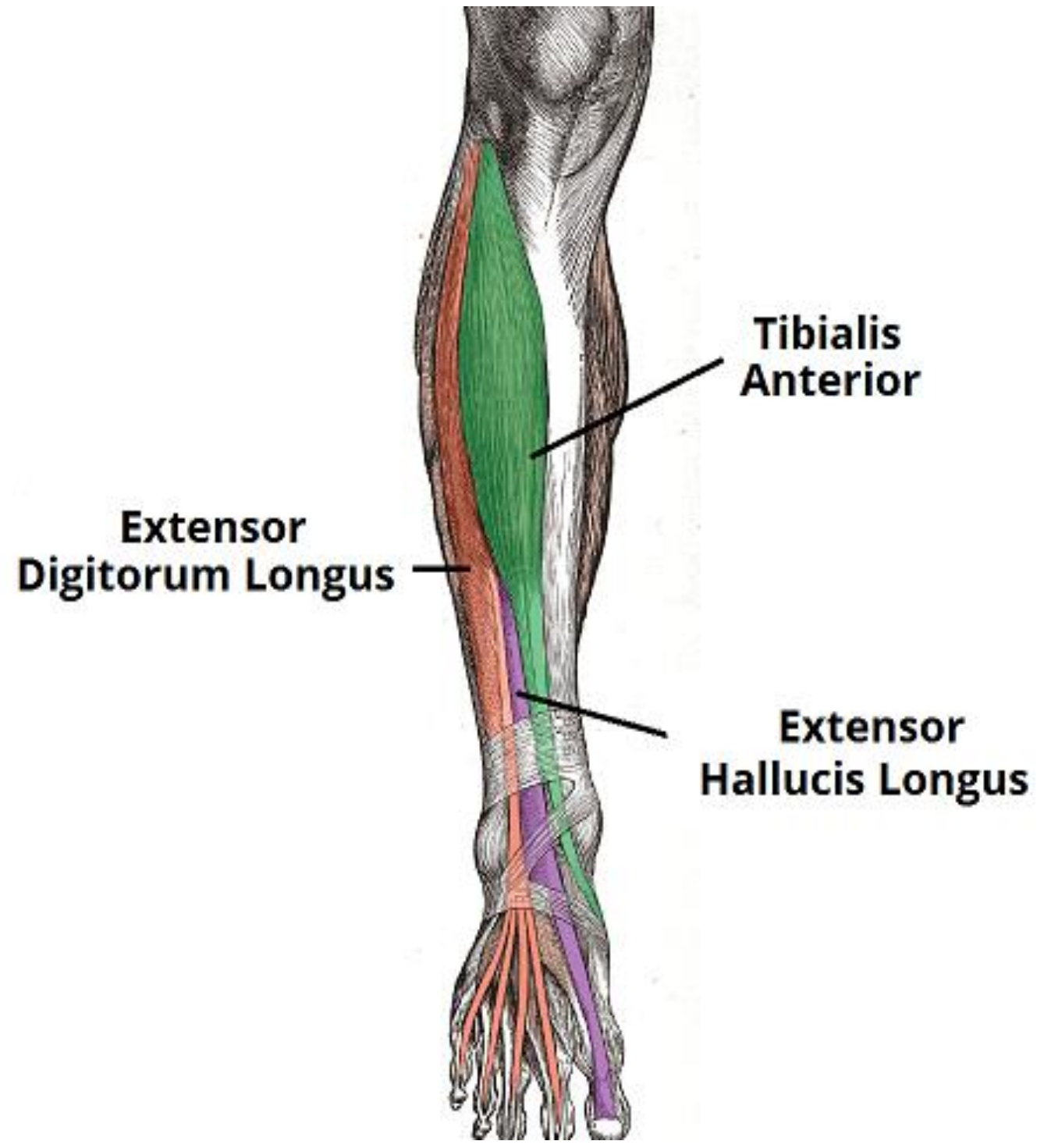
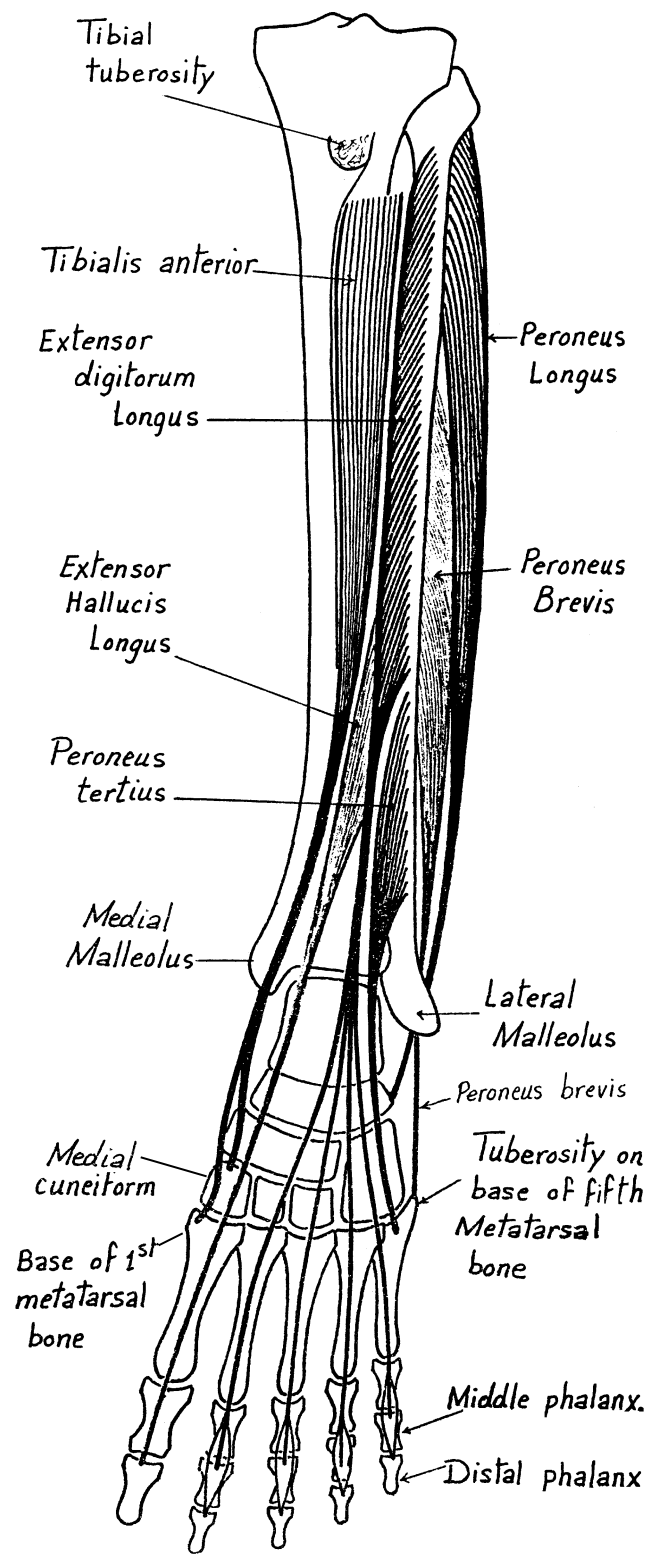
IV. Muscles of Leg.

A. Muscles of Front leg. (Extensors or Dorsiflexors)

- These muscles pass in front of ankle from medial to lateral "Tom has very nice dog & pig"
- Anterior Surface of fibula (except tibialis anterior) & interosseous membrane.
- All muscles are supplied by deep fibular nerve .
- Common action: Extension "Dorsiflexion" of ankle joint with the medial 2 muscles produce inversion & lateral 2 muscles produce eversion .
- From medial to lateral they are:

Muscle	Origin	Insertion	Main Action
1-Tibialis anterior	• Upper ½ of lateral surface of tibia & interosseous membrane.	• Medial cuneiform bone & base of 1 st . metatarsal bone .	• Extend the ankle • Invert the foot.
2-Extensor hallucis longus	• Anterior Surface of fibula & interosseous membrane.	• Base of terminal phalanx of big toe.	• Extend the big toe & ankle • Invert the foot.
3-Extensor digitorum longus	• Anterior Surface of fibula & interosseous membrane.	• By 4 tendons into the extensor expansion of lateral 4 toes .	• Extend the ankle & lateral 4 toes • Evert the foot.
4- Fibularis tertius	• Anterior Surface of fibula & interosseous membrane.	• Base of 5 th . metatarsal bone .	• Extend the ankle . • Evert the foot.

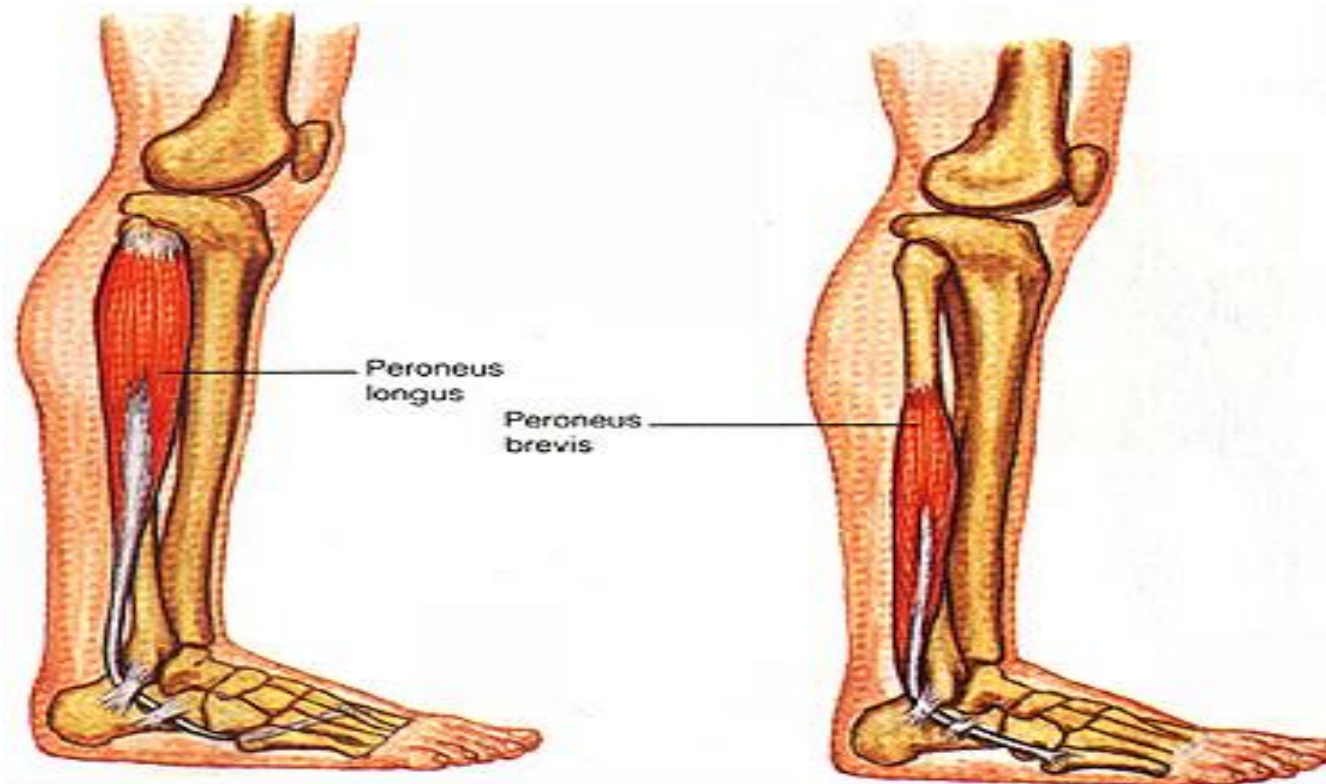




B. Muscle of lateral Aspect of leg. (Evertors)

- The muscles pass behind lateral malleolus.
- Common origin : lateral surface of fibula .
- All muscles are supplied by Superficial fibular nerve.
- Common action : Eversion & maintain the transverse arch of foot.

Muscle	Origin	Insertion
1. Fibularis longus (superficial)	• Upper 2/3 of lateral surface of fibula.	• Its tendon pass from lateral to medial in the sole of the foot to insert in medial cunifrom bone & base of 1st metatarsal bone (as tibialis anterior).
2. Fibularis brevis (deep)	• Lower 2/3 of lateral surface of fibula.	• Tuberosity of 5th metatarsal bone



C. Muscles of back of leg (flexors or plantar flexors)

a) Superficial group.

- All muscles pass behind the ankle.
- All muscles are supplied by Tibial nerve
- Common action: Plantar flexion of foot .

Muscle	Origin	Insertion	Action
1. Gastrocnemius	a- Lateral Head: lateral surface of lateral condyle of femur b- Medial Head: Popliteal surface of femur above the medial Condyle	• By tendo-calcaneus (tendoachilis) into posterior surface of calcaneus.	• Common action . • Help flexion of knee .
2. Soleus	• Posterior aspect of head & upper 1/3 of shaft of fibula, fibroteninous arch between tibia & fibula, soleal line & middle 1/3 of medial border of tibia .		• Common action
3- Plantaris	• Lower end of lateral supracondylar ridge .		• Common action

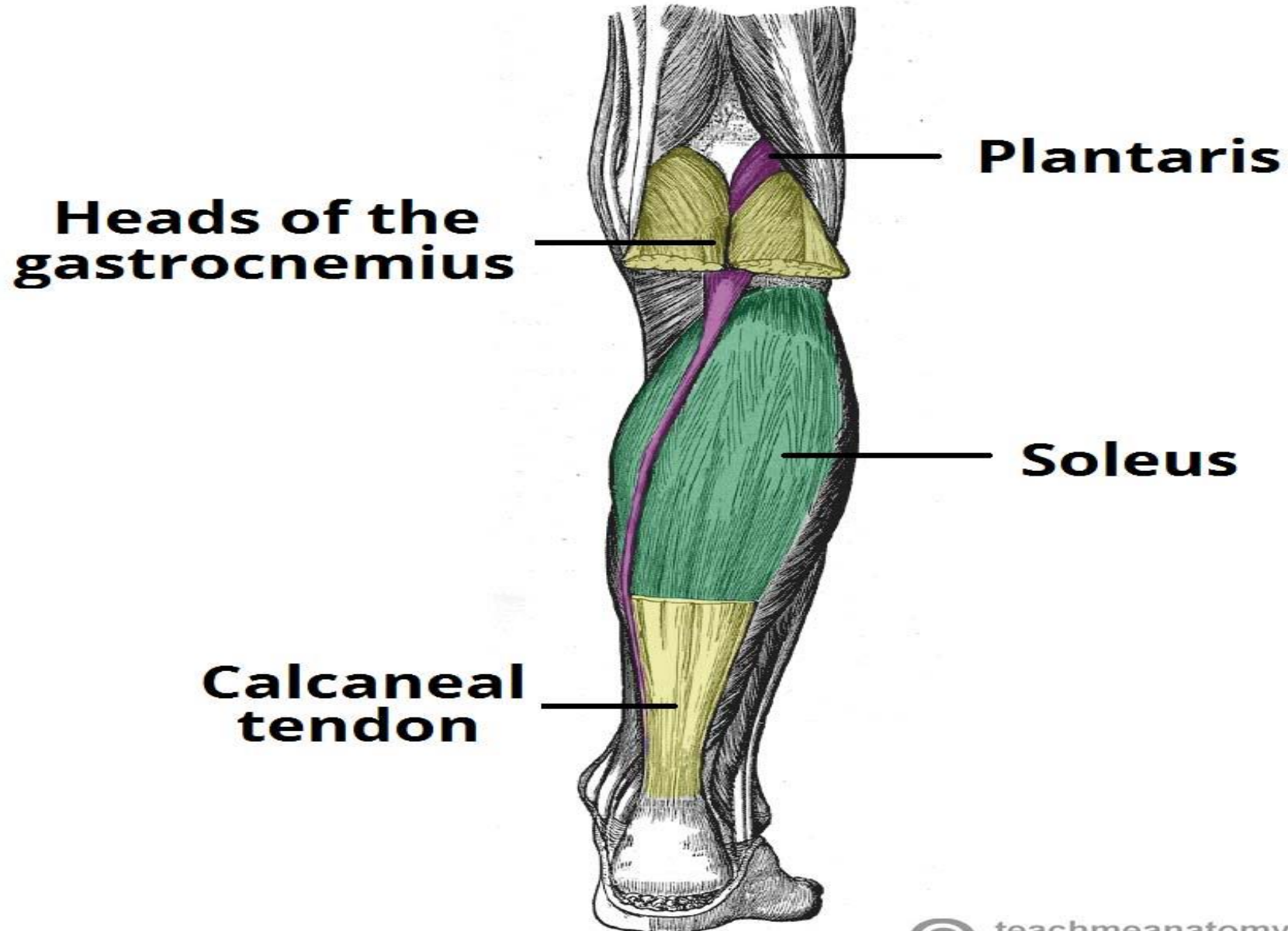
b) Deep Group.

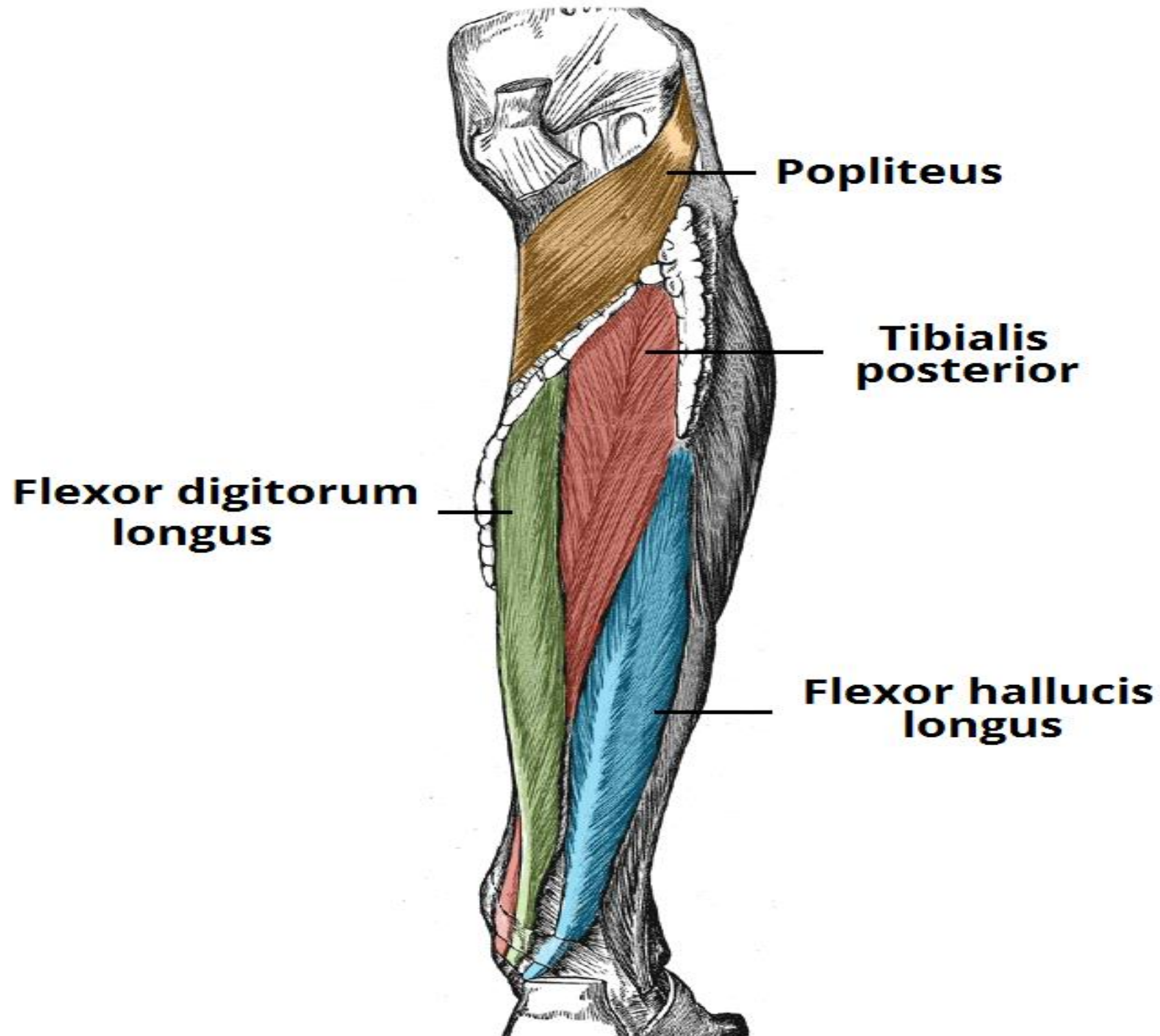
- All muscles pass behind medial malleolus (except popliteus). " Tom Dose Very Nice Hat "
- All muscles are Supplied by tibial nerve .
- Common action: Plantar flexion of ankle and maintain longitudinal arches of foot (except popliteus) .

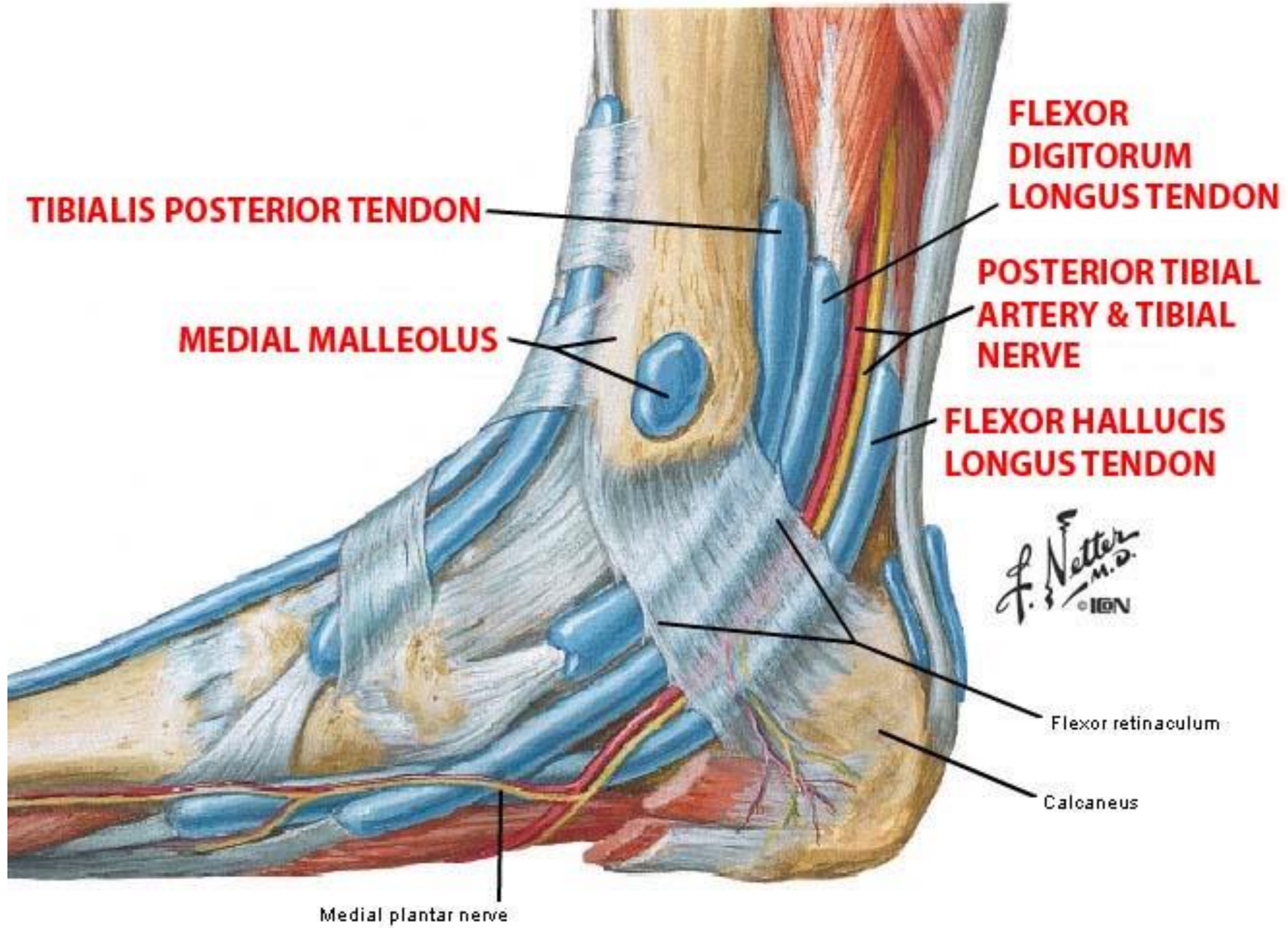
Muscle	Origin	Insertion	Main Action
1- Popliteus	• Groove on the lateral surface of lateral condyle of femur.	• Posterior surface of tibia above soleal line.	• Flexion & Medial rotation of knee at beginning of flexion (unlocking).
2- Flexor hallucis longus	• Posterior surface of fibula.	• Base of terminal phalanx of big toe.	• Flexes the ankle & big toe. • Invert the foot.
3- Flexor digitorum longus	• Back of tibia below soleal line.	• By 4 tendons into the base of terminal phalanx of lateral 4 toes.	• Flexes the ankle & lateral 4 toes.
4- Tibialis posterior	• Posterior surface of tibia & fibula & interosseous membrane.	• Tuberosity of navicular bone & all tarsal bones except talus.	• Flexes the ankle & invert the foot.

* Important notes :

- 1- All muscles of back of the leg are supplied by tibial nerve .
- 2- Any tibialis muscle invert the foot .
- 3 Any fibularis muscle evert the foot .







Layers of The Sole Of the Foot

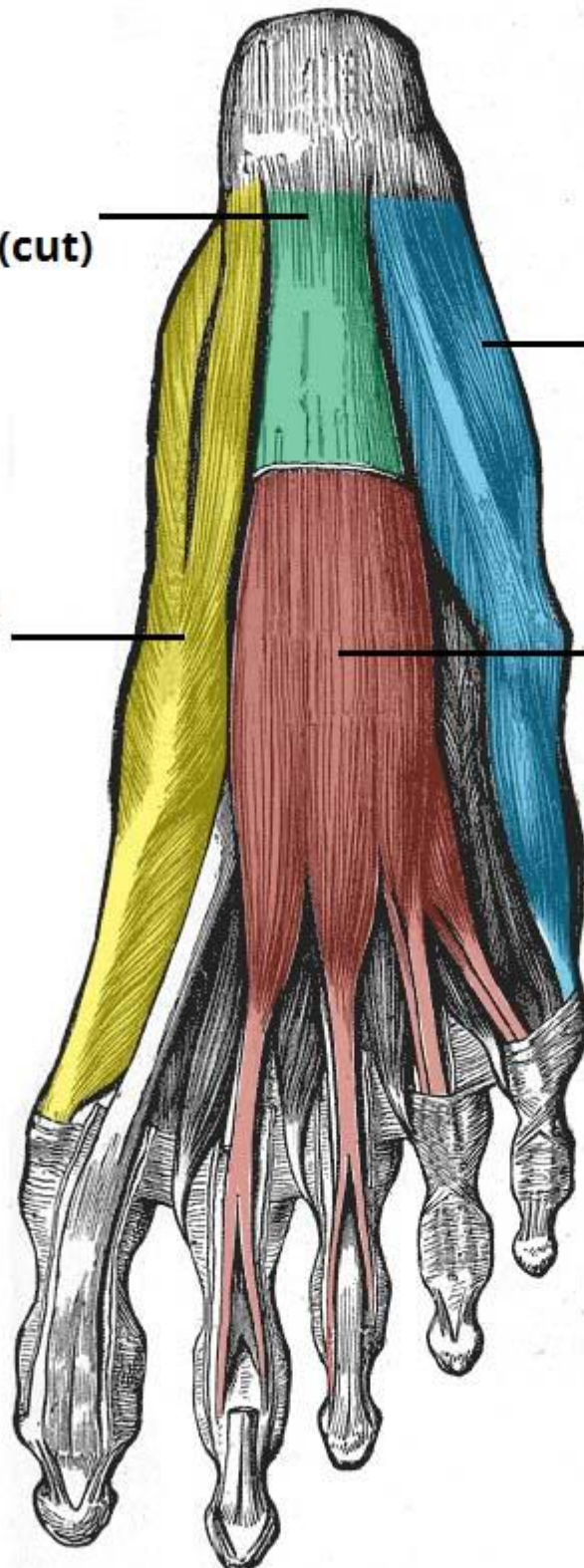
Layer	Muscle	Tendon
* 1st layer : (3 muscles)	<ul style="list-style-type: none"> • Abductor hallucis. • Abductor digiti minimi. • Flexor digitorum brevis. 	
* 2nd layer : (2 muscles & 2 tendons)	<ul style="list-style-type: none"> • Four lambricals. • Flexor accessorius. 	<ul style="list-style-type: none"> • Flexor hallucis longus. • Flexor digitorum longus.
* 3rd layer : (3 muscles)	<ul style="list-style-type: none"> • Adductor hallucis. • Flexor hallucis brevis. • Flexor digiti minimi brevis 	
* 4th layer : (2 muscles & 2tendons)	<ul style="list-style-type: none"> • 3 Plantar interossei • 4 dorsal interossei 	<ul style="list-style-type: none"> • Peroneus longus. • Tibialis posterior.

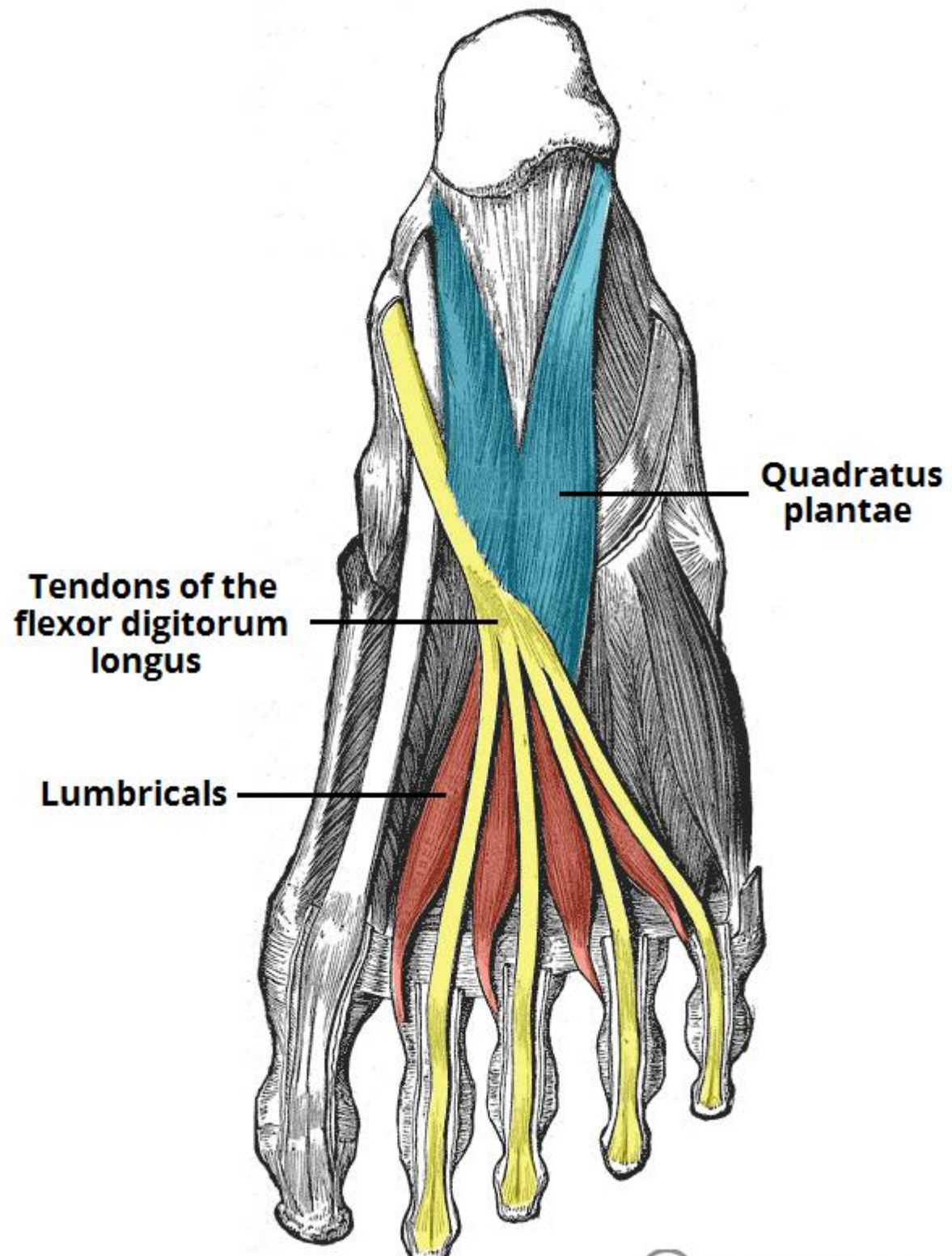
**Plantar
aponeurosis (cut)**

**Abductor digiti
minimi**

**Abductor
hallucis**

**Flexor digitorum
brevis**

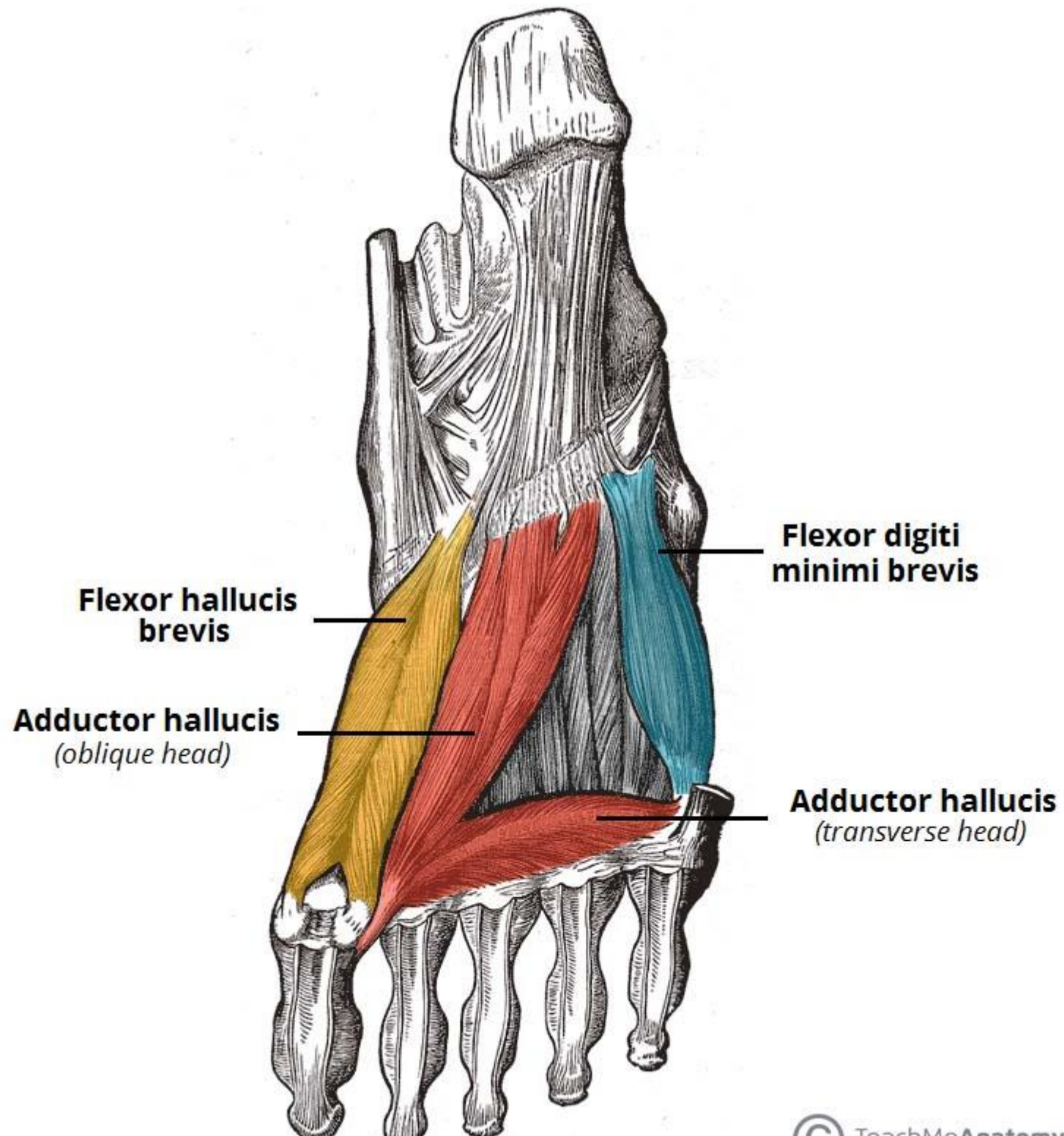


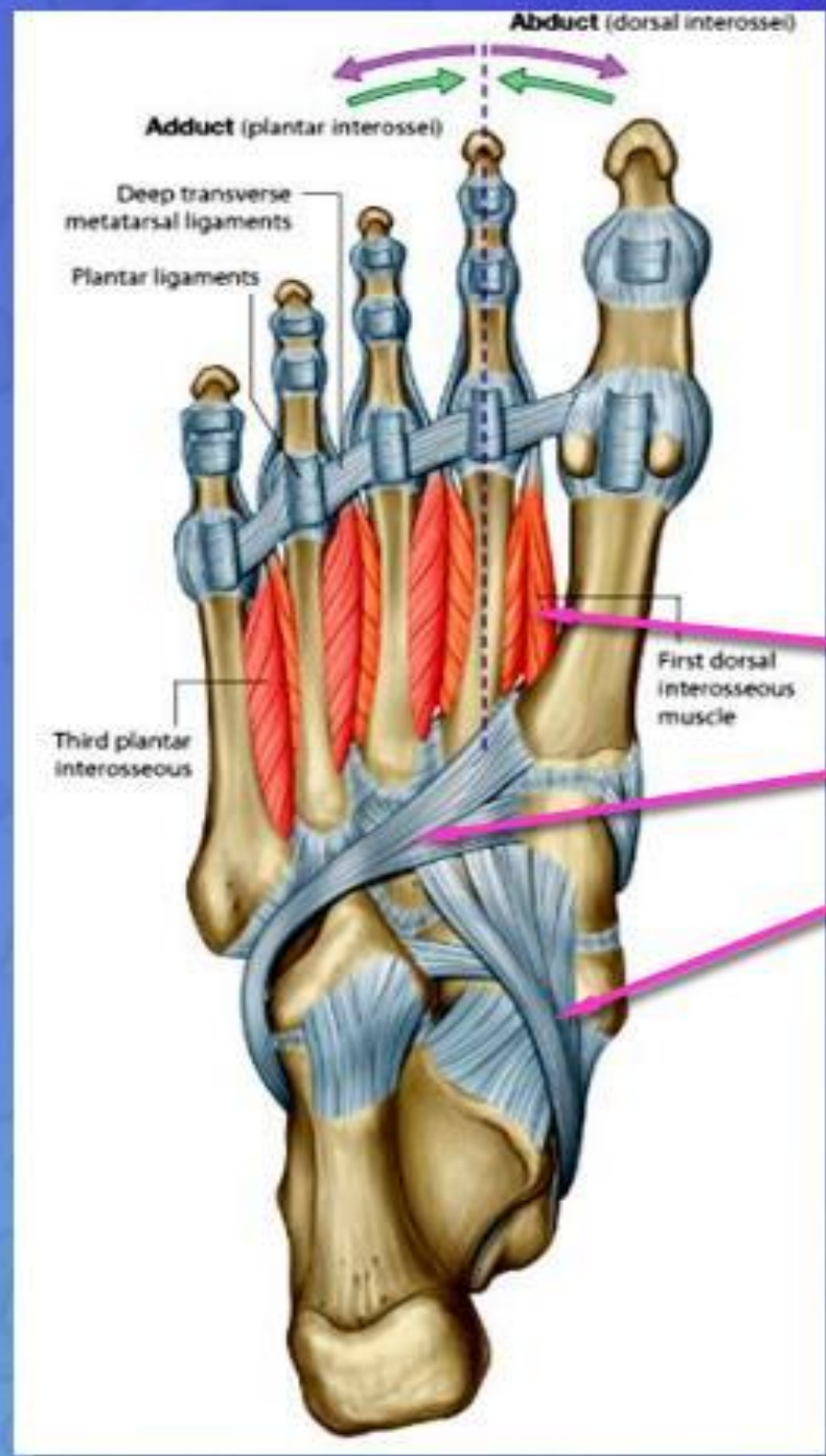

**Quadratus
plantae**

**Tendons of the
flexor digitorum
longus**

Lumbricals





Fourth Layer

1. Interossei,
2. Peroneus longus tendon,
3. Tibialis posterior tendon