

# Classification of the anatomical variation in female external genitalia

Objectives	To create a comprehensive, richly illustrated classification for the naturally occurring anatomical variation in the female external genitalia. To create awareness about and acknowledgment of the extent of variation.
Design	Observational, cross-sectional study.
Population	310 women, between 18 and 55 years old.
Methods	A cross-sectional study using digital photography of the female external genitalia.
Main anatomical aspects	Relation of the clitoris, hood and inner lips; shape, width, texture and (relative) length and breadth of the hood; shape, protrusion, thickness, texture, (relative) length and span of the inner lips; thickness, texture and length of the vulva.
Results	A wide range of variation was found for the observed anatomical aspects. The resulting classification is a robust system to describe and map this diversity.
Conclusion	Women vary widely in genital appearance. This variation can now be classified and mapped. That would allow for statistical analysis of the different anatomical aspects.

## TERMINOLOGY AND ABBREVIATIONS

hood	The skin that covers the clitoris.
anterior / posterior	To the front / back of the body, respectively (up / down in the photos).
proximal / distal	Close to / away from the center of the body, respectively (back / front in the photos).
lateral / medial	Away from / close to the midline of the body (and in the photos), respectively.
VL	Viewer's left. Refers to the righthand side of the woman.
VR	Viewer's right. Refers to the lefthand side of the woman.

## METHODS

For the observational cross-sectional study, 310 participants were recruited online and asked to anonymously submit standardized photos of their genitalia, taken according to the Gynodiversity Shooting Guide<sup>1</sup>. Age, country and ethnicity were recorded. Based on the submitted photos, the skin type was determined according to the Fitzpatrick scale<sup>2</sup>.

# Introduction

About ninety percent of all women have been self-conscious about their genital appearance at some point. Usually during adolescence or as young adults.

Pictures of lady parts in adult magazines and websites are largely to blame for this, because those pictures are usually selected or even edited for a tidy, desirable appearance. This creates an unrealistic image of what real-life lady parts actually look like. Therefore, many girls and women do not know what can be considered normal.

Their insecurities can be largely eliminated by showing what real-life lady parts look like. That is why we created Gynodiversity: a crowd-sourced, body positive project to showcase the wide range of variation found in female external genitalia. We aim to do this as follows:

The images we receive, are cropped and colour corrected based on the Fitzpatrick scale<sup>2</sup> and, where needed, adjusted for unwanted shadows or highlights. Nothing else will be retouched to keep the image as real as possible. The resulting images are placed in seamless grids, called panels, making clear at a glance the enormous variety in shape, texture, colour and size.

Since the project was started in 2010, more than 2300 women have been kind and brave enough to participate. As the project grew, and we saw and compared more and more lady parts as we processed them and placed them into panels, we started noticing patterns in the way anatomical variations manifest themselves. This gave us the idea to attempt to create this classification for the naturally occurring anatomical variation in the female external genitalia. In the process, it will help increase awareness about and acknowledgment of the wide range of variation.

The classification is currently based on observations and measurements done on a population of 310 women. These women all sent more photos than needed for the panels. They sent photos from multiple angles, which enabled us to make all necessary observations and measurements.

Hopefully this document will help empower the young women who feel these anxieties, because they now have hard evidence that their lady parts are perfectly normal.

# Outline of the anatomical aspects

The anatomical aspects, measurements and variations distinguished for classification are outlined below.

They, along with their contained classes, are explained in more detail on their respective pages noted on the right.

1 Common anatomical aspects	1.1 The vulva	1.1.1 Protrusion: innie or outie?	4
		1.1.2 Symmetry	6
		1.1.3 Length	6
	1.2 The hood	1.2.1 Shape	7
		1.2.2 Texture	8
		1.2.3 Breadth	9
		1.2.4 Length	9
1.3 Linkage between the hood, clitoris and inner lips *	1.3.1 Single connection	10	
	1.3.2 Double connection	11	
1.4 The inner lips	1.4.1 Shape *	12	
	1.4.2 Texture *	14	
	1.4.3 Span *	15	
	1.4.4 Length *	15	
	1.4.5 Thickness *	15	
	1.4.6 Fourchette: union at the back	16	
1.5 The outer lips	1.5.1 Thickness of the outer lips *	17	
	1.5.2 Texture of the outer lips *	18	
* Symmetry dependent. Separate observations are made for the VL and VR sides of these aspects.			
1.6 The perineum		19	
2 Occasional anatomical variations	2.1 The vulva	2.1.1 Groove folds	20
	2.2 The hood	2.2.1 Umbrella top	20
		2.2.2 Ridged hood	20
	2.3 Linkage between the hood, clitoris and inner lips	2.3.1 Inner lip loop	21
		2.3.2 Detached outer folds	21
2.4 The inner lips	2.4.1 Scalloped inner lips	22	
2.5 The outer lips	2.5.1 Creased outer lips	22	
3 Colour variations	3.1 Fitzpatrick types and colour palette	23	
	3.2 Type I	24	
	3.3 Type II	25	
	3.4 Type III	26	
	3.5 Type IV	27	
	3.6 Type V	28	
	3.7 Type VI	29	

# 1 Common anatomical aspects

The anatomical aspects described in this chapter are common, in the sense that they are present in some form in all women. In other words, every woman fits into exactly one of the classes contained by these aspects.

## 1.1 THE VULVA

This section deals with anatomical aspects that involve the vulva as a whole.

### 1.1.1 Protrusion: innie or outie?

The main source of anxiety is probably visibility and protrusion of the inner lips and/or hood when standing up; whether or not the the hood and/or inner lips stick out; an innie or an outie. Below are descriptions, reference images and probability of the variations regarding protrusion of the hood and inner lips.

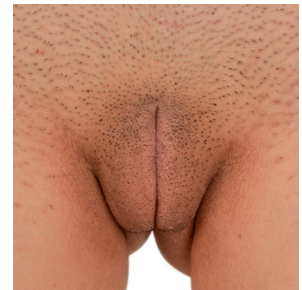
#### Variations with an innie appearance

##### innie

The hood and inner lips are deep-set and are hidden from view by the outer lips, which form a cleft together.

NOTE: this variation is the only *actual* innie variation, where there is no protrusion at all.

found in  
**27%**  
of women

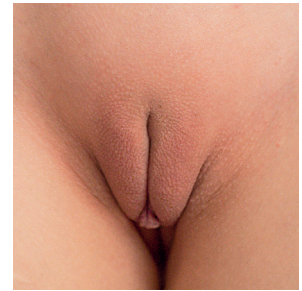

##### moderate outie lips

Either or both of the inner lips are visible and stick out. The hood does not and is hidden from view by the outer lips, which form a cleft at the front. The inner lips are at least flush with the outer lips. They stick out *no more* than their thickness.

NOTE: this variation can *appear* to be an innie.

found in  
**10%**  
of women

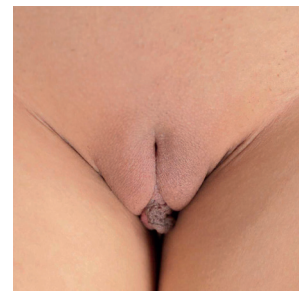


##### marked outie lips

Either or both of the inner lips are very visible and stick out *no less* than their thickness. The hood is mostly covered by the outer lips, which form a cleft at the front. Also, this outie often is wider.

NOTE: this variation can *appear* to be an innie.

found in  
**2%**  
of women



## Variations with an outie appearance

### flush

The hood and inner lips are (almost) flush with the outer lips and are therefore visible. However, they *do not* stick out.


found in  
**14%**  
of women



### moderate outie

Both the hood and the inner lips are visible and either or both stick out beyond the level of the outer lips. They stick out *less* than their total width.


found in  
**34%**  
of women



### marked outie

Both the hood and the inner lips are very visible and stick out way beyond the level of the outer lips. They stick out *more* than their total width. Also, this outie often is wider.

found in  
**9%**  
of women



### outie hood

Only the hood is visible. It may be flush with the outer lips or it may stick out. Below it, the outer lips form a cleft.

found in  
**4%**  
of women



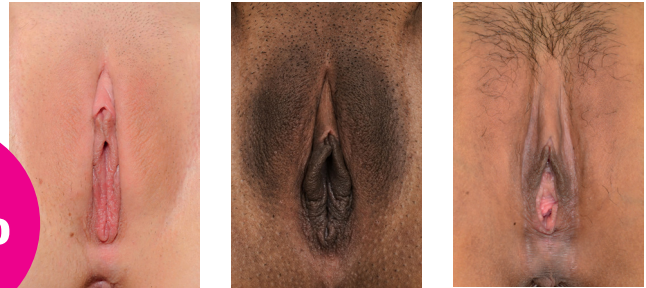
## 1.1.2 Symmetry

Below are descriptions, reference images and probability of the variations regarding the symmetry of the vulva.

### symmetrical

The left and right side are (nearly) symmetrical.

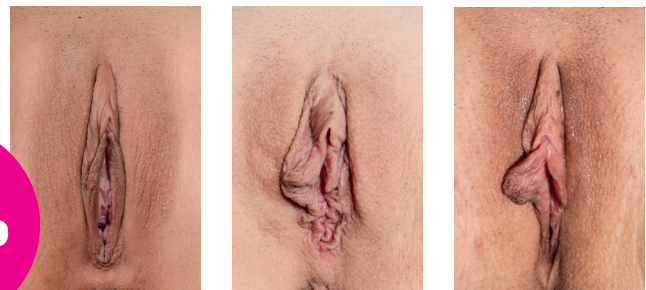
found in  
**52%**  
of women



### dominant VL side

The VL side is significantly more pronounced and/or complex than the VR side.

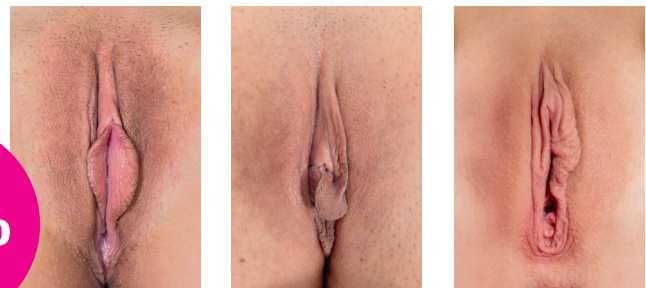
found in  
**19%**  
of women



### dominant VR side

The VR side is significantly more pronounced and/or complex than the VL side.

found in  
**29%**  
of women



## 1.1.3 Length of vulva

The length of the vulva is measured from the point where the inner lips meet at the back (*fourchette*) to the top of the hood.

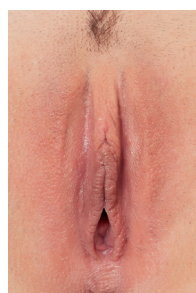
Where available, scale reference included in the source photographs was used to determine the actual length of the vulva.

It ranges between 60 and 103mm, with an average of 78mm.

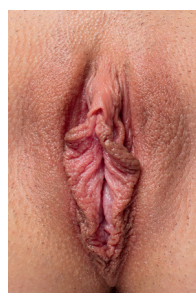The images below provide examples from small to large.



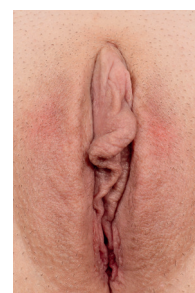
60mm



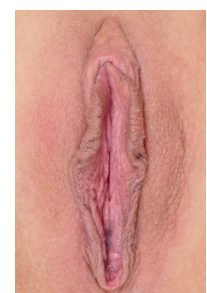
70mm



78mm



90mm



103mm

## 1.2 THE HOOD

This section deals with anatomical aspects that involve the hood.

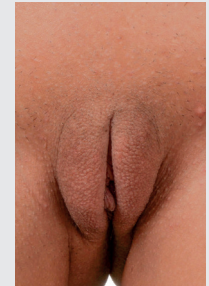
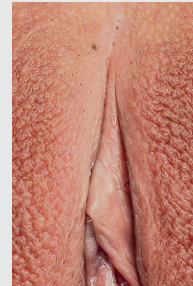
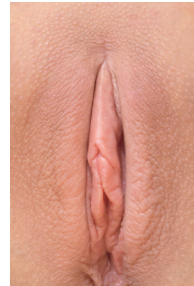
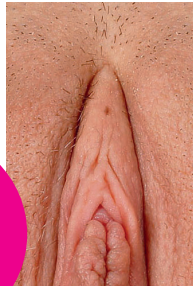### 1.2.1 Shape

Below are descriptions, reference images and probability of the variations observed in the shape of the hood.

#### pointed

The hood tapers towards a more or less sharp top. The slanted edges may be straight or slightly curved.

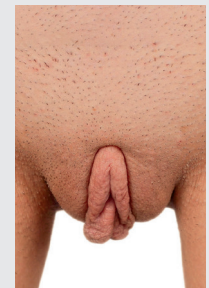
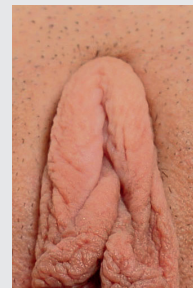
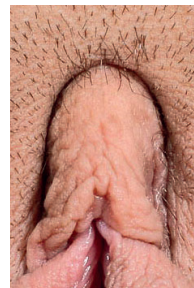
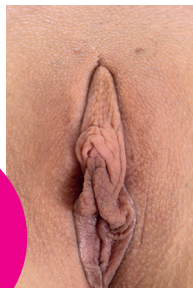found in  
**23%**  
of women



#### rounded

The hood has a rounded top. The edges may be parallel or slanted. This shape is not always apparent in caudal view. In frontal view it is easier to spot.


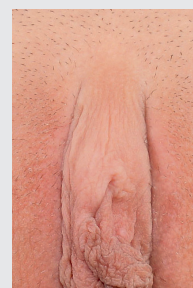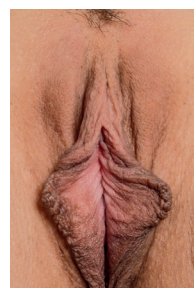
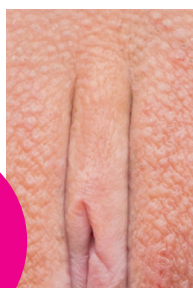found in  
**15%**  
of women



#### square

The hood appears to have a square top, as if cut off, because the it dissolves into the pubic mound without a clear border. The edges may be parallel or slanted.

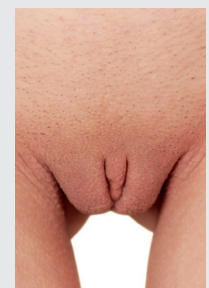
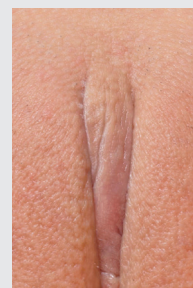
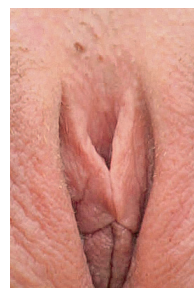
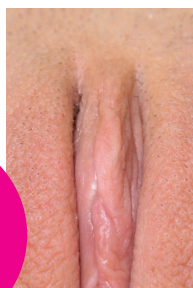found in  
**56%**  
of women



#### wedge shaped

The hood is either slightly wedge shaped itself or has a wedge shaped appearance because it is partly covered by the outer lips. It widens towards the top. Can be seen best in frontal view.

found in  
**7%**  
of women



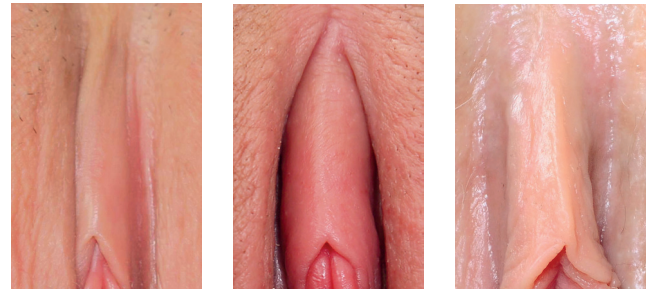
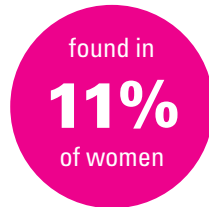Above: in very rare cases, the dominant outer folds of the hood form a double V-shaped top.

### 1.2.2 Texture

Below are descriptions, reference images and probability of the variations observed in the texture of the hood.

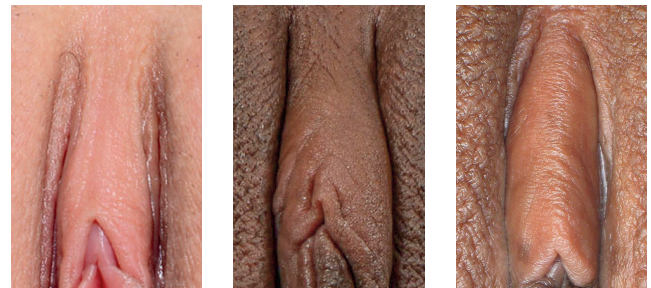
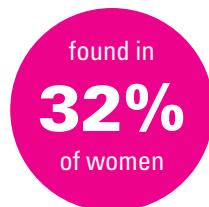#### smooth

The skin is completely smooth.



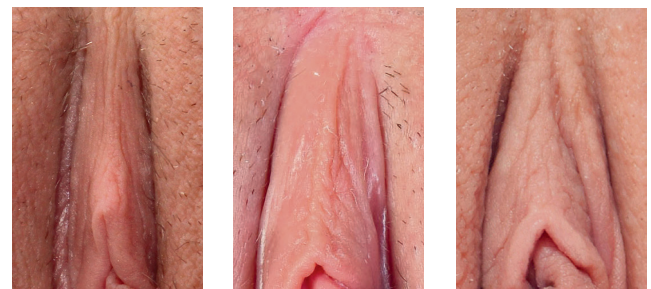
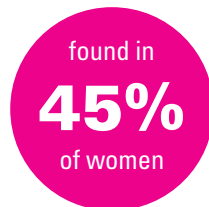#### slight

The skin has a very fine texture and possibly minor ruffles.



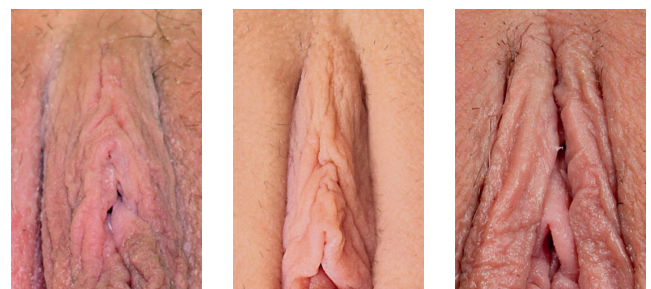
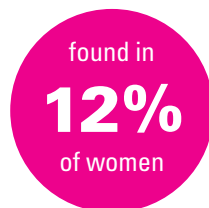#### moderate

The skin has distinct texture with many fine ruffles and possibly some more prominent creases.



#### marked

The skin has a very rough texture consisting of pronounced ruffles and often very prominent creases and folds.



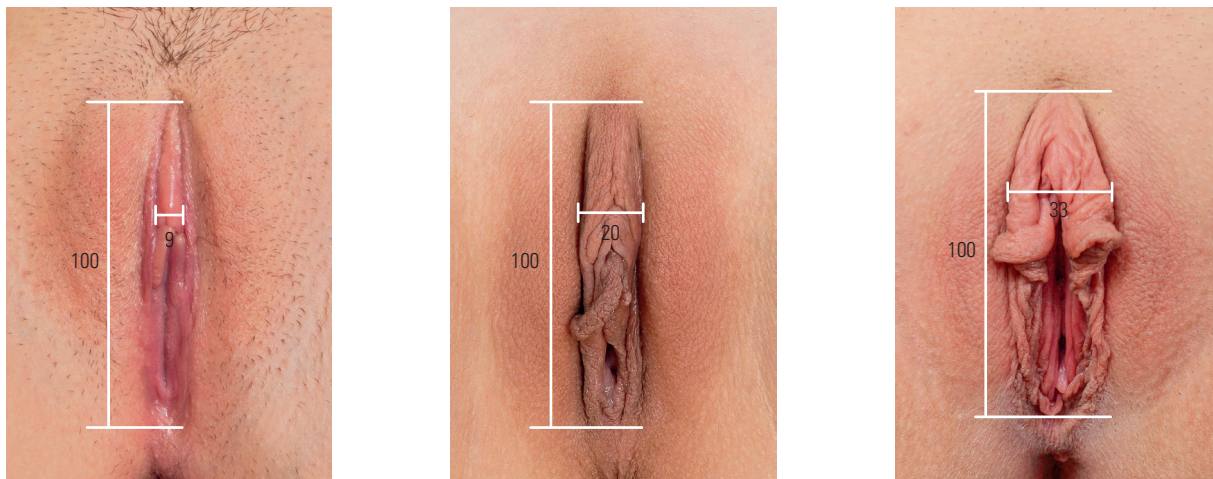


### 1.2.3 Breadth of the hood

The *relative* breadth of the hood is defined as the breadth of the hood divided by the length of the vulva. It ranges between 7% and 33% of the length of the vulva. The average relative breadth of the hood is 17%.

Where available, scale reference included in the source photographs was used to determine the actual breadth of the hood. Actual breadth of the hood ranges between 7 and 23mm, with an average of 14mm.

The images below provide examples for the various relative breadths observed in the hood.

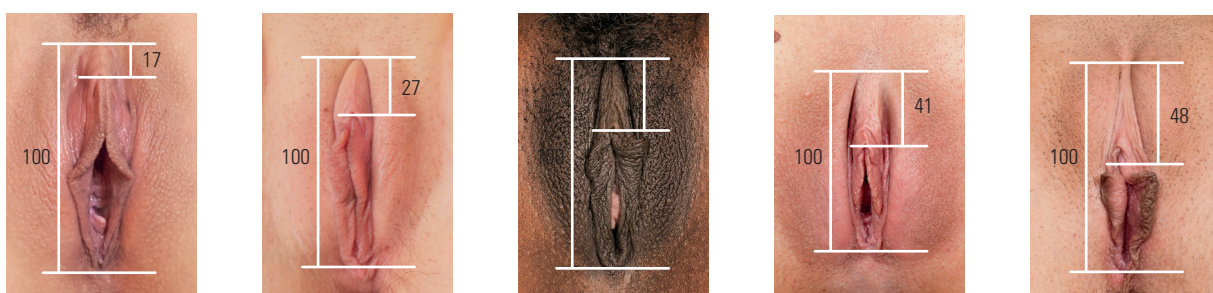


### 1.2.4 Length of the hood

The *relative* length of the hood is the length of the hood divided by the length of the vulva. Range between 17% and 50% of the length of the vulva. The average relative length of the hood is 34%.

Where available, scale reference included in the source photographs was used to determine the actual length of the hood. Actual length of the hood ranges between 13 and 38mm, with an average of 26mm.

The images below provide examples for the various relative lengths observed.



## 1.3 LINKAGE BETWEEN THE HOOD, CLITORIS AND INNER LIPS

Below are descriptions, reference images and probability of the various ways the inner lip can split up into either two or three branches to connect to the clitoris and contribute to the hood. The innermost branch *always* joins with the undersurface of the clitoris to form the *frenulum*.

The remaining one or two outer branches connect and contribute to the hood, forming a single or a double connection respectively. These branches are either called *fold* or *fusion*, depending on the way the hood and inner lip are connected.

In case of a *single connection*, we either find a *minimal fold*, a *full fold* or a *united fusion*.

In case of a *double connection*, we either find a *dominant inner fold*, a *dominant outer fold* or a *divided fusion*.

The left side can differ from the right. This aspect is therefore observed separately for both sides. However, for clarity, the examples on this page are all symmetrical.

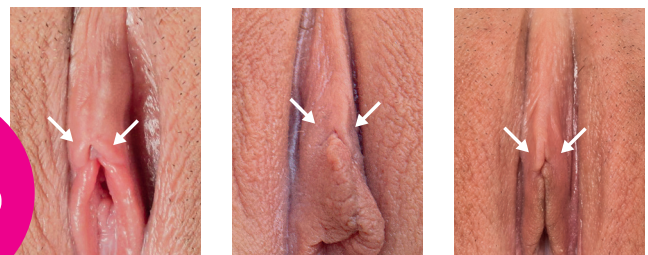
### 1.3.1 Single connection (found in 60% of women)

In case of a single connection, the inner lip is usually connected to the hood by a single fold, which joins with the outer face of the inner lip. In rare cases, a complete and seamless fusion occurs between the single branch of the inner lip and the hood.

#### minimal fold

The inner lip is connected to the corresponding side of the hood by a single, minimal fold. The fold meets with its opposing counterpart at the midline to form the hood. These primary folds are present in all women to a certain extent. In this case they are very small, short and usually smooth.

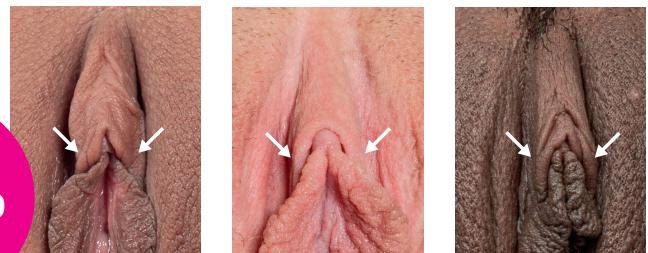
found in  
**17%**  
of women



#### full fold

The inner lip is connected to the corresponding side of the hood by a single fold. In this case, the fold is well to overly developed and varies in size from moderate to quite large. The surface of these folds varies from smooth to ruffled.

found in  
**38%**  
of women

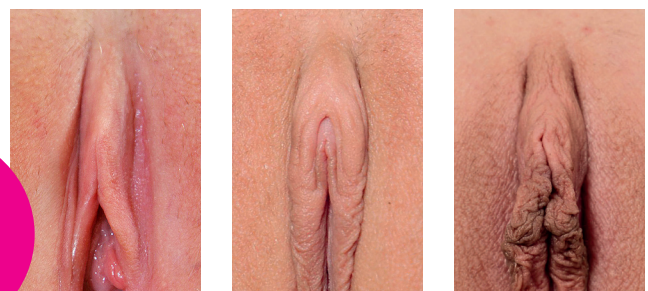


#### united fusion

The front of the inner lip is fused with the corresponding side of the hood, making it very hard or impossible to tell where the lip ends and the hood begins.

The lip fuses with the hood and *unites with its opposing counterpart*, forming a *united hood*.

found in  
**5%**  
of women



### 1.3.2 Double connection (found in 40% of women)

In case of a double connection, the inner lip is usually connected to the hood by two distinct folds: the inner and outer folds, either of which can be the dominant one in prominence. The outer fold joins with the outer face of the inner lip farther towards the back than the inner fold does.

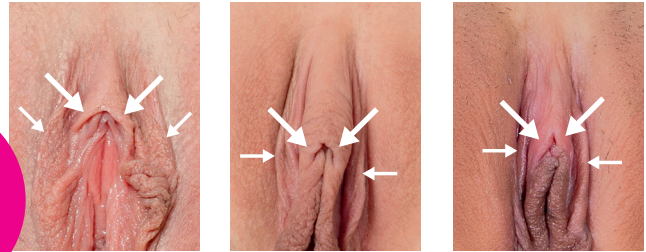
In rare cases, the inner lip and hood are connected by an inner fold combined with an outer, *divided fusion*.

#### dominant inner fold

At the top, the *inner fold* is farther from the center of the body than the outer fold. I.e. it is closer to the observer than the outer fold.

The *inner fold* usually contributes more to the hood than the outer fold. The outer fold does not unite with its opposing counterpart.

found in  
**18%**  
of women

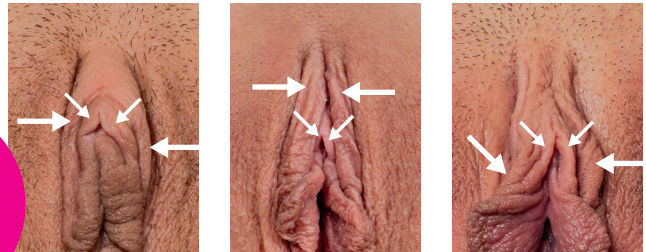


#### dominant outer fold

At the top, the *outer fold* is farther from the center of the body than the inner fold. I.e. it is closer to the observer than the inner fold.

The *outer fold* usually is larger and contributes more to the hood than the inner fold. It may unite with the opposing outer fold to form the top part of a united hood (*left reference image*).

found in  
**20%**  
of women

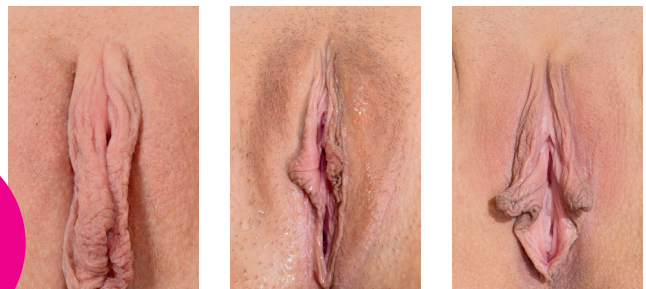


#### divided fusion

The front of the inner lip is fused with the corresponding side of the hood, making it very hard or impossible to tell where the lip ends and the hood begins.

While the lip fuses with the hood, it *does not* unite with its opposing counterpart. In stead, it continues separately towards the front, forming a *divided hood*. In between are the much smaller, inner folds, which *do meet across the midline* to cover the clitoris.

found in  
**2%**  
of women



## 1.4 THE INNER LIPS

This section deals with anatomical aspects that involve the inner lips.

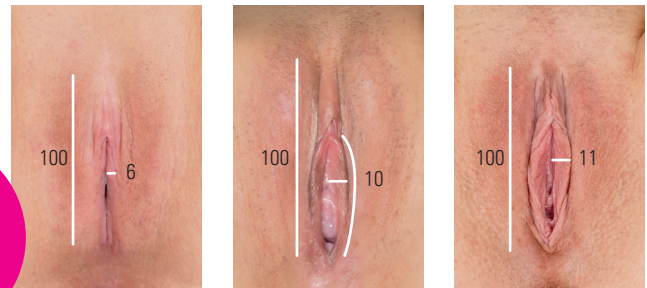
### 1.4.1 Shape

Below are descriptions, reference images and probability of the various profile shapes of the inner lips. This aspect can be asymmetrical and is therefore observed separately for the left and right side. However, for clarity, the examples in this section are symmetrical wherever possible. The length of the vulva is measured from the fourchette to the top of the hood.

#### lance shaped

The inner lip has a narrow profile shaped like the upside-down tip of a lance. Its span is between 4 and 16 percent of the length of the vulva. Its widest point is in the front half.

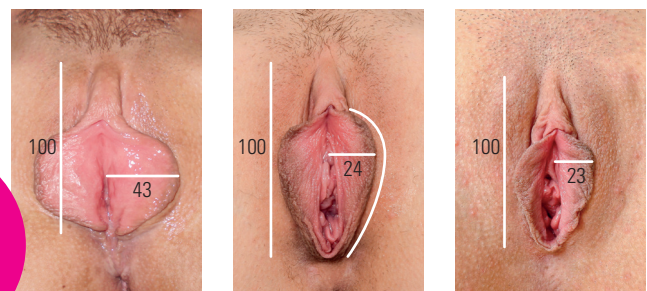
found in  
**22%**  
of women



#### egg shaped

The inner lip is shaped like an upside-down egg. Its span is between 14 and 45 percent of the length of the vulva. Its widest point is in the front half.

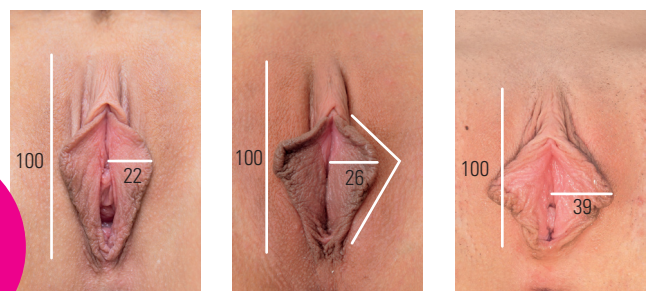
found in  
**15%**  
of women



#### diamond shaped

The inner lip is shaped like a diamond or kite with rounded corners. While the corner is rounded, the profile is more angular than an egg shaped lip. Its span is between 11 and 45 percent of the length of the vulva. Its widest point is in the front half.

found in  
**10%**  
of women

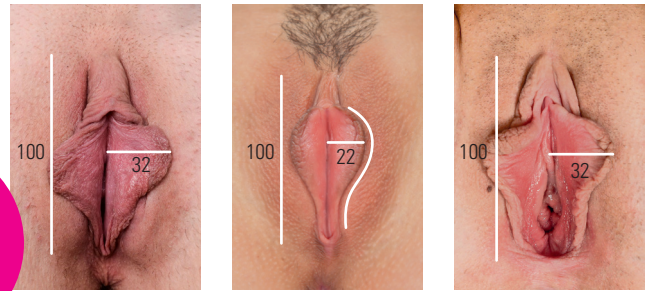


## 1.4.1 Shape, *continued*

### pear shaped

The inner lip is shaped like an upside-down pear. The wide front part curving outward, before curving back inward into a more narrow back part. Its span is between 10 and 45 percent of the length of the vulva.

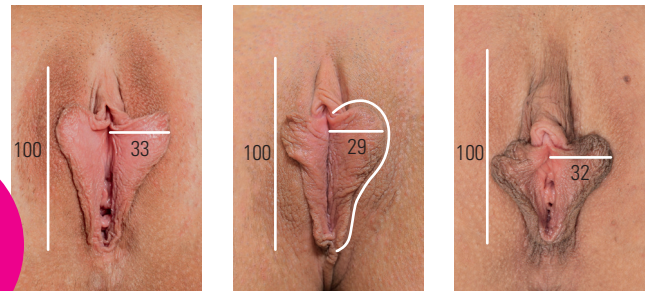
found in  
**33%**  
of women



### heart shaped

The inner lip is shaped like a heart. This shape is similar to the pear shape. The front edge is different, because it curves towards the front significantly above the level of the clitoris. Its span is between 20 and 45 percent of the length of the vulva.

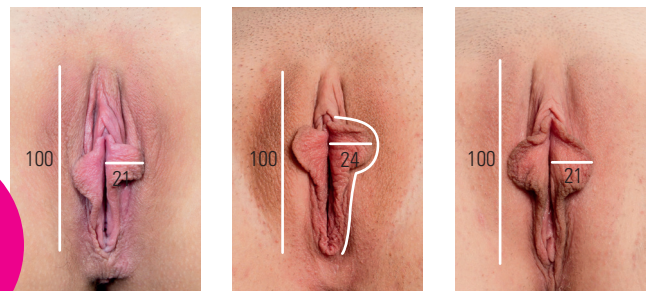
found in  
**8%**  
of women



### spatula shaped

The inner lip is shaped like a spatula. The back part is very narrow. The front part abruptly widens into an oval lobe at least twice as wide as the back part. Its span is between 10 and 45 percent of the length of the vulva.

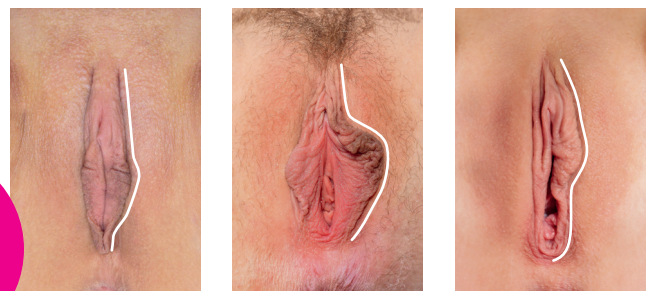
found in  
**8%**  
of women



### spindle shaped

The inner lip is shaped like a spindle. This shape only occurs as a result of the fusion (either united or divided) between the inner lip and the hood. The profile includes the fused hood. It is tapered both towards the front and the back. The curvature in between varies. Its span is between 10 and 45 percent of the length of the vulva.

found in  
**4%**  
of women

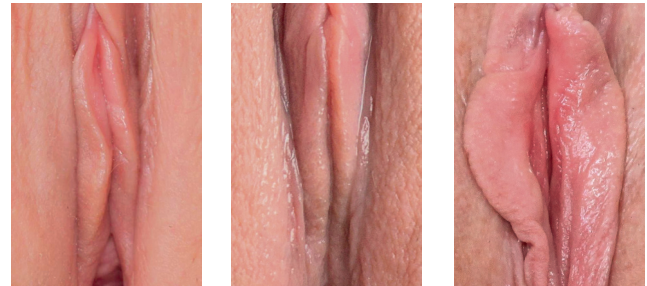
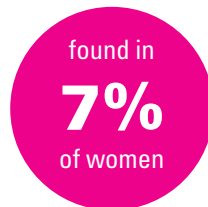

### 1.4.2 Texture

Below are descriptions, reference images and probability of the various textures observed in the inner lips. It may be asymmetrical and is therefore observed separately for each lip.

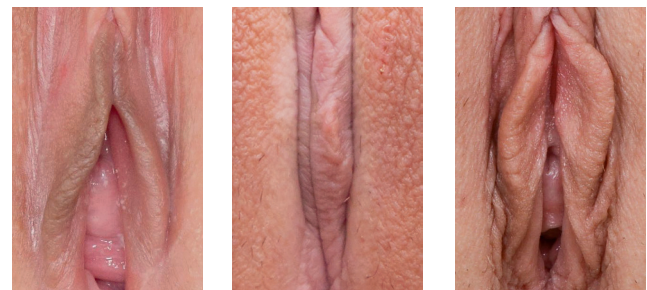
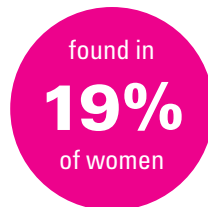#### smooth

The lips are completely smooth, rarely with minor creases.



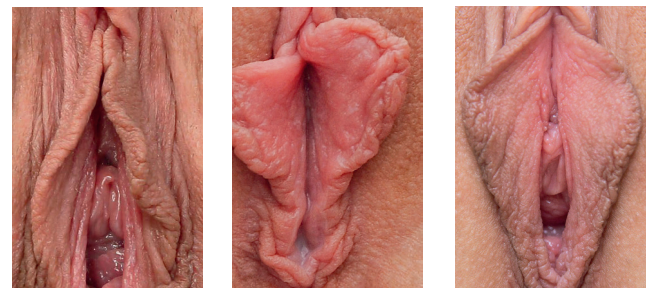
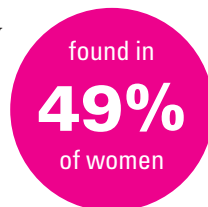#### slight

The lips have a subtle texture, possibly with minor ruffles.



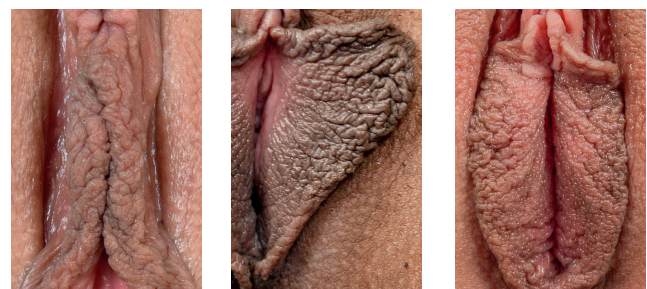
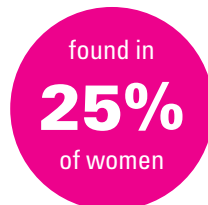#### moderate

The lip has a distinct texture with many fine or moderate ruffles, sometimes creating a crumpled appearance along the edge.



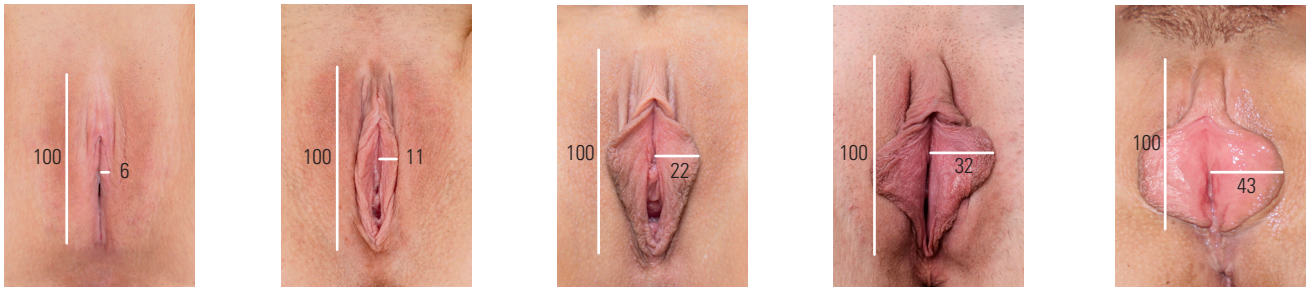
#### marked

The lip has a very coarse texture consisting of pronounced ruffles resulting in a very crumpled appearance.



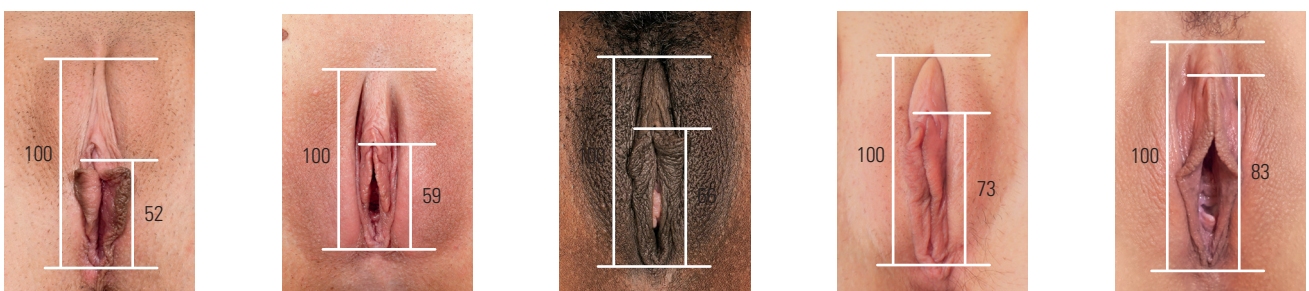
### 1.4.3 Span

The span of the inner lip is defined as the distance from the base of the inner lip (midline) to the edge at its widest point. The *relative* span of the inner lip ranges between 6% and 45% of the length of the vulva, with an average of 21%. Where available, scale reference included in the source photographs was used to determine the actual span of the inner lip. It ranges between 3 and 36mm, with an average of 17mm. May be asymmetrical. Measured separately for each inner lip. The images below provide examples from narrow to wide.



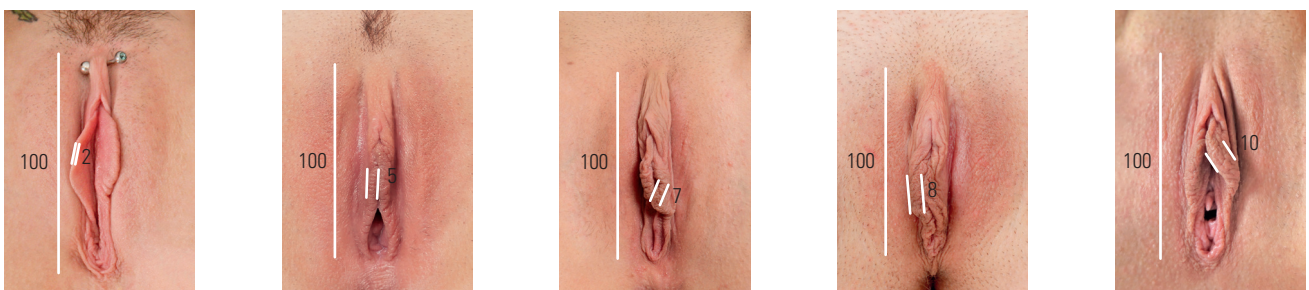
### 1.4.4 Length

The length of the inner lip is measured from the fourchette to the point where the front of the inner lip meets the undersurface of the clitoris. The *relative* length of the inner lip is the length of the inner lip divided by the length of the vulva. Range between 50% and 83% of the length of the vulva, with an average of 66%. Where available, scale reference included in the source photographs was used to determine the actual length of the inner lip. It ranges between 31 and 86mm, with an average of 52mm. The images below provide examples from short to long.



### 1.4.5 Thickness

The *relative* thickness of the inner lip is defined as the thickness of the inner lip divided by the length of the vulva. Range between 2% and 17% of the length of the vulva, with an average of 6%. Where available, scale reference included in the source photographs was used to determine the actual thickness of the inner lip. It ranges between 2 and 14mm, with an average of 5mm. May be asymmetrical. Measured separately for each inner lip. The images below provide examples from thin to thick.



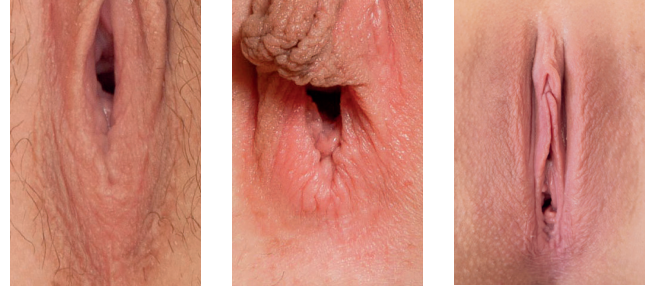
### 1.4.6 Fourchette: how the inner lips meet at the back

Below are descriptions, reference images and probability of the various ways the inner lips can meet at the back (*fourchette*).

#### minimal

At the back, the inner lips dissolve into the surrounding tissue. They may be connected by a tiny fold of skin that may be difficult to see.

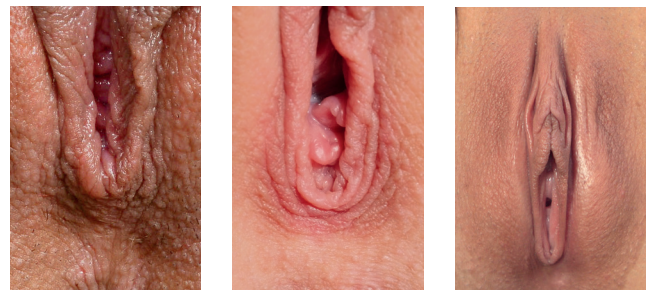
found in  
**20%**  
of women



#### moderate

A well developed and clearly visible fold of skin connects the opposing lips.

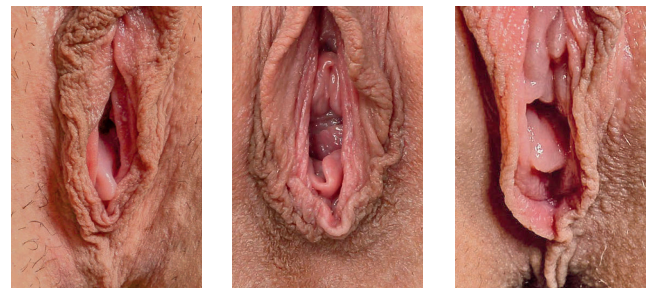
found in  
**64%**  
of women



#### prominent

A very well developed and prominently visible, often ruffled fold of skin connects the opposing lips.

found in  
**16%**  
of women





## 1.5 THE OUTER LIPS

This section deals with anatomical aspects that involve the outer lips.


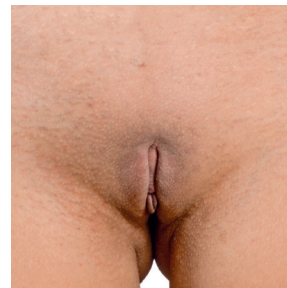
### 1.5.1 Thickness

Below are descriptions, reference images and probability of the various degrees of thickness of the outer lips. A frontal view is needed to determine this with acceptable accuracy. It can be asymmetrical and is therefore observed separately for both sides.

#### thin

The lip is almost completely flat, possibly narrowly bulged along the inner edge. The frontal contour is slightly curved at most.

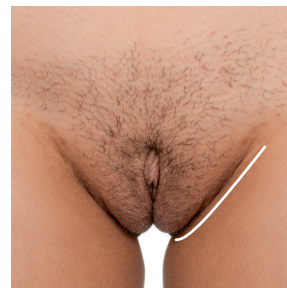found in  
**8%**  
of women



#### moderate

The lip is moderately full. The frontal contour transitions smoothly into the diagonal junction between the belly and the thigh.

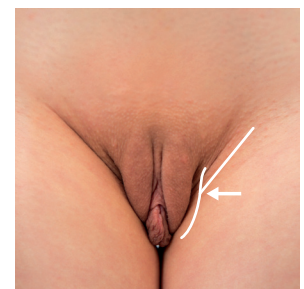
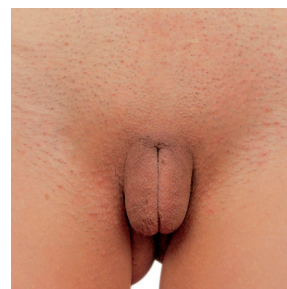found in  
**60%**  
of women



#### thick

The lip is very full and bulged. The frontal contour is very curvy and often meets the diagonal junction between the belly and the thigh at an angle.

found in  
**32%**  
of women

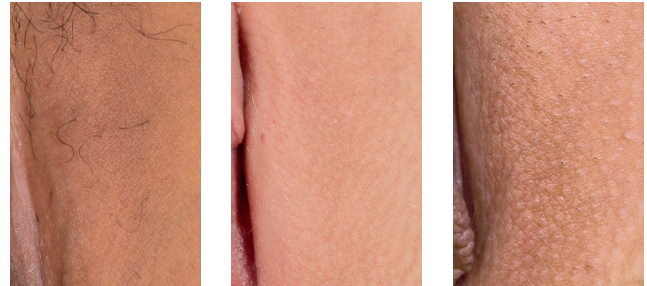
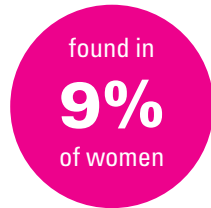
## 1.5.2 Texture

The outer lips have a typical cellular, honeycomb-like texture. Below are descriptions, reference images and probability of the various degrees of this texture found in the outer lips. It may be asymmetrical and is therefore observed separately for both sides.

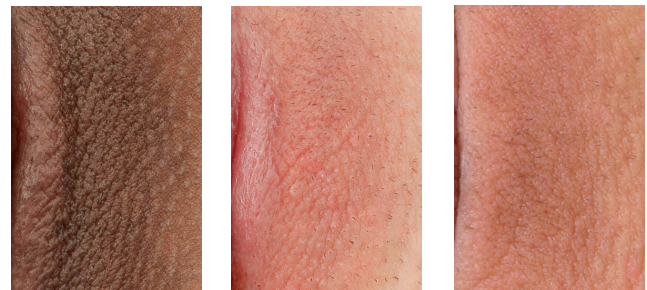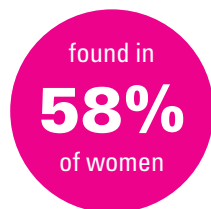### slight

The lip has a fine, subtle version of the aforementioned texture.



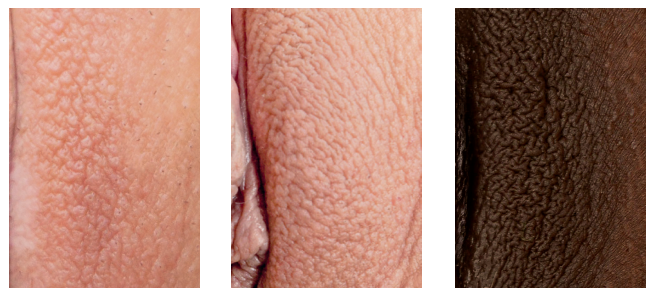
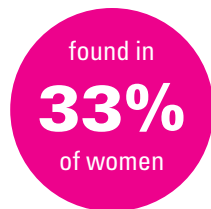### moderate

The lip has a moderate version of the aforementioned texture.



### marked

The lip has a coarse, marked version of the aforementioned texture. Occasionally, pronounced ruffles result in a crumpled appearance.



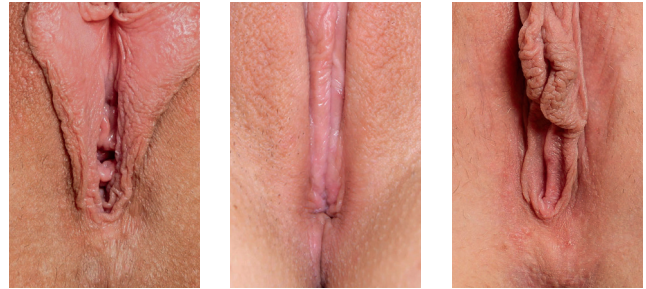
## 1.6 THE PERINEUM

Below are descriptions, reference images and probability of the variations found in the perineum.

### regular skin

The perineum is covered with regular skin, similar to that on the buttocks.

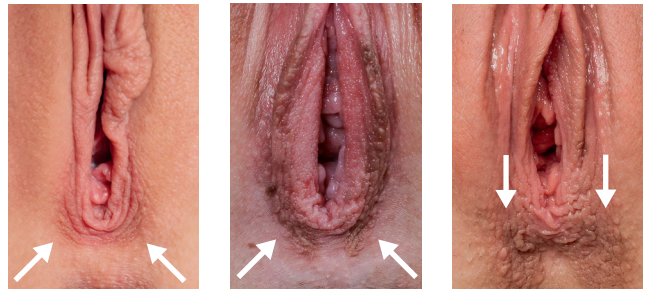
found in  
**66%**  
of women



### rough patch(es)

Rough, puckered skin is present either in separate patches on both sides of the midline, on either side of the midline or in a single patch across the midline.

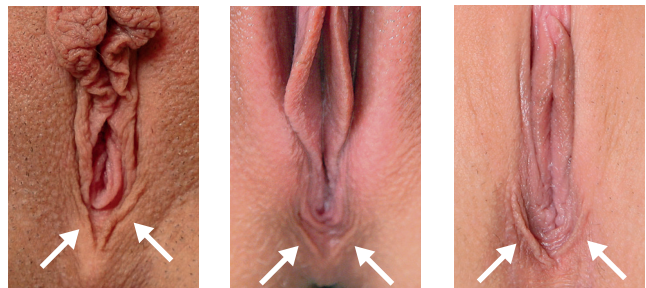
found in  
**17%**  
of women



### diagonal ridge(s)

Diagonal ridges of skin are present on either or both sides of the midline. The folds are closer to the midline at the back, forming a wedge or V shape that is usually open-ended.

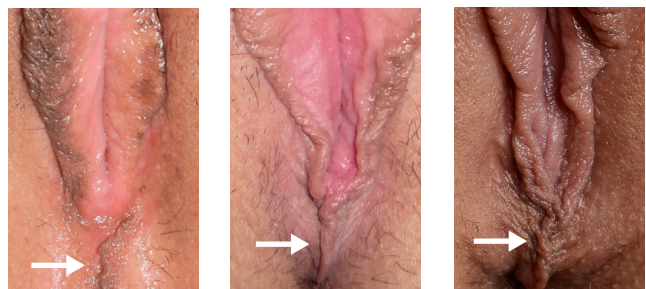
found in  
**6%**  
of women



### raphé

A ridge of skin is present along the midline. May split into two branches at the front, forming a Y shape.

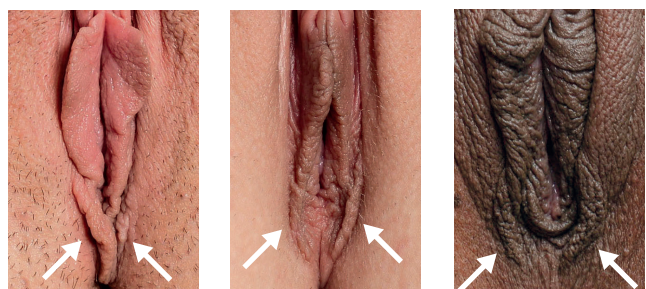
found in  
**3%**  
of women



### patch(es), ridge(s) and/or raphé

A combination of the patches, ridges and/or raphé outlined above is present.

found in  
**8%**  
of women



## 2 Occasional anatomical variations

In addition to the common anatomical aspects distinguished in all women, the following *occasional* anatomical variations are recognized. These variations are only found in a small percentage of women. Below are their descriptions, reference images and probability.

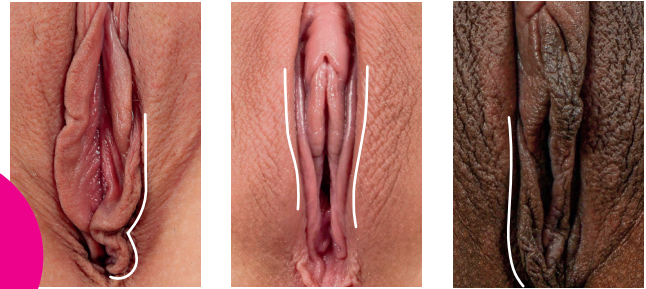
### 2.1 THE VULVA

This section deals with occasional anatomical variations that involve the vulva as a whole.

#### 2.1.1 groove fold(s)

An extra fold of skin is present in the groove between the inner lip and the outer lip. It can be present on either or both sides. Often, it is situated towards the back, in which case the front end of the fold is just in front of the back end of the related inner lip. While these folds may extend all the way to the front, they never join with or contribute to the hood. Unlike the *detached outer folds*, which *do* contribute to the hood.

found in  
**9%**  
of women



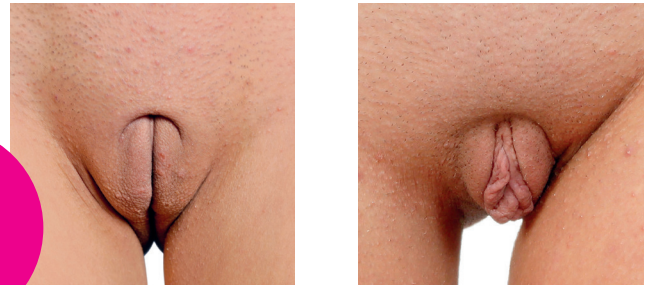### 2.2 THE HOOD

This section deals with occasional anatomical variations that involve the hood.

#### 2.2.1 umbrella top

At the front (top) of the vulva, where the outer lips meet the pubic mound, an umbrella shaped crease or overhang is present. This trait can be difficult to spot in caudal view. The frontal view is therefore recommended.

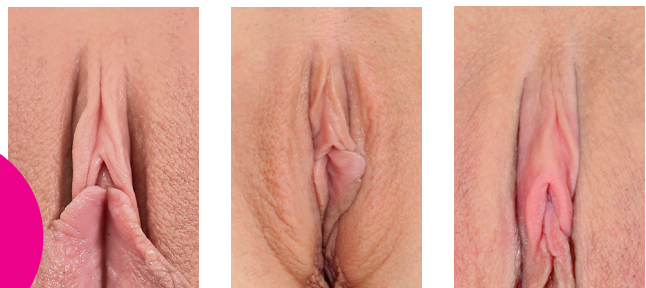
found in  
**2%**  
of women



#### 2.2.2 ridged hood

The hood features one or more vertical wing-like ridges of skin. These occur only in women with a single connection between the inner lips and hood (*minimal fold*, *full fold* and *united fusion*). Although the ridges may look similar to the outer folds found in women with a double connection, they do not connect with the inner lips, but dissolve back into the hood itself.

found in  
**3%**  
of women



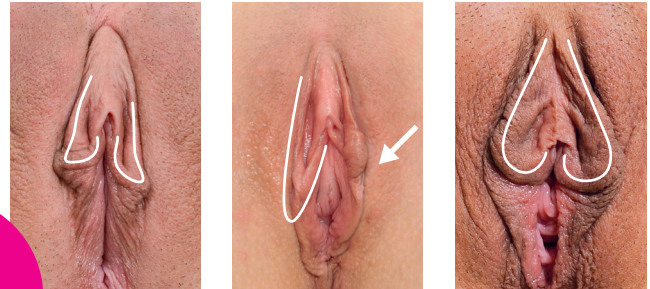
## 2.3 LINKAGE BETWEEN THE HOOD, CLITORIS AND INNER LIPS

Below are descriptions, reference images and probability of rare variations of the connection between the inner lip, the clitoris and the hood.

### 2.3.1 inner lip loop

Occurring sometimes in women with a double connection between the inner lips and hood. At the point where the outer fold merges with the outer face of its corresponding inner lip, a complexity is formed where the inner lip thickens and often twists towards or doubles over in horizontal direction. At that point, the outer fold sometimes appears to loop back, across the inner lip, towards the undersurface of the clitoris.

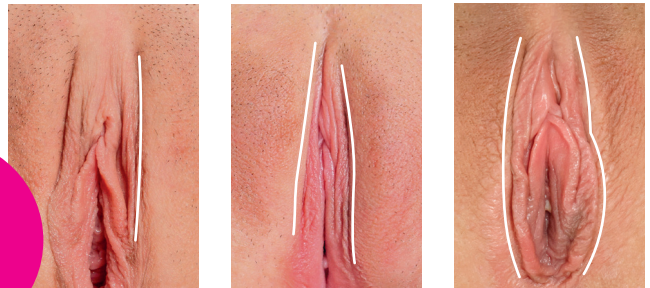
found in  
**5%**  
of women



### 2.3.2 detached outer fold(s)

The outer fold(s) never join(s) with its/their corresponding inner lip. They dissolve into the groove between the inner and outer lips towards the back. In some cases the outer folds are at least as prominent as the inner lips and look like a third pair of lips in their own right. Not to be confused with *groove folds*, which *do not* connect or contribute to the hood.

found in  
**2%**  
of women



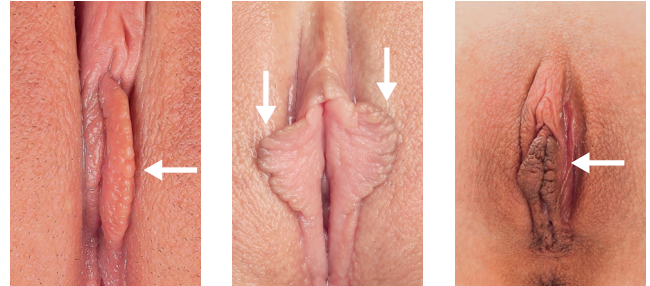
## 2.4 THE INNER LIPS

Below are the description, reference images and probability of a rare variation found in the inner lips.

### 2.4.1 scalloped inner lips

The edges of either or both of the inner lips are partly cut into rounded scallops.

found in  
**5%**  
of women



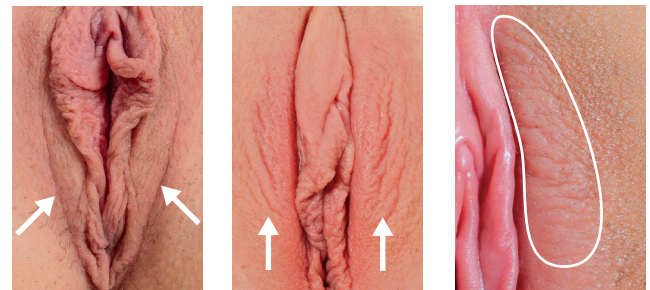
## 2.5 THE OUTER LIPS

Below are the description, reference images and probability of an occasional variation found in the outer lips.

### 2.5.1 creased outer lips

In addition to their typical texture described earlier, the outer lips have one or more pronounced creases. The creases usually run in diagonal direction, forming a V shape. They may also run in vertical or horizontal direction.

found in  
**16%**  
of women

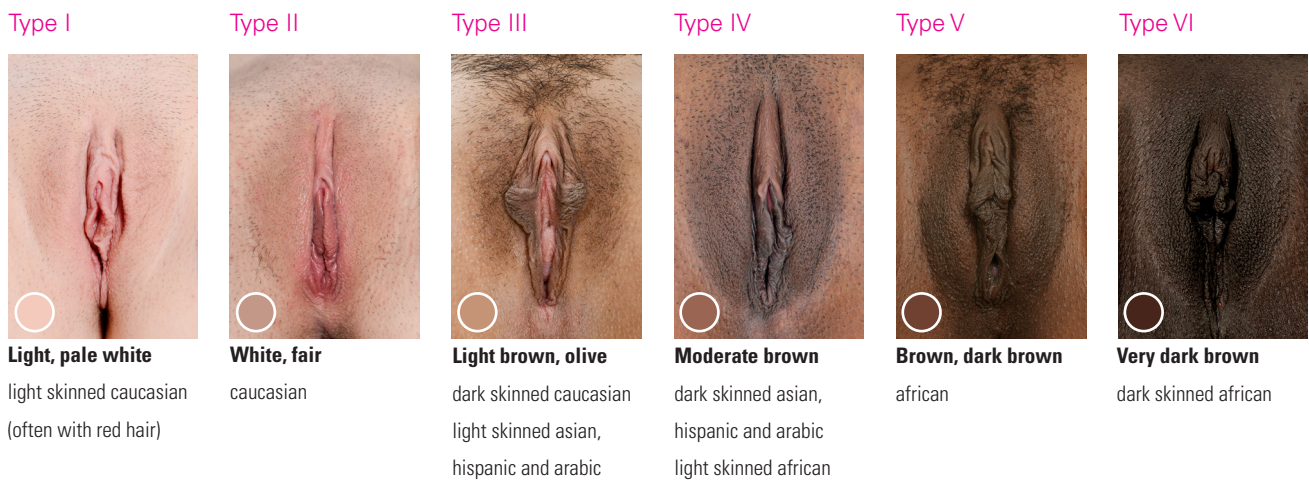


# 3 Colour of the vulva

In this chapter we will describe the colour found in the vulva and surrounding skin.


## 3.1 FITZPATRICK TYPES AND COLOUR PALETTE

To classify the type of skin we follow the scheme developed by Thomas B. Fitzpatrick<sup>2</sup>, MD, PhD. This scheme distinguishes six skin types that are defined as follows. Some ethnicities are listed as well, but note that these are examples and not exhaustive.



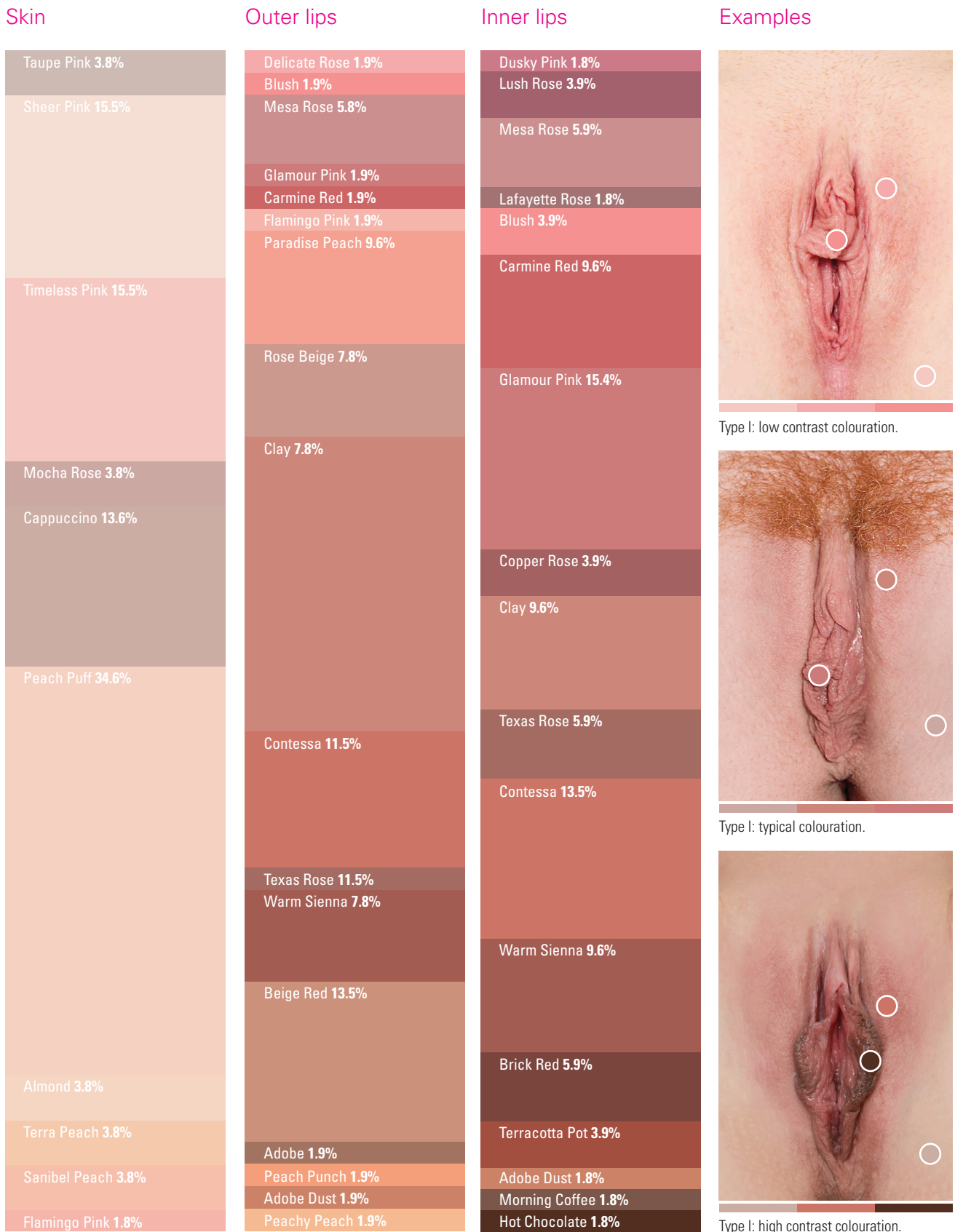
The colour analysis was done on a subset of the population (n=295), because in some cases, we were unable to properly determine the colours due to being obscured by pubic hair. Of this subset, 52 women have skin type I, 52 women have skin type II, 50 women have skin type III, 53 women have skin type IV, 51 women have skin type V and 37 women have skin type VI.

For each woman, the colour of the surrounding skin was sampled on the inner thigh near the buttock. The colour of the outer lips was sampled at the darkest area and the colour of the inner lips was sampled at the darkest area along the edge of the lips. All colours were collected and distilled into the following palette of 69 distinct colours:



## 3.2 TYPE I

This section shows the colours found in the skin, outer lips and inner lips of women with skin type I.  
The probability of a given colour is illustrated by the size of its swatch.

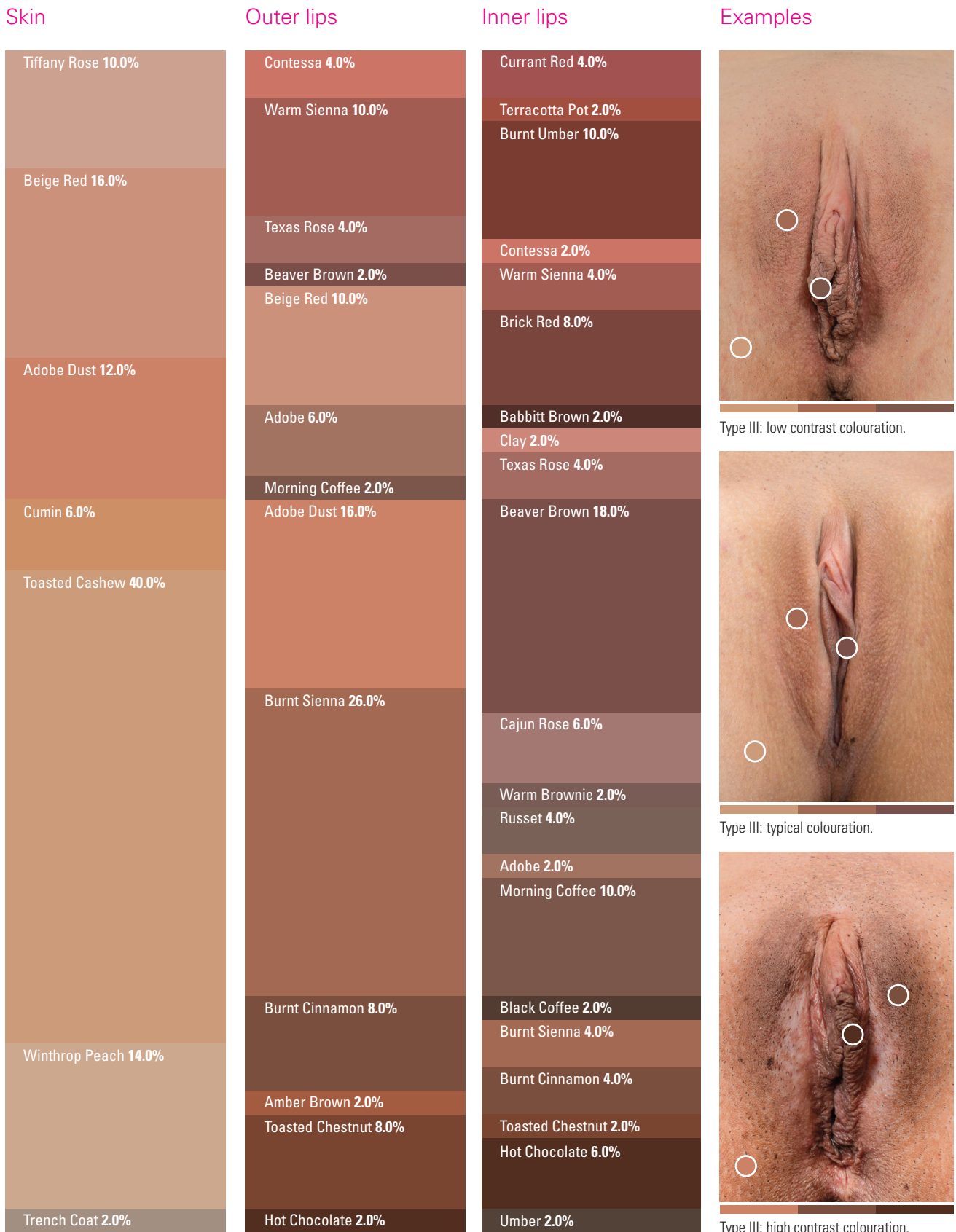






### 3.4 TYPE III

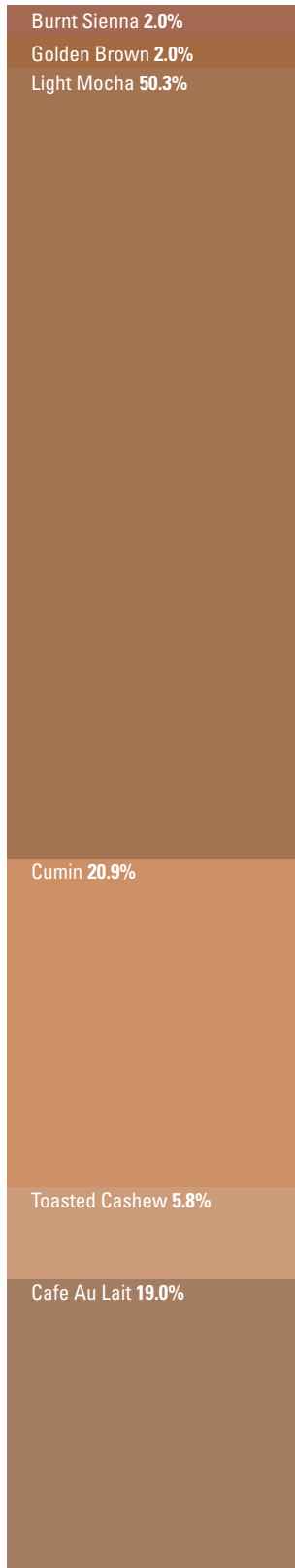
This section shows the colours found in the skin, outer lips and inner lips of women with skin type III.  
The probability of a given colour is illustrated by the size of its swatch.



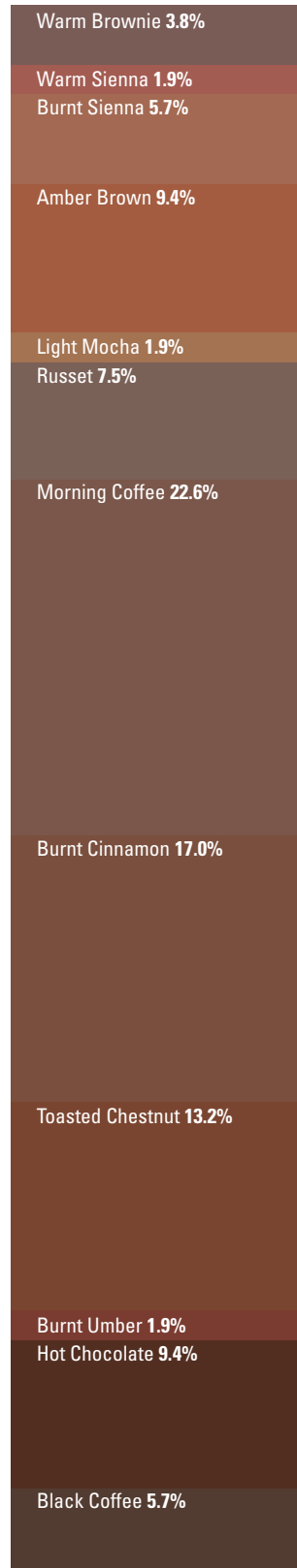
## 3.5 TYPE IV

This section shows the colours found in the skin, outer lips and inner lips of women with skin type iv.  
The probability of a given colour is illustrated by the size of its swatch.

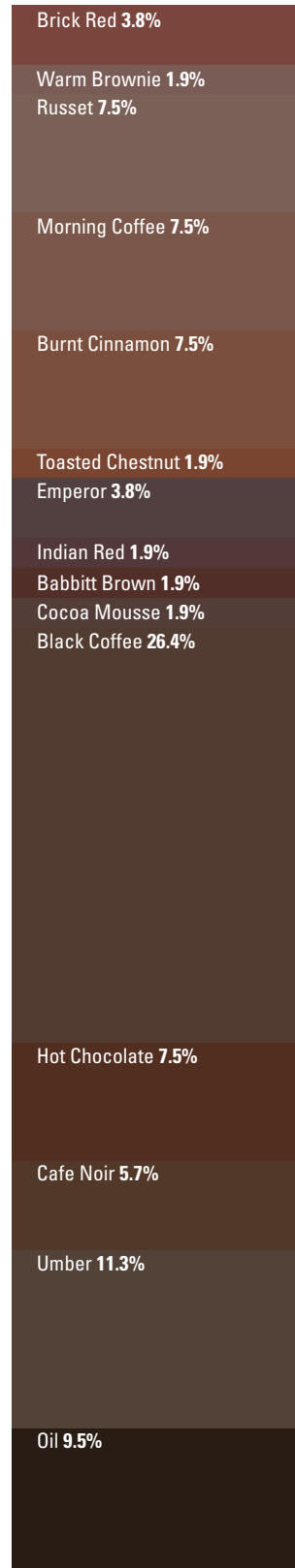
### Skin



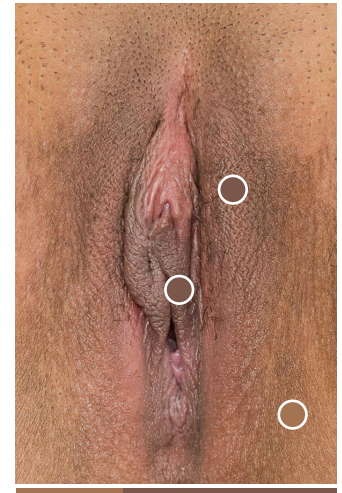
### Outer lips



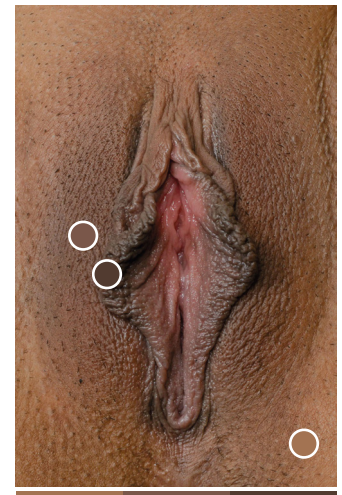
### Inner lips



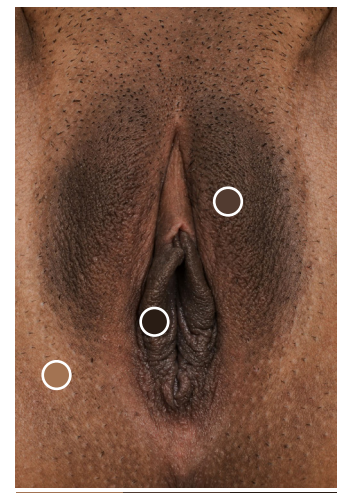
### Examples



Type IV: low contrast colouration.



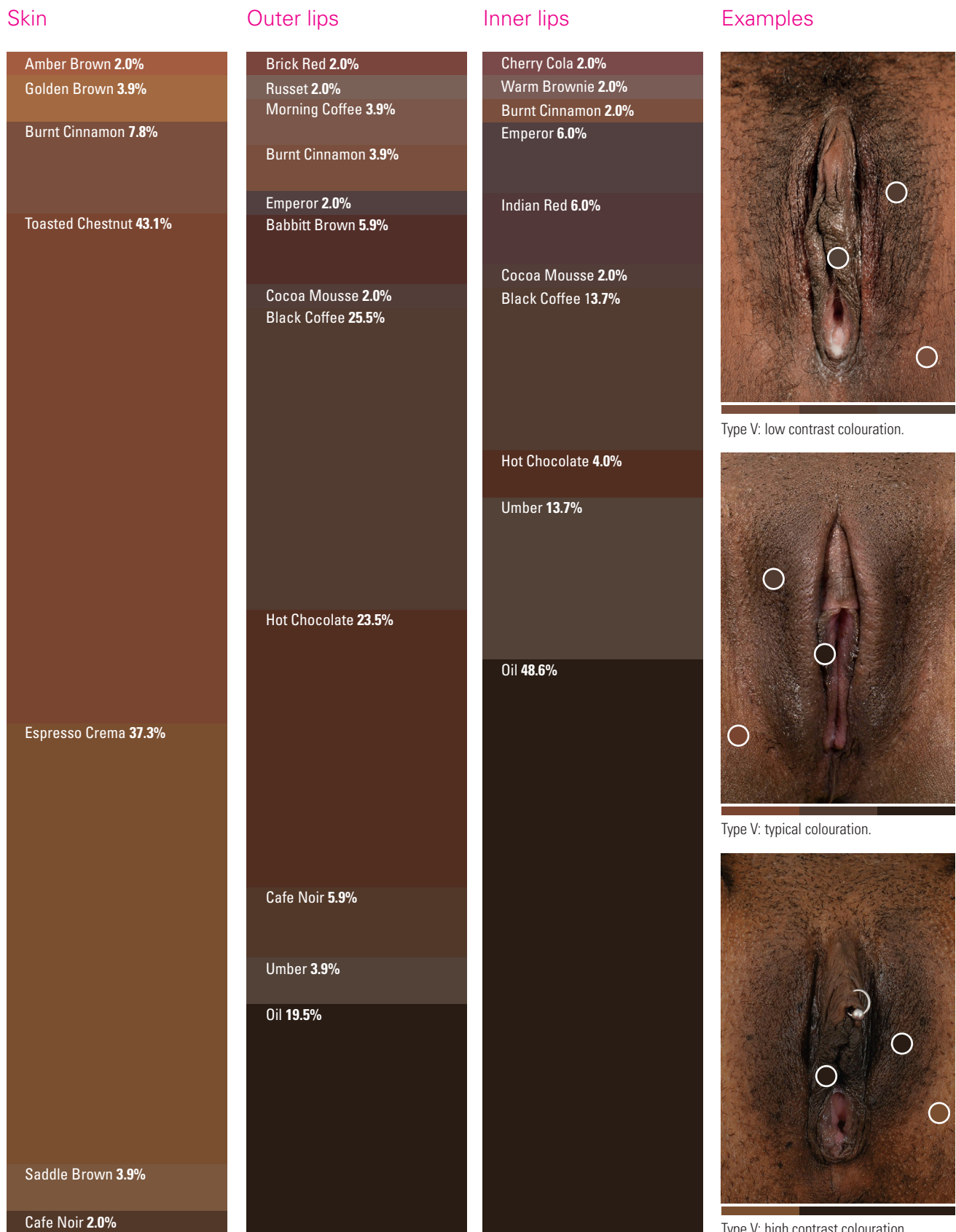
Type IV: typical colouration.



Type IV: high contrast colouration.

### 3.6 TYPE V

This section shows the colours found in the skin, outer lips and inner lips of women with skin type v.  
The probability of a given colour is illustrated by the size of its swatch.



Type V: low contrast colouration.


Type V: typical colouration.

Type V: high contrast colouration.


### 3.7 TYPE VI

This section shows the colours found in the skin, outer lips and inner lips of women with skin type VI.  
The probability of a given colour is illustrated by the size of its swatch.


#### Skin



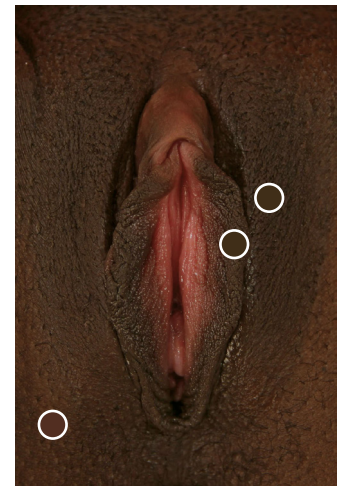
#### Outer lips



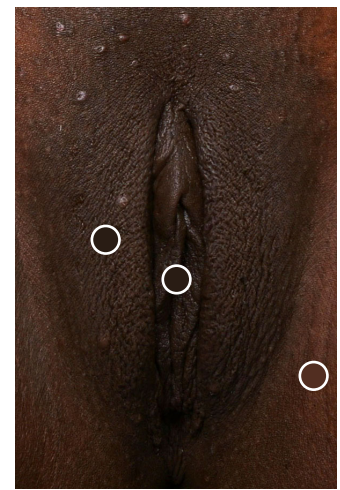
#### Inner lips



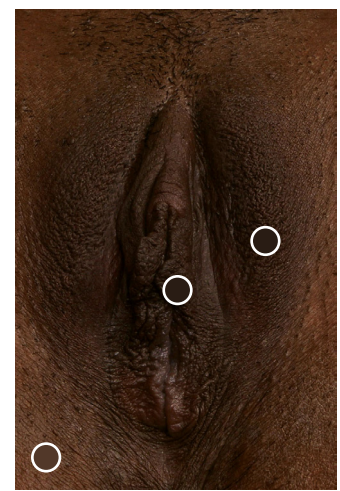
#### Examples



Type VI: low contrast colouration.



Type VI: typical colouration.



Type VI: high contrast colouration.

## RESULTS AND CONCLUSION

All vulvae observed in the population could be mapped successfully into exactly one of the categories contained within each of the common anatomical aspects. Additionally, occasional anatomical variations were found in small percentages of the population.

Given the size of the population, the existence of vulvae that would require additional categories to be added to the classification to be able to map them, is possible. We plan to expand the population as we receive more contributions that are suitable and update this document accordingly.

However, the current classification resulting from this study is probably comprehensive enough to successfully map and describe the vast majority of naturally occurring variation found in the female external genitalia.

## REFERENCES

1. Pryce, L. (2015) *Gynodiversity Shooting Guide*. <http://gynodiversity.com/shooting-guide.html>.
2. Fitzpatrick, T.B. (1988) *The validity and practicality of sun reactive skin types I through VI*. Arch. Dermatol. 124; 869-871.