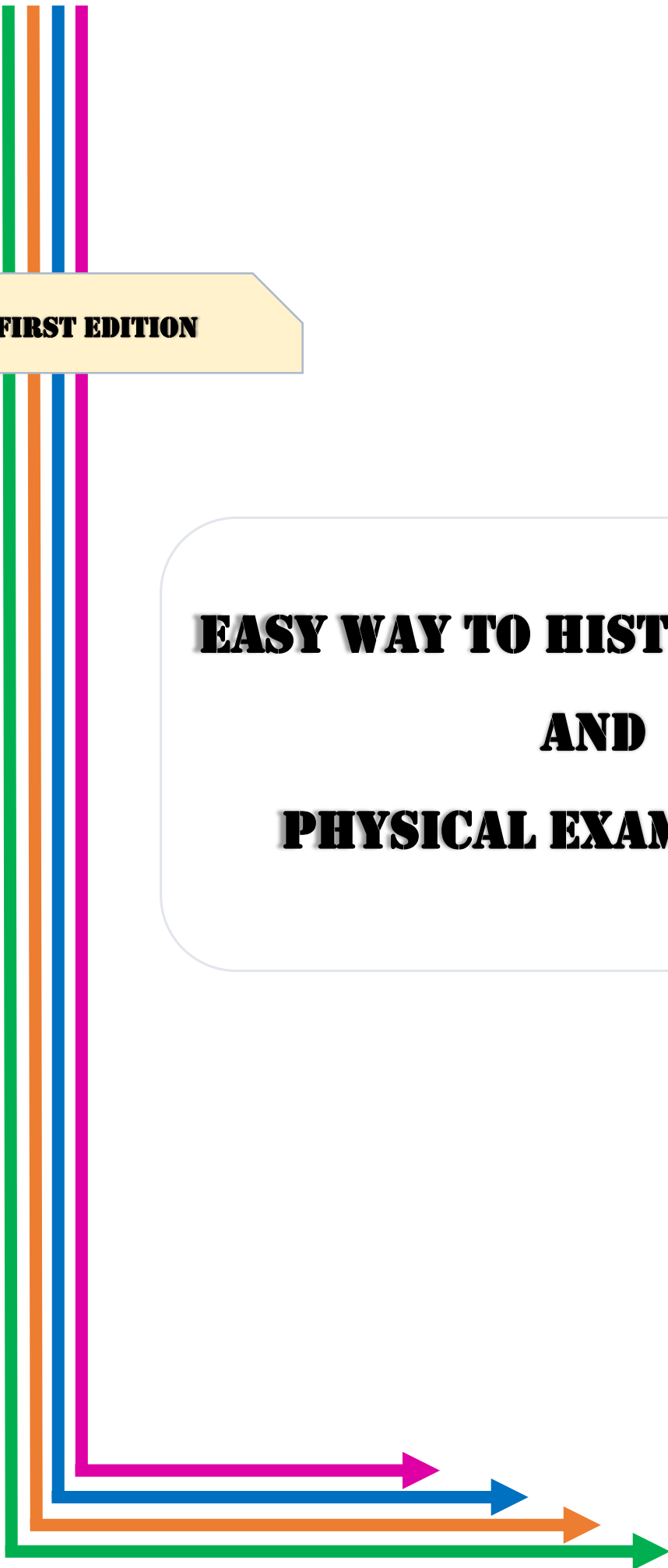





**FIRST EDITION**

**EASY WAY TO HISTORY TAKING  
AND  
PHYSICAL EXAMINATION**



# **Introduction**

**The Name Of Allah The Most Gracious The Merciful**

**We Are Swaed Team , Putting This Book In Your Hand Dear Student .**

**We Hope This Book Will Help You In Your Medical Courses As A Fast And Simple Source Of Informations That You Will Need To Improve Your Clinical Skill .**

## **About The Team :**

**The Team Aims To Lend A Helping Hand For Medical Students In Different Years Through The Work Of A Group Of Abstracts That Would Contribute To Facilitating Studying And Recalling The Informations .**

# **Names Of Participants**

- Raed Hamad Hassan Rayani .
- Suzan Ali Mohammed Alhazmi .
- Ebtehal Zaid Mahdi Alqahtani .
- Tahani Ahmed Moasa Moafa .
- Rafan Abdulrahman Mohammad Madkor .
- Shatha Ibrahim Qassem Alqassemi .
- Mona Ali Mansour Gahtani .
- Rafea Hassan Ali Fathi .
- Muath Hassan Ibrahim Najmi .
- Wedad Mohammad Mohammad Alhazmi .
- Arwa Ahmed Ali Abutaleb .
- Nadiah Taher Ali Somily .
- Mathab Ali Abdulwahab Jarad .
- Nehad Khalaf Mohammad Khawaji .
- Mymona Abdullah Sulaiman Alfaifi .
- Nourah Hamad Soliman Alkeaid .
- Feras Essa Mohammed Al-Omar .
- Alrumaisaa Ahmad Abdu Daafi .
- Abdulrahman Ali Ahmed Khawaji .
- Nouf Mohammed Ahmed Mari .
- Ali Mansor Taher Sumayli .
- Ali Mohammed Abdu Abutaleb .
- Duaa Thyabi Yahya Hakami .
- Azhar Ahmad Abdu Halawi .
- Aisha Yahya Mohammad Alkhaldy .
- Samira Mohammed Ali Nasib .
- Nada Mohammad Hasser Hakami .
- Saud Abdulaziz Musa Alqhtany .
- Ahmed Hadi Ahmed Alkhormi .
- Azhar Eisa Lahige Dallak .
- Amnah Ali Azzam Shubayli .
- Reem Mohammed Yahya Kariri .
- Taysir Hassan Jadduh Hakami .

## **Contact Informations**

**# e-Mail : [saudihelpers@gmail.com](mailto:saudihelpers@gmail.com)**

**# Twitter :**

**@RaedRayani " <https://twitter.com/RaedRayani> "**

**@Swaed\_Team " [https://twitter.com/Swaed\\_Team](https://twitter.com/Swaed_Team) "**

**# Facebook :**

**Raed Rayani " <https://www.facebook.com/raed.rayani> "**

**We Are Pleased To Receive Your Comments And  
Suggestions On This Email 😊**

**" [saudihelpers@gmail.com](mailto:saudihelpers@gmail.com) "**

# **Book Contents**

**Internal Medicine ..... Page : 1**

**General Surgery ..... Page : 94**

**Pediatrics ..... Page : 160**

**Obstetric & Gynecology ..... Page : 237**

**References ..... Page : 274**

# **Chapter ( 1 )**

## **" Internal Medicine "**

### **# Content :**

- **General History Form ..... Page : 2**
- **General Examination ..... Page : 8**
- **Cardiology ..... Page : 13**
  - **History Of Common Cases ..... Page : 14**
  - **Cardiology Examination ..... Page : 19**
- **Pulmonogy ..... Page : 36**
  - **History Of Common Cases ..... Page : 37**
  - **Respiratory Examination ..... Page : 40**
- **GIT ..... Page : 50**
  - **History Of Common Cases ..... Page : 51**
  - **GIT Examination ..... Page : 54**
- **Neurology ..... Page : 61**
  - **History Of Common Cases ..... Page : 62**
  - **Neurology Examination ..... Page : 66**
- **Hematology ..... Page : 77**
- **Nephrology ..... Page : 79**
- **Endocrinology ..... Page : 82**
- **Infectious Diseases ..... Page : 85**
- **DDx Of Common Signs & Symptoms ..... Page : 88**



**General History In**  
**Medicine**

# General History In Medicine

## 1- Personal History :

- ✓ **Name** : For Identification & To Be Familiar With Patient .
- ✓ **Age** : Certain Diseases Are Related To Certain Age Groups .
- ✓ **Sex** : Some Diseases Are More Common In Males / Females .
- ✓ **Nationality** : Certain Diseases Are Related To Certain Countries .
- ✓ **Home & Residence** : Certain Diseases Are Related To Certain Areas .
- ✓ **Occupation** : Some Diseases Are Related To Certain Occupations .
- ✓ **Marital Status** .
- ✓ **Date Of Admission** .

## 2- Chief Complaint ( C/O ) :

- ✓ In Patient's Own Words .
- ✓ Write The Duration .
- ✓ Sort Them In Chronological Manner .

Example : Right Inguinal Swelling / 1 Month .

## 3- History Of Presenting Illness ( HPI ) :

A- *The Patient Is Known Case Of ..... ( Chronic Disease ) .*

B- *The Patient Was Well Till / On Usual Status Till ..... ( Hours - Days - Weeks - Months ) Back When He/She Started To Has ..... ( Complaint ) .*

C- *Analysis Of Complaint :*

## I) General Symptoms :

- 1- **Fever** : Onset , Course , Duration , Pattern , Grade , Associated With ( Rigors - Convulsions - Skin Rash ) .
- 2- **Wight Changes** : Onset , Course , Duration , How Much ? , Associated Symptoms .
- 3- **Fatigue / Malaise** : Onset , Course , Duration , Grade , Associated Symptoms .



## II) GIT Symptoms :

- 1- Dysphagia / Odynophagia: Onset , Course , Duration , Type ( Food - Fluid ) , Level , Associated Symptoms .
- 2- Regurgitation: Onset , Course , Duration , Associated Symptoms .
- 3- Loss Of Appetite: Onset , Course , Duration , Associated Symptoms .
- 4- Nausea: Onset , Course , Duration , Associated Symptoms .
- 5- Vomiting: Onset , Course , Duration , Content , Color , Odour , Relation To Eating , Precipitated By Nausea , Associated Symptoms .
- 6- Abdominal Pain: Site , Onset , Course , Duration , Character ( Nature ) , Radiated / Referred / Shifted , Aggravating & Relieving Factors , Severity ( Measured By : Interfering With Daily Activities , 0-10 Score ) , Associated Symptoms .
- 7- Abdominal Swelling: Site , Onset , Course , Duration , Associated Symptoms .
- 8- Diarrhea: Onset , Course , Duration , Content , Color , Odour , Frequency , Consistency , Associated Symptoms .
- 9- Constipation: Onset , Course , Duration , Type ( Partial - Complete ) , Presence Of Anal Pain , Associated Symptoms .
- 10- Jaundice: Onset , Course , Duration , Who Notice ? , Stool Color , Urine Color , RUQ Pain .
- 11- Bleeding: Onset , Course , Duration , Content , Color , Odour .

## III) Cardio-Pulmonary Symptoms :

- 1- Cough: Onset , Course , Duration , Character , Frequency , Aggravating & Relieving Factors , Sputum , Relation To Position , Associated Symptoms .
- 2- Sputum: Onset , Course , Duration , Color , Odour , Amount , Relation To Position , Consistency .
- 3- SOB: Onset , Course , Duration , Type , Severity , Grade , Associated Symptoms .
- 4- Chest Pain: Site , Onset , Course , Duration , Character , Radiation , Aggravating & Relieving Factors , Associated Symptoms ( Abdominal Pain , Nausea , Vomiting , Sweating , Fever ) .
- 5- Palpitation: Onset , Course , Duration , Rhythm , Occurrence ( Exposure - Exertion ) , Frequency , Associated Symptoms .
- 6- Syncope: Onset , Course , Duration , Occurrence ( Exposure - Exertion ) , Frequency , Associated Symptoms .
- 7- Wheeze: Onset , Course , Duration , Occurrence ( Exposure - Exertion ) , Associated Symptoms .
- 8- Cyanosis: Site ( Oral - Extremities ) , Onset , Course , Duration , Occurrence ( Rest - Exertion ) , Relation To Position , Associated Symptoms .
- 9- Lower Limb Swelling: Onset , Course , Duration , Site ( Uni/Bilateral ) , Ascending / Descending , Result From Trauma ? , Associated Symptoms .

## IV) CNS Symptoms :

- 1- Symptoms Suggestive Of Higher Functions Involvement : Onset , Course , Duration , Type , Associated Symptoms .
- 2- Symptoms Suggestive Of Cranial Nerves ( CNs ) Involvement : Onset , Course , Duration , Type , Function Impairment ( Sensory , Motor , Gustatory ) , Associated Symptoms .
- 3- Weakness : Site , Onset , Course , Duration , Grade , Features Of Increased Intra-Cranial Pressure ( ICP ) , Associated Symptoms .
- 4- Abnormal Movement : Site , Onset , Course , Duration , Type , Features Of Increased ICP , Sphincter Function , Associated Symptoms .
- 5- Headache : Site , Onset , Course , Duration , Grade , Character , Related To Trauma , Associated Symptoms .

### \*\* Notes :

- Symptoms Of Higher Function : Loss Of Consciousness - Memory - Speech , ... Etc.
- Symptoms Of CNs Involvement : Anosmia , Visual Field Defect , Diplopia , Abnormal Sensation In The Face , Symptoms Of Facial Nerve Palsy , Decrease Hearing / Vertigo , Dysphagia , Nasal Regurge , Tongue Deviation .
- Symptoms Of Increased ICP : Headache , Blurred Vision , Projectile Vomiting .

## V) Genito-Urinary Symptoms :

- 1- Pain : Site , Onset , Course , Duration , Character , Radiation , Aggravating & Relieving Factors , Severity , Associated Symptoms .
- 2- Polyuria : Onset , Course , Duration , Frequency , Volume , Associated Symptoms .
- 3- Dysuria : Onset , Course , Duration , Associated Symptoms .
- 4- Hesitancy / Urgency / Urine Retention : Onset , Course , Duration , Associated Symptoms .
- 5- Incontinence : Onset , Course , Duration , Related To Neurological Problem ? , Associated Symptoms .
- 6- Discharge : Onset , Course , Duration , Color , Amount , Odour , Consistency , Itching .

## VI) Musculo-Skeletal Symptoms :

- 1- Bone / Joint / Muscle Pain : Site , Onset , Course , Duration , Character , Radiation , Aggravating & Relieving Factors , Severity , Frequency ( Morning / Night ) , Any Swelling , Limitation Of Movement , Trauma , Stiffness , Associated Symptoms .
- 2- Joint / Muscle Swelling : Site , Onset , Course , Duration , Trauma , Stiffness , Associated Symptoms .

## VII) Skin Symptoms :

- 1- Skin Rash : Onset , Course , Duration , Distribution , Type , Associated Symptoms .
- 2- Itching : Onset , Course , Duration , Associated Symptoms .
- 3- Hyper/Hypo Pigmentation : Onset , Course , Duration , Associated Symptoms .
- 4- Hirsutism / Alopecia : Onset , Course , Duration , Associated Symptoms .
- 5- Ulcer : Onset , Course , Duration , Itching , Loss Of Sensation , Associated Symptoms .

### *D- Review The Symptoms Of The Affected System :*

- Example : In The Case Of Abdominal Pain , You Have To Review Other GIT Symptoms Which Include :  
Dysphagia , Heartburn , Jaundice , Hematemesis , Constipation , Diarrhea , Melena , Bleeding Per Rectum .

### *E- Systemic Review :*

- **CNS** : Headache , Dizziness , Change In Behavior , Loss Of Consciousness , Weakness , Abnormal Movement .
- **GIT** : Dysphagia , Heartburn , Jaundice , Hematemesis , Constipation , Diarrhea , Melena , Bleeding Per Rectum .
- **Cardio-Pulmonary** : Cough , Hemoptysis , Dyspnea , Chest Pain , Palpitations , Syncope , Claudication .
- **Urogenital** : Loin Pain , Dysuria , Polyuria , Hematuria , Urethral Discharge .
- **Skin & Musculoskeletal** : Pain , Muscle Wasting , Pigmentation , Ulcers .
- **Hematology** : Easy Fatigability , Petichiae , Gum Bleeding , Pallor .

### *F- Hospital Course :*

- **Investigations** .
- **Medications & Interventions** .
- **Improving OR Not** .

## 4- Past History :

- **Chronic Diseases ( HTN , DM , Asthma , TB , Hepatitis , HIV )** : When , Where & How Diagnosed ?
- **Similar Conditions** .
- **Previous Hospital Admissions** .
- **Previous Surgical Interventions** .
- **Previous Blood Transfusion** .

## 5- Family History :

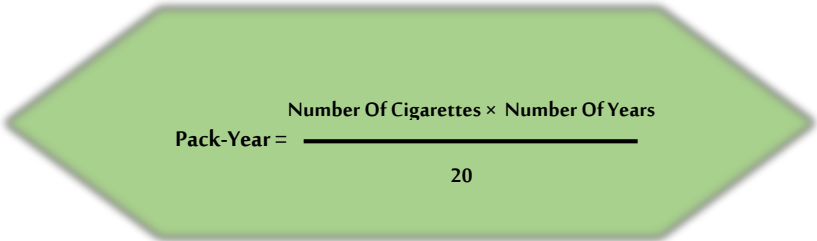
- Chronic Diseases ( HTN , DM , Asthma , TB , Hepatitis , HIV ) .
- Similar Conditions .
- Inherited / Genetic Diseases .
- Consanguinity .
- History Of Sudden Death , Cancers .

## 6- Social History :

- Housing Conditions .
- Social & Educational Class .
- Special Habits ( Alcohol Abuse , Smoking , Drug Abuse , Sexual Activities , ... ) .
- History Of Recent Travelling ( When , Where , How Many Times ) .
- Contact With Animals .

## 7- Drug & Allergies History :

- Long Term Medications .
- Short Term Medications .
- Allergy To Certain Food OR Medication .

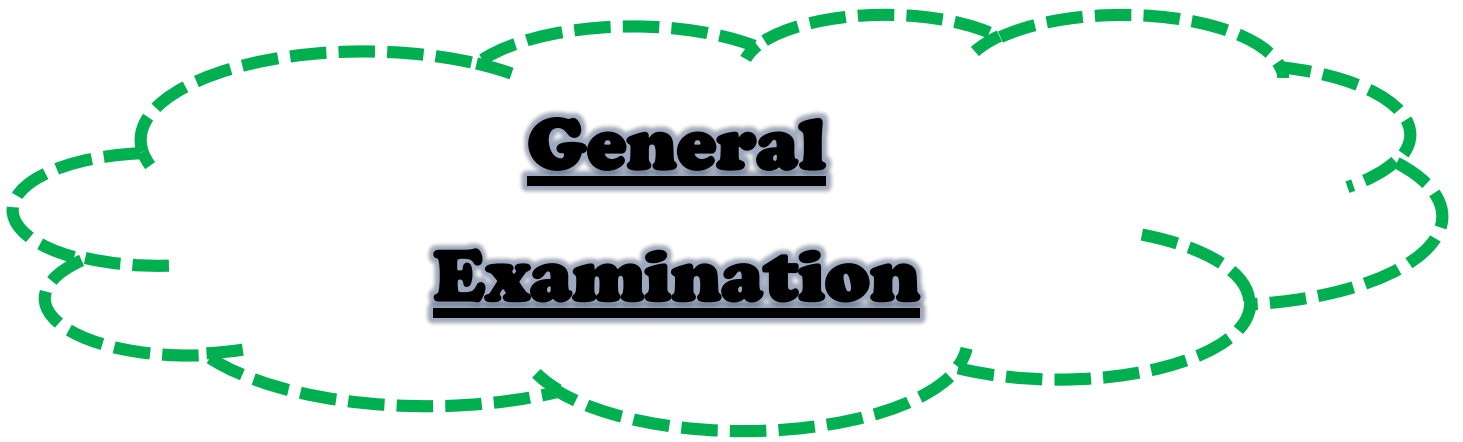

$$\text{Pack-Year} = \frac{\text{Number Of Cigarettes} \times \text{Number Of Years}}{20}$$

**\*\* Note :** For Smoking , You Have To Ask About : Duration + Type + Smoking Index ( Pack-Year ) .

## 8- Obstetric & Gynecological History :

- Age Of Menarche , Regularity , Character ( Heavy OR Not ) , Duration , Volume .
- Age Of Menopause .
- Use Of Contraception Methods .
- Duration Of Delivery , Mode Of Delivery Of Each One & Complicated OR Not .

" Summary "



**General**  
**Examination**

# General Examination

## - ABCDE :

- ✓ **Appearance :** Looks Well/Ill , Consciousness , Alert , Orientation To Time - Palace - Person .
- ✓ **Body Built :** Average , Thin , Obese ( Depends On BMI ) .
- ✓ **Color :** Pale , Cyanosed , Erythematous .
- ✓ **Decubitus :** Patient's Sitting & Position .
- ✓ **Environment :** Any Connections To Patient ( IV Line , Catheter , O<sub>2</sub> Mask , Wheelchair , ...Etc. )

## - Vital Signs :

- ✓ **Temperature ( Temp ) :** Normally (  $37.2 \pm 0.4$  °C ) .
- ✓ **Pulse :** Normally ( 60-100 Beat/Min ) .
- ✓ **Blood Pressure ( BP ) :** Normally ( 120-139/80-90 mmHg ) .
- ✓ **Respiratory Rate ( RR ) :** Normally ( 12-16 Breaths/Min ) .
- ✓ **O<sub>2</sub> Saturation :** Normally ( > 98% ) .

## \*\* Note : Comments On Pulse :

- Rate : For 30 Seconds  $\times$  2 OR 15 Seconds  $\times$  4 ( If Regular ) .
- Rhythm : Regular Or Irregular .
- Volume : Large , Average , Low .
- Character : Collapsing Pulse , Pulsus Paradoxus , Pulsus Alternans , ...
- Radio-Radial , Radio-Brachial & Radio-Femoral Delay .
- Condition Of Vessel Wall .

## - Hands : ( Compare Both Hands Together )

### ✓ Nails :

- Clubbing . ( Pic.1 )
- Capillary Refill . ( Pic.2 )
- Splinter Hemorrhage . ( Pic.3 )
- Peripheral Cyanosis . ( Pic.4 )
- Koilonychia . ( Pic.5 )
- Leukonychia . ( Pic.6 )

### Grades Of Clubbing :

- **1** > Fluctuation Of The Nail Bed .
- **2** > Obliteration Of The Lovibond Angle .
- **3** > Parrot Beak Appearance Or Drum Stick Appearance .
- **4** > Hypertrophic Osteo-Arthropathy ( HOPA ) .

✓ **Palm :**

- Muscle Wasting .
- Palmar Erythema . ( Pic.7)
- Pallor Which Seen In Palmar Creases . ( Pic.8)
- Osler Node Which Seen In Palmar Surface Of Fingertip .
- Janeway Lesions .

✓ **Tremors :**

- Flabbing Tremor , Fine Tremor .

✓ **Arm :**

- Tendon Xanthoma ( Yellowish Discoloration Of Tendon At Wrist ) .
- Bruises , Scratch Marks , Ulcers , Scars , Pigmentation .
- Muscle Wasting
- Spider Nevi ( In Face - Neck - Upper Chest Also ) .

- **Head & Neck :**

✓ **Eye :**

- Jaundice : Look At Upper Bulbar Conjunctiva While Patient Is Looking Downward . ( Pic.9)
- Pallor : Look At Lower Palpebral Conjunctiva While Patient Is Looking Upward . ( Pic.10)
- Peri-Orbital Edema . ( Pic.11)
- Xanthelasma .

✓ **Mouth:**

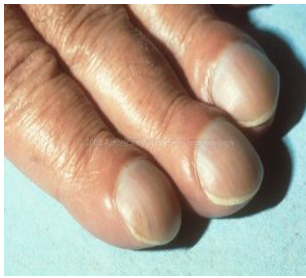- Cyanosis : Lips For Peripheral Cyanosis & Tongue For Central Cyanosis . ( Pic.12)
- Jaundice : In Mucous Membranes .
- Aphthous Ulcer & Candida , Glossitis , Mouth Hygiene , Odour Of Breath .

✓ **Neck :**

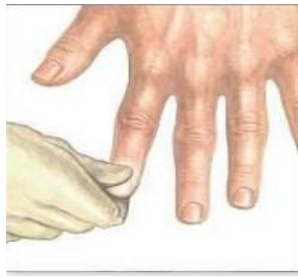
- Lymph Nodes .
- Jugular Vein .
- Carotid Artery .

- **Lower Limbs :**

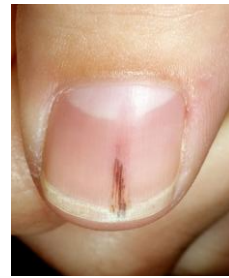- Skin Changes , Muscle Wasting , Loss Of Hair .
- Edema : Pitting / Non-Pitting - Unilateral / Bilateral - Level . ( Pic.13)
- Pulse : Femoral - Popliteal - Dorsalis Pedis - Posterior Tibial . ( Pic.14+15)



**Pic.1**



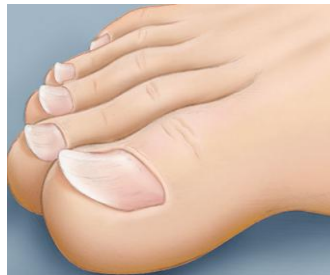**Pic.2**



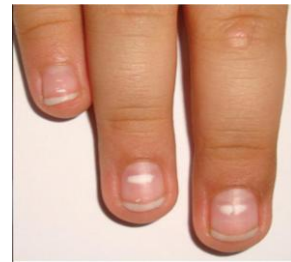**Pic.3**



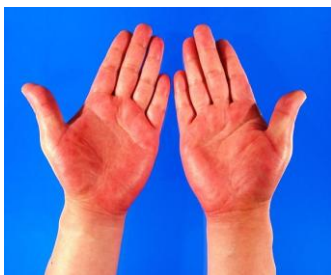**Pic.4**



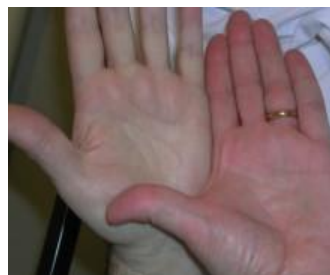**Pic.5**



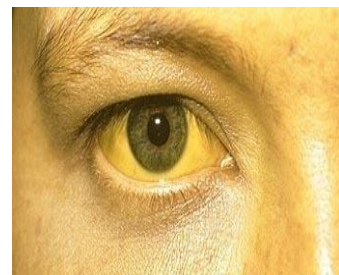**Pic.6**



**Pic.7**

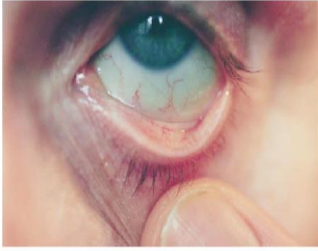

**Pic.8**

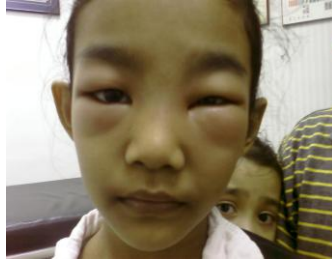

**Pic.9**

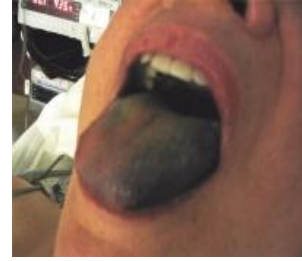



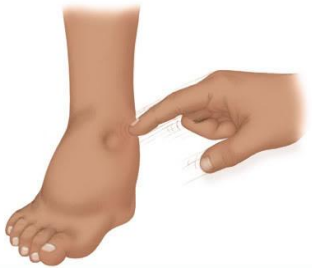**Pic.10**



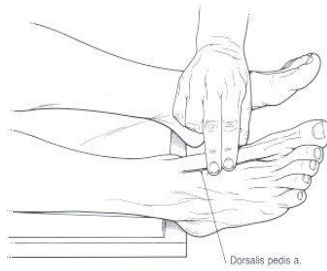
**Pic.11**



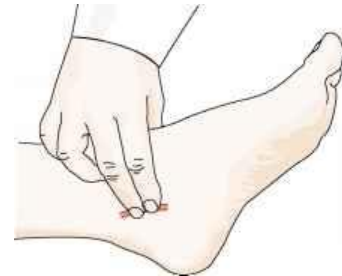**Pic.12**



**Pic.13**

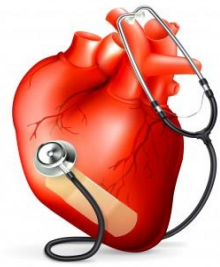


**Pic.14**



**Pic.15**

# Cardiology



# History Of Common Cases

## 1) Congestive Heart Failure ( CHF ) :

### - Personal History:

Ahmed Mohammed Ali , 68 Y/O Saudi Male From Jazan , Retired , Married For 38 Years And Has 7 Offsprings . Admitted Through ER On 2-1-1436 H .

### - C/O:

SOB / 2 Days .

### - HPI:

The Patient Is Known Case Of HTN , DM & CHF .

He Was On Usual Status Till 2 Days Back When He Started To Has SOB Which Was Acute In Onset , Progressive In Course , Aggravated By Lying Flat and By Moderate Exertion , Relieved By Setting And Rest , Awakening The Patient 2 Hours After Sleeping , Associated With Lower Limb Swelling Which Is Bilateral , Painless And Increasing Gradually . There No Wheezing , No Chest Pain , No Palpitation , No Cyanosis , No Cough .

● Systemic Review : -Ve Apart From Increase In Body Weight .

● Hospital Course : Underwent CBC , ECG , Chest X-Ray , Oxygen , Diuretics And The Patient Is Improving .

### - Past History:

HTN & DM Were Diagnosed In KFCH 10 Years Back , CHF Was Diagnosed In KFCH 2 Years Back , And All Are Controlled . +Ve History Of 2 Previous Similar Attacks With Admissions .

### - Family History:

-Ve Apart From +Ve Consanguinity , +Ve Hx Of HTN And DM In His Father & +Ve Hx Of Sudden Death .

### - Social History:

Good Living Conditions & Socio-Economic Status .

He Is Heavy Smoker ( 3 Buckets/Day For 20 Year ) .

### - Drugs & Allergies:

On ACEI + Diuretics + Hypoglycemic Agent ( Metformin ) .

### Summary

68 Y/O Saudi Male Admitted Through ER Complaining Of SOB / 2 Days , Which Associated With Lower Limb Edema , He Is A Known Case Of Controlled HTN , DM & CHF . He Is Heavy Smoker , And +Ve Hx Of Sudden Death In His Family .

### +Ve Findings In Examination:

- General Examination: Looking Ill , In Cardiac Bed , Dyspnic , LL Swelling , Raised JVP .

### - Local ( Precordium ) Examination:

✓ **Inspection:** Apex Beat In The 6<sup>th</sup> ICS , Anterior Axillary Line .

✓ **Palpation:** Diffuse , Displaced Apex Beat .

✓ **Auscultation:** S3 Gallop , Systolic Murmur , Bilateral Lung Bases Crackles .

## 2) Ischemic Heart Disease ( IHD ) :

### - Personal History :

Ahmed Mohammed Ali , 43 Y/O Saudi Male From Jazan , Retired , Married For 38 Years And Has 7 Offsprings . Admitted Through ER On 2-1-1436 H .

### - C/O :

Chest Pain / 1 Day .

SOB / 4 Hours .

### - HPI :

The Patient Is Known Case Of HTN .

The Patient Was On Usual Status Till 1 Days Back When He Started To Complain From Retrosternal Chest Pain , Lasting For 15 Minute , Heaviness-Like Pain , Severity 5 From 10 , Aggravated By Exercise , No Relieving Factors , Radiated To The Left Shoulder , Associated With SOB Which Was Acute In Onset , Progressive In Course , 1 Days Duration , Aggravated By Stress Or Moderate Exertion , Relieved By Setting And Rest . No Fever , No Palpitation , No Cough , No Cyanosis , No LL Swelling , No Wheeze .

● Systemic Review : -Ve .

● Hospital Course : Underwent CBC , ECG , Chest X-Ray , Cardiac Enzymes , Oxygen , Nitrates & The Patient Is Improving .

### - Past History :

-Ve Apart From HTN Which Diagnosed In KFCH 8 Years Back & Controlled .

### - Family History :

-Ve Apart From +Ve Consanguinity , +Ve Hx Of HTN And DM In His Father & +Ve Hx Of Sudden Death .

### - Social History :

Good Living Conditions & Socio-Economic Status .

He Is Heavy Smoker ( 3 Buckets/Day For 20 Year ) .

- Drugs & Allergies : On Anti-HTN Drugs & Diuretics .

### Summary

43 Y/O Saudi Male Admitted Through ER Complaining Of Chest Pain / 1 Days & SOB / 4 Hours , The Pain Is Retrosternal , Heaviness-Like & Radiated To Left Shoulder Associated With SOB , He Is A Known Case Of Controlled HTN . He Is Heavy Smoker , And +Ve Hx Of Sudden Death In His Family .

### +Ve Findings In Examination :

- General Examination : Looking Ill , Dyspnic , Restless , With Bradycardia / Tachycardia ± Hypotension .

- Local ( Precordium ) Examination :

✓ Palpation : Dyskinetic Apex Beat .

✓ Auscultation : S3 , S4 , Decrease Intensity Of Heart Sound , Transient Apical Holo-Systolic Or Late Systolic Murmur .

### 3) Rheumatic Fever ( RF ) :

- **Personal History :**

Ahmed Mohammed Ali , 18 Y/O Saudi Male From Jazan , Single Student . Admitted Through ER On 2-1-1436 H .

- **C/O :**

Fever + Joint Pain / 5 Days .

Awareness Of Heart Beat / 1 Day .

- **HPI :**

Patient Was Well Till 5 Days Back , When He Started To Has Fever Which Was Acute Onset , Low Grade , Intermittent Fever ( 38.5 °C ) Relieved By Antipyretic And Cold Compressor , Not Associated With Convulsion , Chill Or Rigor . On The Same Time He Was Complaining From Acute , Intermittent , Severe , Asymmetrical Joints Pain ( Affect His Right Knee Joint Then Resolved Completely After 2 Days And Now It Migrate To His Left Elbow Joint ) , Increase With Movement , Slightly Decrease With Paracetamol , Associated With Swelling , Redness Of Affected Joint And Limitation Of Movement During The Attacks , And Not Associated With Stiffness . No History Of Trauma . 1 Day Back He Started Complaint Of Awareness Of Her Heart Beat . No Chest Pain , No SOB , No Cough , No Cyanosis , No Muscle Wasting Or Pain .

● Systemic Review : -Ve Apart +Ve History Of Lethargy , Anorexia , Loss Of Weight ( Loss 1 Kg Of His Weight ) .

● Hospital Course : Underwent CBC , ECG , Chest X-Ray , Throat Swab , I.V Fluids . Analgesics & The Patient Is Improving .

- **Past History :**

-Ve Apart From History Of Pharyngitis 3 Weeks Back .

- **Family History :** -Ve .

- **Social History :** Good Living Conditions & Socio-Economic Status .

- **Drugs & Allergies :** Short-Term Use Of Aspirin & Corticosteroids .

#### Summary

18 Y/O Saudi Male Admitted Through ER Complaining Of Fever , Joints Pain / 5 Days , Awareness Of Heart Beat / 1 Day . Joint Pain & Swelling Was Migratory . He Has History Of Pharyngitis 3 Weeks Ago .

#### +Ve Findings In Examination :

- **General Examination :** Lethargy , Loss Of Weight , Tachycardia , Maybe Dyspnea .

- **Skin :** Erythema Marginatum .

- **MSS :** Subcutaneous Nodules Over Extensor Surface Of Bone Or Tendons , Redness , Hotness , Tenderness , Limitation Of Movement , Swelling Of Affected Joint ( Migratory Arthritis ) .

- **Precordium Examination :**

✓ **Inspection :** Parasternal Bulge Or Visible Parasternal Pulsation ( Due To Left Atrial Enlargement ) .

✓ **Auscultation :** Murmur Of Valvular Lesion .

- **Neurological :** Purposeless Involuntary Choreiform Movement Of Face , Hands Or Feet ( Sydenham's Chorea ) .

## 4) Pericarditis :

### - Personal History :

Ahmed Mohammed Ali , 30 Y/O Saudi Male From Jazan , Soldier , Married For 5 Years And Has 2 Offsprings . Admitted Through ER On 2-1-1436 H .

### - C/O :

Chest Pain / Today Morning .

### - HPI :

Patient Came To Hospital After He Started Complaint Of Acute , Progressive , Sharp , Stitching , Central Chest Pain , Radiate To Neck And Left Shoulder , Aggravated By Movement , Respiration And Lying Down And Relieved By Sitting Forward , Associated With Painful Inspiration . His Recent History Includes A Slight Fever And Chills With Progressive Upper Respiratory Illness Over The Last Two Days . He Adds That He's Been Sick Since He Came Home From His Dentist's Office After Having A Cavity Filled . No Palpitation , No Cough , No Cyanosis , No Dyspnea , No LL Swelling , No Wheeze .

● Systemic Review : -Ve .

● Hospital Course : Underwent , ECG , Blood Test , Oxygen , IV Fluid , Nitroglycerine , Aspirin And The Patient Is Improving .

- Past History : -Ve .

- Family History : -Ve .

- Social History : Good Living Conditions & Socio-Economic Status .

- Drugs & Allergies : Short-Term Use Of Aspirin & Nitroglycerine .

### Summary

30 Years Old Saudi Male Admitted To Hospital Complaining Of Chest Pain .

He Has History Of Upper Respiratory Illness 2 Days Back Since He Came Home From His Dentist's Office .

### +Ve Findings In Examination :

- General Examination : Looking Ill , Tachypnic , Dyspnic & Feverish .

- Local ( Cardiology ) Examination :

✓ Pericardial Friction Rub Is Characteristic .

## 5) Infective Endocarditis :

### - Personal History :

Ahmed Mohammed Ali , 64 Y/O Saudi Male From Jazan , Retired , Married For 35 Years And Has 5 Offsprings . Admitted Through ER On 2-1-1436 H .

### - C/O :

SOB / 1 Day .

Red Urine / 3 Days .

### - HPI :

He Was On Usual Status Till 1 Week Back When He Started Feel General Malaise , Then 3 Days Back When He Started To Has Red Urine . The Urine Like Tea Acute Onset 3 Day Duration With No Dysuria , No Pain , No Polyuria , No Change In The Frequency , No Flank Pain , No Abdominal Pain And No Change In The Stool Color , No Diarrhea Or Constipation And No Jaundice . It Is Associated With The Fever Which Was Acute , 38.1 °C , Consistence With Chills , Not Associated With Rigor , Convulsions And Vomiting , With No Relieving Or Aggravating Factor , No Change In The Weight Or Decrease The Appetite . He Didn't Seek Medical Advice Until Yesterday When He Started To Has Sudden Onset Of Dyspnea , Progressive Aggravated By Moving With No Reliving Factor , Associated With Palpitation . No Chest Pain , No Cough , No Sputum , No Syncopal Attacks , No Cyanosis , No Wheeze & No LL Swelling .

● Systemic Review : -Ve .

● Hospital Course : Underwent CBC , ECG , CXR , Echo , Blood Culture , Oxygen , Antibiotic & The Patient Is Improving .

- Past History : -Ve .

- Family History : -Ve .

- Social History :

Good Living Conditions & Socio-Economic Status .

He Is Smoker ( 1 Bucket/Day For 2 Years ) .

- Drugs & Allergies : -Ve .

### Summary

64 Y/O Saudi Male Admitted Through ER Complaining Of SOB / 1 Day Associated With Palpitation , Red Urine And Fever \ 3 Days , Which Associated With Chills , He Is Smoker .

### +Ve Findings In Examination :

- General Examination : Looking Ill , Tachypnic , Dyspnic & Feverish , With Janeway Lesions , Osler's Nodes , Petichiae , Splinter Hemorrhage & Roth Spots .

# Cardiology Examination

## 1- General Examination :

### - ABCDE:

- ✓ **Appearance :** Looks Well/Ill , Consciousness , Alert , Orientation To Time - Place - Person .
- ✓ **Body Built :** Average , Thin , Obese ( Depends On BMI ) .
- ✓ **Color :** Pale , Cyanosed , Erythematous .
- ✓ **Decubitus :** Patient's Sitting & Position .
- ✓ **Deformities :** Any Congenital Abnormality ( If You Find One Anomaly Search For Others )
- ✓ **Distress :** Difficulty In Breathing ( Dyspnic ) .
- ✓ **Environment :** Any Connections To Patient ( IV Line , Catheter , O<sub>2</sub> Mask , ECG , Wheelchair , ...Etc. "

### \*\* Notes:

#### # Signs Of Respiratory Distress :

- Tachypnea .
- Tachycardia .
- Flaring Of Ala Nasi .
- Cyanosis .
- Using Of Accessory Muscles , Intercostal , Subcostal , Suprasternal Recession .
- Grunting .

#### # Some Syndromes Are Associated With Cardiac Problems Like :

- **Down Syndrome :** Associated With Endocardial Cushion Defect .
- **Marfan Syndrome :** Associated With Mitral / Aortic Valve Regurgitation .
- **Turner Syndrome :** Associated With Coarctation Of Aorta .

### - Vital Signs :

#### A- Temperature (Temp.):

- **Normal Range :**  $36.8^{\circ}\text{C} \pm 0.4$  (  $36.4^{\circ}\text{C} - 37.2^{\circ}\text{C}$  ) .
- **Some Causes Of Fever In A Cardiac Patient :**
  - ✓ Rheumatic Fever .
  - ✓ Acute Myocardial Infraction .
  - ✓ Myocarditis .
  - ✓ Acute Pericarditis .



**B- Respiratory Rate (RR):**

- Normal Range : 12 - 16 Breaths / Minute .

**C- Blood Pressure (BP):**

Category	Systole ( mmHg )	Diastole ( mmHg )
Hypotension	< 90	< 60
Optimal	< 120	< 80
Normal	120 - 129	80 - 84
High Normal	130 - 139	85 - 89
Mild HTN ( Grade I )	140 - 159	90 - 99
Moderate HTN ( Grade II )	160 - 179	100 - 109
Severe HTN ( Grade III )	> 180	> 110

**# NOTES :**

**# Postural Blood Pressure :**

- When There Is A Drop In Systolic BP More Than 15mmhg Or Diastolic BP More Than 10mmhg With Upright Posture , It May Associated With Dizziness .

**# Causes Of Postural Hypotension : ( HANDI )**

- **H** = Hypovolemia , Hypopituitarism .
- **A** = Addison's Disease .
- **N** = Neuropathy ( Autonomic ) , **E.g** : DM .
- **D** = Drugs : Vasodilators , Diuretics , Antipsychotic, TAC Antidepressant .
- **I** = Idiopathic .

**# Special Notes :**

- The Systolic BP May Normally Vary Between The Arms By Up To 10 mmHg , If More Than That You Have To Think About Some Diseases , **E.g** : Aortic Dissection .
- The Blood Pressure In The Legs Normally Higher Than In The Arms Up To 20 mmHg , Unless The Patient Has Some Disease , **E.g** : Coarctation Of Aorta ( BP In LL < UL ) .
- Peripheral Vascular Disease Of Lower Limb , BP In LL < UL .

## D- Pulse :

# Technique : Use The Index , Middle Finger & Ring Finger Of The Examining Hand . ( Pic.1 )

### 1- Radial Artery.

### 2- Brachial Artery.

### 3- Carotid Artery:

- This Is The Best Place To Assess The Pulse Volume And Character .
- Carotid Pulsation Not Normally Apparent On Inspection Of Neck , But May Be Present In Conditions Associated With Large Volume Pulse Such As Aortic Regurge , Anemia , Thyrotoxicosis And This Is Called ( Corrigan's Sign ) .
- Be Careful Not To Compress Both Carotids At Once , For Fear Of Diminishing Blood Flow To The Brain .

### 4- Femoral Artery:

- Can Be Felt Midway Between The Pubic Tubercle And The Anterior Superior Iliac Spine.

### 5- Popliteal Artery.

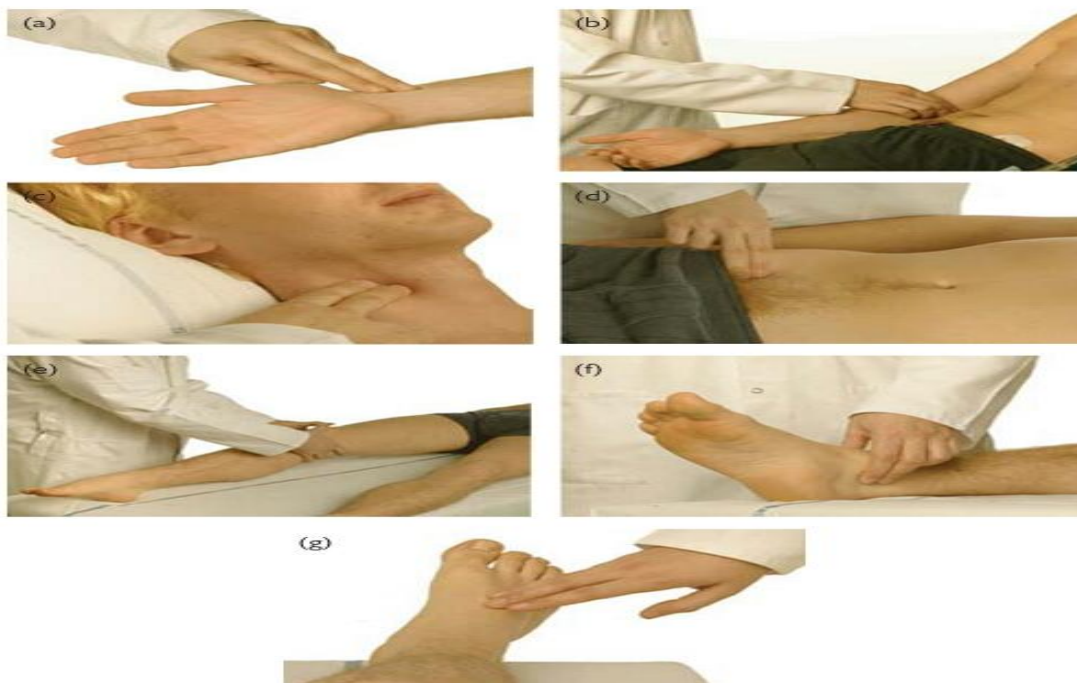### 6- Posterior Tibial Artery

- Palpate At The Ankle Just Posterior And Inferior To The Medial Malleolus

### 7- Dorsalis Pedis:

- This Runs Lateral To The Exterior Hallucis Longus Tendon On The Superior Surface Of The Foot Between The Bases Of The First And Second Metatarsals .

**Pic.1**



## # Comment On :

### A- Rate:

- **Normal** : 60 - 100 Beat / Minute .
- **Bradycardia** : Less Than 60 Beat / Minute .
- **Tachycardia** : More Than 100 Beat / Minute .
- Count For **1 Minute** , But In Regular Rhythm You Can Count For ( 15 Seconds  $\times$  4 ) **OR** ( 30 Seconds  $\times$  2 ) .

### B- Rhythm :

- **Regular** : Normal .
- **Irregular-Irregular** : Atrial Fibrillation .
- **Regular Irregular** : Sinus Arrhythmia .

### C- Volume :

- **Average Volume** .
- **High Volume** : Hyperdynamic Circulation ( Anemia , Pregnancy , ... ) .
- **Low Volume** : Shock , Severe Aortic Stenosis .

### D- Character :

#### 1- **Collapsing OR Water Hammer Pulse :**

- Large Volume Pulse Characterize By Short Duration With Brisk Rise And Fall .
- **Technique** : Palpitating The Radial Artery With Palmer Aspect Of Four Fingers While Raising The Patient's Arm Above The Level Of Heart .
- **E.g** : Aortic Regurge , Persistent Ductus Arteriosus , Anemia .

#### 2- **Pulsus Parvus :**

- Small Volume And Slow Rising To Peak .
- **E.g** : Aortic Stenosis .

#### 3- **Pulsus Alternans :**

- Regular Alternate Beats That Are Weak And Strong .
- It Is Easily Noticed When Taking BP ( By Sphygmomanometer ) Because Systolic BP May Vary From Beat To Beat As Much As 50 mmHg .
- **E.g** : Myocardial Failure ( LVF ) .
- Indicate Very Poor Prognosis .

#### 4- Pulsus Bigeminus :

- Premature Ectopic Beat Following Every Sinus Beat ( Giving Irregular Rhythm ) .
- E.g : Digitalis Toxicity , Hypokalemia .

#### 5- Pulsus Bisferiens :

- Palpable Double Systolic Pulse , ( It Is Normal If In Diastole ) .
- E.g : Hypertrophic Cardiomyopathy , Mixed Aortic Valve Disease .

#### 6- Pulsus Paradoxus :

- When Systolic And Diastolic BP Fall During Inspiration By More Than 10 mmHg , And This Will Decrease Pulse Volume Also .
- E.g : Pericardial Effusion, Constrictive Pericarditis , Severe CHF , Sever Asthma .

### E- Synchronization :

#### 1- Radio-Radial Delay :

- Occur Usually Due To Occlusion Or Stenosis On One Side , Dissection Of Thoracic Aorta Or Aortic Aneurysm .

#### 2- Radio-Femoral Delay :

- Suggest The Diagnosis Of Coarctation Of Aorta .

#### 3- Radio-Brachial Delay :

- Occur In Case Of Aortic Stenosis .

### F- Condition Of Vessel Wall :

- Assess Any Change In Medial Layer Of Radial Artery By Palpation .
- **Technique** : Empty The Radial Artery By Two Finger And Use One Finger To Assess The Wall By Rolling Radial Artery Against Radial Bone .
- **Felt Thickened ( Cord Like )** : Normal In Elderly And Atherosclerosis In Young People .

## - Upper Limb: ( Compare Both Hands Together )

- **Clubbing** . ( Pic.1 )
- **Capillary Refill** : > 2 Seconds ( Peripheral Vascular Disease , Hypothermia , Dehydration , Shock ) . ( Pic.2 )
- **Capillary Pulsation ( Quinke's Sign )** : Aortic Regurge .
- **Splinter Hemorrhage** ( Pic.3 ) , **Osler Node Which Seen In Palmar Surface Of Fingertip** ( Pic.4 ) , **Janeway Lesions** ( Pic.5 ) , **Petechial Rash , Evidence Of IV Drug Abuse** : Infective Endocarditis .
- **Peripheral Cyanosis** . ( Pic.6 )
- **Pallor Which Seen In Palmar Creases** .
- **Tendon Xanthoma ( Yellowish Discoloration Of Tendon At Wrist )** : Hyperlipidemia .
- **Erythema Marginatum** ( Pic.7 ) , **Subcutaneous Nodule** ( Pic.8 ) : Rheumatic Fever .

## - Head & Neck:

### ✓ **Eye**:

- **Jaundice** : CHF With Hepatic Congestion , Hemolysis Due To Prosthetic Valve . ( Pic.9 )
- **Pallor** : Anemia
- **Conjunctival Hemorrhage** : Infective Endocarditis . ( Pic.10 )
- **Roth's Spots** : Bacterial Endocarditis . ( Pic.11 )
- **Xanthelasma** : Hyperlipidemia . ( Pic.12 )

### ✓ **Mouth**:

- **Cyanosis** : Lips For Peripheral Cyanosis & Tongue For Central Cyanosis . ( Pic.13 )
- **Bad Dental Hygiene** : Infective Endocarditis .

### ✓ **Cheeks**:

- **Mitral Facies** : Severe Mitral Stenosis . ( Pic.14 )

### ✓ **Neck**:

- Lymph Nodes .
- Jugular Vein .
- Carotid Artery .

## # What Are The Differences Between Carotid Artery Pulsation & Jugular Vein Pulsation ?

Carotid Artery Pulsation	Jugular Vein Pulsation
Medial To The Sternomastoid Muscle	Along The Line Of Sternomastoid
Provide Information About Aorta And Left Ventricular Function	Provide Information About Right Atrial And Right Ventricular Function
Palpable More Than Visible	Visible But Not Palpable
Has One Peak	Has Two Peaks ( In Normal Sinus Rhythm )
Little Moves With Respiration	Normally Decrease On Inspiration
Hard To Obliterated	Obliterated And Filled From Above When Light Pressure Applied At The Base Of Neck
Not Affected By Changing The Posture	Affected By Changing The Posture , Goes Up With Being More Flat , And Vice Versa
Synchronous With Heart Beats	Not Synchronous With Heart Beats
Not Affected With Abdomino-Jugular Reflex	Abdomino-Jugular Reflex Cause Pulse To Raise

### 1- Carotid Artery:

#### - Inspection :

- ✓ Carotid Pulsation Not Normally Apparent On Inspection But May Be Visible In Conditions Associated With Large Volume Pulse , E.g : Aortic Regurgitation ( Corrigan's Sign ) , And May Be Normally Visible In Thin People .

#### - Palpation :

- ✓ To Assess The Pulse Volume And Character .
- ✓ Also Palpate For Thrill Of AS And AR As A Part Of Precordial Examination .

#### - Auscultation :

- ✓ For Any Bruit .

### 2- Jugular Vein :

#### A- Measurement :

- With The Patient Lying On 45° , Expose The Neck .
- Ask The Patient To Turn Head Away From You ( To Left ) And Ensure That The Neck Muscles Are Relaxed .
- Try To Look Upward , Along The Line Of The Sternomastoid . Don't Get Too Close , And Use Oblique Lighting ( By Torch ) To Make The Pulsation More Obvious .
- When You Assess If The Pulsation Palpable Or Not , Just Put Your Hand ( Don't Press ) Otherwise You Will Feel Transmitted Impulse From Carotid Artery And Mistakenly Will Diagnose Jugular Vein As Palpable Carotid Artery .

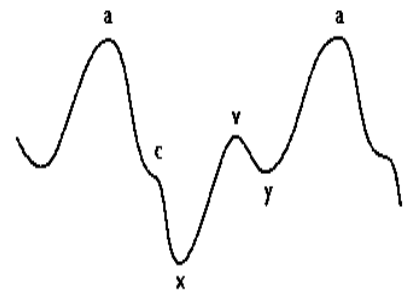
- After Make Sure That This Pulsation Arise From Jugular Vein , Measure The Vertical Distance From The Top Of The Pulsation To The Sternal Angle :
  - ✓ Right Atrium Lies 5 Cm Below The Sternal Angle, Which Is Used As The Reference Point .
  - ✓ Normal JVP Is Up To 3 Cm Above Sternal Angle .
  - ✓  $CVP = JVP \text{ (Above Sternal Angle)} + 5 \text{ Cm (That Are Not Measured Below Sternal Angle)}$  .

#### B- JVP Waves :

- ✓ **a - Wave :** Caused By Atrial Contraction , Seen Just Before The Carotid Pulse .
- ✓ **c - Point :** Due To Transmitted Carotid Pulsation .
- ✓ **x - Descent :** Atrial Relaxation .
- ✓ **v - Wave :** Tricuspid Closure And Atrial Filling , It Coincide With Carotid Pulse .
- ✓ **y - Descent :** Ventricular Filling As Tricuspid Valve Opens .

#### C- JVP Waves Abnormalities :

- **Dominant ( a - Wave ) :**
  - ✓ Tricuspid Stenosis , Pulmonary Stenosis , Pulmonary Hypertension .
- **Absent ( a - Wave ) :**
  - ✓ Atrial Fibrillation .
- **Giant ( a - Wave ) :**
  - ✓ Tricuspid Stenosis , Pulmonary Stenosis , Pulmonary Hypertension .
- **Cannon ( a - Wave ) :**
  - ✓ Complete Heart Block ( Atrial Ventricular Dissociation ) .
- **Dominant ( v - Wave ) :**
  - ✓ Tricuspid Regurgitation .
- **Absent ( x - Wave ) :**
  - ✓ Atrial Fibrillation .
- **Exaggerated ( x - Wave ) :**
  - ✓ Acute Cardiac Tamponade , Constrictive Pericarditis .
- **Sharp ( y - Wave ) :**
  - ✓ Severe Tricuspid Regurgitation , Constrictive Pericarditis .
- **Slow ( y - Wave ) :**
  - ✓ Tricuspid Stenosis .



## # NOTES :

# **Kassmul's Sign** : Elevation Of JVP During Inspiration ( Normally Decrease ) .

### # Causes Of Congested + Wavy JVP :

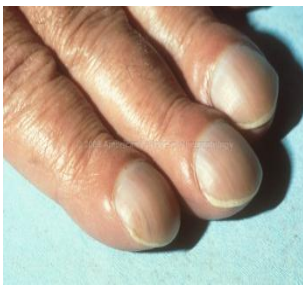- Increase Right Atrial Pressure ( Rt Sided HF , ... ) .
- Increase Intra-Thoracic Pressure ( Pneumothorax , ... ) .
- Increase Intra-Abdominal Pressure ( Tense Ascites , ... ) .
- Increase Blood Volume ( Anemia , Pregnancy , ... ) .

### # Causes Of Congested + Non-Wavy JVP :

- Severe Right Side HF .
- Complete SVC Obstruction..
- Pericardial Effusion And Constrictive Pericarditis .

### - Lower Limbs :

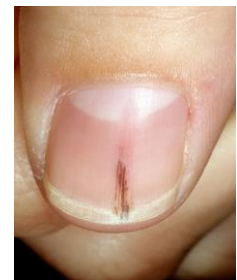- Skin Changes , Muscle Wasting , Loss Of Hair .
- Edema : Pitting / Non-Pitting - Unilateral / Bilateral - Level . ( Pic.15 )
- Pulse : Femoral - Popliteal - Dorsalis Pedis - Posterior Tibial .



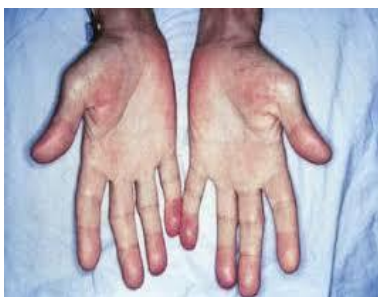Pic.1



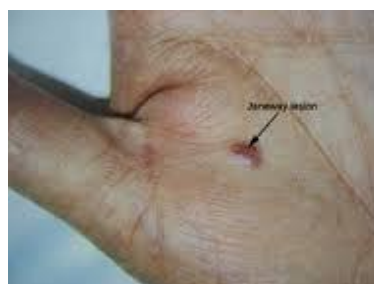Pic.2



Pic.3



Pic.4

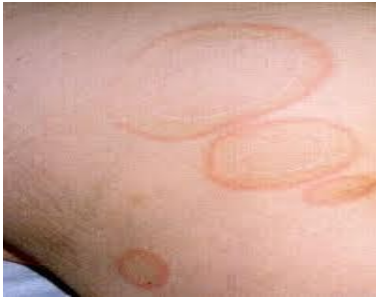

Pic.5  
۲۷

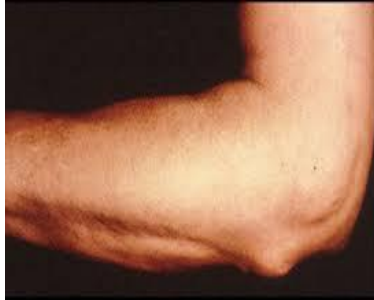

Pic.6

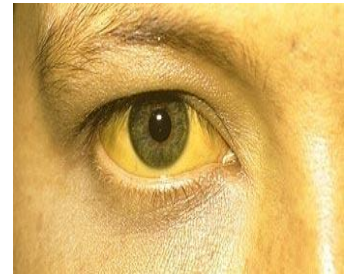



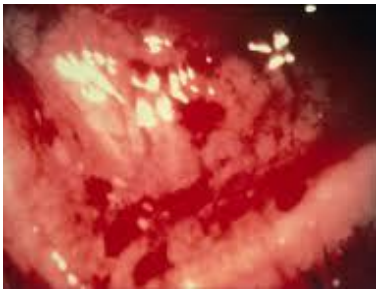
**Pic.7**



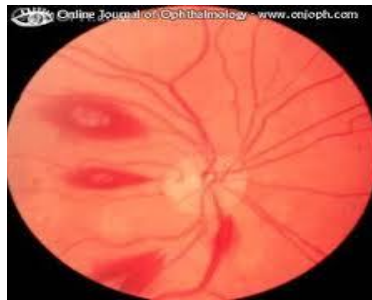**Pic.8**



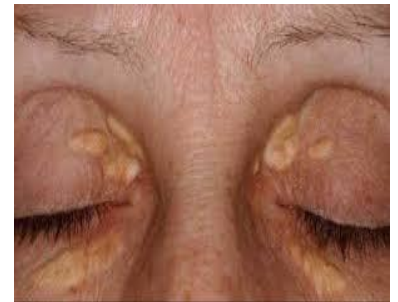**Pic.9**



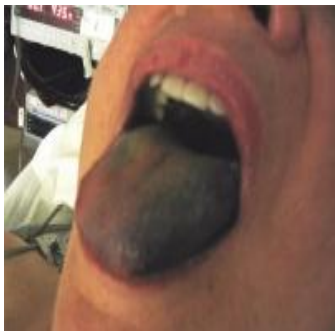**Pic.10**



**Pic.11**



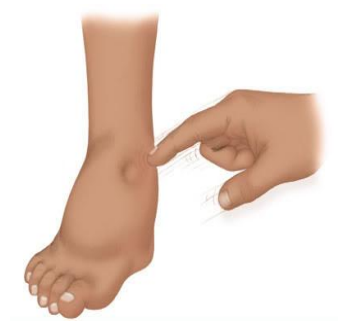**Pic.12**



**Pic.13**



**Pic.14**



**Pic.15**

## **2- Local Examination :**

- Introduce Yourself .
- Take Permission .
- Explain What You Are Going To Do .
- Maintain Privacy .
- Wash Your Hand .
- Exposure ( Full Exposure Of Trunk ) , Position ( Semi-Sitting Position 45° ) .

## Precordial Examination :

### Inspection

- Asymmetry .
- Any Bulge : Pacemaker , Pericardial Effusion , Atrial Or Ventricular Enlargement .
- Deformity : Kyphosis , Scoliosis , Pectus Excavatum , Pectus Carinatum .
- Previous Scars : Median Sternotomy , Lateral Thoracotomy .
- Dilated Veins .
- Any Visible Pulsation : Determine The Site .

### # NOTES :

- **Epigastric Pulsation** : Right Ventricle , Aorta Or Liver ( Differentiated By Palpation ) .
- **Lt Parasternal Pulsation** : Huge Lt Atrium Or Right Ventricle Enlargement .
- **Rt Parasternal Pulsation** : Huge Lt Atrium , Rt Atrium Enlargement Or Aortic Aneurysm .
- **Aortic Area Pulsation ( 2<sup>nd</sup> Right ICS )** : Aortic Aneurysm , Systemic Hypertension .
- **Pulmonary Area Pulsation ( 2<sup>nd</sup> Left ICS )** : Pulmonary Hypertension .
- **Suprasternal / Carotid Pulsation** : Aortic Regurgitation ( Corrigan's Sign ) .

### Palpation

" Don't Forget To Warm Your Hand "

#### 1- Apex Beat . ( Pic.1 )

- **Definition** : Lower Most And Outer Most Visible And Palpable Pulsation Over The Chest .
- **Normal Site** : 5<sup>th</sup> Left ICS , 1 Cm Medial To Mid-Clavicular Line .
- **Normal Size** : Less Than 2 Intercostal Space And Localized .
- **Normal Character** : Gentle Tap .
- **Technique** :
  - Place The Flat Of Your Right Hand On The Chest Wall And Search For Any Pulsation ( If There Is No Apex Beat Felt , Ask Patient To Lies On The Left Side ) .
  - Once You Feel The Pulsation Try To Localized The Point Of Maximum Impulse By The Tip Of Your Finger .
  - Use Your Other Hand To Count The Ribs To Determine Site Of Apex Beat .

## # NOTES :

### # Abnormal Position Of The Apex Beat :

- **Outward Displacement** : Right Ventricular Enlargement .
- **Outward And Downward Displacement** : Left Ventricular Enlargement .
- **Right Side Apical Beat** : Congenital Dextrocardia .

### # Abnormal Size Of The Apex :

- **Diffused Apex** : Usually With Left Ventricular Dilatation .

### # No Apex Beat Felt :

- Could Be Due To : Obesity , Emphysema , Pneumothorax , Pleural Effusion , Pericardial Effusion , Constrictive Pericarditis Or Dextrocardia ( So , If No Beat Is Felt , Check The Right Side ) .

### # Abnormal Character Of The Apex Beat :

- **Tapping Apex ( Palpable 1st Heart Sound )** : Mitral Stenosis .
- **Volume Overload ( Vigorous Or Thrusting Apex )** : Apex Beat Is Displaced , Diffuse , Non Sustained Impulse , Occurs Commonly With Aortic Regurgitation And Dilated Cardiomyopathy .
- **Pressure Load ( Heaving Or Sustained )** : Apex Beat Is Forceful And Sustained , This Occurs With AS , Hypertrophic Cardiomyopathy , Left Ventricular Hypertrophy .
- **Double Pulsation ( Palpable S4 )** : Hypertrophic Cardiomyopathy .
- **Sustained Left Parasternal Heave** : Left Atrial Enlargement , Right Ventricular Hypertrophy .

### 2- Parasternal Heave : ( Pic.2 )

- Rest The Heel Of The Hand Just To The Left Of The Sternum With The Fingers Lifted Slightly Off The Chest ( Also You Can Use Ulnar Border Of Right Hand ) .
- Normally No Impulses Or A Slight Inward Impulse Is Felt , But In Severe Left Atrial Enlargement Or Right Ventricular Enlargement , The Heel Of Hand Is Lifted Off The Chest With Each Systole .

### 3- Any Thrills ( Palpable Murmurs ) :

- **Apical thrill** : aortic stenosis ( systolic ) .
- **Left Parasternal thrill** : ventricular septal defect ( systolic ) .
- **Thrill in pulmonary area** : pulmonary stenosis ( systolic ) .
- **Thrill in aortic area** : aortic stenosis ( systolic and propagated to neck ) .
- **Thrill of Left infra-Clavicular area** : PDA ( continuous ) .
- **Neck ( carotid ) thrill** : propagated from heart base ( AS ) , Initiated in the carotid itself ( AR ) .

# Auscultation

## # Component Of Auscultation :

- Heart Sound .
- Murmurs .
- Additional Sounds .

### 1- Heart Sounds :

#### A- 1<sup>st</sup> Heart Sound (S<sub>1</sub>):

- Due To Closure Of Mitral And Tricuspid Valves ( Indicate Beginning Of Ventricular Systole ) .
- Heard At :
  - ✓ Mitral Area : 5<sup>th</sup> Left ICS , Mid-Axillary Line ( By Bell Of Stethoscope ) .
  - ✓ Tricuspid Area : 4<sup>th</sup> ICS , Parasternal ( By Diaphragm Of Stethoscope ) .

#### B- 2<sup>nd</sup> Heart Sound (S<sub>2</sub>):

- Due To Closure Of Pulmonary And Aortic Valves .
- Heard At :
  - ✓ Pulmonary Area : 2<sup>nd</sup> Left ICS .
  - ✓ Aortic Area : 2<sup>nd</sup> Right ICS .

#### C- 3<sup>rd</sup> Heart Sound (S<sub>3</sub>):

- This Is A Low-Pitch Mid-Diastolic Sound Occurring After S<sub>2</sub> . ( Can Just Be Heard With The Bell ) .
- It Occurs Due To Shortening Of The Papillary Muscles At The End Of Rapid Ventricular Filling .
- **Physiological** : Soft Sound Heard Only At The Apex, Normal In Patientren And Fit Adults Up To Age 30 .
- **Pathological** : Indicates Reduce Ventricular Compliance As In Ventricular Failure And Dilatation .

#### D- 4<sup>th</sup> Heart Sound (S<sub>4</sub>):

- This Is A Late Diastolic Sound ( Just Before S<sub>1</sub> ) .
- Caused By Atrial Contraction Against A Stiff Ventricle .
- Indicate Diastolic Dysfunction.
- Never Physiological .
- Causes Are Hypertrophic Cardiomyopathy , Aortic Stenosis, Pulmonary HTN , Pulmonary Stenosis .
- Don't Occur If The Patient Is In Atrial Fibrillation .

# **NOTE** : If Heart Rate More Than 120 Beat/Min , S<sub>3</sub> And S<sub>4</sub> May Be Superimposed Resulting In **Summation Gallop** ( Two Audible Sounds Combine To Produce Audible One ) .

## 2- Murmurs :

- Comment On ( Timing , Site Of Maximum Intensity , Radiation , Grade , Relation To Position ) .

### A- Timing :

- You Must Decide Whether The Noise Occurs In Systole Or Diastole ( Compare To Carotid Artery To Be Sure ) .

### # Systolic Murmurs :

#### - **Ejection Systolic :**

- ✓ Start Quietly At The Beginning Of Systole , Quickly Rise To A Crescendo And Then Decrescendo .
- ✓ Caused By : Pulmonary Stenosis , Aortic Stenosis , Hypertrophic Cardiomyopathy .

#### - **Pansystolic :**

- ✓ Lasts For The Whole Of Systole And Tends To Be Due To Backflow Of Blood From A Ventricle To An Atrium .
- ✓ Caused By : Tricuspid Regurgitation , Mitral Regurgitation , VSD .

#### - **Late Systolic :**

- ✓ There Is An Audible Gap Between  $S_1$  And The Start Of The Murmur , Which Then Continues Until  $S_2$  .
- ✓ Typically This Is Due To Tricuspid Or Mitral Regurgitation Through A Prolapsing Valve .

### # Diastolic Murmurs :

#### - **Early Diastolic :**

- ✓ It Starts Loudly At  $S_2$  And Decrescendos During Diastole .
- ✓ Usually Due To Aortic Or Pulmonary Regurgitation .

#### - **Mid-Diastolic :**

- ✓ Begin Later In Diastole And May Be Brief Or Continue Up To  $S_1$  .
- ✓ Usually Due To Mitral Or Tricuspid Stenosis .

### # Continuous Murmurs :

- Heard Throughout Both Systole And Diastole .
- Common Causes : PDA , A-V Fistula .

### B- Site Of Maximum Intensity :

- The Site That You Can Hear The Murmur Louder .
- Aortic Regurgitation Is Heard Louder If You Ask The Patient To Sit Up And Lean Forward , Then Listen At The Left Sternal Border .
- Mitral Stenosis Is Louder If You Ask The Patient To Lie On Their Left Side , Then Listen With The Bell At The Apex .

**C- Radiation :**

- Murmur Of Aortic Stenosis Will Radiate To The Carotids .
- Murmur Of Mitral Regurgitation May Be Heard In The Left Axilla .

**D- Grade :**

- Grading The Murmurs According To Loudness Into Six Grades ( Levine's Grading System ) :
  - **Grade 1/6** : Very Soft And Not Heard At First .
  - **Grade 2/6** : Soft But Can Be Detected Almost Immediately By Experiences Auscultator .
  - **Grade 3/6** : Moderate , There Is No Thrill .
  - **Grade 4/6** : Loud , Thrill Just Palpable .
  - **Grade 5/6** : Very Loud , Thrill Easily Palpable .
  - **Grade 6/6** : Very Very Loud , Can Be Heard Even Without Stethoscope .

**E- Relation To Position :**

- **Respiration :**

- ✓ Right-Sided Murmurs Tend To Be Louder During Inspiration And Left-Sided Murmurs Are Louder During Expiration .

- **Valsalva Manoeuver :**

- ✓ Forceful Expiration Against A Closed Glottis .
- ✓ Murmurs Of Hypertrophic Obstructive Cardiomyopathy , Mitral Regurgitation , And Mitral Prolapse Will Get Louder On Release Of Valsalva .

**F- Hand Grip :**

- ✓ Murmur Mitral Regurgitation Will Get Louder .

**G- Squatting :**

- ✓ Murmurs Of Aortic Stenosis And Mitral Regurgitation Will Get Louder .

**H- Sit Upright , Lean Forward , Exhale , And Hold Their Breath :**

- ✓ Aortic Regurgitation And Pericardial Friction Rub Will Get Louder .

### 3- Additional Sounds :

#### A- Opening Snap :

- Sudden Opening Of The Stiffened Valve Can Cause An Audible High-Pitched Snap In Early Diastole .
- Present In Mitral Or Tricuspid Stenosis .
- Best Heard Over The Left Lower Sternal Border With The Diaphragm Of The Stethoscope .

#### B- Systolic Ejection Click :

- High-Pitched Click Heard Early In Systole , Caused By The Opening Of A Stiffened Semilunar Valve .
- Present In Aortic Stenosis , And Associated With Bicuspid Aortic Valves .
- Heard At The Aortic Or Pulmonary Areas And Down The Left Sternal Border .

#### C- Pericardial Friction Rub :

- Scratching Sound Has Three Components Occurring At Any Time During Cardiac Cycle , Heard With Each Heartbeat And Caused By Inflamed Pericardial Membranes .
- It Is Louder As The Patient Is Sitting Up , Leaning Forward , And Heard Best In Expiration .

### At The End Of Cardiovascular Examination , You Must Check :

#### - Abdomen :

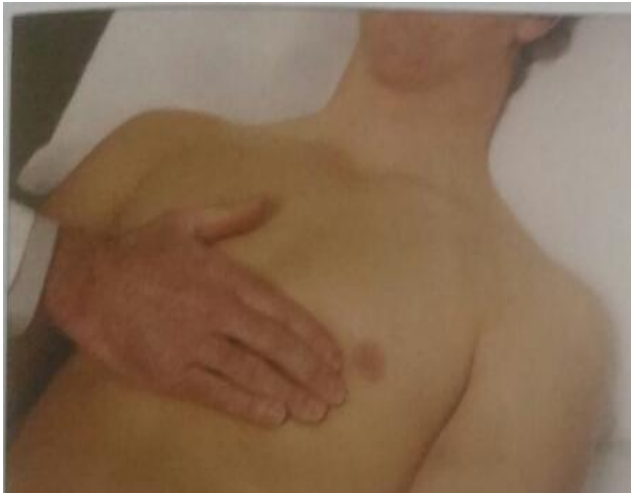- ✓ Palpate The Liver & Spleen ( If It Enlarge Or Not ) .

#### - Lungs :

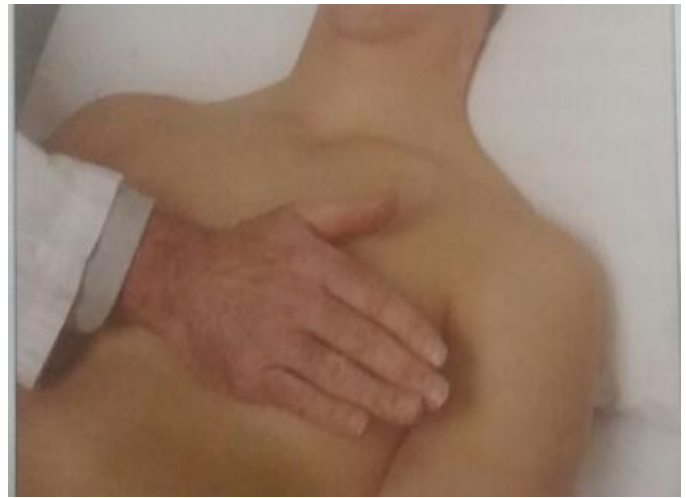- ✓ Auscultate Bases Of Lungs For Crepitations .

#### - Lower Limbs :

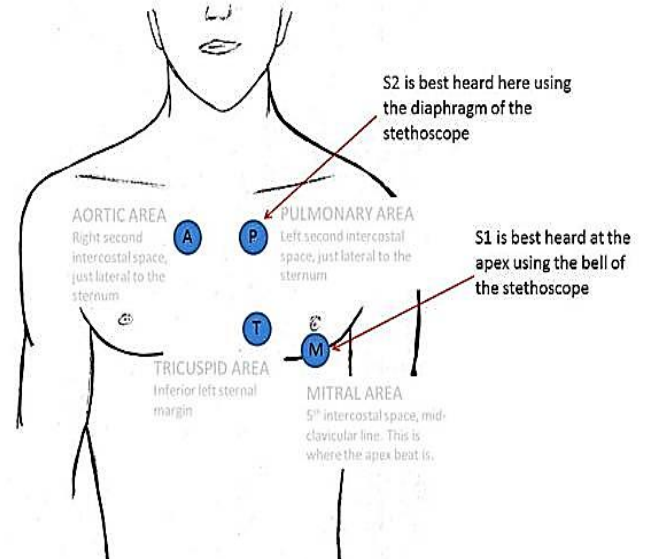
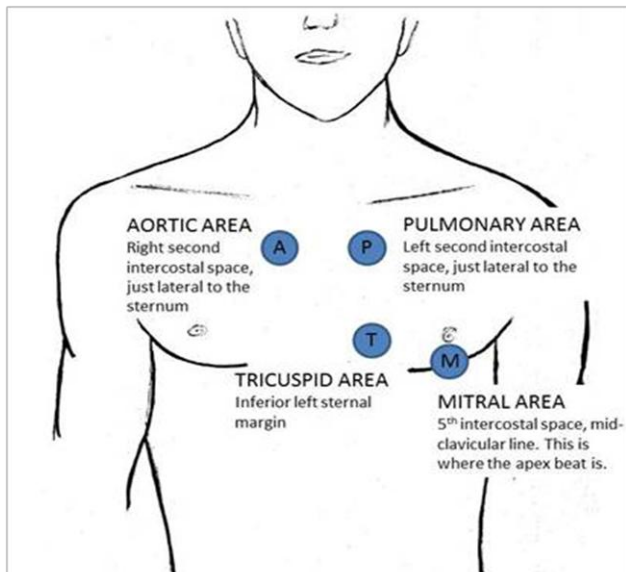
- ✓ Edema , Cyanosis , Clubbing .



Pic.1

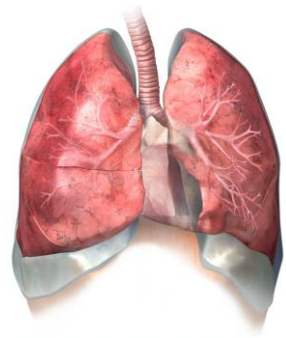


Pic.2





# Pulmonogy



This image was created using the Zygote Female Respiratory System and Heart

# History Of Common Cases

## 1) Pneumonia :

### - Personal History:

Ahmed Mohammed Ali , 34 Y/O Saudi Male From Jazan , Policeman , Married For 10 Years And Has 3 Offsprings .  
Admitted Through ER On 12-1-1436 H .

### - C/O:

Cough / 4 Days .

Fever / 2 Days .

### - HPI:

The Patient Was Will Till 4 Days Back When He Started To Has Cough , Which Was Acute In Onset , Progressive In Course , 4 Days Duration , With Little In Amount Of Foamy , Purulent Sputum , 1 Cup Amount , With No Bad Smell . The Fever Was Acute In Onset , 2 Days Duration , Intermittent , Not Measured . Not Associated With Chest Pain , Palpitation , Cough , Cyanosis, Dyspnea Or Wheeze .

● Systemic Review : -Ve .

● Hospital Course : Underwent CBC , Chest X-Ray , Oxygen , IV Fluids & Antibiotic And The Patient Is Improving .

- Past History: -Ve .

- Family History:

-Ve Apart From +Ve Consanguinity , +Ve Hx Of HTN And DM In His Father .

- Social History:

Good Living Conditions & Socio-Economic Status .

No Special Habits Of Medical Importance .

- Drugs & Allergies: -Ve .

### +Ve Findings In Examination:

- General Examination: Looking Ill , Feverish .

- Local ( Respiratory ) Examination:

✓ **Inspection:** The Right Side Moving Less Than Left .

✓ **Palpation:** The Chest Expansion Less Than Normal .

✓ **Percussion:** Dullness On Right Side .

✓ **Auscultation:** Bronchial Breathing On Right Side , And Decrease Breathing Sound On Right Side .

### Summary

34 Y/O Saudi Male Admitted Through ER Complaining Of Productive Cough / 4 Days , Associated Intermittent Fever , No Chest Pain , Wheeze , Cyanosis Or Palpitation .

## 2) Tuberculosis ( TB ) :

### - Personal History :

Ahmed Mohammed Ali , 34 Y/O Saudi Male From Jazan , Policeman , Married For 10 Years And Has 3 Offsprings .  
Admitted Through ER On 12-1-1436 H .

### - C/O :

Cough / 2 Months .

### - HPI :

Patient's Condition Started About 2 Months Prior To Consultation , Non Productive Cough , Associated With Night Sweats And Intermittent Fever Usually In The Afternoon , Moderate Grade , Relieved By Taking Of Paracetamol . Two Days Prior To Admission The Patient Experienced Worsening Of The Condition , He Had Productive Cough Non-Bloody With Whitish Secretions . There Is Also Difficulty Of Breathing And Vomiting . The Patient Can't Eat Properly Because She Has No Appetite For Food . He Also Experience Stabbing Pain On His Chest Radiates To His Back . The Patient Only Took Paracetamol For His Fever . The Condition Associated With Loss Of Weight . There Is No Palpitation , No Cyanosis , No Wheeze .

● Systemic Review : -Ve .

● Hospital Course : Underwent CBC , Chest X-Ray , Oxygen , IV Fluids , Sputum Culture And The Patient Is Improving .

- Past History : -Ve .

- Family History : -Ve Apart From +Ve Consanguinity .

- Social History :

Good Living Conditions & Socio-Economic Status .

No Special Habits Of Medical Importance .

- Drugs & Allergies : -Ve .

### Summary

34 Y/O Saudi Male Admitted Through ER Complaining Of Productive Cough / 2 Months Non-Bloody, Which Associated With Moderate Fever , Weight Loss , Chest Pain And Difficulty In Breathing .

### +Ve Findings In Examination :

- General Examination : Looking Ill , Feverish , Underweight .

- Local ( Respiratory ) Examination :

- ✓ **Inspection :** The Right Side Moving Less Than Left .
- ✓ **Palpation :** The Chest Expansion Less Than Normal .
- ✓ **Percussion :** Dullness On Right Side , Increase TVF .
- ✓ **Auscultation :** Crepitations .

### 3) Bronchial Asthma ( TB ) :

- **Personal History :**

Ahmed Mohammed Ali , 22 Y/O Saudi Male From Jazan , Policeman , Single , Admitted Through ER On 12-1-1436 H .

- **C/O :**

SOB / 2 Hours .

- **HPI :**

The Patient Is Known Cases Of BA .

The Patient Was On Usual Status Till 2 Hours Back When He Started To Has Sob Which Was Acute In Onset , Progressive In Course , 2 Hours Duration , Aggravated By Running And Relieved By Setting And Rest , Associated With Chest Tightness , Wheeze And Non Productive Cough As Same As Dyspnea Started . No Fever , No Palpitation , No Cyanosis .

● Systemic Review : -Ve .

● Hospital Course : Underwent CBC , Chest X-Ray , Oxygen , IV Fluids , Sputum Culture And The Patient Is Improving .

- **Past History :**

BA Diagnosed At KFCH , Controlled .

Hx Of Multiple Previous Attacks With Admissions , Last One Was Month Ago .

- **Family History :** -Ve Apart From +Ve Consanguinity & +Ve Similar Condition In His Sister .

- **Social History :**

Good Living Conditions & Socio-Economic Status .

No Special Habits Of Medical Importance .

- **Drugs & Allergies :**

On Salbutamol & Steroids Inhaler .

**N.B : Precipitation Factors Of BA :**

- Infection .
- Exercise .
- Specific Allergen .

**Summary**

22 Y/O Saudi Male , Known Case Of BA , Admitted Through ER Complaining Of SOB / 2 Hours , Which Associated With Chest Tightness And Non-Productive Cough .

**+Ve Findings In Examination :**

- **General Examination :** Looking Ill , With Signs Of Respiratory Distress .

- **Local ( Respiratory ) Examination :**

- ✓ **Inspection :** Free .
- ✓ **Palpation :** Free .
- ✓ **Percussion :** Resonant .
- ✓ **Auscultation :** Expiratory Wheeze .

# Respiratory Examination

## 1- General Examination :

### - ABCDE:

- ✓ **Appearance** : Looks Well/Ill , Consciousness , Alert , Orientation To Time - Place - Person .
- ✓ **Body Built** : Average , Thin , Obese ( Depends On BMI ) .
- ✓ **Color** : Pale , Cyanosed , Erythematous .
- ✓ **Decubitus** : Patient's Sitting & Position .
- ✓ **Deformities** : Any Congenital Abnormality ( If You Find One Anomaly Search For Others )
- ✓ **Distress** : Difficulty In Breathing ( Dyspnic ) .
- ✓ **Environment** : Any Connections To Patient ( IV Line , Catheter , O<sub>2</sub> Mask , ECG , Wheelchair , ...Etc. "

### \*\* Notes:

#### # Signs Of Respiratory Distress :

- Tachypnea .
- Tachycardia .
- Flaring Of Ala Nasi .
- Cyanosis .
- Using Of Accessory Muscles , Intercostal , Subcostal , Suprasternal Recession .
- Grunting .

#### # Some Definitions :

- **Dyspnea** : Difficult In Breathing .
- **Orthopnea** : Difficult In Breathing While Lying Down .
- **Paroxysmal Nocturnal Dyspnea** : Dyspnea That Awake The Patient After 2 Hours Of Sleeping .

### - Vital Signs :

- ✓ **Temperature ( Temp )** : Normally (  $37.2 \pm 0.4$  °C ) .
- ✓ **Pulse** : Normally ( 60-100 Beat/Min ) .
- ✓ **Blood Pressure ( BP )** : Normally ( 120-139/80-90 mmHg ) .
- ✓ **Respiratory Rate ( RR )** : Normally ( 12-16 Breaths/Min ) .
- ✓ **O<sub>2</sub> Saturation** : Normally ( > 98% ) .

- **Hands :** ( Compare Both Hands Together )

✓ **Nails :**

- Clubbing .
- Capillary Refill .
- Peripheral Cyanosis .
- Koilonychia .
- Leukonychia .

✓ **Palm :**

- Muscle Wasting .
- Palmar Erythema .
- Pallor Which Seen In Palmar Creases .

✓ **Arm :**

- Bruises , Scratch Marks , Ulcers , Scars , Pigmentation .
- Muscle Wasting .
- Spider Nevi ( In Face - Neck - Upper Chest Also ) .

- **Head & Neck :**

✓ **Eye :**

- Jaundice : Look At Upper Bulbar Conjunctiva While Patient Is Looking Downward .
- Pallor : Look At Lower Palpebral Conjunctiva While Patient Is Looking Upward .

✓ **Mouth:**

- Cyanosis : Lips For Peripheral Cyanosis & Tongue For Central Cyanosis .
- Jaundice : In Mucous Membranes .
- Aphthous Ulcer & Candida , Glossitis , Mouth Hygiene , Odour Of Breath .

✓ **Neck :**

- Lymph Nodes .
- Jugular Vein .
- Carotid Artery .

- **Lower Limbs :**

- Skin Changes , Muscle Wasting , Loss Of Hair .
- Edema : Pitting / Non-Pitting - Unilateral / Bilateral - Level .
- Pulse : Femoral - Popliteal - Dorsalis Pedis - Posterior Tibial .

**Grades Of Clubbing :**

- **1** > Fluctuation Of The Nail Bed .
- **2** > Obliteration Of The Lovibond Angle .
- **3** > Parrot Beak Appearance Or Drum Stick Appearance .
- **4** > Hypertrophic Osteo-Arthropathy ( HOPA ) .

## 2- Local Examination :

- Introduce Yourself .
- Take Permission .
- Explain What You Are Going To Do .
- Maintain Privacy .
- Wash Your Hand .
- Exposure ( Full Exposure Of Trunk ) , Position ( Sitting OR Semi-Sitting Position 45° ) .

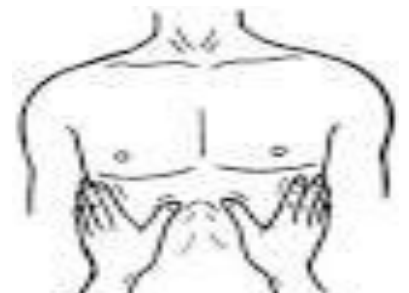### " From Front "

#### Inspection

- **Shape & Symmetry : ( Normally )**
  - ✓ **Normally** : Elliptical And Symmetrical Shape , AP Diameter Little Shorter Than Or Nearly Equal Transverse Diameter , Ribs Are Oblique And Subcostal Angle = 90° .
  - ✓ **Symmetrical Deformities** : Barrel Chest , Pigeon Chest , Funnel Chest , Flat Chest .
  - ✓ **Asymmetrical Deformities** : Unilateral Retraction , Unilateral Bulge .
- **Type Of Breathing :**
  - ✓ **Abdomino-Thoracic** : Males , Changing Indicates Phrenic Nerve Injury , Abdominal Distention Or Peritonitis .
  - ✓ **Thoraco-Abdominal** : Females , Changing Indicates Intercostal Paralysis , Or Chest Pain .
- **Action Of Accessory Muscles :**
  - ✓ Indicate Presence Of Respiratory Distress , May Due To Asthma , Tracheal Obstruction , Emphysema , ...
- **Apex Beat & Other Pulsation . ( See Cardiology )**
- **Any Scars , Dilated Veins , Spider Nevi .**
- **Chest Deformity :**
  - ✓ Pectus Carinatum , Pectus Excavatum .

# Palpation

- **For Any Tenderness .**
- **Confirm The Position Of Apex Beat & Other Pulsations .**
- **Position Of Trachea :**
  - ✓ **Normally :** Centralized .
  - ✓ **May Be Pulled :** Due To Lung Collapse Or Fibrosis .
  - ✓ **May Be Pushed :** Due To Pleural Effusion , Pneumothorax , Or Tumor .
  - ✓ **Technique :** Seen In Suprasternal Notch By Put Your Index And Ring Fingers On Sterno-Clavicular Junction , While Your Middle Finger On Trachea .
- **Subcostal Angle :**
  - ✓ **Normally :** Acute OR Right .
  - ✓ **Abnormally :** Obtuse .
- **Chest Expansion ( Confirm Respiratory Movement ) :**
  - During A Deep Inspiration Compare Displacement By Palms Of Both Hands In Following Areas : ( Pic.1 )
    - ✓ **Upper Chest ( Infra-Clavicular Area ) :** Observe The Equal Movement Of Your Hand Up And Down .
    - ✓ **Middle Zone ( Below The Nipple ) :** See Your Thumbs Moving Apart .
    - ✓ **Lower Chest ( Above Costal Margin ) :** Same As Middle Zone .



**Pic.1**

- **Tactile Vocal Fremitus ( TVF ) :**
  - Palpable The Vibration Of Vocal Cord Transmitted Through Respiratory Passage To Chest Wall .
  - **Technique :**
    - ✓ It Is Done By Applying Hand On Chest Wall And Ask Patient To Repeat 99 In English Or 44 In Arabic .
  - Compare Between RT & LT By Palm Of The Hand .
  - **May Be Increased :** Like In Consolidation .
  - **May Be Decreased :** Like In Pleural Effusion , Emphysema .



# Percussion

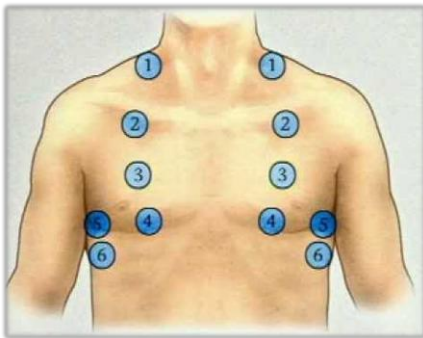
## - Technique ( Pic.1 ) : " Light Percussion "

- ✓ Direct Percussion On The Clavicle .
- ✓ Separate Your Fingers From Each Other And Press The Middle Finger In The ICS .
- ✓ Percuss By The Middle Finger Over The Middle Finger Of Other Hand . ( Pic.2 )
- ✓ Comparative Percussion ( Right & Left ) .
- ✓ Start From Supraclavicular Area Then Downwards , With Axillae .

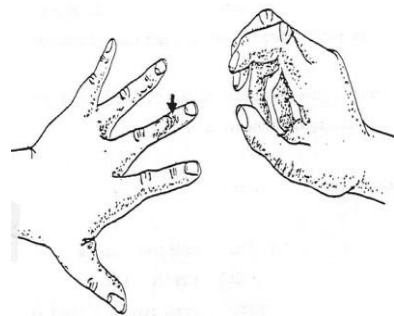
## # Findings :

- **Resonant** : Normal .
- **Hyper-Resonant** : Pneumothorax , Emphysema .
- **Dullness** : Consolidation , Pleural Effusion .

Pic.1



Pic.2



## - Percussion Of Special Areas ( Pic.3 ) :

### A- Bare Area Of The Heart :

- **Definition** : Area Of Heart Not Covered By Lung Tissue .
- **Site** : 4<sup>th</sup> & 5<sup>th</sup> Space Between Mid-Clavicular Line And Parasternal Line .
- **Normally** : Dull By Light Percussion , If Resonant : Emphysema , Pneumothorax .

### B- Hepatic Dullness :

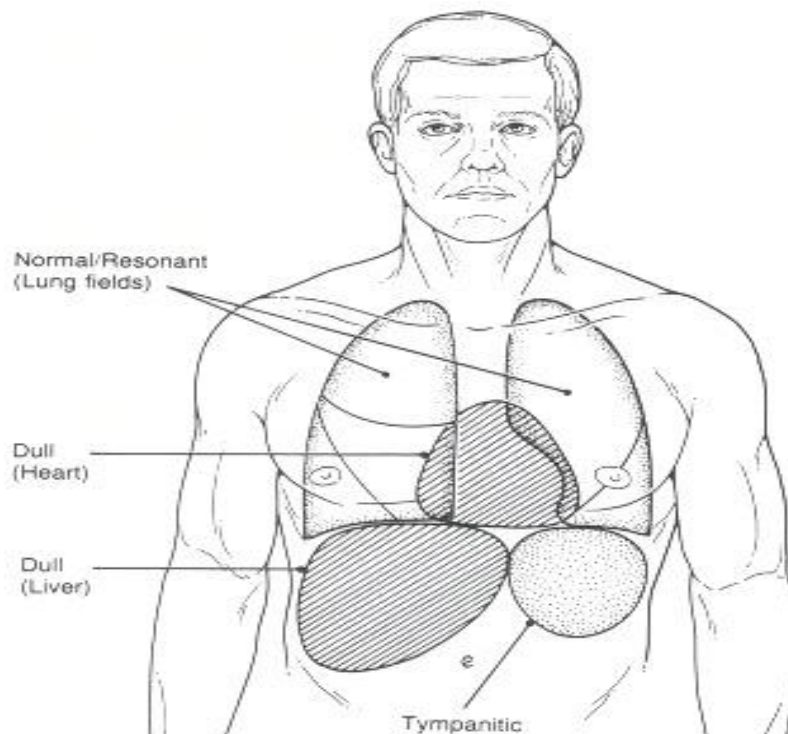
- **Normally** : Upper Border In 5<sup>th</sup> Right ICS Mid-Clavicular Line , If Lower Than That You Have To Suspect Emphysema .

### C- Splenic Dullness :

- Underlies 9<sup>th</sup> , 10<sup>th</sup> , 11<sup>th</sup> Ribs Between Mid Axillary And Scapular Line .

### D- Traub's Area :

- Definition : An Area Of Tympanic Resonance Overlying Air Bubbles In Fundus Of Stomach .
- Site : Area Between Lt 5<sup>th</sup> ICS To 8<sup>th</sup> Costal Cartilage Mid-Clavicular Line & Lt 9<sup>th</sup> ICS To 11<sup>th</sup> ICS Mid-Axillary Line .
- Causes Of Dullness Of This Area :
  - ✓ **From Above :** Lt Basal Lung Disease, Lt Pleural Effusion , Pericardial Effusion .
  - ✓ **From Below :** Elevated Diaphragm Due To Ascites , Tumor , Pregnancy .
  - ✓ **From Right :** Enlarged Left Hepatic Lobe .
  - ✓ **From Left :** Splenomegaly .
  - ✓ **Stomach Fullness .**



**Pic.3**

- **Special Test :**

### # Tidal Percussion :

- Differentiate Between Supra & Infra-Diaphragmatic Dullness

#### **Technique :**

While Percussion For Hepatic Dullness, After Getting The 1<sup>st</sup> Dull Space ,Ask Patient Take Deep Inspiration & Percuss Again :

- ✓ **If Dullness Persist :** Supra-Diaphragmatic .
- ✓ **If Dullness Change To Resonance :** Infra-Diaphragmatic .

## Auscultation

### # Auscultate For :

- Breath Sounds .
- Added Sounds .
- Vocal Resonance .

### # Technique :

- Auscultate The Supra-Clavicular Area By The Bell Of Stethoscope .
- Auscultate The Same Areas Of Percussion By The Diaphragm Of Stethoscope .
- Comment On The Air Entry ( Equal , Reduced ) .
- Comment On The Type Of Breathing ( Vesicular , Bronchial ) .
- Comment On Added Sounds ( Wheeze , Crackles ) & If It Is Inspiratory OR Expiratory .
- Comment On Vocal Resonance .

### A- Breath Sound :

#### ● Vesicular Breathing ( Alveolar Breathing ) :

##### - **Character :**

- ✓ Flow Of Air In & Out The Normal Lung Alveoli .
- ✓ Vesicular .
- ✓ Inspiration Is Longer Than Expiration .
- ✓ No Gap Between Inspiration & Expiration .
- ✓ Heard All Over The Chest .

- **Bronchial Breathing :**

- **Character :**

- ✓ The Expiratory Sounds Are Longer Than The Inspiratory Sounds .
- ✓ Gap In Between Inspiratory And Expiratory .
- ✓ Bronchial Breathing Is Normally Heard Over Trachea & Main Bronchi ( In The 2<sup>nd</sup> ICS ) .
- ✓ Abnormally Heard Over Consolidation , Collapse .

- B- **Added Sounds :**

- **Wheeze ( Rhonchi ) :**

- **Definition :** Dry Continuous Musical Sound .
- **Mechanism :** Passage Of Air In A Narrowed Bronchus .
- **Timing :** Relation To The Respiratory Cycle , Tend To Be Louder On Expiration Due To Spasm Or Edema .
- **Some Causes Of Wheeze :** Asthma , COPD , Foreign Body .

- **Creptitations ( Crackles ) :**

- **Definition :** Moist Interrupted Wet Sound ( Non-Musical Sound ) .
- **Mechanism :** Passage Of Air Through Fluid In Bronchi & Alveoli .
- **Timing :** Usually Occur In Inspiration .
- **Types :**
  - ✓ **Fine :** Due To Passage Of Air Through Small Amount Of Fluid In Alveoli Or Small Bronchioles , Can Be Due To Fibrosis , TB , Pneumonia .
  - ✓ **Coarse :** Due To Air Bubbling Through Big Amount Of Fluid In Alveoli Or Big Bronchi , Can Be Due To Acute Pulmonary , Edema , Bronchiectasis , Lung Abscess .

- **Pleural Friction Rub :**

- **Definition :** Localized Superficial Leathery Friction Sound .
- **Mechanism :** When Thickened ,Roughened Pleural Surfaces Rub Together .
- **Timing :** Occur During Both Inspiration & Expiration .
- **Some Causes :** Pleurisy , Malignant Involvement Of The Pleura .

C- Vocal Resonance :

- To Confirm Bronchial Breathing .
- Ask The Patient To Say "44" In Arabic Or "99" In English .
- The Sound Is Muffled Over A Normal Lung .
- The Voice Will Be Heard Clearly With Consolidation Or Fibrosis , And It Will Be Very Clear With COPD And Decreased Or Absent If There Is Effusion Or Collapse .

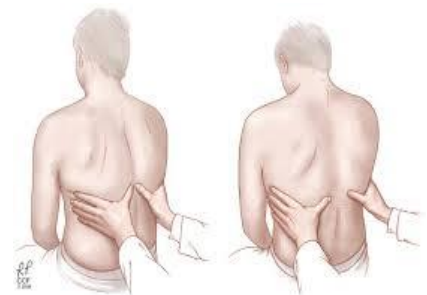**" From Back "**

**Inspection**

- **Shape & Symmetry** .
- **Scars , Skin Changes** .
- **Any Deformity** :
  - ✓ Scoliosis : Curve Chest , OR S-Shaped .
  - ✓ Kyphosis : K-Shaped , Seen From The Side .

**Palpation**

- **Chest Expansion** . ( Pic.1 )
- **Tactile Vocal Fremitus** .

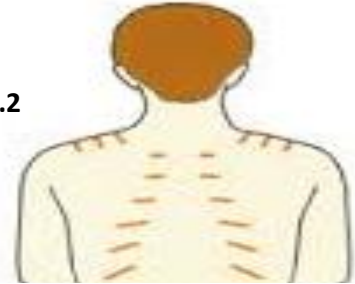

**Pic.1**

## Percussion

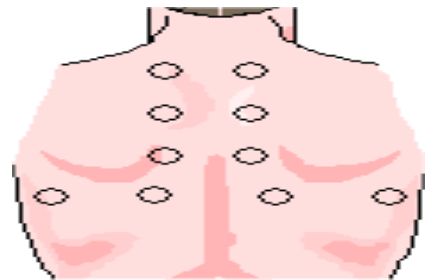
- Heavy Percussion .
- Scapular Line ( Paravertebral Line ) . ( Pic.2 )
- Start From Apex To 10<sup>th</sup> Space .

Pic.2



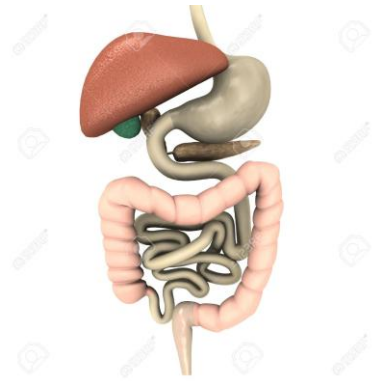## Auscultation

- At Supra , Infra-Scapular Area .
- At Paravertebral Area .
- Vocal Resonance .
- See ( Pic.3 )



Pic.3

**GIT**



# History Of Common Cases

## 1) Acute Hepatitis :

### - Personal History :

Ahmed Mohammed Ali , 28 Y/O Saudi Male From Jazan , Nurse , Single , Admitted Through ER On 12-1-1436 H .

### - C/O :

Right Upper Abdominal Pain / 2 Weeks .

### - HPI :

The Patient Was Will Till 2 Weeks Back When He Started To Has Right Upper Abdominal Pain , Dull-Aching , Progressive , Not Radiated , With No Aggravating Or Relieving Factors , It Is Associated With Nausea , Frequent Vomiting , And Yellowish Discoloration Of Eyes . There Is No Dysphagia , No Diarrhea , No Constipation , No Diarrhea , No Hematemesis , No Melena Or Change In Urine Or Stool . He Mentioned A History Of Contact With Blood During His Work And He Is Worried About That .

● Systemic Review : -Ve .

● Hospital Course : Underwent CBC , LFT , Hepatitis Markers , Abdominal U/S , Analgesics & And The Patient Is Improving .

### - Past History : -Ve .

- Family History : -Ve Apart From +Ve Consanguinity , +Ve Hx Of HTN And DM In His Father .

### - Social History :

Good Living Conditions & Socio-Economic Status .

No Special Habits Of Medical Importance .

### - Drugs & Allergies : -Ve .

### Summary

28 Y/O Saudi Male Admitted Through ER Complaining Of Rt Upper Abdominal Pain / 2 Weeks Which Was Progressive , Not Radiated , Associated With Nausea , Vomiting & Jaundice . There Is +Ve History Of Contact With Blood .

### +Ve Findings In Examination :

- General Examination : Looking Ill , With Mild Fever , Jaundice .

### - Local ( Abdominal ) Examination :

✓ **Inspection :** Free .

✓ **Palpation :** Rt Upper Quadrant Tenderness , Enlarged Liver .

✓ **Percussion :** Free .

✓ **Auscultation :** Free .



## 2) Peptic Ulcer :

### - Personal History:

Ahmed Mohammed Ali , 28 Y/O Saudi Male From Jazan , Teacher , Single , Admitted Through ER On 12-1-1436 H .

### - C/O:

Epigastric Abdominal Pain / 3 Days .

### - HPI:

The Patient Was Will Till 3 Days Back When He Started To Has Epigastric Abdominal Pain , Burning , Intermittent , Not Radiated , Occurs After 2 Hours From Eating , Aggravated By Spicy Food , Relieved By Analgesics . It Is Associated With Loss Of Appetite , Nausea , Vomiting , And Heartburn . There Is No Dysphagia , No Jaundice , No Diarrhea , No Constipation , No Diarrhea , No Hematemesis , No Melena .

● Systemic Review : -Ve .

● Hospital Course : Underwent CBC , Abdominal U/S , Upper GI Endoscopy , Analgesics & And The Patient Is Improving .

- Past History: -Ve .

- Family History: -Ve Apart From +Ve Consanguinity , +Ve Hx Of HTN And DM In His Father .

- Social History:

Good Living Conditions & Socio-Economic Status .

No Special Habits Of Medical Importance .

- Drugs & Allergies: -Ve .

### Summary

28 Y/O Saudi Male Admitted Through ER Complaining Of Epigastric Abdominal Pain / 3 Days Which Was Intermittent , Burning , Not Radiated , Occurs After 2 Hours From Eating , Aggravated By Spicy Food , Associated With Nausea , Vomiting & Heartburn .

### +Ve Findings In Examination:

### - Local ( Abdominal ) Examination:

- ✓ **Inspection:** Free .
- ✓ **Palpation:** Epigastric Tenderness .
- ✓ **Percussion:** Free .
- ✓ **Auscultation:** Free .

### 3) Chronic Liver Disease :

- **Personal History :**

Ahmed Mohammed Ali , 65 Y/O Saudi Male From Jazan , Retired , Married For 20 Years And Has 4 Offsprings , +Ve History Of Alcohol Abuse . Admitted Through ER On 12-1-1436 H .

- **C/O :**

Vomiting Of Blood / 1 Hour .

- **HPI :**

The Patient Is Known Case Of Liver Cirrhosis .

He Was On Usual Status Till 1 Hour Back When He Started To Has Vomiting Of Blood , Acute In Onset , Large Amount , Red In Color , Not Containing Food Particles . There Is Abdominal Distention , But No Dysphagia , No Jaundice , No Diarrhea , No Constipation , No Melena Or Bleeding Per Rectum .

● Systemic Review : -Ve .

● Hospital Course : Underwent CBC , Upper GI Endoscopy , Blood Transfusion & And The Patient Is Improving .

- **Past History :**

He Was Diagnosed As Liver Cirrhosis 2 Years Back , In KFCH , And Was Compensated .

+Ve Of Previous 2 Similar Attacks With Admissions , Last One Was 2 Months Back .

- **Family History :** -Ve Apart From +Ve Consanguinity , +Ve Hx Of Liver Cirrhosis In His Brother .

- **Social History :**

Good Living Conditions & Socio-Economic Status .

- **Drugs & Allergies :**

He Is On Low Sodium Diet & Diuretics .

#### Summary

65 Y/O Saudi Male , Known Case Of Liver Cirrhosis , Admitted Through ER Complaining Of Vomiting Of Blood / 1 Hour . He Has A History Of Previous 2 Similar Attacks With Admissions And +Ve Family History Of Liver Cirrhosis In His Brother .

#### +Ve Findings In Examination :

- **General Examination :** Looking Ill , Jaundice , Palmar Erythema , Spider Nevi .

- **Local ( Abdominal ) Examination :**

✓ **Inspection :** Caput Medusa , Abdominal Distention .

✓ **Palpation :** Abdominal Tenderness , Enlarged Liver .

✓ **Percussion :** Moderate Ascites .

✓ **Auscultation :** Free .

# GIT Examination

- Introduce Yourself .
- Take Permission .
- Explain What You Are Going To Do .
- Maintain Privacy .
- Wash Your Hand .
- Exposure ( Full Nipples To Mid-Thigh ) .

## 1- General Examination :

### ABCDE :

- ✓ **Appearance :** Looks Well/Ill , Consciousness , Alert , Orientation To Time - Place - Person .
- ✓ **Body Built :** Average , Thin , Obese ( Depends On BMI ) .
- ✓ **Color :** Pale , Cyanosed , Erythematous .
- ✓ **Decubitus :** Patient's Sitting & Position .
- ✓ **Deformities :** Any Congenital Abnormality ( If You Find One Anomaly Search For Others )
- ✓ **Distress :** Difficulty In Breathing ( Dyspnic ) .
- ✓ **Environment :** Any Connections To Patient ( IV Line , Catheter , O<sub>2</sub> Mask , ECG , Wheelchair , ...Etc. "

### Vital Signs :

- ✓ **Temperature ( Temp ) :** Normally (  $37.2 \pm 0.4$  °C ) .
- ✓ **Pulse :** Normally ( 60-100 Beat/Min ) .
- ✓ **Blood Pressure ( BP ) :** Normally ( 120-139/80-90 mmHg ) .
- ✓ **Respiratory Rate ( RR ) :** Normally ( 12-16 Breaths/Min ) .
- ✓ **O<sub>2</sub> Saturation :** Normally ( >98% ) .

### Hands : ( Compare Both Hands Together )

#### ✓ Nails :

- Clubbing .
- Capillary Refill .
- Peripheral Cyanosis .
- Koilonychia .
- Leukonychia .

#### Grades Of Clubbing :

- **1** > Fluctuation Of The Nail Bed .
- **2** > Obliteration Of The Lovibond Angle .
- **3** > Parrot Beak Appearance Or Drum Stick Appearance .
- **4** > Hypertrophic Osteo-Arthropathy ( HOPA ) .

✓ **Palm :**

- Muscle Wasting .
- Palmar Erythema .
- Pallor Which Seen In Palmar Creases .

✓ **Arm :**

- Bruises , Scratch Marks , Ulcers , Scars , Pigmentation .
- Muscle Wasting .
- Spider Nevi ( In Face - Neck - Upper Chest Also ) .

- **Head & Neck :**

✓ **Eye :**

- Jaundice : Look At Upper Bulbar Conjunctiva While Patient Is Looking Downward .
- Pallor : Look At Lower Palpebral Conjunctiva While Patient Is Looking Upward .

✓ **Mouth :**

- Cyanosis : Lips For Peripheral Cyanosis & Tongue For Central Cyanosis .
- Jaundice : In Mucous Membranes .
- Aphthous Ulcer & Candida , Glossitis , Mouth Hygiene , Odour Of Breath .

✓ **Neck :**

- Lymph Nodes .
- Jugular Vein .
- Carotid Artery .

- **Lower Limbs :**

- Skin Changes , Muscle Wasting , Loss Of Hair .
- Edema : Pitting / Non-Pitting - Unilateral / Bilateral - Level .
- Pulse : Femoral - Popliteal - Dorsalis Pedis - Posterior Tibial .

## **2- Local Examination :**

# Inspection

## - Contour ( Stand At The Patient's Feet ) :

- ✓ **Normal** : Convex From Side-To-Side Antero-Posteriorly .
- ✓ **Generalized Bulge** : Obesity , Pregnancy , Ascites .
- ✓ **Localized Bulge** : Organomegally , Abdominal Mass .
- ✓ **Generalized Retraction** : Dehydration , Starvation .
- ✓ **Localized Retraction** : Previous Scar .

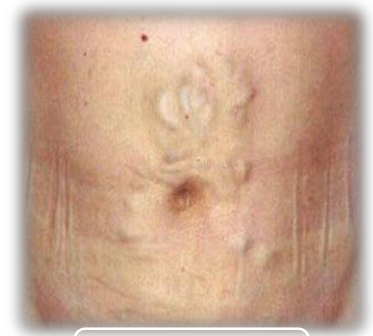## - Movement With Respiration ( Stand In The Rt . Side Of The Patient ) :

- ✓ **Males** : Abdomino-Thoracic .
- ✓ **Females** : Thoraco-Abdominal .

## - Peristalsis Movement , Skin Changes , Scars .

### - Subcostal Angle :

- ✓ **Normal** : Right / Acute Angle .
- ✓ **Obtuse** : Increase Intra-Abdominal Pressure .



Pic .1

### - Epigastric Pulsation :

- ✓ **Hepatic** : Tricuspid Incompetence .
- ✓ **Cardiac** : Right Ventricular Hypertrophy .
- ✓ **Vascular** : Abdominal Aorta Aneurism ( AAA ) .

### - Divarication Of Recti .

### - Umbilicus :

- ✓ **Normal** : Midway Between Xiphisternum & Symphysis Pubis , Rounded , Inverted .
- ✓ **Bluish** : Intra-Abdominal Hemorrhage , Pancreatitis , Pregnancy , Hemorrhagic Ascites .

### - Hernia Orifices .

### - Distribution Of Hair :

- ✓ **Males** : Triangular ( Become Transverse Indicates Feminization ) . ▲
- ✓ **Females** : Transverse . ▼

### - Dilated Veins :

- ✓ **Caput Medusa** : In Portal HTN . ( Pic .1 )
- ✓ **Flanks** : Inferior Vena Cava Obstruction .

#### # When We Say Dilated Vein ?

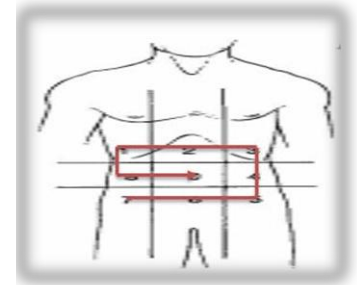
- Around Umbilicus Or In Flanks .
- Tortuous .
- Dilated .

## # N.B: How To Differentiate Between Caput Medusa & Dilated Veins Due To IVC Obstruction ?

- The Technique Should Be Performed Under The Level Of Umbilicus .

### Palpation

- Be At The Level Of The Patient .
- Keep Looking At The Face Of The Patient To Observe Painful Expression .
- Warm Your Hands .
- Ask The Patient About Presence Of Pain .
- Palpate Gently Keeping Hand Flat .



Pic.1

#### 1- Superficial Palpation : ( Pic.1 )

- i. Start Away From Pain , If There Is No Pain You Have To Start From Right Iliac Fossa And Proceed Clock-Wise To End In Supra-Pubic Area .
- ii. Comment On : Hotness , Tenderness , Rigidity & Superficial Masses .

#### 2- Deep Palpation : For Organomegally , Deep Masses And Deep Tenderness .

### Liver

- Start From Rt. Iliac Fossa And Palpate Towards The Right Costal Margin With Examining Hand Aligned Parallel To The Right Costal Margin .
- **If Palpable , Comment On :**
  - ✓ Size ( Enlarged - Shrunken ) .
  - ✓ Edge ( Sharp - Rounded , Irregular ) .
  - ✓ Consistency ( Soft - Firm - Hard ) .
  - ✓ Surface ( Smooth - Nodular ) .
  - ✓ Tenderness .
  - ✓ Pulsation .
  - ✓ Liver Span .

### **\*\* Notes :** In Case Of Tense Ascites , You Can Palpate By Dipping Method :

- ✓ Fingers Tips Are Pressed With A Quick Stabbing Motion Into The Abdomen , A Tapping Sensation Is Felt By The Organ Due To Displacement By Fluid .

## Spleen

- Start Palpation In The Right Iliac Fossa With Patient Breath In And Out .
- Move Your Hand Toward The Left Costal Margin .
  
- **If Palpable , Comment On :**
  - ✓ Size .
  - ✓ Notch .
  - ✓ Consistency .
  - ✓ Surface .
  - ✓ Tenderness .
  
- **If Not Palpable , Use The Following Methods :**
  - ✓ Roll The Patient Over Right Lateral Position , And Palpate Again While Pt. Is Taking Deep Breath
  - ✓ Bimanual Examination .
  - ✓ Hooking Method .
  - ✓ Dipping Method In Tense Ascites .
  - ✓ Percussion Of Traub's Area .

## Kidney

### Bimanual Palpation :

- Put Left Hand In Renal Angle And Right Hand In Lumbar Area .
- Push Left Hand Upward And Right Hand Downward .
- If Palpable Look For Ballottement .
- Repeat Same In Other Side .
- Normally Kidneys Are Not Palpable Except In Early Infancy Or In Very Thin Patient While Lower Pole Is Palpable .
- Kidneys Are Round And Firm .
- **If Palpable , Comment On :**
  - ✓ Size .
  - ✓ Consistency .
  - ✓ Surface .
  - ✓ Tenderness .
  - ✓ Percussion : Resonant .

## # Spleen VS Left Kidney :

Spleen	Left Kidney
In The Left Hypochondrium .	In The Lumbar Region .
Notch Is Present .	Notch Is Not Present
You Cannot Insinuate The Fingers Under Left Costal Margin .	You Can Insinuate The Fingers Under Left Costal Margin .
Moves Inferio-Medially On Inspiration .	Move Inferiorly On Inspiration .
Well Defined Medial Border .	Upper End Is Rounded .
Not Ballottable .	Ballottable .
Dull On Percussion .	Resonant On Percussion .

## Urinary Bladder

- Distended Bladder Is Felt In Supra-Pubic Area, It's Globular Arising From Pelvis .
- Dullness On Percussion .
- Desire For Micturition On Palpation .
- Causes : Normal Patient , Outflow Tract Obstruction , Neurological Problems .

### \*\* Note :

- Don't Forget To Palpate Also For Deep Masses & Comment If You Find A Mass .

## Percussion

### " To Detect Ascites & Liver Span "

A- Fluid Thrill > For Huge Collection Of Fluid :

- Need One Assistant To Put His / Her Ulnar Side Of The Hand In The Middle Of The Abdomen .
- Put Your Left Hand Flat On Patient's One Lumbar Region .
- Now Tap The Opposite Lumbar Region By One Hand And Feel The Impulse By Flat Of Your Other Hand .



**B- Shifting Dullness** > For Moderate Collection Of Fluid :

- Start With Patient In Supine Position .
- Start From Umbilicus Toward Left Flank And Note The Point Of Dullness.
- Keep Your Finger At That Point , Then Roll The Patient Over The Right Side And Wait For About 30 Seconds .
- Percuss Over The Same Area And Note The Resonance .
- Now Proceed Toward Umbilicus Till You Get The Dullness Again .
- The Previous Point Of Dullness Is Shifted From Left To The Right Side ( Shifting Dullness ) .

**C- Puddle Test** > For Minimal Collection Of Fluid :

- Minimal Ascites Maybe Missed By Previous Methods , But Maybe Elicited By Putting Patient In Knee-Elbow Position .
- Percuss Over Umbilicus And Note The Dullness , Normally It's Resonant .
- Turn On Supine Position Again Note The Resonance .

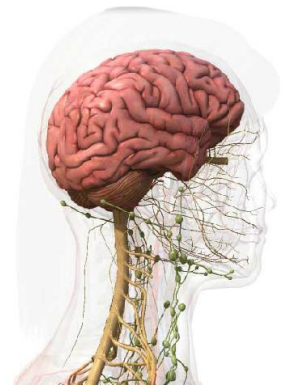
## Auscultation

- ✓ **Venous Hum** : In Epigastric Area .
- ✓ **Liver Bruit** : On Liver Area .
- ✓ **Renal Bruit** : In Para-Umbilical Area .
- ✓ **Intestinal Sounds** : In Umbilical Area :
  - Normally : 1 Sound each 6 Seconds .
  - Diminished : In Paralytic Ileus .
  - Exaggerated In : In Intestinal Obstruction .

**\*\* Note :** By The End Of Abdominal Examination Do Not Forget Examine :

External Genitalia / Back Examination / PR Examination / Lymph Nodes Examination .

# Neurology



# History Of Common Cases

## 1) Epilepsy :

### - Personal History :

Ahmed Hussain Ali , 26 Y/O Saudi Male From Jazan , Single , Student . Admitted Through ER On 2-1-1436 H .

### - C/O :

Abnormal Movement / 1 Day .

### - HPI :

He Is Known Case Of Epilepsy For 4 Years .

The Patient Was On Usual Status Till 1 Day Back When He Started To Has Abnormal Movement Which Was Abrupt In Onset , 1 Day Duration , Appear When He Was Playing , The Condition Starts By Abnormal Movement Of Right Limb For 2 Minutes Then Stiffening Of All Body And Loss Of Consciousness , Then Tonic-Clonic Movement Of All Limb For 2 Minutes . Then He Sleep For 45 Minutes And Feel Pain In All Muscle . There Is No Loss Of Memory , No Weakness & No Headache .

● Systemic Review : -Ve .

● Hospital Course : Underwent CBC , Blood Glucose Level , I.V Fluids , Medications And The Patient Is Improving .

### - Past History :

Diagnosed At KFCH , Since He Was 4 Years Back , Controlled On Phenytoin .

+Ve History Of 5 Previous Similar Attack With 2 Previous Admissions , The Last One Was 6 Months Back .

- Family History : -Ve Apart From +Ve History Of Epilepsy In His Father & +Ve Consanguinity .

- Social History : Good Living Conditions & Socio-Economic Status .

- Drugs & Allergies : Phenytoin , 1 Time/Day , With Good Compliance .

### Summary

26 Y/O Saudi Male Known Case Of Epilepsy , Admitted Through ER Complaining Of Abnormal Movement / 1 Day . The Condition Started With Movement Of Right Hand , Then Became Generalized Tonic-Clonic , For 2 Minutes Then He Sleep For 45 Minutes .

## 2) Guillain-Barre Syndrome ( GBS ) :

### - Personal History:

Fatimah Hussain Ali , 22 Y/O Saudi Female From Jazan , Single , Student . Admitted Through ER On 2-1-1436 H .

### - C/O:

Difficulty In Breathing / 1 Day .

Difficulty In Swallowing / 2 Days .

### - HPI:

Patient Was Well Until 2 Weeks Ago When She Had A Common Cold , After Subsided By 5 Days She Started Difficulty Of Swallowing For Both Fluid & Solid , Nasal Regurgitation That Badly Interfere With Eating . After 1 Day She Complained Of Muscle Weakness Of Lower Limb " Can't Walk " And Progressive Dyspnea By Which Went To ER .

● Systemic Review : -Ve .

● Hospital Course : Patient Putted Immediately Under Mechanical Ventilator And Admitted To ICU For 3 Days , She Is Improved And Discharged To Medical Ward On Regular Monitoring Of Ventilation .

- Past History: -Ve .

- Family History: -Ve .

- Social History: Good Living Conditions & Socio-Economic Status .

- Drugs & Allergies: -Ve .

- Gynecological History: Regular Cycle , Average Amount , 7/28 .

### Summary

22 Y/O Saudi Female Admitted Through ER Complaining Difficulty In Breathing / 1 Day , Difficulty In Swallowing / 2 Days , Associated With Lower Limb Weakness .

### +Ve Findings In Examination:

- General Examination: Patient Looks Ill , Dyspnic .

- Facial Palsy: May Present .

- Motor System: Weakness & Hyporeflexia .

- Sensory System: Usually Intact .

## 3) Stroke :

### - Personal History:

Ahmed Hussain Ali , 72 Y/O Saudi Male From Jazan , Married For 30 Years And Has 7 Offsprings , Retired .

Admitted Through ER On 2-1-1436 H .

### - C/O:

Left Sided Weakness / 1 Hour .

### - HPI:

Patient Is Known Case Of HTN .

He Was Well Until 1 Hour Back When He Stated To Has Sudden Left Sided Weakness . He Was Outside Walking When His Legs Suddenly Gave Way Beneath Him , A Passer By Came To His Assistance , They Noticed His Speech Was Slurred , His Face Looked Asymmetrical And He Was Unable To Lift His Left Arm Up . There Is No LOC , No Loss Of Memory , No Headache . No Change In Vision .

● Systemic Review : -Ve .

● Hospital Course : Underwent CBC , CT Brain , IV Fluids , Some Medications And He Is Improving .

- Past History: HTN Diagnosed 10 Years Back In KFCH , Controlled .

- Family History: -Ve .

- Social History: Good Living Conditions & Socio-Economic Status .

- Drugs & Allergies: Anti-HTN Medications + Aspirin .

### Summary

72 Y/O Saudi Male Came To ER Complaining Left Sided Weakness / 1 Hour Associated With Slurred Speech And Asymmetrical Face . He Is Known Case Of HTN And Long Use Of Aspirin .

### +Ve Findings In Examination :

- General Examination: Conscious , Alert , Oriented , Respond To Commands .

- Neurological Examination :

- ✓ Intact Visual Field .
- ✓ Moderate Left Sided Facial Weakness With Sparing Of The Muscles Of The Forehead .
- ✓ When Extend Left Arms Out In Front Of Him , It Drifts Down .
- ✓ Hand Grip In Left Side Is Weak .
- ✓ Sensory Inattention On The Left Side .

## # NOTES On Stroke :

### • Localization Of Stroke :

#### A- Cortical :

- **Impairment Of Higher Function :** LOC , Aphasia In Dominant Hemisphere .
- **Impairment Of Motor Function :** Incomplete Hemiplegia .
- **Impairment Of Sensory Function :** Cortical Sensation Affected .
- **Urinary Incontinence :** Medio-Frontal Lobe Lesion .

#### B- Sub-Cortical :

##### - **Internal Capsule :**

- ✓ Complete Hemiplegia .
- ✓ Sensory Loss Of All Modalities .
- ✓ CNs Affection : UMNL Of Facial And Hypoglossal Nerves , Weakness Of Face And Tongue Correlate With Side Of Weakness In Body

##### - **Brainstem :**

- ✓ **Midbrain :** 3<sup>rd</sup> & 4<sup>th</sup> CNs Affection At The Same Side .
- ✓ **Pons :** 5<sup>th</sup> CN ( Mid-Pons ) , 6<sup>th</sup> CN ( Medial Lower Pons ) & 7<sup>th</sup> CN ( Lateral Lower Pons ) Affection At Same Side .
- ✓ **Medulla :** 12<sup>th</sup> CN , Tongue Will Deviate To The Site Of Lesion .

##### - **Spinal Cord :**

- ✓ **Weakness :** Due To Cortico-Spinal Tract Injury .
- ✓ **Sensory Level :** Due To Ascending Tract Injury .
- ✓ **Sphincter Dysfunction :** Due To Autonomic Nerves Injury .

# **Neurological Examination**

- **Introduce Yourself .**
- **Take Permission .**
- **Explain What You Are Going To Do .**
- **Maintain Privacy .**
- **Wash Your Hand .**

## **A- Important Points In General Examination**

- General Look & Environment .
- Signs Of Respiratory Distress .
- Vital Signs : Pulse , BP , RR , Temp .
- Pallor , Jaundice .
- Skin Changes , Any Deformities .
- Any Dysmorphic Features .
- Skull Shape , Fontanel Size & Closure .
- Abnormalities In The Spines ( Scoliosis , Kyphosis , Lordosis , Spina Pifida ) .
- Growth Parameters .

## **B- Signs Of Meningeal Irritation**

### **A- Neck Stiffness :**

- Start By Active Movement , Ask The Patient To Flex His Neck As Full As He Can & Then Proceed To Passive Flexion.

### **B- Kernig's Sign :**

- With Patient Lying Flat On The Bed , Flex The Hip Fully & Then Try To Extend The Knee Slowly .
- Positive Response If There Is Pain Or Resistance To Knee Straightening In The Neck Or Back .

### **C- Brudzinski's Sign :**

- Flex The Neck Of The Patient While Observing The Hip & Knees .
- Positive Response If There Is A Flexion In The Neck Results In Hip & Knee Flexion With Pain On The Back Of Neck .

## D- Higher Function Examination

### ❖ Loss Of Consciousness (LOC):

- By Glasgow Coma Scale ( GCS ) :

Eye Opening	Verbal Response	Motor Response
Spontaneous (4)	Oriented (5)	Obeys (6)
To Loud Voice (3)	Confused , Disoriented (4)	Localized (5)
To Pain (2)	Inappropriate Words (3)	Withdraws ( Flexion ) (4)
Non (1)	Incomprehensible Sounds (2)	Abnormal Flexion Posturing (3)
	Non (1)	Extension Posturing (2)
		Non (1)

- Interpretation Of GCS :

- ✓ 3 - 8 : Severe Brain Injury .
- ✓ 9 - 12 : Moderate Brain Injury .
- ✓ 13 - 15 : Mild Brain Injury .

### ❖ Orientation ( Frontal Lobe Function ):

- What Is Your Name ?
- What Is Your Age ? What Is Your Address ?
- Where Are You Now ? What Is The Time , Day , Date , And Month ?

# Disorientation May Be Acute ( Delirium ) Or Chronic ( Dementia ) .

### ❖ Memory ( Temporal Lobe Function ):

- **Short Term Memory** : Ask About Any Recent News .
- **Long Term Memory** : Ask About Event That Occur More Than 5 Years Ago ( Marriage , Graduation , ... ) .

### ❖ Handedness:

- Shake The Patient Hand And Ask Is He Right Or Left Handed .
- To Identify The Dominant Hemisphere .



### ❖ Speech :

- Let The Patient Talks Freely , This Comes From History Taking Already .
- Ask Patient To Describe The Room Or His Job To Promote Flowing Speech .
- Then Test **Comprehension** By Applying Commands " Touch Your Nose Then Ear Then , ..." , Then By Yes & No Questions .
- Then Test **Repetition** , For Example : Repeat " Alhamdulillah " .

# If No Abnormality Detected There Is No Need To Further Examination .

### NOTES : Abnormal Speech :

#### A- Dysphasia :

- **Receptive ( Posterior ) Dysphasia :** The Patient Can't Understand The Spoken Or Written Words . Speech Is Fluent But Disorganized , Occur With Lesions In Dominant Hemisphere : Wernicke's Area Specifically.
- **Expressive ( Anterior ) Dysphasia :** The Patient Understand But Can't Answer Appropriately . Speech Isn't Fluent , Occur With Lesions In Dominant Hemisphere : Broca's Area Specifically .
- **Nominal Dysphasia :** The Patient Can't Names The Objects Rather That Is Normal , Occur With Lesions In Dominant Hemisphere : Posterior Temporo-Parietal Area .
- **Conductive Dysphasia :** The Patient Repeats Statements Poorly But Can Follow Commands , Lesion In Arcuate Fasciculus Or Other Connecting Fibers .

#### B- Dysarthria :

- Difficulty In Articulation Without Any Problems In Content Of Speech , Occurs In UMNL Of Cranial Nerves And Cerebellum Lesion .

#### C- Dysphonia :

- Alteration Of The Sound Of The Voice , May Due To Laryngeal Diseases Or RLN Palsy .

### ❖ Cortical Sensation :

- **Astereognosis :** Ability To Recognize Familiar Objects When Put On Hand While Closed Eyes .
- **Graphesthesia :** Ability Recognize Numbers & Letters When Written In The Palm While The Eyes Closed .
- **Tactile Localization :** Ability To Recognize The Point Of Touch With Closed Eyes .
- **Two Points Discrimination :** Ability To Identify 2 Points Applied Simultaneously To The Dorsum Of The Foot Or Pulp Of The Finger. Approximate The Two Points Together Until He Perceives Them As One Point , Minimal Separation 3 Cm .

## E- Cranial Nerves Examination (CNs)

### 1- Olfactory Nerve (I): " Not Tested Routinely "

- Ask The Patient To Close His Eyes & Say Yes If He Smells Anything New ( Use Familiar Odour ).
- Each Nostril Should Be Examined Separately

### 2- Optic Nerve (II):

#### A- **Visual Acuity** : ( Pic.1 )

- Examine Near Vision By Reading & Far Vision By Snellen Chart .
- Each Eye Should Examined Separately .

#### B- **Color Vision** : ( Pic.2 )

- By Ishihara Chart .

#### C- **Visual Field** : ( Pic.3 )

- By Confrontation Test , The Examiner Head Should Be At Level Of Patient Head And Test Each Eye Separately .
- Patient Looks Directly To Examiner Eye .
- By Finger Or Colored Pin Brought In From Outside Until The Patient Can See It .

#### D- **Papillary Reactions** :

##### - **Reaction To Light** :

- ✓ Ask The Patient To Look Away From The Major Source Of Light In The Room , Then Shine Pen Torch On The Pupil From The Side Of The Eye .
- ✓ Both Pupils On The Same Side ( Direct Light Reflex ) As Well As The Opposite Side ( Consensual Light Reflex ) Well Constrict ( Repeat From The Other Side ) .
- ✓ Remember That The Afferent Limb Is 2<sup>nd</sup> CN & The Efferent Is 3<sup>rd</sup> CN .

##### - **Reaction To Accommodation Reflex** :

- ✓ Ask The Patient To Look At A Distant Object , Then Ask Him To Focus On A Finger Held Close To His Nose .
- ✓ The Eyes Converge & The Pupils Constrict Attempting To Look At A Close Object .

#### E- **Fundoscopy** : To Examine The Optic Disc & Retina ( Not Routinely Performed ) .

### 3- Oculomotor, Trochlear & Abducent nerves ( III, IV, VI ):

- All Muscles Are Supplied By Oculomotor Except Superior Oblique ( Trochlear ) & Lateral Rectus ( Abducent ) .
- Ask The Patient To Follow An Object ( E.g : Your Finger ) In Different Direction .
- Move It In Vertical , Horizontal & Oblique Directions .

#### 4- Trigeminal nerve ( V ) : ( Not Routinely Examined )

##### - **Motor Component :**

- ✓ Ask The Patient To Open & Close His Mouth , The Jaw Will Be Deviated To The Paralyzed Side .
- ✓ Ask The Patient To Clench His Teeth , Then Palpate For Masseter & Temporalis Muscles.
- ✓ Jaw Reflex Test ( Pic 4 ) : Ask The Patient To Open His Mouth A Little , Place Your Index Over The Chin & Then Tap Your Index In A Downward Direction With A Tendon Hammer. Normally There Is A Weak Or Absent Jerks Of The Jaw .

##### - **Sensory Component :**

- ✓ Touch The Face In 3 Different Regions With A Cotton Over The Forehead ( Ophthalmic ) , Cheeks ( Maxillary ) , And Chin ( Mandibular ) .
- ✓ Ask The Patient To Close His Eyes & Say Yes If He Feels The Touch .
- ✓ Corneal Reflex Test : Ask The Patient To Look In One Direction & Approach The Cornea From The Opposite Side With A Cotton , Observe For The Blink .

#### 5- Facial nerve ( VII ) :

##### - **Motor :**

- ✓ Facial Asymmetry ( Absence Of Frontal Wrinkles ) .
- ✓ Flattening Of Naso-labial Folds .
- ✓ Open Eye ( Widened Palpebral ) .
- ✓ Deviation Of The Angle Of Mouth ( Drooping ) .

##### - Ask The Patient To :

- ✓ Raise Eyebrows ( Occipito-Frontalis Muscle ) .
- ✓ Close Eyes Tightly While You Are Trying To Open Them ( Orbicularis Oculi ) .
- ✓ Smile Or To Show His Teeth ( Levator Labii Muscle ) .
- ✓ Whistle ( Orbicularis Oris ) .
- ✓ Puff Out Cheeks & To Keep Them Out While You Are Tapping With Your Finger Over Both Cheeks ( Buccinators ) .

##### - **Sensory :**

- ✓ Chorda Tympani Supplies Taste To The Anterior Two-Thirds Of The Tongue .
- ✓ Examination Of Taste Is Hard To Perform & Not Usually Recommended .

#### 6- Vestibulo-cochlear Nerve ( VIII ) :

##### - **Cochlear Division :**

- ✓ Audiometry , Rinne's Test , Weber's Tests . ( Pic.5 )

##### - **Vestibular Division :**

- ✓ It's Usually Tested Along With Cerebellar Function In Order To Assess Balance & Gait .

### 7- Glossopharyngeal & Vagus Nerves ( IX, X ):

- Talk To The Patient To Comment On His Voice ( Hoarseness Of Voice ) .
- **Palatal Reflex** : Touch The Patient's Soft Palate With Tongue Depressor , It Will Lead To Elevation Of Soft Palate & Retraction Of Uvula .
- **Gag Reflex** : Touch The Patient's Pharyngeal Wall With Spatula , It Will Stimulate Gagging .

### 8- Spinal Accessory Nerve ( XI ): ( Pic.6)

- **Trapezius** :
  - ✓ Ask The Patient To Shrug His Shoulder , Any Weakness Result In Ipsilateral Dropping Of The Shoulder .
- **Sternocleidomastoid** :
  - ✓ Put Your Hand On The Medial Side Of The Patient's Jaw , Ask Him To Push Against Your Hand While You Are Palpating The Opposite Sternocleidomastoid Muscles .

### 9- Hypoglossal Nerve ( XII ):

- Look At The Patient's Tongue , While Inside The Mouth Observe For Size , Position , Wasting , Fasciculation .
- Ask The Patient To Stick His Tongue Out , Observe For Any Deviation To Any Side .
- Ask The Patient To Push By His Tongue Against Tongue Blade ( On Each Side ) .

## F- Motor System Examination

### - Inspection :

- **Posture** .
- **Gait** .
- **Muscle Bulk** : Atrophy - Hypertrophy .
- **Involuntary movements** : Chorea , Tics , Tremor , Fasciculation .

### - Examination Of The Tone :

#### A- Upper Limb :

- Shaking Hands And Do Supination & Pronation .
- Flexion And Extension In The Elbow .

#### B- Lower Limb :

- Rolling .
- Flexion And Extension In Knee Joint .
- Raise Legs Up And Release It To Fall Down .

### Notes :

#### - Grades Of Power :

- ✓ 0/5 : No Contraction .
- ✓ 1/5 : Just Flickering .
- ✓ 2/5 : Horizontal Movement With Gravity Only .
- ✓ 3/5 : Against Gravity , But WITHOUT Resistant .
- ✓ 4/5 : Against Gravity , With Minimal Resistant .
- ✓ 5/5 : Normal Strength .

- Movement Against Gravity = Grade 3 Or Above .

- **Examination Of The Power :**

A- **Upper Limb :**

- Hand Grip .
- Flexion And Extension In Elbow With & Without Resistant .
- Abduction & Adduction Of Both Arms With & Without Resistant .

B- **Upper Limb :**

- Abduction , Adduction , Flexion , Extension Of Hip Joint With & Without Resistant .
- Flexion And Extension In Knee Joint With & **Without** Resistant .
- Eversion , Inversion , Planter Flexion , Plantar Extension Of Feet With & Without Resistant .

- **Examination Of The Reflexes :**

A- **Deep Tendon Reflex : ( Pic.7 )**

Reflexes	Root	Method
Biceps	C5 – C6	- Flex the elbow to 120. - Put your finger on the tendon and percuss over it.
Triceps	C6 – C7 – C8	- Flex the elbow to 90. - Percuss directly over the tendon.
Brachioradialis	C5 – C6	- Cause wrist extension.
Knee-jerk	L2 – L3 – L4	- Percuss over the tendon above the tibial tuberosity. - Contraction of quadriceps muscle will extend the knee.
Ankle-jerk	S1 – S2	- Both knee and ankle are flexed. - Percuss over the achilles tendon. - Contraction of gastrocnemius cause planter flexion.

- **Rating Of Deep Tendon Reflexes :**

- ✓ 0 : Absent = LMNL OR Early UMNL ( Shock Stage ) .
- ✓ +1 : Trace OR Seen Only With Reinforcement .
- ✓ +2 : Normal .
- ✓ +3 : Brisk .
- ✓ +4 : Non-Sustained Clonus .
- ✓ +5 : Sustained Clonus .

B- **Planter Reflex : ( Pic.8 )**

- Scratch From Lateral Surface Of Dorsum Of Foot And Goes Medially .
- Plantar Extension ( Big Toe Upward ) Called Babinski Sign And It Indicates UMNL .

## C- Superficial Reflexes :

### 1- Abdominal Reflexes ( Epigastric T6-T9 , Abdominal T9-T11 , Lower Abdomen T12-L1 ) : ( Pic.9 )

- By Lightly Stroking The Abdominal Wall Diagonally Towards Umbilicus In Each Quadrant Of The Abdomen .
- Normally : Contraction Of Abdominal Wall .
- Absent Of Contractions Indicates UMNL .

### 2- Cremasteric Reflex ( L1-L2 ) :

- Stroke Inner Part Of Thigh In A Downward Direction .
- Cremasteric Muscle Contraction Causes Pull Up Of Scrotum At Same Side .

## G- Sensory System Examination :

### A- Superficial Sensation : " Carried On Spino-Thalamic Tract "

#### 1- Pain :

- ✓ A Similar Approach Is Used With Stimulus Being The Tip Of A Pin , The Patient Should Be Respond By Saying Sharp OR Dull .

#### 2- Temperature :

- ✓ Use Two Tubes Of Cold & Warm Water , Touch The Patient With One Of The Tubes And Ask Him To Tell You If It's Cold Or Warm .

#### 3- Fine Touch :

- ✓ Touch The Skin Lightly With A Wisp Of Cotton , Then Ask Him To Say Yes If He Feel It With Closed Eyes .

### B- Deep Sensation : " Carried On DCML Tract "

#### 1- Proprioception :

Hold The Middle Phalanx Of The Patient's Index Finger By Side, Then Flex & Extend The Distal Phalanx Telling The Patient Which Direction You Mean By Up & Down, Then Repeat It With His Eyes Closed .

#### 2- Vibration : By Tuning Fork On Bony Prominence While Eyes Are Closed .

#### 3- Deep Touch .

## H- Cerebellar & Coordination Examination : ( Not Routinely Examined )

### 1- Upper Limbs:

#### A- **Finger-Nose Test :**

- Ask The Patient To Place The Tip Of The Index On His Own Nose Starting From Full Abduction Of The Arm With Eyes Open , Then Eyes Closed .
- Observe For Intention Tremor & Dysmetria ( Overshooting ) .

#### B- **Dysdiadochokinesia :**

- Ask The Patient To Put One Hand On The Back Of The Other Quickly & Regularly , Then Ask Him To Tap The Back Of His Right Hand Alternately With The Palm Of His Left Hand & Vice Versa , Also Ask Him To Rapidly Supinate & Pronate His Hands Together To Observe Symmetry & Regularity .

### 2- Lower Limbs:

#### A- **Heel-Shin Test : ( Pic.10 )**

- Ask The Patient To Place His Heel On The Opposite Knee & Then Run It Downwards Over The Shin Of The Tibia To The Foot .

#### B- **Toe-Finger Test :**


- Ask The Patient To Left His Big Toe & Touch Your Finger With It .

#### C- **Gait :**


- Ask The Patient To Walk .

### ## Romberg's Test : ( Pic.11 )

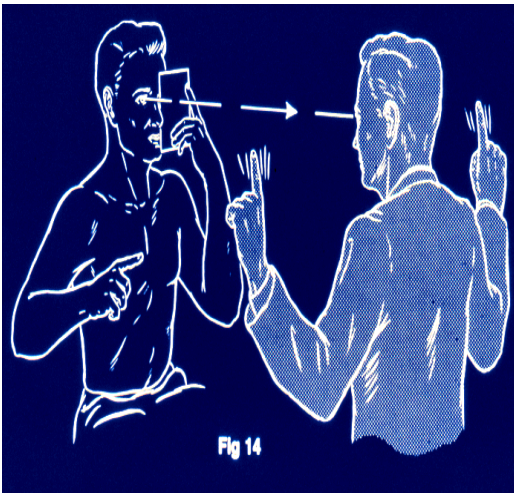
- Ask The Patient To Stand Erect With Eyes Open , Then Ask Him To Close His Eyes .
- It Is Positive When Unsteadiness Increase With Closed Eyes .
- Positive Result Indicates Proprioception Loss .



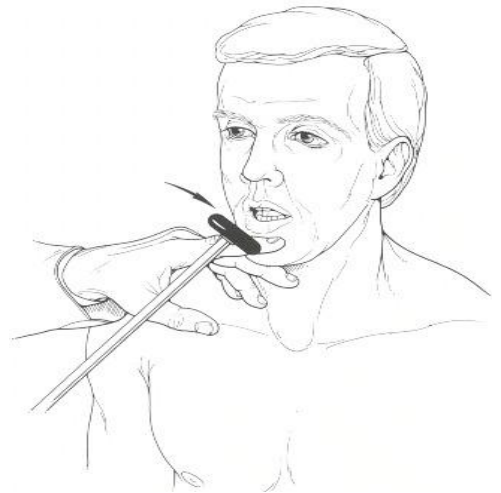Pic.1



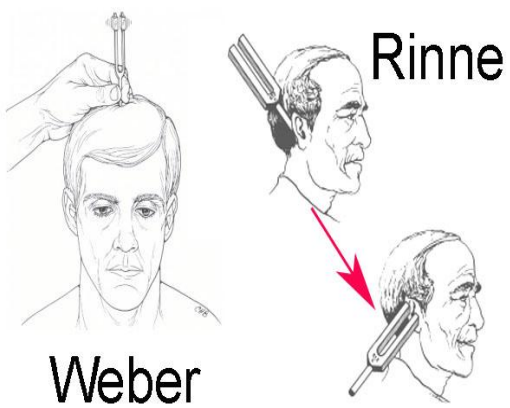
Pic.2



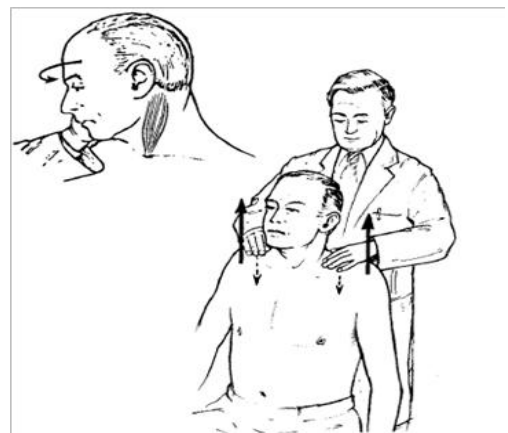Pic.3



Pic.4

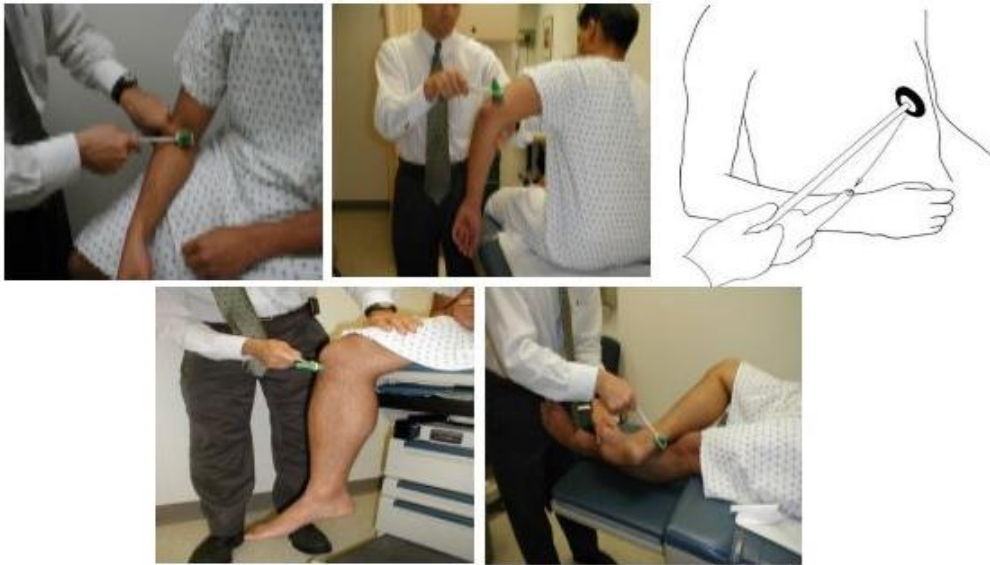

Pic.5

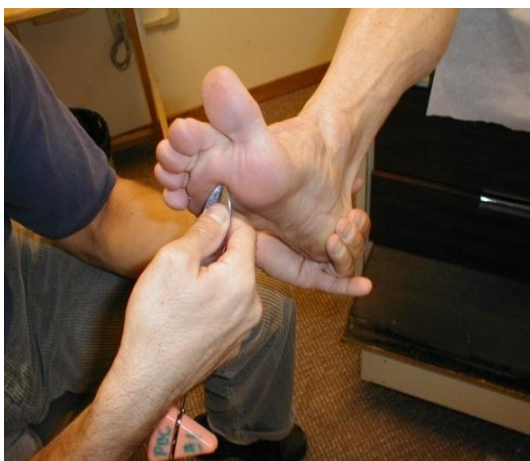

Pic.6

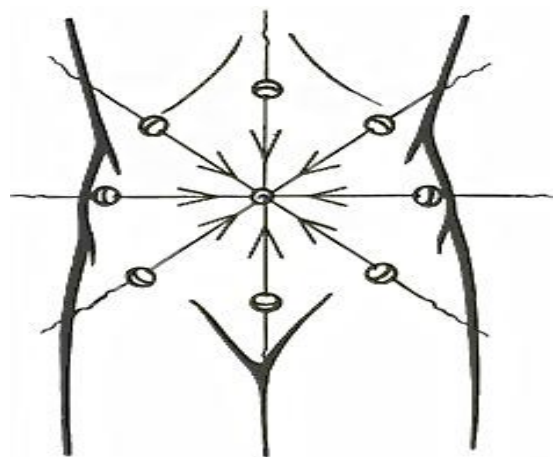




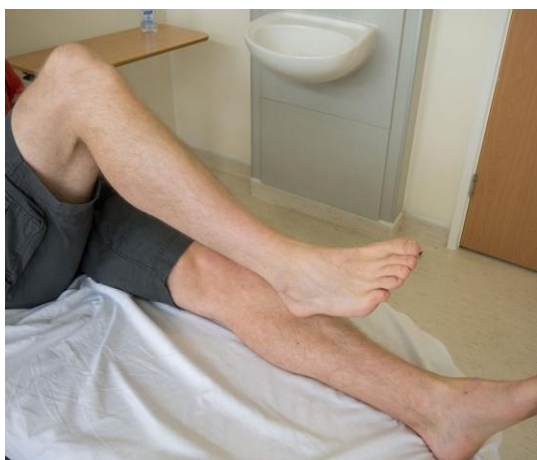Pic.7



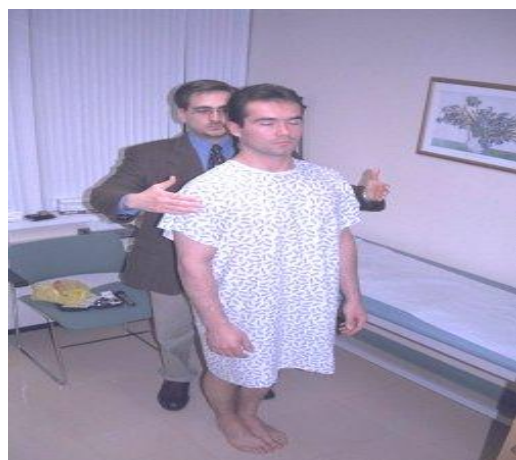Pic.8



Pic.9



Pic.10



Pic.11

# Hematology



# History Of Common Cases

## Sickle Cell Anemia (SCA) :

### - Personal History :

Ahmed Hussain Ali , 19 Y/O Saudi Male From Jazan , Single , Student , Admitted Through ER On 2-1-1436 H .

### - C/O :

Back And Joint Pain / 1 Day .

### - HPI :

He Is Known Case Of SCA . He Was On Usual Status Till 1 Days Back When She Started To Have Back Pain Which Was Gradual Onset , Progressive In Course , Lower Back At Sacral Area Which Radiating To Lower Extremities , Aggravating When The Patient Move And Relieving By Analgesic , Interfering With Patient's Activity And Sleep . After 2 Hours , The Patient Complains Of Joint Pain In Knee , Progressive , Aggravating When The Patient Move , Not Reliving By Analgesic . No Muscle Pain Or Wasting & No Subcutaneous Nodules .

● Systemic Review : -Ve .

● Hospital Course : Underwent CBC , X-Ray , Analgesic & I.V Fluids And The Patient Is Improving .

### - Past History :

SCA Diagnosed At KFCH Since He Was 1 Years Old , He Is On Folic Acid , Hydroxyurea .

+Ve History Of Many Previous Attacks With Admissions , Last One Was 4 Months Back .

Blood Transfusion : Tow Times With One Unit .

- Family History : -Ve Apart From Consanguinity & His Brother Has SCA .

- Social History : Good Living Conditions & Socio-Economic Status .

- Drugs & Allergies : He Is On Folic Acid & Hydroxyurea .

### N.B : Precipitation Factors Of Vaso-Occlusive Crisis :

- Infection .
- Cold
- Hypoxia , High Altitude .

### Summary

19 Y/O Saudi Boy Admitted Through ER Complaining Of Back Pain & Joint Pain / 1 Day . He Is Known Case Of SCA Since He Was 1 Y/O . He Has Many Previous Similar Attacks & Admissions .

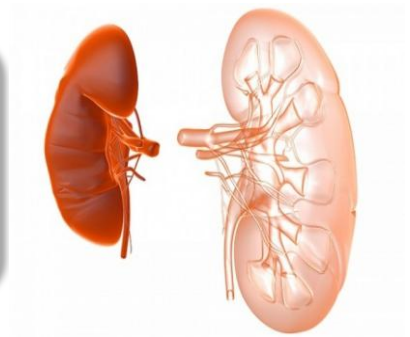
### +Ve Findings In Examination :

- General Examination : Looking Ill , With Pallor & Jaundice , No Organomegally .

- Local ( Joint ) Examination :

- ✓ Painful Range Of Motion , With No Swelling Or Tenderness .

# Nephrology



# History Of Common Cases

## 1) Acute Renal Failure ( ARF ) :

### - Personal History :

Ahmed Hussain Ali , 30 Y/O Saudi Male From Jazan , Single , Teacher , Admitted Through ER On 2-1-1436 H .

### - C/O :

Loin Pain / 3 Days .

### - HPI :

The Patient Was Well Till 4 Days Back When He Started To Has Abdominal Pain , Fever , Vomiting And Diarrhea , Which Associated With Severe Dehydration And Admitted To The Hospital . After ONE Day Of Admission , He Started Complaining Of Loin Pain Which Was Dull Aching , Progressive , Not Radiated , With No Aggravating Or Reliving Factor , Associated With Decrease Urine Output & Dizziness . No History Of Dysuria , Urine Retention , Urethral Discharge , Dysphagia , Regurgitation , Jaundice , Constipation OR Melena .

● Systemic Review : -Ve .

● Hospital Course : Underwent CBC , Analgesic , I.V Fluids & Anti-Emesis And The Patient Is Improving .

- Past History : -Ve .

- Family History : -Ve Apart From Consanguinity & His Father Has HTN .

- Social History : Good Living Conditions & Socio-Economic Status .

- Drugs & Allergies :

He Is On Anti-Emesis , Analgesics and Multivitamins Now .

No History Of Long-Term Medication OR Allergy .

### Summary

30 Y/O Saudi Male Compiling Of Loin Pain For 3 Days Due To Severe Dehydration, Associated With Decrease Urine Output & Dizziness .

### +Ve Findings In Examination :

- General Examination : Looking Ill .

- Local ( Abdominal ) Examination :

✓ May Be Palpable Mass , Costo-Vertebral Angle Tenderness .

## 2) Renal Stone :

- **Personal History :**

Ahmed Hussain Ali , 30 Y/O Saudi Male From Jazan , Single , Teacher , Admitted Through ER On 2-1-1436 H .

- **C/O :**

Loin Pain + Red Urine / 1 Day .

- **HPI :**

Acute Onset Right Flank Pain , Progressive In Course , Radiating To Lower Abdomen & Thigh , Aggravating When The Patient Move And Relieving By Analgesic , Interfering With Patient's Activity And Sleep . Patient Also Complains Of Red Urine , Small In Amount . No Dysuria , Urine Retention , Urethral Discharge .

● Systemic Review : -Ve .

● Hospital Course : Underwent CBC , Abdominal X-Ray , Analgesic & I.V Fluids And The Patient Is Improving .

- **Past History :** -Ve .

- **Family History :** -Ve Apart From Consanguinity & His Father Has HTN .

- **Social History :** Good Living Conditions & Socio-Economic Status .

- **Drugs & Allergies :**

He Is On Analgesics Now .

No History Of Long-Term Medication OR Allergy .

### Summary

30 Y/O Saudi Male Admitted Through ER Complaining Of Loin Pain And Red Urine For 1 Days Prior Of Admission , The Pain Radiated To Lower Abdomen & Thigh .

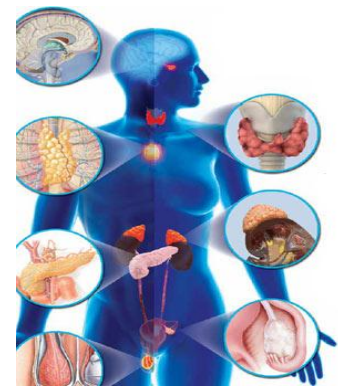### +Ve Findings In Examination :

- **General Examination :** Looking Ill , Move Constantly ( Seeking For Comfortable Position ) .

- **Local ( Abdominal ) Examination :**

✓ Costo-Vertebral Angle Tenderness .

# Endocrinology



# History Of Common Cases

## 1) Diabetes Mellitus ( DM ) :

### - Personal History:

Ahmed Hussain Ali , 45 Y/O Saudi Male From Jazan , Married And Has 3 Offsprings , Teacher .

Admitted Through ER On 2-1-1436 H .

### - C/O:

Increase Urination / 5 Days .

### - HPI:

The Patient Was Well Till 5 Days Back When He Started To Has Gradual Increasing in Urination , The Patient Notice That His Urine Amount Increased And Increase The Frequency Also . The Condition Associated With Excess Eating , Excess Thirst Which Overcome By Drinking More Amount Of Water And Sometimes Feel Of Dizziness . There Is No History Of Dysuria , Urine Retention , Changing In Urine Color OR Urethral Discharge .

● Systemic Review : -Ve .

● Hospital Course : Underwent CBC , Blood Sugar , Urine Analysis , I.V Fluids .

- Past History: -Ve .

- Family History: -Ve Apart From Consanguinity & His Father & Mother Have DM .

- Social History: Good Living Conditions & Socio-Economic Status .

- Drugs & Allergies: -Ve .

### Summary

45 Y/O Saudi Male Compiling Of Increase Urination For 5 Days Associated With Increase Thirst , Eating , And Sometimes Feeling Of Dizziness .

### +Ve Findings In Examination :

- General Examination: Dehydrated , Pale .



## 2) Cushing's Syndrome :

### - Personal History:

Ahmed Hussain Ali , 45 Y/O Saudi Male From Jazan , Single , Teacher , Admitted Through ER On 2-1-1436 H .

### - C/O:

Fatigue , Weakness And Decreased Concentration / 1 Month .

### - HPI:

The Patient Was Admitted To The Hospital For Evaluation Of High Blood Cortisol Level . His Complaints Were Fatigue , Weakness , Lethargy , Decrease Concentration And Decreased Memory Over The Last Month . He Also Gained 12 Kg Over The Last 3 Months , And He Notable For New Onset Acne In His Face And Striae Appear In His Abdomen .

● Systemic Review : -Ve Apart From Polyuria & Joint Pain .

● Hospital Course : Underwent CBC , Blood Sugar , Cortisol Level Test And The Patient Is Improving .

- Past History: -Ve .

- Family History: -Ve Apart From Consanguinity & His Mother Have HTN .

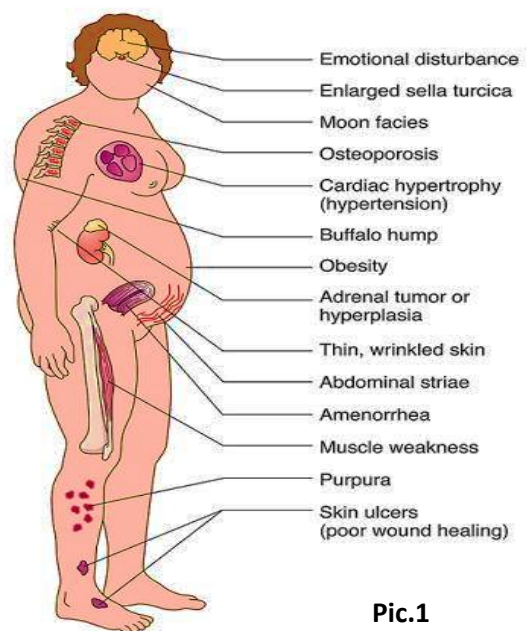
- Social History: Good Living Conditions & Socio-Economic Status .

- Drugs & Allergies: -Ve .

### Summary

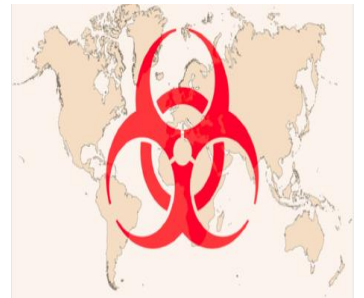30 Y/O Saudi Male Admitted Through ER Complaining Of Fatigue , Weakness And Decreased Concentration For 1 Month . Associated With Weight Gain , Face Acne & Abdominal Striae .

### +Ve Findings In Examination : ( Pic.1 )



**Pic.1**

# **Infectious Diseases**



# History Of Common Cases

## 1) Malaria :

### - Personal History :

Ahmed Hussain Ali , 28 Y/O Saudi Male From Jazan , Single , Teacher , Admitted Through ER On 2-1-1436 H .

### - C/O :

Fever / 6 Hours .

Headache / 2 Hours .

### - HPI :

The Patient Was Well Till 6 Hours Back When He Started To Has Fever Which Was Acute In Onset , Continuous , High Grade ( 41 °C ) , Interfering With Normal Activity . The Attack Started By Feeling Of Cold And Start To Cover Himself By Blankets For 1 Hour , After That He Developed The Fever Which Followed By Sweating , No Aggravating Factors But Relieved By Cold Wet , Associated With Muscle Pain , Fatigue And Headache Which Was Generalized , Aggravated By Light & Loud Noise Relive By Analgesic . There Is No Loss Of Weight , No Skin Rash , No Loss Of Consciousness , No Loss Of Memory , No Abnormal Movement OR Weakness .

● Systemic Review : -Ve .

● Hospital Course : Underwent CBC , Blood Film , I.V Fluids & Anti-Pyretic + Anti-Malarial Medications , And The Patient Is Improving .

- Past History : -Ve .

- Family History : -Ve .

- Social History :

Good Living Conditions & Socio-Economic Status .

+Ve History Of Recent Travelling To Yemen .

- Drugs & Allergies : -Ve .

### Summary

28 Y/O Saudi Male Admitted Through ER Complaining Of High Grade Intermittent Fever / 6 Hours And Generalized Headache /2 Hours .

The Condition Associated With Muscle Pain And Fatigue . There Is +Ve History Of Recent Travelling To Yemen .

### +Ve Findings In Examination :

- General Examination : Looking Ill , Dehydrated , Feverish .

- Abdominal Examination : Splenomegaly .

## 2) Brucellosis :

### - Personal History:

Ahmed Hussain Ali , 45 Y/O Saudi Male From Jazan , Single , Farmer , Admitted Through ER On 2-1-1436 H .

### - C/O:

Fever & Headache / 3 Days .

### - HPI:

The Patient Was Will Till 3 Days Back When He Started To Has Fever Which Was Acute In Onset , Intermittent , High Grade (39 °C) , Interfering With Normal Activity , No Aggravating Factors But Relieved By Cold Wet , Associated With Muscle Pain , Fatigue And Headache Which Was Generalized , Aggravated By Light & Loud Noise Relive By Analgesic . There Is No Loss Of Weight , No Skin Rash , No Rigors , No Sweating , No Loss Of Consciousness , No Loss Of Memory , No Abnormal Movement OR Weakness .

● Systemic Review : -Ve .

● Hospital Course : Underwent CBC , Blood Film , Blood Culture , I.V Fluids & Anti-Pyretic And The Patient Is Improving .

- Past History: -Ve .

- Family History: -Ve .

- Social History:

Good Living Conditions & Socio-Economic Status .

+Ve History There Is Hx Of Animals Contact And Drink Of Raw Milk .

- Drugs & Allergies: -Ve .

### Summary

45 Y/O Saudi Male Admitted Through ER Complaining Of High Grade Intermittent Fever And Generalized Headache / 3 Days . The Condition Associated With Muscle Pain And Fatigue . There Is +Ve History Of Recent Animal Contact And Drink Of Raw Milk .

### +Ve Findings In Examination :

- General Examination: Looking Ill , Feverish , With Lymphadenopathy .

- Abdominal Examination: Hepato-Splenomegaly .

# **DDx Of Common Signs & Symptoms**

## **1- Right Upper Abdominal Pain :**

- Gallstone .
- Ascending Cholangitis .
- Hepatitis .
- Liver Abscess .

## **2- Epigastric Pain :**

- Peptic Ulcer .
- Esophagitis .
- Pancreatitis .
- Myocardial Infarction .

## **3- Left Upper Abdominal Pain :**

- Splenic Abscess .
- Splenic Rupture .
- Myocardial Infarction .

## **4- Right Lumbar Pain :**

- Renal Colic .
- Pyelonephritis .

## **5- Umbilical Pain :**

- Early Appendicitis .
- Mesenteric Adenitis .
- Meckel's Diverticulitis .

## **6- Right Iliac Fossa Pain :**

- Late Appendicitis .
- Crohn's Disease .
- Cecum Obstruction .
- Ovarian Cyst .
- Ectopic Pregnancy .

### 7- Hypogastric Pain :

- Urine Retention .
- Testicular Torsion .
- Cystitis .
- Placental Abruption .

### 8- Left Iliac Fossa Pain :

- Diverticulitis .
- Ulcerative Colitis .
- Ovarian Cyst .
- Colonic Obstruction .

### 9- DDx Of GIT Bleeding :

#### - General Bleeding Causes :

- ✓ Bleeding Disorders ( Hemophilia , Thrombocytopenia ) .
- ✓ Some Drugs ( Anticoagulant Therapy ) .

#### - Upper GI Bleeding Causes :

- ✓ Esophageal Varices .
- ✓ Acute Gastric Erosions Usually Caused By Ingestion Of NSAIDs .
- ✓ Acute Hemorrhagic Gastritis .
- ✓ Chronic Peptic Ulcer .

#### - Lower GI Bleeding Causes :

- ✓ Hemorrhoids .
- ✓ Diverticular Disease .
- ✓ Ulcerative Colitis .
- ✓ Ischemic Colitis .
- ✓ Angiodysplasia .
- ✓ Massive Bleeding From Upper GIT .

## **10-DDx Of Dysphagia :**

- Esophageal Atresia .
- Plummer - Vinson Syndrome .
- Zenker's Diverticulum .
- Benign Strictures .
- Achalasia .
- Diffuse Esophageal Spasm .
- Esophageal Web .
- Esophageal Cancer .

## **11-DDx Of Dyspnea :**

### **Airway Diseases :**

- ✓ COPD .
- ✓ Asthma .
- ✓ Bronchiectasis .
- ✓ Cystic Fibrosis .
- ✓ Laryngeal And Pharyngeal Tumors .
- ✓ Bilateral Cord Palsy .
- ✓ Tracheal Obstruction Or Stenosis .
- ✓ Tracheomalacia .

### **Parenchymal Diseases :**

- ✓ Interstitial Lung Diseases .
- ✓ Diffuse Infection .
- ✓ Acute Respiratory Distress Syndrome .
- ✓ Infiltrative And Metastatic Tumors .
- ✓ Pneumothorax .

### **Pulmonary Circulation Diseases :**

- ✓ Pulmonary Embolism .
- ✓ Pulmonary HTN .
- ✓ Pulmonary Arteriovenous Malformation .

- Chest Wall And Pleural Diseases :

- ✓ Effusion And Massive Ascites .
- ✓ Pleural Tumors .
- ✓ Fractured Rib .
- ✓ Kyphoscoliosis .
- ✓ Neuromuscular Disease .
- ✓ Bilateral Diaphragmatic Disease .

- CVS Causes :

- ✓ Heart Failure .
- ✓ Pericarditis .
- ✓ Pericardial Effusion .
- ✓ MI .
- ✓ Aortic Dissection .
- ✓ Cardiomyopathy .

- Other Causes :

- ✓ Anemia .
- ✓ Metabolic Acidosis .
- ✓ Obesity .
- ✓ Myasthenia Gravis .
- ✓ Pregnancy .

**12-DDx Of Cough :**

- Productive Cough :

- ✓ Pneumonia .
- ✓ TB .
- ✓ COPD .
- ✓ Lung Abscess .
- ✓ Bronchitis .



- **Dry Cough :**
  - ✓ Upper Respiratory Tract Infection .
  - ✓ Asthma .
  - ✓ Smoking .
  - ✓ ACEI Use .

### **13-DDx Of Hemoptysis :**

- Bronchiectasis .
- Bronchogenic Carcinoma .
- Cystic Fibrosis .
- TB .
- Lung Abscess .

### **14-DDx Of Wheeze :**

- Bronchial Asthma .
- Anaphylaxis .
- Bronchiectasis .
- COPD .
- Foreign Body .
- Vocal Cord Dysfunction .
- Cardiac Asthma .

### **15-DDx Of Chest Pain :**

- **Cardiac Causes :**
  - ✓ Angina/ Acute Coronary Syndrome .
  - ✓ Pericarditis .
  - ✓ Aortic Dissection .
  - ✓ Valvular Lesions .
  
- **Pulmonary Causes :**
  - ✓ Pulmonary Embolism .
  - ✓ Pneumonia .
  - ✓ Pneumothorax .

- **GIT Causes :**

- ✓ GERD .
- ✓ Esophageal Spasm .
- ✓ PUD .
- ✓ Esophagitis .
- ✓ Pancreatitis .
- ✓ Cholecystitis .

- **Musculoskeletal Causes :**

- ✓ Trauma .
- ✓ Fractures .
- ✓ Muscle Tear .
- ✓ Costochondritis .
- ✓ Osteomyelitis .
- ✓ Herpes Zoster .

- **Other Causes :**

- ✓ Cardiac Neurosis .

**16-DDx Of Palpitations :**

- Atrial Fibrillation .
- Atrial Flutter .
- Atrial Premature Beat .
- Anxiety .
- Caffeine Use .
- Hyperthyroidism .

**17-DDx Of Seizures :**

- Epilepsy .
- Stroke .
- Metabolic ( Hypoglycemia ) .
- Intracranial Hemorrhage .
- Brain Tumor .
- Hyponatremia .
- Eclampsia .

# **Chapter ( 2 )**

## **" General Surgery "**

### **# Content :**

- **General History Form ..... Page : 95**
- **Breast History & Examination ..... Page : 101**
- **Thyroid History & Examination ..... Page : 111**
- **Hernia History & Examination ..... Page : 123**
- **GIT History & Examination ..... Page : 132**
- **Ulcer History & Examination ..... Page : 143**
- **Specific Signs In Examination ..... Page : 149**
- **DDx Of Common Signs & Symptoms ..... Page : 151**



**General History In**  
**Surgery**

# **General History In Surgery**

## **1- Personal History :**

- ✓ **Name** : For Identification & To Be Familiar With Patient .
- ✓ **Age** : Certain Diseases Are Related To Certain Age Groups .
- ✓ **Sex** : Some Diseases Are More Common In Males / Females .
- ✓ **Nationality** : Certain Diseases Are Related To Certain Countries .
- ✓ **Home & Residence** : Certain Diseases Are Related To Certain Areas .
- ✓ **Occupation** : Some Diseases Are Related To Certain Jobs .
- ✓ **Marital Status** .
- ✓ **Special Habits Of Medical Importance** ( Smoking , Water-Pipe , Alcohol , Drug Abuse , ... Etc. ) .

## **2- Chief Complaint ( C/O ) :**

- ✓ In Patient's Own Words .
- ✓ Write The Duration .
- ✓ Sort Them In Chronological Manner .

**Example** : Right Inguinal Swelling / 1 Month .

**NOTE** : Most Common Complaints In Surgery Are " Pain & Swelling " .

## **3- History Of Presenting Illness ( HPI ) :**

**Pain**

*A- The Patient Is Known Case Of ..... ( Chronic Disease ) .*

*B- The Patient Was Well Till / On Usual Status Till ..... ( Hours - Days - Weeks - Months ) Back When He/She Started To Has ..... ( Complaint ) .*

*C- Analysis Of Complaint :*

- ✓ **Site .**
- ✓ **Onset :**
  - **Sudden :** Vascular Causes .
  - **Acute :** Some Infections , Inflammation Causes .
  - **Gradual :** Some Infections .
- ✓ **Course :**
  - **Progressive :** Increasing With Time .
  - **Regressive :** Decreasing With Time .
  - **Stationary :** No Change .
  - **Intermittent :** Come & Goes With Total Relief Between Attacks , E.g : Abdominal Colic .
- ✓ **Character ( Nature ) :**
  - **Dull-Aching :** Generalized Unspecified Pain , E.g : Peritonitis .
  - **Colicky :** Pain Due To Hollow Organ Obstruction , E.g : Cholecystitis , Appendicitis .
  - **Throbbing :** Pus Under Tension .
  - **Stitching / Tingling :** Due To Neuropathy , E.g : Diabetic Foot .
- ✓ **Radiation :** Feeling Of Pain Along The Course Of The Nerve , E.g : Renal Colic .  
OR Referral : Feeling Of Pain In Areas Supplied By The Same Dermatome , E.g : Biliary Colic .  
OR Shifting : Pain Started In One Area Then Disappear And Felt In Another Area , E.g : Appendicitis .
- ✓ **Aggravating & Relieving Factors :** Things OR Situations That Increase / Decrease The Pain , E.g : Fatty Meal In Cholecystitis .
- ✓ **Associated Symptoms .**
- ✓ **Severity ( Measured By ) :**
  - **Interfering With Daily Activities .**
  - **( 0 – 10 ) Scale .**

***D- Review The Symptoms Of The Affected System :***

**- Example :** In The Case Of Abdominal Pain , You Have To Review Other GIT Symptoms Which Include :  
 Dysphagia , Heartburn , Jaundice , Hematemesis , Constipation , Diarrhea , Melena , Bleeding Per Rectum .

**E- Systemic Review :**

- **CNS :** Headache , Dizziness , Change In Behavior , Loss Of Consciousness , Weakness , Abnormal Movement .
- **GIT :** Dysphagia , Heartburn , Jaundice , Hematemesis , Constipation , Diarrhea , Melena , Bleeding Per Rectum .
- **Cardio-Pulmonary :** Cough , Hemoptysis , Dyspnea , Chest Pain , Palpitations , Syncope , Claudication .
- **Urogenital :** Loin Pain , Dysuria , Polyuria , Hematuria , Urethral Discharge .
- **Skin & Musculoskeletal :** Pain , Muscle Wasting , Pigmentation , Ulcers .

**F- Hospital Course :**

- **Investigations .**
- **Medications & Interventions .**
- **Improving OR Not .**

## Swelling

**A- The Patient Is Known Case Of..... ( Chronic Disease ) .**

**B- The Patient Was Well Till / On Usual Status Till ..... ( Hours - Days - Weeks - Months ) Back When He/She Started To Has ..... ( Complaint ) .**

**C- Analysis Of Complaint :**

✓ **Site .**

✓ **Number & Size .**

✓ **Shape :**

- **Lemon .**
- **Orange .**
- **Pear .**

✓ **Onset :**

- **Accidental :** E.g : Breast Swellings .
- **Acute :** E.g : Acute Inflammation .
- **Sudden :** E.g : Perforation .
- **Gradual Onset :** E.g : Chronic Inflammation OR Neoplastic Swellings .

✓ **Course :**

- **Progressive :** Neoplastic Swellings .
- **Regressive :** Inflammatory Conditions .
- **Stationary :** Chronic Inflammation .
- **Fluctuating :** Chronic Inflammation With Acute Exacerbation .

✓ **Duration :**

- **Short ( Days - Weeks ) :** Inflammatory .
- **Long ( Months - Years ) :** Neoplastic .
- **Since Birth :** Congenital .

**Notes On Lumps :**

- Short Duration + Pain : Acute Inflammatory .
- Short Duration + No Pain : Benign Tumor.
- Long Duration ± Slight Pain : Malignant Tumor.

✓ **When , How & Who Notice .**

✓ **Apparent Cause :** Trauma , Lifting Heavy Weight , Emotional Stress , Chronic Disease .

✓ **What Increases / What Decreases It ?**

✓ **Other Swellings .**

✓ **Associated Symptoms .**

✓ **Effects On The General Condition :**

- **Constitutional Symptoms :** Fever - Loss Of Appetite - Loss Of Weight .
- **Metastatic Symptoms :** Back pain - Dyspnea & Hemoptysis - RUQ Pain & Jaundice - Convulsions .
- **Toxic Symptoms :** According To Situation ( E.g : Hyperthyroidism / Hypothyroidism ) .

**D- Review The Symptoms Of The Affected System :**

**E- Systemic Review :**

- **CNS :** Headache , Dizziness , Change In Behavior , Loss Of Consciousness , Weakness , Abnormal Movement .
- **GIT :** Dysphagia , Heartburn , Jaundice , Hematemesis , Constipation , Diarrhea , Melena , Bleeding Per Rectum .
- **Cardio-Pulmonary :** Cough , Hemoptysis , Dyspnea , Chest Pain , Palpitations , Syncope , Claudication .
- **Urogenital :** Loin Pain , Dysuria , Polyuria , Hematuria , Urethral Discharge .
- **Skin & Musculoskeletal :** Pain , Muscle Wasting , Pigmentation , Ulcers .

**F- Hospital Course :**

- **Investigations .**
- **Medications & Interventions .**
- **Improving OR Not .**



#### **4- Past History :**

- Chronic Diseases ( HTN , DM , Asthma , TB , Hepatitis ) : When , Where & How Diagnosed ?
- Similar Conditions .
- Previous Hospital Admissions .
- Previous Operations : You Can Exclude ( Like Appendectomy , Cholecystectomy ) OR Suspect ( Like Adhesions ) .
- Previous Blood Transfusion .

#### **5- Drugs & Allergies History .**

- Long Term Medications .
- Short Term Medications .
- Allergy To Certain Food OR Medication .

#### **6- Family History :**

- Chronic Diseases ( HTN , DM , Asthma , TB , Hepatitis ) .
- Similar Conditions .
- Inherited / Genetic Diseases :
- Consanguinity .

#### **7- Social History :**

- Type Of House
- Income / Social Status
- Travelling History : Infectious Diseases , Endemic Diseases .

#### **8- Obstetric & Gynecological History :**

- Age Of Menarche , Regularity , Character ( Heavy OR Not ) , Duration , Volume .
- Age Of Menopause .
- Use Of Contraception Methods .
- Duration Of Delivery , Mode Of Delivery Of Each One & Complicated OR Not .

**" Summary "**



**Breast History &**  
**Examination**

# **Breast History & Examination**

## **1) History Sheet For Breast Swelling :**

- **Personal History :**
- **Chief Complaint ( C/O ) :**    " Breast Swelling / Duration "
- **History Of Presenting Illness :**
  - **Chronic Diseases :**
  - **The Patient Was Well Till / On Usual Status Till ....**
  - **Analysis Of Complaint :**
    - Number :**
    - Site :**
    - Size :**
    - Onset :**
    - Course :**
    - When & How Noticed :**
    - Apparent Cause :** ( Trauma - Pregnancy - Lactation - No Apparent Cause ) .
    - What Increase / Decrease It :**
    - Other Swellings :**
    - Associated With :** ( Pain - Redness - Skin Changes - Nipple Changes & Discharge ) .
  - **Constitutional Symptoms :** ( Fever - Loss Of Weight - Loss Of Appetite ) .
  - **Metastatic Symptoms :** ( Back pain - Dyspnea & Hemoptysis - RUQ Pain & Jaundice – Convulsions ) .
  - **Risk Factors Of Breast Cancer :**
    - Age Of Menarche .
    - Age Of Menopause .
    - Menstruation .
    - Married At Age :
    - Number Of Offsprings .
    - Age Of 1<sup>st</sup> Pregnancy .
    - Breastfed Her Children ?
    - Use Contraceptive Method ?
    - Hormonal Therapy ?
    - Family History Of Breast Cancer .

- Hospital Course :
- Systemic Review :

- Past History :

- Drugs & Allergies :

- Family History :

- Social History :

- Obstetric & Gynecological History :

## " Summary "

### \*\* Note :

- Nipple Discharge :

- ✓ **Character :** Serous - Bloody - Milky - Pus .
- ✓ **Color :** White - Red - Yellow - Green - Blue .
- ✓ **Amount .**
- ✓ **Smell .**

## 2) History Sheet For Breast Pain :

- Personal History :

- Chief Complaint ( C/O ) :     "Breast Pain / Duration"

- History Of Presenting Illness :

● **Chronic Diseases :**

● **The Patient Was Well Till / On Usual Status Till ....**

● **Analysis Of Complaint :**

Site :

Onset :

Course :

Duration :

Character :

Aggravating & Relieving Factors :

Radiation :

Associated Symptoms :

Severity :

● **Constitutional Symptoms :** ( Fever - Loss Of Weight - Loss Of Appetite ) .

● **Risk Factors Of Breast Cancer :**

- Age Of Menarche .

- Number Of Offsprings .

- Age Of Menopause .

- Age Of 1<sup>st</sup> Pregnancy .

- Hormonal Therapy ?

- Menstruation .

- Breastfed Her Children ?

- Family History Of Breast Cancer .

- Married At Age :

- Use Contraceptive Method ?

● **Hospital Course :**

● **Systemic Review :**

- Past History :
  
- Drugs & Allergies :
  
- Family History :
  
- Social History :
  
- Obstetric & Gynecological History :

**" Summary "**

**\*\* Note :**

**- Painful Breast Lesions :**

- ✓ Mastitis .
- ✓ Breast Abscess .
- ✓ Fibroadenosis .
- ✓ Malignancy .

### 3) Common Case " Breast Cancer As An Example " :

- **Personal History:**

Salma Mohammed Ahmed , 42 Years Old Saudi Female From Riyadh Married And Has 3 Offsprings , She Is A Teacher , With No Habits Of Medical Importance .

- **C/O:**

Left Breast Swelling / 3 Month .

- **HPI:**

She Was Well Till 3 Month Back When She Accidentally Noticed A Swelling In Her Left Breast . The Swelling Is Single In The Left Upper Quadrant , Discovered During Changing Her Clothes , Lemon-Size , Progressive , Painless , With Skin Changes Over It , Not Related To Cycle , With No Other Swelling In The Body . She Is Also Noticed A Swelling In The Left Axilla Which Is Not Related To Any History Of Inflammation .

● Constitutional Symptoms : (+Ve) Loss Of Appetite , (+Ve) Loss Of Weight .

● Metastatic Symptoms : -Ve .

● Risk Factors : Early Menarche , Late 1<sup>st</sup> Pregnancy .

● Hospital Course : Underwent Mammography , US , CBC .

● In Her Systemic Review : -Ve .

- **Past History:** -Ve .

- **Drugs & Allergies:** -Ve .

- **Family History:**

+Ve History Of Similar Condition : Her Sister Died From Breast Cancer 5 Years Back After Mastectomy .

No History Of Hereditary & Chronic Diseases .

+Ve Consanguinity.

- **Social History:**

Living In Modern House / 2 Floors .

Educated & Satisfactory Income .

No History Of Recent Travelling .

- **Obs/Gynae History:**

Her Menarche Started At Age Of 11 , Regular , 7/28 , Normal Amount .

All Deliveries Were Full Term , Spontaneous Vaginal With No Complications .

#### **Summary**

42 Y/O Saudi Female With 1 Month Breast Swelling In Upper Outer Quadrant Of Her Left Breast , Progressive , Associated With Left Axillary Swelling , Loss Of Appetite & Weight . Her Menarche Started Early & Has A Late 1<sup>st</sup> Pregnancy , Her Sister Died From Breast Cancer 5 Years Back .

## 4) Local Examination Of The Breast :

- Introduce Yourself .
- Take Permission .
- Explain What You Are Going To Do .
- Maintain Privacy .
- Wash Your Hand .
- Exposure ( Up To The Waist ) .

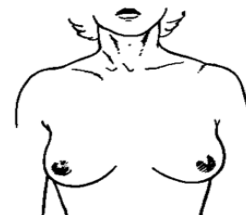### Inspection

- Inspection Of Both Breasts :

#### 1- With Hands Down : ( Pic .1 )

##### # Benefits Of This Position :

- Symmetry Of Both Breasts .
- Comparing The Level Of Nipples .

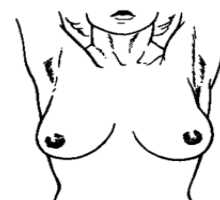

Pic .1

#### 2- With Arms Over The Head : ( Pic .2 )

##### # Benefits Of This Position :

- Skin Changes Related To Cancer Is More Prominent .
- Give Access To Both Axillae .
- Access Undersurface Of Breast .



Pic .2

#### 3- With Pending Forward :

##### # Benefit Of This Position :

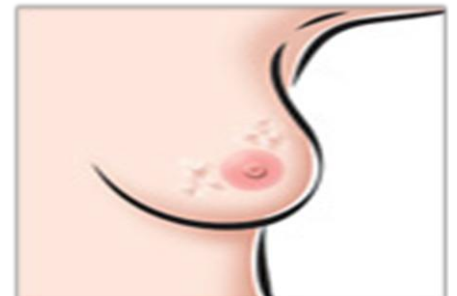- To Detect Breast Lagging In Cancer .



- **Inspection Of Affected Breast :**

### 1- Nipple & Areola :

- **Nipple Displacement** : Movement Of Nipple In Relation To The Horizontal Line Between 2 Nipples ( Up / Down ) .
- **Nipple Deviation** : Movement Of Nipple In Relation To The Mass ( Toward / Away ) .
- **Nipple Retraction** .
- **Nipple Discharge** : Ask The Patient To Squeeze The Breast If There Is Any Discharge .
- **Nipple & Areola Ulcers , Erosion** .



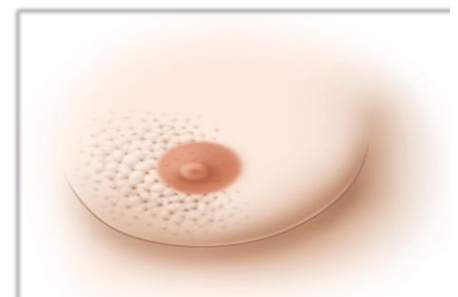**Pic .1**

### 2- Skin

- Signs Of Inflammation ( Redness - Shines - Edema ) .
- Dilated Veins ( Indicates Sarcoma ) , Dimpling ( Pic .1 ) , Puckering , Pseudo'range ( Pic .2 ) .

**# N.B :** If There Is Visible Mass → Describe It ( N + 7 S ) :

- ✓ **Number** .
- ✓ **Site** .
- ✓ **Size** : Better In Centimeters .
- ✓ **Shape** : Irregular - Oval - Rounded .
- ✓ **Skin Overlying** : Dilated Veins - Pseudo'range - Dimpling - Puckering .
- ✓ **Surrounding** : Enlarged Lymph Nodes .
- ✓ **Special Character** .



**Pic .2**

### 3- Arms

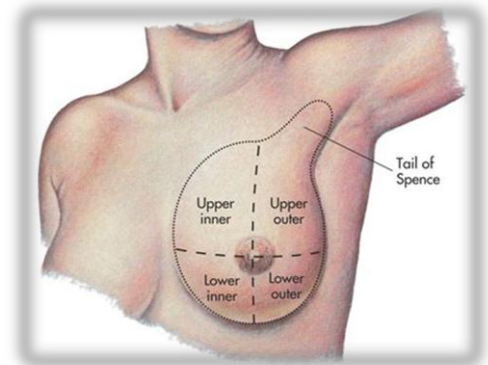
- For Edema .

### \*\* Note :

- Dimpling Occurs Due To Involvement & Retraction Of Cooper's Ligaments .

# Palpation

- Position → Sitting Then Lying Down .
- 7 Compartment : ( Pic .1 )
  - ✓ 4 Compartments In Breast : ( Upper Inner - Upper Outer - Lower Inner - Lower Outer ) .
  - ✓ Nipple And Areola .
  - ✓ Axillary Tail .
  - ✓ Infra-Mammary .



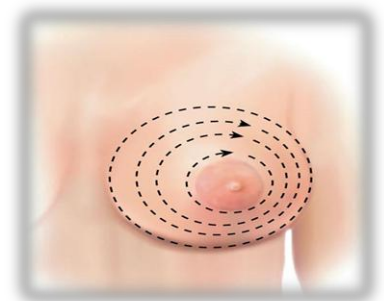Pic .1

## \*\* Superficial Palpation :

- For :
  - ✓ Hotness .
  - ✓ Tenderness
    - Inflammatory Is Tender .
    - Neoplastic Is Not Tender .

## \*\* Deep Palpation :

- Palpate The Normal Breast First .
- Systemic Pattern With Palmar Surface Of Finger + Rolling . ( Pic .2 )
- If There Is A Mass → Examine The Mass :



Pic .2

- ✓ Number .
- ✓ Site .
- ✓ Size .
- ✓ Shape : Irregular - Oval - Rounded .
- ✓ Surface : Smooth - Rough .
- ✓ Mobility : Free Mobile - Mobile - Immobile .
- ✓ Edge : Well-Defined - ill-Defined .
- ✓ Consistency : ( Cystic - Soft - Hard ) By :
  - Fluctuation Test → In 2 Perpendicular Planes .
  - Paget's Test → For Swelling < 2 cm .

## **\*\* Attachment Of The Mass :**

### **1- To Skin :**

- **Not Related To Overlying Skin :** Skin Can Be Pinched .
- **Infiltrate The Skin :** Moves With Movement Of Skin .

### **2- To Breast Tissue :**

- **Fix The Breast Tissues By One Hand And Move The Mass By Another Hand .**

### **3- To Muscles :**

- **To Pectoralis Major :** Try To Move The Mass While Pushing Against The Waist .
- **To Serratus Anterior :** Try To Move The Mass While Pushing Against The Wall .

### **4- To Chest Wall :**

- **The Mass Is Fixed And Immobile From The Start ( While The Patient Is Relaxed ) .**

## **\*\* The Draining LNs :**

- Axillary LNs .
- Supraclavicular LNs .



**Thyroid History &**  
**Examination**

# **Thyroid History & Examination**

## **1) History Sheet For Thyroid Swelling :**

- **Personal History :**
- **Chief Complaint ( C/O ) :** " ( Painful ) Swelling In Lower Part In Front Of Neck / Duration "
- **History Of Presenting Illness :**
  - Chronic Diseases :
  - The Patient Was Well Till / On Usual Status Till ....
  - Analysis Of Complaint :

**( Swelling ) :**

- Number :
- Site :
- Size :
- Onset :
- Course :
- When & How Noticed :
- Apparent Cause : ( Trauma - Pregnancy - Lactation - Emotional Stress - No Apparent Cause ) .
- What Increase / Decrease It :
- Other Swellings :

**(Pain):**

- Site :
- Onset :
- Course :
- Duration :
- Character :
- Aggravating & Relieving Factors :
- Radiation :
- Associated Symptoms :
- Severity :

● **Pressure Manifestations :**

- Dysphagia :
- Dyspnea :
- Puffiness Of Face :
- Fainting :
- Change In Voice :
- Ear Pain :

● **Toxic Manifestations ( For Hyperthyroidism ) :**

- **CNS** : Insomnia - Night Mares - Irritability .
- **Cardiac** : Palpitations .
- **Metabolic** : Heat Intolerance - Change In Appetite .
- **Eye** : Exophthalmos - Diplopia .
- **Genital** : Female Menorrhagia Then Amenorrhea - Male Impotence .
- **GIT** : Diarrhea .
- **Urinary** : Polyuria .
- **Skin** : Sweating .

● **Toxic Manifestations ( For Hypothyroidism ) :**

- Slow Thinking .
- Apathy .
- Tendency To Sleep .
- Loss Of Appetite .
- Increase Body Weight .
- Oligomenorrhea .
- Constipation .
- Cold-Intolerance .

● **Metastatic Manifestations :**

- Bone Pain :
- Dyspnea - Hemoptysis :
- RUQ Pain - Jaundice :
- LNs Enlargement :

- Hospital Course :
- Systemic Review :

- Past History :

- Drugs & Allergies :

- Family History :

- Social History :

- Obstetric & Gynecological History :

**" Summary "**

## 2) Common Case " Hyperthyroidism As An Example " :

### - Personal History:

Salma Mohammed Ahmed , 29 Years Old Saudi Female From Riyadh Married And Has 2 Offsprings , She Is A Housewife , With No Habits Of Medical Importance .

### - C/O:

Painful Swelling In The Lower Part In Front Of The Neck / 3 Month .

### - HPI:

She Was Well Till 3 Month Back When She Started To Has A Painful Swelling In The Lower Part In Front Of The Neck . The Swelling Is Single , Noticed By Her Mother 3 Month Back , Butter-Fly In Shape , Progressive , With No Apparent Cause And No Other Swelling In The Body . This Swelling Is Associated With Pain Which Started During This Month , Dull-Aching , Not Radiated & No Aggravating Or Relieving Factors .

● Pressure Manifestation : (+Ve) Dysphagia , Dyspnea .

● Toxic Manifestation : (+Ve) Loss Of Weight , Increase Appetite , Palpitation , Sweating , Heat Intolerance .

● Metastatic Manifestation : -Ve .

● Hospital Course : Underwent CBC , US Of The Neck , CXR .

● In Her Systemic Review :

- CNS : No Headache , No Change In Behavior , No Loss Of Consciousness , No Weakness .

- GIT : (+Ve Diarrhea) , No Nausea , No Vomiting , No Abdominal Pain , No Jaundice .

- Cardio-Pulmonary : (+Ve Dyspnea , Palpitation) , No Cough , No Hemoptysis , No Chest Pain , No Syncope , No Claudication .

- Urogenital : (+Ve Polyuria) , No Loin Pain , No Dysuria , No Hematuria .

- Musculoskeletal : No Pain , No Muscle Wasting .

- Past History: -Ve .

- Drugs & Allergies: -Ve .

- Family History:

+Ve History Of Similar Condition : Her Sister Diagnosed As Hyperthyroidism 2 Years Back .

No History Of Hereditary & Chronic Diseases .

+Ve Consanguinity.

- Social History:

Living In Modern House / 2 Floors .

Educated & Satisfactory Income .

No History Of Recent Travelling .

- Obs/Gynae History:

Her Menarche Started At Age Of 11 , Regular , 7/28 , Normal Amount .

All Deliveries Were Full Term , Spontaneous Vaginal With No Complications .

### Summary

29 Y/O Saudi Female With 3 Months Painful Neck Swelling , Progressive , Butter-Fly , Associated With Loss Of Weight In Spite Of Increase The Appetite , Palpitation , Sweating & Heat Intolerance . Her Sister Diagnosed As Hyperthyroidism 2 Years Back .



## 3) Thyroid Examination :

### A) Important Findings In General Examination :

- **Body Built :**
  - ✓ **Underweight :** Hyperthyroidism / Malignancy .
  - ✓ **Overweight :** Hypothyroidism .
  
- **Decubitus :**
  - ✓ **Orthopenic :** Thyrotoxic HF.
  
- **Facial Expressions :**
  - ✓ **Irritable :** Thyrotoxicosis .
  - ✓ **Lazy :** Myxoedema .
  
- **Complexion ( 3 Colors ) :**
  - ✓ **Jaundice :** Anti-Thyroid Drugs / Liver Metastasis In Carcinoma .
  - ✓ **Pallor :** Thyroid Dysfunction ( Hypo / Hyper ) / Malignancy .
  - ✓ **Cyanosis :** Retrosternal Goiter ( RSG ) / Thyrotoxic HF.
  
- **Abdomen :**
  - ✓ **Hepatomegaly :** Grave's / Hashimoto .
  
- **Extremities :**
  - ✓ **Tremors - Skin - Temperature - Sweating - Clubbing .**
  - ✓ **Lower Limb :** State Of Muscles - Edema - Pretibial Myxedema .
  
- **Pulse :**
  - ✓ **Tachycardia + Large Volume + Collapsing :** Hyperthyroidism .
  - ✓ **Bradycardia :** Hypothyroidism .
  
- **Blood Pressure & Temperature :**
  - ✓ **High :** Hyperthyroidism .
  - ✓ **Low :** Hypothyroidism .

- **Head :**

- ✓ Loss Of Hair : Hyperthyroidism .
- ✓ Loss Of Hair In The Outer Part Of Eye Brow : Myxedema .

- **Eye :**

# Examination Of Exophthalmos ( To Show True Or False ) :

1) From The Front Of The Patient : ( Pic .1 )

- ✓ Rim Of Sclera Above And Below The Cornea → True Exophthalmos .

2) Frazer's Test :

- ✓ To See The Obliteration Of Sulcus Of Orbital Margin With Slight Closed Eye .

3) Naffziger Test : ( Pic .2 )

- ✓ To See The Level Of Supra And Infra Orbital Ridge With Cornea .

4) Ruler Test : ( Pic .3 )

- ✓ To See The Level Of Supra And Infra Orbital Margin With Cornea By A Ruler .

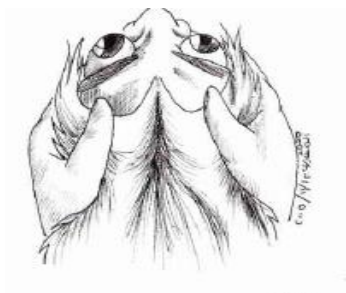5) Ruler :

- ✓ To Measure Distance Between Lateral Orbital Margin And Apex Of Cornea ( Normally = 15-17 mm ) .

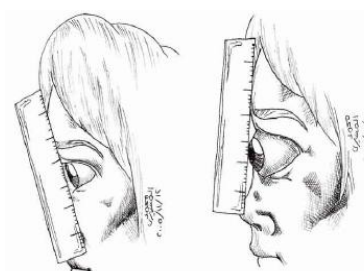
6) Exophthalmometer.



Pic .1



Pic .2

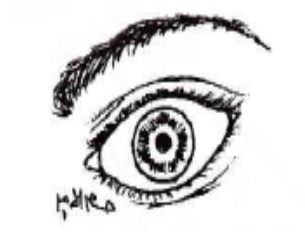


Pic .3

## # Examination Of Eye Signs :

### 1) Dalrymple Sign : ( Pic .1 )

- ✓ Rim Of Sclera Between Cornea And Upper Eyelid .



Pic .1

### 2) Stellwag's Sign :

- ✓ Infrequent Blinking .

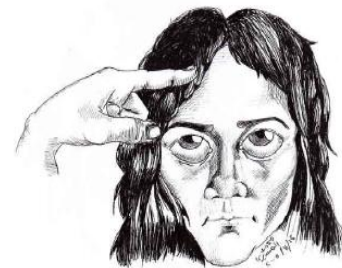### 3) Joffroy's Sign : ( Pic .2 )

- ✓ Lack Of Wrinkling Of Forehead On Looking Upwards .

## # Examination Of Eye Movements :

### 1) Mobius Sign : ( Pic .3 )

- ✓ Failure Of Convergence .



Pic .2

### 2) Von Graefe's Sign : ( Pic .4 )

- ✓ Lid Lag .

### 3) Rosenbach's Sign :

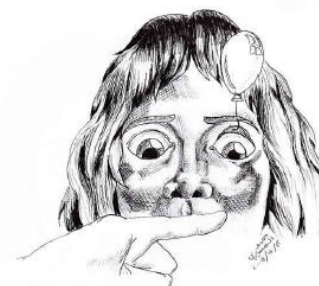- ✓ Fine Tremors Of The Upper Eyelid When Eyes Are Gently Closed .

### 4) Jellinek's Sign :

- ✓ Brownish Pigmentation Of The Eyelid, Especially In Upper Led .



Pic .3



Pic .4

## **B) Local Examination Of Thyroid Gland :**

- Introduce Yourself .
- Take Permission .
- Explain What You Are Going To Do .
- Maintain Privacy .
- Wash Your Hand .
- Exposure ( Up To The Nipple Line ) .
- Position ( Sitting Position ) .

### **Inspection**

- From 2 Different Planes ( From Front And Sides With The Patient Sitting ) .
- Patient Should Drink Water To See Thyroid Movement .

#### **1- Skin :**

- ✓ Normal / Stretches / Pigmented .
- ✓ Any Signs Of Inflammation ( Redness / Edematous ) .
- ✓ Dilated Veins Crossing The Manubrium ( Retrosternal Goiter ) .
- ✓ Scar Of Previous Operation ( Recurrent Goiter ) .

#### **2- Swelling :**

- ✓ **Number** .
- ✓ **Site** .
- ✓ **Size** : Better In Centimeters .
- ✓ **Shape** : Irregular - Oval - Butterfly .
- ✓ **Skin Overlying** .
- ✓ **Surrounding** : Enlarged Lymph Nodes .
- ✓ **Special Character** :
  - Move With Swallowing : Thyroid - Sub-hyoid Bursitis - Pre/Para Tracheal LNs .
  - Move With Protrusion Of Tongue : Thyroglossal Cyst .

# Palpation

## # Examination Of Lobes : ( Pic.1 )

- Better To Stand **Behind** The Patient .
- Ask About Presence Of Pain .
- Push Thyroid To One Side By Hand Then Examine By Other , With The Neck Fixed .
- Place The Thumbs Upon The Nape Of The Patient .
- The Other Finger Tips Meeting At The Midline Anteriorly .
- Start By Palpating One Lobe At A Time .
- Always Tilt The Head **To The Side You Palpate** To Relax The Fascia For Better Palpation .
- Palpate The Swelling As Usual .

## # Examination Of The Lower Border : ( Pic.2 )

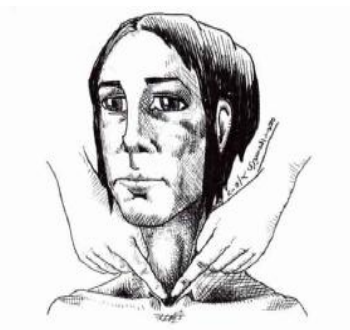- By The Tips Of 2 Index Fingers .

## # Examination Of Isthmus : ( Pic.3 )

- Stand **Behind** The Patient .
- Put One Of Your Hands On The Head Of The Patient .
- Tilt The Head Of The Patient Forward .
- Put The Index Of Other Hand On The Midline Of The Trachea And Palpate .
- Ask The Patient To Swallow .



Pic .1



Pic .2

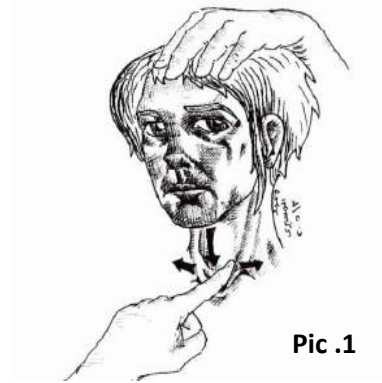

Pic .3

## # Examination Of The Swelling:

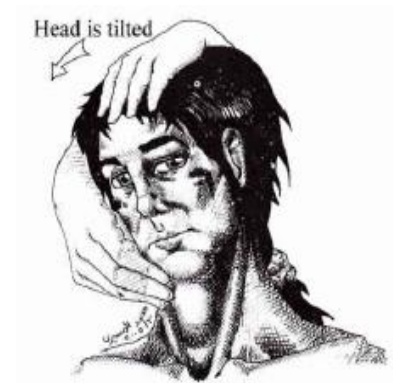### \*\* Superficial Palpation :

- For :
  - ✓ Hotness .
  - ✓ Tenderness { Inflammatory Is Tender .  
Neoplastic Is Not Tender .



### \*\* Deep Palpation :

- ✓ Number .
- ✓ Site .
- ✓ Size .
- ✓ Shape : Irregular - Oval - Rounded .
- ✓ Surface : Smooth - Nodular .
- ✓ Edge : Well-Defined - ill-Defined .
- ✓ Consistency : Cystic - Soft - Firm - Hard .
- ✓ Mobility : Mobile - Fixed :



### **N.B:** Fixation Of Swelling :

- To Skin → Pinch The Skin Over The Swelling .
- To Sternomastoid :
  - ✓ Turn The Head To The Tested Side , Pinch The Muscle From The Swelling And Ask Patient To Swallow .
  - ✓ If You Pinch The Muscle Freely And Not Moved With Swallowing → Not Fixed .

## # Examination Of The Trachea : ( Pic .1 )

- Position ( Central / Deviated ) .
- Important In Anesthesia As The Tube May Injure The Trachea .

## # Examination Of The Carotid Pulse : ( Pic .2 )

- Site And Volume ( Felt Against Carotid Tubercles On The Transverse Spine Of 6th Cervical Vertebra ) .

## # Examination Of The LNs :

- No Examination Is Complete Without Examining The Draining LNs .
- Upper And Lower Deep Cervical , Pre-Laryngeal , Pre-Tracheal LNs .

## # Special Test & Sign:

### - Kocker's Test :

- ✓ Slight Compression On Lateral Lobes Produce Stridor So May Be Tracheo-Malacia .

### - Pemberton's Sign :

- ✓ Reversible S.V.C Obstruction Produced By Retrosternal Goiter Obstructing The Thoracic Inlet .
- ✓ Technique : Patient Elevates The Arm Above The Level Of The Head If Nothing Happened After 3 Minutes Test Is Considered Negative . It's Considered Positive When Facial Plethora ( Blue Or Pink Effusion Of The Neck And/Or Face Due To Venous Obstruction ) .

## Percussion

- Direct On The Manubrium ( For Retrosternal Goiter ) .

## Auscultation

- Over The Apex Of The Lateral Lobes For Machinery Bruit ( In Thyrotoxicosis ) .
- Over Carotid Artery For Bruit ( In Aneurism OR Stenosis ) .



**Hernia History &**  
**Examination**



# Hernia History & Examination

## 1) History Sheet For Hernia :

- Personal History :
- Chief Complaint ( C/O ) : " ( Painful ) Rt/Lt Groin - Umbilical - Abdominal Swelling / Duration "
- History Of Presenting Illness :
  - Chronic Diseases :
  - The Patient Was Well Till / On Usual Status Till ....
  - Analysis Of Complaint :

( Swelling ) :

- Number :
- Site :
- Size :
- Shape :
- Onset :
- Course :
- When & How Noticed :
- Reducible OR Not :
- Apparent Cause : ( Trauma - Lifting Heavy Object - Cough - No Apparent Cause ) .
- What Increase / Decrease It :
- Other Swellings :

(Pain):

- Site :
- Onset :
- Course :
- Duration :
- Character :
- Aggravating & Relieving Factors :
- Radiation :
- Associated Symptoms : ( Vomiting - Constipation - Abdominal Distention - Fever - Dysuria - Cough ) .
- Severity :

- **Hospital Course :**

- **Systemic Review :**

**N.B:** **Complications Of Hernia :**

- **Irreducibility :** Was Reducible Then Become Irreducible , Or Any Irreducibility In The Past .
- **Obstruction :** Abdominal Pain , Distention , Constipation And Vomiting .
- **Strangulation :** Become Irreducible , Tender And Painful .

- **Past History :**

- **Drugs & Allergies :**

- **Family History :**

- **Social History :**

- **Obs/Gynae History :**

**" Summary "**

## 2) Common Case " Inguinal Hernia As An Example " :

### - Personal History:

Ahmed Ali Nasser , 33 Years Old Saudi Male From Jeddah , Married And Have 2 Offsprings . He Is A Policeman , He Is A Heavy Smoker ( 3 Buckets \ Day ) .

### - C/O:

Painful Right Groin Swelling Descend To Scrotum / 4 Days .

### - HPI:

The Condition Was Started Before 4 Months As Painless Solitary Lump In Right Groin . Discovered Accidentally After Lifting A Heavy Object , Increase In Size By Time , The Swelling Was Reducible By Hand And By Lying On His Back And Increases In Size When He Cough Or Walk . Since 4 Days . The Swelling Became Painful , Irreducible . The Pain Was Severe Intermittent Colicky In Nature , Progressive In Course At Site Of Swelling , Aggravated By Movement And Not Radiated Or Referred To Other Area . Associated With Fever , Vomiting ( 4 Time \ Day Yellow Color , Not Related To Meal ) . Constipation . Abdominal Distention And Loss Of Appetite , No Dysphagia , No Odynophagia , No Heart Burn , No Diarrhea , No Bleeding Per Rectum .

● Hospital Course : Underwent CBC , AXR .

● In Systemic Review : -Ve .

### - Past History: -Ve .

### - Drugs & Allergies: -Ve .

### - Family History: -Ve .

### - Social History:

Living In Modern House / 2 Floors .

Educated & Satisfactory Income .

No History Of Recent Travelling .

### Summary

33 Y/O Saudi Male With 4 Days Painful Rt. Groin Swelling , Appear After Lifting A Heavy Object , Descend To Scrotum , Reducible , With Intermittent Colicky Pain . He Is A Heavy Smoker .

### **3) Local Examination Of Hernia :**

#### **A) Groin Hernia Examination :**

- Introduce Yourself .
- Take Permission .
- Explain What You Are Going To Do .
- Maintain Privacy .
- Wash Your Hand .
- Exposure ( From The Nipple Line Up To Mid-Thigh ) .
- Position ( Standing Position ) , Why : Because The Standing Position Allows The Hernia Content To Fill The Hernia Sac And Make The Hernia Obvious On Examination .

### **Inspection**

- ✓ Number .
- ✓ Site .
- ✓ Size : Better In Centimeters .
- ✓ Shape : Irregular - Oval - Rounded , Pear .
- ✓ Skin Overlying .
- ✓ Extension To Scrotum .
- ✓ Expansile With Cough .

# Palpation

- Ask About Presence Of Pain .

## # Feel From Front :

- Examine The Scrotum , Decide If It's Scrotal Or Not By Examining The Upper Limit Of The Swelling :
  - ✓ If You Can Get Above It, Then It Is Scrotal Swelling
  - ✓ If You Can't Feel The Upper Limit Of The Swelling , Then It Is Inguino-Scrotal Swelling.

## # Feel From The Side :

- Stand At The Same Side Of The Hernia .
- Place One Hand On The Back Of Patient To Support Him And Your Examining Hand Over The Swelling .

### Comment On Swelling :

- ✓ **Site .**
- ✓ **Size .**
- ✓ **Shape :** Irregular - Oval - Rounded - Pear .
- ✓ **Surface :** Smooth - Lobulated .
- ✓ **Edge :** Well-Defined - ill-Defined .
- ✓ **Consistency :** Doughy - Soft - Hard .
- ✓ **Pulsility .**
- ✓ **Expansile With Cough :**
  - Ask Patient To Turn His /Her Head Away From You And Cough And Feel The Cough Impulse With Your Hand Over The Swelling .
- ✓ **Reducibility :**
  - Ask Patient To Reduce Hernia By Himself ( He Knows Better Than You 😊 ) .

## # Special Tests :

### 1- Internal Ring Test : ( Pic .1 )

- The Patient Lying Down , Reduce The Hernia , Then Put Your Finger Over The Internal Ring Which Lies 1/2 Inch Above Mid-Point Of Inguinal Ligament .
- Ask Patient To Cough Then Repeat While Standing
- **The Result :**
  - ✓ An Indirect Inguinal Hernia Does Not Protrude Except After Removal Of The Finger .
  - ✓ Indirect Hernia Will Slide Obliquely Along The Line Of Inguinal Canal Whereas Direct Hernia Will Project Directly Forward .

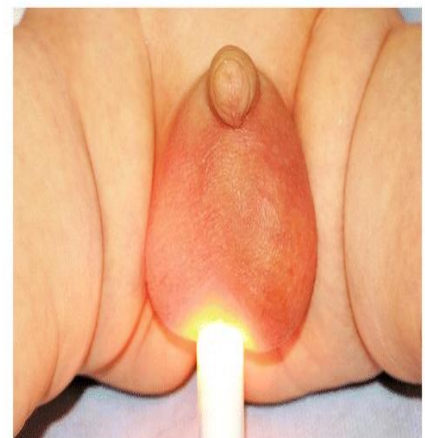
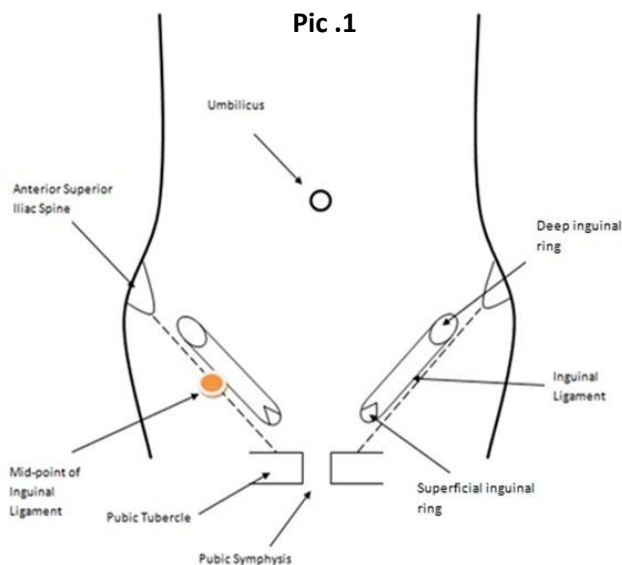
**N.B :** Remove Your Hand And Watch The Hernia Reappear ( Ask Patient To Cough , The Hernia Will Reappear ) .

### 2- External Ring Test :

- It Is Prohibited , Because It Is Painful .

### 3- Transillumination Test : ( Pic .2 )

- By Holding A Light Behind The Scrotum , Can Easily Determine Whether The Mass Is Cystic OR Solid .
- Cystic = Light Shines Through / Solid = Light Blocked By The Mass .



## Percussion

- **If The Hernia Sac Contain Bowel** : The Percussion Will Be Resonant .
- **If The Hernia Sac Contain Omentum** : The Percussion Will Be Dull .

## Auscultation

- **If The Hernia Contain Bowel** : You Will Hear The Bowel Sounds .

### N.B :

- Feel The Other Side .
- Ask Patient To Cough For Presence Of Any Cough Impulse .
- Feel The Scrotal Content Of Each Side .
- Examine Testis , Epididymis And Spermatic Cord For Any Pathology .

### # Clinical Notes :

- Above And Medial To Pubic Tubercle → Inguinal Hernia .
- Below And Lateral To Pubic Tubercle → Femoral Hernia .

## **B) Other Abdominal Wall Hernia Examination :**

- Patient Is Lying On Bed .
- Similar To The Examination Of The Inguinal Hernia .

### **N.B : Characteristic Feature Of Hernia :**

- Site : At Weak Point In The Abdominal Wall
- Reducibility
- Cough Impulse

### **\*\* Note :**

- General Look .
- Vital Sing ( Important In Obstructed And Strangulated Hernia ) .
- **Chest Examination :**
  - ✓ Helps In Demonstrating The Potential Risk Factor For The Cause And Recurrence Of The Hernia , In Addition To Ensure The Patient Fitness For Surgery .
- **Abdominal Examination With PR Examination :**
  - ✓ Do Complete Abdominal Examination And Look For Other Abdominal Hernias , Ascites And Large Intra-Abdominal Swelling .
  - ✓ Enlarged Prostate ( PR Examination ) .





**GIT History &**  
**Examination**

# GIT History & Examination

## 1) History Sheet For GIT :

- Personal History :
- Chief Complaint ( C/O ) : " Abdominal Pain OR Yellowish Discoloration Of Eyes / Duration "
- History Of Presenting Illness :
  - Chronic Diseases :
  - The Patient Was Well Till / On Usual Status Till ....
  - Analysis Of Complaint :

### (Pain):

- Site :
- Onset :
- Course :
- Duration :
- Character :
- Aggravating & Relieving Factors :
- Radiation :
- Associated Symptoms :
- Severity :

### (Yellowish Discoloration Of Eyes):

- Onset :
- Course :
- Duration :

Change In Urine :

Change In Stool :

Fever :

Pain :

Itching :

Pain :

Bleeding :

- Review GIT Symptoms .
- Metastatic Manifestations : ( If Malignancy Is Suspected )
- Hospital Course :
- Systemic Review :

- Past History :

- Drugs & Allergies :

- Family History :

- Social History :

- Obs/Gynae History :

**" Summary "**

## 2) Common Case " Acute Cholecystitis As An Example " :

### - Personal History :

Salma Mohammed Ahmed , 43 Years Old Saudi Female From Riyadh Married And Has 3 Offsprings , She Is A Housewife , With No Habits Of Medical Importance .

### - C/O :

Right Upper Abdominal Pain / 4 Days .

### - HPI :

She Was Well Till 4 Days Back When She Started To Has Acute Right Upper Abdominal Colicky Pain , Intermittent , Radiated To Right Shoulder And Back , It Is Increased By Eating Fatty Meals , By Movement And By Breathing With No Relieving Factor . The Pain Is Associated With Nausea And Vomiting , Fever 38 °C Measured In The Hospital Relieved By Paracetamol . There Is No History Of Jaundice , Change In Appetite , Weight Loss , Heartburn , Dysphasia , Hematemesis , Melena , Constipation , Diarrhea , Itching Or Bleeding Tendency .

● Hospital Course : Underwent CBC , US .

● In Her Systemic Review : -Ve .

- Past History : -Ve .

- Drugs & Allergies : -Ve .

- Family History : -Ve .

- Social History :

Living In Modern House / 2 Floors .

Educated & Satisfactory Income .

No History Of Recent Travelling .

- Obs/Gynae History :

Her Menarche Started At Age Of 11 , Regular , 7/28 , Normal Amount .

All Deliveries Were Full Term , Spontaneous Vaginal With No Complications .

### Summary

43 Y/O Saudi Female With 4 Days RUQ Pain , Colicky , Radiated To Rt. Shoulder , Increased After Eating A Heavy Meal . Associated With High Low Grade Fever , Other GIT Symptoms Are Irrelevant . There Is +Ve History Of Similar Attack 3 Months Back .

### **3) GIT Examination :**

- Introduce Yourself .
- Take Permission .
- Explain What You Are Going To Do .
- Maintain Privacy .
- Wash Your Hand .
- Exposure ( From The Nipple Line Up To Mid-Thigh ) .
- Position ( Supine Position ) .

#### **A) General Examination .**

#### **B) Local Examination :**

- Inspection .
- Palpation .
- Percussion .
- Auscultation .

# Inspection

## - Contour ( Stand At The Patient's Feet ) :

- ✓ **Normal** : Convex From Side-To-Side Antero-Posteriorly .
- ✓ **Generalized Bulge** : Obesity , Pregnancy , Ascites .
- ✓ **Localized Bulge** : Organomegally , Abdominal Mass .
- ✓ **Generalized Retraction** : Dehydration , Starvation .
- ✓ **Localized Retraction** : Previous Scar .

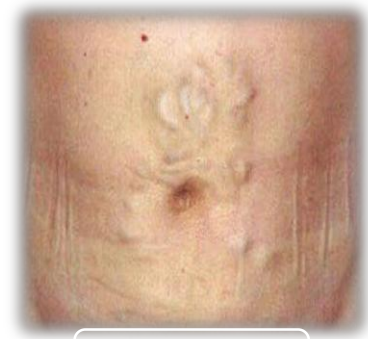## - Movement With Respiration ( Stand In The Rt . Side Of The Patient ) :

- ✓ **Males** : Abdomino-Thoracic .
- ✓ **Females** : Thoraco-Abdominal .

## - Peristalsis Movement , Skin Changes , Scars .

### - Subcostal Angle :

- ✓ **Normal** : Right / Acute Angle .
- ✓ **Obtuse** : Increase Intra-Abdominal Pressure .



Pic .1

### - Epigastric Pulsation :

- ✓ **Hepatic** : Tricuspid Incompetence .
- ✓ **Cardiac** : Right Ventricular Hypertrophy .
- ✓ **Vascular** : Abdominal Aorta Aneurism ( AAA ) .

### - Divarication Of Recti .

### - Umbilicus :

- ✓ **Normal** : Midway Between Xiphisternum & Symphysis Pubis , Rounded , Inverted .
- ✓ **Bluish** : Intra-Abdominal Hemorrhage , Pancreatitis , Pregnancy , Hemorrhagic Ascites .

### - Hernia Orifices .

### - Distribution Of Hair :

- ✓ **Males** : Triangular ( Become Transverse Indicates Feminization ) . ▲
- ✓ **Females** : Transverse . ▼

### - Dilated Veins :

- ✓ **Caput Medusa** : In Portal HTN . ( Pic .1 )
- ✓ **Flanks** : Inferior Vena Cava Obstruction .

#### # When We Say Dilated Vein ?

- Around Umbilicus Or In Flanks .
- Tortuous .
- Dilated .

**# N.B :** How To Differentiate Between Caput Medusa & Dilated Veins Due To IVC Obstruction ?

- The Technique Should Be Performed Under The Level Of Umbilicus , See ( Pic.1 ) .

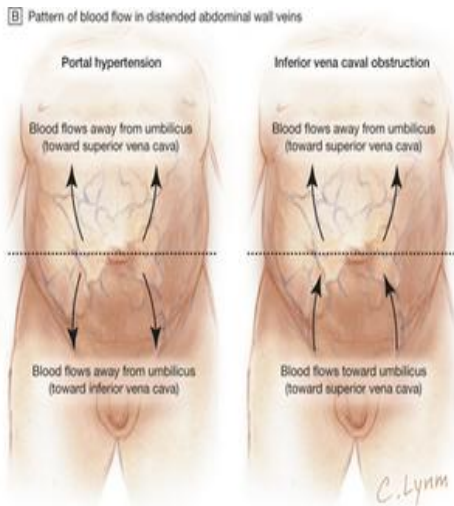
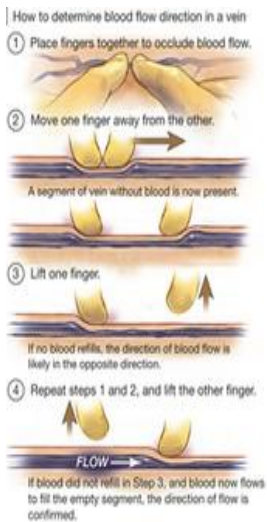
**Palpation**

**\*\* Superficial Palpation :**

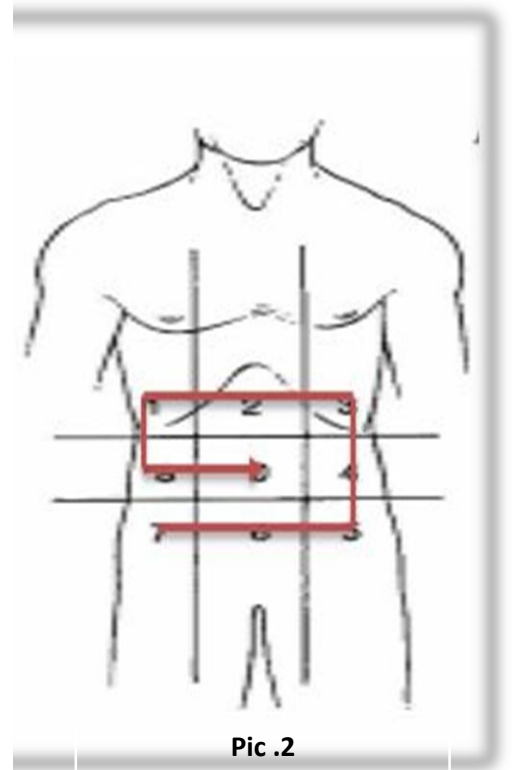
- ✓ Hotness .
- ✓ Tenderness .
- ✓ Superficial Mass .
- ✓ Rigidity .

**# Technique : ( Pic .2 )**

- Ask About Presence Of Pain .
- Gently Rest The Hand On The Abdomen And Press Lightly .
- Move Your Hand Systematically Over All Areas Of The Abdomen .
- Start Away And Move To Tender Area .



Pic .1



## \*\* Deep Palpation ( For Organomegally , Deep Masses , Deep Tenderness ) :

### 1- Liver :

#### - Right Lobe :

- ✓ Start From Rt. Iliac Fossa And Palpate Towards The Right Costal Margin With Examining Hand Aligned Parallel To The Right Costal Margin .
- ✓ Ask The Patient To Breath In And Out Slowly .
- ✓ If There Is Enlargement Can Confirm Diagnosis By Percussion Of Liver Span .

#### - Left Lobe :

- ✓ From Mid Line To Just Below Xiphoid Process .

#### - Liver Span :

- ✓ Determine Upper & Lower Borders Of Liver By Percussion .
- ✓ Measure The Distance By Measuring Tape ( Normally = 8-12 cm ) .

## \*\* Notes :

### - **Comments On Liver ( If There Is Hepatomegaly ) :**

- ✓ Size ( Enlarged - Shrunken ) .
- ✓ Edge ( Sharp - Rounded ) .
- ✓ Consistency ( Soft - Firm - Hard ) .
- ✓ Surface ( Smooth - Nodular ) .
- ✓ Tenderness .
- ✓ Pulsation .

### - **Other Palpation Techniques In Liver :**

- ✓ Bimanual Method .
- ✓ Dipping Method ( In Tense Ascites ) :
  - Fingers Tips Are Pressed With A Quick Stabbing Motion Into The Abdomen , A Tapping Sensation Is Felt By The Organ Due To Displacement By Fluid .



## 2- Spleen :

- Start Palpation In The Right Iliac Fossa With Patient Breath In And Out .
- Move Your Hand Toward The Left Costal Margin .
- **If You Couldn't Palpate It , Use The Following Methods :**
  - ✓ Bimanual Examination : Ask The Patient To Lying On The Right Side , Then Put Your Lt Hand On The Back And Palpate By Rt Hand .

## \*\* Notes :

- **Comments On Spleen ( If There Is Splenomegaly ) :**
  - ✓ Size .
  - ✓ Notch .
  - ✓ Consistency .
  - ✓ Surface .
  - ✓ Tenderness .

## 3- Kidney :

- **Bimanual Palpation :**
  - ✓ Place The Flat Of One Hand Behind The Patient Under The Loin And Other Hand On Upper Quadrant Of The Same Side And Ask The Patient To Take Deep Inspiration .

## # Spleen VS Left Kidney :

Spleen	Left Kidney
Antero-Medial Notch Which May Be Palpable .	No Notch .
You Cannot Get Between The Spleen And The Costal Margin .	You Can Get Above It .
Moves Inferio-Medially On Inspiration .	Move Inferiorly On Inspiration .
Not Ballottable .	Ballottable .
Dull On Percussion .	Resonant On Percussion .

## 4- Gall Bladder :

### - Murphy Sign :

- ✓ It Is Elicited By Palpating From Rt Iliac Fossa Upward And Asking The Patient To Breathe Deeply .
- ✓ If The Gallbladder Is Inflamed , The Patient Will Experience Pain And Catch Their Breath As The Gallbladder Descends And Contacts The Palpating Hand .

## Percussion

### - Liver Span :

- ✓ Start By Rt 2<sup>nd</sup> Intercostal Space On Mid-Clavicular Line Until The You Hear Dullness .
- ✓ Usually In 4<sup>th</sup> Intercostal Space .

### - Ascites :

- ✓ **Knee-Elbow Position :** For Mild Ascites ( 500 - 1000 cc ) .
- ✓ **Shifting Dullness :** For Moderate Ascites (1000 - 2000 cc ) :
  - While The Patient Lying In Supine Position Start Percuss In Midline Of Abdomen Until Reach To Umbilicus .
  - After That From Umbilicus Move Laterally Till You Meet Flank Dullness .
  - Keep Your Finger In The Place While Patient Rolls On His Side .
  - Wait For Seconds And Then Percuss Again And Notice If The Area Of Dullness Has Become Resonant As Fluid Has Shifted Elsewhere In The Abdomen .
- ✓ **Fluid Thrill :** For Severe Ascites (> 2000 cc ) :
  - Ask The Patient To Place The Edge Of His / Her Hand Along The Midline .
  - Flick One Side With The Index Of One Hand While Feeling The Other Side With The Palm Of The Other Hand And Feel Thrill .

## \*\* Notes :

### - All Percussion Is Heavy Except In :

- ✓ Lower Border Of Liver .
- ✓ Bare Area Of Heart .
- ✓ Anterior Chest Wall .

Which Are Light Percussion .

## Auscultation

- **Venous Hum:**
  - ✓ Epigastric Area .
  
- **Liver Bruit:**
  - ✓ On Liver Area .
  
- **Renal Bruit:**
  - ✓ Para-Umbilical Area .
  
- **Intestinal Sounds:**
  - ✓ Umbilical Area .
  - ✓ Normally       → 1 Sound each 6 Seconds .
  - ✓ Diminished     → In Paralytic Ileus .
  - ✓ Exaggerated In → In Intestinal Obstruction .

" By The End Of Abdominal Examination **Do Not Forget Examine** ( External Genitalia / Back / LNs ) " .



**Ulcer History &**  
**Examination**

# Ulcer History & Examination

## 1) History Sheet For Ulcer :

- Personal History :
- Chief Complaint ( C/O ) : "( Painful ) Foot - Face - Hand - ... Ulcer / Duration .."
- History Of Presenting Illness :

- Chronic Diseases :
- The Patient Was Well Till / On Usual Status Till ....
- Analysis Of Complaint :

### ( Pain ) :

- Site :
- Onset :
- Course :
- Duration :
- Character :
- Aggravating & Relieving Factors :
- Radiation :
- Associated Symptoms :
- Severity :

### ( Ulcer ) :

- Number :
- Site :
- Size
- Onset :
- Course :

When & How Noticed :

Apparent Cause : ( Trauma - Infection - DM - Varicose Veins - No Apparent Cause ).

Discharge :

- Review The Symptoms Of The Affected System .

- Hospital Course :

- Systemic Review :

- Past History :

- Drugs & Allergies :

- Family History :

- Social History :

- Obs/Gynae History :

## " Summary "

### \*\* Note :

- Types Of Ulcer :

- ✓ **Arterial ( Ischemic ) :** History Of Claudication Pain .

- ✓ **Venous :** History Of Varicose Veins .

- ✓ **Lymphatic :** History Of Multiple Swelling All Over The Body .

- ✓ **Neuropathic :** History Of Numbness OR Loss Of Sensation .

## 2) Common Case " Diabetic Foot As An Example " :

### - Personal History:

Salma Mohammed Ahmed , 75 Years Old Saudi Female From Riyadh Married And Has 3 Offsprings , She Is A Housewife , With No Habits Of Medical Importance .

### - C/O:

Non-Healing Foot Ulcer / 1 Month .

### - HPI:

She Is Known Case Of DM For 30 Years .

She Was Well Till 1 Month Back When She Started To Has Ulcer In Sole Of The Right Foot Due To Trauma , Progressive In Course , With No Discharge Or Bad Odour , No Pain , But It Is Bleed During Walking . Associated With Muscle Wasting & Loss Of Sensation In The Lower Limb .

● Hospital Course : Underwent CBC , Bone X-Ray .

● In Her Systemic Review : -Ve .

- Past History: -Ve Apart From DM For 30 Years , But Uncontrolled .

- Drugs & Allergies:

She Is On Insulin Injection But Uncontrolled .

- Family History:

No History Of Similar Condition .

+Ve History Of DM In Her Father

No History Of Hereditary Diseases .

-Ve Consanguinity.

- Social History:

Living In Modern House / 2 Floors .

Educated & Satisfactory Income .

No History Of Recent Travelling .

- Obs/Gynae History:

Her Menarche Started At Age Of 11 , Regular , 7/28 , Normal Amount , Menopause Ate Age Of 50 .

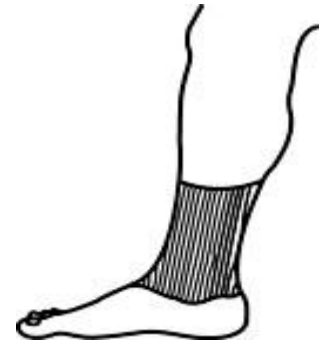All Deliveries Were Full Term , Spontaneous Vaginal With No Complications .

### Summary

75 Y/O Saudi Female , Known Case Of Uncontrolled DM , Complaining Of 1 Month Of Painless , Progressive Right Foot Ulcer , Associated With Loss Of Sensation In The Lower Limb .

# 3) Local Examination Of Ulcer :

- Introduce Yourself .
- Take Permission .
- Explain What You Are Going To Do .
- Maintain Privacy .
- Wash Your Hand .
- Exposure ( Till The Area Of Draining LNs ) .



Pic .1

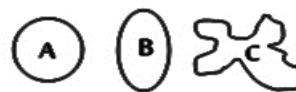
## Inspection

- Number .
- Site .
- Area :
  - ✓ Venous Ulcer → Gaiter Area Which Is The Area Between Knee & Ankle . ( Pic .1 )
  - ✓ Rodent Ulcer → Face ( Area Above The Line Between Angle Of Mouth And Ear ) .

- Size .

- Shape : ( Pic .2 )

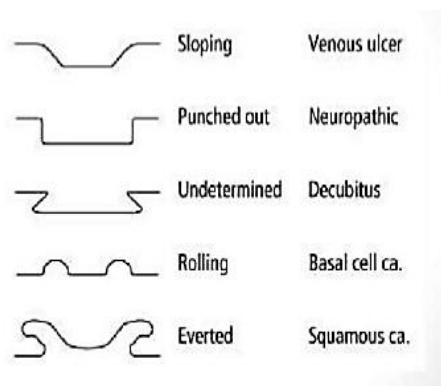
- ✓ Rounded (A)
- ✓ Oval (B)
- ✓ Geometrical (C)



Pic .2

- Edge : ( Pic .3 )

- ✓ Punched Out
- ✓ Undermined
- ✓ Sloping
- ✓ Irregular
- ✓ Rolled
- ✓ Everted

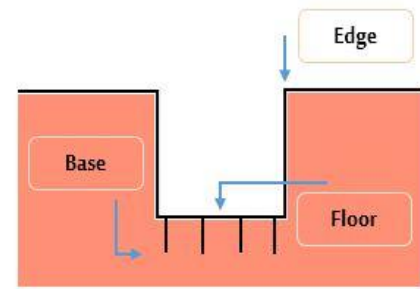


Pic .3



- **Floor:**
  - ✓ **Healthy:** Flat, No Discharge, Fishy Odour.
  - ✓ **Caseous Material:** TB.
  - ✓ **Necrotic Material:** Neoplastic.

- **Margin:**
  - ✓ **Red & Tender:** Inflammatory.
  - ✓ **Cyanotic:** TB.
  - ✓ **Pigmentation & Eczema:** Venous.



Edge, Floor & Base

- **Discharge:**
  - ✓ Bloody.
  - ✓ Purulent.

## Palpation

- **Base:**
  - ✓ **Indurated (Hard):** Venous, Ischemic.
  - ✓ **Infiltrative:** Malignant.
- **Tenderness:**
  - ✓ **TB:** Tender.
  - ✓ **Venous:** Tender.
  - ✓ **Ischemia, Trophic:** Not Tender.
  - ✓ **Neoplastic:** Not Tender, But Become Tender Later.
- **Relation To Other Structure According To Suspected Cause:**
  - ✓ Pulsation In Ischemia.
  - ✓ Edema In Venous.
  - ✓ Sensation In Neuropathy.
- **Draining Lymph Nodes:**
  - ✓ **Lower Limb:** Inguinal.
  - ✓ **Upper Limb:** Axillary.



**Specific Signs In**  
**Examination**

# Specific Signs In Examination

## Signs Of Appendicitis :

### - Rovsing Sign : ( Pic .1)

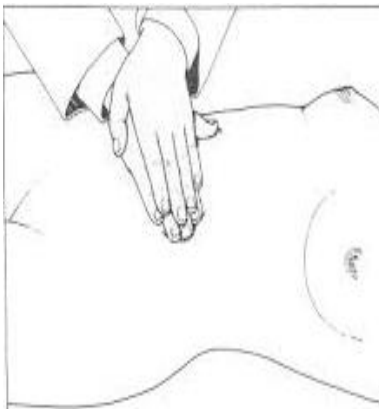- ✓ Right Iliac Fossa Pain When You Palpate The Left Iliac Fossa → Suggest Peritoneal Irritation .

### - Obturator Sign : ( Pic .2)

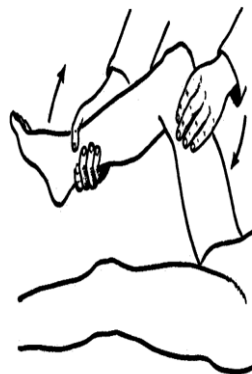- ✓ Right Iliac Fossa Pain With Internal / External Rotation Of Flexed Hip → Suggest Deep Inflamed Appendix .

### - Psoas Sign : ( Pic .3)

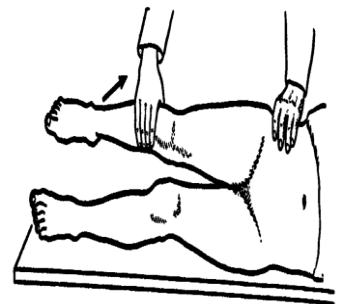
- ✓ Right Iliac Fossa Pain With Hip Extension / Flexion Against Resistant → Suggest Inflamed Appendix Along Psoas Muscle .



Pic .1



Pic .2



Pic .3



**DDx Of Common Signs &**  
**Symptoms**

# **DDx Of Common Signs & Symptoms**

## **1- DDx Of Right Upper Quadrant ( RUQ ) Swelling :**

### - **Parietal :**

#### ✓ **Skin :**

- Abscess .
- Sebaceous Cyst .
- Hematomas .
- Hemangioma .
- Neuro-Fibrosarcoma .

#### ✓ **Sub-Cutaneous Tissue :**

- Lipoma .
- Neuro-Fibroma .

#### ✓ **Muscles :**

- Hernia .
- Fibro-Sarcoma .

### - **Visceral :**

#### ✓ **Right Lobe Of Liver :**

- Amoebic Hepatitis .
- Hydatid Cyst .
- Liver Cirrhosis .
- Cancer .

#### ✓ **Hepatic Flexure :**

- Colonic Carcinoma .

#### ✓ **Gall-Bladder :**

- Mucocele .
- Empyema .
- GB Carcinoma .

#### ✓ **Right Kidney :**

- Hydro-nephrosis .
- Solitary Cystic Kidney .
- Polycystic Kidney .
- Wilm's Tumor .

#### ✓ **Retro-Peritoneal Sarcoma .**

## 2- DDx Of Left Upper Quadrant ( LUQ ) Swelling :

- Parietal :
  - ✓ Same As RUQ.
  
- Visceral :
  - ✓ Spleen :
    - Metabolic .
    - Bacterial Infections .
    - Tumors .
    - Portal HTN .
    - Blood disease .
  
  - ✓ Splenic Flexure :
    - Colonic Carcinoma .
  
  - ✓ Left Kidney :
    - Same As Right .
  
  - ✓ Retro-Peritoneal Sarcoma .

## 3- DDx Of Right Iliac Fossa Swelling :

- Parietal :
  - ✓ Same As RUQ.
  
- Visceral :
  - ✓ GIT :
    - Crohn's Disease .
    - Colonic Carcinoma .
    - Ileo-Cecal TB / Ileo-Cecal Actinomycosis .
    - Appendicular Mass / Abscess .

- ✓ Tubo-Ovarian & Uterus :
  - Ovarian Cyst / Tumor .
  - Hydrosalpinx Or Pyosalpinx .
  - Tubal Pregnancy .
  - Uterine Fibroid .
  
- ✓ Renal :
  - Ectopic Kidney .
  - Ptosed Kidney .
  
- ✓ Vascular & Lymphatic :
  - Right Iliac Artery Aneurysm .
  - Right Iliac LNs .
  
- ✓ Retro-Peritoneal Sarcoma .
  
- ✓ Malignant Undescended Testis .

#### 4- DDx Of Left Iliac Fossa Swelling :

- Parietal :
  - ✓ Same As RUQ .
  
- Visceral :
  - ✓ GIT :
    - Pelvic Colon .
    - Bilharzial Mass .
    - Pelvic Carcinoma .
    - Diverticulitis .
    - Spastic Colon .
  
  - ✓ Tubo-Ovarian & Uterus :
    - Same As Right Iliac Fossa .
  
  - ✓ Renal :
    - Same As Right Iliac Fossa .

- ✓ Vascular & Lymphatic :
  - Same As Right Iliac Fossa .
- ✓ Renal :
  - Same As Right Iliac Fossa .
- ✓ Retro-Peritoneal Sarcoma .
- ✓ Malignant Undescended Testis .

## 5- DDx Of Epigastric Swelling :

- Parietal :
  - ✓ Same As RUQ .
- Visceral :
  - ✓ Left Lobe Of Liver :
    - Same As Right Lobe .
  - ✓ Transverse Colon :
    - Carcinoma .
    - Bilharzial Colitis .
    - Diverticulitis .
  - ✓ Greater Omentum :
    - TB Peritonitis .
    - Malignant Nodule .
  - ✓ Stomach :
    - Carcinoma .
    - Epigastric Abscess .
    - Gastric Outlet Obstruction .
  - ✓ Vascular & Lymphatic :
    - Abdominal Aortic Aneurysm ( AAA ) .
    - Para-Aortic LNs .
  - ✓ Retro-Peritoneal Sarcoma .



## 6- DDx Of Umbilical Swelling:

- Parietal:
  - ✓ Same As RUQ.
  
- Visceral:
  - ✓ Transverse Colon:
    - The Same .
  - ✓ Greater Omentum:
    - The Same .
  - ✓ Stomach:
    - The Same .
  - ✓ Vascular & Lymphatic:
    - The Same .
  - ✓ Mesentery:
    - Mesenteric Cyst .
    - Mesenteric Abscess .
    - Mesenteric LNs .
  - ✓ Retro-Peritoneal Sarcoma .

## 7- DDx Of Abdominal Distention:

- ✓ Fetus .
- ✓ Flatus .
- ✓ Feces ( Intestinal Obstruction ) .
- ✓ Fat .
- ✓ Fluid ( Ascites ) .
- ✓ Fibroid .

## 8- DDx Of Acute Abdomen :

### ✓ Thoracic Causes :

- Pneumonia .
- Tonsil Tummy .
- Child With Acute Tonsillitis .
- Diaphragmatic Pleurisy .
- Myocardial Infarction .

### ✓ Upper Abdominal Causes :

- Perforated Peptic Ulcer ( Air Under Diaphragm In CXR ) .
- Acute Cholecystitis .
- Intestinal Obstruction .

### ✓ Lower Abdominal Causes :

- Non-Specific Mesenteric Lymphadenitis ( +Ve Shifting Tenderness ) .
- Regional Ileitis .
- Deep Iliac Adenitis .
- Mickle's Diverticulitis .
- Perforated Ileal Typhoid Ulcer .

### ✓ Pelvic Causes :

- Ectopic Pregnancy .
- Acute Salpingitis .
- Mid-Cyclic Pain ( Mittelschmerz ) .
- Twisted Ovarian Cyst .
- PID .

### ✓ Urological Causes :

- Renal Stone .
- Ureteric Stone .
- Pyelonephritis .

## 9- DDx Of Anal Pain :

- ✓ Anal Fissure .
- ✓ Prolapsed Strangulated Piles .
- ✓ Perianal Suppuration .
- ✓ Acute Perianal Hemorrhoids .
- ✓ Carcinoma Of The Anus .

## 10- DDx Of GIT Bleeding :

- ✓ General Bleeding Causes :
  - Bleeding Disorders ( Hemophilia , Thrombocytopenia ) .
  - Some Drugs ( Anticoagulant Therapy ) .
  
- ✓ Upper GI Bleeding Causes :
  - Esophageal Varices .
  - Acute Gastric Erosions Usually Caused By Ingestion Of NSAIDs .
  - Acute Hemorrhagic Gastritis .
  - Chronic Peptic Ulcer .
  
- ✓ Lower GI Bleeding Causes :
  - Hemorrhoids .
  - Diverticular Disease .
  - Ulcerative Colitis .
  - Ischemic Colitis .
  - Angiodysplasia .
  - Massive Bleeding From Upper GIT .
  - Mickle's Diverticulum .

## 11-DDx Of GIT Neck Swelling :

### ✓ Medline Neck Swelling :

- Thyroid & Parathyroid ( Benign & Malignant ) .
- Thyroglossal Cyst .
- Laryngocele .
- Ludwig's Angina .
- Lymphadenopathy .

### ✓ Lateral Neck Swelling :

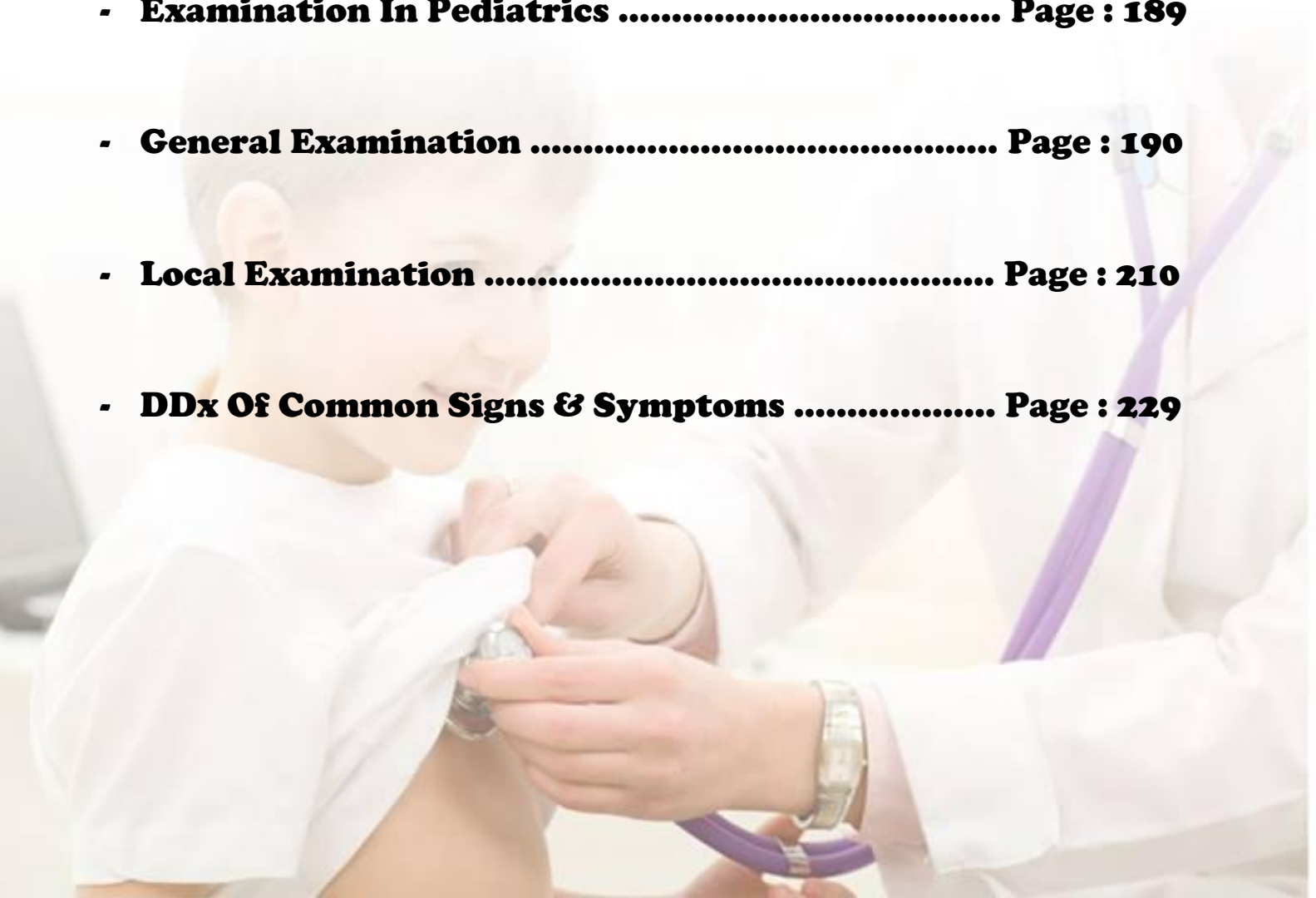
- Lymphadenopathy .
- Carotid Tumor .
- Cystic Hygroma .
- Brachial Cyst .
- Infectious Mononucleosis .
- TB .
- Lipoma .

# **Chapter ( 3 )**

## **" Pediatrics "**

### **# Content :**

- **General History Form ..... Page : 161**
- **History Of Common Cases ..... Page : 170**
- **Examination In Pediatrics ..... Page : 189**
- **General Examination ..... Page : 190**
- **Local Examination ..... Page : 210**
- **DDx Of Common Signs & Symptoms ..... Page : 229**





**General History In**  
**Pediatrics**

# **General History In Pediatrics**

## **1- Personal History :**

- ✓ **Name** : For Identification & To Be Familiar With Patient .
- ✓ **Age** : Certain Diseases Are Related To Certain Age Groups .
- ✓ **Sex** : Some Diseases Are More Common In Males / Females .
- ✓ **Nationality** : Certain Diseases Are Related To Certain Countries .
- ✓ **Home & Residence** : Certain Diseases Are Related To Certain Areas .
- ✓ **Informant** : Who Give You The History .
- ✓ **Date Of Admission** .

## **2- Chief Complaint ( C/O ) :**

- ✓ In Patient's Own Words .
- ✓ Write The Duration .
- ✓ Sort Them In Chronological Manner .

**Example:** Abdominal Pain / 1 Day .

## **3- History Of Presenting Illness ( HPI ) :**

*A- The Patient Is Known Case Of..... ( Chronic Disease ).*

*B- The Patient Was Well Till / On Usual Status Till ..... ( Hours - Days - Weeks - Months ) Back When He/She Started To Has ..... ( Complaint ).*

*C- Analysis Of Complaint :*

## I) General Symptoms :

- 1- **Fever:** Onset , Course , Duration , Pattern , Grade , Associated With ( Rigors - Convulsions - Skin Rash ) .
- 2- **Wight Changes:** Onset , Course , Duration , How Much ?

## II) GIT Symptoms :

- 1- **Abdominal Pain:** Site , Onset , Course , Duration , Character ( Nature ) , Radiated / Referred / Shifted , Aggravating & Relieving Factors , Severity ( Measured By : Interfering With Daily Activities , School Missing ) , Associated Symptoms .
- 2- **Vomiting:** Onset , Course , Duration , Content , Color , Odour , Relation To Eating .
- 3- **Diarrhea:** Onset , Course , Duration , Content , Color , Odour , Frequency , Consistency .
- 4- **Constipation:** Onset , Course , Duration , Type ( Partial - Complete ) , Presence Of Anal Pain .
- 5- **Jaundice:** Onset , Course , Duration , Who Notice ? , Stool Color , Urine Color , RUQ Pain .
- 6- **Bleeding:** Onset , Course , Duration , Content , Color , Odour .

## III) Cardio-Pulmonary Symptoms :

- 1- **Cough:** Onset , Course , Duration , Character , Frequency , Aggravating & Relieving Factors , Sputum , Relation To Position .
- 2- **Sputum:** Onset , Course , Duration , Color , Odour , Amount , Relation To Position , Consistency .
- 3- **SOB:** Onset , Course , Duration , Type , Severity , Grade .
- 4- **Chest Pain:** Site , Onset , Course , Duration , Character , Radiation , Aggravating & Relieving Factors , Associated Symptoms ( Abdominal Pain , Nausea , Vomiting , Sweating , Fever ) .
- 5- **Wheeze:** Onset , Course , Duration , Occurrence ( Exposure - Exertion ) .
- 6- **Cyanosis:** Site ( Oral - Extremities ) , Onset , Course , Duration , Occurrence ( Rest - Exertion ) , Relation To Feeding , Associated With ( Sweating - Cold Extremities ) .
- 7- **Runny Nose.**
- 8- **Earache.**



## IV) CNS Symptoms :

- 1- Symptoms Suggestive Of Higher Functions Involvement : Onset , Course , Duration , Type .
- 2- Symptoms Suggestive Of Cranial Nerves Involvement : Onset , Course , Duration , Type , Function Impairment ( Sensory , Motor , Gustatory ) .
- 3- Weakness : Site , Onset , Course , Duration , Grade , Features Of Increased Intra-Cranial Pressure ( ICP ) .
- 4- Abnormal Movement : Site , Onset , Course , Duration , Type , Features Of Increased ICP , Sphincter Function .

### \*\* Notes :

- Symptoms Of Higher Function : Consciousness , Memory , Speech , ... Etc.
- Symptoms Of Increased ICP : Headache , Blurred Vision , Projectile Vomiting .

## V) Genito-Urinary Symptoms :

- 1- Pain : Site , Onset , Course , Duration , Character , Radiation , Aggravating & Relieving Factors , Severity .
- 2- Polyuria : Onset , Course , Duration , Frequency , Volume .
- 3- Dysuria : Onset , Course , Duration , Baby Crying .
- 4- Discharge : Onset , Course , Duration , Color , Amount , Odour , Consistency , Itching .

## VI) Musculo-Skeletal Symptoms :

- Bone / Joint / Muscle Pain : Site , Onset , Course , Duration , Character , Radiation , Aggravating & Relieving Factors , Severity , Loss Of Movement , Trauma , Stiffness ,

## VII) Skin Symptoms :

- 1- Skin Rash : Onset , Course , Duration , Distribution , Type .
- 2- Itching : Onset , Course , Duration .
- 3- Hyper/Hypo Pigmentation : Onset , Course , Duration .

*D- Review The Symptoms Of The Affected System .*

#### *E- Review The Symptoms Of Other Systems :*

- ✓ **General** : Weak Cry , Poor Feeding , Child Activity .
- ✓ **CNS** : Headache , Higher Functions , CNS , Loss Of Sensation , Weakness , Abnormal Movement .
- ✓ **GIT** : Dysphagia , Nausea , Vomiting , Abdominal Pain , Jaundice , Change In The Bowel Habits , Bleeding .
- ✓ **Cardio-Pulmonary** : Cough , Dyspnea , Chest Pain , Wheeze , Cyanosis .
- ✓ **Urogenital** : Loin Pain , Dysuria , Polyuria , Hematuria , Discharge .
- ✓ **Musculoskeletal** : Pain , Loss Of Movement , Stiffness .
- ✓ **Skin** : Rash . Itching , Pigmentation .
- ✓ **Hematology** : Easy Fatigability , Petichiae , Gum Bleeding , Pallor .

#### *F- Hospital Course ( Investigations & Medications ) .*

### **4- Past History :**

- **Chronic Diseases ( HTN , DM , Asthma , TB , Hepatitis )** : When , Where & How Diagnosed ?
- **Similar Conditions** .
- **Previous Hospital Admissions** .
- **Previous Surgical Interventions** .
- **Previous Blood Transfusion** .

### **5- Peri-Natal History :**

#### **A) Prenatal:**

- **Antenatal Care** : Antenatal Visits , Folic Acid Supplementation .
- **Mother Age At Pregnancy** .
- **Hx Of Maternal Infection ( TORCH Infection )** : Fever , Skin Rash > Teratogenic .
- **Hx Of Maternal DM , HTN** .
- **Hx Of Maternal Drug Intake** : Some Causes Teratogenicity & Some Causes Permanent Damage ( Tetracycline ) .
- **Hx Of Maternal Exposure To Radiation** : Teratogenic .

#### **B) Natal:**

- **Duration Of Pregnancy** : Full-Term , Pre-Term , Post-Term .
- **Duration Of Delivery** .
- **Mode Of Delivery** : Normal Vaginal , Cesarean Section .
- **Complication During Delivery** .
- **Weight Of The Baby** .
- **APGAR Score / Crying** .

#### **C) Postnatal:**

- **Discharge** .
- **Neonatal Admission** .
- **Neonatal Complications ( Jaundice , Cyanosis , Convulsion , Fever )** .

## **6- Nutritional History :**

- **Breast / Bottle Feeding .**
- **Weaning .**
- **Weight .**
- **Current Food .**

**\*\* Note :** For Bottle Feeding , You Have To Ask About :

- ✓ Which Formula Did The Patient Receive ?
- ✓ How Was It Prepared ?
- ✓ What Volume Did The Patient Take At Each Feed ?
- ✓ How Long Did The Patient Take It ?
- ✓ Frequency Of Feeds .
- ✓ Total Daily Intake .

## **7- Developmental History : ( Pic.1 )**

- **Gross Motor .**
- **Fine Motor .**
- **Social .**
- **Language .**
- **Schooling ( Level And Performance ) .**

## **8- Immunization History : ( Pic.2 )**

- **Check Immunization Card .**
- **If There Is A Missed Vaccine , Ask About The Reason .**

## **9- Family History :**

- **Chronic Diseases ( HTN , DM , Asthma , TB , Hepatitis ) .**
- **Similar Conditions .**
- **Inherited / Genetic Diseases .**
- **Consanguinity .**
- **Age Of Parents .**
- **Number Of Siblings & Age Of Each One .**
- **History Of Previous Abortion & Neonatal Death .**

(Pic.1)

## **Important Developmental Mile-Stones**

Age In Months	Gross Motor	Fine Motor	Social	Language
1.5			Social Smile	
3	Head Support			
4	Sitting With Support	Palmer Grasp		
6	Sit With Out Support			Babbles
7	Crawl / roll Over			
9		Pincer Grasp		
10	Stand With Support		Waves Bye-Bye	Say Mama &Dad
11				
12	Walks Alone			Speak 1 <sup>st</sup> Word
15	Crawls Upstairs	Make A Tower Of 2-3 Cubes		
18	Walks Upstairs With One Hand Held	Make A Tower Of 4 Cubes		2 Words Sentence
24		- Handle Spoon Well - Make A Tower Of 6 Cubes		Speak In 3 Words Sentence
36	Ride A Tricycle	Copies A Circle		
48		Copies Square & A Cross		
60		Draws A Triangle		

(Pic.2)

## Vaccination Schedule In KSA

جدول التطعيمات الوطني		
التطعيم Vaccine	الزيارة Visit	
• BCG • Hepatitis B	• درن • التهاب كبدى (ب)	• عند الولادة • At Birth
• IPV • DTaP • Hepatitis B • Hib • Pneumococcal Conjugate (PCV)* • Rota**	• شلل أطفال معطل • الثلاثى البكتيري • الالتهاب الكبدى (ب) • المستدمية النزلية • البكتيريا العقدية الرئوية* • فيروس الروتا**	• عمر شهرين • 2 months
• IPV • DTaP • Hepatitis B • Hib • Pneumococcal Conjugate (PCV)* • Rota**	• شلل أطفال معطل • الثلاثى البكتيري • الالتهاب الكبدى (ب) • المستدمية النزلية • البكتيريا العقدية الرئوية* • فيروس الروتا**	• عمر 4 شهور • 4 months
• OPV • IPV • DTaP • Hepatitis B • Hib • Pneumococcal Conjugate (PCV)*	• شلل الأطفال الفموي • شلل أطفال معطل • الثلاثى البكتيري • الالتهاب الكبدى (ب) • المستدمية النزلية • البكتيريا العقدية الرئوية*	• عمر 6 شهور • 6 months
• Measles • Meningococcal Conjugate quadrivalent (MCV4)	• الحصبة المفرد • الحمى الشوكية الرباعي المقترن	• عمر 9 أشهر • 9 months
• OPV • MMR • Pneumococcal Conjugate (PCV)* • Meningococcal Conjugate quadrivalent (MCV4)	• شلل الأطفال الفموي • الثلاثى الفيروسي • البكتيريا العقدية الرئوية* • الحمى الشوكية الرباعي المقترن	• عمر 12 شهر • 12 months
• OPV • DTaP • Hib • MMR • Varicella • Hepatitis A • Hepatitis A	• شلل الأطفال الفموي • الثلاثى البكتيري • المستدمية النزلية • الثلاثى الفيروسي • الجدري المائي • الالتهاب الكبدى (أ) • الالتهاب الكبدى (أ)	• عمر 18 شهر • 18 months
• OPV • DTaP (Td)*** • MMR • Varicella	• شلل الأطفال الفموي • الثلاثى البكتيري (الثنائي البكتيري)*** • الثلاثى الفيروسي • الجدري المائي	• عمر 24 شهر • عند دخول الصف • الأول الإبتدائي • First class primary • school age

## **10- Social History :**

- Housing Conditions .
- Parents' Occupation .
- Parents' Special Habits ( Smoking , Alcohol / Drug Abuse ) .
- History Of Recent Travelling .
- Contact With Animals .

## **11- Drug & Allergies History :**

- Long Term Medications .
- Short Term Medications .
- Allergy To Certain Food OR Medication .

**" Summary "**



**History Of Common**  
**Cases In Pediatrics**

# History Of Common Cases

## 1) Pneumonia :

### - Personal History :

Amal Hussain Ali , 4 Months Saudi Girl From Jazan , Admitted Through ER On 2-1-1436 H . Information Taken From Her Mother.

### - C/O :

Fever, Cough / 2 Days .

SOB / 1 Day .

### - HPI :

She Was Well Till 2 Days Back When She Started To Has Fever Which Was Low Grade , Gradual In Onset , Intermittent In Course , 3- 4 Times / Day Each One Remain 1-2h , Relieving By Medication & Cold Path , No Aggravating Factor, Interfering With Patient's Sleep , Documented At Home 37.9 C° , Associated With Cough Gradual Onset , Progressive In Course , 2 Days Duration , Aggravating In Cold Weather, No Relieving Factors, Not Productive, Interfering With Patient's Sleep . Yesterday, The Fever Became High Grade , Continuous, Not Relived By Medication And Cold Path . The Cough Became Productive With Small Amount Sputum , Whit Color , No Blood . Also The Patient Complaint From Shortness Of Breath , Gradual Onset ,1 Day Duration , Progressive In Course , No Aggravating Or Reliving Factor Interfering With Patient's Sleep . There No Wheezing , No Chest Pain , No Palpitation , No Cyanosis .

● Systemic Review : -Ve .

● Hospital Course : Underwent CBC , Chest X-Ray , Oxygen , Nebulizer , Medications And The Patient Is Improving .

- Past History : -Ve .

- Peri-Natal History :

✓ Prenatal :

Antenatal Care : Regular Antenatal Care , Folic Acid And Iron Supplementation , Mother Age At Pregnancy : 22 Years Old , Maternal Infection , Maternal DM Or Hypertension , Drug Taking & Exposure To Radiation : -Ve .

✓ Natal :

Full Term Baby , Spontaneous Vaginal Delivery With No Complications To Mother Or Baby , Weight Of The Baby Was 3 Kg , The Baby Cry Immediately .

✓ Postnatal :

Discharged After 24 Hours On Doctor's Permission , No Neonatal Admission & No Complication .

- Nutritional History :

Exclusive Brest Feeding , Many Times In Day 5-10 Minutes For Each With Average Weight .



- **Developmental History:**

She Can Sit With Support & Palmar Grasp .

- **Vaccination History:** Up-To-Date .

- **Family History:** -Ve .

- **Social History:** Good Living Conditions & Socio-Economic Status .

- **Drugs & Allergies:** -Ve .

**Summary**

4 Months Saudi Girl Admitted Through ER Complaining Of Fever & Cough / 2 Days , SOB / 1 Day , The Fever Is High Grade & Continuous Associated With Productive Cough & SOB , Informations Taken From Her Mother .

**+Ve Findings In Examination:**

- **General Examination:** Appears Ill , Dyspnic , With Signs Of Respiratory Distress .

- **Local ( Chest ) Examination:**

- ✓ **Inspection:** Decrease Movement Of Right Upper Side ( Affected Lobe ) , Intercostal Retraction .
- ✓ **Palpation:** Increased Tactile Vocal Fremitus.
- ✓ **Percussion:** Dullness In Right Upper Side Of Chest .
- ✓ **Auscultation:** Decreased Air Entry On Right Upper Side , Crepitation , Increased Vocal Resonance .

# History Of Common Cases

## 2) Bronchial Asthma ( BA ) :

### - Personal History :

Ahmed Hussain Ali , 4 Y/O Saudi Boy From Jazan , Admitted Through ER On 2-1-1436 H . Information Taken From His Mother.

### - C/O :

Cough & SOB / 1 Day .

### - HPI :

He Is Recently Diagnosed As BA 5 Months Back . She Was On Usual Status Till 1 Days Back When He Started To Has Cough Which Was Acute In Onset , Progressive In Course , 2 Days Duration , Aggravating In Cold Weather & Activity , No Relieving Factors , Not Productive , Interfering With His Activity And Sleep , More Intense In Night , Associated With Shortness Of Breath Which Is Acute Onset , Progressive In Course , Aggravating By Activity , Relieving By Rest And Inhaler . There Is Wheezing , Chest Pain But No Palpitation , No Cyanosis , No Sputum .

● Systemic Review : -Ve .

● Hospital Course : Underwent CBC , Chest X-Ray , Oxygen , Nebulizer , Medications And The Patient Is Improving .

### - Past History :

BA Diagnosed At KFCH 5 Months Back , Controlled On Inhaler .

History Of 2 Previous Similar Attacks With Admission , The Last One Occurred Before 1 Month .

### - Peri-Natal History :

✓ Prenatal :

Antenatal Care : Regular Antenatal Care , Folic Acid And Iron Supplementation , Mother Age At Pregnancy : 28 Years Old , Maternal Infection , Maternal DM Or Hypertension , Drug Taking & Exposure To Radiation : -Ve .

✓ Natal :

Full Term Baby , Spontaneous Vaginal Delivery With No Complications To Mother Or Baby , Weight Of The Baby Was 3.5 Kg , The Baby Cry Immediately .

✓ Postnatal :

Discharged After 7 Days On Doctor's Permission , No Neonatal Admission & No Complication .

### - Nutritional History :

Exclusive Brest Feeding , Many Times In Day 5-10 Minutes For Each With Average Weight .

Weaning Started At 6<sup>th</sup> Month With Fortified Infant Cereal .

### - Developmental History :

He Can Draw Square , Counts , Names Color .

### N.B : Precipitation Factors Of BA :

- Infection .
- Exercise .
- Specific Allergen .

- **Vaccination History:** Up-To-Date .
- **Family History:** +Ve History Of BA In His Brother .
- **Social History:** Good Living Conditions & Socio-Economic Status .
- **Drugs & Allergies:** On Salbutamol , 2 Times/Day , With Good Compliance .

#### Summary

4 Y/O Saudi Boy Admitted Through ER Complaining Of Cough And Shortness Of Breath / 1 Day Associated With Wheezing , He Is Recently Diagnosed As BA 5 Months Back , On Inhaler . The Informations Taken From His Mother .

#### +Ve Findings In Examination :

- **General Examination:** Appears Ill , Dyspnic , With Signs Of Respiratory Distress .
- **Local ( Chest ) Examination :**
  - ✓ **Inspection :** Barrel-Shaped Chest , Decrease Movement , Intercostal Retraction .
  - ✓ **Palpation :** Decrease Tactile Vocal Fremitus.
  - ✓ **Auscultation :** Decreased Air Entry on Both sides ,Vesicular Breathing with Prolonged Expiration , Decreased Vocal Resonance, Wheeze Mainly Expiratory ( In Severe Cases also Inspiratory Or May Be Absent ) , Crepitation ( Due to Excess Mucus Secretion in The Bronchi ) .

# History Of Common Cases

## 3) Bronchiolitis :

### - Personal History :

Ahmed Hussain Ali , 3 Months Saudi Boy From Jazan , Admitted Through ER On 2-1-1436 H . Information Taken From His Mother.

### - C/O :

Cough & Fever / 2 Days .

### - HPI :

He Was Well Till 3 Day Back When His Mother Noticed A Nasal Discharge & Congestion , Then After 2 Days He Suffered From Productive Cough Which Was Acute , Progressive , Associated With Low In Grade Fever , Intermittent , No Aggravating Factors & Relieved By Cold Fumets , Followed By Difficulty Of Breathing & Poor Feeding With No Loss Of Wight , No Cyanosis .

● Systemic Review : -Ve .

● Hospital Course : Underwent CBC , Chest X-Ray , Oxygen , Antipyretics And The Patient Is Improving .

### - Past History : -Ve .

### - Peri-Natal History :

#### ✓ Prenatal :

Antenatal Care : Regular Antenatal Care , Folic Acid And Iron Supplementation , Mother Age At Pregnancy : 28 Years Old , Maternal Infection , Maternal DM Or Hypertension , Drug Taking & Exposure To Radiation : -Ve .

#### ✓ Natal :

Full Term Baby , Spontaneous Vaginal Delivery With No Complications To Mother Or Baby , Weight Of The Baby Was 3.5 Kg , The Baby Cry Immediately .

#### ✓ Postnatal :

Discharged After 24 Hours On Doctor's Permission , No Neonatal Admission & No Complication .

### - Nutritional History :

Exclusive Brest Feeding , Many Times In Day 5-10 Minutes For Each With Average Weight .

### - Developmental History :

He Can Smile , Turn Head Toward Sound & Able To Hold Head Up .

- **Vaccination History:** Up-To-Date .
- **Family History:** -Ve .
- **Social History:** Good Living Conditions & Socio-Economic Status .
- **Drugs & Allergies:** -Ve .

#### **Summary**

3 Months Saudi Boy Admitted Through ER Complaining Of Cough And Fever / 2 Days . The Condition Started With Rhinorrhea 3 Days Back Then He Developed Productive Cough , Intermittent Low Grade Fever & Difficulty Breathing , -Ve History Of Bronchial Asthma In His Family . The Informations Taken From His Mother .

#### **+Ve Findings In Examination:**

- **General Examination:** Looking Ill But Active , With Nasal Flaring , No Obvious Cyanosis , Good Skin Turgor.
- **Local ( Chest ) Examination:**
  - ✓ **Auscultation:** Moderate Bilateral Expiratory Wheeze & Fine Rales .

# History Of Common Cases

## 4) Congenital Heart Disease ( CHD ) :

### - Personal History :

Amal Hussain Ali , 2 Months Saudi Girl From Jazan , Admitted Through ER On 2-1-1436 H . Information Taken From Her Mother.

### - C/O :

Easy Fatigability / 1 Week .

### - HPI :

The Condition Start Gradually From Birth , Baby Cannot Easily Feed She Was Drink Little Amount Then She Start Sweating Stop Feeding For 5 Minutes , Then Start Feeding Again , BUT In Last Week This Condition Became More Worse And Increase Frequency When She Drink Or Cry She Start Sweat And Her Mouth And Hand Became Blue .

- Systemic Review : -Ve Apart From Decrease In Weight , Dyspnea And Sometime Her Mother Feel Her Heart Beat BUT No Cough .
- Hospital Course : Underwent CBC , Chest X-Ray , ECG , Echo And The Patient Is Improving .

### - Past History : -Ve .

### - Peri-Natal History :

#### ✓ Prenatal :

Antenatal Care : Regular Antenatal Care , Folic Acid And Iron Supplementation , Mother Age At Pregnancy : 28 Years Old , Maternal Infection , Maternal DM Or Hypertension , Drug Taking & Exposure To Radiation : -Ve .

#### ✓ Natal :

Full Term Baby , Spontaneous Vaginal Delivery With No Complications To Mother Or Baby , Weight Of The Baby Was 3.5 Kg , The Baby Cry Immediately .

#### ✓ Postnatal :

Discharged After 24 Hours On Doctor's Permission , No Neonatal Admission & No Complication .

### - Nutritional History :

Exclusive Brest Feeding Till Now , Many Times In Day 5-10 Minutes For Each With Average Weight .

### - Developmental History :

He Can Smile .

- **Vaccination History:** Up-To-Date .
- **Family History:** -Ve .
- **Social History:** Good Living Conditions & Socio-Economic Status .
- **Drugs & Allergies:** -Ve .

### Summary

2 Months Saudi Girl Admitted Through ER Complaining Of Easy Fatigability / 1 Week . The Condition Started Gradually From Birth , But Progress 1 Week Back When She Developed Difficult Feeding Associated With Sweating , Dyspnea & Peripheral Cyanosis . The Informations Taken From His Mother .

### +Ve Findings In Examination :

- **General Examination :** Looking Ill But Active , Tachypnic , With Peripheral Cyanosis When She Cry .
- **Local ( Cardiology ) Examination :**
  - ✓ **Auscultation Findings In Acyanotic Heart Disease :**
    - **VSD :** Normal Heart Sound & Harsh Pan-Systolic Murmur At Left Sternal Edge In 3<sup>rd</sup> & 4<sup>th</sup> ICS .
    - **ASD :** Wide Fixed Splitting Of Second Heart Sound & Ejection Systolic Murmur At Pulmonary Area
    - **PDA :** Normal Heart Sound & Continuous Murmur Below Left Clavicle Radiated To Back .
  - ✓ **Auscultation Findings In Cyanotic Heart Disease :**
    - **Tetralogy Of Fallot :** Single Heart Sound & Ejection Systolic Murmur At Pulmonary Area .

# History Of Common Cases

## 5) Sickle Cell Anemia ( SCA ) :

### - Personal History :

Ahmed Hussain Ali , 9 Y/O Saudi Boy From Jazan , Admitted Through ER On 2-1-1436 H . Information Taken From His Mother .

### - C/O :

Back And Joint Pain / 1 Day .

### - HPI :

He Is Known Case Of SCA . He Was On Usual Status Till 1 Days Back When She Started To Have Back Pain Which Was Gradual Onset , Progressive In Course , Lower Back At Sacral Area Which Radiating To Lower Extremities , Aggravating When The Patient Move And Relieving By Analgesic , Interfering With Patient's Activity And Sleep . After 2 Hours , The Patient Complains Of Joint Pain In Knee , Progressive , Aggravating When The Patient Move , Not Reliving By Analgesic . No Muscle Pain Or Wasting & No Subcutaneous Nodules .

● Systemic Review : -Ve .

● Hospital Course : Underwent CBC , X-Ray , Analgesic & I.V Fluids And The Patient Is Improving .

### - Past History :

SCA Diagnosed At KFCH Since He Was 1 Years Old , He Is On Folic Acid , Hydroxyurea .

+Ve History Of Many Previous Attacks With Admissions , Last One Was 4 Months Back .

Blood Transfusion : Tow Times With One Unit .

### - Peri-Natal History :

✓ Prenatal :

Antenatal Care : Regular Antenatal Care , Folic Acid And Iron Supplementation , Mother Age At Pregnancy : 28 Years Old , Maternal Infection , Maternal DM Or Hypertension , Drug Taking & Exposure To Radiation : -Ve .

✓ Natal :

Full Term Baby , Spontaneous Vaginal Delivery With No Complications To Mother Or Baby , Weight Of The Baby Was 3.5 Kg , The Baby Cry Immediately .

✓ Postnatal :

Discharged After 24 Hours On Doctor's Permission , No Neonatal Admission & No Complication .

### - Nutritional History :

Exclusive Brest Feeding For 6 Months , Weaning At Age Of 6<sup>th</sup> Month With Fortified Infant Cereal , Now He Eats Usual Food With Family .

### N.B : Precipitation Factors Of Vaso-Occlusive Crisis :

- Infection .
- Cold
- Hypoxia , High Altitude .



- **Developmental History:** He Is In 3<sup>rd</sup> Primary Year School With Good Performance .
- **Vaccination History:** Up-To-Date + Extra Vaccines .
- **Family History:** -Ve Apart From Consanguinity & His Brother Has SCA .
- **Social History:** Good Living Conditions & Socio-Economic Status .
- **Drugs & Allergies:** He Is On Folic Acid & Hydroxyurea .

#### **Summary**

9 Y/O Saudi Boy Admitted Through ER Complaining Of Back Pain & Joint Pain / 1 Day . He Is Known Case Of SCA Since He Was 1 Y/O . He Has Many Previous Similar Attacks & Admissions . The Informations Taken From His Mother .

#### **+Ve Findings In Examination :**

- **General Examination:** Looking Ill , With Pallor & Jaundice , No Organomegally .
- **Local ( Joint ) Examination :**
  - ✓ Painful Range Of Motion , With No Swelling Or Tenderness .

# **History Of Common Cases**

## **6) Gastro-Enteritis :**

### **Personal History :**

Ahmed Hussain Ali , 6 Months Saudi Boy From Jazan , Admitted Through ER On 2-1-1436 H . Information Taken From His Mother .

### **C/O :**

Vomiting & Diarrhea / 18 Hours .

### **HPI :**

The Patient Was Well Till 18 Hours Back When He Suffered From Severe Vomiting , Yellow In Color , Non Bilious , High Amount , 10 Times Till Now , Associated With Severe Watery Stool Without Blood Or Mucous , 12 Times Till Now , With No Dysphagia , No Regurgitation , No Jaundice , Associated With Fever , 38 °C Intermittent In Course , With No Aggravated Or Relieved Factors , No Rash , No Rigor , No Sweating , No Convulsion & No Loss Of Weight .

● Systemic Review : -Ve .

● Hospital Course : Underwent CBC , Stool Analysis , Serum Electrolytes , Antipyretic & I.V Fluids And The Patient Is Improving .

### **Past History :** -Ve .

### **Peri-Natal History :**

✓ Prenatal :

Antenatal Care : Regular Antenatal Care , Folic Acid And Iron Supplementation , Mother Age At Pregnancy : 28 Years Old , Maternal Infection , Maternal DM Or Hypertension , Drug Taking & Exposure To Radiation : -Ve .

✓ Natal :

Full Term Baby , Spontaneous Vaginal Delivery With No Complications To Mother Or Baby , Weight Of The Baby Was 3.5 Kg , The Baby Cry Immediately .

✓ Postnatal :

Discharged After 24 Hours On Doctor's Permission , No Neonatal Admission & No Complication .

### **Nutritional History :**

Exclusive Brest Feeding Till Now , Many Times In Day 5-10 Minutes For Each With Average Weight .

- **Developmental History :** He Can Smile , Sit Without Support , Babbles & Rolls Over Prone To Supine .

- **Vaccination History:** Up-To-Date .
- **Family History:** -Ve Apart From Consanguinity .
- **Social History:** Good Living Conditions & Socio-Economic Status .
- **Drugs & Allergies:** -Ve .

#### **Summary**

6 Months Saudi Boy Admitted Through ER Complaining Of Vomiting & Diarrhea / 18 Hours . The Vomiting Was Severe , Yellow & Diarrhea Was Severe Watery , Associated With Low Grade Fever . The Informations Taken From His Mother .

#### **+Ve Findings In Examination :**

- **General Examination :** Looking Ill , With Pallor , Sunken Fontanel & Decreased Skin Turgor .
- **Local ( Abdominal ) Examination :**
  - ✓ Generalized Tenderness , With No Organomegally .

# History Of Common Cases

## 7) Diabetic Keto-Acidosis (DKA):

### - Personal History:

Ahmed Hussain Ali, 6 Y/O Saudi Boy From Jazan, Admitted Through ER On 2-1-1436 H. Information Taken From His Mother.

### - C/O:

Abdominal Pain / 2 Hours.

### N.B: Precipitation Factors Of DKA:

- Infection.
- Missed Insulin Dose.
- High Calorie Intake.

### - HPI:

The Patient Is Known Case Of DM Type I. He Was On Usual Status Till 2 Hours Back When The Condition Started After Missing The Insulin Dose, He Suffered From Diffuse Abdominal Pain, Progressive, Dull-Aching In Epigastric Area, Not Radiated, Aggravated By Movement & No Relieving Factors, Associated With Vomiting ( 1 Time ), Increase Thirst & Urination. No Dysphagia, No Jaundice, No Diarrhea, No Constipation, No Dysuria.

- Systemic Review: -Ve Apart From Loss Of Weight & SOB.
- Hospital Course: Underwent CBC, Urine Analysis, Blood Glucose Level, I.V Fluids & Insulin And The Patient Is Improving.

### - Past History:

Diagnosed As DM Type I At KFCH, Since He Was 3 Y/O, Controlled On Insulin Injections.

+Ve History Of 1 Previous Similar Attack With Admission 6 Months Back.

### - Peri-Natal History:

#### ✓ Prenatal:

Antenatal Care: Regular Antenatal Care, Folic Acid And Iron Supplementation, Mother Age At Pregnancy: 28 Years Old, Maternal Infection, Drug Taking & Exposure To Radiation: -Ve, But Maternal DM Was +Ve.

#### ✓ Natal:

Full Term Baby, Elective Cesarean Section With No Complications To Mother Or Baby, Weight Of The Baby Was 4.5 Kg, The Baby Cry Immediately.

#### ✓ Postnatal:

Discharged After 2 Days On Doctor's Permission, No Neonatal Admission & No Complication.

### - Nutritional History:

Exclusive Brest Feeding For 6 Months, Weaning At Age Of 6<sup>th</sup> Month With Fortified Infant Cereal, Now He Eats Usual Food With Family But With Sugar Control.

- **Developmental History:** He Is In 1<sup>st</sup> Primary Year School With Good Performance .
- **Vaccination History:** Up-To-Date .
- **Family History:** -Ve Apart From Consanguinity .
- **Social History:** Good Living Conditions & Socio-Economic Status .
- **Drugs & Allergies:** Insulin Injection , 2 Times/Day , With Good Compliance .

#### **Summary**

6 Y/O Saudi Boy Admitted Through ER Complaining Of Abdominal Pain / 2 Hours . He Is Known Case Of DM Type I , Controlled On Insulin Injection . The Pain Started After Missing Of Insulin Dose And Was Severe Epigastric Dull-Aching Pain , Associated Polyuria & Polydipsia . He Has 1 Previous Attack & Admission . The Informations Taken From His Mother .

#### **+Ve Findings In Examination:**

- **General Examination:** Looking Ill , With Signs Of Dehydration , Characteristic Fruity ( Acetone ) Breath Odour , Tachycardia , Hypotension & Deep Rapid Breathing .
- **Local ( Abdominal ) Examination:**
  - ✓ Epigastric Tenderness , With No Organomegally .

# History Of Common Cases

## 8) Meningitis :

### - Personal History :

Ahmed Hussain Ali , 18 Months Saudi Boy From Jazan , Admitted Through ER On 2-1-1436 H . Information Taken From His Mother .

### - C/O :

Fever / 4 Days .

### - HPI :

He Was Quite Well Till 4 Days Prior To Admission When He Started To Has Fever Which Was Acute Onset , Progressive , Without Aggravating Factor , Relieved Temporary By Antipyretic For 1 Hour Then Retain Back , Measured At Hospital It Always 39 °C , Interfere With His Feeding & Usual Activities , Associated With Skin Rash & Convulsions Which Were 4 Attacks Till Today All Of Them Were Generalized Tonic Clonic . In The Last Day He Developed Diarrhea Which Was 4 Times/Day , Yellow , Without Offensive Smell , Not Mixed With Blood Or Mucous . Marked Wight Loss Was Noticed .

● Systemic Review : -Ve .

● Hospital Course : Underwent CBC , Urine Analysis , Blood Culture , CXR , ECG , Lumber Puncture , I.V Fluids , Antibiotic And The Patient Is Improving .

- Past History : -Ve .

- Peri-Natal History :

✓ Prenatal :

Antenatal Care : Regular Antenatal Care , Folic Acid And Iron Supplementation , Mother Age At Pregnancy : 28 Years Old , Maternal Infection , Maternal DM Or Hypertension , Drug Taking & Exposure To Radiation : -Ve .

✓ Natal :

Full Term Baby , Spontaneous Vaginal Delivery With No Complications To Mother Or Baby , Weight Of The Baby Was 3.5 Kg , The Baby Cry Immediately .

✓ Postnatal :

Discharged After 24 Hours On Doctor's Permission , No Neonatal Admission & No Complication .

- Nutritional History :

Exclusive Brest Feeding For 6 Months , Weaning At Age Of 6<sup>th</sup> Month With Fortified Infant Cereal , Now He Is On Rice , Yogurt , Fish Or Chicken .

- Developmental History : Now He Walks Upstairs , Make A Tower Of 4 Cubes , Say 2 Words Sentence .

- **Vaccination History:** Up-To-Date .
- **Family History:** -Ve Apart From Consanguinity .
- **Social History:** Good Living Conditions & Socio-Economic Status .
- **Drugs & Allergies:** -Ve .

#### **Summary**

18 Months Saudi Boy Admitted Through ER Complaining Of Fever / 4 Days . The Fever Was Acute Progressive High Grade Associated With Skin Rash , Convulsions , Diarrhea & Weight Loss . The Informations Taken From His Mother .

#### **+Ve Findings In Examination:**

- **General Examination:** Looking Ill , Crying , With Skin Rash Specially In Legs , Neck Stiffness And +Ve Brudzinski Sign .

# History Of Common Cases

## 9) Epilepsy :

### - Personal History :

Ahmed Hussain Ali , 7 Y/O Saudi Boy From Jazan , Admitted Through ER On 2-1-1436 H . Information Taken From His Mother .

### - C/O :

Abnormal Movement / 2 Days .

### - HPI :

He Is Known Case Of Epilepsy For 4 Years .

The Patient Was On Usual Status Till 2 Days Back When He Started To Has Abnormal Movement Which Was Abrupt In Onset , 2 Days Duration , Appear When Child Was Playing , The Condition Starts By Abnormal Movement Of Right Limb For 2 Minutes Then Stiffening Of All Body And Loss Of Consciousness , Then Tonic-Clonic Movement Of All Limb For 2 Minutes . The Child Micturate On Himself And Sleep For 45 Minutes And Feel Pain In All Muscle . There Is No Loss Of Memory , No Weakness & No Headache .

● Systemic Review : -Ve .

● Hospital Course : Underwent CBC , Blood Glucose Level , I.V Fluids , Medications And The Patient Is Improving .

### - Past History :

Diagnosed At KFCH , Since He Was 3 Y/O , Controlled On Phenytoin .

+Ve History Of 5 Previous Similar Attack With 2 Previous Admissions , The Last One Was 6 Months Back .

### - Peri-Natal History :

✓ Prenatal :

Antenatal Care : Regular Antenatal Care , Folic Acid And Iron Supplementation , Mother Age At Pregnancy : 28 Years Old , Maternal Infection , Maternal DM Or Hypertension , Drug Taking & Exposure To Radiation : -Ve .

✓ Natal :

Full Term Baby , Spontaneous Vaginal Delivery With No Complications To Mother Or Baby , Weight Of The Baby Was 3.5 Kg , The Baby Cry Immediately .

✓ Postnatal :

Discharged After 24 Hours On Doctor's Permission , No Neonatal Admission & No Complication .

### - Nutritional History :

Exclusive Brest Feeding For 6 Months , Weaning At Age Of 6<sup>th</sup> Month With Fortified Infant Cereal , Now He Eats Usual Family Food .



- **Developmental History**: He Is In 1<sup>st</sup> Primary Year School With Good Performance .
- **Vaccination History**: Up-To-Date .
- **Family History**: -Ve Apart From +Ve History Of Epilepsy In His Father & +Ve Consanguinity .
- **Social History**: Good Living Conditions & Socio-Economic Status .
- **Drugs & Allergies**: Phenytoin , 1 Time/Day , With Good Compliance .

#### **Summary**

7 Y/O Saudi Boy Known Case Of Epilepsy , Admitted Through ER Complaining Of Abnormal Movement / 2 Days . The Condition Started With Movement Of Right Hand , Then Became Generalized Tonic-Clonic , For 2 Minutes Then He Micturate On Himself & Sleep For 45 Minutes . The Informations Taken From His Mother .



**Examination In**  
**Pediatrics**

# Examination In Pediatrics

## 1- General Examination :

### - ABCDE :

- ✓ **Appearance** : Looks Well/Ill , Consciousness , Alert , Orientation To Time - Place - Person .
- ✓ **Body Built** : Average , Thin , Obese ( Depends On BMI ) .
- ✓ **Color** : Pale , Cyanosed , Erythematous .
- ✓ **Decubitus** : Patient's Sitting & Position .
- ✓ **Deformities** : Any Congenital Abnormality ( If You Find One Anomaly Search For Others )
- ✓ **Distress** : Difficulty In Breathing .
- ✓ **Environment** : Any Connections To Patient ( IV Line , Catheter , O<sub>2</sub> Mask , Wheelchair , ...Etc. "

### \*\* Note : Signs Of Respiratory Distress :

- Tachypnea .
- Tachycardia .
- Flaring Of Ala Nasi .
- Cyanosis .
- Using Of Accessory Muscles , Intercostal , Subcostal , Suprasternal Recession .
- Grunting .

### - Vital Signs :

**Table 3. Normal Vital Signs For Age Of Pediatric Patients.**

Age	Heart Rate (bpm)	Respiratory Rate (bpm)	Systolic Blood Pressure (mm Hg)	Diastolic Blood Pressure (mm Hg)
Newborn	90-180	30-50	60 ± 10	37 ± 10
1-5 months	100-180	30-40	80 ± 10	45 ± 15
6-11 months	100-150	25-35	90 ± 30	60 ± 10
1 year	100-150	20-30	95 ± 30	65 ± 25
2-3 years	65-150	15-25	100 ± 25	65 ± 25
4-5 years	65-140	15-25	100 ± 20	65 ± 15
6-9 years	65-120	12-20	100 ± 20	65 ± 15
10-12 years	65-120	12-20	110 ± 20	70 ± 15
13+ years	55-110	12-18	120 ± 20	75 ± 15

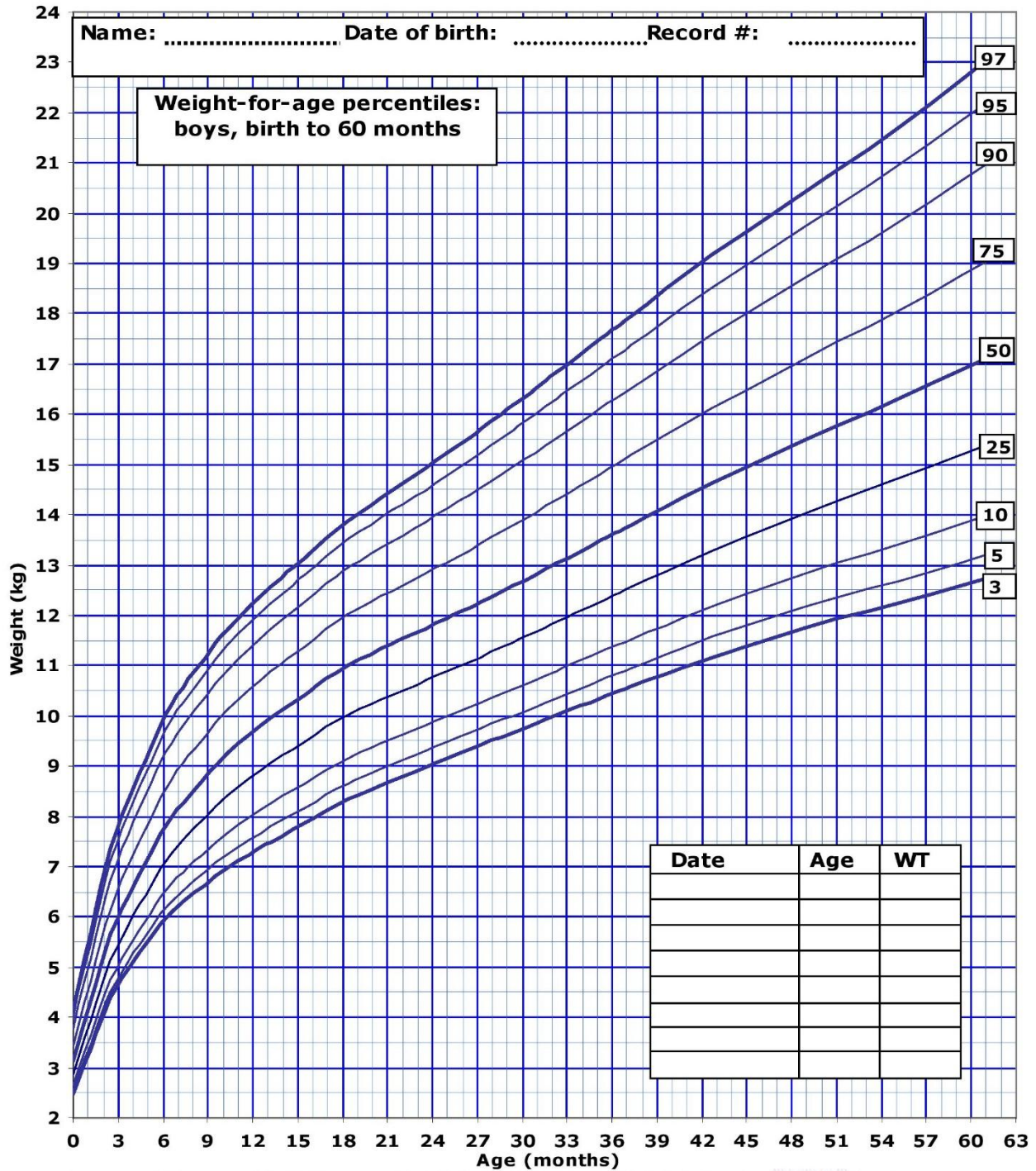
\*Adapted from: Silverman BK. Practical Information. In: *Textbook of Pediatric Emergency Medicine*, ©2006. Also: Jorden RC. Multiple Trauma. In: *Emergency Medicine: Concepts and Clinical Practice*, ©1990. All rights reserved. See References 94 and 95, respectively.

**Growth Parameters ( Anthropometric Measurements ) :**

- ✓ Weight, Height, Head Circumference .
- ✓ Plot Them On Standard Centile Chart .
- ✓ Failure To Thrive Or Well Nourished .

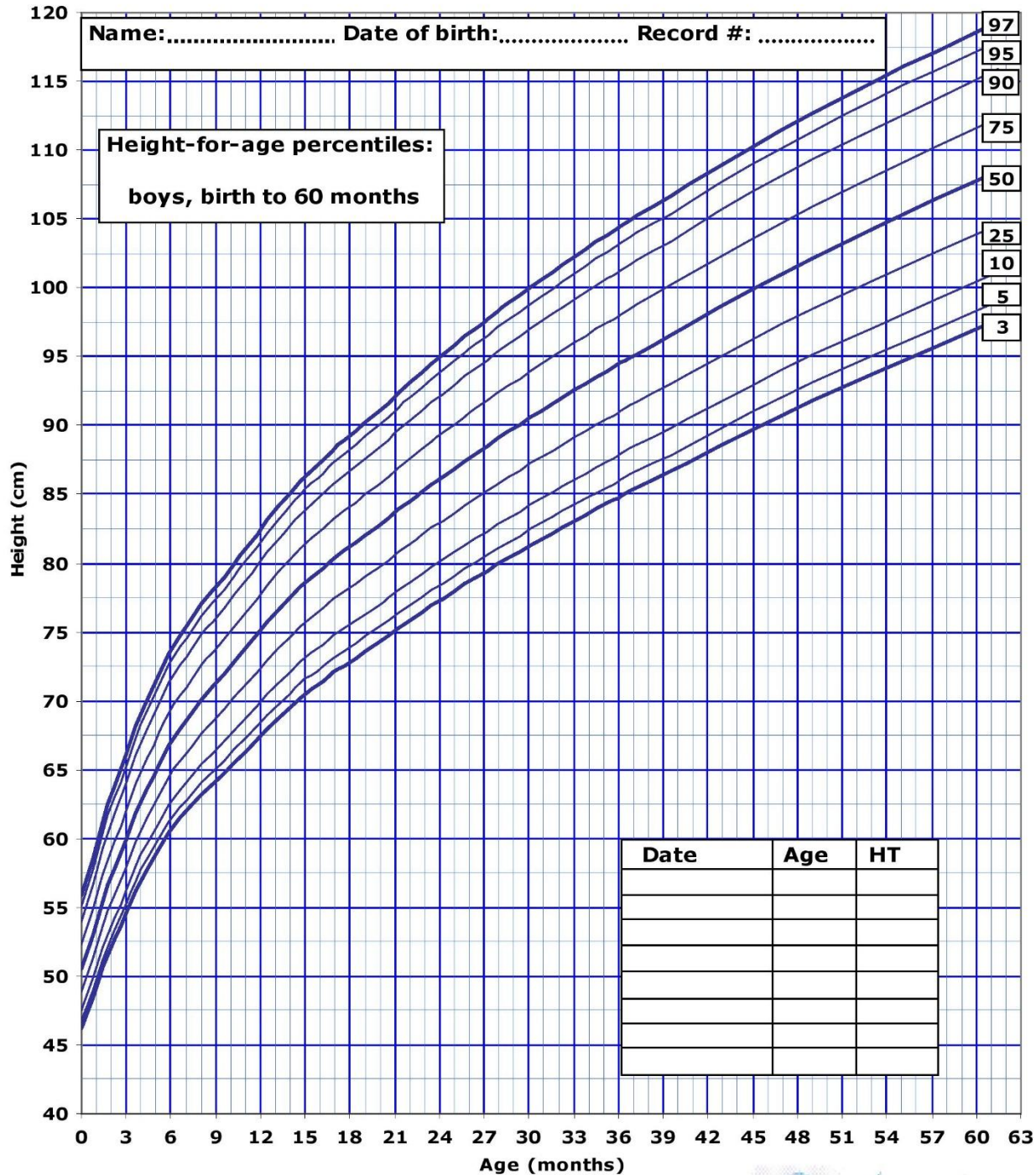
**The Growth Charts for Saudi Children and Adolescents**

Endorsed by The Health Services Council of Saudi Arabia No.29 (24/6/2007)



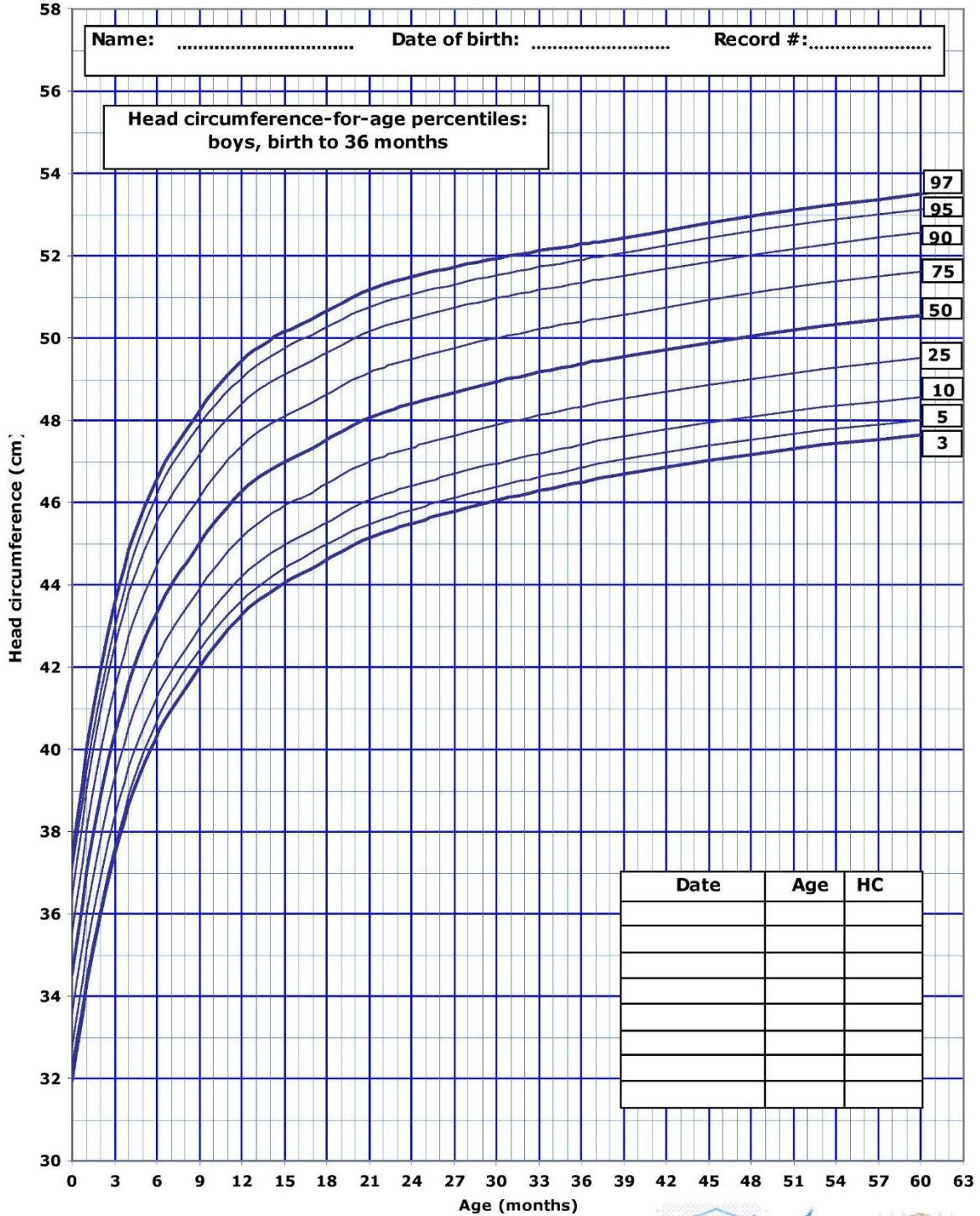
# The Growth Charts for Saudi Children and Adolescents

Endorsed by The Health Services Council of Saudi Arabia No. 29 (24/6/2007)



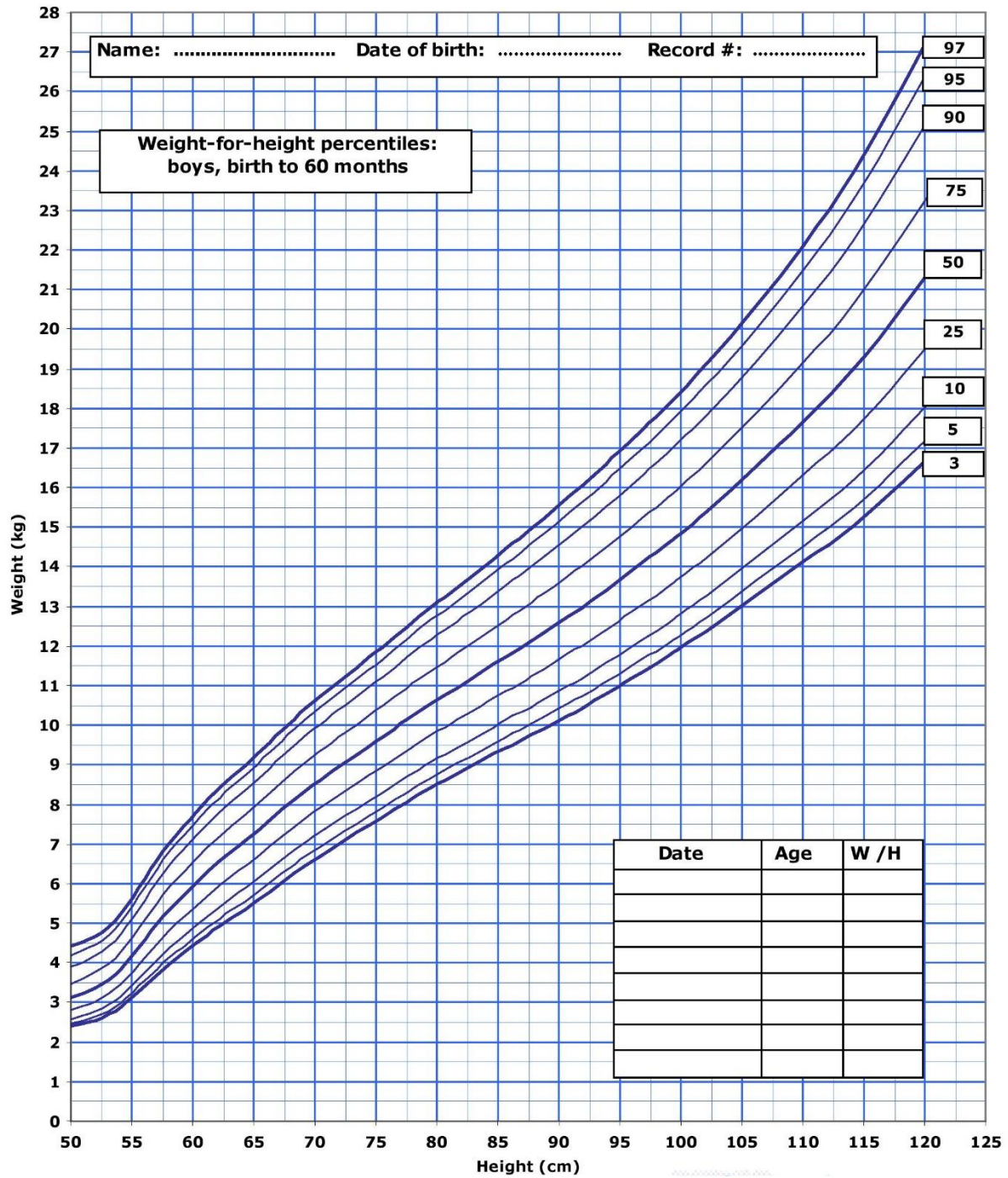
## The Growth Charts for Saudi Children and Adolescents

Endorsed by The Health Services Council of Saudi Arabia No. 29 (24/6/2007)



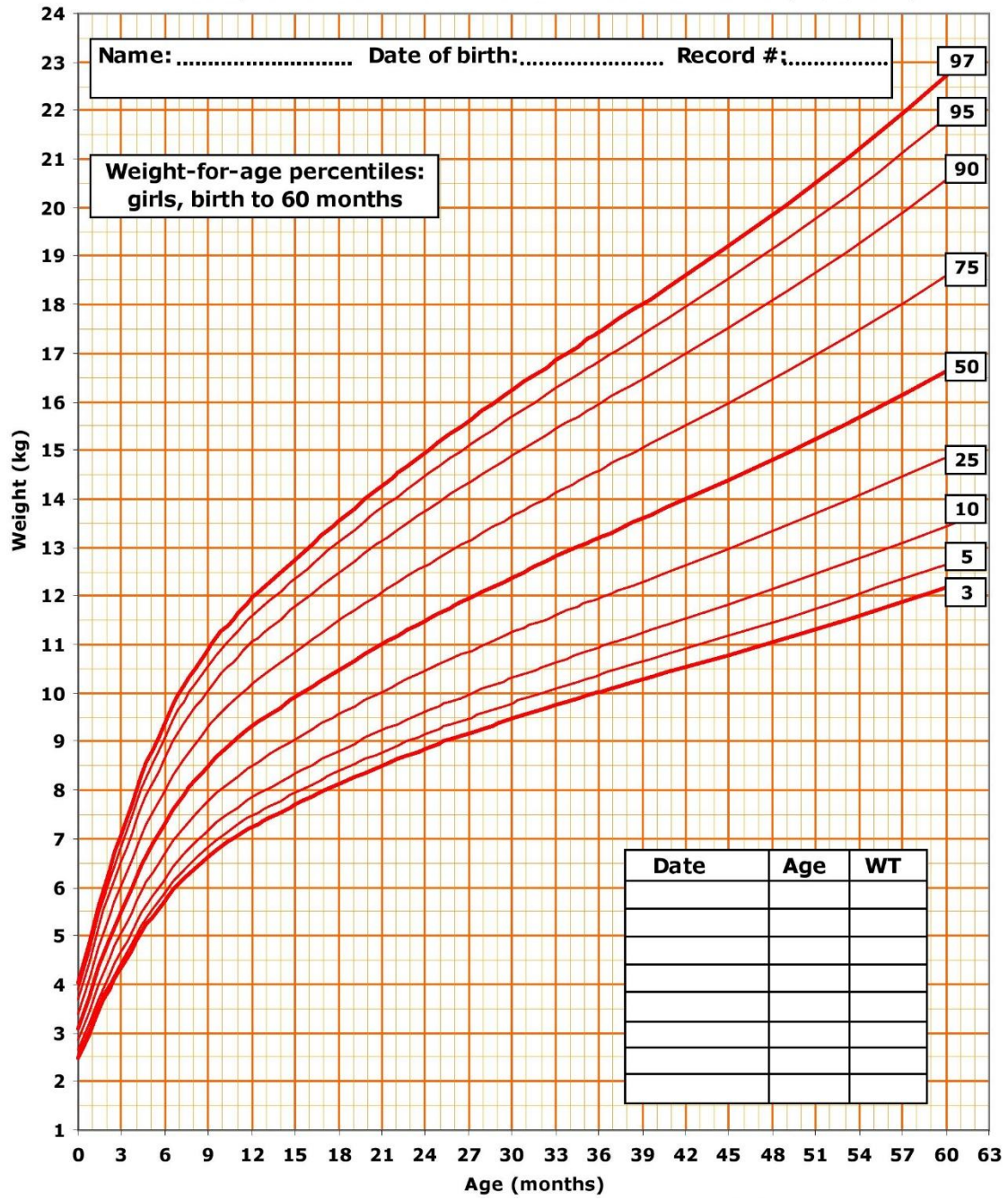
## The Growth Charts for Saudi Children and Adolescents

Endorsed by The Health Services Council of Saudi Arabia No. 29 (24/6/2007)



## The Growth Charts for Saudi Children and Adolescents

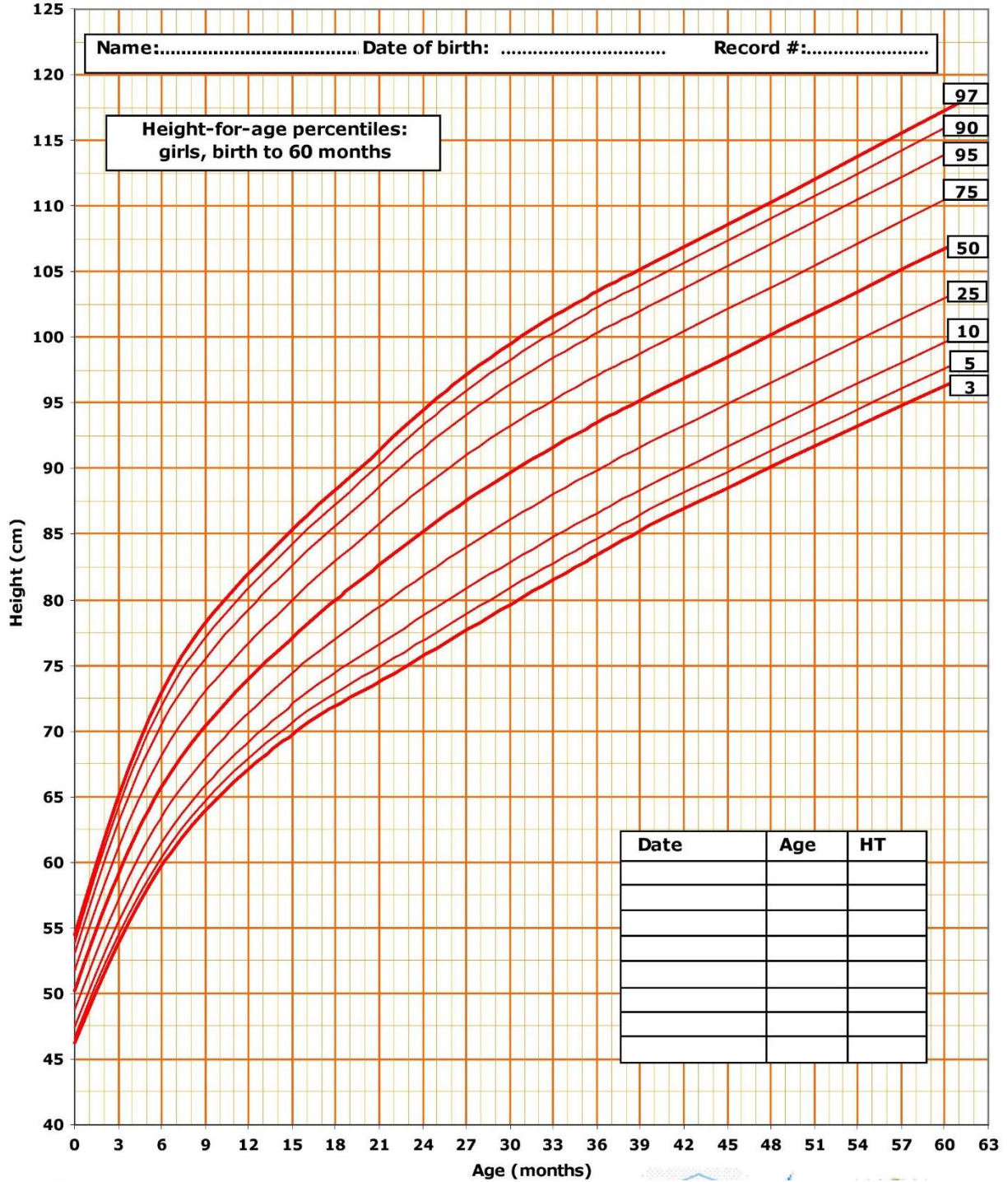
Endorsed by The Health Services Council of Saudi Arabia No. 29 (24/6/2007)





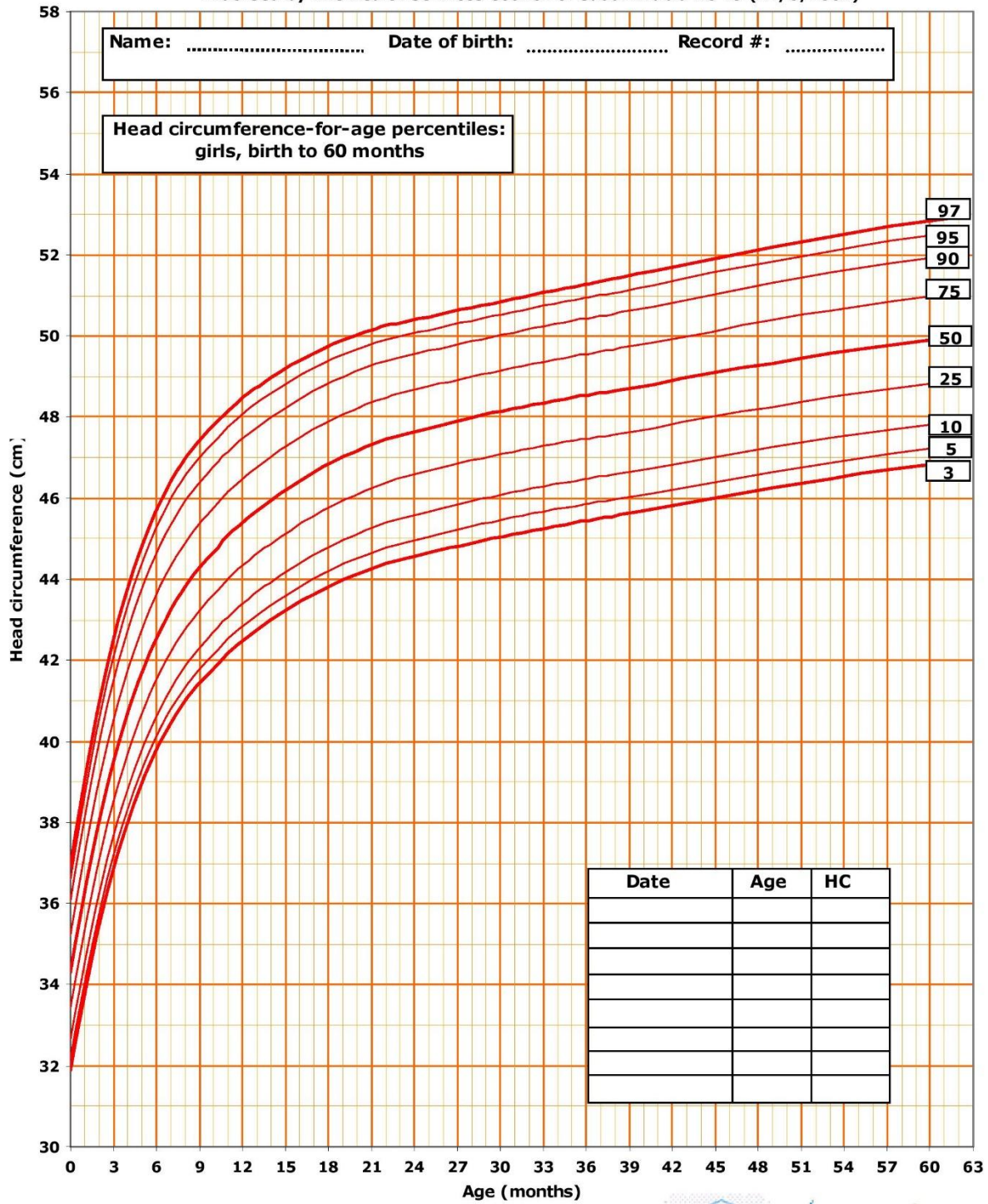
## The Growth Charts for Saudi Children and Adolescents

Endorsed by The Health Services Council of Saudi Arabia No.29 (24/6/2007)



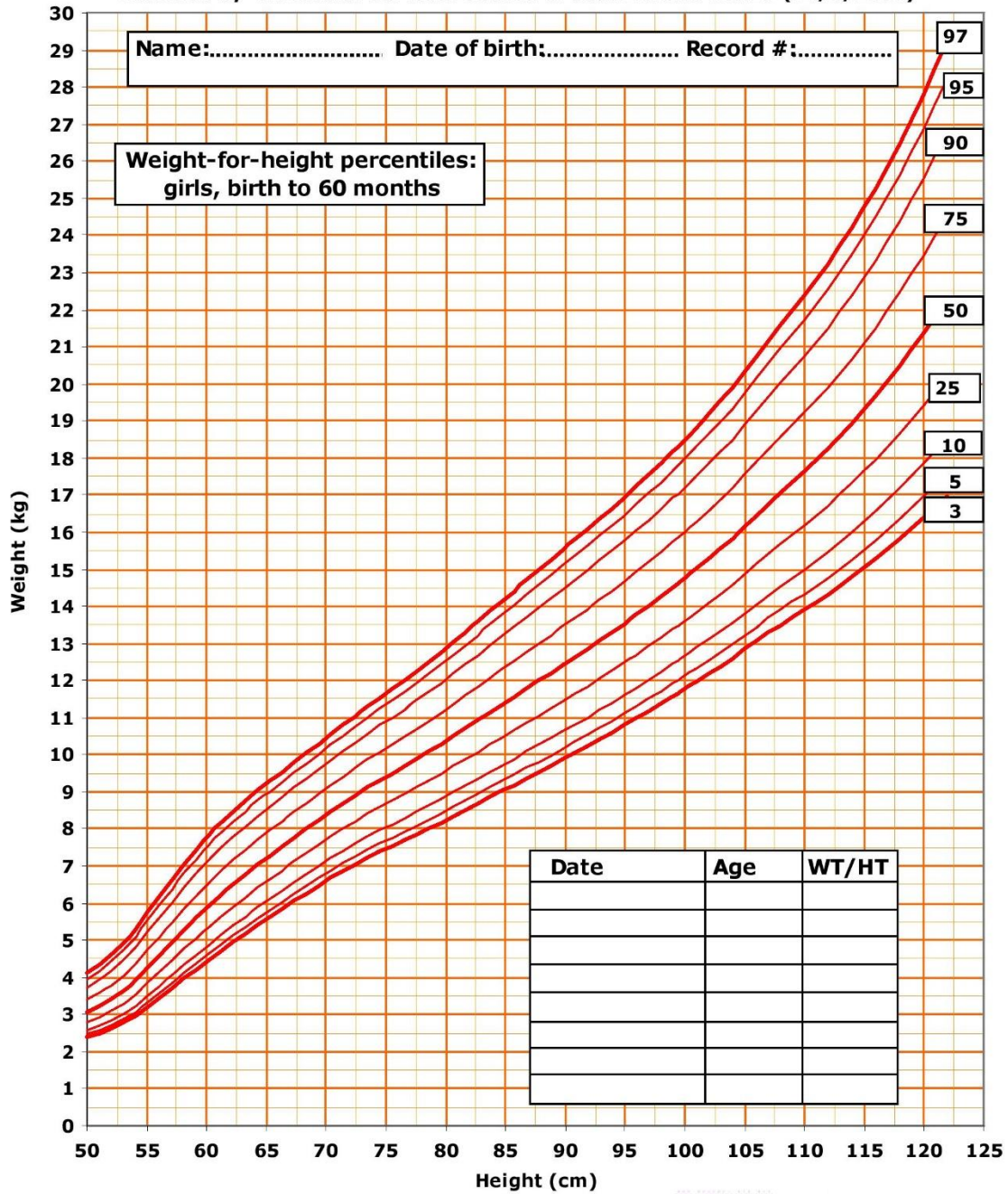
## The Growth Charts for Saudi Children and Adolescents

Endorsed by The Health Services Council of Saudi Arabia No 29 (24/6/2007)



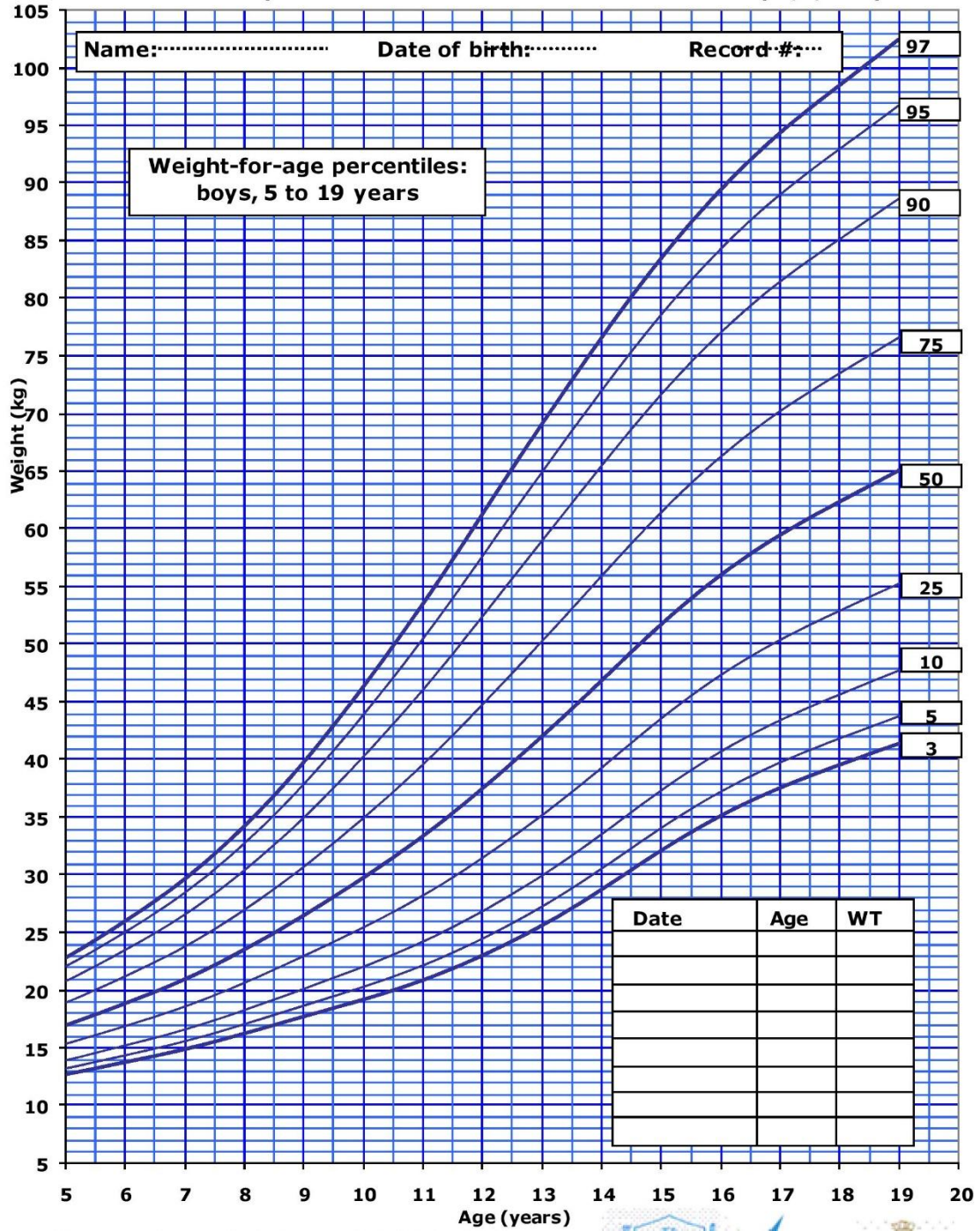
# The Growth Charts for Saudi Children and Adolescents

Endorsed by The Health Services Council of Saudi Arabia No. 29 (24/6/2007)



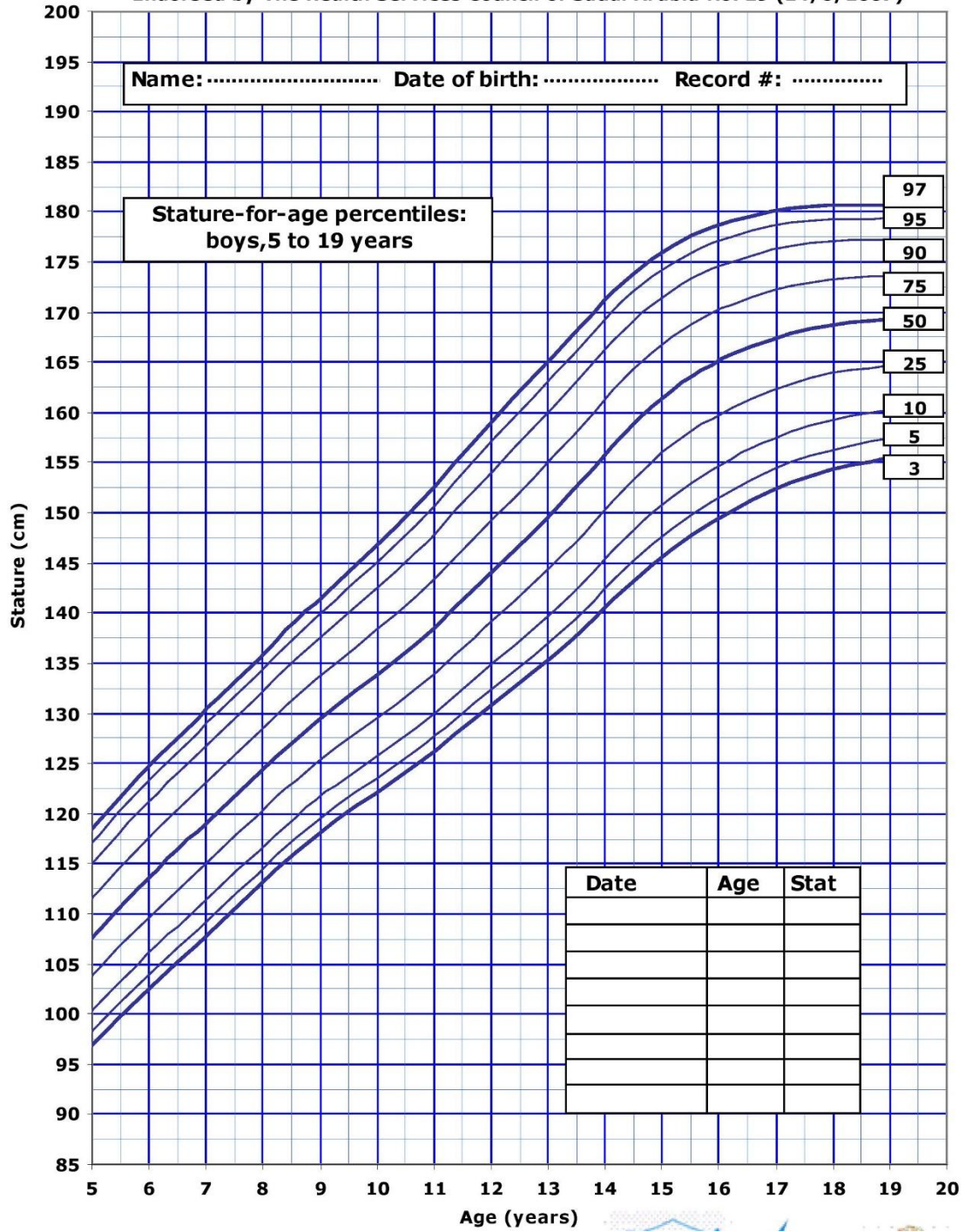
# The Growth Charts for Saudi Children and Adolescents

Endorsed by The Health Services Council of Saudi Arabia No. 29 (24/6/2007)



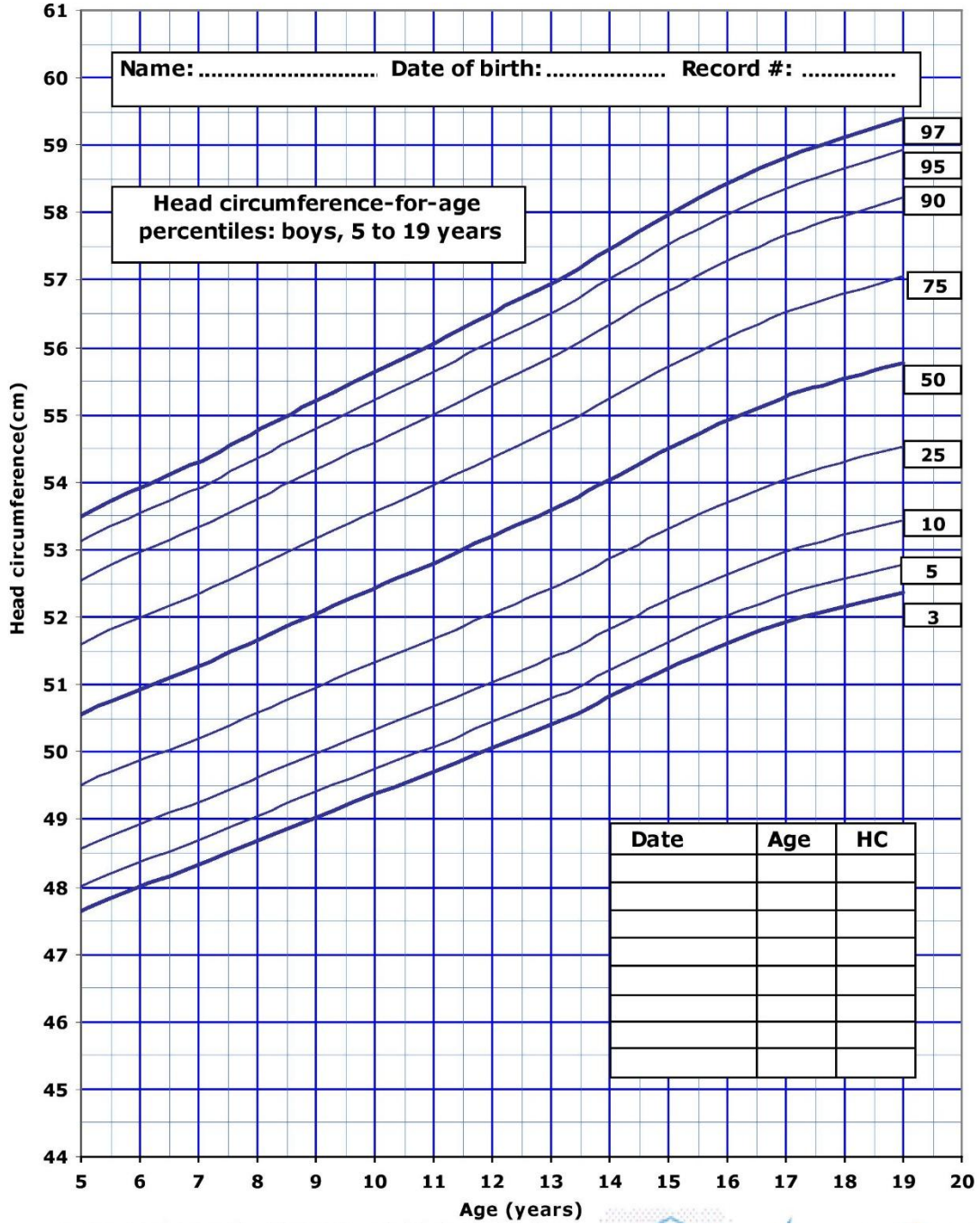
# The Growth Charts for Saudi Children and Adolescents

Endorsed by The Health Services Council of Saudi Arabia No. 29 (24/6/2007)



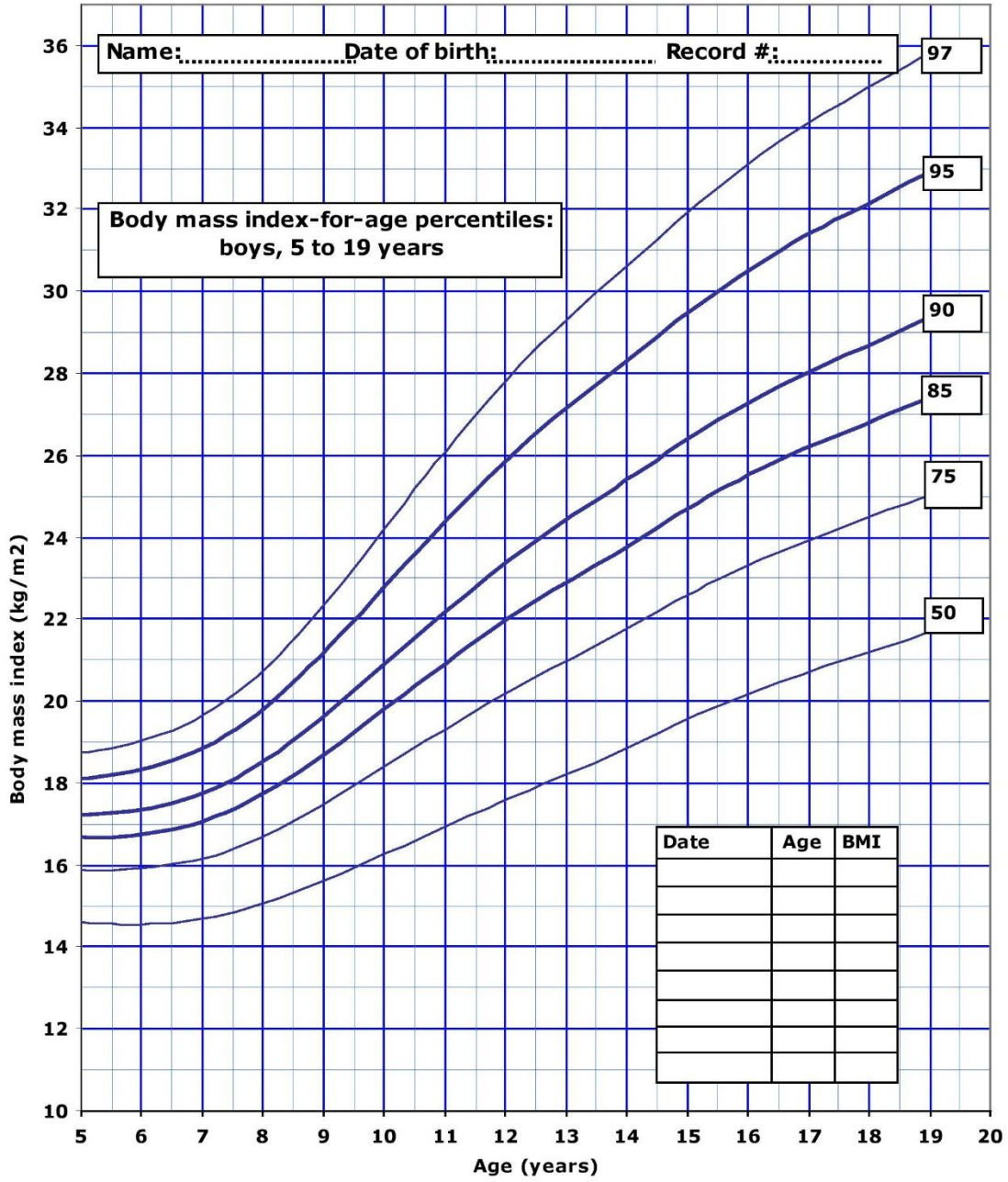
# The Growth Charts for Saudi Children and Adolescents

Endorsed by The Health Services Council of Saudi Arabia No. 29 (24/6/2007)



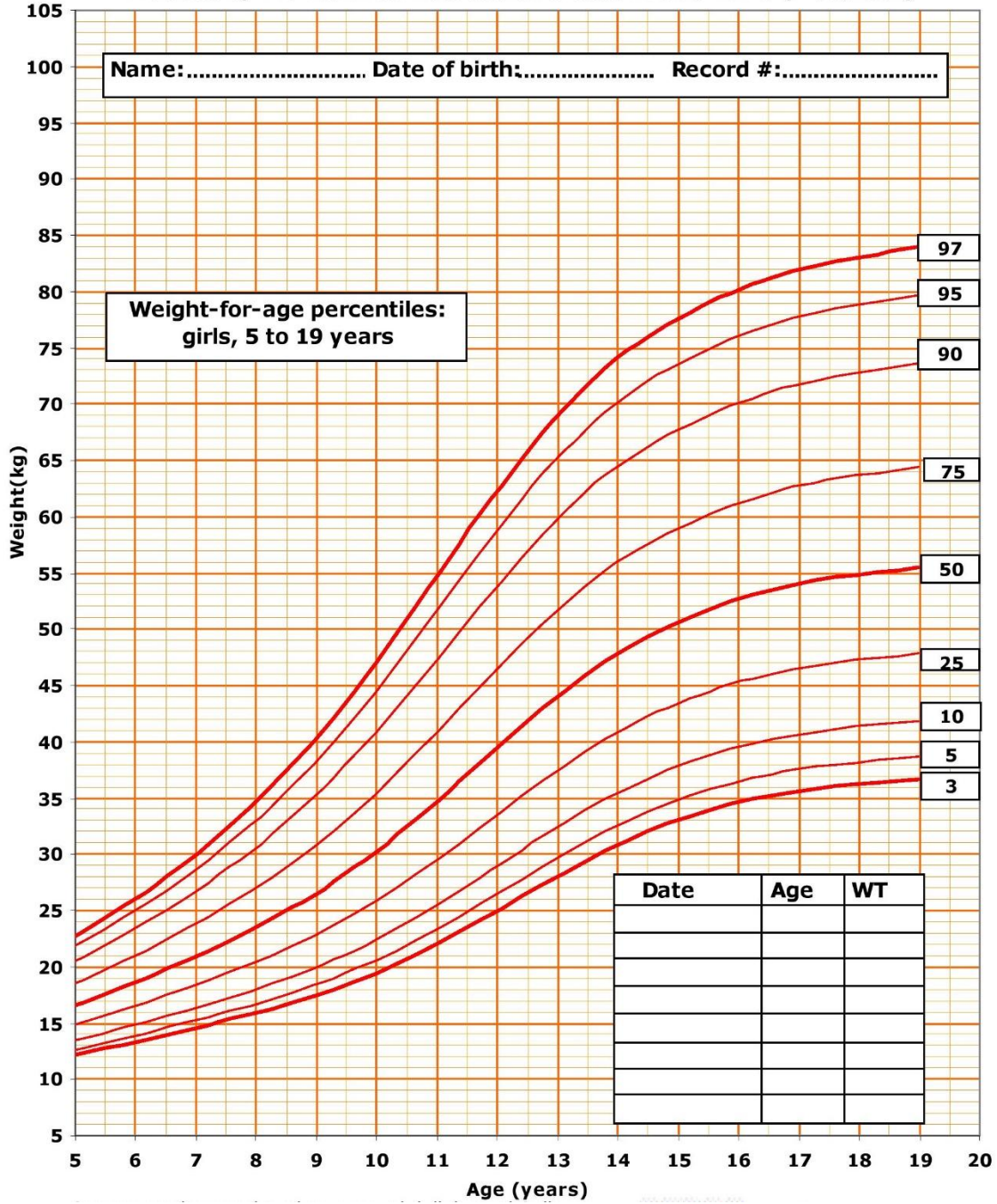
# The Growth Charts for Saudi Children and Adolescents

Endorsed by The Health Services Council of Saudi Arabia No. 29 (24/6/2007)



# The Growth Charts for Saudi Children and Adolescents

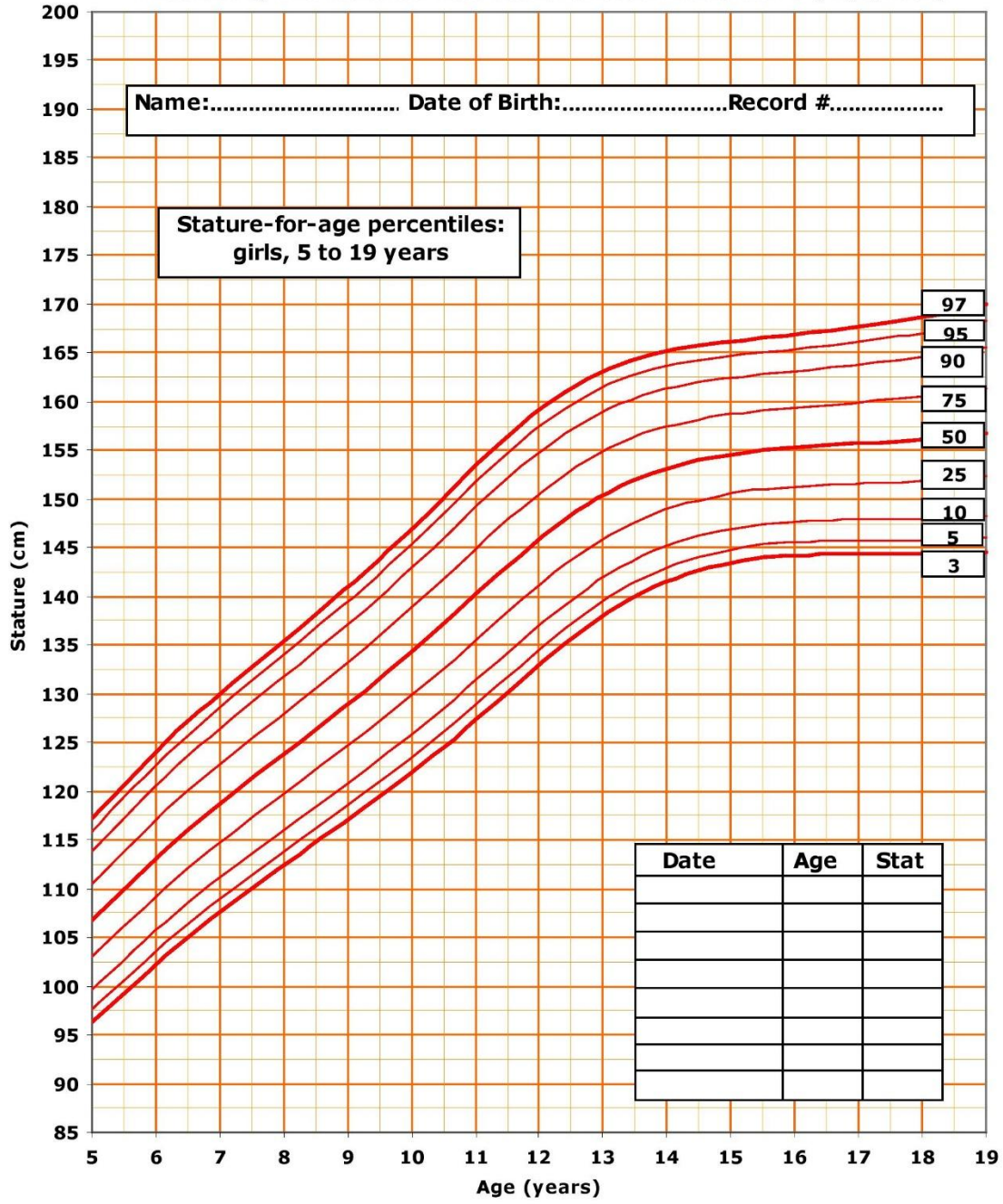
Endorsed by The Health Services Council of Saudi Arabia No. 29 (24/6/2007)





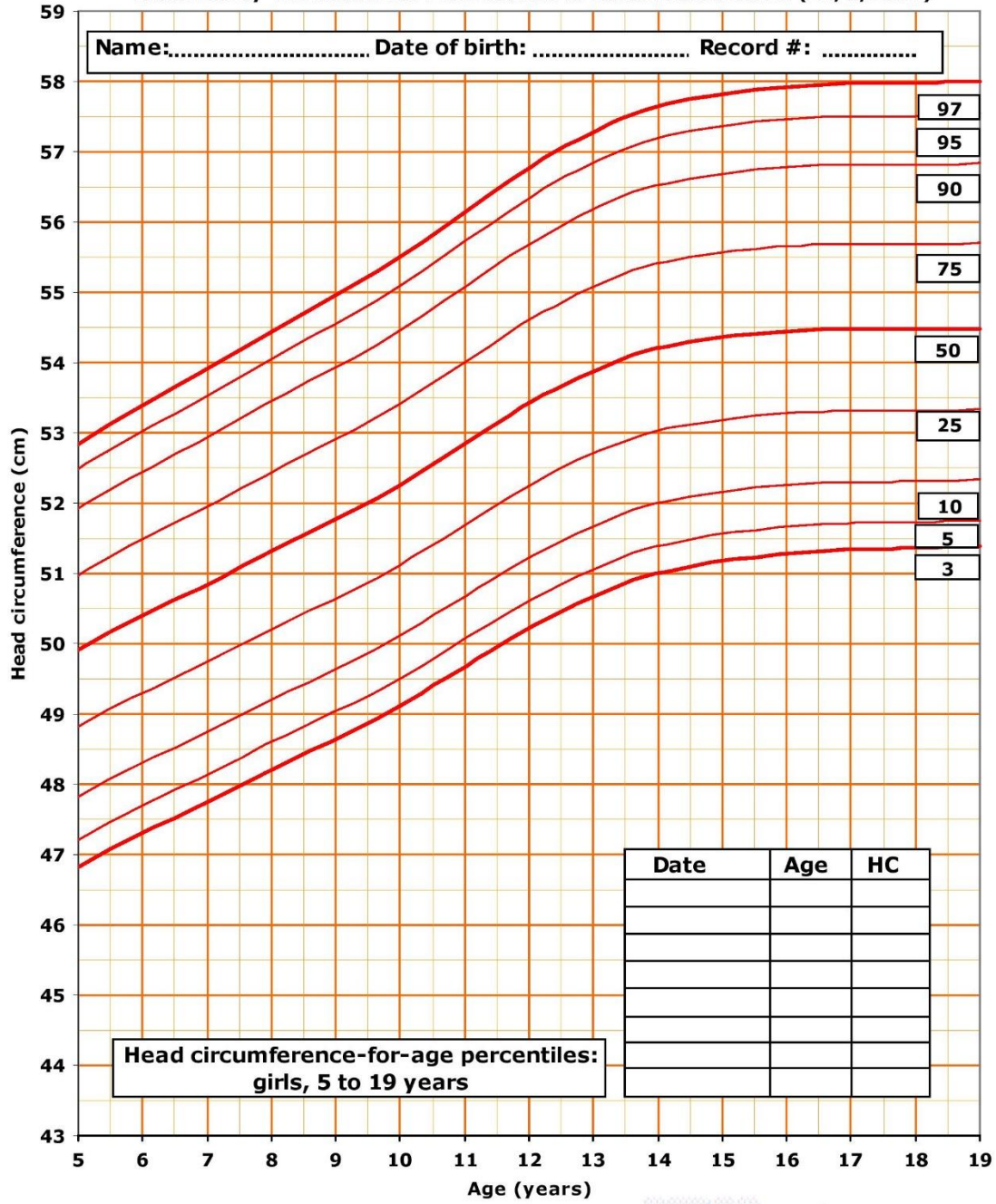
# The Growth Charts for Saudi Children and Adolescents

Endorsed by The Health Services Council of Saudi Arabia No. 29 (24/6/2007)



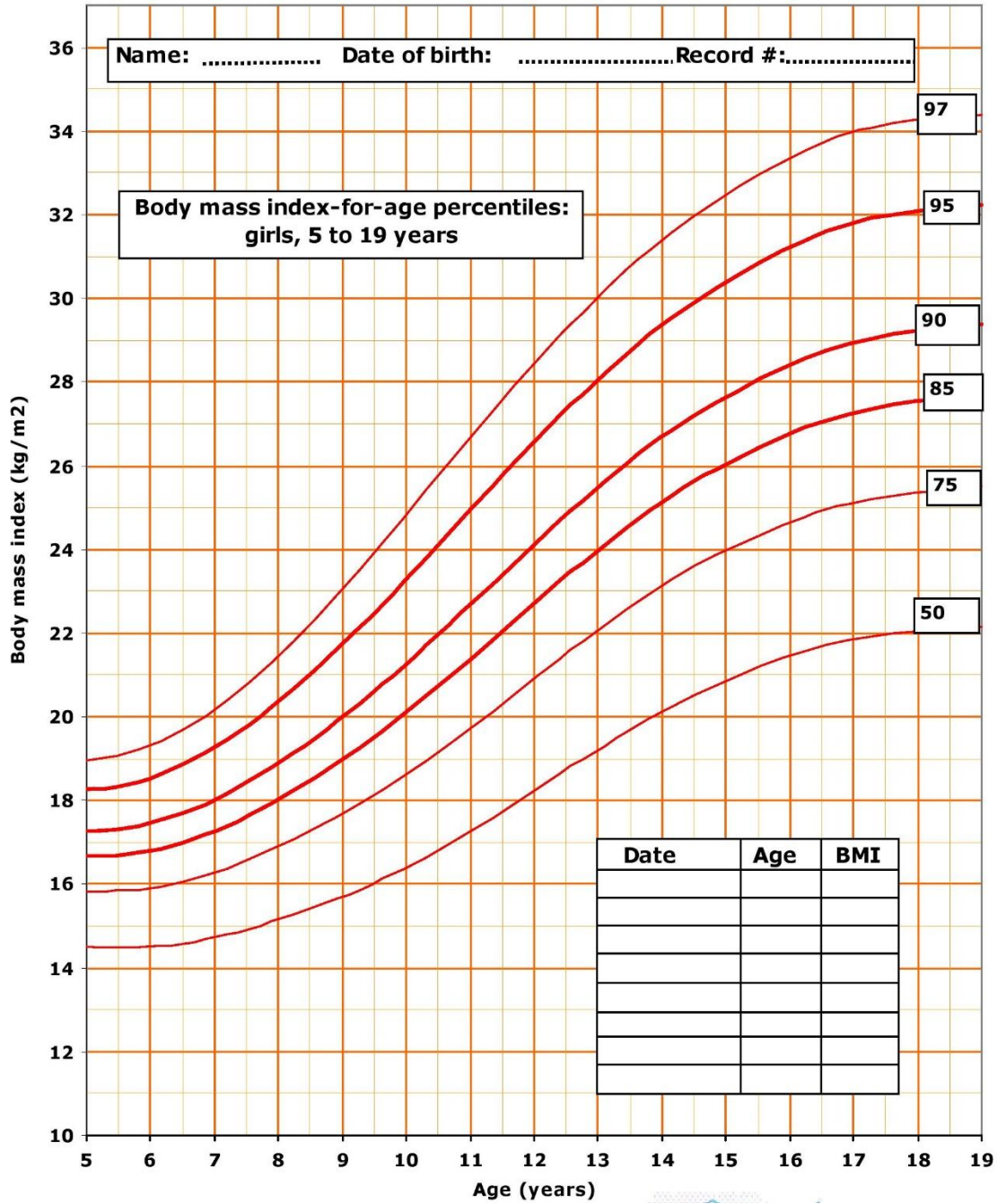
# The Growth Charts for Saudi Children and Adolescents

Endorsed by The Health Services Council of Saudi Arabia No.29 (24/6/2007)



# The Growth Charts for Saudi Children and Adolescents

Endorsed by The Health Services Council of Saudi Arabia No. 29 (24/6/2007)



## - Hands : ( Compare Both Hands Together )

### ✓ Nails :

- Clubbing . ( Pic.1 )
- Capillary Refill . ( Pic.2 )
- Splinter Hemorrhage . ( Pic.3 )
- Peripheral Cyanosis . ( Pic.4 )
- Koilonychia . ( Pic.5 )
- Leukonychia . ( Pic.6 )

### ✓ Palm :

- Muscle Wasting .
- Palmar Erythema . ( Pic.7 )
- Pallor Which Seen In Palmar Creases . ( Pic.8 )
- Osler Node Which Seen In Palmar Surface Of Fingertip .
- Janeway Lesions .

### ✓ Tremors :

- Flapping Tremor , Fine Tremor .

### ✓ Arm :

- Tendon Xanthoma ( Yellowish Discoloration Of Tendon At Wrist ) .
- Arterial Pulse : ( Radial , Brachial ) Comments On :
  - Rate : For 30 Seconds  $\times$  2 OR 15 Seconds  $\times$  4 ( If Regular ) .
  - Rhythm : Regular Or Irregular .
  - Volume : Large , Average , Low .
  - Character : Collapsing Pulse , Slow Rising Pulse , Pulsus Paradoxus , Pulsus Alternans .
  - Radio-Radial , Radio-Brachial & Radio-Femoral Delay
- Blood Pressure .
- Bruises , Scratch Marks , Spider Nevi ( In Face - Neck - Upper Chest Also ) .

## - Head & Neck :

### ✓ Eye :

- Jaundice : Look At Upper Bulbar Conjunctiva While Child Is Looking Downward . ( Pic.9 )
- Pallor : Look At Lower Palpebral Conjunctiva While Child Is Looking Upward . ( Pic.10 )
- Peri-Orbital Edema . ( Pic.11 )

### ✓ Nose :

- Active Ala Nasi .
- Presence Of Discharge .

### Grades Of Clubbing :

- 1 > Fluctuation Of The Nail Bed .
- 2 > Obliteration Of The Lovibond Angle .
- 3 > Parrot Beak Appearance Or Drum Stick Appearance .
- 4 > Hypertrophic Osteo-Arthropathy ( HOA ) .

✓ **Mouth:**

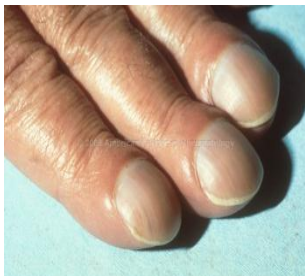- Cyanosis : Lips For Peripheral Cyanosis & Tongue For Central Cyanosis . ( Pic.12 )
- Jaundice .
- Aphthous Ulcer & Candida , Glossitis , Mouth Hygiene , Odour Of Breath .

✓ **Neck :**

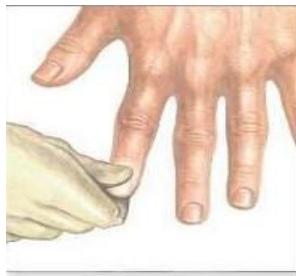- Lymph Nodes .
- Jugular Vein .
- Carotid Artery .

- **Lower Limbs :**

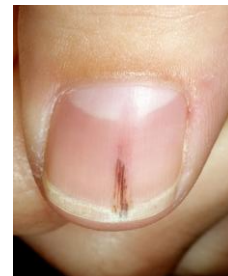- Skin Changes , Muscle Wasting , Any Deformities .
- Edema : Pitting / Non-Pitting - Unilateral / Bilateral - Level . ( Pic.13 )" Also Check The Sacral Edema "
- Pulse : Femoral - Popliteal - Dorsalis Pedis - Posterior Tibial . ( Pic.14,15 )



**Pic.1**



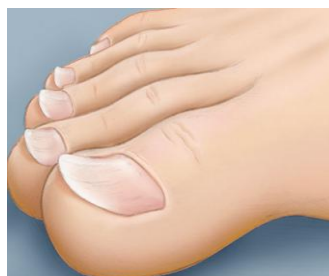**Pic.2**



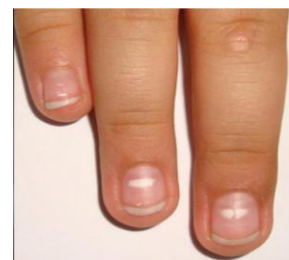**Pic.3**



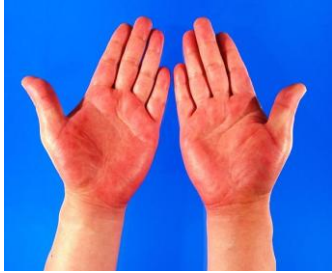**Pic.4**



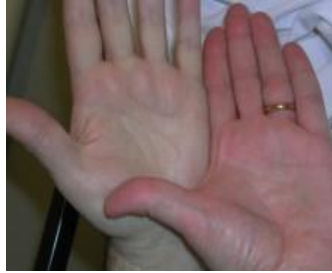**Pic.5**



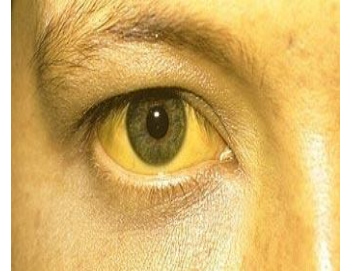**Pic.6**



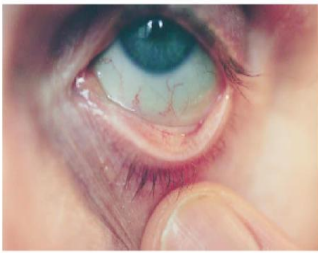**Pic.7**



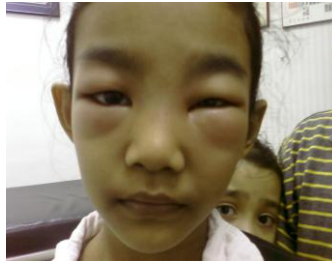**Pic.8**



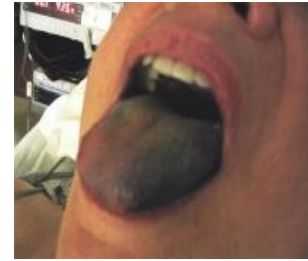**Pic.9**



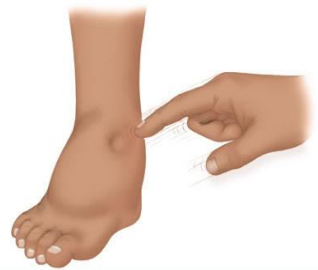**Pic.10**



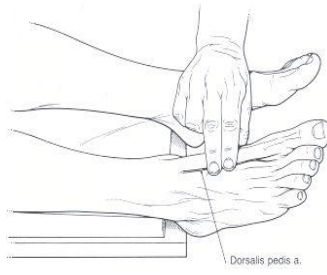
**Pic.11**



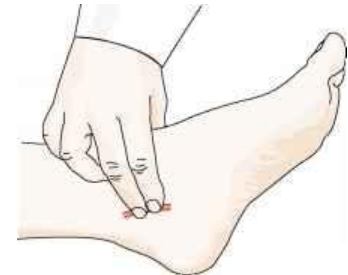**Pic.12**



**Pic.13**



**Pic.14**



**Pic.15**

## 2- Local Examination :

### " Cardio-Vascular Examination "

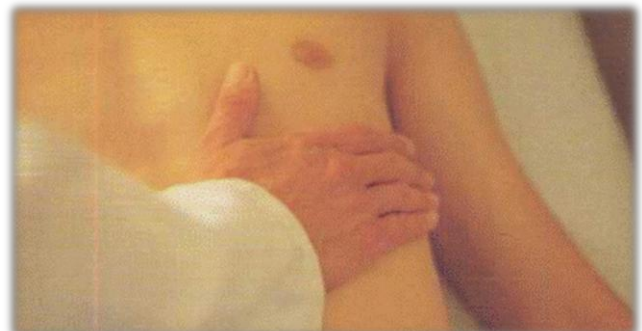- Introduce Yourself .
- Take Permission .
- Explain What You Are Going To Do .
- Maintain Privacy .
- Wash Your Hand .
- Exposure ( Up To The Umbilicus ) .

#### A- Important Points In General Examination :

- General Look & Environment .
- Signs Of Respiratory Distress .
- Vital Signs : Specially Pulse & BP .
- Central & Peripheral Cyanosis .
- Pallor & Jaundice .
- In Hand : Clubbing , Splinter Hemorrhage , Osler Nodules , Janeway Lesion .
- Lower Limb Edema .
- Sacral Edema .
- Growth Parameters .

#### B- Pericardium Examination :

- **Inspection For :**
  - ✓ Asymmetry .
  - ✓ Any Bulge Or Deformity .
  - ✓ Previous Scars .
  - ✓ Any Visible Pulsation ( Apex Beat ) .
- **Palpation : " Don't Forget To Warm Your Hand "**
  - ✓ Apex Beat . ( Pic.1 )
  - ✓ Parasternal Heave .
  - ✓ Any Thrills .
  - ✓ Palpable P<sub>2</sub> .
  - ✓ Carotid Pulsation .



Pic.1

- **Auscultation :**

- ✓ S1, S2.
- ✓ Any Additional Sounds : S3, S4, Opening Snap .
- ✓ Murmurs : Comment On ( Site Of Maximum Intensity & Radiation & Time & Grade ) .

**\*\* Note :** **Auscultatory Areas :** ( Pic.2 )

- Mitral Area : 5<sup>th</sup> Left Intercostal Space ( ICS ) Mid-Clavicular Line .
- Tricuspid : 4<sup>th</sup> ICS Left Sternal Edge .
- Pulmonary Area : 2<sup>nd</sup> Left ICS .
- Aortic Area : 2<sup>nd</sup> Right ICS .
- Left Sub-Clavicular Area For PDA Murmur .
- In The Back Between 2 Scapulae For Coarctation Of Aorta Murmur .

**C- At The End Of Cardiovascular Examination , You Must Check :**

- **In Abdomen :**

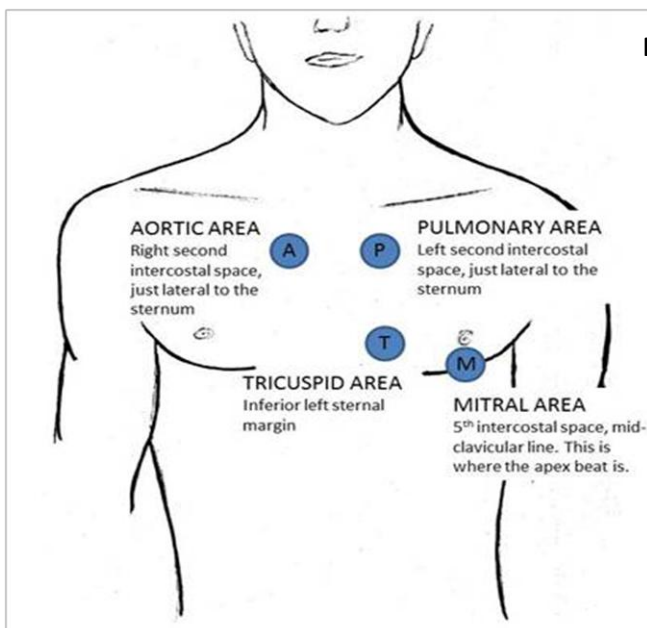
- ✓ Palpate The Liver & Spleen ( If It Enlarge Or Not ) .

- **Lungs :**

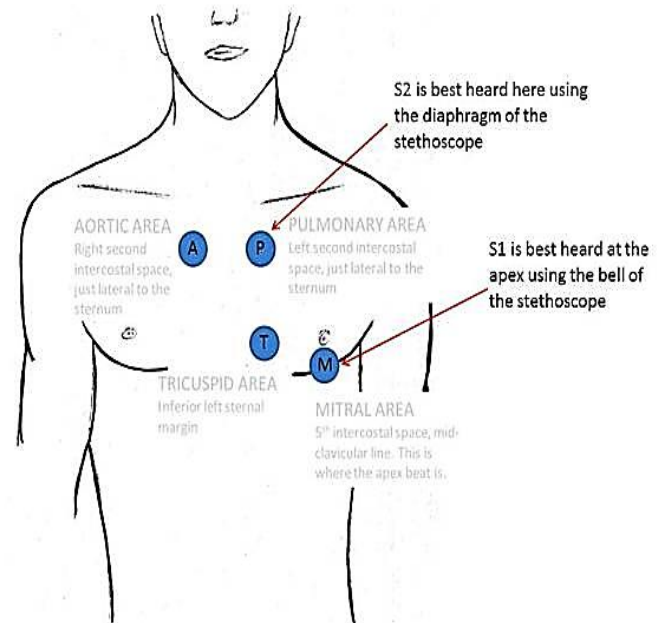
- ✓ Auscultate Bases Of Lungs For Crepitations .

- **Lower Limbs :**

- ✓ Edema , Cyanosis , Clubbing .



Pic.2





# " Respiratory Examination "

- Introduce Yourself .
- Take Permission .
- Explain What You Are Going To Do .
- Maintain Privacy .
- Wash Your Hand .
- Exposure ( Full Exposure Of The Trunk ) .

## A- Important Points In General Examination :

- General Look & Environment .
- Signs Of Respiratory Distress , Audible Wheeze , Stridor .
- Vital Signs: Pulse , BP , RR .
- Central & Peripheral Cyanosis .
- Pallor , Jaundice .
- In Hand : Pallor , Clubbing .
- Lower Limb Edema & Sacral Edema .
- Growth Parameters .

## B- Anterior Chest Examination ( From Front ):

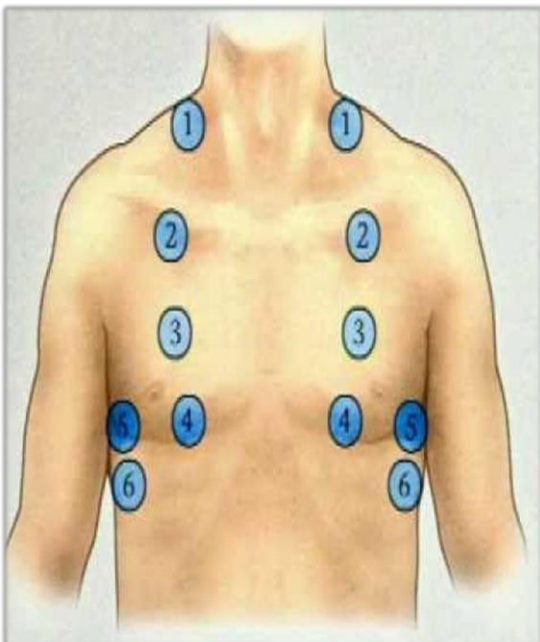
- **Inspection :**
  - ✓ Shape & Symmetry .
  - ✓ Type Of Breathing ( Abdomino-Thoracic , Thoraco-Abdominal ) .
  - ✓ Use Of Accessory Muscles .
  - ✓ Visible Pulsations .
  - ✓ Apex Pulse .
  - ✓ Any Scars , Skin Changes , Chest Wall Deformities ( Pectus Carinatum , Pectus Excavatum ) .
- **Palpation :** " Don't Forget To Warm Your Hand "
  - ✓ Position Of Trachea : By Comparing The Gap Between The Sternal Head Of Sternomastoid Muscle & Tracheal Margin By The Index Finger .
  - ✓ Position Of Apex Beat .
  - ✓ Tactile Vocal Fremitus ( In Older Children ) : Ask Patient To Say 99 ( In English ) OR 44 ( In Arabic ) .
  - ✓ Chest Expansion ( In Older Children ) .

- **Percussion ( Pic.1 ): " Light Percussion "**
  - ✓ Direct Percussion On The Clavicle .
  - ✓ Separate Your Fingers From Each Other And Press The Middle Finger In The ICS .
  - ✓ Percuss By The Middle Finger Over The Middle Finger Of Other Hand . ( Pic.2 )
  - ✓ Comparative Percussion ( Right & Left ) .
  - ✓ Start From Supraclavicular Area Then Downwards , With Axillae .
  
- **Auscultation :**
  - ✓ Auscultate The Supra-Clavicular Area By The Bell Of Stethoscope .
  - ✓ Auscultate The Same Areas Of Percussion By The Diaphragm Of Stethoscope .
  - ✓ Comment On The Air Entry ( Equal , Reduced ) .
  - ✓ Comment On The Type Of Breathing ( Vesicular , Bronchial ) .
  - ✓ Comment On Added Sounds ( Wheeze , Crackles ) & If It Is Inspiratory OR Expiratory .
  - ✓ Comment On Vocal Resonance ( In Older Children ) .

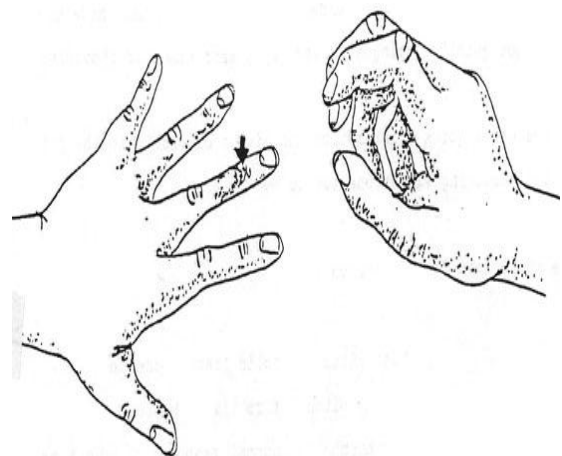
**\*\* Notes :**

- Bronchial Breathing Is Normally Heard Over Trachea & Main Bronchi ( In The 2<sup>nd</sup> ICS ) .

**Pic.1**



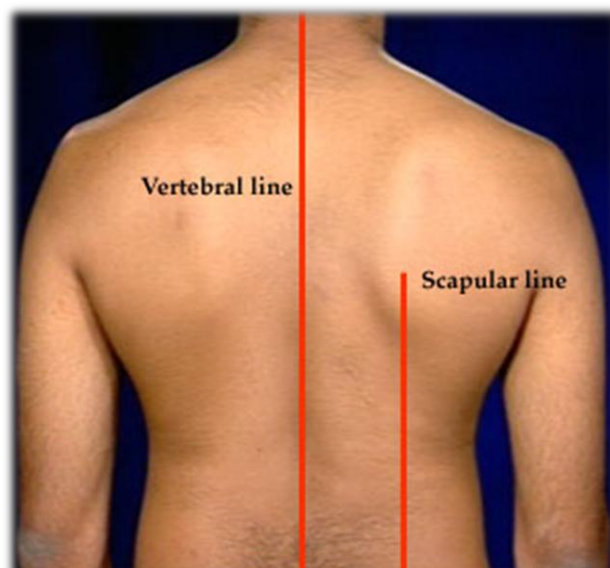
**Pic.2**



## C- Posterior Chest Examination ( From The Back ):

- **Inspection :**
  - ✓ Shape & Symmetry .
  - ✓ Any Scars , Skin Changes .
  - ✓ Any Deformities ( Scoliosis , Kyphosis ) .
  
- **Palpation : " Don't Forget To Warm Your Hand "**
  - ✓ Tactile Vocal Fremitus ( In Older Children ) : Ask Patient To Say 99 ( In English ) OR 44 ( In Arabic ) .
  - ✓ Chest Expansion ( In Older Children ) .
  
- **Percussion : " Heavy Percussion "**
  - ✓ Percuss The Lung Apex ( Light Percussion ) .
  - ✓ Percuss The Superior Border Of Scapula .
  - ✓ Percuss Between Scapular Line & Vertebral Line . ( Pic.1 )
  - ✓ Comparative Percussion ( Right & Left ) .
  
- **Auscultation :**
  - ✓ Auscultate The Lung Apex .
  - ✓ Auscultate The Same Areas Of Percussion By The Diaphragm Of Stethoscope .
  - ✓ Comment On The Air Entry ( Equal , Reduced ) .
  - ✓ Comment On The Type Of Breathing ( Vesicular , Bronchial ) .
  - ✓ Comment On Added Sounds ( Wheeze , Crackles ) & If It Is Inspiratory OR Expiratory .
  - ✓ Comment On Vocal Resonance ( In Older Children ) .

Pic.1



# " GIT Examination "

- Introduce Yourself .
- Take Permission .
- Explain What You Are Going To Do .
- Maintain Privacy .
- Wash Your Hand .
- Exposure ( Full Nipples To Mid-Thigh ) .

## A- Important Points In General Examination :

- General Look & Environment .
- Vital Signs : Pulse , BP , RR , Temp .
- Pallor , Jaundice , Peri-Orbital Edema .
- In Hand : Pallor , Clubbing , Koilonychia , Leukonychia , Palmar Erythema , Muscle Wasting .
- Spider Nevi .
- Mouth Hygiene , Inflammations , Pallor , Cyanosis .
- Lymph Nodes .
- Lower Limb Edema & Sacral Edema .
- Growth Parameters .

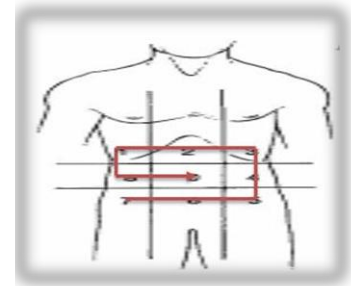
## B- Abdominal Examination :

### Inspection :

- ✓ Contour ( Stand At The Patient's Feet ) .
- ✓ Movement With Respiration ( Stand In The Right Side Of The Patient ) .
- ✓ Skin Changes , Scars , Colostomy , Tubes .
- ✓ Subcostal Angle .
- ✓ Epigastric Pulsation .
- ✓ Divarication Of Recti .
- ✓ Umbilicus .
- ✓ Hernia Orifices .
- ✓ Dilated Veins .

- **Palpation :**

- Be At The Level Of The Patient .
- Keep Looking At The Face Of The Patient To Observe Painful Expression .
- Warm Your Hands .
- Ask The Patient Where It Hurts And Start Away From Pain ( In Older Children ) .
- Palpate Gently Keeping Hand Flat .



**Pic.1**

1- **Superficial Palpation :** ( Pic.1 )

- i. Start Away From Pain , If There Is No Pain You Have To Start From Right Iliac Fossa And Proceed Clock-Wise To End In Supra-Pubic Area .
- ii. Comment On : Hotness , Tenderness , Rigidity & Superficial Masses .

2- **Deep Palpation :** For Organomegally And Deep Masses .

**Liver**

- Start From Rt. Iliac Fossa And Palpate Towards The Right Costal Margin With Examining Hand Aligned Parallel To The Right Costal Margin .
- **If Palpable , Comment On :**
  - ✓ Size ( Enlarged - Shrunken ) .
  - ✓ Edge ( Sharp - Rounded , Irregular ) .
  - ✓ Consistency ( Soft - Firm - Hard ) .
  - ✓ Surface ( Smooth - Nodular ) .
  - ✓ Tenderness .
  - ✓ Pulsation .
  - ✓ Liver Span .

**\*\* Notes :** In Case Of Tense Ascites , You Can Palpate By Dipping Method :

- ✓ Fingers Tips Are Pressed With A Quick Stabbing Motion Into The Abdomen , A Tapping Sensation Is Felt By The Organ Due To Displacement By Fluid .

## Spleen

- Start Palpation In The Right Iliac Fossa With Patient Breath In And Out .
- Move Your Hand Toward The Left Costal Margin .
  
- **If Palpable , Comment On :**
  - ✓ Size .
  - ✓ Notch .
  - ✓ Consistency .
  - ✓ Surface .
  - ✓ Tenderness .
  
- **If Not Palpable , Use The Following Methods :**
  - ✓ Roll The Patient Over Right Lateral Position , And Palpate Again While Pt. Is Taking Deep Breath
  - ✓ Bimanual Examination .
  - ✓ Hooking Method .
  - ✓ Dipping Method In Tense Ascites .
  - ✓ Percussion Of Traub's Area .

## Kidney

### Bimanual Palpation :

- Put Left Hand In Renal Angle And Right Hand In Lumbar Area .
- Push Left Hand Upward And Right Hand Downward .
- If Palpable Look For Ballottement .
- Repeat Same In Other Side .
- Normally Kidneys Are Not Palpable Except In Early Infancy Or In Very Thin Child While Lower Pole Is Palpable .
- Kidneys Are Round And Firm .
- **If Palpable , Comment On :**
  - ✓ Size .
  - ✓ Consistency .
  - ✓ Surface .
  - ✓ Tenderness .
  - ✓ Percussion : Resonant .

### # Spleen VS Left Kidney :

Spleen	Left Kidney
In The Left Hypochondrium .	In The Lumbar Region .
Notch Is Present .	Notch Is Not Present
You Cannot Insinuate The Fingers Under Left Costal Margin .	You Can Insinuate The Fingers Under Left Costal Margin .
Moves Inferio-Medially On Inspiration .	Move Inferiorly On Inspiration .
Well Defined Medial Border .	Upper End Is Rounded .
Not Ballottable .	Ballottable .
Dull On Percussion .	Resonant On Percussion .

### Urinary Bladder

- Distended Bladder Is Felt In Supra-Pubic Area, It's Globular Arising From Pelvis .
- Dullness On Percussion .
- Desire For Micturition On Palpation .
- Causes : Normal Child , Outflow Tract Obstruction , Neurological Problems .

### \*\* Note :

- Don't Forget To Palpate Also For Deep Masses & Comment If You Find A Mass .

- **Percussion** : " To Detect Ascites & Liver Span "

A- **Fluid Thrill** > For Huge Collection Of Fluid :

- Need One Assistant To Put His / Her Ulnar Side Of The Hand In The Middle Of The Abdomen .
- Put Your Left Hand Flat On Child's One Lumbar Region .
- Now Tap The Opposite Lumbar Region By One Hand And Feel The Impulse By Flat Of Your Other Hand .

B- **Shifting Dullness** > For Moderate Collection Of Fluid :

- Start With Child In Supine Position .
- Start From Umbilicus Toward Left Flank And Note The Point Of Dullness.
- Keep Your Finger At That Point , Then Roll The Child Over The Right Side And Wait For About 30 Seconds .
- Percuss Over The Same Area And Note The Resonance .
- Now Proceed Toward Umbilicus Till You Get The Dullness Again .
- The Previous Point Of Dullness Is Shifted From Left To The Right Side ( Shifting Dullness ) .

C- **Puddle Test** > For Minimal Collection Of Fluid :

- Minimal Ascites Maybe Missed By Previous Methods , But Maybe Elicited By Putting Child In Knee-Elbow Position .
- Percuss Over Umbilicus And Note The Dullness , Normally It's Resonant .
- Turn On Supine Position Again Note The Resonance .

- **Auscultation** :

✓ **Venous Hum** : In Epigastric Area .

✓ **Liver Bruit** : On Liver Area .

✓ **Renal Bruit** : In Para-Umbilical Area .

✓ **Intestinal Sounds** : In Umbilical Area :

- Normally : 1 Sound each 6 Seconds .
- Diminished : In Paralytic Ileus .
- Exaggerated In : In Intestinal Obstruction .

**\*\* Note :** By The End Of Abdominal Examination Do Not Forget Examine :

External Genitalia / Back Examination / PR Examination / Lymph Nodes Examination .

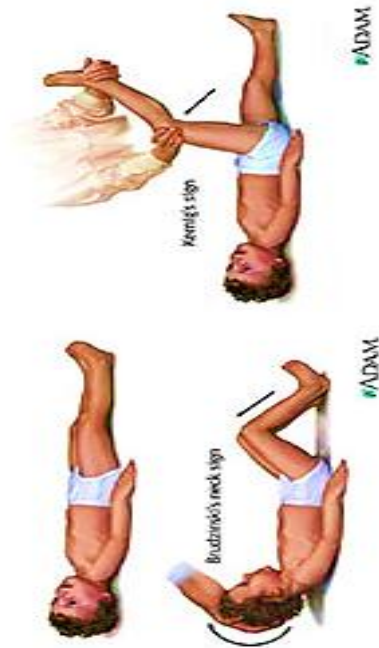


# " Neurological Examination "

- Introduce Yourself .
- Take Permission .
- Explain What You Are Going To Do .
- Maintain Privacy .
- Wash Your Hand .
- Exposure ( Full Exposure Of The Trunk ) .

## A- Important Points In General Examination :

- General Look & Environment .
- Signs Of Respiratory Distress .
- Vital Signs : Pulse , BP , RR , Temp .
- Pallor , Jaundice .
- Skin Changes , Any Deformities .
- Any Dysmorphic Features .
- Skull Shape , Fontanel Size & Closure .
- Abnormalities In The Spines ( Scoliosis , Kyphosis , Lordosis , Spina Pifida ) .
- Growth Parameters .



Pic.1

## B- Signs Of Meningeal Irritation : (Pic.1)

### - Neck Stiffness :

- ✓ Start By Active Movement , Ask The Child To Flex His Neck As Full As He Can & Then Proceed To Passive Flexion.

### - Kernig's Sign :

- ✓ With Child Lying Flat On The Bed , Flex The Hip Fully & Then Try To Extend The Knee Slowly .
- ✓ Positive Response If There Is Pain Or Resistance To Knee Straightening In The Neck Or Back .

### - Brudzinski's Sign :

- ✓ Flex The Neck Of The Child While Observing The Hip & Knees .
- ✓ Positive Response If There Is A Flexion In The Neck Results In Hip & Knee Flexion With Pain On The Back Of Neck .

## C- Mental State Examination :

- It Is Difficult To Perform This In Young Children , However It Can Be Done In Older Children .
- The Following Are Examples On How To Inquire About These Functions In Children :

### ❖ Orientation ( Frontal Lobe Function ):

- ✓ What Is Your Name ? Do You Go To School ? Which Grade ?
- ✓ What Is Your Age ? What Is Your Address ?
- ✓ Where Are You Now ? What Is The Time , Day , Date , And Month ?
- ✓ Ask Younger Child To Point To The Nose , Eyes , Ear Or Ask What Is This ?

### ❖ Attention ( Frontal Lobe Function ):

- ✓ Young Children & Infants Can Be Assessed By Observing Their Interest To The Surrounding .

### ❖ Thought ( Frontal Lobe Function ):

- ✓ Differentiate Between Two Objects Such As Chair / Table , Shirt / Trousers .

### ❖ Memory ( Temporal Lobe Function ):

- ✓ **Immediate Recall :** Give The Child Name Of 3 Object & Ask Him To Repeat Them .
- ✓ **Short Term Memory :** Give The Child A Name Of 3 Objects ( E.G. Pen , Chair , Apple ) To Remember At The Beginning Of The Interview & Then Ask Him To Repeat Them At The End .
- ✓ **Long Term Memory :** Ask The Child About His Address , Names , Ages Of His Siblings .

### ❖ Spatial ( Parietal - Posterior Temporal - Occipital Lobe Functions ):

- ✓ Draw A Clock Face & Ask The Child To Fill The Hands On A Given Time .
- ✓ Draw A Square OR Triangle .

### ❖ Visual & Body Perception ( Parietal – Posterior Temporal – Occipital Lobe Functions ):

- **Agnosia :** Inability To Perceive The Sensation Despite Normal Sensory Pathway .
- ✓ Ask The Child To Show You His Index Finger Or Thumb ( Finger Agnosia If He Can't ) .
- ✓ Ask The Child To Put His Right Hand On His Left Ear ( Body Agnosia If He Can't ) .

**\*\* N.B :** Higher Function Examination Is Not Routinely Performed In Most Of The Patients .

## D- Cranial Nerves Examination (CN):

### 1- Olfactory Nerve (I): ( Not Routinely Examined )

- Ask The Child To Close His Eyes & Say Yes If He Smells Anything New ( Use Familiar Odour ) .
- Each Nostril Should Be Examined Separately

### 2- Optic Nerve (II):

#### A- **Visual Acuity :**

- ( 0 – 5 Months ) :
  - ✓ Fixate On The Mother Face & Follow A Bright Object (E.G. Pen Torch) .
  - ✓ Follow Moving Object Horizontally At Distance 100 Cm Away .
- ( 6 – 18 Months ) :
  - ✓ Near Vision : Assessed By Ability Of The Child To Fix On Small Objects .
  - ✓ Distant Vision : To Fix On Small Object At 3 M .
- ( 6 Years & Above ) :
  - ✓ Snellen Chart Should Be Used .
  - ✓ The Child Should Read The Chart From A Distance 6 M (20 Feet) .
  - ✓ The Child Wearing His Glasses, Test Each Eye Separately With Adequate Illumination .
  - ✓ If The Child Cannot Read The Largest Letter, Use Finger Counting & Hand Motion Detection .

#### B- **Visual Field :**

- ( Old Cooperative Child ) :
  - ✓ Set In Front Of The Child So That Your Head Should Be At The Same Level With His Head .
  - ✓ Instruct Him To Look At Your Nose & Not Move His Head .
  - ✓ Examine Each Eye Separately .
  - ✓ Now Take Your Hand To The Periphery Of Visual Field With Index Finger Extended , And Then Tell The Child That You Are Going Flicker Your Finger & Ask Him To Tell You When He Can Detect It .
  - ✓ Repeated At Different Points In The Perimeter Of The Field .
- ( Young Uncooperative Child ) :
  - ✓ Move A Red Ball Or Torchlight In The Visual Field From Behind To Front To See If It Attracts His Attention .

### C- Papillary Reactions :

#### - Reaction To Light :

- ✓ Ask The Child To Look Away From The Major Source Of Light In The Room , Then Shine A Flash Light ( Pen Torch ) On The Pupil From The Side Of The Eye .
- ✓ Both Pupils On The Same Side ( Direct Light Reflex ) As Well As The Opposite Side ( Consensual Light Reflex ) Well Constrict ( Repeat From The Other Side ) .
- ✓ Remember That The Afferent Limb Is 2nd CN & The Efferent Is 3rd CN .

#### - Reaction To Accommodation Reflex :

- ✓ Ask The Child To Look At A Distant Object , Then Ask Him To Focus On A Finger Held Close To His Nose .
- ✓ The Eyes Converge & The Pupils Constrict Attempting To Look At A Close Object .

D- **Funduscopy** : To Examine The Optic Disc & Retina ( Not Routinely Performed ) .

E- **Color Vision** : ( Not Routinely Examined ) .

### 3- Oculomotor , Trochlear & Abducent nerves ( III , IV , VI ) :

- All Muscles Are Supplied By Oculomotor Except Superior Oblique ( Trochlear ) & Lateral Rectus ( Abducent ) .
- **Older Child :**
  - ✓ Ask The Child To Follow An Object ( E.G. Your Finger ) In Different Direction .
  - ✓ Ask Him How Many Fingers Or Objects He Has Seen ( Diplopia ) .
- **Infant / Young Child :**
  - ✓ Attract The Attention Of The Child By A Small Toy .
  - ✓ Move It In Vertical , Horizontal & Oblique Directions .

### 4- Trigeminal nerve ( V ) : ( Not Routinely Examined )

#### - **Motor Component :**

- ✓ Ask The Child To Open & Close His Mouth , The Jaw Will Be Deviated To The Paralyzed Side .
- ✓ Ask The Child To Clench His Teeth , Then Palpate For Masseter & Temporalis Muscles .
- ✓ Jaw Reflex Test : Ask The Child To Open His Mouth A Little , Place Your Index Over The Chin & Then Tap Your Index In A Downward Direction With A Tendon Hammer. Normally There Is A Weak Or Absent Jerks Of The Jaw.

#### - **Sensory Component :**

- ✓ Touch The Face In 3 Different Regions With A Cotton Over The Forehead ( Ophthalmic ) , Cheeks ( Maxillary ) , And Chin ( Mandibular ) .
- ✓ Ask The Child To Close His Eyes & Say Yes If He Feels The Touch .
- ✓ Corneal Reflex Test : Ask The Child To Look In One Direction & Approach The Cornea From The Opposite Side With A Cotton , Observe For The Blink .

## 5- Facial nerve (VII):

### - **Motor :**

- ✓ Facial Asymmetry ( Absence Of Frontal Wrinkles ) .
- ✓ Flattening Of Naso-labial Folds .
- ✓ Open Eye ( Widened Palpebral ) .
- ✓ Deviation Of The Angle Of Mouth ( Drooping ) .
- **Ask The Child To :**
- ✓ Raise Eyebrows ( Occipito-Frontalis Muscle ) .
- ✓ Close Eyes Tightly While You Are Trying To Open Them ( Orbicularis Oculi ) .
- ✓ Smile Or To Show His Teeth ( Levator Labii Muscle ) .
- ✓ Whistle ( Orbicularis Oris ) .
- ✓ Puff Out Cheeks & To Keep Them Out While You Are Tapping With Your Finger Over Both Cheeks ( Buccinators ) .

### - **Sensory :**

- ✓ Chorda Tympani Supplies Taste To The Anterior Two-Thirds Of The Tongue .
- ✓ Examination Of Taste Is Hard To Perform & Not Usually Recommended .

## 6- Vestibulo-cochlear Nerve (VIII):

### - **Cochlear Division :**

- ✓ **Old Children :** Audiometry , Rinne's Test , Weber's Tests .

### - **Vestibular Division :**

- ✓ It's Usually Tested Along With Cerebellar Function In Order To Assess Balance & Gait .

## 7- Glossopharyngeal & Vagus Nerves (IX, X):

- Talk To The Child To Comment On His Voice ( Hoarseness Of Voice ) .
- **Palatal Reflex :** Touch The Child's Soft Palate With Tongue Depressor , It Will Lead To Elevation Of Soft Palate & Retraction Of Uvula .
- **Gag Reflex :** Touch The Child's Pharyngeal Wall With Spatula , It Will Stimulate Gagging .

## 8- Spinal Accessory Nerve (XI):

### - **Trapezius :**

- ✓ Ask The Child To Shrug His Shoulder , Any Weakness Result In Ipsilateral Drooping Of The Shoulder .

### - **Sternocleidomastoid :**

- ✓ Put Your Hand On The Medial Side Of The Child's Jaw , Ask Him To Push Against Your Hand While You Are Palpating The Opposite Sternocleidomastoid Muscles .

### 9- Hypoglossal Nerve (XII) :

- Look At The Child's Tongue , While Inside The Mouth Observe For Size , Position , Wasting , Fasciculation .
- Ask The Child To Stick His Tongue Out , Observe For Any Deviation To Any Side .
- Ask The Child To Push By His Tongue Against Tongue Blade ( On Each Side ) .

### E- Motor System Examination :

#### - Inspection :

- ✓ **Posture .**
- ✓ **Gait .**
- ✓ **Muscle Bulk :** Atrophy - Hypertrophy .
- ✓ **Involuntary movements :** Chorea , Tics , Tremor , Fasciculation .

#### - Examination Of The Tone :

##### A- Upper Limb :

- ✓ Shaking Hands And Do Supination & Pronation .
- ✓ Flexion And Extension In The Elbow .

##### B- Lower Limb :

- ✓ Rolling .
- ✓ Flexion And Extension In Knee Joint .
- ✓ Raise Legs Up And Release It To Fall Down .

#### - Examination Of The Power :

##### A- Upper Limb :

- ✓ Hand Grip .
- ✓ Flexion And Extension In Elbow With & Without Resistant .
- ✓ Abduction & Adduction Of Both Arms With & Without Resistant .

##### B- Lower Limb :

- ✓ Abduction , Adduction , Flexion , Extension Of Hip Joint With & Without Resistant .
- ✓ Flexion And Extension In Knee Joint With & Without Resistant .
- ✓ Eversion , Inversion , Planter Flexion , Plantar Extension Of Feet With & Without Resistant .

#### Notes :

##### - Grades Of Power :

- ✓ 0/5 : No Contraction .
- ✓ 1/5 : Just Flickering .
- ✓ 2/5 : Horizontal Movement With Gravity Only .
- ✓ 3/5 : Against Gravity , But WITHOUT Resistant .
- ✓ 4/5 : Against Gravity , With Minimal Resistant .
- ✓ 5/5 : Normal Strength .

- Movement Against Gravity = Grade 3 Or Above .

- **Examination Of The Reflexes :**

A- **Deep Tendon Reflex :**

Reflexes	Root	Method
<b>Biceps</b>	C5 – C6	- Flex the elbow to 120. - Put your finger on the tendon and percuss over it.
<b>Triceps</b>	C6 – C7 – C8	- Flex the elbow to 90. - Percuss directly over the tendon.
<b>Brachioradialis</b>	C5 – C6	- Cause wrist extension.
<b>Knee-jerk</b>	L2 – L3 – L4	- Percuss over the tendon above the tibial tuberosity. - Contraction of quadriceps muscle will extend the knee.
<b>Ankle-jerk</b>	S1 – S2	- Both knee and ankle are flexed. - Percuss over the achilles tendon. - Contraction of gastrocnemius cause planter flexion.

- **Rating Of Deep Tendon Reflexes :**

- ✓ 0 : Absent = LMNL OR Early UMNL ( Shock Stage ) .
- ✓ +1 : Trace OR Seen Only With Reinforcement .
- ✓ +2 : Normal .
- ✓ +3 : Brisk .
- ✓ +4 : Non-Sustained Clonus .
- ✓ +5 : Sustained Clonus .

B- **Planter Reflex :**

- Scratch From Lateral Surface Of Dorsum Of Foot And Goes Medially .
- Plantar Extension ( Big Toe Upward ) Called Babinski Sign And It Indicates UMNL .

## F- Sensory System Examination :

### A- Superficial Sensation : " Carried On Spino-Thalamic Tract "

#### - **Pain :**

- ✓ A Similar Approach Is Used With Stimulus Being The Tip Of A Pin , The Child Should Be Respond By Saying Sharp " OR Dull .

#### - **Temperature :**

- ✓ Use Two Tubes Of Cold & Warm Water , Touch The Child With One Of The Tubes And Ask Him To Tell You If It's Cold Or Warm .

#### - **Fine Touch :**

- ✓ Touch The Skin Lightly With A Wisp Of Cotton , Then Ask Him To Say Yes If He Feel It With Closed Eyes .

### B- Deep Sensation : " Carried On DCML Tract "

#### - **Proprioception :**

Hold The Middle Phalanx Of The Child's Index Finger By Side, Then Flex & Extend The Distal Phalanx Telling The Child Which Direction You Mean By Up & Down, Then Repeat It With His Eyes Closed .

#### - **Vibration :** It Is Difficult To Perform .

#### - **Deep Touch .**

### C- Cortical Sensation :

#### - **Astereognosis :**

- ✓ Failure To Recognize Familiar Objects When Put On Hand While Closed Eyes .

#### - **Agraphesthesia :**

- ✓ Failure To Recognize Numbers & Letters When Written In The Palm While The Eyes Closed .

#### - **Two Points Discrimination :**

- ✓ Ability To Identify 2 Points Applied Simultaneously To The Dorsum Of The Foot Or Pulp Of The Finger. Approximate The Two Points Together Until He Perceives Them As One Point .

#### - **Tactile Localization :**

- ✓ Inability To Recognize The Point Of Touch With Closed Eyes .



## G- Cerebellar & Coordination Examination : ( Not Routinely Examined )

### 1- Upper Limbs:

#### - **Finger-Nose Test :**

- ✓ Ask The Child To Place The Tip Of The Index On His Own Nose Starting From Full Abduction Of The Arm With Eyes Open , Then Eyes Closed .
- ✓ Observe For Intention Tremor & Dysmetria (Overshooting)

#### - **Dysdiadochokinesia :**

- ✓ Ask The Child To Put One Hand On The Back Of The Other Quickly & Regularly , Then Ask Him To Tap The Back Of His Right Hand Alternately With The Palm Of His Left Hand & Vice Versa , Also Ask Him To Rapidly Supinate & Pronate His Hands Together To Observe Symmetry & Regularity .

### 2- Lower Limbs:

#### - **Heel-Shin Test :**

- ✓ Ask The Child To Place His Heel On The Opposite Knee & Then Run It Downwards Over The Shin Of The Tibia To The Foot .

#### - **Toe-Finger Test :**

- ✓ Ask The Child To Lift His Big Toe & Touch Your Finger With It .

#### - **Gait :**

- ✓ Ask The Child To Walk .



**DDx Of Common Signs &**  
**Symptoms**

# **DDx Of Common Signs & Symptoms**

## **1- Tachycardia :**

- **Hyperdynamic Circulation :** Exercise , Anxiety , Anemia , Pyrexia , Thyrotoxicosis .
- Heart Failure .
- Shock .
- Constrictive Pericarditis .
- **Drugs :** Aminophylline , Salbutamol , Adrenaline .
- Atrial Fibrillation .

## **2- Bradycardia :**

- Congenital .
- **Drugs :** Beta Blockers , Digoxin .
- Hypothyroidism .
- Hypothermia .
- Increased ICP .
- Hyperkalemia .
- Complete Heart Block .
- Second Degree Av Block .

## **3- Tachypnea :**

- Pulmonary Diseases .
- Acidosis ( DKA ) .
- Fever .
- Extreme Anxiety .

## **4- Apnea :**

- Apnea Of Prematurity .
- Metabolic ( Hypoglycemia ) .
- Sepsis .
- Shock .
- Some Drugs .
- Severe Anemia .
- Hyaline Membrane Disease .
- Persistent Fetal Circulation

5- **Short Stature:** " Length Or Height Below 3<sup>rd</sup> Centile Chart "

- Genetic .
- Constitutional .
- Chronic Illness .
- Small For Gestational Age .
- **Syndromes:** Turner's Syndrome .
- **Endocrinopathy:** Hypothyroidism , Growth Hormone Deficiency , Hypoparathyroidism .
- Social Deprivation

6- **Tall Stature:** " Length Or Height Above 97<sup>th</sup> Centile Chart "

- Genetic
- Constitutional .
- Simple Obesity .
- Gigantism .
- Hyperthyroidism .
- **Syndromes:** Klinefelter , Marfan .

7- **Obesity:**

- Simple , Non-Pathological , Nutritional Obesity ( Most Common ) .
- **Endocrinopathy:** Hypothyroidism , Cushing Syndrome , Hypoparathyroidism , Hyperinsulinism .
- **Syndromes:** Prader-Willi Syndrome ( PWS ) , Laurence-Moon Biedl Syndrome ( LMBS ) .

8- **Finger Clubbing:**

- **Cardiac Causes:** Cyanotic CHD , Infective Endocarditis .
- **Pulmonary Causes:** Chronic Suppurative Lung Diseases , Cystic Fibrosis , Fibrosing Alveolitis .
- **GIT Causes:** Biliary Cirrhosis , Biliary Atresia , Ulcerative Colitis , Crohn's Disease .
- **Other Rare Causes:** Thyrotoxicosis , Malignant Neoplasm Of Lung , Familial And Idiopathic .

9- **Peripheral Cyanosis:**

- Physiological > Cold .
- Reduced Cardiac Output .
- Peripheral Vascular Disease ( Polyarteritis Nodosa ) .

#### 10- Central Cyanosis :

- Detectable If There Is Deoxygenated Hemoglobin Of More Than 5 Gm/100 ML Of Blood .
- Corresponding To Arterial Saturation Of 75%
- **Cardiac Causes :** Cyanotic Congenital Heart Disease , Pulmonary Atresia .
- **Pulmonary Causes :** Respiratory Distress Syndrome , Lung Hypoplasia , Diaphragmatic Hernia Pneumonia , Bronchial Asthma , Bronchiolitis , Cystic Fibrosis , Bronchiectasis .
- **Nervous System And Neuromuscular Causes :** Birth Asphyxia , Head Trauma , Spinal Muscular Atrophy , Diaphragmatic Weakness .
- **Others :** Persistent Pulmonary HTN , Non-Cyanotic Heart Disease With Heart Failure .

#### 11- Jaundice :

- **Pre-Hepatic :** Hemolytic Anemia ( SCA , Thalassemia , Hereditary Spherocytosis , ... ) .
- **Hepatic :** Hepatitis ,  $\alpha_1$ - Antitrypsin Deficiency , Inborn Errors Of Bile Acid Synthesis .
- **Post-Hepatic ( Obstructive ) :** Biliary Atresia , Congenital Bile Duct Anomalies , Cholelithiasis , Primary Sclerosing Cholangitis , Infectious Cholangitis .

#### 12- Systolic Murmurs :

- **Mid-Systolic :**
  - ✓ Aortic Stenosis .
  - ✓ Pulmonary Stenosis .
  - ✓ ASD .
- **Holo-Systolic :**
  - ✓ Mitral Regurgitation .
  - ✓ Tricuspid Regurgitation .
  - ✓ VSD .
- **Late Systolic :**
  - ✓ Mitral Prolapse .

#### 13- Diastolic Murmurs :

- **Early Diastolic :**
  - ✓ Aortic Regurgitation .
  - ✓ Pulmonary Regurgitation .
  - ✓ ASD .
- **Mid/Late Diastolic :**
  - ✓ Mitral Stenosis .
  - ✓ Tricuspid Stenosis .
  - ✓ VSD .

14- **Continous Murmurs :**

- PDA .

15- **Pectus Carinatum :**

- Asthma .
- Rickets .
- Osteomalacia .

16- **Pectus Excavatum :**

- Isolated Congenital Anomaly
- **Chronic Upper Airway Obstruction** : Adenoid Hypertrophy , Laryngomalacia .

17- **Deviation Of Trachea :**

- **To Opposite Side :**
  - ✓ Pneumothorax .
  - ✓ Plural Effusion .
  - ✓ **Unilateral Hyperinflation** : Foreign Body , Tumor .
- **To Same Side :**
  - ✓ Collapse .
  - ✓ Fibrosis .
  - ✓ Hypoplasia .

18- **Dullness On Percussion :**

- Consolidation , Collapse , Fibrosis .
- Pleural Thickening .
- Plural Effusion ( Stony Dullness ) .

19- **Hyper-Resonance On Percussion :**

- Normal Infant .
- Pneumothorax .
- Asthma .
- Emphysema .

## 20- **Bronchial Breathing :**

- **Normal Infant :** On The Sides Of The 2<sup>nd</sup> Thoracic Spine At The Back .
- **Normal Children :** Below The Right Clavicle .
- Consolidation
- Large Cavity
- At The Air-Fluid Level Of Small Effusion
- Collapse

## 21- **Stridor :**

- Bacterial Tracheitis .
- CROUP .
- Diphtheria .
- Epiglottitis .
- Foreign Body Inhalation .
- Laryngomalacia .
- Tracheomalacia .
- Vocal Cord Paralysis .
- Laryngeal Web .
- Congenital Sub-Glottic Stenosis .

## 22- **Wheeze :**

- BA .
- Bronchiolitis .
- Foreign Body .
- **Aspiration Syndromes :** Gastro-Esophageal Reflux , Tracheo-Esophageal Fistula .

## 23- **Ascites :**

- **Transudate :**
  - ✓ Nephrotic Syndrome .
  - ✓ Malnutrition .
  - ✓ Protein Losing Enteropathy .
  - ✓ Hepatic Failure .
  - ✓ Cirrhosis .
  - ✓ Portal HTN .
  - ✓ IVC Obstruction .
  - ✓ Congestive Cardiac Failure .
  - ✓ Constrictive Pericarditis .

- **Exudate :**
  - ✓ Peritonitis
- **Chylous :**
  - ✓ Lymphatic Obstruction Or Abnormalities .

#### 24- **Hepatomegaly:**

- **Infection :**
  - ✓ **Viral :** Hepatitis , EPV , CMV , Congenital Rubella .
  - ✓ **Bacterial :** Typhoid , Congenital Syphilis , Neonatal Infection .
  - ✓ **Protozoal :** Malaria , Toxoplasmosis , Schistosomiasis , Leishmaniasis .
- **Chronic Hemolytic Anemia :**
  - ✓ Thalassemia .
  - ✓ Sickle Cell Anemia .
- **Neoplastic Disorders :**
  - ✓ Leukemia .
  - ✓ Lymphoma .
  - ✓ Hepatoma .
  - ✓ Neuroblastoma .
- **Metabolic And Storage Disorders :**
  - ✓ Galactosemia .
  - ✓ Glycogen Storage Disease .
  - ✓ Mucopolysaccharidosis .
  - ✓ Alpha-1 Antitrypsin Deficiency .
- **Cardiac Causes :**
  - ✓ Congestive Cardiac Failure .
  - ✓ Constrictive Pericarditis .
  - ✓ Inferior Vena Cava Obstruction .
  - ✓ Hepatic Vein Thrombosis .



## 25- Splenomegaly:

- **Infection :**
  - ✓ Viral : Hepatitis , EPV , CMV .
  - ✓ Bacterial : Brucellosis , Typhoid , Syphilis , Sub-Acute Infective Endocarditis , Septicemia .
  - ✓ Protozoal : Malaria , Toxoplasmosis , Schistosomiasis And Leishmaniasis .
  
- **Chronic Hemolytic Anemia :**
  - ✓ Thalassemia .
  - ✓ Hereditary Spherocytosis .
  - ✓ Autoimmune Hemolytic Anemia .
  
- **Neoplastic Disorders :**
  - ✓ Leukemia .
  - ✓ Lymphoma .
  
- **Storage Disease :**
  - ✓ Gaucher's Disease .
  - ✓ Niemann-Pick Disease .

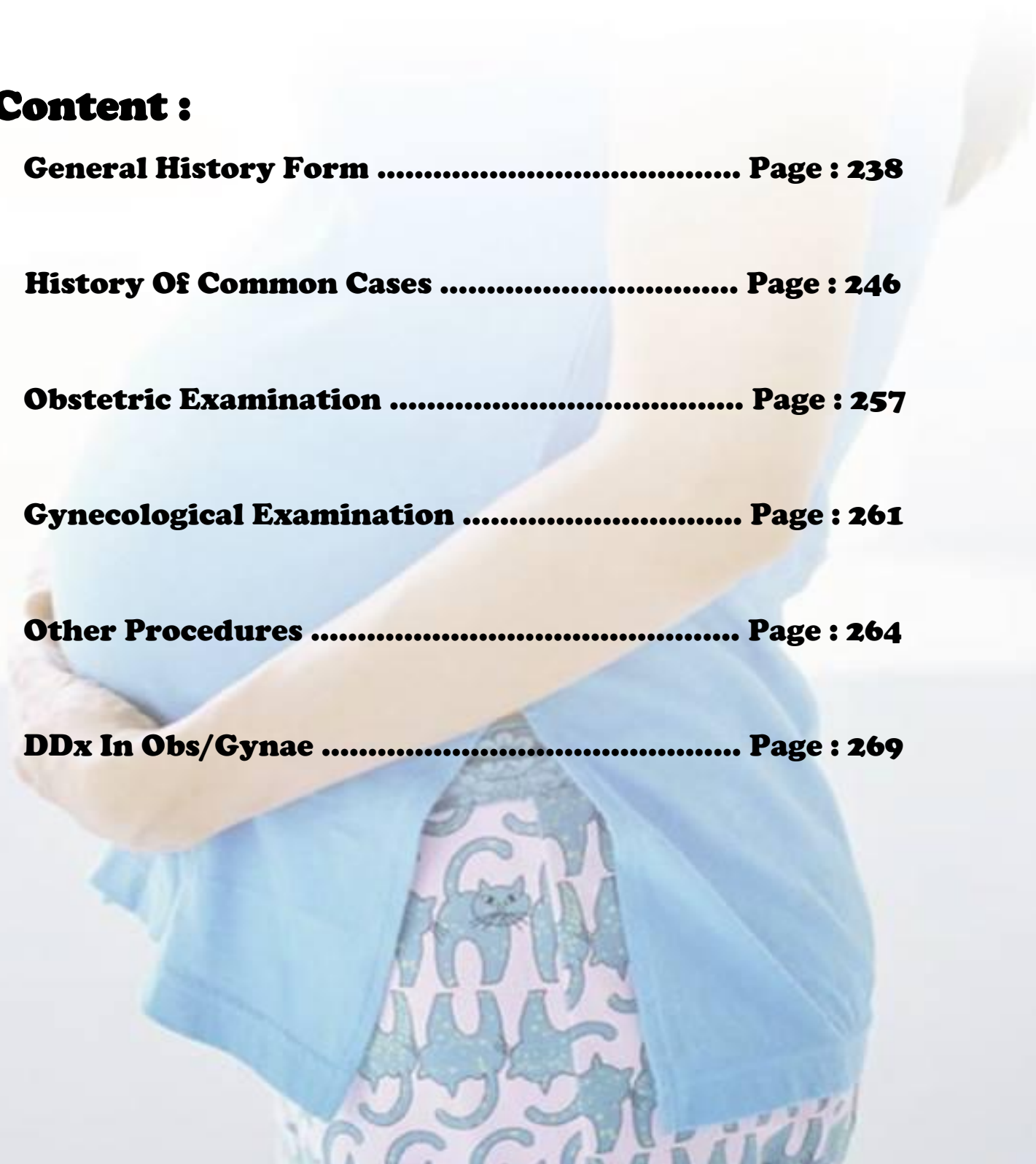
## 26- Hepato-Splenomegaly:

- **Infection :** Viral , Bacterial , Protozoal .
- **Hematological :** Thalassemia .
- **Malignancies :** Leukemia , Lymphoma .
- Storage Disease .
- Congenital Cirrhosis .
- Collagen Vascular Diseases .

**Chapter ( 4 )**  
**" Obstetric & Gynecology "**

**# Content :**

- **General History Form ..... Page : 238**
- **History Of Common Cases ..... Page : 246**
- **Obstetric Examination ..... Page : 257**
- **Gynecological Examination ..... Page : 261**
- **Other Procedures ..... Page : 264**
- **DDx In Obs/Gynae ..... Page : 269**





**General History In**  
**Obs/Gynae**

# General History In Obs/Gynae

## 1- Personal History :

- ✓ **Name** : For Identification & To Be Familiar With Patient .
- ✓ **Age** : Certain Diseases Are Related To Certain Age Groups .
- ✓ **Sex** .
- ✓ **Nationality** : Certain Diseases Are Related To Certain Countries .
- ✓ **Home & Residence** : Certain Diseases Are Related To Certain Areas .
- ✓ **Occupation** : Some Diseases Are Related To Certain Jobs .
- ✓ **Marital Status** .
- ✓ **Special Habits Of Medical Importance** : Smoking , Water-Pipe , Alcohol , Drug-Abuse , ... Etc.
- ✓ **Transportation & Distance From Hospital** .

## 2- Chief Complaint ( C/O ) :

- ✓ In Patient's Own Words .
- ✓ Write The Duration .
- ✓ Sort Them In Chronological Manner ( Oldest To Newest ) .

Example : Vaginal Bleeding / 2 Days .

NOTE : Common Complaints In Obs/Gynae Are " Pain OR Vaginal Bleeding " .

## 3- History Of Presenting Illness ( HPI ) :

**Pain**

A- *She Is In Week ..... Of Gestation , ( And ) Known Case Of ..... ( Chronic Disease ) .*

B- *The Patient Was Well Till / On Usual Status Till ..... ( Hours - Days - Weeks - Months ) Back When She Started To Has ..... ( Complaint ) .*

C- *Analysis Of Complaint :*

- ✓ Site .
- ✓ Onset :
  - Sudden .
  - Acute .
  - Gradual .
- ✓ Course :
  - Progressive .
  - Regressive .
  - Stationary .
  - Intermittent .
- ✓ Character ( Nature ) :
  - Dull-Aching .
  - Colicky .
  - Throbbing .
  - Stitching .
- ✓ Radiation / Referral / Shifting .
- ✓ Aggravating & Relieving Factors .
- ✓ Associated Symptoms .
- ✓ Severity .

*D- Review The Symptoms Of The Affected System :*

*E- Exclude Warning Symptoms : ( In Obstetric Case )*

- ✓ Vaginal Bleeding .
- ✓ Gush Of Fluid Per Vagina .
- ✓ Abdominal Pain .
- ✓ Persistent Headache .
- ✓ Blurring Of Vision .
- ✓ Edema Of Hands Or Face .
- ✓ Persistent Vomiting .
- ✓ Diminished Or Absent Fetal Movements .

**F- Systemic Review :**

- CNS : Headache , Dizziness , Change In Behavior , Loss Of Consciousness , Weakness , Abnormal Movement .
- GIT : Dysphagia , Heartburn , Jaundice , Hematemesis , Constipation , Diarrhea , Melena , Bleeding Per Rectum .
- Cardio-Pulmonary : Cough , Hemoptysis , Dyspnea , Chest Pain , Palpitations , Syncope , Claudication .
- Urogenital : Loin Pain , Dysuria , Polyuria , Hematuria , Urethral Discharge .
- Skin & Musculoskeletal : Pain , Muscle Wasting , Pigmentation , Ulcers .

**N.B:** If All Systems Are -Ve → Say : " No History Suggestive Of Other System Affection " .

**G- Hospital Course :**

- Investigations .
- Medications & Interventions .
- Improving OR Not .

## Vaginal Bleeding

**A- She Is In Week ..... Of Gestation , ( And ) Known Case Of ..... ( Chronic Disease ) .**

**B- The Patient Was Well Till / On Usual Status Till ..... ( Hours - Days - Weeks - Months ) Back When She Started To Has ..... ( Complaint ) .**

**C- Analysis Of Complaint :**

✓ **Onset :**

- Sudden .
- Acute .
- Gradual .

✓ **Course :**

- Progressive .
- Regressive .
- Stationary .
- Fluctuating .

- ✓ **Duration .**
- ✓ **Color :**
  - **Bright Red :** Fresh .
  - **Brown :** Accumulated For Period Of Time .
- ✓ **Presence Of Clots .**
- ✓ **Aggravating & Relieving Factors :**
- ✓ **Apparent Cause :** Trauma , Emotional Stress , Chronic Disease .

**D- Review The Symptoms Of The Affected System :**

**E- Exclude Warning Symptoms : ( In Obstetric Case )**

- ✓ Vaginal Bleeding .
- ✓ Gush Of Fluid Per Vagina .
- ✓ Abdominal Pain .
- ✓ Persistent Headache .
- ✓ Blurring Of Vision .
- ✓ Edema Of Hands Or Face .
- ✓ Persistent Vomiting .
- ✓ Diminished Or Absent Fetal Movements .

**F- Systemic Review :**

- **CNS :** Headache , Dizziness , Change In Behavior , Loss Of Consciousness , Weakness , Abnormal Movement .
- **GIT :** Dysphagia , Heartburn , Jaundice , Hematemesis , Constipation , Diarrhea , Melena , Bleeding Per Rectum .
- **Cardio-Pulmonary :** Cough , Hemoptysis , Dyspnea , Chest Pain , Palpitations , Syncope , Claudication .
- **Urogenital :** Loin Pain , Dysuria , Polyuria , Hematuria , Urethral Discharge .
- **Skin & Musculoskeletal :** Pain , Muscle Wasting , Pigmentation , Ulcers .

**N.B:** If All Systems Are -Ve → Say : " No History Suggestive Of Other System Affection " .

**G- Hospital Course :**

- **Investigations .**
- **Medications & Interventions .**
- **Improving OR Not .**

## 4) Gynecological History :

### • Menstrual History :

- Age Of Menarche .
- Regular Or Irregular Cycle .
- Heavy Cycle Or Not .
- Associated Symptoms .
- Duration ( How Many Days ) .
- Length ( How Many Days Between 2 Cycles ) .
- **1st Day Of LMP To Calculate :**
  - ✓ EED      ↘      **Hijri** = ( 1<sup>st</sup> Day Of LMP + 14 Days / - 3 Months ) .
  - ↙      **Gregorian** = ( 1<sup>st</sup> Day Of LMP + 7 Days / - 3 Months ) .
  - ✓ Gestational Age (GA) .

### # Example On EDD :

- 1<sup>st</sup> Day Of LMP 1/5/1435 H > EED = 15/2/1436H .
- 1<sup>st</sup> Day Of LMP 5/4/2011 > EED = 12/1/2012 .

### # Example On GA :

- 1<sup>st</sup> Day Of LMP = 2/1/1436 H .
- EDD = 16/10/1436 H .
- Date Of The Day = 1/7/1436 H .
- GA :
  - ✓ Month 7 = Remain 29 Days .
  - ✓ Month 8 = Remain 30 Days .
  - ✓ Month 9 = Remain 30 Days .
  - ✓ Month 10 = Remain 16 Days .

Calculate : 29 + 30 + 30 + 16 = 105 Days

Covert Days Into Weeks : 104 / 7 = 15 Weeks .

Subtract From 40 Weeks : 40 - 15 = 25 Weeks >>>> **GA = 25 Weeks** .

### \*\* Notes :

- If She Didn't Remember The 1st Day Of LMP Ask Her : Did She Do US OR Pregnancy Test ?
- If She Didn't Do These Tests Ask Her When She Noticed The First Movement Of Baby ?

### • Contraceptive Methods History .

### • Sexual History : ( Relevant In )

- Infertility , Sexual Transmitted Diseases ( STDs ) , Genital Prolapse .

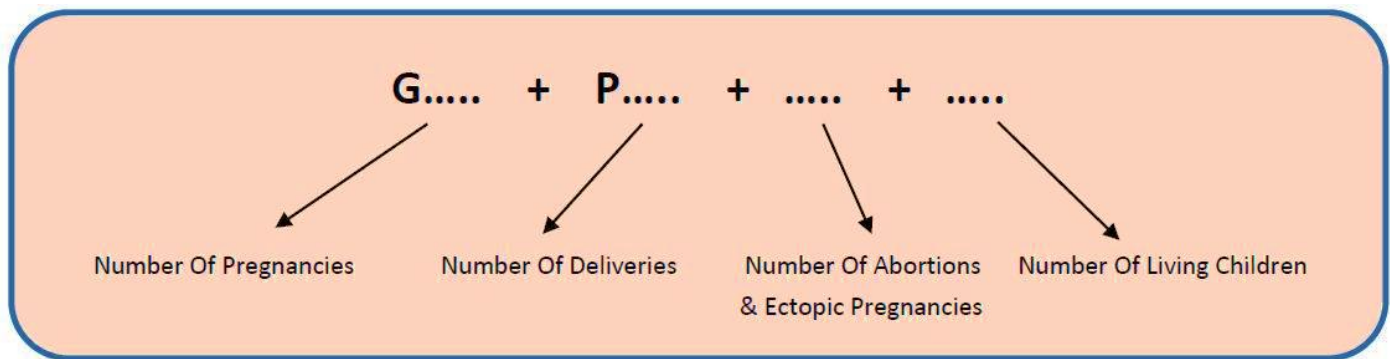


## 5- Obestetric :

### - Current Pregnancy History :

- ✓ Ante-natal Visits .
- ✓ 1<sup>st</sup> Trimester → Morning Sickness , Vaginal Bleeding , Exposure To Radiation , Infection , Abdominal Pain .
- ✓ 2<sup>nd</sup> Trimester → Quickening , Vaginal Bleeding , Gush Of Fluids , UTI .
- ✓ 3<sup>rd</sup> Trimester → Vaginal Bleeding , Gush Of Fluids , Abdominal Pain .

### - Number Of Pregnancies , Deliveries , Abortions & Living Children .



- ✓ Full Comment On Everyone .
- ✓ Last Labor : When ?
- ✓ Last Abortion : When ?

**# Example :** ( G3 + P1 + 1 + 1 ) , Last Labor = 5 Years Back , Last Abortion = 2 Years Back .

Number	Duration Of Pregnancy	Mode Of Termination	Complicated OR Not ?	Outcome	Lactation
1	38 Weeks	Vaginal Delivery	No	Living Male	Breast Feeding
2	12 Weeks	Surgical Evacuation	-	-	-

### \*\* Comment :

- Her 1<sup>st</sup> Pregnancy Was 5 Years Back , Full-Term , Terminated By Normal Vaginal Delivery , Not Complicated , With Living Male , Breast Feeding Is Carried For 2 Years After Delivery .
- Her 2<sup>nd</sup> Pregnancy Was 2 Years Back , Terminated By Spontaneous Abortion Followed By Surgical Evacuation .

## **6- Past History :**

- **Past Medical History :** Chronic Diseases , Blood Transfusion .
- **Past Surgical History :** Surgical Operations .
- **Hx Of Trauma .**
- **Hx Of Hormonal Replacement Therapy ( Post-Menopause , Abnormal Puberty ) !!**

## **7- Family History :**

- **Chronic Diseases ( HTN , DM , Asthma , TB , Hepatitis ) .**
- **Similar Conditions .**
- **Inherited / Genetic Diseases .**
- **History Of Twins .**
- **History Of Breast Cancer / Cervical Cancer / Endometrial Cancer .**
- **Consanguinity .**

## **8- Socioeconomic History :**

- **Occupation Of Husband .**
- **Living Conditions .**
- **Level Of Education .**
- **Income .**

## **9- Immunization History .**

## **9- Drugs & Allergies History .**

- **Long Term Medications .**
- **Short Term Medications .**
- **Allergy To Certain Food OR Medication .**

**" Summary "**



**History Of Common**  
**Cases In Obs/Gynae**

# History Of Common Cases

## 1) Abortion :

### - Personal History :

Fatimah Ali Ahmed 23 Years Old Saudi Female From Jeddah , Housewife , Married For 1 Year , With No Special Habits Of Medical Importance . The Distance From The Hospital Is 15 Minutes , Admitted Through ER On 3 -1 -1436 H .

### - C/O :

Vaginal Bleeding + Abdominal Pain / 5 Hours .

### - HPI :

She Is Pregnant In Her 10<sup>th</sup> Week Of Gestation .

She Was Well Till 5 Hours Back When She Started To Has Sudden Vaginal Bleeding , Red Fresh In Color , With Clots , Gradually Increase , No Aggravating Or Relieving Factor . Then Followed By Abdominal Pain , Dull-Aching , Progressive , Radiated To The Back , Associated With Cold Extremities & Palpitations .

\*\* Warning Symptoms : -Ve .

\*\* Systemic Review : No History Suggestive Of Other Systems Affection .

### - Gynecological History :

\*\* Age Of Menarche At 14 Years Old , Regular , Average Amount , 7/28 .

\*\* LMP : 23 -10 -1435 H .

\*\* EDD : 7 - 8 -1436 H .

\*\* Gestational Age : Approximately 10 Week .

\*\* Contraceptive History : -Ve .

\*\* Sexual History : Not Important In This Case .

### - Obstetric History :

Primi-Gravida In Her 10 Week Of Pregnancy .

With Regular Antenatal Visits .

- Past History : - Ve .

- Family History : - Ve .

- Social History :

Her Husband Is Teacher , With Good Socioeconomic Status . There Is +Ve History Of Contact With Cats .

- Drugs & Allergies :

No History Of Long / Short Term Medications , No History Of Allergy To Certain Food Or Medication .

### Summary

23 Y/O Saudi Female , Housewife , Married For 1 Years , Primi-Gravida In Her 10<sup>th</sup> Week Of Gestation With Vaginal Bleeding & Abdominal Pain For 5 Hour For Further Investigations & Management .

# History Of Common Cases

## 2) Ectopic Pregnancy :

### - Personal History :

Fatimah Ali Ahmed 27 Years Old Saudi Female From Jeddah , Housewife , Married For 3 Year , With No Special Habits Of Medical Importance . The Distance From The Hospital Is 2 Hours , Admitted Through ER On 19 - 12 -1435 H .

### - C/O :

Severe Lower Abdominal Pain With Vaginal Bleeding / 4 Hours .

### - HPI :

She Is Pregnant After 2 Weeks Of Missed Menses By Urine Pregnancy Test At Home But She Did Not Go To The Hospital To Confirm .

She Was Well till 4 Hours Prior Admission When She Suffered From Severe Colicky Lower Abdominal Pain , Gradually In Onset Progressive And No Aggravating Or Relieving Factors Followed By Heavy Vaginal Bleeding , Red In Color With No Clots , Associated With Dizziness And Tachycardia .

\*\* Warning Symptoms : -Ve .

\*\* Systemic Review : No History Suggestive Of Other Systems Affection .

### - Gynecological History :

\*\* Age Of Menarche At 14 Years Old , Regular , Average Amount , 7/28 .

\*\* LMP : 23 - 10 -1436 H .

\*\* EDD : 7 - 8 -1437 H .

\*\* Gestational Age : 8 Weeks .

\*\* Contraceptive History : -Ve .

\*\* Sexual History : -Ve .

### - Obstetric History :

\*\* G 2 + P 0 + 1 Ectopic .

\*\* Current Pregnancy : No Antenatal Visits .

\*\* Previous Pregnancy : Ectopic , Diagnosed At 7 Week By The Same Presentation , Managed By Salpingostomy .

- Past History : -Ve Apart From History Of Chlamydia Infection 2 Years Back .

- Family History : -Ve .

- Social History : Her Husband Is Teacher , With Good Socioeconomic Status .

- Drugs & Allergies :

No History Of Long / Short Term Medications , No History Of Allergy To Certain Food Or Medication .

### Summary

27 Y/O Saudi Female , Housewife , Married For 3 Years , G2+P0+1 Ectopic In Her 8<sup>th</sup> Week Of Gestation With Severe Lower Abdominal Pain & Vaginal Bleeding For 4 Hours Associated With Dizziness & Tachycardia . Positive History Of Chlamydia Infection 2 Years Back Was Noticed For Further Investigations & Management .

# History Of Common Cases

## 3) Molar Pregnancy :

### - Personal History :

Fatimah Ali Ahmed 27 Years Old Saudi Female From Jeddah , Housewife , Married For 5 Year , With No Special Habits Of Medical Importance . The Distance From The Hospital Is 15 Minutes , Admitted Through ER On 19 - 12 -1435 H .

### - C/O :

Blood Stained Vaginal Discharge / 1 hour .

### - HPI :

She Is Pregnant In Her 8<sup>th</sup> Week Of Gestation .

She Was Well till 1 Hours Prior Admission When She Noticed Suddenly Watery Vaginal Discharge With Scanty Brownish Spot , Without Clot . The Condition Associated With Exaggerated Nausea & Vomiting From The Beginning Of Pregnancy .

\*\* Warning Symptoms : -Ve .

\*\* Systemic Review : No History Suggestive Of Other Systems Affection .

### - Gynecological History :

\*\* Age Of Menarche At 14 Years Old , Regular , Average Amount , 7/28 .

\*\* LMP : 23 - 10 -1436 H .

\*\* EDD : 7 - 8 -1437 H .

\*\* Gestational Age : 8 Weeks .

\*\* Contraceptive History : -Ve .

\*\* Sexual History : -Ve .

### - Obstetric History :

\*\* G 2 + P 0 + 1 Abortion .

\*\* Current Pregnancy : No Antenatal Visits .

\*\* Previous Pregnancy : Aborted , At 1<sup>st</sup> Trimester .

### - Past History : -Ve .

### - Family History : -Ve .

### - Social History : Her Husband Is Teacher , With Good Socioeconomic Status .

### - Drugs & Allergies :

No History Of Long / Short Term Medications , No History Of Allergy To Certain Food Or Medication .

### Summary

27 Y/O Saudi Female , Housewife , Married For 5 Years , G2+P0+1 Abortion In Her 8<sup>th</sup> Week Of Gestation With Blood Stained Vaginal Discharge For 1 Hour Associated With Nausea & Vomiting For Further Investigations & Management .

# History Of Common Cases

## 4) Placenta Previa :

### - Personal History :

Fatimah Ali Ahmed 28 Years Old Saudi Female From Jeddah , Housewife , Married For 4 Year , With No Special Habits Of Medical Importance . The Distance From The Hospital Is 30 Minutes , Admitted Through ER On 15 - 6 -1436 H .

### - C/O :

Vaginal Bleeding / 5 Hours .

### - HPI :

She Is Pregnant In Her 34<sup>th</sup> Week Of Gestation .

She Was Well till 4 Hours Prior Admission When She Started To Has Acute Vaginal Bleeding , Small Amount , Bright Red In Color , No Clots , No Aggravating Or Relieving Factor, No Odour & Not Associated With Abdominal Pain .

\*\* Warning Symptoms : -Ve .

\*\* Systemic Review : No History Suggestive Of Other Systems Affection .

### - Gynecological History :

\*\* Age Of Menarche At 14 Years Old , Regular , Average Amount , 7/28 .

\*\* LMP : 10 - 10 -1435 H .

\*\* EDD : 24 - 7 -1436 H .

\*\* Gestational Age : 34 Weeks + 5 Days .

\*\* Contraceptive History : -Ve .

\*\* Sexual History : -Ve .

### - Obstetric History :

\*\* G 2 + P 1

\*\* Current Pregnancy : Regular Antenatal Visits With No Complications In 1<sup>st</sup> , 2<sup>nd</sup> & 3<sup>rd</sup> Trimesters .

\*\* Previous Pregnancy : Full Term , Vaginal Delivery , Not Complicated , Result In Living Boy & Breastfed For 1 Year .

- Past History : -Ve .

- Family History : -Ve .

- Social History : Her Husband Is Teacher , With Good Socioeconomic Status .

- Drugs & Allergies :

No History Of Long / Short Term Medications , No History Of Allergy To Certain Food Or Medication .

### Summary

28 Y/O Saudi Female , Housewife , Married For 4 Years , G2+P1 In Her 34<sup>th</sup> Week Of Gestation With Painless Vaginal Bleeding For 5 Hour For Further Investigations & Management .

# History Of Common Cases

## 5) Abruptio Placentae :

### - Personal History :

Fatimah Ali Ahmed 28 Years Old Saudi Female From Jeddah , Housewife , Married For 4 Year , With No Special Habits Of Medical Importance . The Distance From The Hospital Is 20 Minutes , Admitted Through ER On 15 - 6 -1436 H .

### - C/O :

Vaginal Bleeding / 5 Hours .

### - HPI :

She Is Pregnant In Her 34<sup>th</sup> Week Of Gestation & Known Case Of HTN .

She Was Well till 5 Hours Back After Car Accident When She Suffered From Acute Onset Of Heavy Vaginal Bleeding , Dark Red In Color , No Clots , No Aggravating Or Relieving Factor & No Odor .

Associated With Abdominal Pain Varies From Mild Cramping To Severe Pain , Radiated To The Back & Also Associated With Rupture Of Membranes .

\*\* Warning Symptoms : -Ve .

\*\* Systemic Review : No History Suggestive Of Other Systems Affection .

### - Gynecological History :

\*\* Age Of Menarche At 14 Years Old , Regular , Average Amount , 7/28 .

\*\* LMP : 10 - 10 -1435 H .

\*\* EDD : 24 - 7 -1436 H .

\*\* Gestational Age : 34 Weeks + 5 Days .

\*\* Contraceptive History : -Ve .

\*\* Sexual History : -Ve .

### - Obstetric History :

\*\* G 2 + P 1

\*\* Current Pregnancy : Regular Antenatal Visits With No Complications In 1<sup>st</sup> , 2<sup>nd</sup> & 3<sup>rd</sup> Trimesters .

\*\* Previous Pregnancy : Full Term , Vaginal Delivery , Not Complicated , Result In Living Boy & Breastfed For 1 Year .

- Past History : -Ve Apart From History Of HTN For 3 Years .

- Family History : -Ve Apart From +Ve History Of HTN & Consanguinity .

- Social History : Her Husband Is Teacher , With Good Socioeconomic Status .

- Drugs & Allergies :

HTN Medications & No History Of Allergy To Certain Food Or Medication .

### Summary

28 Y/O Saudi Female , Housewife , Married For 4 Years , G2+P1 In Her 34<sup>th</sup> Week Of Gestation With Painful Vaginal Bleeding For 5 Hour After Car Accident . She Is Known Case Of HTN For Further Investigations & Management .



# History Of Common Cases

## 6) Gestational Diabetes ( GDM ) :

### - Personal History :

Fatimah Ali Ahmed 28 Years Old Saudi Female From Jeddah , Housewife , Married For 4 Year , With No Special Habits Of Medical Importance . The Distance From The Hospital Is 30 Minutes , Admitted Through OPD On 3 - 10 -1436 H .

### - C/O :

Prepare For Elective CS Due To Large Baby / 1 Day .

### - HPI :

She Is Known Case Of GDM From Last Pregnancy , Now Is Discovered In The 6<sup>th</sup> Month Of Gestation When She Complain Of Generalized Fatigue Start When She Wakeup In The Morning, And Continue For Few Days . She Went To PHC For Regular Follow Up . CBC , BP , And Blood Sugar Measuring Was Done , Her Blood Sugar Was High , She Diagnosed As GDM & Received Card For Regular Follow Up Of Diabetes .

Now She Is Admitted For Elective CS Without Any Complain .

\*\* Warning Symptoms : -Ve .

\*\* Systemic Review : No History Suggestive Of Other Systems Affection .

### - Gynecological History :

\*\* Age Of Menarche At 14 Years Old , Regular , Average Amount , 7/28 .

\*\* LMP : 3 - 1 -1436 H .

\*\* EDD : 17 - 10 -1436 H .

\*\* Gestational Age : 38 Weeks .

\*\* Contraceptive History : -Ve .

\*\* Sexual History : -Ve .

### - Obstetric History :

\*\* G 2 + P 1

\*\* Current Pregnancy : Regular Antenatal Visits With No Complications In 1<sup>st</sup> , 2<sup>nd</sup> & 3<sup>rd</sup> Trimesters .

\*\* Previous Pregnancy : Full Term , Cesarean , Not Complicated , Result In 4.5 Kg Living Boy & Breastfed For 1 Year .

- Past History : -Ve .

- Family History : -Ve Apart From +Ve History Of DM & Consanguinity .

- Social History : Her Husband Is Teacher , With Good Socioeconomic Status .

- Drugs & Allergies :

No History Of Long / Short Term Medications , No History Of Allergy To Certain Food Or Medication .

### Summary

28 Y/O Saudi Female , Housewife , Married For 4 Years , G2+P1 In Her 38<sup>th</sup> Week Of Gestation Admitted Through OPD For Elective CS Due To Large Baby . She Is Known Case Of GDM .

# History Of Common Cases

## 7) HTN During Pregnancy :

### - Personal History :

Fatimah Ali Ahmed 28 Years Old Saudi Female From Jeddah , Housewife , Married For 2 Year , With No Special Habits Of Medical Importance . The Distance From The Hospital Is 15 Minutes , Admitted Through OPD On 19 - 9 -1436 H .

### - C/O :

Headache & Face Edema / 2 Days .

### - HPI :

The Condition Started At 5<sup>th</sup> Month Of Pregnancy When She Complaint Of Acute Onset Of Headache, Intermittent In Course , Severe In The Back Of Head With Interfering With Daily Activity , No Relieving Or Aggravating Factors . Associated With Slight Edema Of The Face In The Morning Then It Regress After Hours . The Mother Went To Antenatal Care & BP Was Measured And Revealed High Result Then Refer To The Hospital For Admission And Received Medication And Then She Improved . 2 Days Back She Started To Has The Same Complaint As Before . She Came To ER Then Admitted To The Ward For Supervision .

\*\* Warning Symptoms : -Ve .

\*\* Systemic Review : No History Suggestive Of Other Systems Affection .

### - Gynecological History :

\*\* Age Of Menarche At 14 Years Old , Regular , Average Amount , 7/28 .

\*\* LMP : 3 - 1 -1436 H .

\*\* EDD : 17 - 10 -1436 H .

\*\* Gestational Age : 36 Weeks .

\*\* Contraceptive History : -Ve .

\*\* Sexual History : -Ve .

### - Obstetric History :

\*\* Primi-Gravida .

\*\* Current Pregnancy : Regular Antenatal Visits With No Complications In 1<sup>st</sup> , 2<sup>nd</sup> & 3<sup>rd</sup> Trimesters .

- Past History : -Ve .

- Family History : -Ve Apart From +Ve History Of HTN & Consanguinity .

- Social History : Her Husband Is Teacher , With Good Socioeconomic Status .

- Drugs & Allergies :

She Use Labetalol & No History Of Allergy To Certain Food Or Medication .

### Summary

28 Y/O Saudi Female , Housewife , Married For 4 Years , Primi-Gravida In Her 36<sup>th</sup> Week Of Gestation Admitted Through ER Headache & Edema Of Face / 2 Days Due To HTN For Further Investigations & Management .

# **History Of Common Cases**

## **8) Elective Cesarean Section :**

### - **Personal History :**

Fatimah Ali Ahmed 28 Years Old Saudi Female From Jeddah , Housewife , Married For 2 Year , With No Special Habits Of Medical Importance . The Distance From The Hospital Is 15 Minutes , Admitted Through OPD On 3 - 10 -1436 H .

### - **C/O :**

She Has No Complaint , Just Admitted For Elective Cesarean Section .

### - **HPI :**

She Is Admitted For Cesarean Section Due To Contracted Pelvis .

\*\* Warning Symptoms : -Ve .

\*\* Systemic Review : No History Suggestive Of Other Systems Affection .

### - **Gynecological History :**

\*\* Age Of Menarche At 14 Years Old , Regular , Average Amount , 7/28 .

\*\* LMP : 3 - 1 -1436 H .

\*\* EDD : 17 - 10 -1436 H .

\*\* Gestational Age : 38 Weeks .

\*\* Contraceptive History : -Ve .

\*\* Sexual History : -Ve .

### - **Obstetric History :**

\*\* Primi-Gravida .

\*\* Current Pregnancy : Regular Antenatal Visits With No Complications In 1<sup>st</sup> , 2<sup>nd</sup> & 3<sup>rd</sup> Trimesters .

- **Past History :** -Ve .

- **Family History :** -Ve .

- **Social History :** Her Husband Is Teacher , With Good Socioeconomic Status .

- **Drugs & Allergies :**

No History Of Long / Short Term Medications , No History Of Allergy To Certain Food Or Medication .

### **Summary**

28 Y/O Saudi Female , Housewife , Married For 4 Years , Primi-Gravida In Her 38<sup>th</sup> Week Of Gestation Admitted Through OPD For Elective Cesarean Section Due To Contracted Pelvis With No Other Complaint .

# **History Of Common Cases**

## **9) Post-Cesarean Section :**

### - **Personal History :**

Fatimah Ali Ahmed 28 Years Old Saudi Female From Jeddah , Housewife , Married For 2 Year , With No Special Habits Of Medical Importance . The Distance From The Hospital Is 15 Minutes , Admitted Through OPD On 3 - 10 -1436 H .

### - **C/O :**

She Is Post-Op Cesarean Section / 2 Days .

### - **HPI :**

She Is Admitted For Elective Cesarean Section Due To Contracted Pelvis 2 Days Back With No Complain .

\*\* Post Partum Warning Symptoms : No Fever , No Severe Pelvic Pains , No Heavy Vaginal Bleeding , No Edema Of Lower Limb With Pain , No Foul Smelling Vaginal Discharge , No Redness/Mass In The Breast , No Flu Like Symptoms , No Symptoms Of Post Partum Depression .

\*\* Systemic Review : No History Suggestive Of Other Systems Affection .

### - **Gynecological History :**

\*\* Age Of Menarche At 14 Years Old , Regular , Average Amount , 7/28 .

\*\* Contraceptive History : -Ve .

\*\* Sexual History : -Ve .

### - **Obstetric History :**

\*\* P1 .

\*\* Previous Pregnancy : Full Term , Cesarean , Not Complicated , Result In Living Boy .

- **Past History :** -Ve .

- **Family History :** -Ve .

- **Social History :** Her Husband Is Teacher , With Good Socioeconomic Status .

- **Drugs & Allergies :**

No History Of Long / Short Term Medications , No History Of Allergy To Certain Food Or Medication .

### **Summary**

28 Y/O Saudi Female , Housewife , Married For 4 Years , Primi-Gravida Post-Op Elective Cesarean Section Due To Contracted Pelvis With No Post-Op Complications .

# **History Of Common Cases**

## **10) Post-Partum Hemorrhage :**

### - **Personal History :**

Fatimah Ali Ahmed 28 Years Old Saudi Female From Jeddah , Housewife , Married For 2 Year , With No Special Habits Of Medical Importance .

### - **C/O :**

Severe Vaginal Bleeding After 2 Hours Of Delivery .

### - **HPI :**

She Was Well till 8 Hours Back When She Started To Feel Labor Pain Then Came To Hospital For Delivery . During Delivery , No Progression Of Normal Delivery Occurred , Then The Nurse Used Assisted Vaginal Delivery Forceps , After 2 Hours Of Delivery The Patient Complained Of Acute Heavy Vaginal Bleeding , Increase Gradually , Bright Red Color , No Clots , No Aggravating Or Relieving Factor , Associated With Cold Extremities & Dizziness .

No History Of Abortion , Abruptio Placenta , Fetal Demise , Gestational HTN , Anemia OR Other Bleeding Disorder And No History Of Multiple Pregnancy .

\*\* Systemic Review : No History Suggestive Of Other Systems Affection .

### - **Gynecological History :**

\*\* Age Of Menarche At 14 Years Old , Regular , Heavy Amount With Clots , 7/28 .

\*\* Contraceptive History : -Ve .

\*\* Sexual History : -Ve .

### - **Obstetric History :**

\*\* p1

\*\* Previous Pregnancy : Full Term , Vaginal With Assisted Forceps , Not Complicated , Result In Living Boy & Breastfed For 1 Year .

- **Past History :** -Ve .

- **Family History :** -Ve .

- **Social History :** Her Husband Is Teacher , With Good Socioeconomic Status .

- **Drugs & Allergies :**

No History Of Long / Short Term Medications , No History Of Allergy To Certain Food Or Medication .

### **Summary**

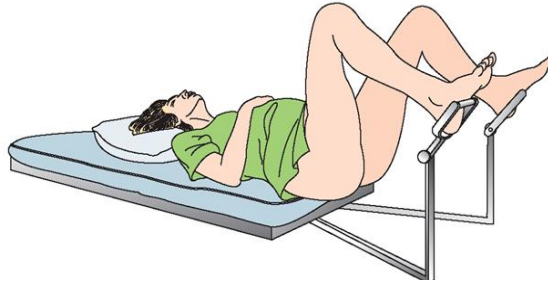
28 Y/O Saudi Female , Housewife , Married For 2 Years , Primi-Gravida With Severe Vaginal Bleeding After 2 Hours Of Delivery For Further Investigations & Management .



**Obstetric**  
**Examination**

# Obstetric Examination

- ✓ Abdominal Examination .
- ✓ Leopold's Maneuvers .



Pic.1

## \*\* Prerequisite Equipment :

- Examination Table For Placing The Patient In The Dorsal Position .
- Flexible Mobile Bedside Light Source .
- Sterile Gloves With Proper Size .
- Measuring Tape .
- Pinard Stethoscope ( Pic.2 ) : Normal Beats = 120-160 B/m .
- ✓ If Cephalic Presentation : Put Pinard In Mid-Way Between Umbilicus And Anterior Superior Iliac Supine( ASIS ) .
- ✓ If Breach Presentation : Put Pinard Above Umbilicus.
- ✓ If Transvers Lie : On Umbilicus .
- Empty Bladder .

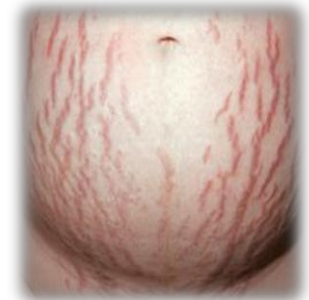

Pic.2

## \*\* Important Things In Abdominal Examination :

### # Inspection :

- **Contour** : Longitudinal / Transverse Distention .
- **Umbilicus** : Everted And Up / Flat .
- **Pigmentation** : Striae Gravidarum ( Pic.3 ) & Linea Nigra ( Pic.4 ) .
- **Visible Fetal Movement** .



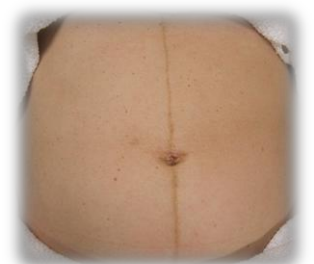Pic.3

### Notes :

- Striae Gravidarum : Slightly Depressed Linear Marks With Varying Length & Width In Pregnancy .
- Linea Nigra : Brown Color In The Mid Line Of Xiphisternum To The Pubis, It Disappear After The Delivery .

### # Palpation :

- **Superficial For** : Hotness , Tenderness , Rigidity , Mass .
- **Deep For** : Organomegally , Fetal Lying Position .



Pic.4

## **\*\* Leopold's Maneuvers :**

### **1- Fundal Level :** To Know The Gestational Age : ( Pic.1 )

- Centralized Uterus By Pushing From Right To Left ( Because The Uterus Is Dextrorotated ) .
- Palpate From Xiphisternum To Determined Fundus , Then Use Tape To Measure From Symphysis Pubic To Fundus ( Symphysio-Fundal Length ) .
- Each 1 Cm = 1 Gestational Week ( From 24 - 34 Weeks ) & Each Finger = 2 Cm .
- Fundal Level By Weeks : At Symphysis Pubis = 12 Weeks , At Umbilicus = 24 Weeks , Between Umbilicus And Xiphisternum = 36 Weeks , At Xiphisternum = 40 Weeks .

### **2- Fundal Grip :** By 2 Hands : ( Pic.2 )

- To Determine Which Part Of The Baby Occupying The Fundus : Cephalic , Breach OR Empty .
- Doctor Position Should Be Facing The Face Of The Mother .
- During Examination Palpate With One Hand & Fix The Other .
- If Cephalic : Characterized By Hard , Round , Regular , Ballottable & Not Comprisable .
- If Breach : Characterized By Soft , Irregular , Comprisable & Not Ballottable .
- If Empty : Indicates Transvers Lie OR Small Baby .

### **3- Lateral Grip :** By 2 Hands : ( Pic.3 )

- To Determine The Back And Limb At Which Side .
- Doctor Position Should Be Facing The Face Of The Mother .
- Back : Characterized By Linear , Firm , Feel Spines .
- Limb : Multiple Parts , Irregular , Mobile & Knobby ( Feel Knees , Feet & Elbow ) .

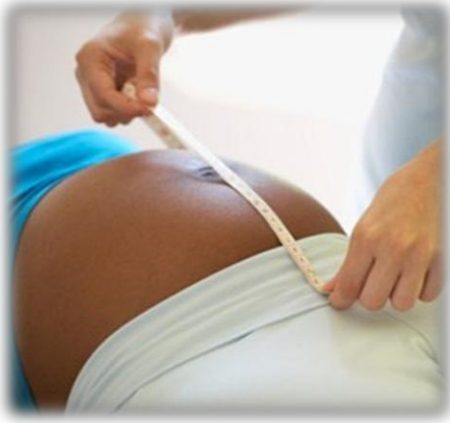### **4- 1<sup>st</sup> Pelvic Grip :** By ONE Hand : ( Pic.4 )

- To Determine Which Part Of The Baby Occupying The Pelvis .
- Doctor Position Should Be Facing The Face Of The Mother .
- **Technique** : Full Abduction Of The Thumb , Put Ulnar Part On The Symphysis Pubic , Then Gentle And Deeply Press The Lower Part Of Pelvic By Index And Thumb Fingers .

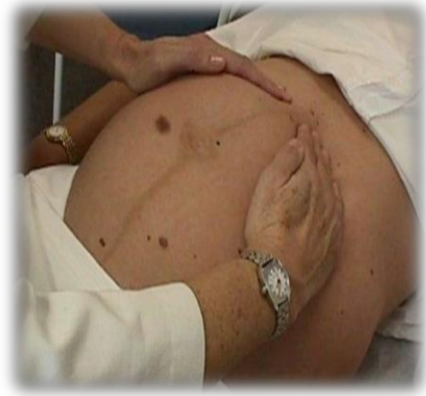### **5- 2<sup>nd</sup> Pelvic Grip :** By 2 Hands : ( Pic.5 )

- Determined The Attitude ( Position Of Fetus Is Extend OR Flex ) & Engagement ( Passage Of Widest Diameter Of Presented Part Of The Fetus In The Inlet Of Mother's Pelvis ) .
- Doctor Position Should Be Facing The Foot Of The Mother .

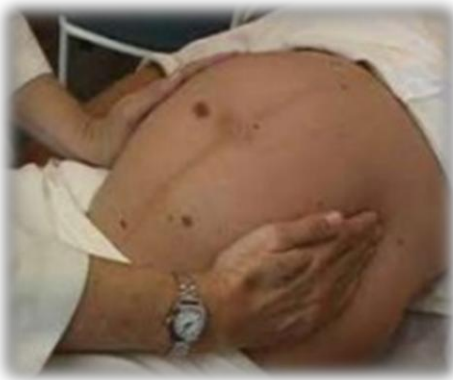



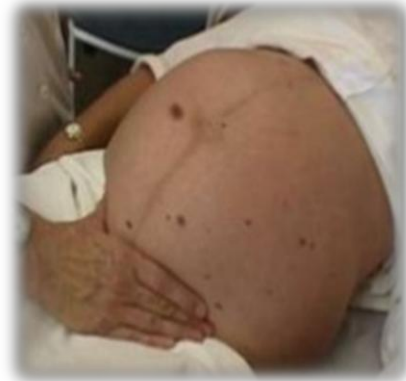**Pic.1**



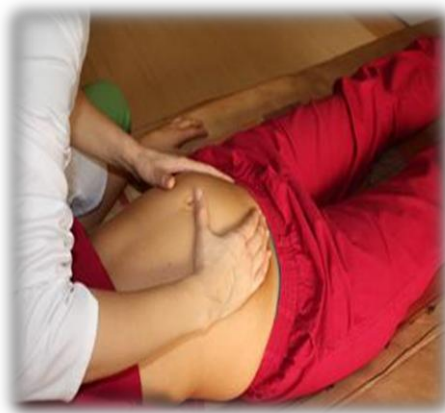**Pic.2**



**Pic.3**



**Pic.4**



**Pic.5**



**Gynecological**  
**Examination**

# Gynecological Examination

## 1) Speculum Examination

- Better To Use Self-Retaining Bivalve Cusco's Vaginal Speculum And Water / Lubricant . ( Pic.1 )

- Uses :

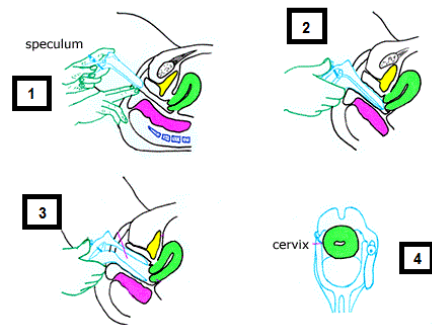
- ✓ Visualization Of Lateral Vaginal Walls .
- ✓ Visualization & Examination Of The Cervix .
- ✓ Taking High Vaginal Swap .
- ✓ Perform Pap-Smear .
- ✓ In Hormonal Study .
- ✓ In Colposcopy .
- ✓ In Small Procedures Such As Cauterization Of Cervix & Inserting Of IUCD .



**Pic.1**

### \*\* Prerequisite Equipment :

- Examination Table For Placing The Patient In The Dorsal Position .
- Flexible Bedside Light Source .
- Sterile Gloves With Proper Size .
- Metallic Cusco's Speculum .
- Sterile Lubricant / Water .
- Empty Bladder .



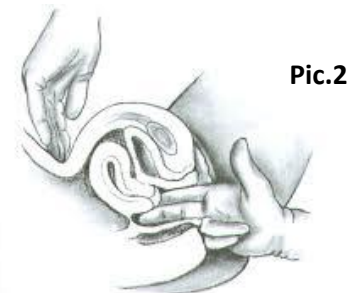
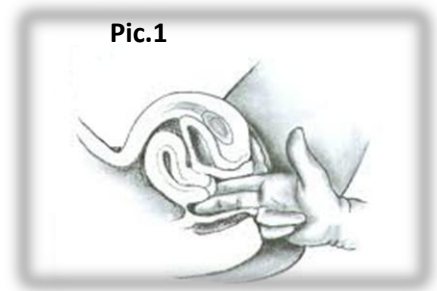
**Pic.2**

### \*\* Technique : ( Pic.2 )

- Put Some Warm Water / Lubricant On The Speculum .
- Use Left Hand For Separate The Labia .
- Insert It Longitudinal Then Turn It Into Transverse , The Screw Should Be Down .
- Visualize The Cervix And See The Cervix Shape : Round = Nulliparity , Transvers = Multiparity .
- Take Swap Or Any Sample Or Procedure .
- Remove It & Don't Forget To Screw It Off .

## 2) PV & Bimanual Examination

- Position : Dorsal Position Near To The Edge Of The Table .
- Exposure : Only Pelvic Area .
- Wash Your Hand & Wear Gloves .
- **Inspection :**
  - ✓ Pubic Hair Distribution .
  - ✓ Visible Mass OR Swelling In Vulvar Area .
  - ✓ Any Ulcer .
  - ✓ Any Discharge .
  - ✓ Prolapse ( Rare Case ) .



**\*\* Note : Bladder Should Be Empty .**

### **\*\* PV Examination : ( Pic.1 )**

- **1<sup>st</sup> Step :** Insert Your Index Finger And Press On The Posterior Vaginal Wall To Relax The Pelvic Floor Muscles .
- **2<sup>nd</sup> Step :** Examine Lateral Vagina Walls & Bartholine Gland By Index And Thumb .
- **3<sup>rd</sup> Step :** Palpate The Cervix By Index And Middle Fingers And Comment On :
  - ✓ **Position :** Anterior = Retro-verted Uterus , Posterior = Ante-verted Uterus .
  - ✓ **Consistency :** Soft = Normally , Firm .
  - ✓ **Shape :** Round = Nulliparity , Transvers = Multiparity .

### **\*\* Bimanual Examination : ( Pic.2 )**

- **1<sup>st</sup> Step :** After Examination Of The Cervix , Put Your Left Hand On The Abdomen ( On Umbilicus ) To Palpate The Uterus And Comment On Size And Consistency .
- **2<sup>nd</sup> Step :** Put Your Right Hand On The Lateral Vaginal Wall & Put Your Left Hand On The Abdomen Parallel To Inguinal Ligament To Palpate Adnexal Mass ( Ovary & Fallopian Tubes ) And Comment On Size And Consistency .

**E.g.:** Comment As Bulky Pelvic Mass , Measuring About 2 Fingers Under The Umbilicus , Mobile And Firm In Consistency With No Palpable Adnexal Mass .



# **Other Procedures**

# Other Procedures

## 1) Taking High Vaginal Swab

### \*\* Prerequisite Equipment :

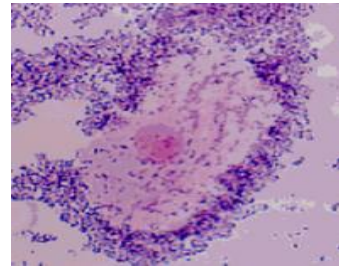
- Good Light Source .
- Sterile Gloves .
- Cusco's Vaginal Speculum .
- High Vaginal Swab Stick & Sterile Container . ( Pic.1 )
- Empty Bladder .



Pic.1

### \*\* Best Site To Take The Sample :

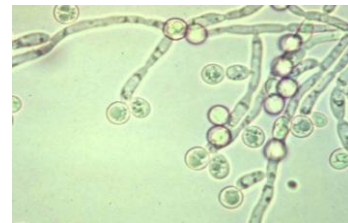Posterior Fornix : Because it Is Widest And Deepest Fornix .



Pic.2

### \*\* Other Sites To Take The Sample :

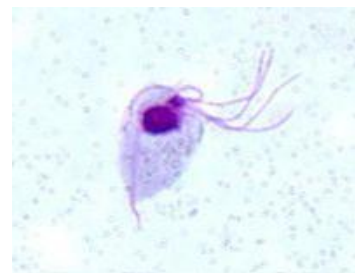- Cervical Canal .
- Lateral Vaginal Walls : In Hormonal Studies .



Pic.3

### \*\* Notes :

- Fish Odour Discharge + Clue Cells Under Microscope = Bacterial Vaginosis . ( Pic.2 )
- Hyphae Buds Under Microscope = Candida Albicans . ( Pic.3 )
- Motile Organisms Under Microscope = Trichomoniasis . ( Pic.4 )



Pic.4

## 2) Performing Pap Smear

### **\*\* Prerequisite Equipment :**

- Good Light Source .
- Sterile Gloves .
- Cusco's Vaginal Speculum .
- Cyto-Brush . ( Pic.1)
- Glass Slides .
- Fixative .
- Empty Bladder .



**Pic.1**

### **\*\* Procedure :**

- Put The Patient In The Dorsal Position .
- Wash Hands & Wear Gloves .
- Examine The Vulva & Outer Vagina Checking For Any Obvious Abnormality .
- Warm The Blades Of The Speculum By The Water ( Best Lubricant Used ) .
- Inform The Patient That You Are About To Start The Procedure .
- Insert The Speculum ( As Mentioned Before ) .
- Place The Tip Of The Cyto-Brush Into The External Os And Rotate It 180 Degree .
- Remove The Brush & Wiped Into The Slides Then Applying Fixator And Wait 10 Minutes To Dry Sample .
- Sending To The Laboratory For Cyto-pathological Examination .
- Carefully Remove Speculum .

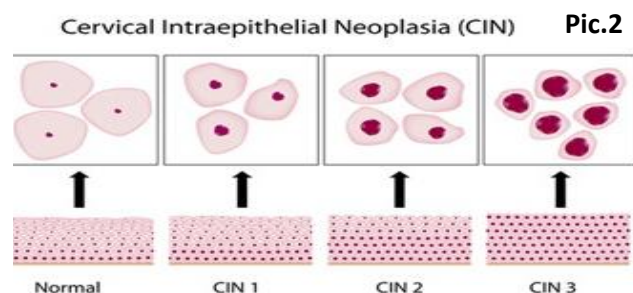
### **\*\* Notes :**

- Cyto-Brush : Contain 2 Shoulders + Tapering :
  - ✓ Tapering Collect Cells From Endo-Cervix ( Opening Of External Os ) .
  - ✓ 2 Shoulder Collect Cells From Exo-Cervix ( Beside The Opening ) .

**\*\* Indications :** HPV Infection , Cervical Hyperplasia , Cervical Cancer .

### **\*\* Classification Of Pap Smear Result : ( Pic.2)**

- Normal .
- Inflammatory .
- Mild Dysplasia ( CIN 1 ) .
- Moderate To Severe ( CIN 2 & 3 ) .
- Carcinoma In Situ ( CIS ) .




### **3) Catheterization**

- Better To Use Self-Retaining Double Way Foley's Catheter . ( Pic.1 )

#### **\*\* Prerequisite Equipment :**

- Good Light Source .
- Foley's Catheter With Appropriate Size .
- Urine Bag .
- Sterile Gloves .
- Sterile Syringe .
- Lubricant ( Xylocaine Jelly ) .
- Antiseptic Solution .
- Sterile Cotton .
- Sterile Forceps .



**Pic.1**

#### **\*\* Procedure :**

- Wear Gloves , Then Clean The Pubic Area And Medial Side Of Thigh By Antiseptic Solution & Cotton .
- Check The Balloon And Connect The Urine Bag .
- Separate The Labia By Non-Dominant Hand .
- Catch The Catheter & Put The Lubricant .
- Insert The Catheter Without Touch Anything .
- Push The Catheter Till Urine Come Out , The Push Few Centimeters .
- Inflate The Balloon With Water Or Normal Saline To Avoid Detachment .
- Finally , Tape It Into The Thigh .

#### **\*\* Indications :**

- Before Any Obstetric & Gynecological Examination .
- In Monitoring Of Urine Output .
- In Cesarean Section .
- In Taking Urine Sample .
- In Cystometry .
- In Ashermann Syndrome .



**\*\* Contraindications :**

- Urethral Injury .

**\*\* Complications :**

- Urethral Injury .
- Bleeding .
- Infection .
- Stenosis .

**\*\* Difficulties :**

- Obesity .
- Previous Child Birth .
- Incorrect Position .

**\*\* Note : If You Put The Catheter BUT No Urine Come Out , It May Be Due To :**

- Obstruction Of Catheter .
- Anuria ( In Pre-Eclampsia ) .



**DDx In**  
**Obs/Gynae**

# **DDx In Obs/Gynae**

## **\*\* Uterus Larger Than Date :**

- Miscalculation .
- Multiple Pregnancy .
- Fibroid With Pregnancy .
- Polyhydraminous .
- Molar Pregnancy .
- Macrosomia .
- Hydrocephalous .
- Hydrops .

## **\*\* Uterus Smaller Than Date :**

- Miscalculation .
- Microsomia
- Oligohydraminous .
- Transverse Lie .
- Intra-Uterine-Growth-Restriction ( IUGR ) .
- Intra-Uterine-Fetal-Death ( IUFD ) .

## **\*\* Bleeding In Early Pregnancy :**

- Abortion ( Bleeding Followed By Pain ) .
- Ectopic Pregnancy ( Pain Followed By Bleeding ) .
- Molar Pregnancy OR Vesicular Mole .
- Local Causes .

### **\*\* Bleeding In Late Pregnancy :**

- Abruptio Placenta ( Painful , Heavy Bleeding , Rupture Of Membrane & Hx Of Trauma ) .
- Placenta Previa ( Causeless , Painless , Recurrent & Fresh ) .
- Vasa Previa
- Incidental Causes ( Trauma , Cervicitis , Genital Tumor ) .

### **\*\* Persistent Vomiting ( Hyperemesis Gravidarum ) :**

- Molar Pregnancy .
- Ectopic Pregnancy .
- Drug Toxicity .
- Eating Disorders .
- Gastro-Paresis .
- Migraines .
- Ovarian Torsion .
- Pseudo-Tumor Cerebri .
- Psychological Disorders .
- Vestibular Lesions .

### **\*\* Soft Uterus :**

- Pregnancy .
- Molar Pregnancy .
- Ectopic Pregnancy .
- Cystic Fibroid .

### **\*\* Firm Uterus :**

- Sub-Serous Fibroid .
- Adenomyosis .
- Sub-Mucous Fibroid .
- Uterine Cancer

### **\*\* Adnexal Mass :**

- Salpingitis .
- Ovarian Cyst .
- Follicular Cyst .
- Corpus Luteal Cyst .
- Ectopic Pregnancy .
- Cecum Tumor .
- Appendicitis .

### **\*\* Pelvic Mass :**

- Normal Intrauterine Pregnancy .
- Molar Pregnancy .
- Uterine Fibroid .
- Advanced Uterine Carcinoma .
- Hematometra / Pyometra .
- Hydro- / Pyosalpinx .
- Tubo-Ovarian Abscess .
- Ovarian Torsion .
- Benign Cyst .
- Endometrioma .

### **\*\* Pelvic Pain :**

- Adenomyosis .
- Degenerating Uterine Fibroid .
- Ectopic Pregnancy .
- Endometriosis .
- Ovarian Torsion .
- Pelvic Inflammatory Disease ( PID ) .
- Ruptured Ovarian Cyst .
- Tubo-Ovarian Abscess .

### **\*\* Primary Amenorrhea :**

- Genetic Or Anatomic Abnormalities .
- Hypogonadotropic Hypogonadism Includes The Following :
  - ✓ Congenital Abnormalities .
  - ✓ Endocrine Disorders .
  - ✓ Tumor .
  - ✓ Systemic Illness .
  - ✓ Eating Disorder .

### **\*\* Secondary Amenorrhea :**

- Pregnancy .
- Weight Loss / Anorexia .
- Chronic Anovulation Including PCOS .
- Hypothyroidism .
- Cushing Syndrome .
- Pituitary Tumor .
- Empty Sella Turcica .
- Sheehan Syndrome .

# References

## Medicine :

- Clinical Examination ; Nicholas J Talley & Simono`Connor . 6<sup>th</sup> Edition.
- Medical Diagnosis & Management ; Inam Danish. 11<sup>th</sup> International Edition .
- Oxford American Examination Handbook .
- Essential Of Clinical Medicine , Magdy Ishak Atallah .

## Surgery :

- Hamad Alqahtani Book , Second Edition .
- Al-Matary Clinical Book .
- Browse's Textbook .

## Pediatrics :

- Manual of pediatrics - Nasser Gamal .
- Manual of clinical pediatrics - Mansour N. Alhowasi .
- Essentials of Pediatrics - Nelson .
- <http://learnpediatrics.com>

## Obstetric & Gynecology :

- Essential Of Obstetric & Gynecology .
- Medscape .

## Pictures :

- Google Pictures .