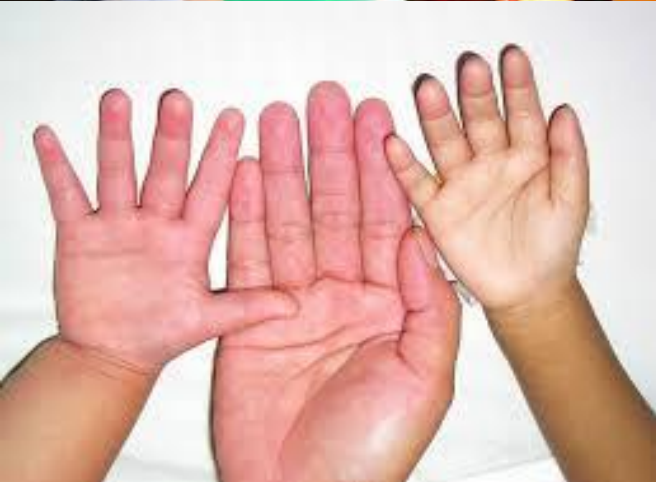



CHILD WITH PALLOR

Dr. Houwayda Al Hagi
Pediatric specialist
Hematology interest
(MRCPCH/ABMS)

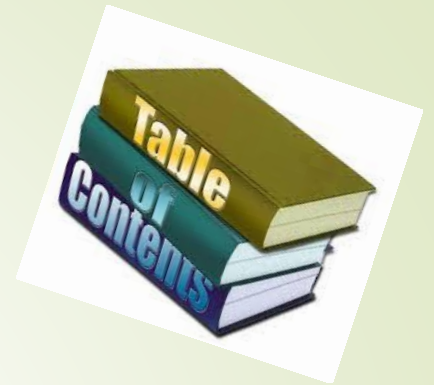2017



Objectives

- To list the different causes of pallor.
- To simplify the practical classifications.
- To stress on the relevant point in history and finding in the examination that enable you to reach a diagnosis.
- To know how to approach different scenarios.

Contents:



- Pallor(definition, physiology and causes).
- Practical classification of anemia.
- Approach to anemic child(history and examination).
- Three case scenarios.

PALLOR:

- Is the paleness of skin and M.M, due to the reduced amount of oxyhemoglobin or decreased peripheral perfusion.

Causes:

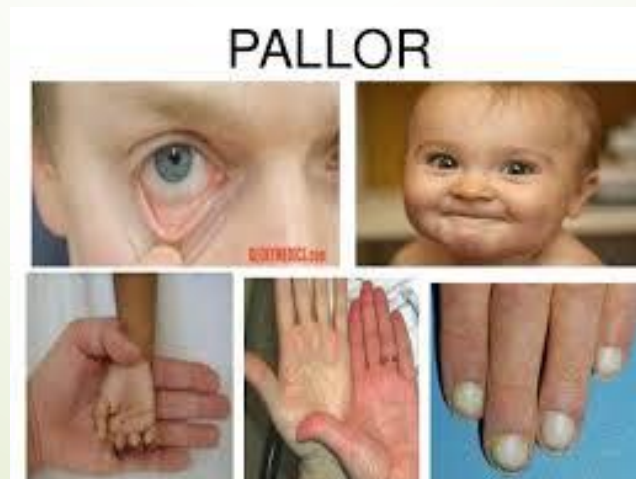Hematological
(anemia)

non hematological

- Physiologically
- Skin edema
- Shock & Anaphylaxis
- Resp. distress
- Hypoglycemia

Anemia:

- Anemia is defined as a condition in which the hemoglobin (Hb) and/or HTC concentration is below 2 SD in peripheral blood lower than normal for age, sex, and pregnancy state of the subject.



Physiology of anemia

► Physiologic adjustments to anemia include

- 1) Increased cardiac output.
- 2) Shunting of blood flow toward vital organs and tissues.
- 3) The concentration of 2,3-diphosphoglycerate (2,3-DPG) increases within the RBC. resultant “shift to the right” of the oxygen dissociation curve.
- 4) Higher levels of erythropoietin (EPO) and consequent increased red cell production by the bone marrow.

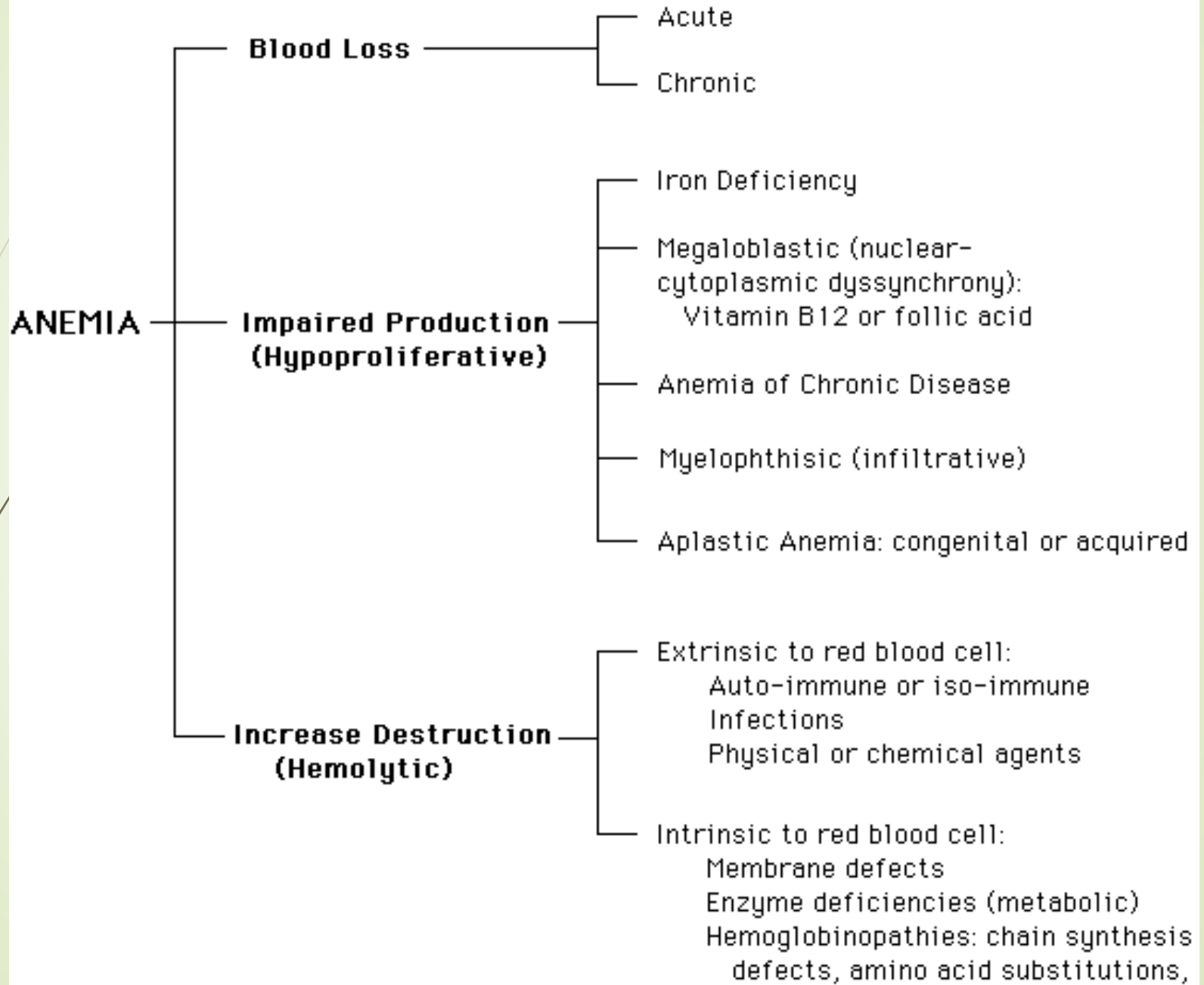
AGE	Hb	HCT	MCV
At birth	16.8(13.7-20.1)	55 (45-65)	110-120
3 Month	12 (9.5- 14.5)	36 (31-41)	100
6 Mo- 6yr	12 (10.5-14)	37 (33-42)	70-74
7-12 yr	13 (11-16)	38(34-40)	76 -80
Adult			
Male	16(14-18)	47(42-52)	80
Female	14(12-16)	42(37-47)	80

In general the anemic child:

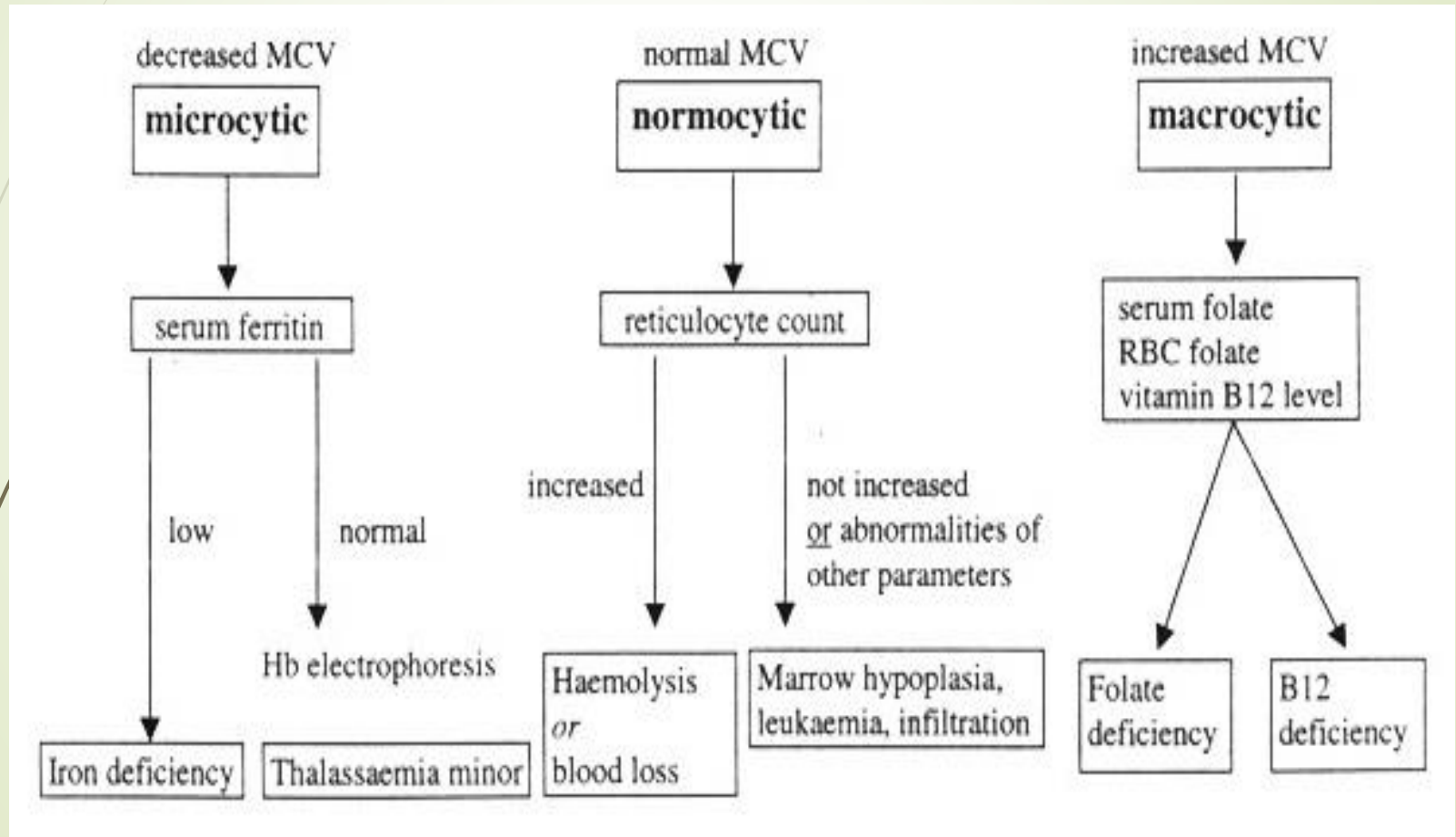
- Neonate: Hb <14g/dl
- 1-12 months: Hb <10g/dl
- 1-12 years: Hb <11g/dl.



CLASSIFICATION OF ANEMIAS




Morphological classification



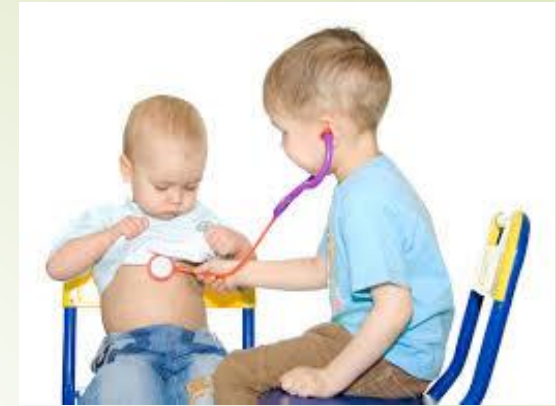Approach to a child with anemia

History

- ➔ **M/C: Pallor:** onset & duration, progression association (fever, yellowish discoloration, abd. Pain/distension, change in bowel habit and color of urine, skin rash.
- ➔ Activity of child, headache, sleep and mood disturbance.
- ➔ **H/O** blood loss (nose, gum, GIT, menstruation if adolescent girl.

- 
- **PMH:** anemia before, blood transfusion, medication.
 - Development and schooling.
 - **Diet history:** type of food ,eating behavior, milk amount and type ,pica (pagophagia).
 - Drug history:(eg: anticonvulsent).
 - **F/H:** same illness, splenectomy, GS, BI.Tx.
 - **S/H:** consanguinity, economic status.... etc.

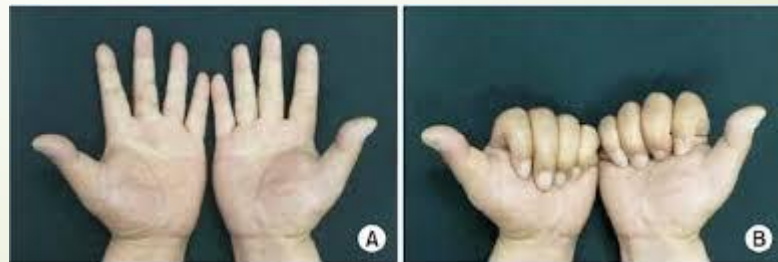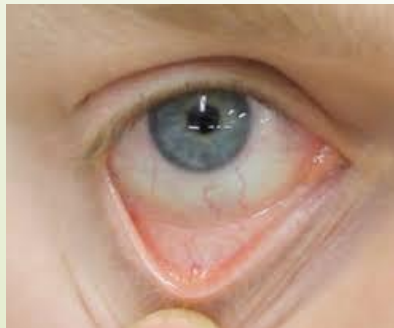Examination

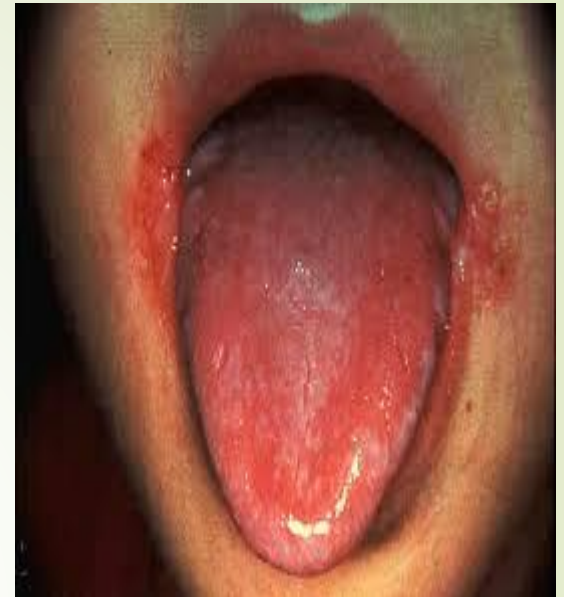
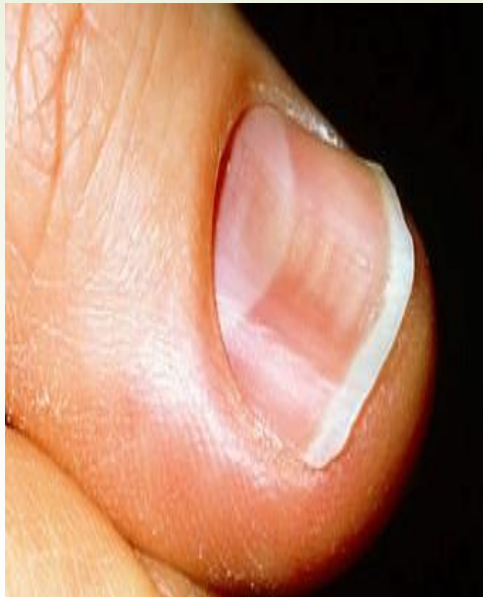
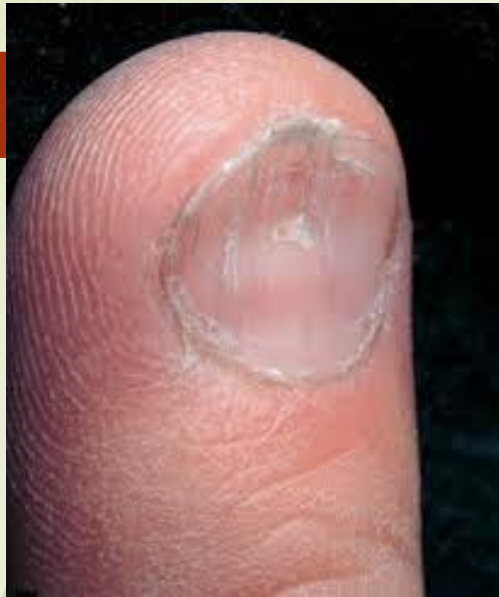- Well or unwell?
- Vital signs and growth parameters.
- Associated congenital anomalies
- Pallor, jaundice, glossitis, angular stomatitis, skin stigmata, a koilonychia, other signs of nutritional deficit, hepatosplenomegaly and LAP.

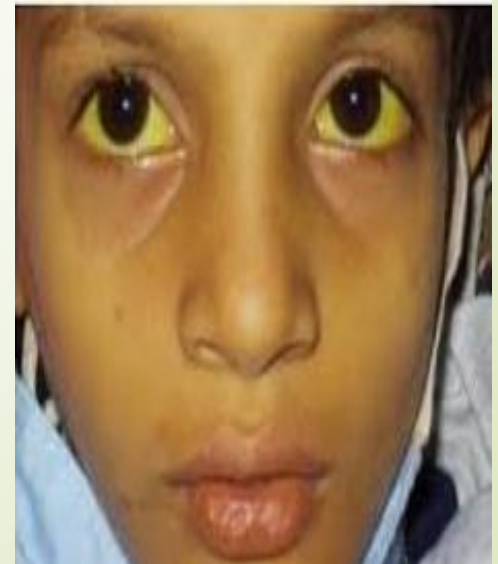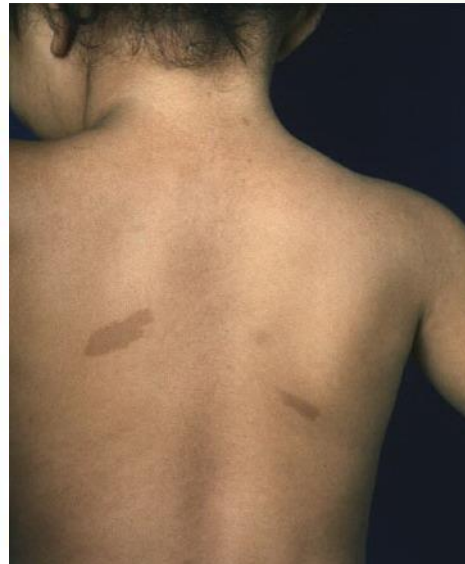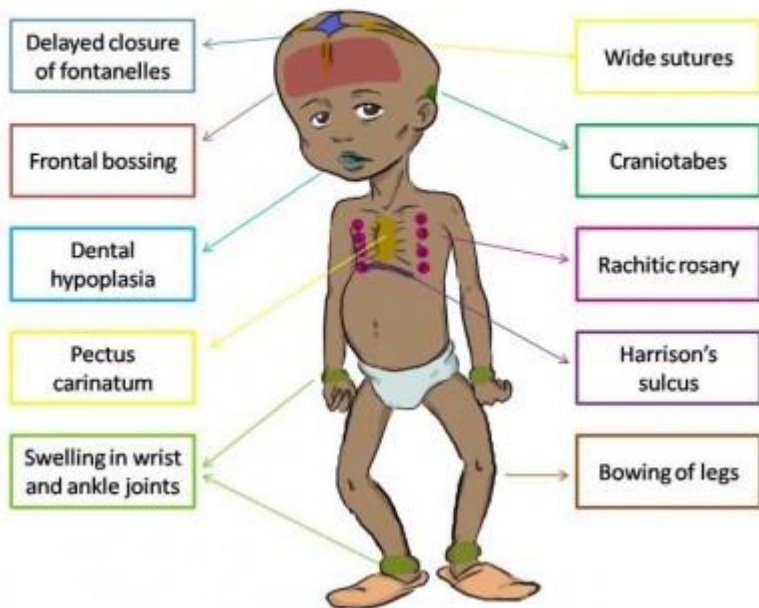
Where to look for pallor?

1. Lower palpebral conjunctiva.
2. Lips
3. Tip and dorsum of the tongue.
4. Nail beds.
5. Palmar or plantar creases.
6. General body skin





10 important clinical features in Rickets



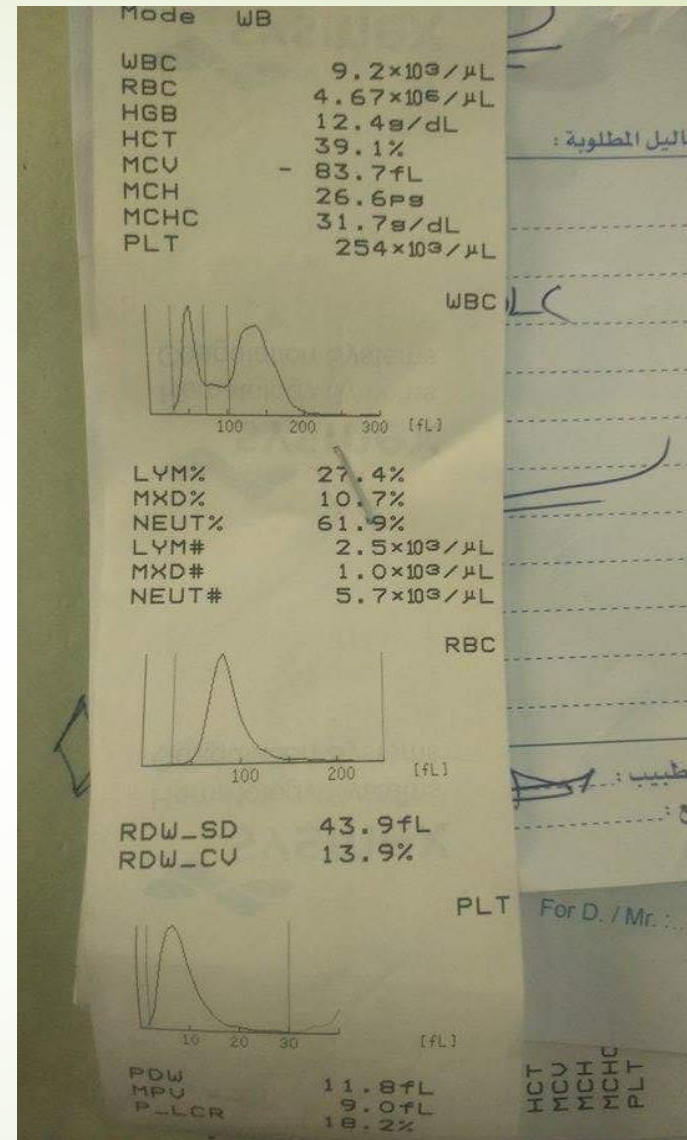


Basic investigations

- **Complete blood count.**
- Blood film.
- Retic`s count.
- Total bilirubin (direct & indirect).
- Serum ferritin, TIBC, serum iron.
- Direct Coombs Test (DCT/DAT).
- Bone marrow aspiration.

Look for:

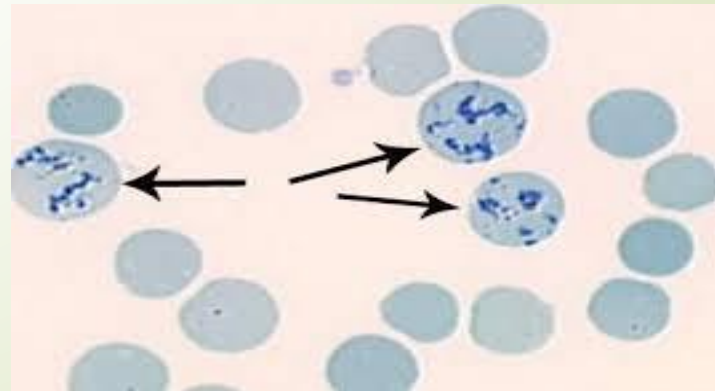
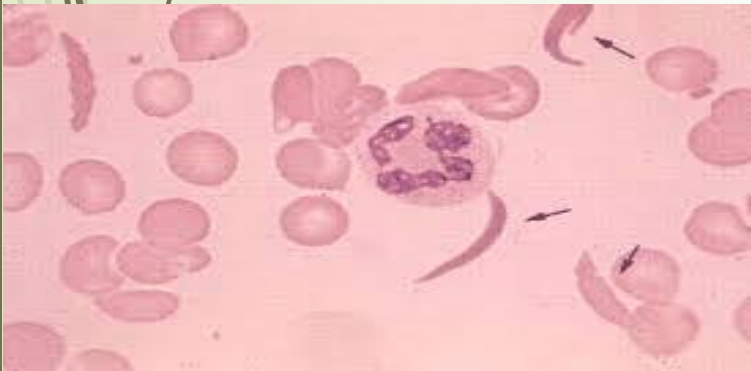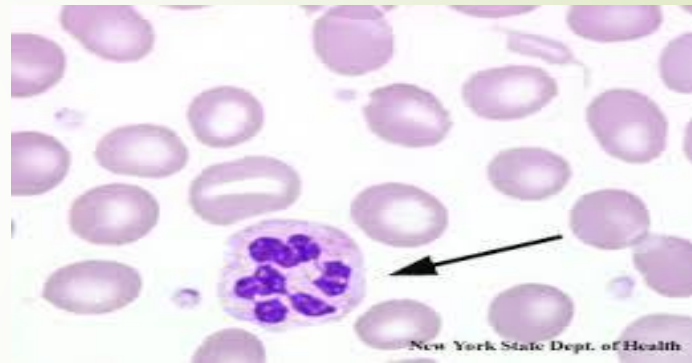
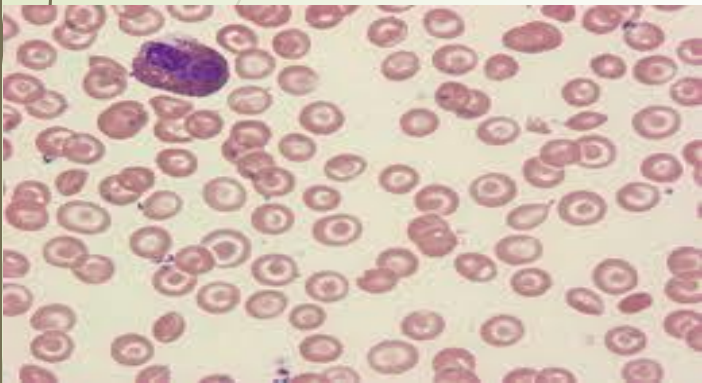
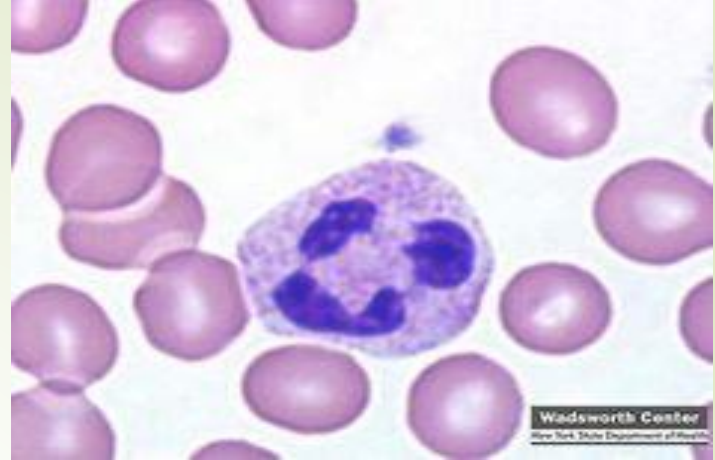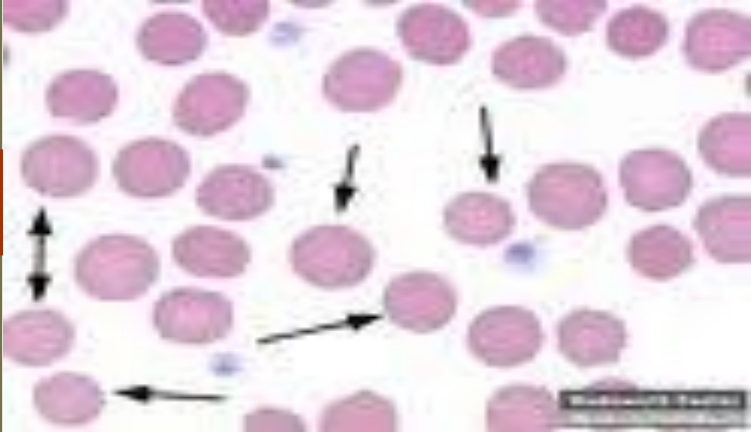
- HGB
- RBC
- MCV
- MCHC
- RDW
- (WBC, PLT)





Basic investigations

- Complete blood count.
- **Blood film.**
- **Retic`s count.**
- Total bilirubin (direct & indirect).
- Serum ferritin, TIBC, serum iron.
- Direct Coombs Test (DCT/DAT).
- Bone marrow aspiration.



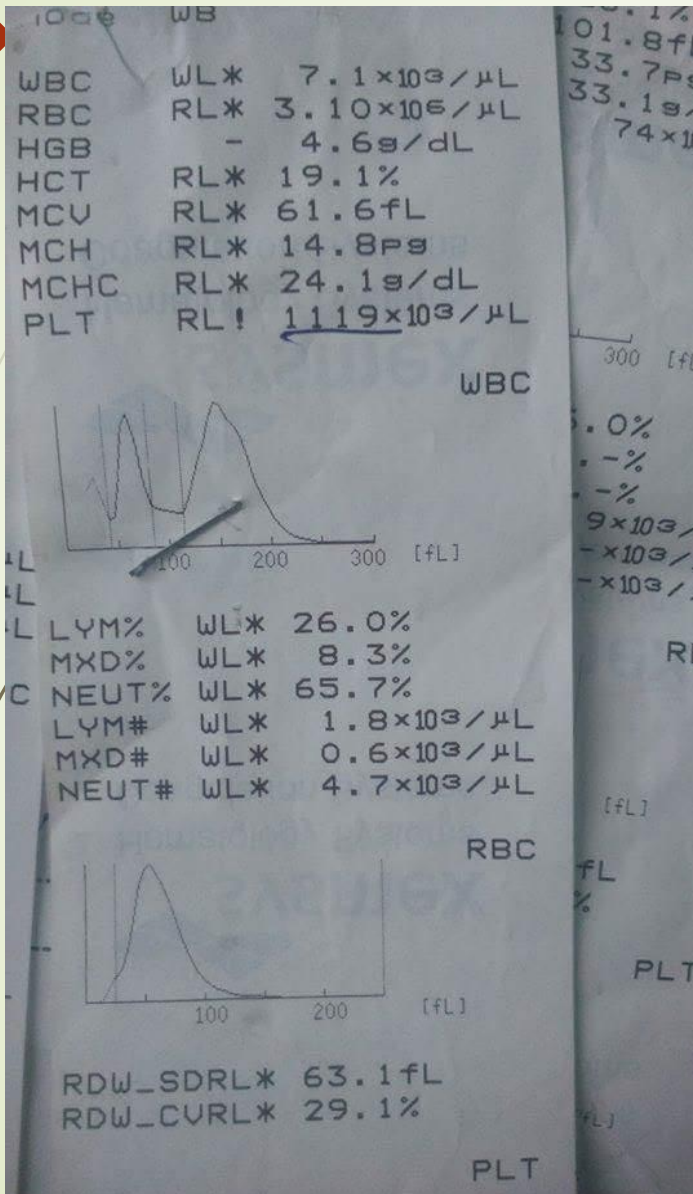


Basic investigations:

- Complete blood count.
- Blood film.
- Retic`s count.
- Total bilirubin (direct & indirect).
- Serum ferritin, TIBC, serum iron (IDA).
- Direct Coombs Test (DCT/DAT).
- +/- Bone marrow aspiration.

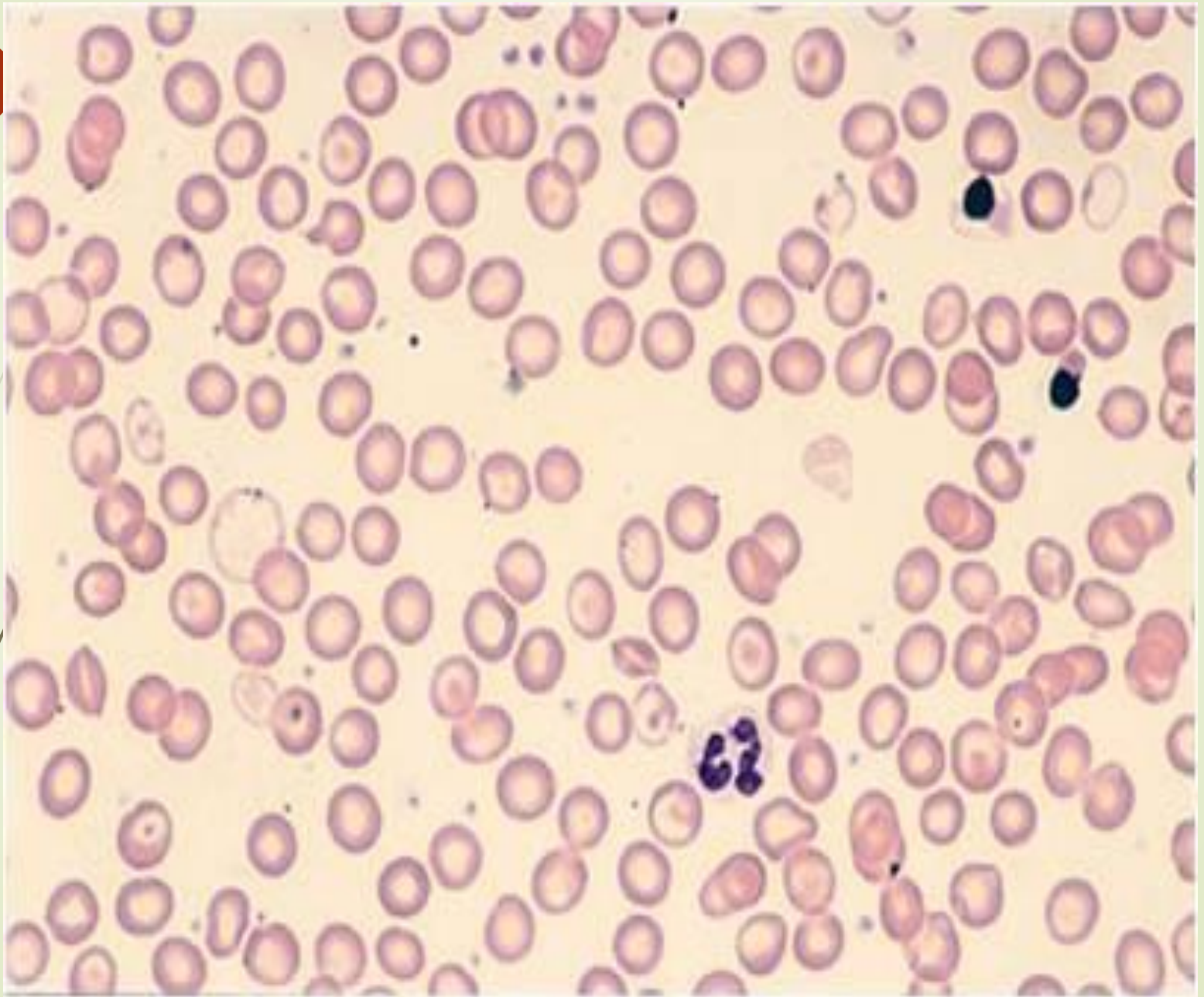
Case (1)

- *A 22 month old boy presents with pallor. A visiting relative who has not seen the child for 5 months told his mother that the boy appears pale. he is an active toddler, with no recent fatigue, increase in sleeping, or exercise intolerance. He has had no blood in his diapers and no black or tarry stool. He is a picky eater, taking only small amounts of chicken, beef, and some vegetables, but loves milk and drinks six to eight bottles of whole milk daily; Family history reveals no H/O splenectomy, gall stones at an early age, or other anemia in the family. **What is the diagnosis?***



Abnormalities

- HGBlow
- MCV.....Low
- Plt.....high
- RDW.....high





Diagnosis: Nutritional iron deficiency anemia

Why?

Investigations:

- CBC, blood film, Retic`s count.
- S.iron, S. Ferritin, TIBC
- Stool for occult blood.

Treatment:

- Diet modification
- Ferrum supplement.

Case (II)

- ▶ 3yr old boy, mother noticed pallor and yellowish eyes, decreased activity today morning ,which is worsening by time.

2D ago visited his grandfather`s farm when he was completely healthy at that time .

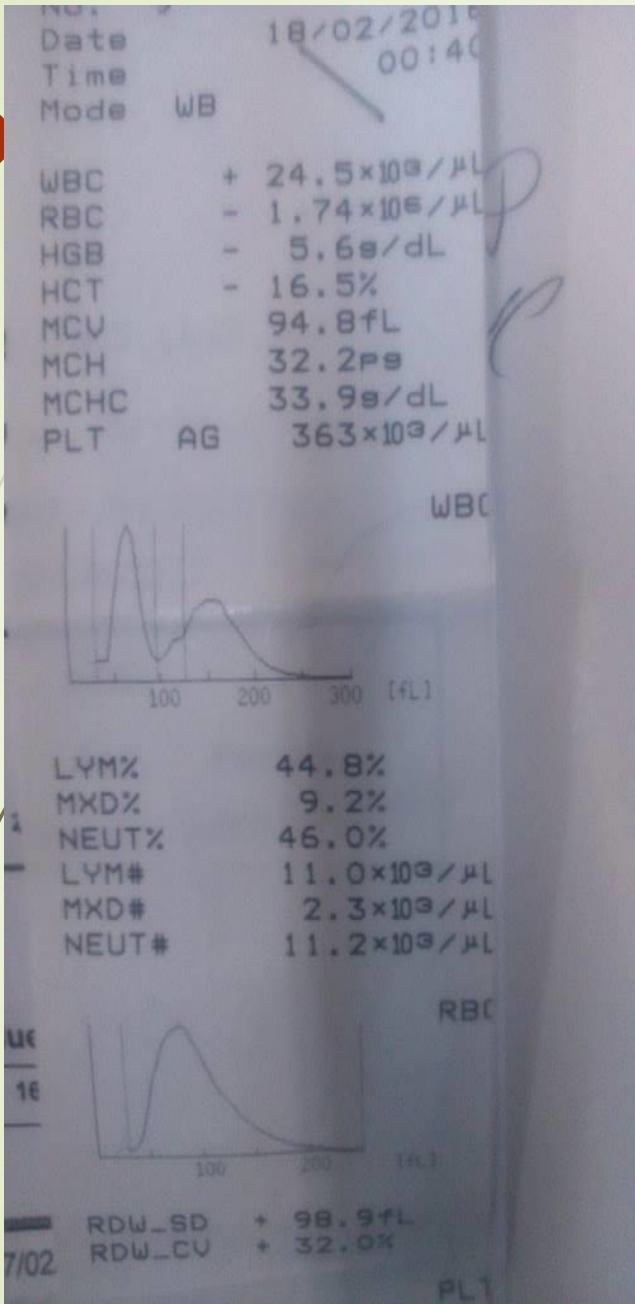
Sought medical advice in polyclinic, reassured and honey was recommended !!!! but he didn`t improved !

O/E: average built, pale, jaundiced, weak,

HR=170 RR=50, liver 3cm and tender

Diagnosis?





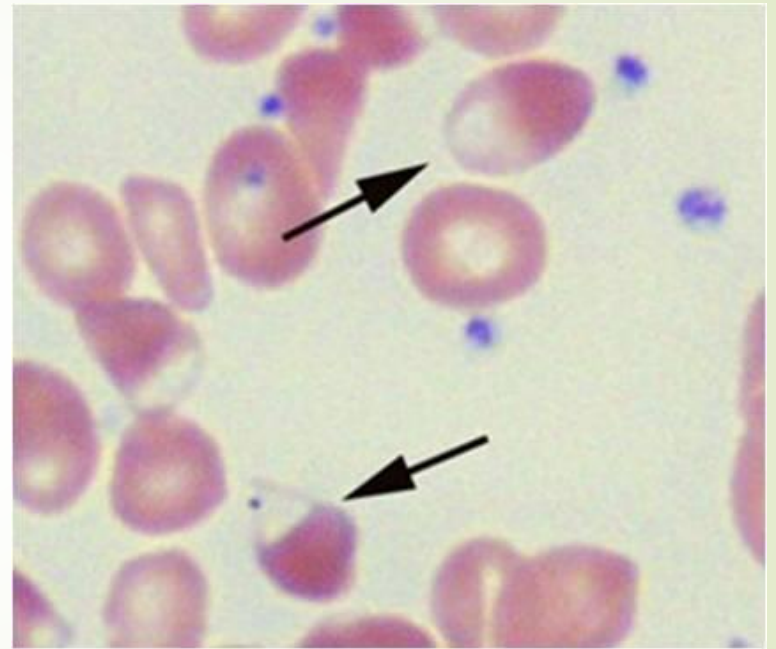
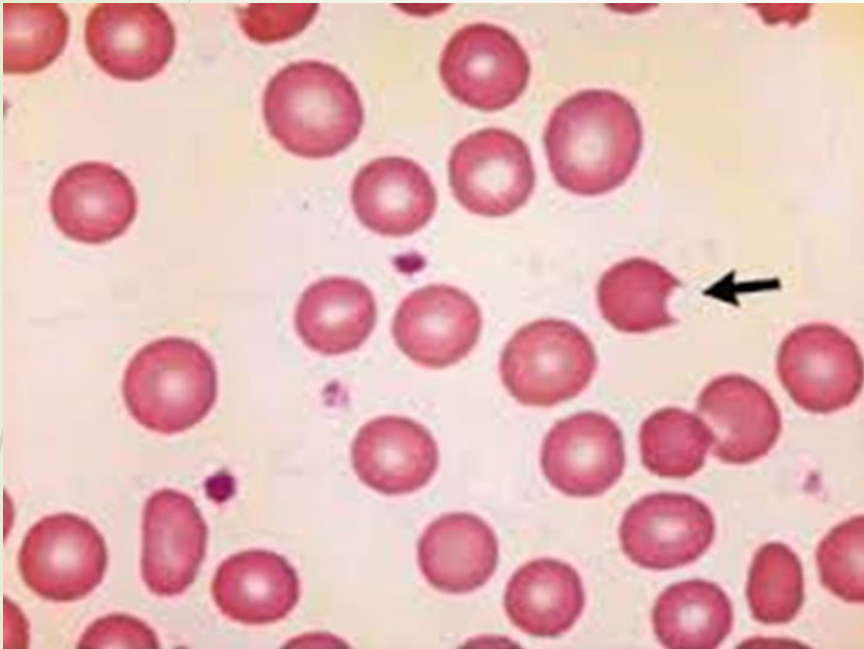
➔ Retics count= 8%

Entered: 16:49 Dec 16 2014

Position: 1
Segment: C

TEST	RESULT	REF. INTERVAL
TBI	3.0 HI	measurement
DBI	0.41 HI	measurement

(bite and blister cell)





Diagnosis is hemolytic anemia. (G6PDH)

Management:

- Blood transfusion(if needed)
- Avoid fava beans ingestion.
- Avoid drugs and chemicals that precipitate the disease
- Confirmatory test: G6PD enzyme level after 2-3 months.

Other causes of hemolytic anemia:

- 1) Membrane defect: Hereditary Spherocytosis.
- 2) Enzyme defect: G6PDH, pyruvate kinase def.
- 3) Hemoglobinopathy: - sickle cell anemia
- β -thalassaemia major
- 4) Immune: Autoimmune hemolytic anemia(AIHA)



Investigations:

- CBC
- Blood film (RBC morphology)
- Reticulocyte count (raised).
- Elevated unconjugated bilirubin & LDH.
- Excess urinary urobilinogen.
- Direct antiglobulin/DCT (Positive in AIHA).
- Osmotic fragility test (H. Spherocytosis).

Case (III)


➔ 9 year old boy referred from orthopedist with anemia Hb= 7g/dl, he presented to him because of Rt. thumb deformity.

O/E: short stature, pale, not jaundiced, multiple coffee auilat spots and multiple bruises all over the body and no organomegaly no lymphadenopathy.

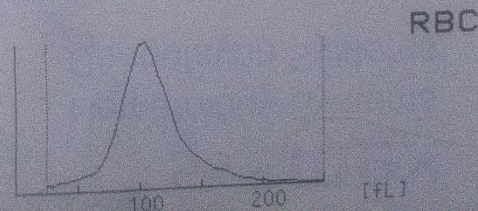
What is the diagnosis?

No. 4
Date 08/10/2015
Time 09:41
Mode WB

WBC - $2.2 \times 10^3 / \mu\text{L}$
RBC - $1.89 \times 10^6 / \mu\text{L}$
HGB - 6.6g/dL
HCT - 20.1%
MCV 106.3fL
MCH 34.9Pg
MCHC 32.8g/dL
PLT PL* $19 \times 10^3 / \mu\text{L}$



LYM% + 79.2%
MXD% T2 ---.-%
NEUT% T2 ---.-%
LYM# $1.7 \times 10^3 / \mu\text{L}$
MXD# T2 ---. $\times 10^3 / \mu\text{L}$
NEUT# T2 ---. $\times 10^3 / \mu\text{L}$

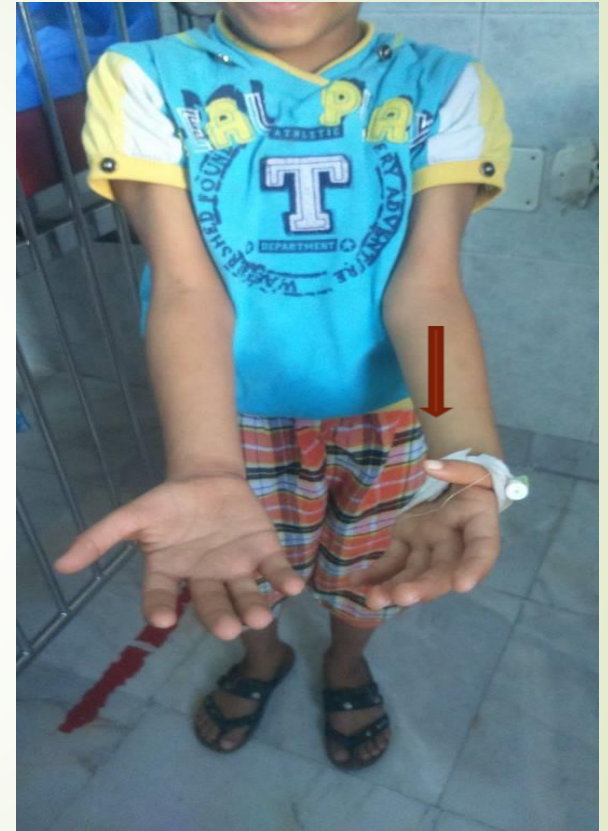
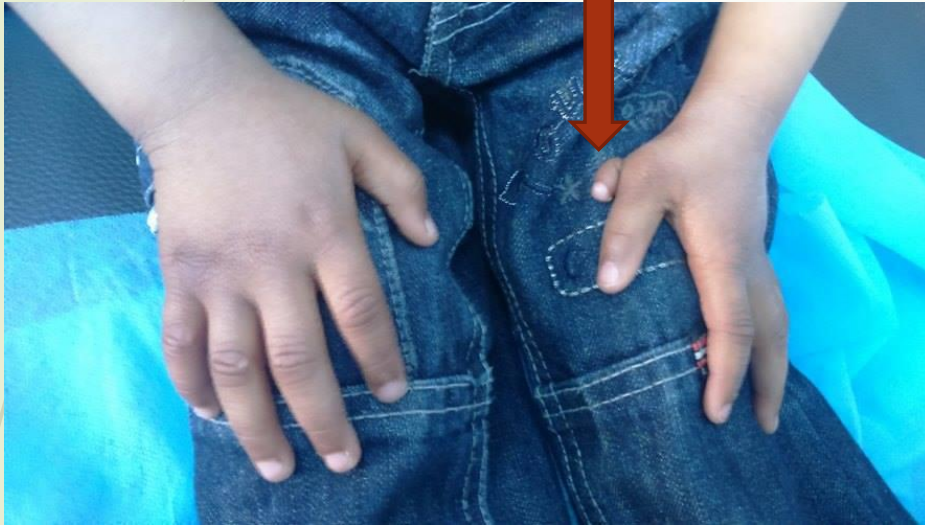
Abnormalities:

- Leucopenia
- RBC.... low
- HGB.... low
- MCV...high
- Plt....low

pancytopenia

Fanconi anemia



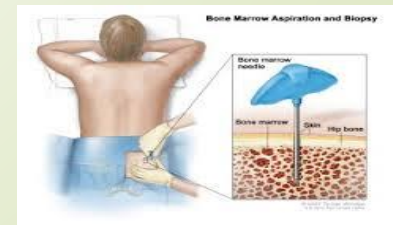Fanconi anemia

Investigations:







- CBC, blood film, low Retic count.
- hemoglobin electrophoresis (high HF).
- BMA & Biopsy (hypocellular).
- U/S abd. & Echocardiography.
- Chromosomal breakage and gene analysis

Treatment:

- Symptomatic: -PRBC& PLATELET transfusion
- antibiotic to treat infection
 - BMT



Pallor with some associations

- ➔ Pallor and jaundice  hemolytic anemia.
- ➔ Pallor/jaundice/black race.  SCA.
- ➔ Pallor/jaundice/fava beans ingestion  G6PD.
- ➔ Pallor/fever/LAP±HSM  infection/malignancy
- ➔ Pallor/edema/rickets  malnutrition
- ➔ Pallor/skin manifestation /dysmorphism  FA

Questions
??????

