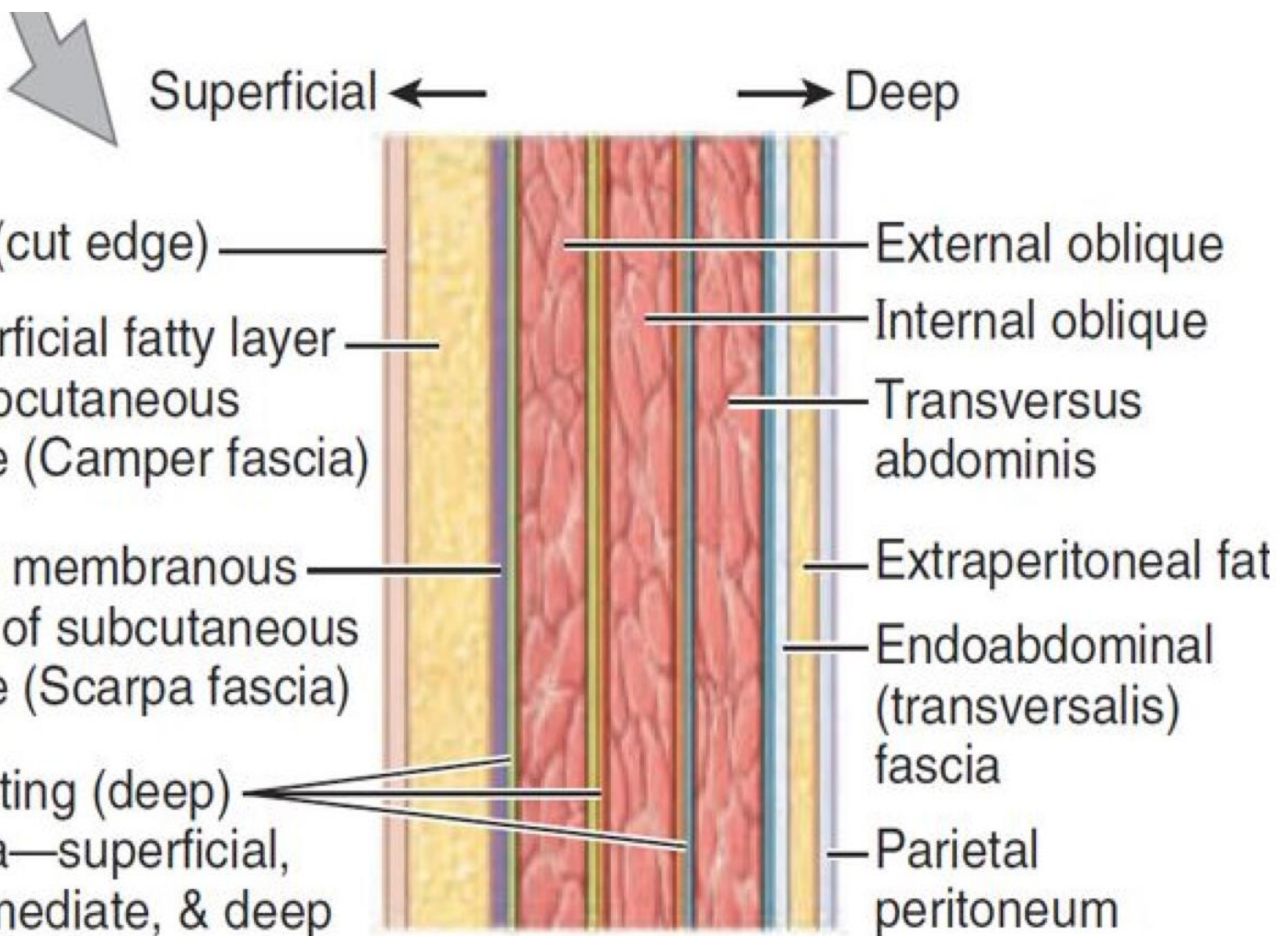


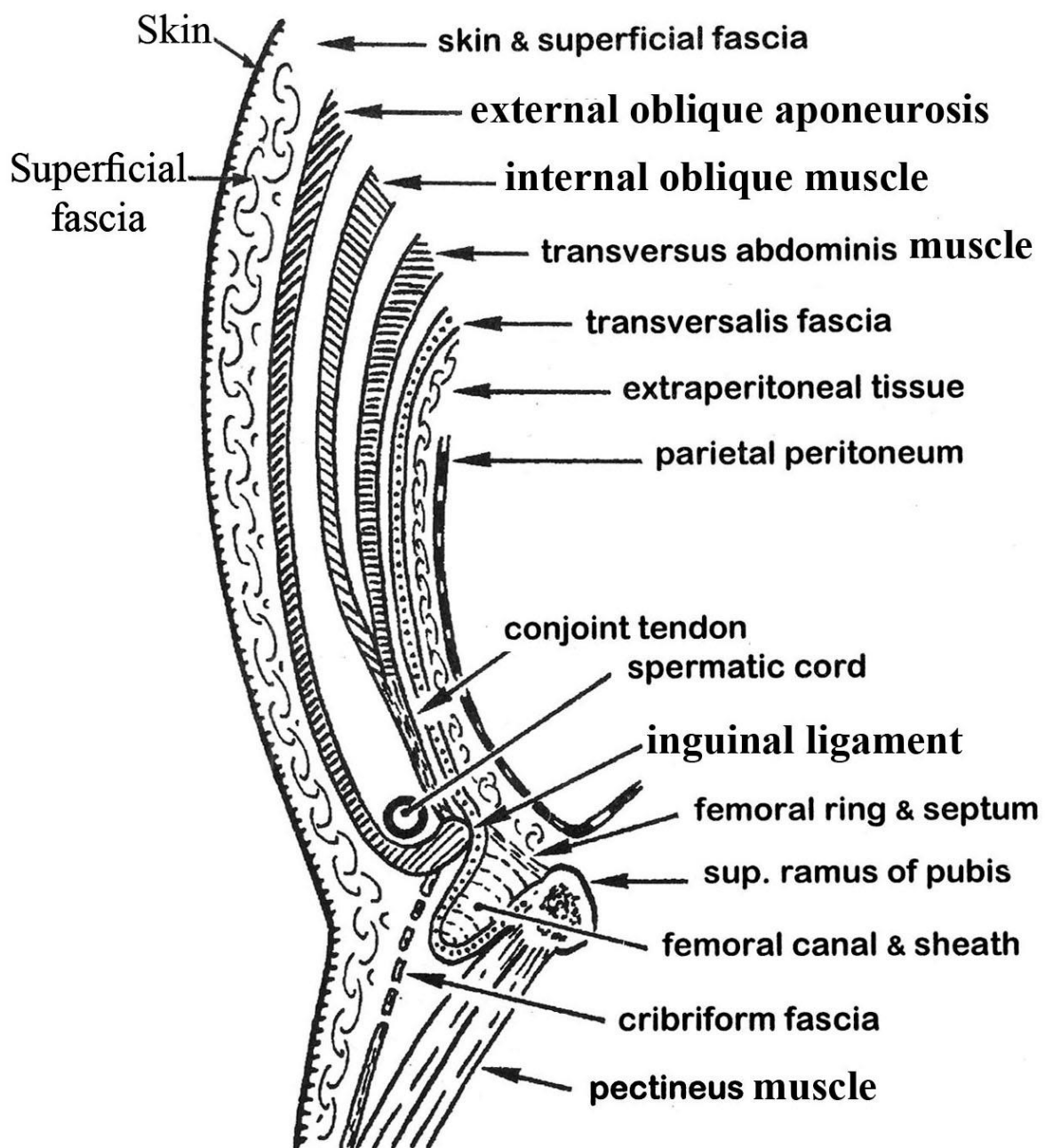
ANTERIOR ABDOMINAL WALL

* **Structures:** It is formed of the following layers:

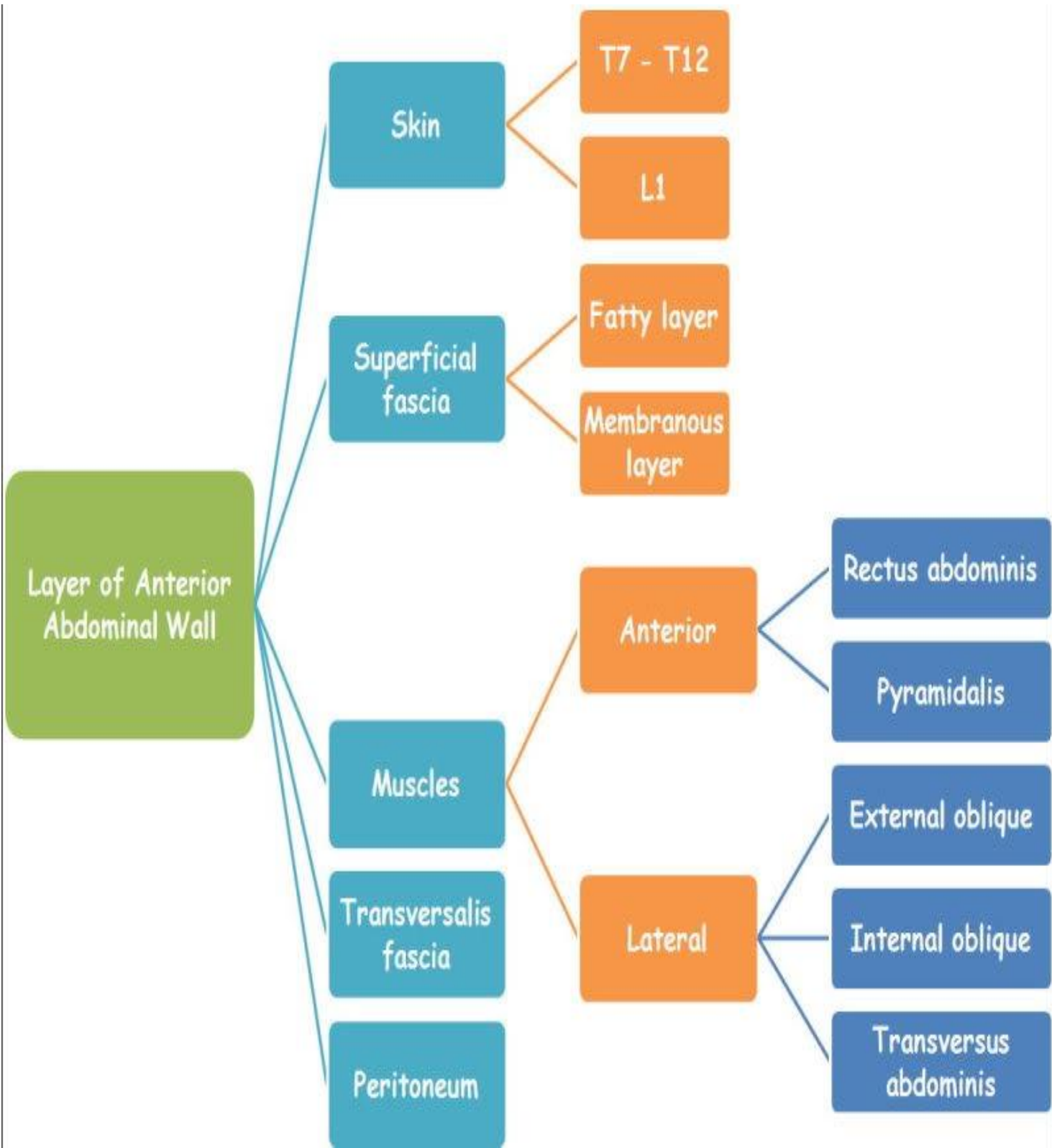
- | | |
|-------------------------|--|
| 1. Skin | 2&3 Superficial fascia (no deep fascia). |
| 4-6 Abdominal muscles. | 7. Fascia transversalis |
| 8. Extraperitoneal fat. | 9. Parietal peritoneum. |



(B) Longitudinal section



Layers of the anterior abdominal wall
(Longitudinal section at the level of femoral sheath)



Layer of Anterior Abdominal Wall

Skin

T7 - T12

L1

Superficial fascia

Fatty layer

Membranous layer

Muscles

Anterior

Rectus abdominis

Pyramidalis

Transversalis fascia

Lateral

External oblique

Internal oblique

Peritoneum

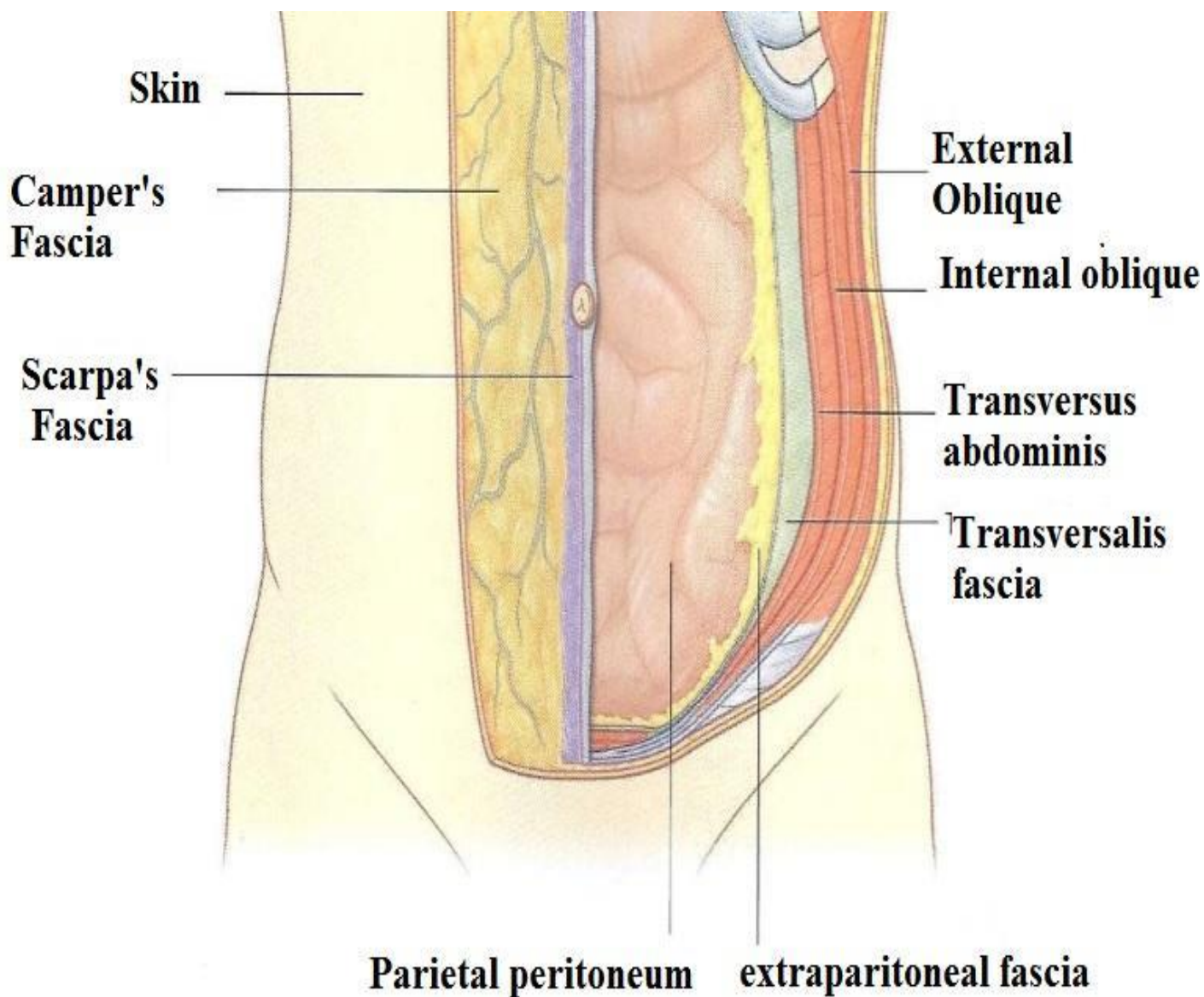
Transversus abdominis

SKIN

- It is thin & presents the **umbilicus** which is inverted scar formed by separation of umbilical stump after birth.
- It lies in the linea alba at variable level. Usually it lies one finger below a point midway between the xiphoid process & symphysis pubis (disc between L_{3&4}).
- Its level is one of the sites of anastomosis between S.V.C&I.V.C as well as porto-systemic anastomosis.
- It is inverted because its posterior surface of the umbilicus is the meeting of falciform ligament, ligamentum teres of liver (obliterated left umbilical vein), right & left medial umbilical ligaments (obliterated umbilical arteries) & median umbilical ligament (obliterated urachus).
- Above the level of umbilicus the lymphatic & venous drainage pass upwards to the axilla while below this level they pass downwards to the groin.
- **Nerve supply:** Skin of anterior abdominal wall is supplied by T₇₋₁₂ & L₁ nerves. Skin of at level of umbilicus is supplied by T₁₀ (as the nerve supply of appendix).

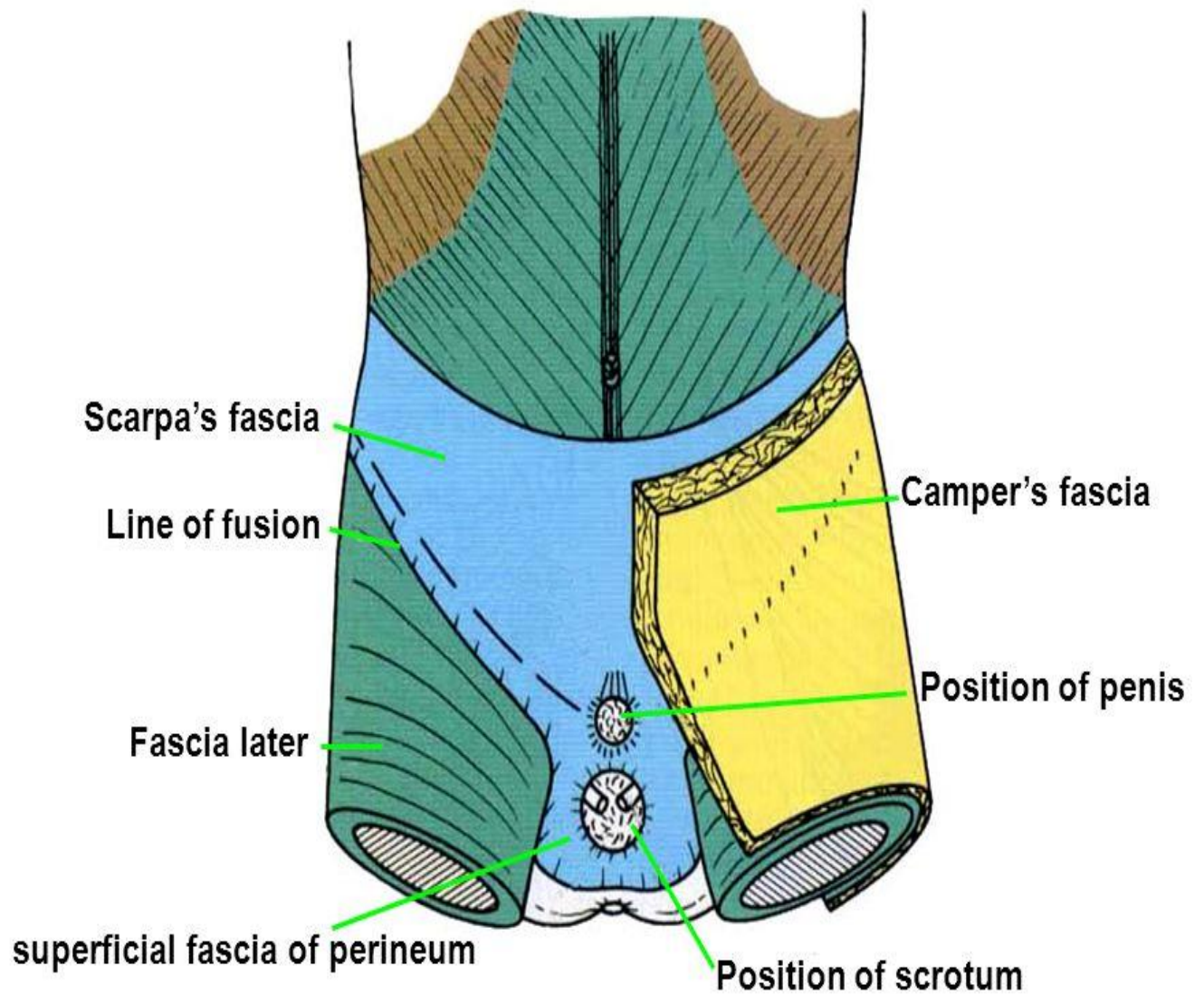
SUPERFICIAL FASCIA

- It differentiates, particularly below the umbilicus, into 2 layers:
 - a) **Superficial fatty layer : (Camper's fascia)** which is a major site for storage of fat.
 - b) **Deep membranous layer: (Scarpa's fascia)** It is developed below the umbilicus. It is attached to the fascia lata of thigh a finger breadth below the inguinal ligament. In the median plane, it envelops the penis & scrotum then extends backwards into the perineum as Colle's Fascia which is attached to the posterior border of perineal membrane → superficial perineal pouch which contain bulbar urethra → *in extra-pelvic rupture of male urethra, extravasation of urine into the perineum, scrotum, penis and anterior abdominal wall (between Scarpa's fascia & abdominal muscles).*

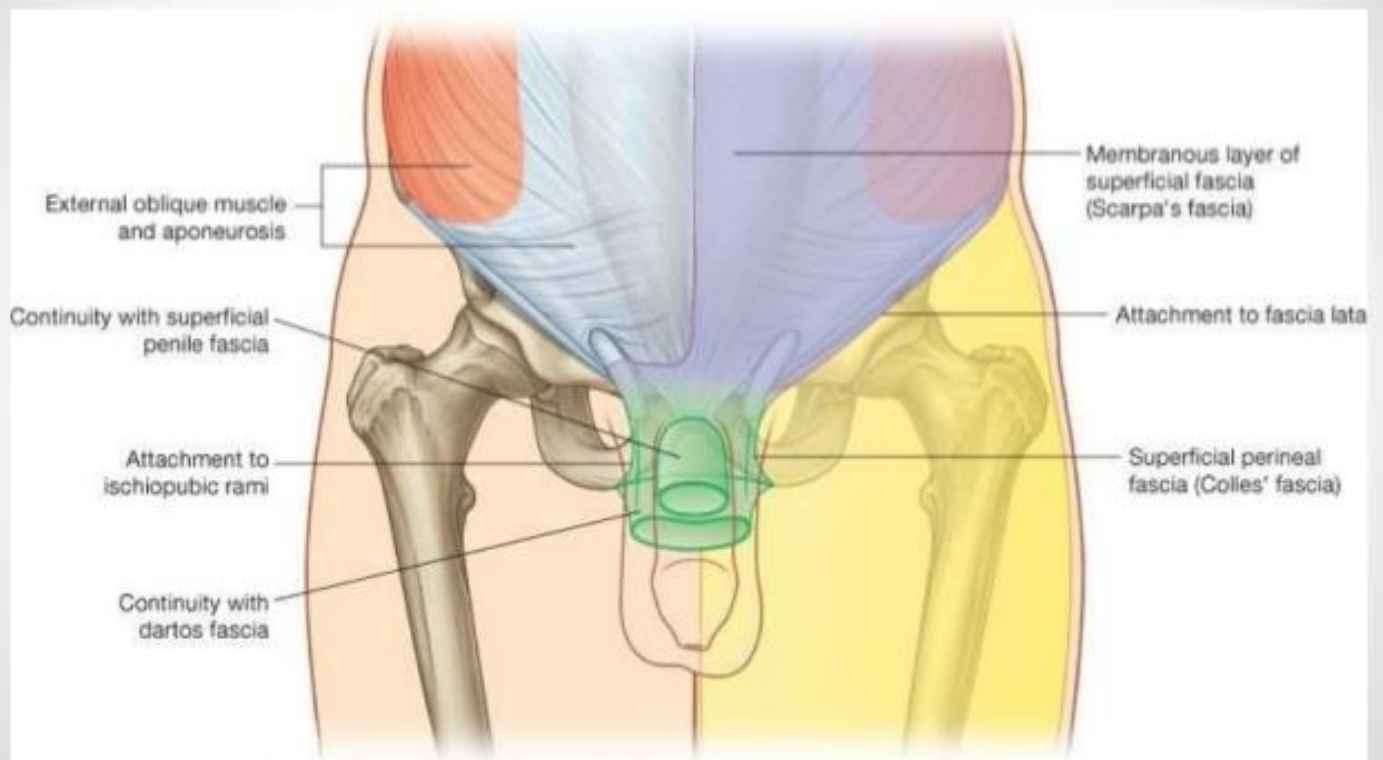


LAYERS OF THE ANTERIOR ABDOMINAL WALL

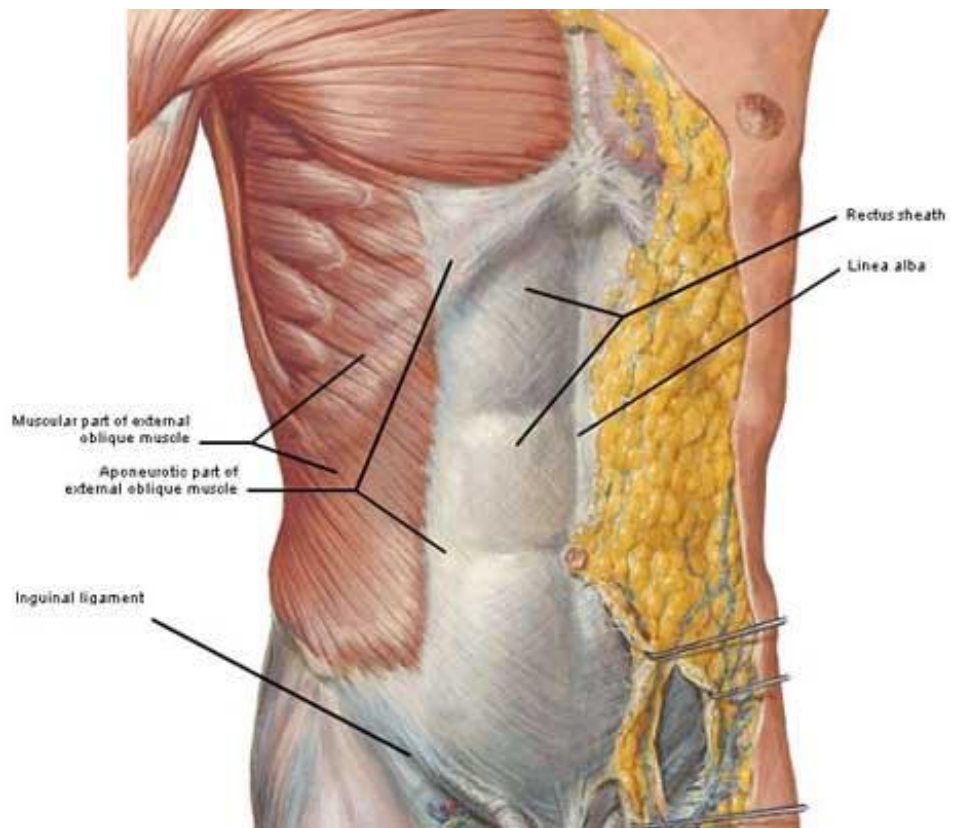
Scarpa's fascia



Superficial Fascia



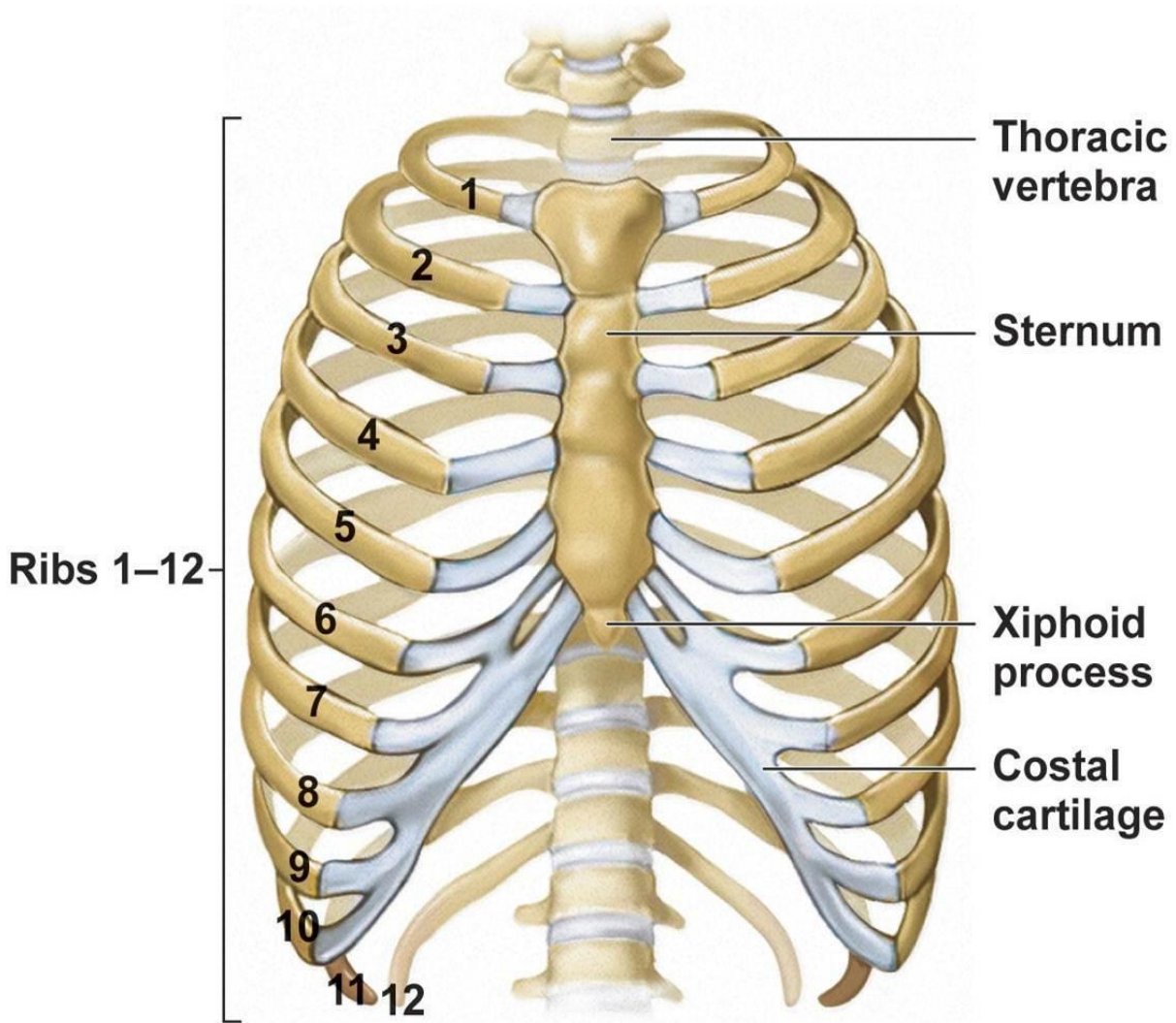
Drake: Gray's Anatomy for Students, 2nd Edition.
Copyright © 2009 by Churchill Livingstone, an imprint of Elsevier, Inc. All rights reserved.



Muscles Of Anterior Abdominal Wall.

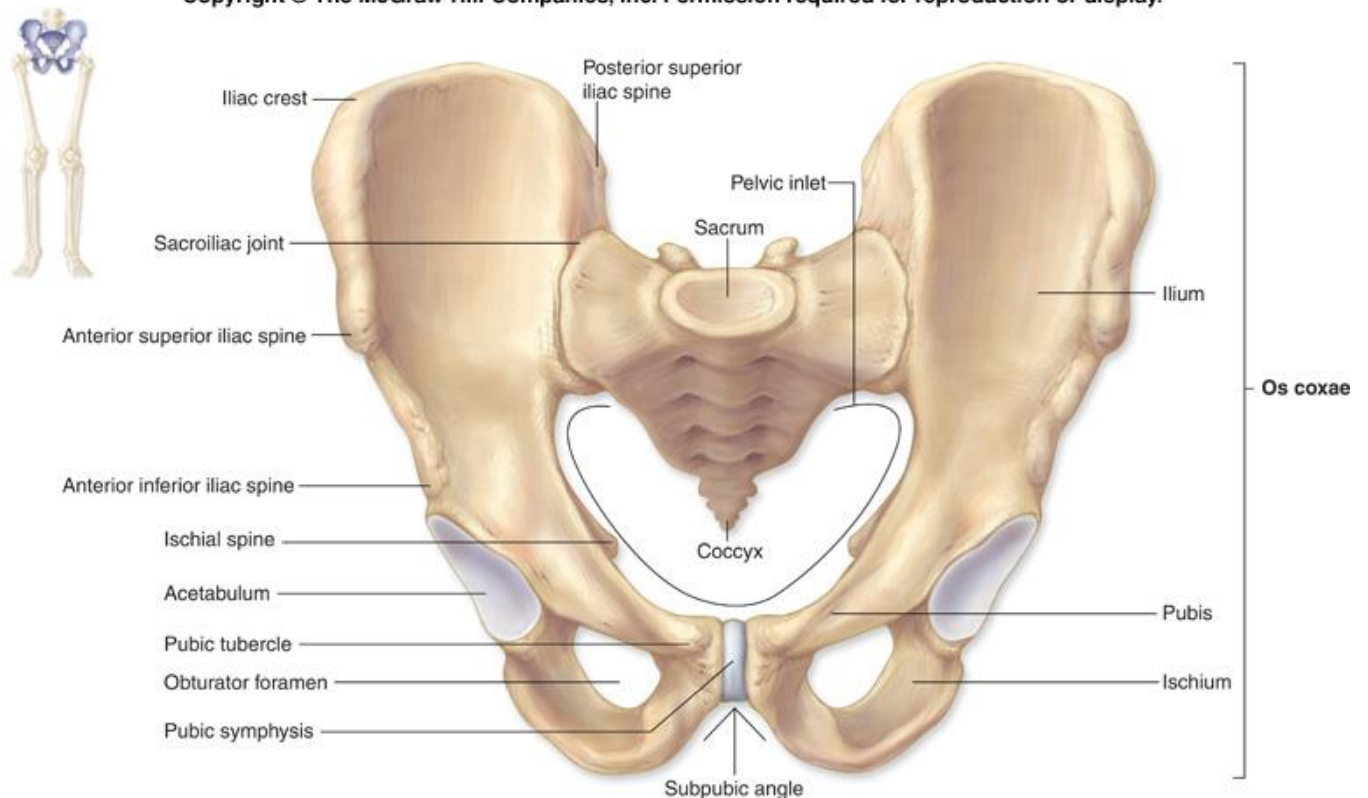
- **INSERTION** : The lateral 3 muscles develop 3 broad aponeuroses towards the median plane to form the rectus sheath, then become inserted mainly in the linea alba which is attached between Xiphoid process & symphysis pubis .
- **NERVE SUPPLY**: Lower 5 intercostal, subcostal , iliohypogastric & ilioinguinal nerves .
- **ACTION** : Respiration, protect viscera, keep viscera in position ,increase intra-abdominal pressure ,flex trunk(rectus) &lateral flex and twist trunk.

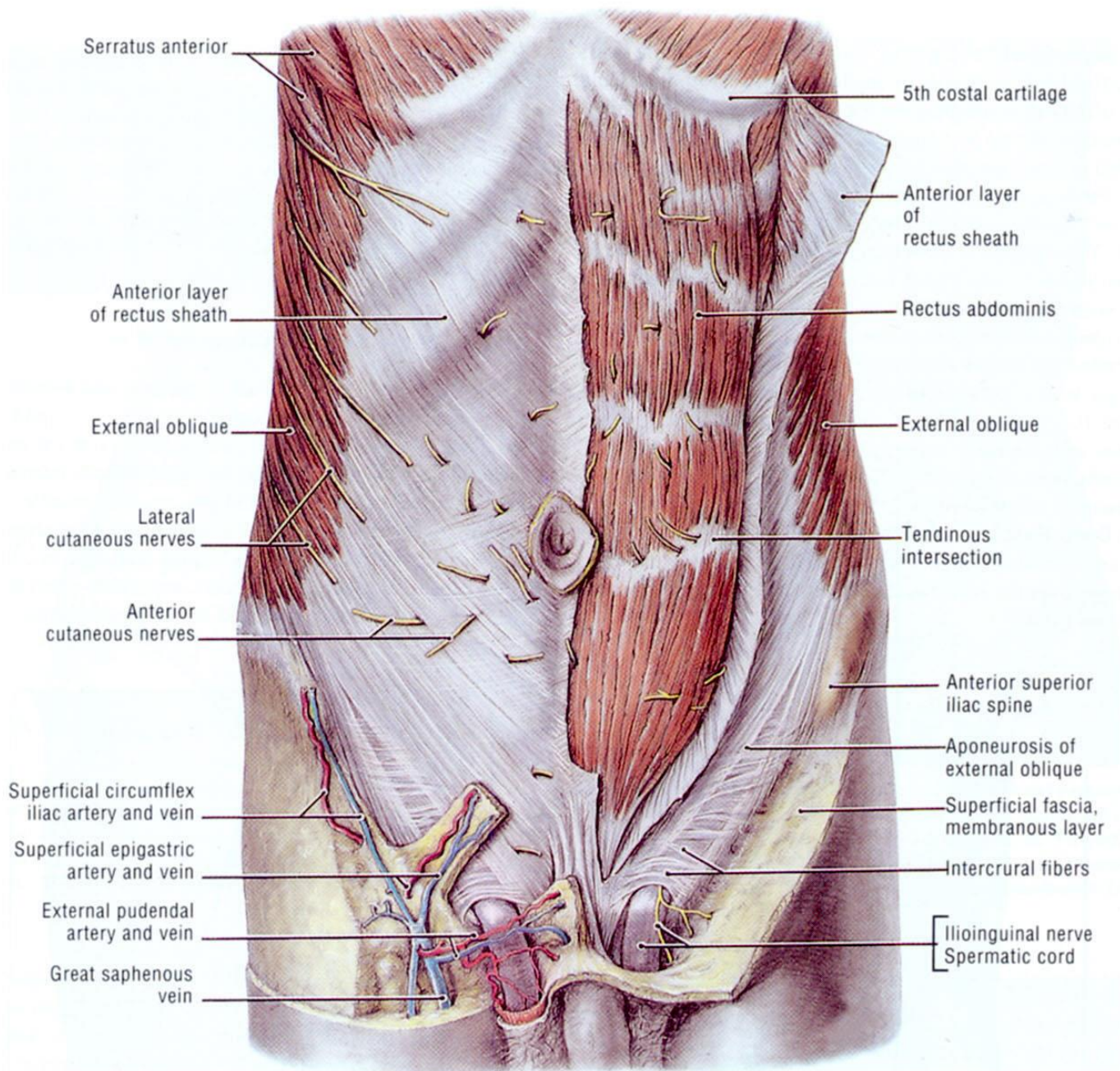
MUSCLE	ORIGIN	INSERTION	IMPO
1. External Abdominal Oblique	<ul style="list-style-type: none"> • Outer Surface of Lower 8 ribs 	<ul style="list-style-type: none"> • Xiphoid process, linea alba& symphysis pubis • A.S.I.S, outer lip of iliac crest. • Pubic tubercle 	<ol style="list-style-type: none"> 1) Its fibers runs downwards, foreward 2) The Lower part of aponeurosis of ex 3) The ext. inguinal ring is an opening i 4) The aponeurosis is prolonged at the 5) Below a line between A.S.I.S. & umb
2. Internal abdominal oblique	<ul style="list-style-type: none"> • Lat. 2/3 of upper concave surface of inguinal ligament . • Intermediate part of iliac crest. • Thoracolumbar fascia 	<ul style="list-style-type: none"> • Lower 6 costal cartilages. • Xiphoid process & linea alba& symphysis pubis . • Lower fibers (conjoint tendon) is inserted into pubic crest & medial part of pectineal line. 	<ul style="list-style-type: none"> • The fibers runs upwards, foreforwards • Cremastic m. is derived from int. ob cord & testis inserted into pubic tubercle & ejection. • The lower fibers of int. oblique has a <ol style="list-style-type: none"> 1) first ant. to the cord forming the lat 2) Arch above the cord forming the ro 3) Finally, the conjoint tendon lies beh inguinal canal.
3- Transversus abdominis	<ul style="list-style-type: none"> • Lat 1/3 of the upper surface of inguinal ligament. • Inner lip of iliac crest. • Thoracolumbar fascia. • Inner surface of lower 6 costal cartilages 	<ul style="list-style-type: none"> • Xiphoid process & linea alba& symphysis pubis . • Lower fibers (conjoint tendon) is inserted into the pubic crest & medial part of pectineal line. 	<ol style="list-style-type: none"> 1- The fibres runs transversely. 3- Conjoint tendon: •It is the fused lower fibers of transversus abdominis near their insertion. • It passes in the med. 1/2 post wall of i • The fibres of trasversus abdominis ar • The formation of inguinal canal. • The conjoint tendon is supplied by ili
4- Rectus abdominis	<ul style="list-style-type: none"> • Pubic crest & front of symphysis pubis 	<ul style="list-style-type: none"> • along a horizontal line into xiphoid process & outer surface of 5,6,7 costal cartilage. 	<ol style="list-style-type: none"> 1- The lat. border of rectus abdominis i 2- It has 3-4 tendinous intersection (at xiphoid process & one below the umbilicus).
5- Pyramidalis	<ul style="list-style-type: none"> • Pubic crest & front of symphysis pubis. 	<ul style="list-style-type: none"> • Lower inch of linea alba 	It is anatomical landmark to midline in



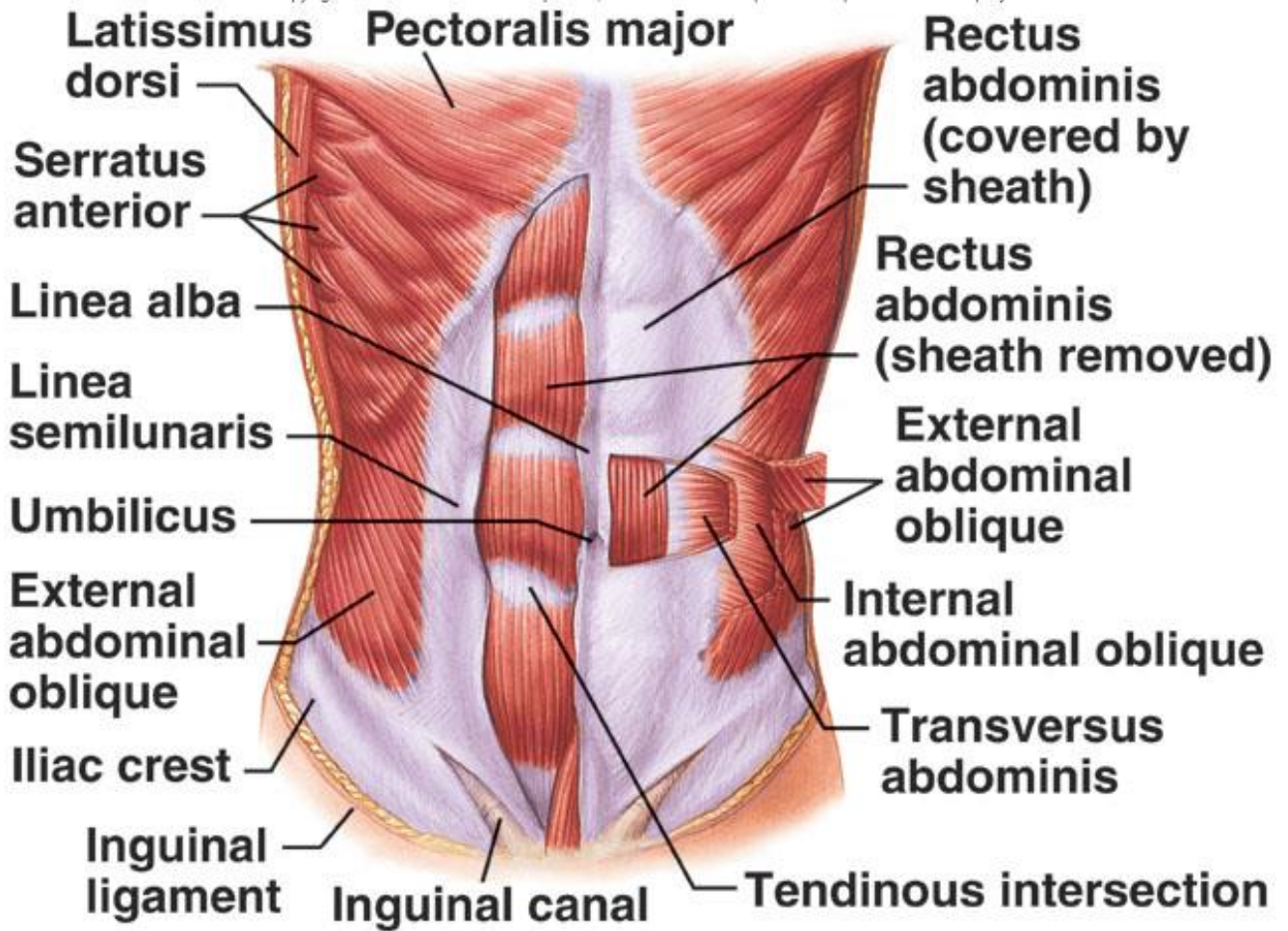
ORIGIN & INSERTION OF MUSCLES OF ANTERIOR ABDOMINAL

Copyright © The McGraw-Hill Companies, Inc. Permission required for reproduction or display.



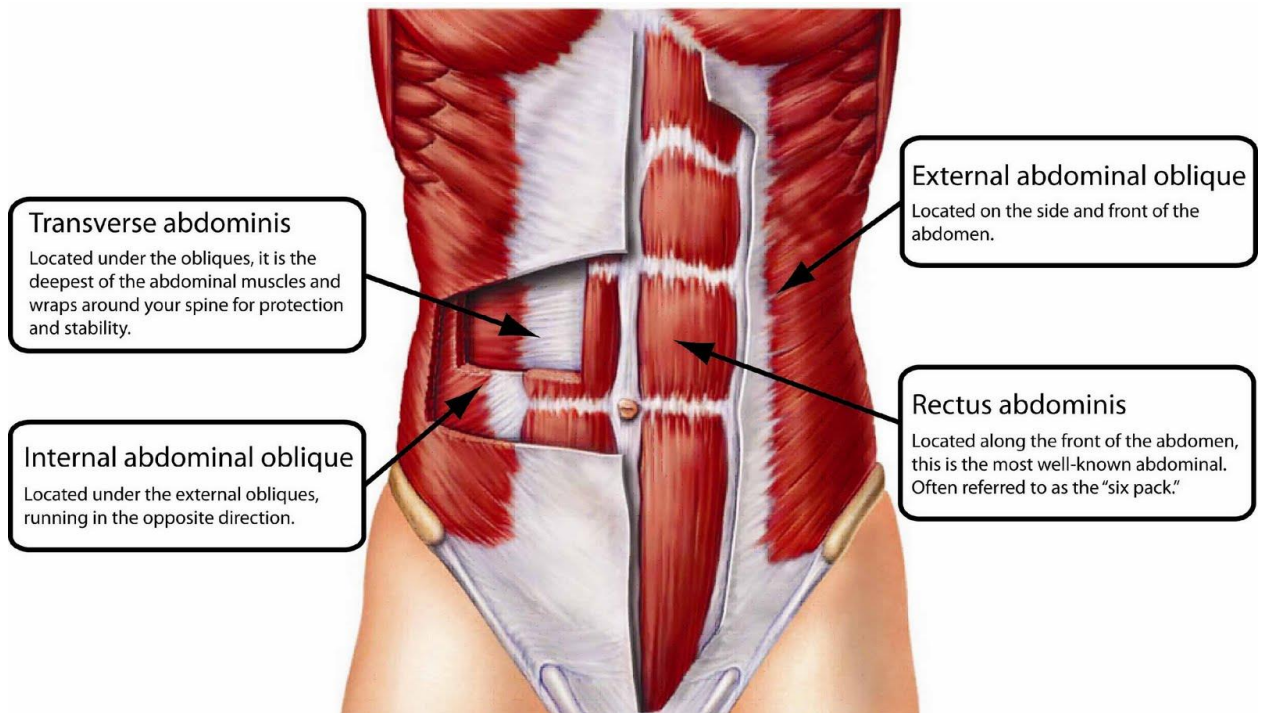


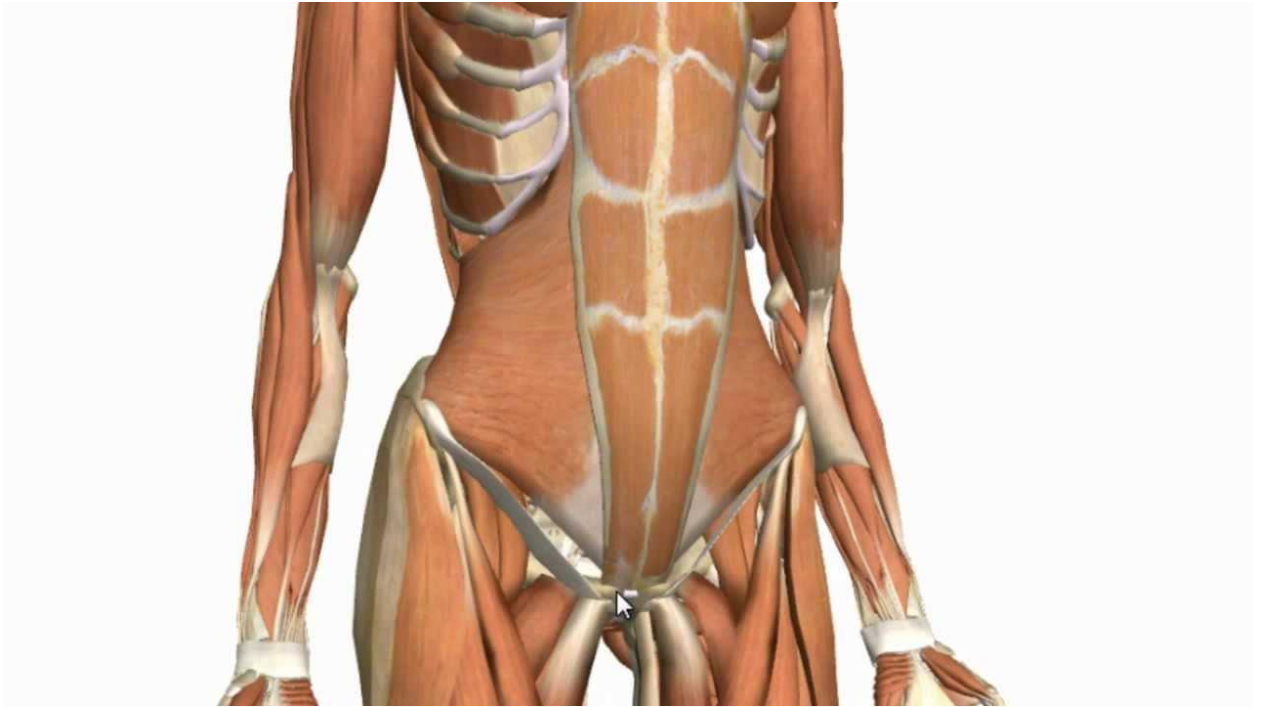
MUSCLES OF ANTERIOR ABDOMINAL WALL



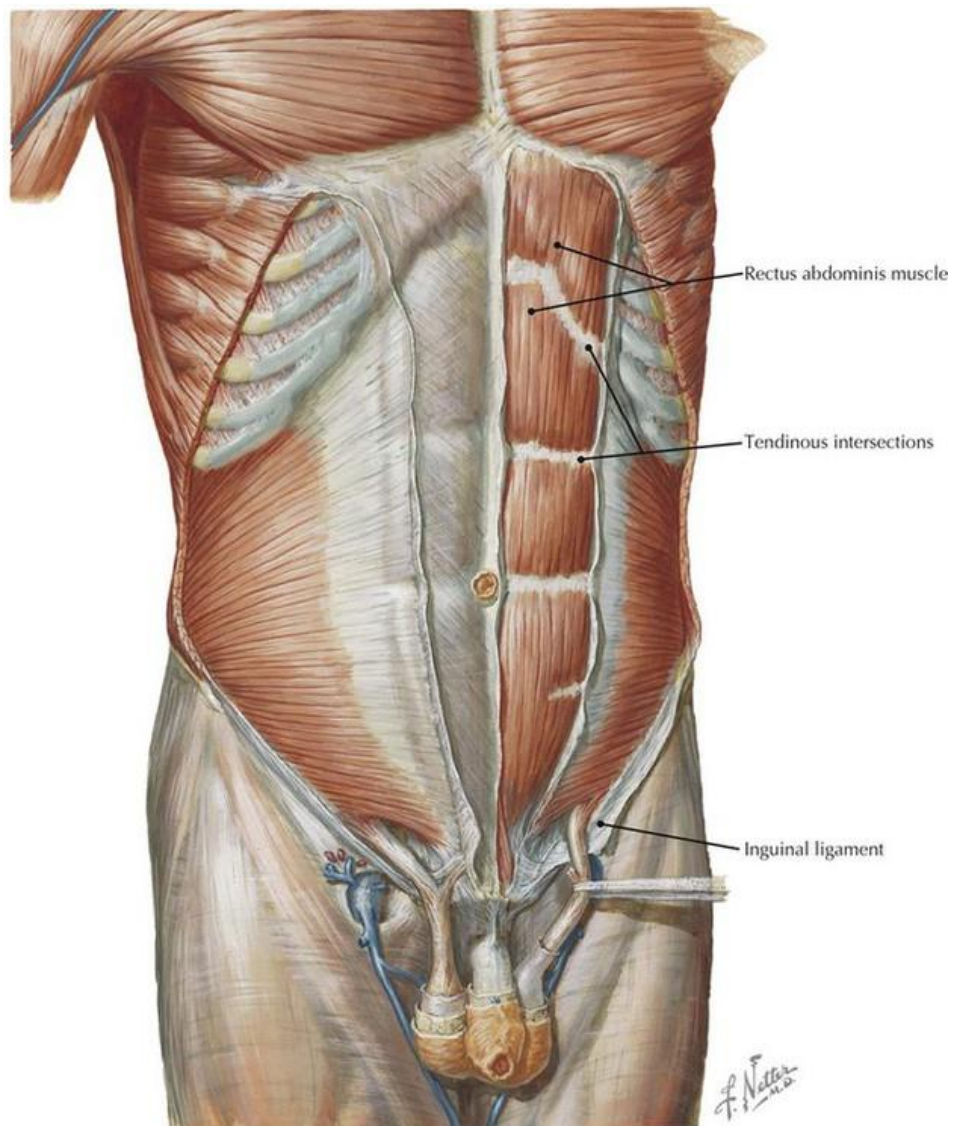
MUSCLES OF ANTERIOR ABDOMINAL WALL

(*External Abdominal Oblique & Rectus Abdominis muscles*)

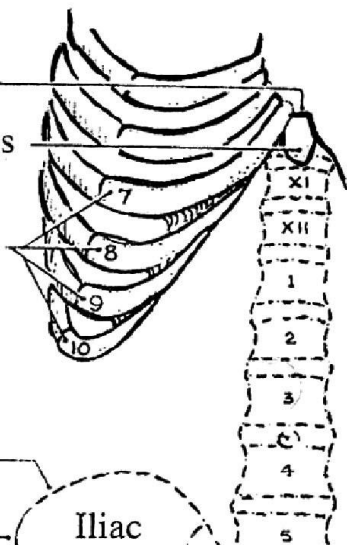





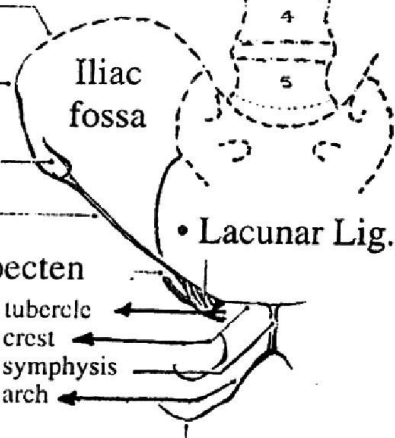
Internal abdominal oblique muscle



- Xiphi-sternal joint
- Xiphoid process
- Costal cartilages

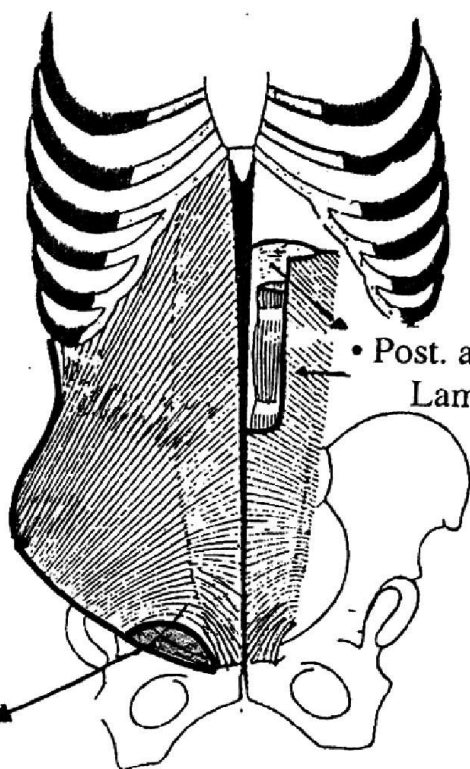


- Iliac crest
- Tubercle
- Ant. sup. spine
- Inguinal lig.
- Pectineal line or pecten
- Pubic
 - tubercle
 - crest
 - symphysis
 - arch
- Ischial tuberosity
- Lacunar Lig.

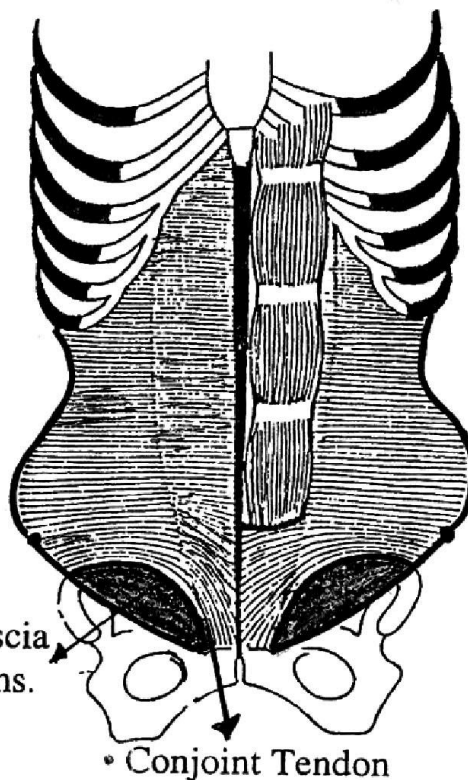


*** Ext. Abdominal Oblique ***

- Skeleton of Abdomen



*** Int. Abdominal Oblique ***



*** Transversus Abdominis ***

LINEA ALBA

- It is a strong raphe (thin tendon) in the middle line of anterior abdominal wall between the 2 recti. It is formed by interlacing fibers of the 3 aponeuroses of the muscles of anterior abdominal wall (after forming the rectus sheath).
- It is attached between xiphoid process & symphysis pubis.
- Above the umbilicus, it is relatively wide (1cm). Normally, contraction of 2 recti → obliteration of linea alba.
- Below the umbilicus, it is a narrow line which can be identified by the insertion of pyramidalis muscles.
- It shows the umbilical scar.

RECTUS SHEATH

* It is a fibrous sheath formed by the aponeuroses of the muscles of anterior abdominal wall.

* **Formation:**

1. Above the costal margin:

a- Ant. wall: Aponeurosis of external oblique.

b- Post. wall: Is deficient, the rectus muscle lies on 5, 6, 7 costal cartilages.

2. From the costal margin to a point midway between umbilicus and symphysis pubis:

a- Anterior wall: Ext. oblique aponeurosis & ant. lamina of int. oblique aponeurosis.

b- Posterior wall: Post. lamina of int. oblique aponeurosis & aponeurosis of transversus abdominis.

3. Below a point midway between umbilicus & symphysis pubis:

a- Anterior wall: Aponeurosis of 3 muscles of anterior abdominal wall.

b- Post. wall: Is deficient, the rectus muscle lies on the transversalis fascia.

The posterior wall of rectus sheath ends by forming arched border called *arcuate line*.

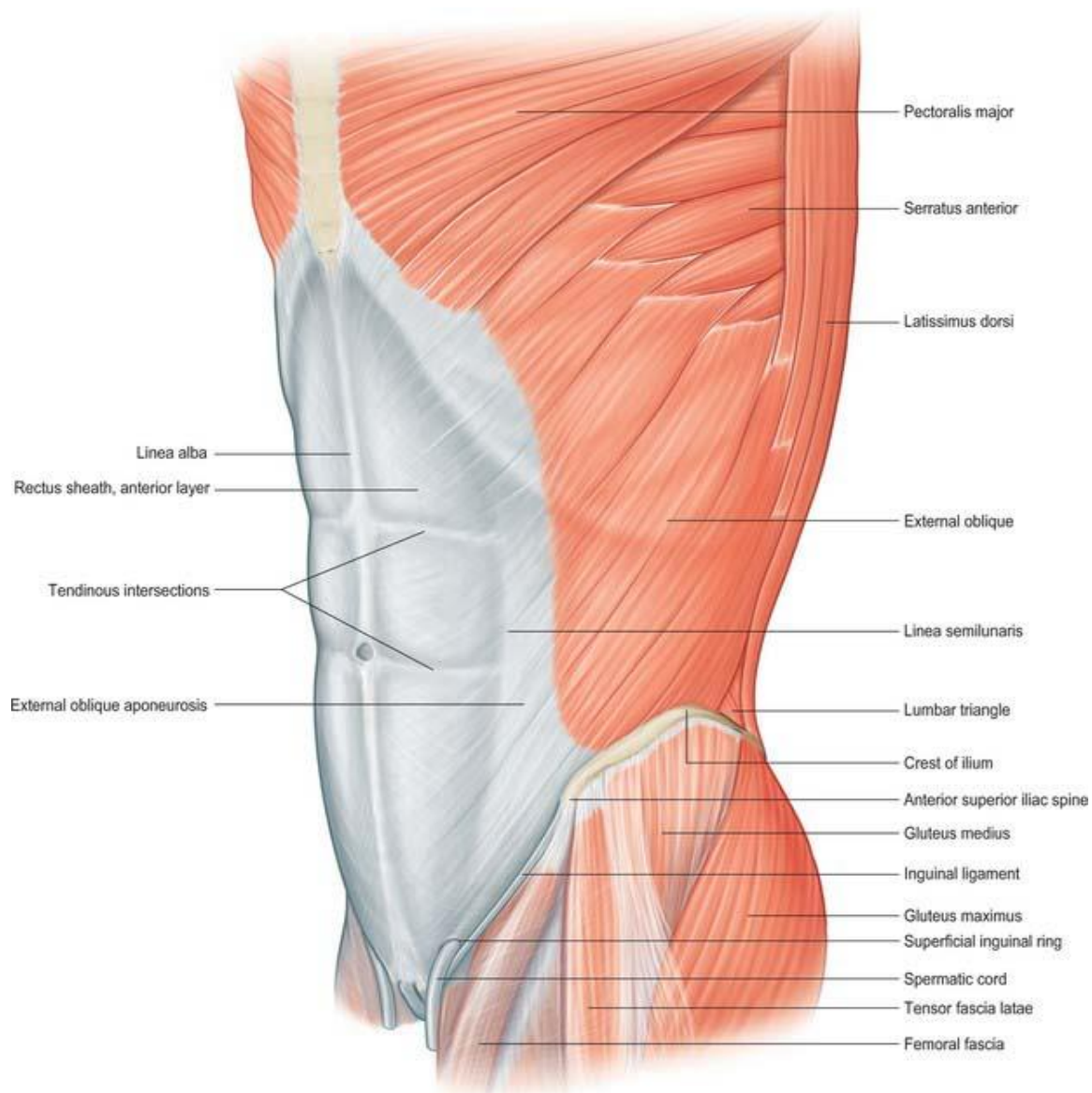
* **Contents:** Rectus abdominis , pyramidalis, superior & inferior epigastric vessels,

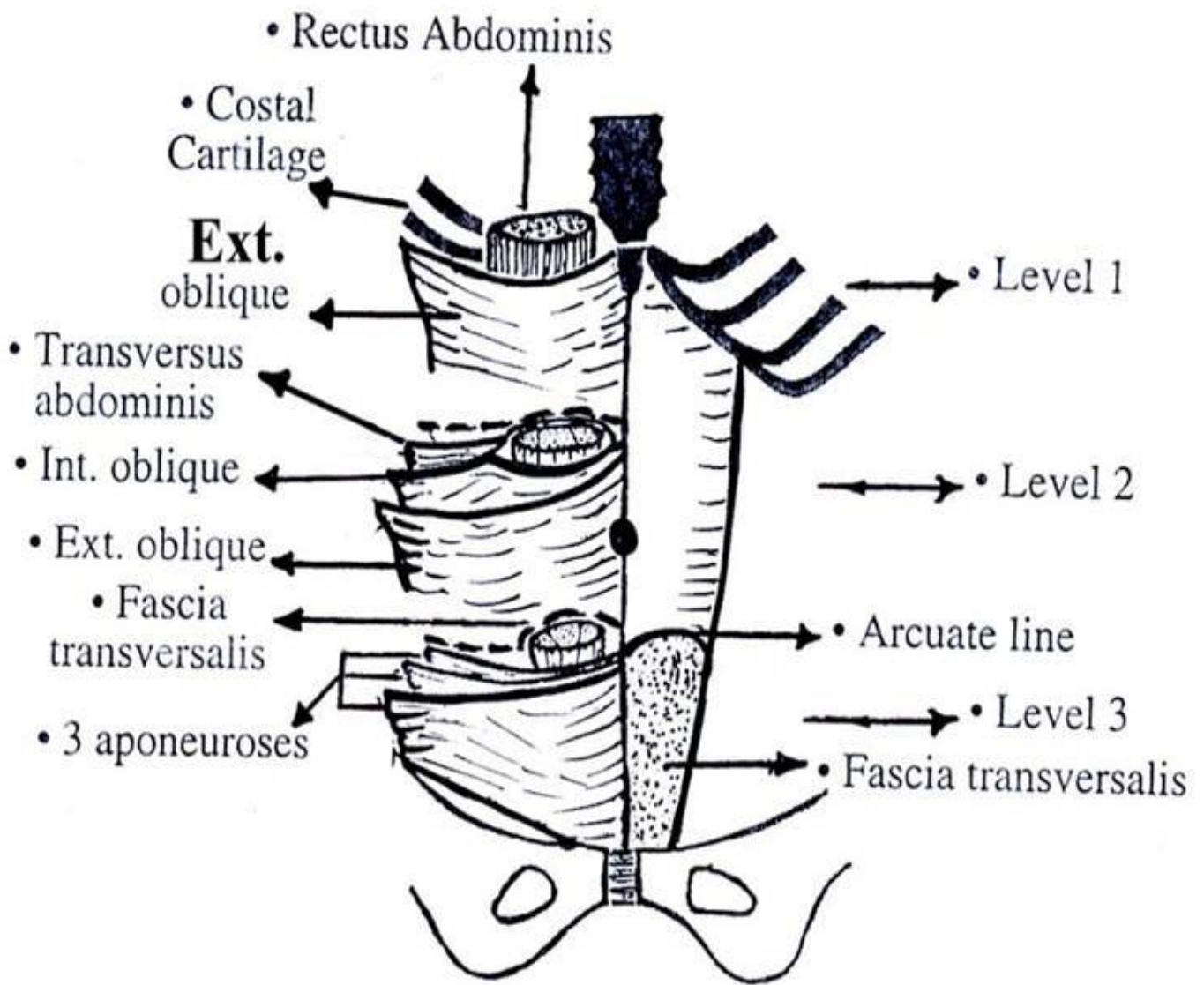
lower 5 intercostal & subcostal nerve & vessels (pass from lateral to medial) and lymph vessels.

** Applied anatomy:*

- 1) In Paramedian abdominal incision, the rectus muscle is retracted laterally to avoid injury of its nerve supply.*
- 2) Malignant cells may spread from cancer breast in the lymphatics in the rectus sheath leading to malignant nodule in the umbilicus (sister Joseph nodule).*

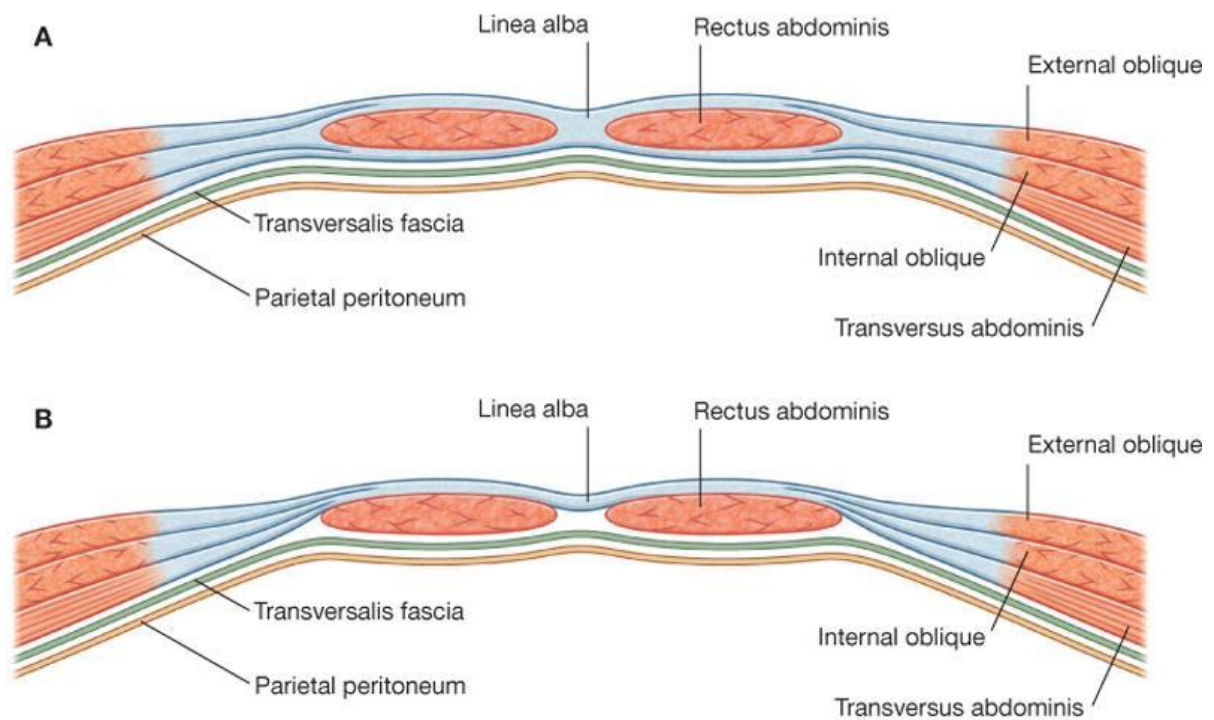
External Abdominal Oblique & Anterior Wall of Rectus Sheath





*** Rectus Sheath ***

* **T.S in the rectus sheath :**
A. Above level of arcuate line
B. Below level of arcuate line

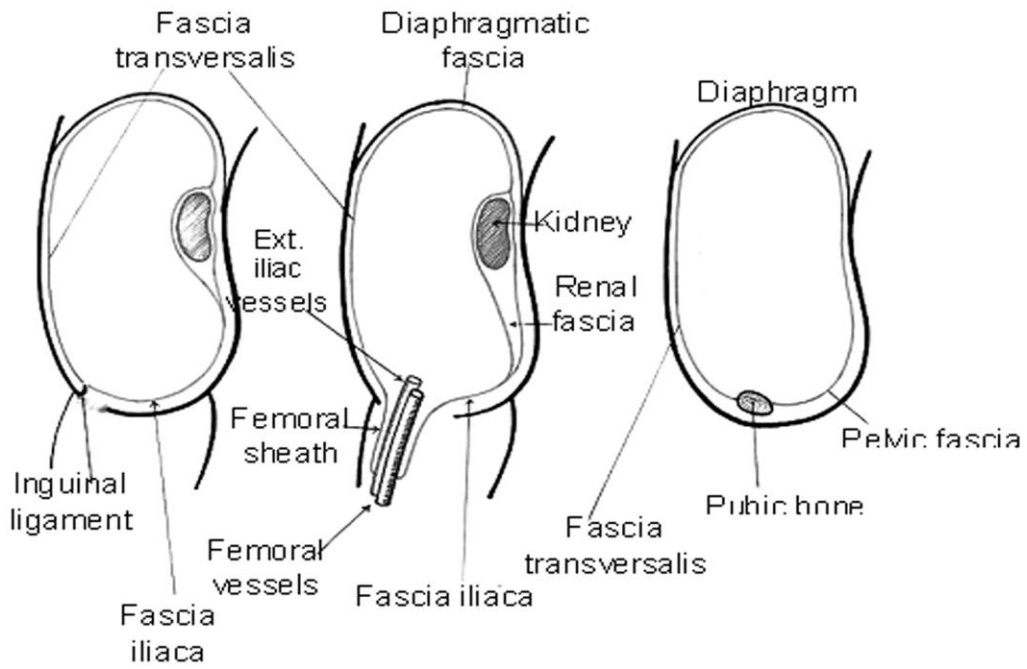


Drake: Gray's Anatomy for Students, 2nd Edition.
 Copyright © 2009 by Churchill Livingstone, an imprint of Elsevier, Inc. All rights reserved.

FASCIA TRANSVERSALIS

- It is a thin fascia which lines the antero-lateral abdominal wall.
- **Above:** It is continuous with the fascia of diaphragm.
- **Posterior:** It enters in the formation of perirenal fascia (Zukercandle fascia)
- **Inferior:**
 - a) **Medial :** It is attached to pubic crest & medial part pectineal line.
 - b) **Lateral:** It is attached to inner lip of iliac crest & lat. 1/2 of inguinal ligament.
 - c) **Between a & b** is passed in the thigh to form the ant. wall of femoral sheath.
- **Deep inguinal ring** is an opening in the transversalis fascia. At the deep inguinal ring, the fascia transversalis prolonges around the spermatic cord as internal spermatic fascia.

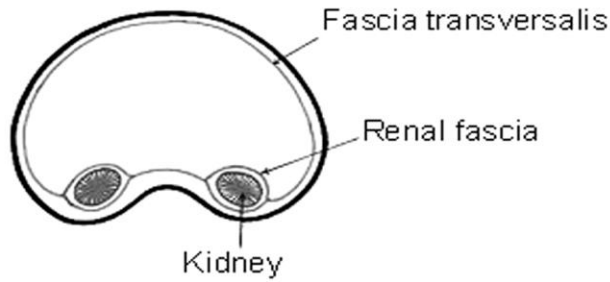
Saggital sections



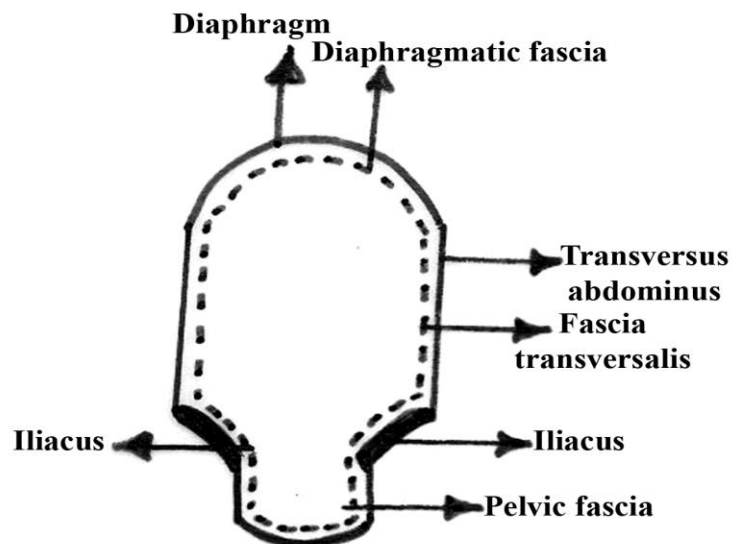
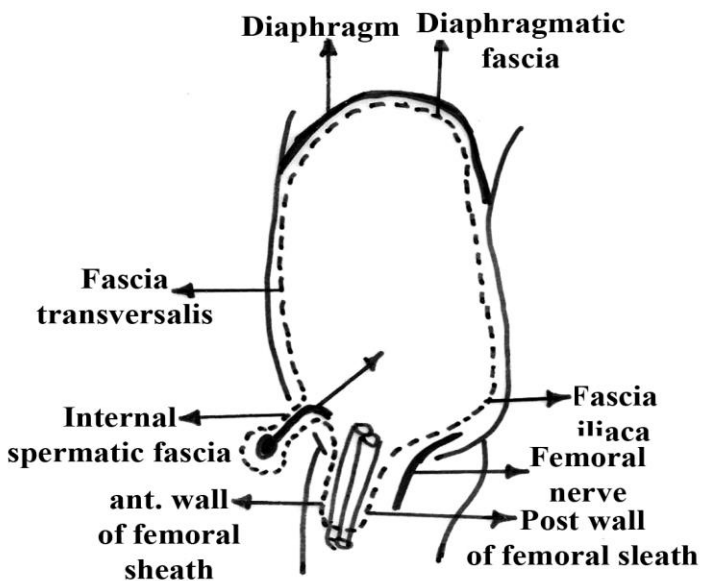
* Laterally

* In between

* Medially



Transverse section



Arteries of Anterior Abdominal Wall

A) Above the umbilicus:

1. 2 Terminal branches of the internal thoracic artery:

a) Superior epigastric artery:

* It descends behind the 7th. costal cartilage to enter the rectus sheath to descend behind the rectus abdominis muscle to the level of the umbilicus where it anastomoses with inferior epigastric artery.

b) Musculo-phrenic artery:

* It runs downwards and laterally along the costal margin.

2. Lower 5 (7-11) posterior intercostal arteries and the subcostal artery (branches of the descending thoracic aorta)

* They descend downwards and medially through the *neuro-vascular plane* between the internal oblique and the transversus abdominis to enter the rectus sheath behind the rectus abdominis from lateral to medial.

B) Below the umbilicus:

1. Superficial branches of the femoral artery:

a) Superficial epigastric artery.

b) Superficial circumflex iliac artery.

2. Branches of the external iliac artery:

a) Inferior epigastric artery:

* **Origin:** it arises from external iliac artery just behind the inguinal ligament.

***Course:**

- It passes upwards and medially, *medial to the internal inguinal ring*, passes in front of the arcuate line to enter the **rectus sheath** behind the rectus abdominis.

***Termination:** at the level of the umbilicus by anastomosing with superior epigastric artery.

*** Applied Anatomy:** *The inferior epigastric artery is medial to the neck of the sac of oblique inguinal hernia but lateral to that of direct inguinal hernia.*

***Branches:**

1) ***Cremasteric artery:***

- It **enters** the deep inguinal ring and passes as one of the contents
- of the spermatic cord to supply the cremasteric muscle.
- It ends by anastomosing with the testicular artery.

2) ***Pubic branch:***

- It descends behind the lacunar ligament and superior pubic
- ramus to anastomose with the pubic branch of obturator artery.
- In 30% of cases, the obturator artery is absent and replaced by
- **abnormal obturator artery** which is a large pubic branch of inferior epigastric artery.
- This abnormal obturator artery passes just behind the free sharp border of the lacunar ligament
- and *liable for injury during operation for femoral hernia.*

b) **Deep circumflex iliac artery:**

* **Origin:** it arises from **external iliac** artery just behind the inguinal ligament.

* **Course:**

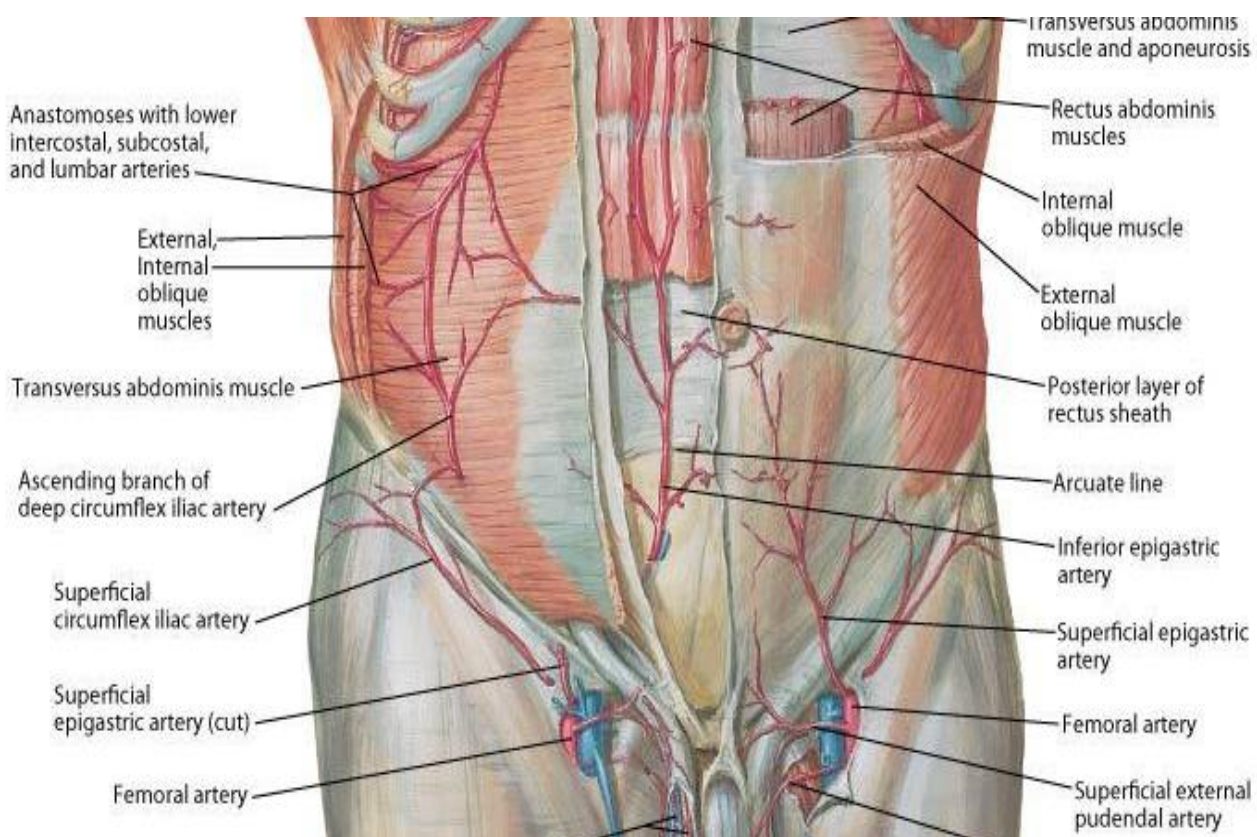
- It passes upwards and laterally behind the inguinal ligament to
- reach anterior superior iliac spine.
- It **runs** on the inner lip of iliac crest where it pierces the
- transversus abdominis to runs in the **neurovascular plane**.

* **Branches:**

1) **Muscular branches**

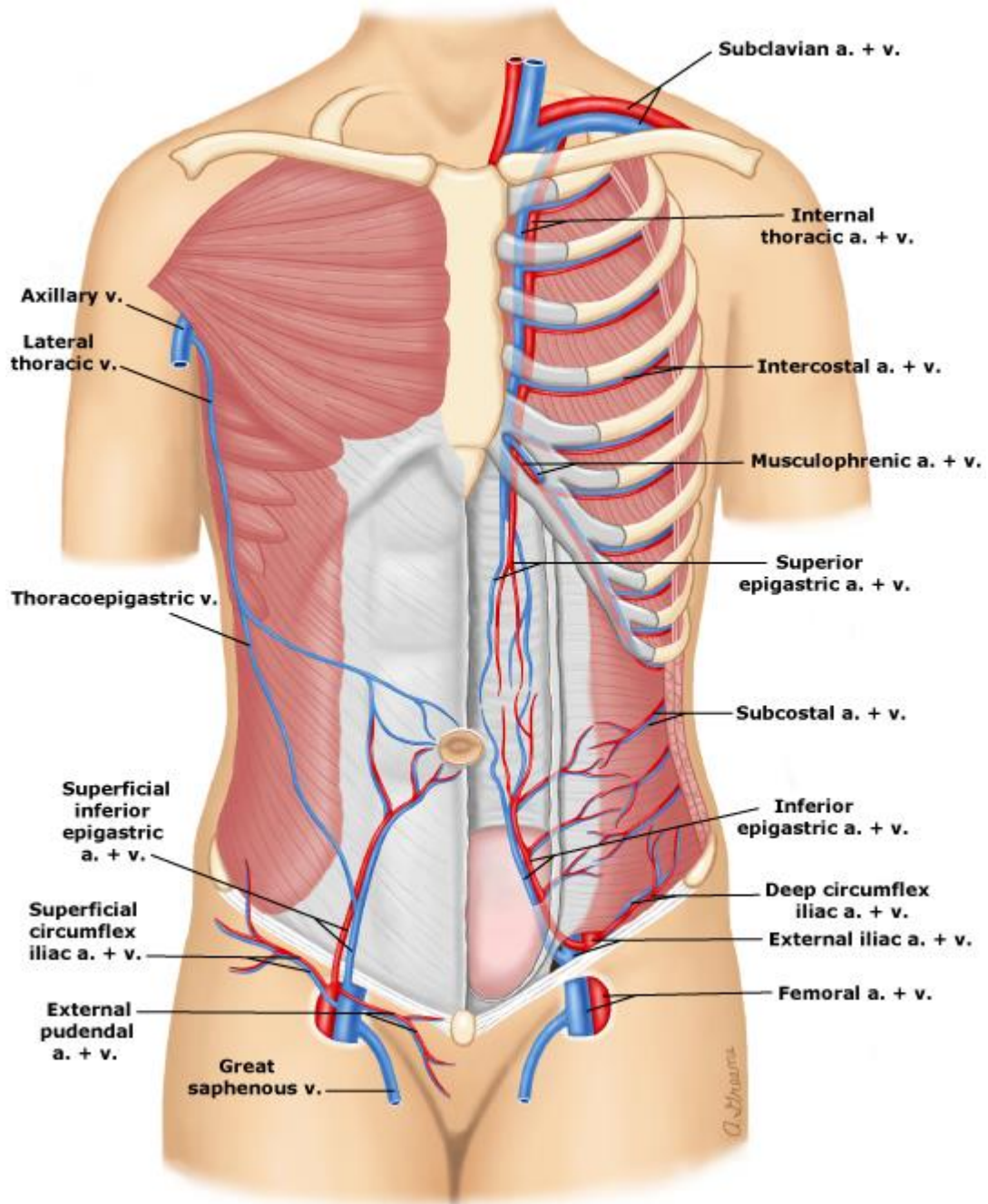
2) **Anastomatic branches** sharing in the anastomosis around anterior superior iliac spine.

3) **Ascending branch:** ascends to anastomose with the lumbar and musculophrenic arteries.

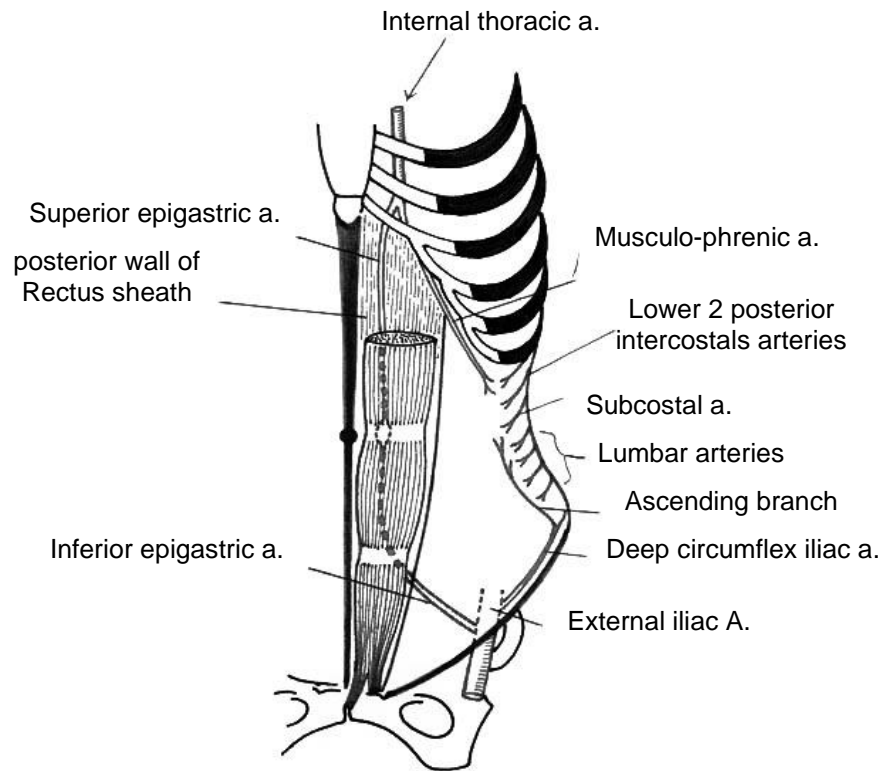


Superficial vessels

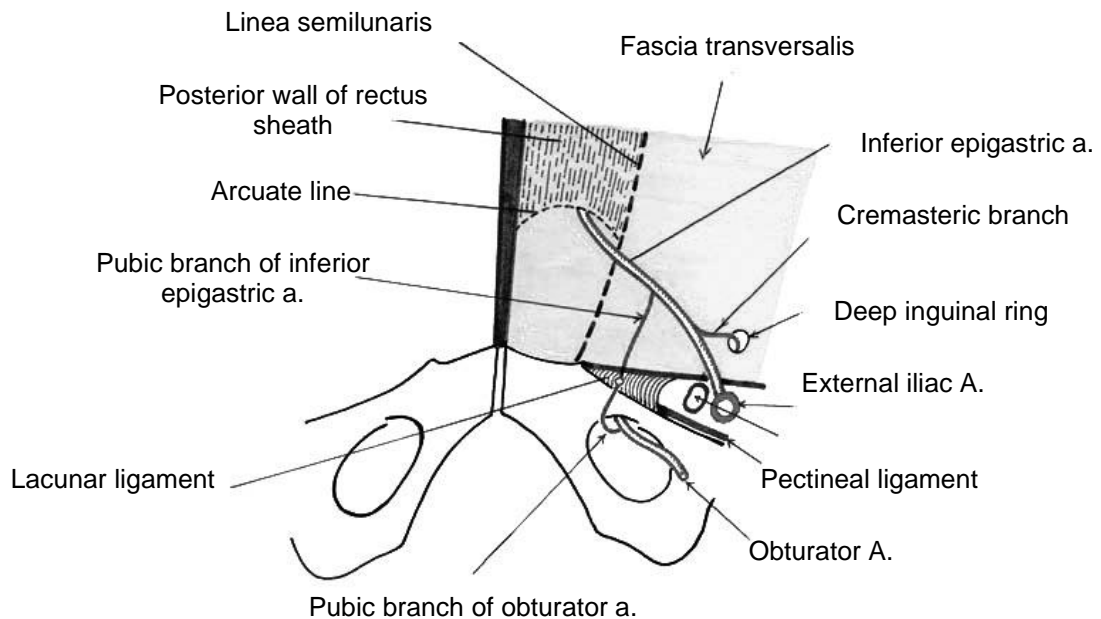
Deep vessels



*** Arterial supply of anterior and lateral abdominal walls ***



Inferior epigastric A.



Anterior abdominal wall seen from inside the abdomen (from behind)

★ **Arterial anastomosis in the anterior abdominal wall:**

- 1) *Lateral anastomosis*: between the ascending branch of deep circumflex iliac, lumbar and musculophrenic arteries.
- 2) *Medial anastomosis*: between the superior and inferior epigastric arteries.

* **Applied anatomy:**

- This anastomosis is very important to establish collateral circulation after obstruction of common or external iliac arteries.

**Veins of
Anterior Abdominal Wall**

A) Above the level of the umbilicus:

- 1) *Superior epigastric vein*: runs in the rectus sheath deep to the rectus muscle to end in the internal thoracic vein (a tributary of brachiocephalic vein).
- 2) *Lateral thoracic vein*: runs in the superficial fascia on the lateral side of abdomen and thorax to end in the axillary vein.

B) Below the level of the umbilicus:

- 1) *Inferior epigastric vein*: runs in the rectus sheath deep to the rectus muscle to end in the external iliac vein.
- 2) *Superficial epigastric and superficial circumflex iliac veins*: run in the superficial fascia of the lower part of the abdomen to end in the long saphenous vein (tributaries of femoral vein).

★ **Venous anastomoses in the anterior abdominal wall:**

1. Anastomosis between the *superior and inferior epigastric* veins in the rectus sheath.

- It connects the superior and inferior venae cavae.

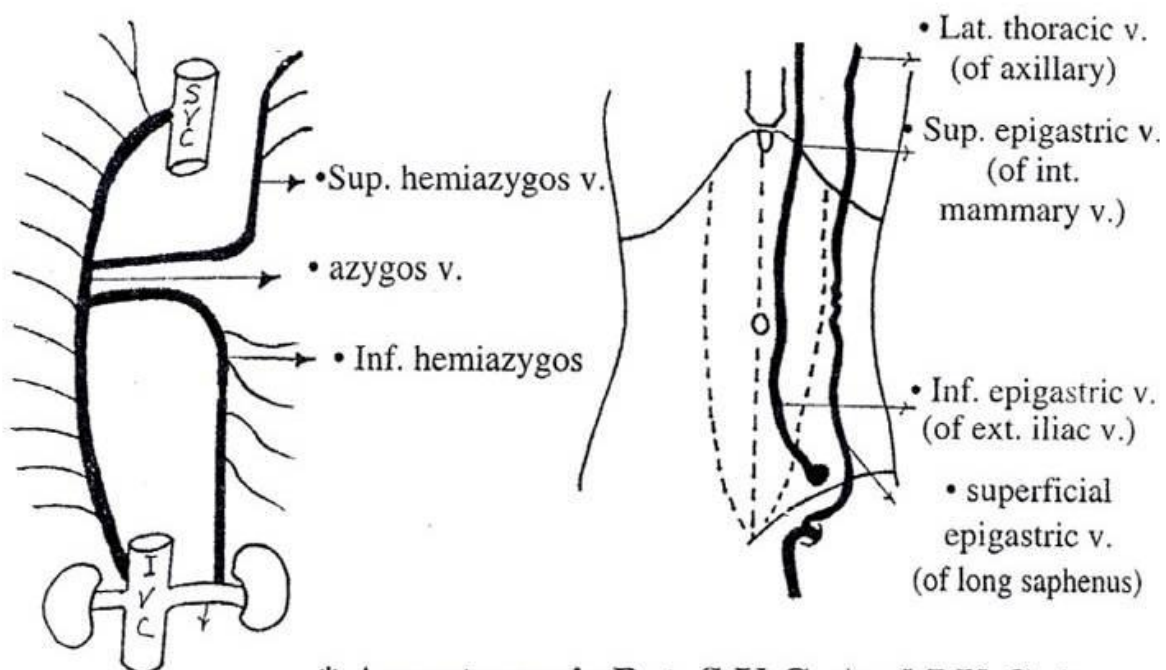
2. Anastomosis between the *lateral thoracic* vein and *superficial epigastric* veins.

- This anastomosis forms the *thoraco-epigastric vein* which connects the superior and inferior venae cavae.

• **Applied anatomy:** *Obstruction* of inferior vena cava or iliofemoral veins, results in opening of this anastomosis with formation of *dilated veins crossing the groin*.

3. Anastomosis between systemic veins of the anterior abdominal wall (tributaries of superior and inferior venae cavae) and para-umbilical veins (tributaries of portal vein).

- Opening of this *porto-systemic anastomosis* in portal hypertension results in formation of **caput medusae**.



* Anastomosis Bet. S.V.C. And I.V.C. *

Lymphatic drainage of anterior abdominal wall

A) Superficial lymphatics: (follow veins)

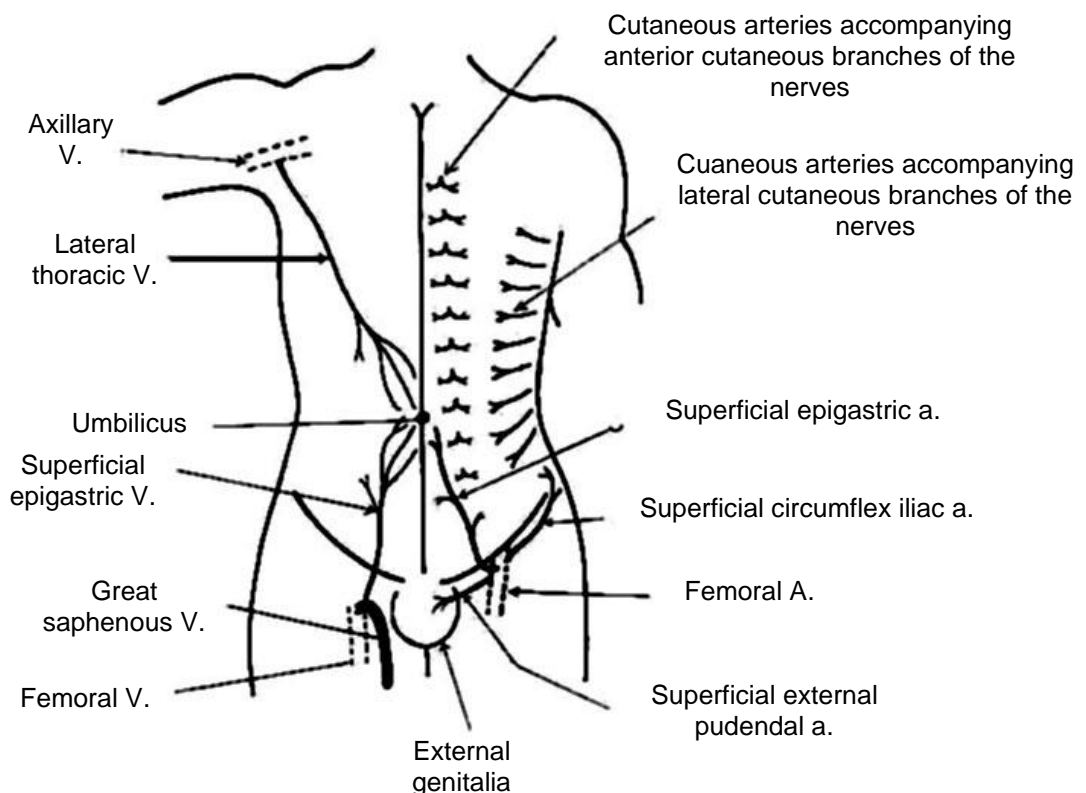
- 1) *Above the umbilicus*: drain into the pectoral group of axillary lymph nodes.
- 2) *Below the umbilicus*: drain into the superficial inguinal lymph nodes.

B) Deep lymphatics: (Follow arteries)

- 1) *Above the umbilicus*: drain into the parasternal lymph nodes (along internal thoracic artery).
- 2) *Below the umbilicus*: drain into the external iliac lymph nodes.
- 3) The *deep surface of the umbilicus* is drained by lymphatics around the ligamentum teres, in the falciform ligament, which drain in the lymph nodes in the porta hepatis.

Veins

Arteries



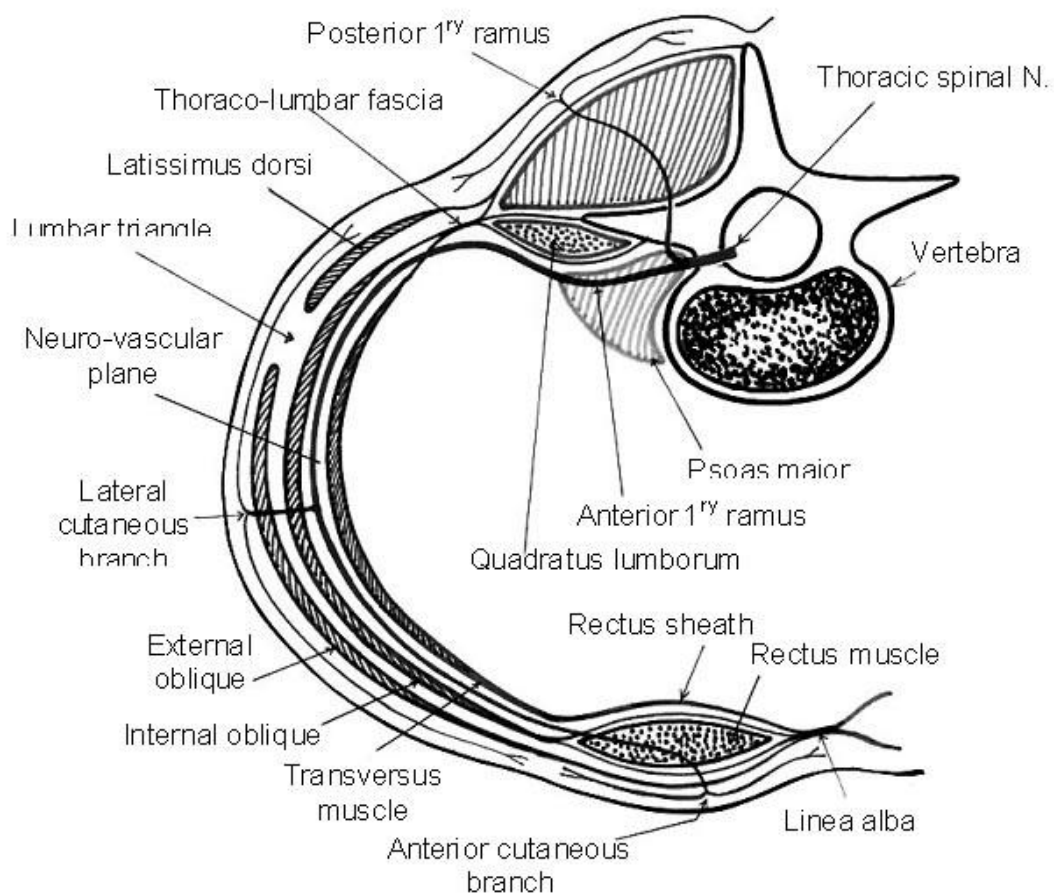
Nerves of anterior abdominal wall

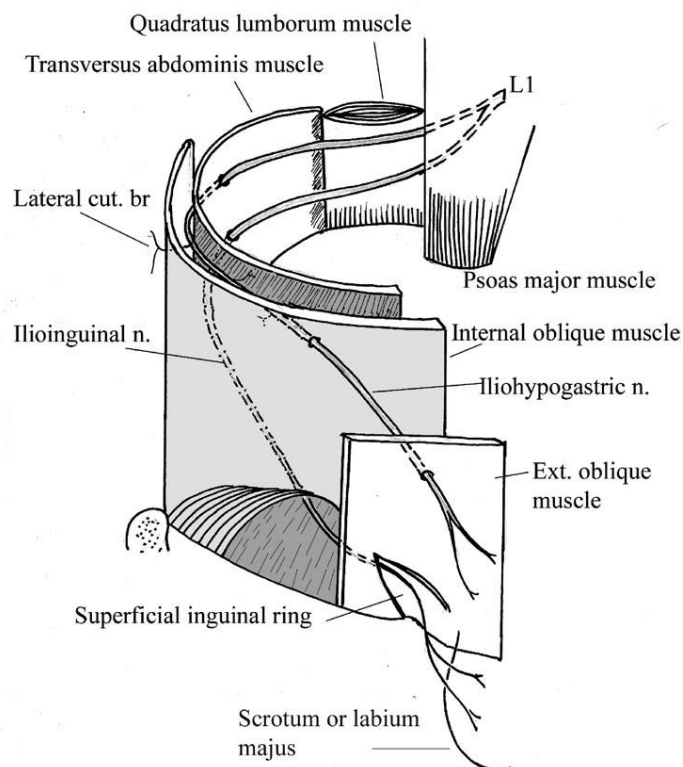
A) Motor supply:

a) The lower five intercostal and subcostal nerves:

- They *supply* the three antero-lateral muscles of the abdominal wall.
- They pass through the *neuro-vascular* plane of the abdominal wall (between the internal oblique and the transversus abdominus), then enter the *rectus sheath* to run between the rectus abdominis and the posterior wall of rectus sheath.

* Subcostal nerve* (Transverse section)





*** Iliohypogastric & ilioinguinal nerves ***

- They pierce the rectus abdominis after supplying it and pierce the anterior wall of rectus sheath to end by becoming the anterior cutaneous nerves lateral to the linea alba.

b) **Iliohypogastric and ilioinguinal nerves:** (branches of the anterior primary ramus of L₁).

- They **pierce the psoas** major muscle to emerge from under cover of its **lateral border**; then descend laterally on the **quadratus lumborum** muscle, behind the kidney with the iliohypogastric lying at a slightly higher level than the ilioinguinal nerve.
- **Both** nerves pierce the transversus abdominis muscle and run forwards in the **neurovascular plane** between the internal oblique and the transversus muscles (supplying both) until they reach the level of anterior superior iliac spine; then they pierce the internal oblique at variable points and continue medially between it and the external oblique as cutaneous nerves.

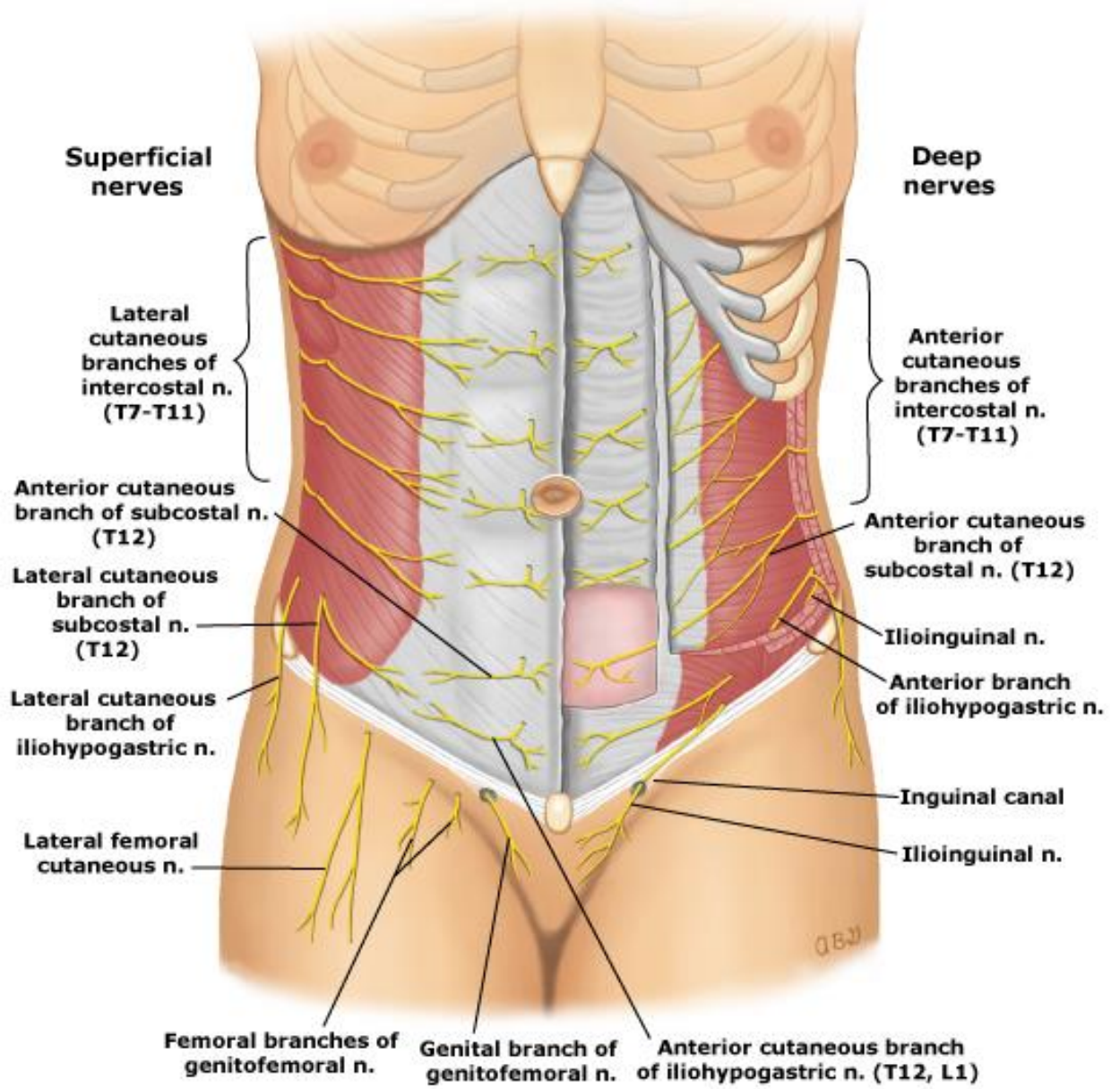
- The *iliohypogastric* nerve pierces the aponeurosis of the external oblique about 2 – 3 cm above the superficial inguinal ring to supply the skin above the symphysis pubis.
- On the other hand, the *ilioinguinal nerve* pass in the inguinal canal below the spermatic cord emerges through the superficial inguinal ring, to supply the skin of the external genitalia and upper part of medial side of the thigh. It also supplies the conjoint tendon.

*** Applied anatomy:**

- Injury of ilioinguinal nerve during appendicectomy leading to paralysis of conjoint tendon which predispose to direct inguinal hernia.

B) Sensory supply:

1. Lateral cutaneous branches of the *lower five intercostal and subcostal nerves*.
 2. Anterior cutaneous branches of the lower five intercostals and subcostal nerves
 3. Cutaneous branch of the *iliohypogastric* nerve.
 4. Cutaneous branches of the *ilioinguinal* nerve. They supply the skin of the scrotum and the upper part of medial side of the thigh.
- * The lower five intercostal and subcostal nerves and the branches of L₁ supply successive and almost horizontal bands of the skin of the anterior abdominal wall.
- ❖ Skin at the subcostal angle is supplied by 7th. thoracic nerve (T₇).
 - ❖ Three nerves (T_{7,8,9}) supply the region above the umbilicus.
 - ❖ Skin at the level of the umbilicus is supplied by 10th. thoracic nerve (T₁₀) (as that of the appendix).
 - ❖ Three nerves (T_{11,12}, L₁) supply the region below the umbilicus.
 - ❖ Skin above the symphysis pubis is supplied by the iliohypogastric nerve (L₁).



Abdominal Incisions

★REQUISITES OF GOOD INCISION:

1. Maximum accessibility.
2. Extensible.
3. Minimal scar after healing.
4. Minimal damage to the muscles.
5. Avoid nerve injury to avoid paralysis of muscles .
6. Minimal bleeding.
7. Rapid healing time.

★TYPES OF ABDOMINAL INCISIONS:

1. The midline incision (through the linea alba):

- This incision may be upper or lower , right or left .
- **Advantages:**
 - a. It provides a bloodless field.
 - b. Could be extended above or below.
- **Disadvantages:** Prolonged healing time due to poor blood supply of the linea alba.

2. The paramedian incision:

- **Method:** This is done 2.5 – 4 cm. lateral to the midline and parallel to it. The anterior rectus sheath is opened, the rectus muscle is retracted laterally and the posterior wall of rectus sheath together with the parietal peritoneum are opened in the same plane as the skin incision.
- **Advantages:**
 - a. It provides a bloodless field.
 - b. Could be extended.
 - c. Good healing in a short time as the rectus abdominis provides the incision with its arterial supply.

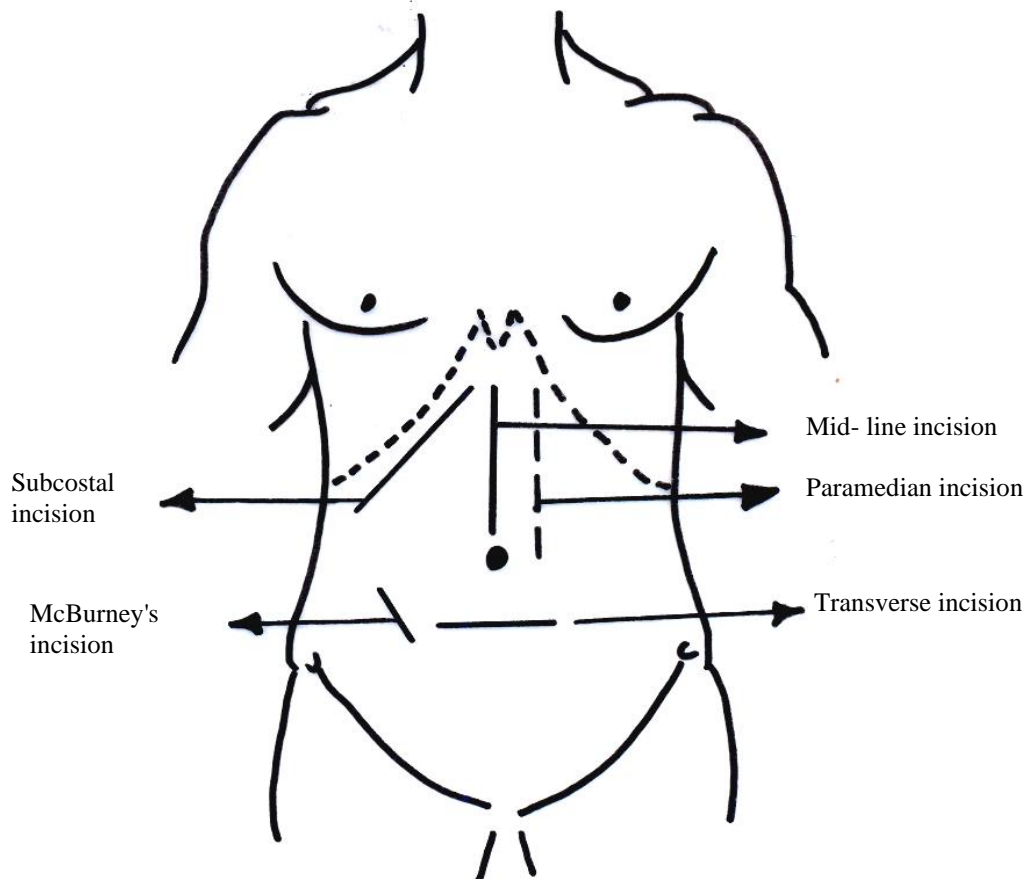
3. Transverse incision:

- In it muscle cutting through the lateral abdominal muscles is done to expose some organs as *Pfannenstiel incision* for the uterus .

- It may lead to some weakness of the abdominal muscles.

4. Right or left subcostal incision:

- It is used to expose the gall bladder on the right side or the spleen on the left side.
- The skin incision begins at the middle line and extends one inch below and parallel to the costal margin.
- **Advantage:** good exposure.
- **Disadvantage:** a muscle cutting incision with high incidence of incisional hernia.



5. McBurney's incision (grid iron):

- It is done to expose the vermiform appendix.

- **Method:** An oblique incision centered at Mc Burney's point (point at the junction of the lateral 1/3 and medial 2/3 of a line extends from the umbilicus to the anterior superior iliac spine).
 - ◆ Open the external oblique, internal oblique and the transversus abdominis (*without cutting them*) in the line of their fibers and retract them.
 - ◆ Finally open the fascia transversalis and parietal peritoneum.
- **Advantage:** a *muscle splitting* incision with no damage the abdominal muscles.