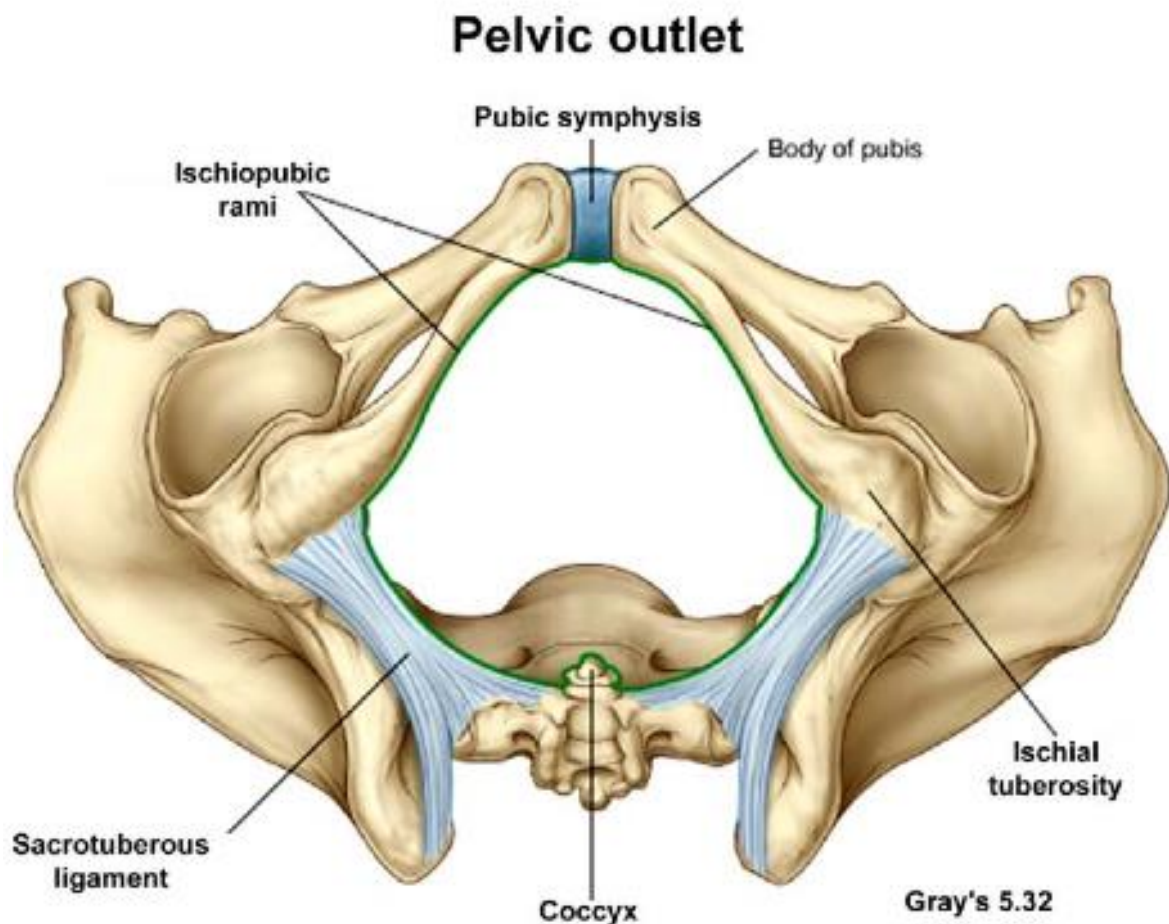


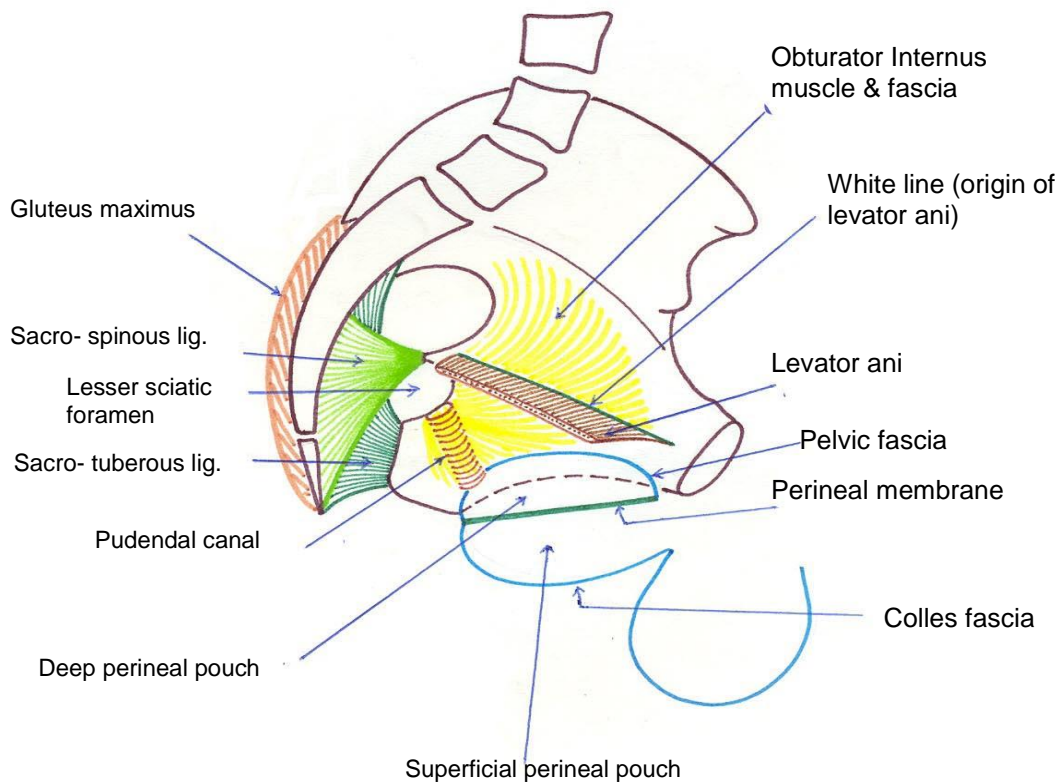
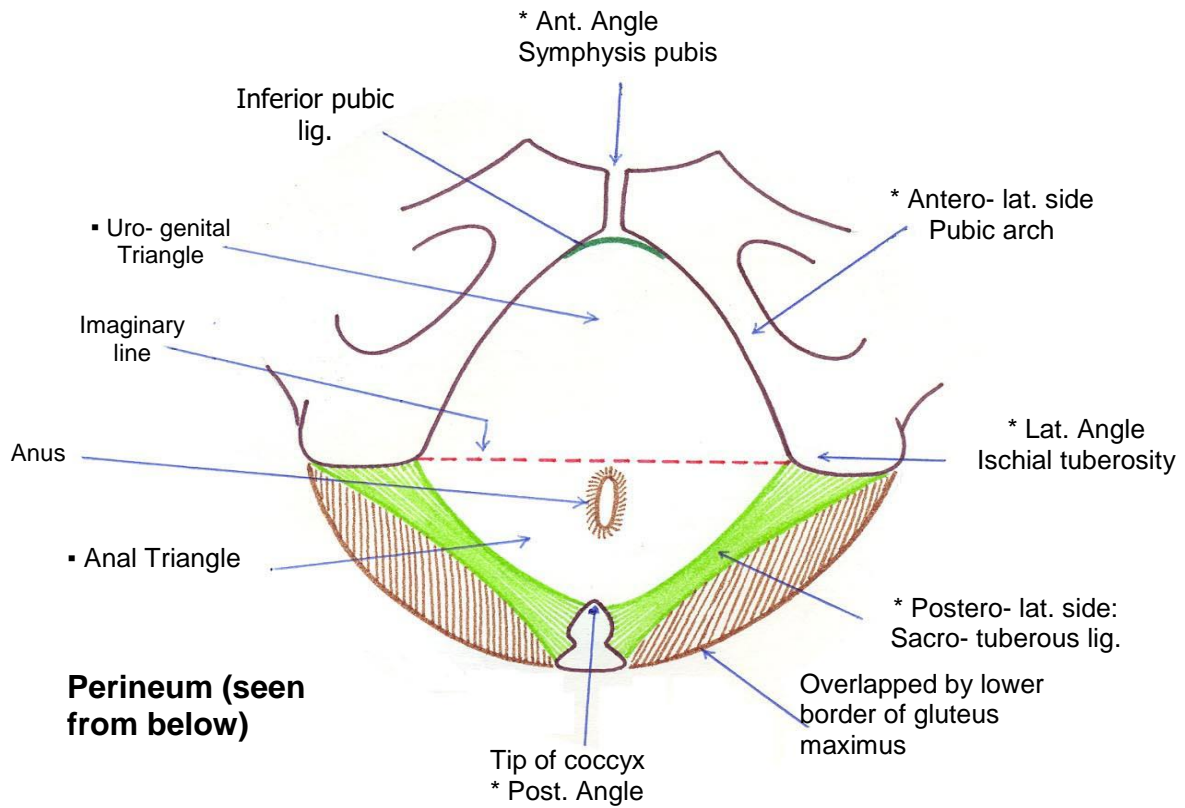
## PERINEUM

- ❖ It is the region that occupies the outlet of the pelvis.
  - ❖ **The boundaries of the perineum are:**
    - The symphysis pubis and inferior pubic ligament .
    - The ischioepubic rami .
    - The ischial tuberosities
    - The sacrotuberous ligament
    - The coccyx
  - ❖ **Divisions of the perineum:**
    - It is divided into two triangles by an imaginary line passing between the 2 ischial tuberosities and lying just in front of the anus:
- 1. Anal triangle:** posteriorly. It contains the lower part of the anal canal in the middle and the two ischioanal fossae on the sides.
  - 2. Urogenital triangle:** anteriorly. It contains the external genital organs, the superficial and deep perineal pouches and perineal membrane.



*Perineum*

**Boundaries and divisions of the perineum**



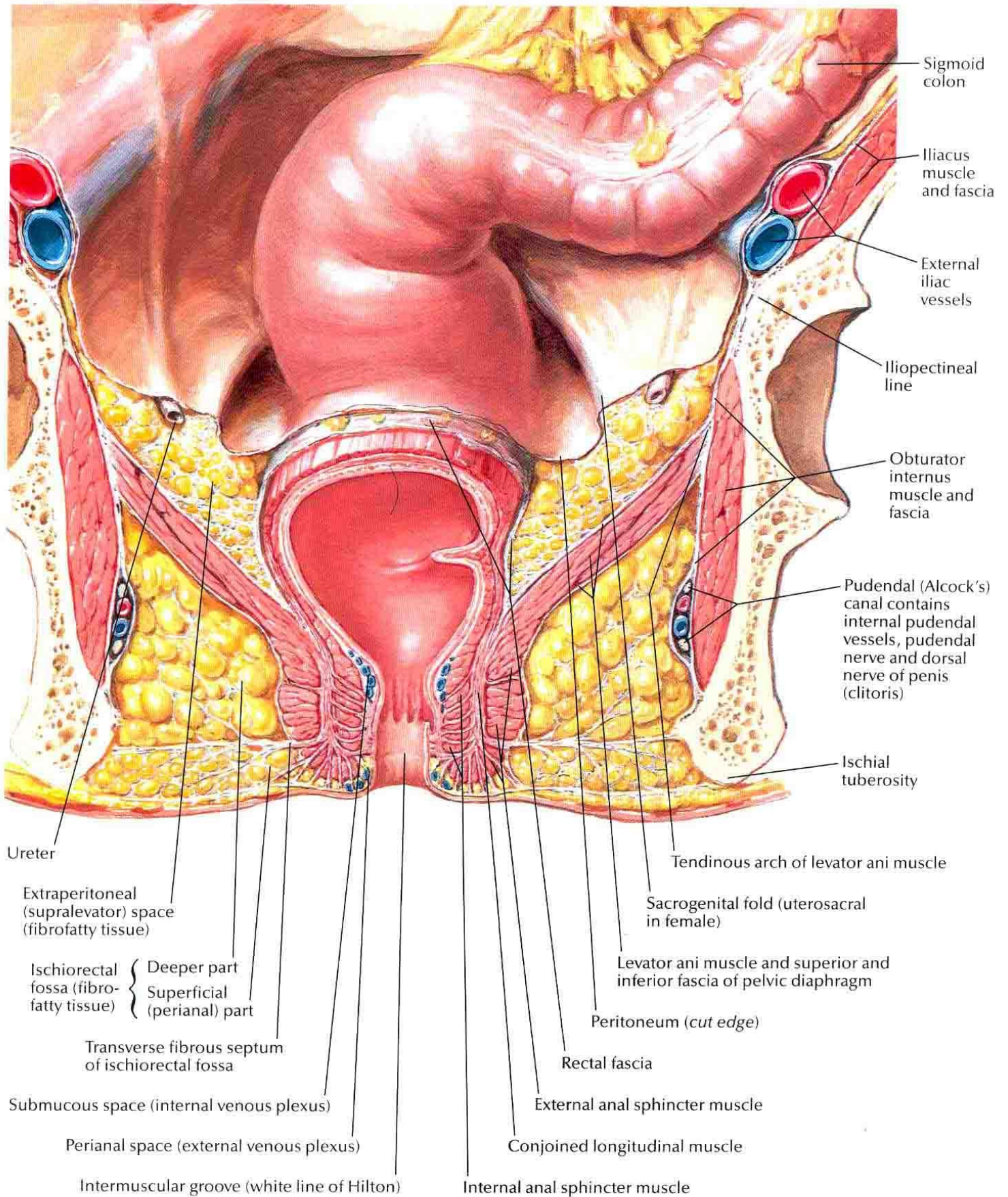
## (I) ANAL TRIANGLE

- ❖ It is the posterior triangle of the perineum containing the anal canal and an ischiorectal fossa on each side of the anal canal.

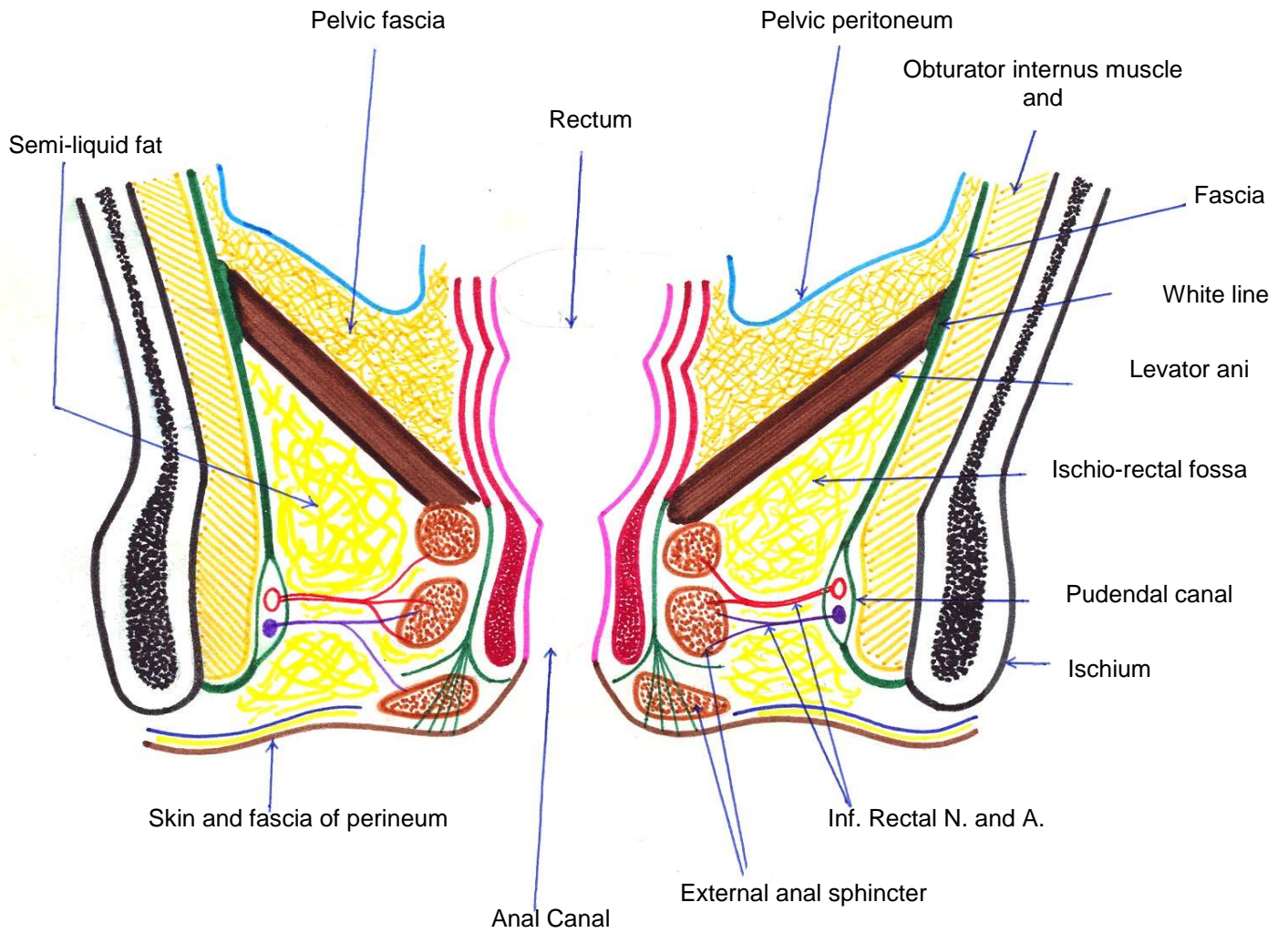
## ISCHORECTAL FOSSA

- ❖ **Site:** it lies in the anal triangle of the perineum on each side of the anal canal.
- ❖ **Boundaries:** it is wedge shaped having: *4 walls, apex and base.*
  - 1. Anterior wall:* posterior border of perineal membrane and the superficial and deep transverse perineal muscles.
  - 2. Posterior wall:* sacrotuberous ligament overlapped by the lower fibers of gluteus maximus muscle.
  - 3. Medial wall:* is sloping in its upper 2/3 where it is formed by levator ani muscle. It is vertical in its lower 1/3 where it is formed by the external anal sphincter.
  - 4. Lateral wall:* is formed by the lower part of obturator internus muscle and its fascia. The lower part of the fascia splits to form the pudendal canal (*Alcock's canal*) which encloses the pudendal nerve and internal pudendal vessels.
  - 5. Apex:* formed by the origin of levator ani muscle from the obturator fascia.
  - 6. Floor (base):* skin and fascia of the perineum.

# Perineum

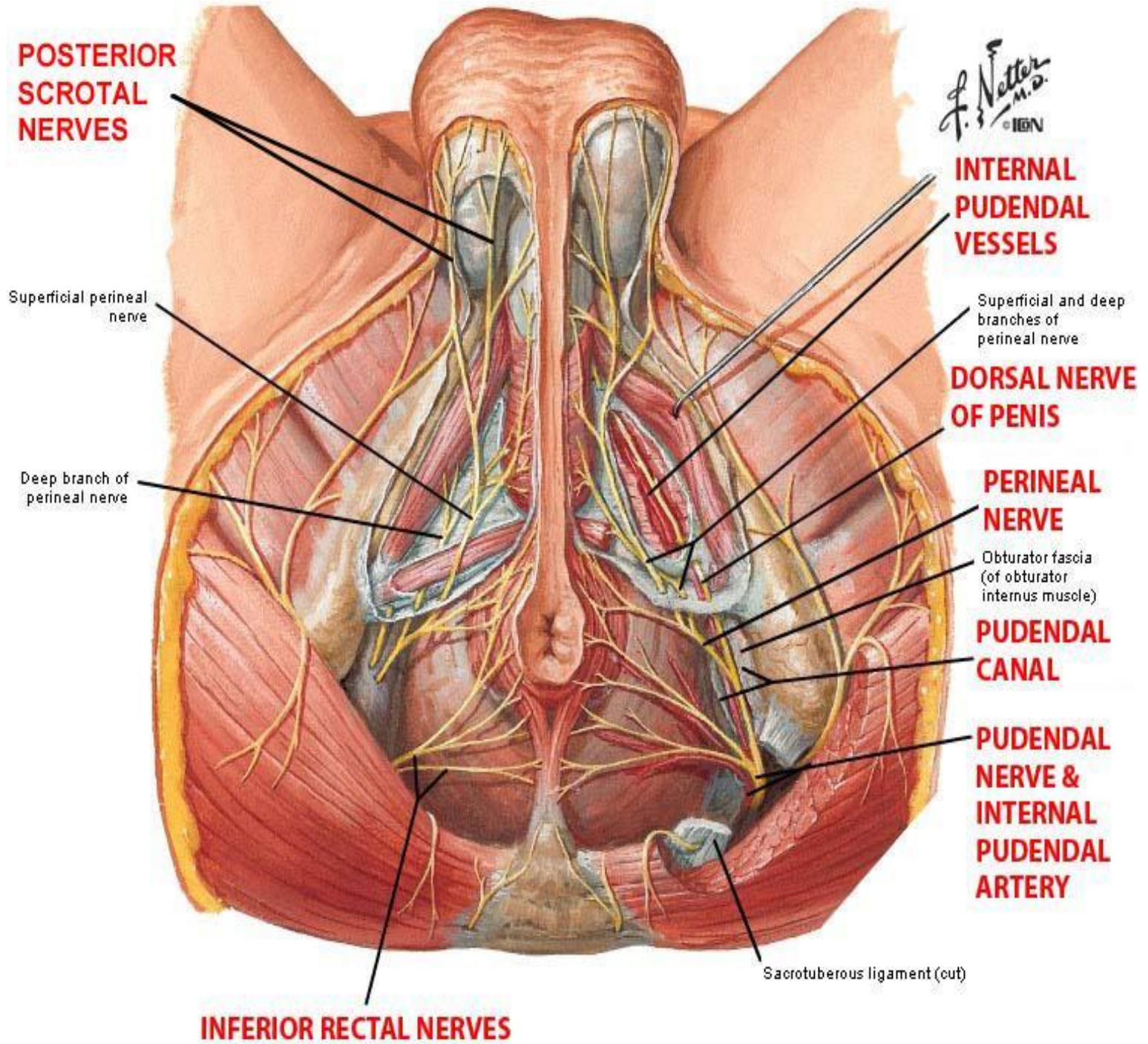


## Ischio-rectal fossa



**Coronal Section of the Perineum Ischio-Rectal Fossa**

## Boundaries and contents



## Anterior and posterior boundaries

### • Contents:

1. **Semi liquid fat:** to allow distension of the anal canal during defecation.

2. **Inferior rectal nerve:** arises from the pudendal nerve in pudendal canal. It crosses the fossa from lateral to medial to supply the external anal sphincter, levator ani and the skin around the anus.

3. **Inferior rectal vessels:** the artery arises from the internal pudendal artery in the pudendal canal, crosses the fossa from lateral to medial to reach the anal canal. The vein accompanies the artery to end in the internal pudendal vein.

4. **perineal nerve & vessels and their terminal branches :**

- Posterior Scrotal ( in male) or labial (in female) nerves and vessels.
- Muscular branches

4. **Perineal branch of S4 nerve:** pierces the coccygeus muscle and enters the posterior part of ischiorectal fossa and passes forwards to supply the external anal sphincter and levator ani muscle.

### ❖ Applied anatomy :

- Infection may occur in the ischiorectal fossa from skin around the anus or lesions within the anal canal ( eg. Anal fissure ) leading to **anorectal abscess** which may rupture on the mucosa of the anal canal or on the skin around the anus leading to **anal fistula**.

- During childbirth a bilateral pudendal nerve block may be performed to provide anesthesia to the majority of the perineum and the lower one fourth of the vagina. To do this the physician inserts a finger into the vagina and presses laterally to palpate the ischeal spine to inject local anaesthesia in the tissues around the pudendal nerve .

## **PUDENDAL CANAL**

❖ **Formation:**

- It is found in the lateral wall of ischiorectal fossa by splitting of the lower part of obturator internus fascia.

❖ **Beginning:** at the lesser sciatic foramen .

❖ **End:** it passes downwards and forwards till the posterior border of the perineal membrane to ends by opening in the deep perineal pouch.

❖ **Contents:**

1. Internal pudendal vessels.
2. Pudendal nerve .

## **INTERNAL PUDENDAL ARTERY**

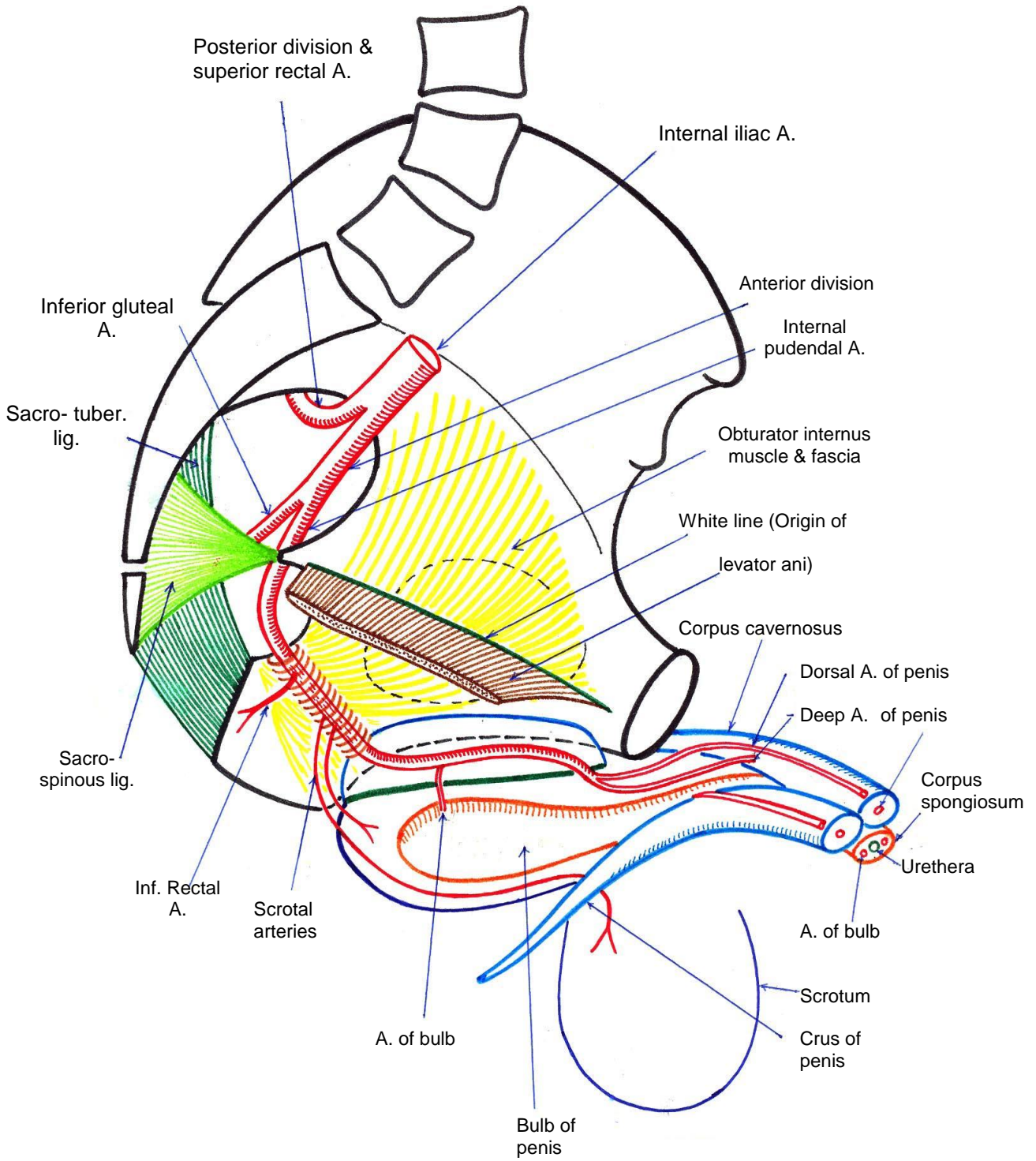
❖ **Beginning:** it begins in the pelvis as one of the 2 terminal branches of the anterior division of internal iliac artery.

❖ **Course:**

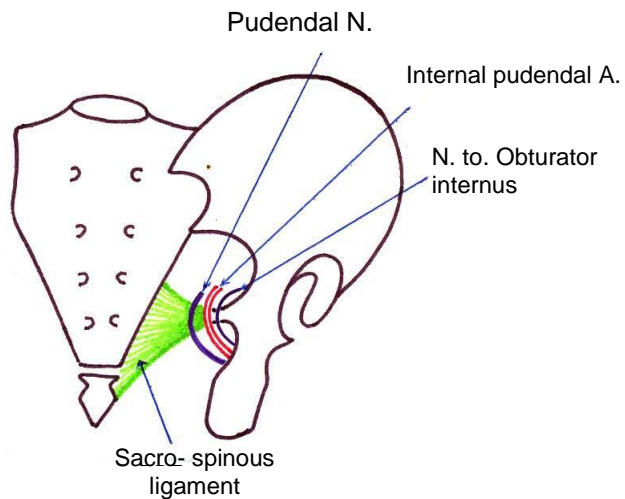
- It leaves the pelvis through the greater sciatic foramen below piriformis muscle to reach the gluteal region.
- It crosses the back of the ischial spine and passes through the lesser sciatic foramen to reach the lateral wall of the ischiorectal fossa.
- In the ischiorectal fossa it enters the pudendal canal and runs from its posterior end to its anterior end where it leaves the canal to enter the deep perineal pouch.
- In the deep perineal pouch it passes along the side of the pubic arch.



# Perineum

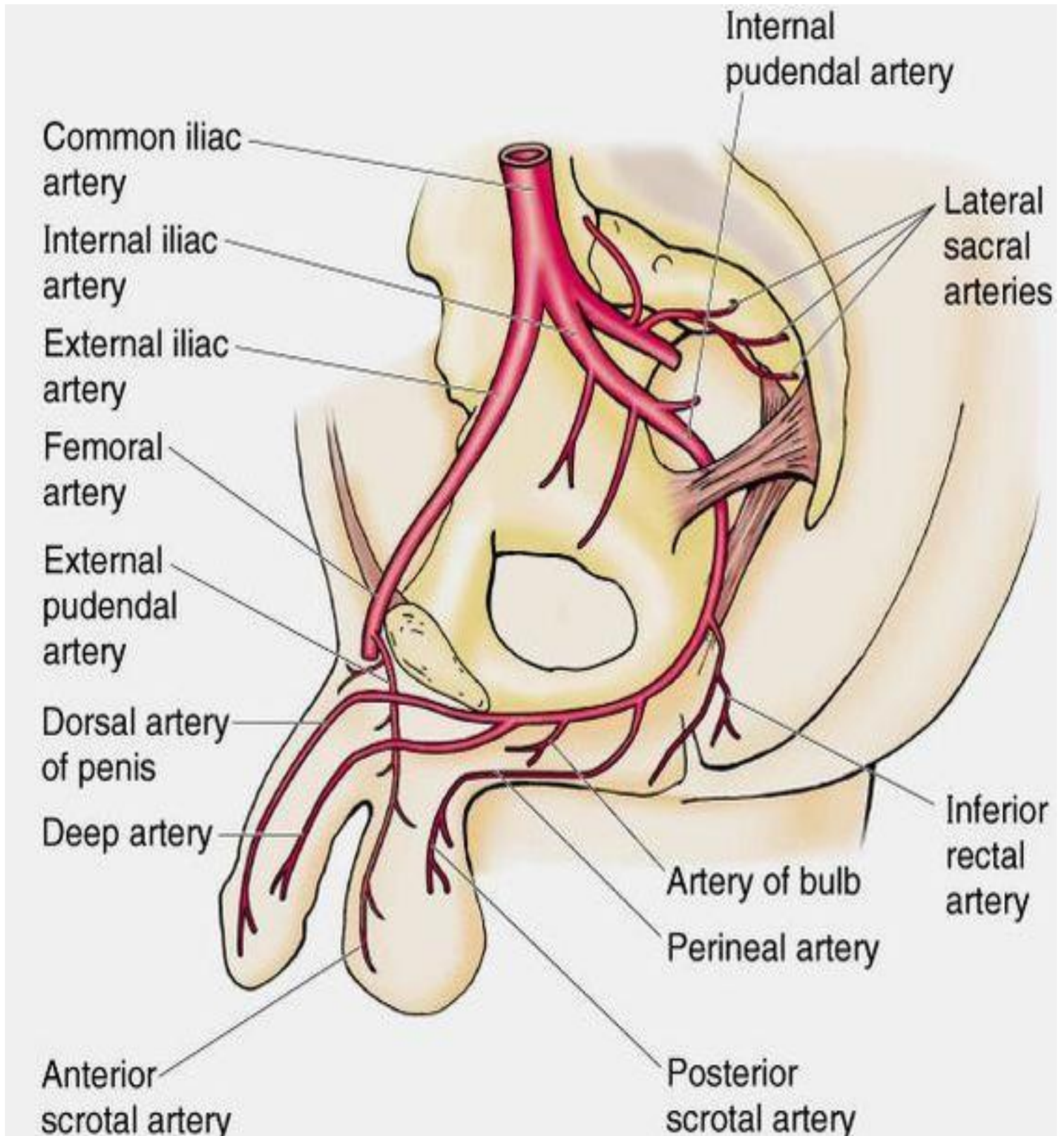


## Internal pudendal A.



## *Perineum*

---

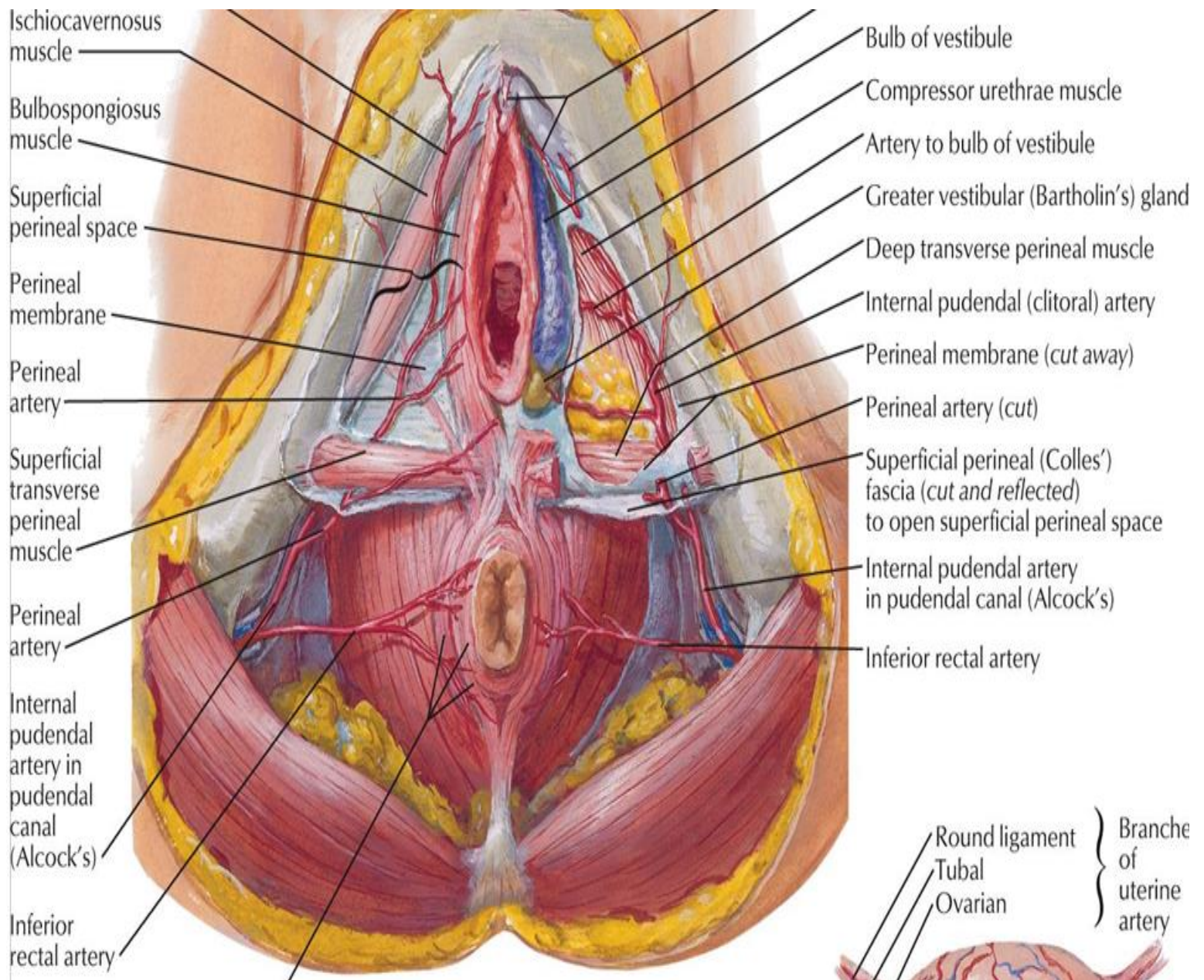


❖ **End:** it ends a short distance posterior the symphysis pubis by dividing into **dorsal and deep arteries** of the penis (in male) or clitoris (in female).

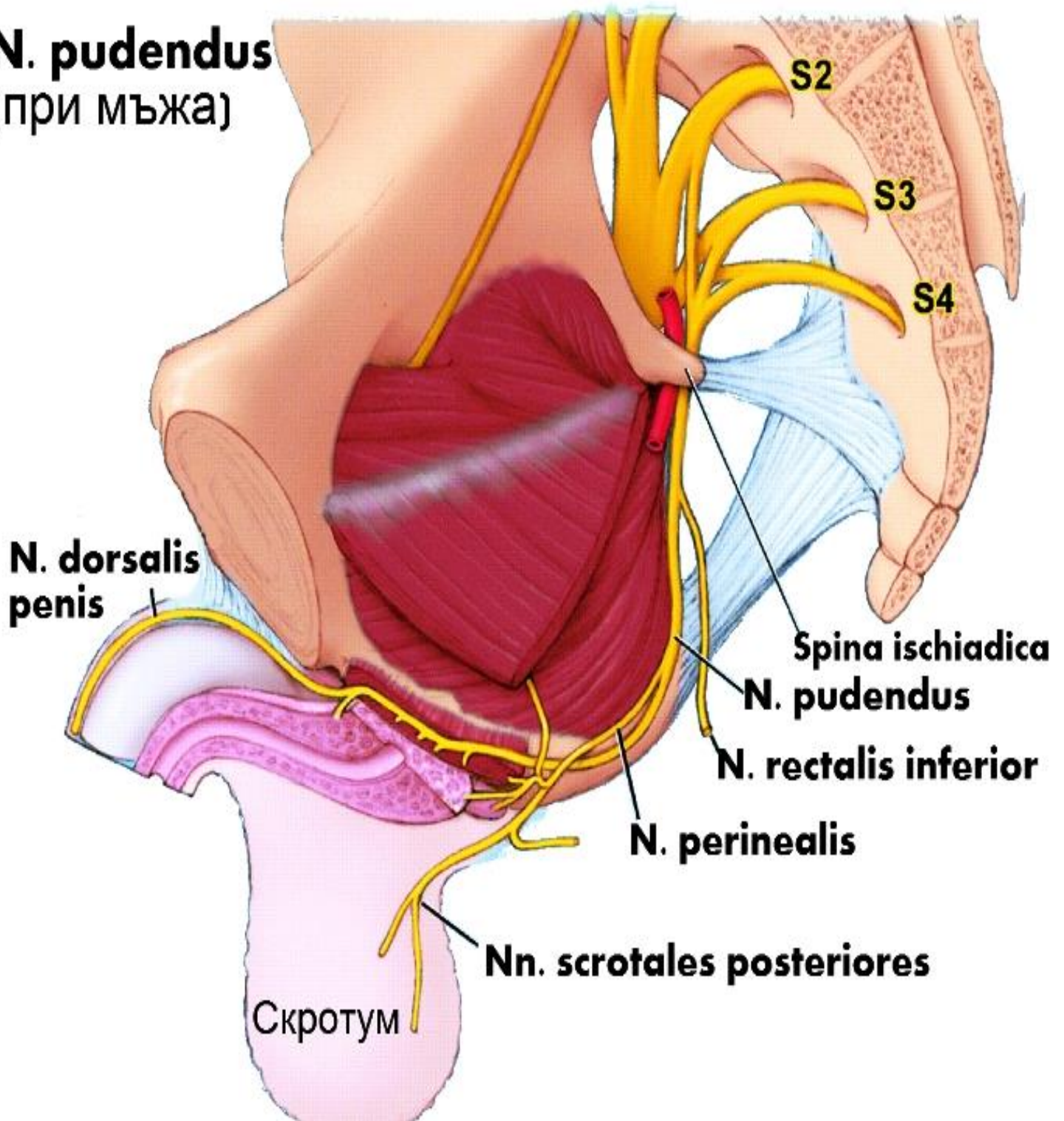
❖ **Branches:**

1. **Inferior rectal artery:** arises in the posterior end of pudendal canal. It pierces the medial wall of the canal to enter the ischio-rectal fossa. It crosses the fossa from lateral to medial to reach and supply the anal canal.
2. **Perineal artery:** pass in the ischio-rectal fossa then enter the superficial perineal pouch and divides into:
  - **Transverse perineal** artery: to supply the superficial transverse perineal muscles.
  - **Posterior scrotal** (in male) or labial (in female) arteries: to supply the scrotum or labium majus.
3. **Artery of the bulb:** arises in the deep perineal pouch. It pierces the perineal membrane to enter the bulb of the penis and runs through the corpus spongiosum along the side of urethra. It supplies the bulb of the vestibule in female
4. **Urethral artery:** arises in the deep perineal pouch & pierces the perineal membrane to supply the penile urethra.
5. **Two terminal branches:**
  - **Dorsal artery of the penis (in male) or clitoris (in female):** it pierces the perineal membrane and passes on the dorsal surface of the penis (in male) or clitoris (in female)
  - **Deep artery of the penis (or clitoris):** it pierces the perineal membrane to enter the corpora cavernosa.

# Perineum



**N. pudendus**  
(при мъжа)



## **PUDENDAL NERVE**

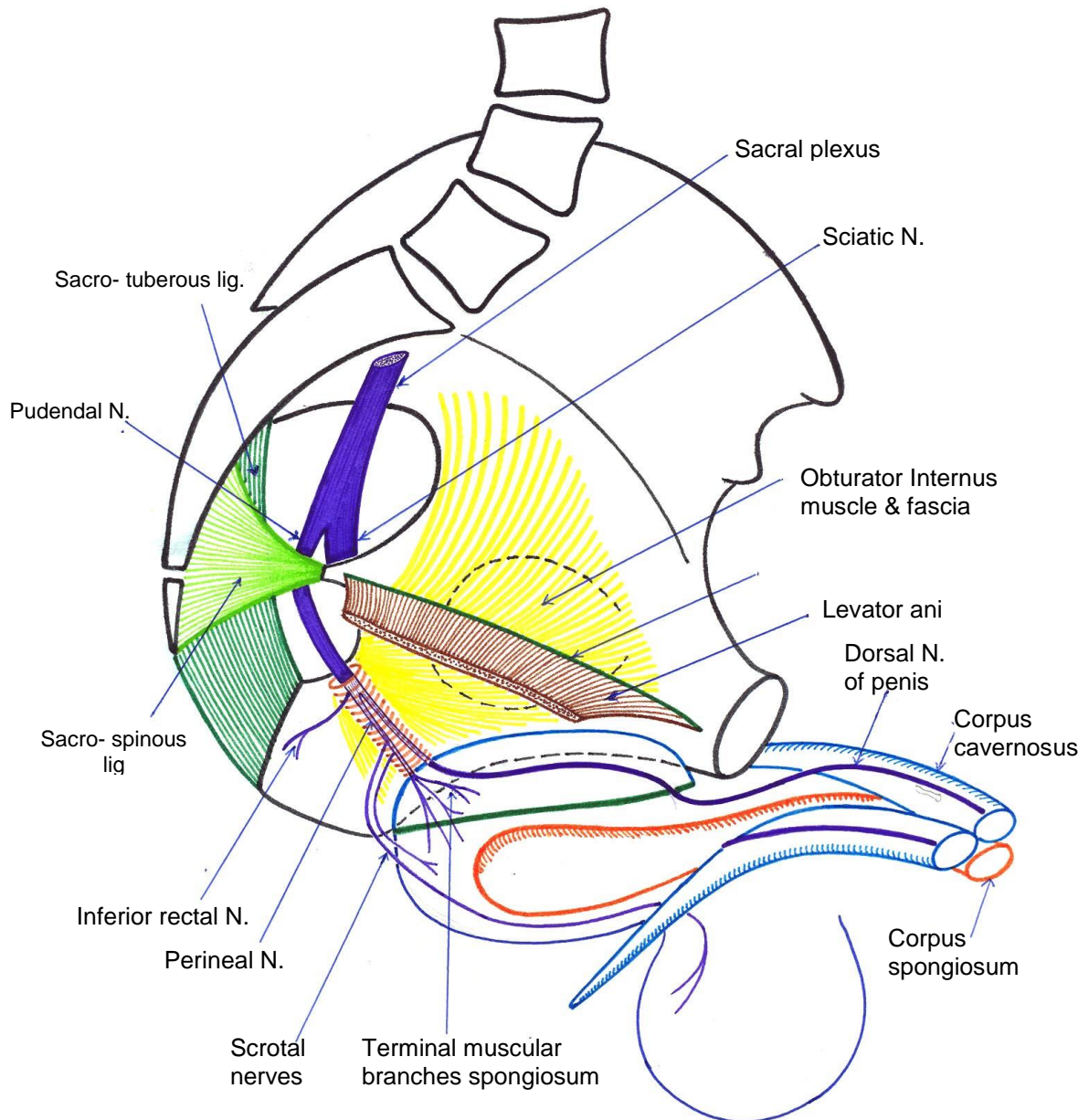
- ❖ **Origin:** in the pelvis as one of the 2 terminal branches of sacral plexus (S2, 3, 4).
- ❖ **Course:** it leaves the pelvis through the greater sciatic foramen below the piriformis muscle , crosses the back of sacrospinous ligament to enter the lesser sciatic foramen. It enters the pudendal canal in the lateral wall of the ischiorectal fossa accompanied by the internal pudendal vessels..
- ❖ **End:** once it enters the pudendal canal it gives the inferior rectal nerve then divides into 2 terminal branches:
  1. Perineal nerve
  2. Dorsal nerve of the penis (or clitoris).

### ❖ **Branches:**

1. **Inferior rectal nerve:** it pierces the medial wall of the pudendal canal crosses the ischiorectal fossa from lateral to medial to supply the external anal sphincter , inferior surface of levator ani and skin around the anus.
2. **Perineal nerve :** is one of the 2 terminal branches of pudendal nerve , pass to the superficial perineal pouch . It gives :
  - Posterior scrotal (or labial) branches
  - Muscular branches which supply the superficial and deep perineal muscles.
3. **Dorsal nerve of the penis (or clitoris):** Is the other terminal branch. It runs forwards in the pudendal canal. At the anterior end of the canal it enters the deep perineal pouch where it pierces the perineal membrane to reach the superficial perineal pouch and runs along the dorsum of the

## *Perineum*

penis with the dorsal artery of the penis. It is the main sensory nerve to the penis ( or clitoris ) especially the sensitive glans at its distal end .



**Pudendal Nerve**

**\*Pudendal nerve\***

## (II)UROGENITAL TRIANGLE

- ❖ It is the *anterior* triangle of the perineum.
- ❖ It *contains* the external genital organs as well as the superficial and deep perineal pouches separated by the perineal membrane.

### PERINEAL MEMBRANE

- ❖ It is a strong fibrous nearly triangular membrane closing the urogenital hiatus in the pelvic diaphragm .
- ❖ It separates the deep from the superficial perineal pouches.

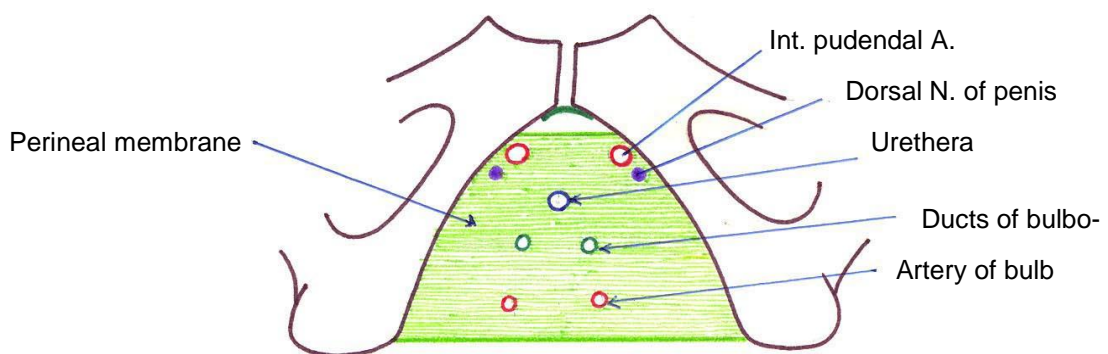
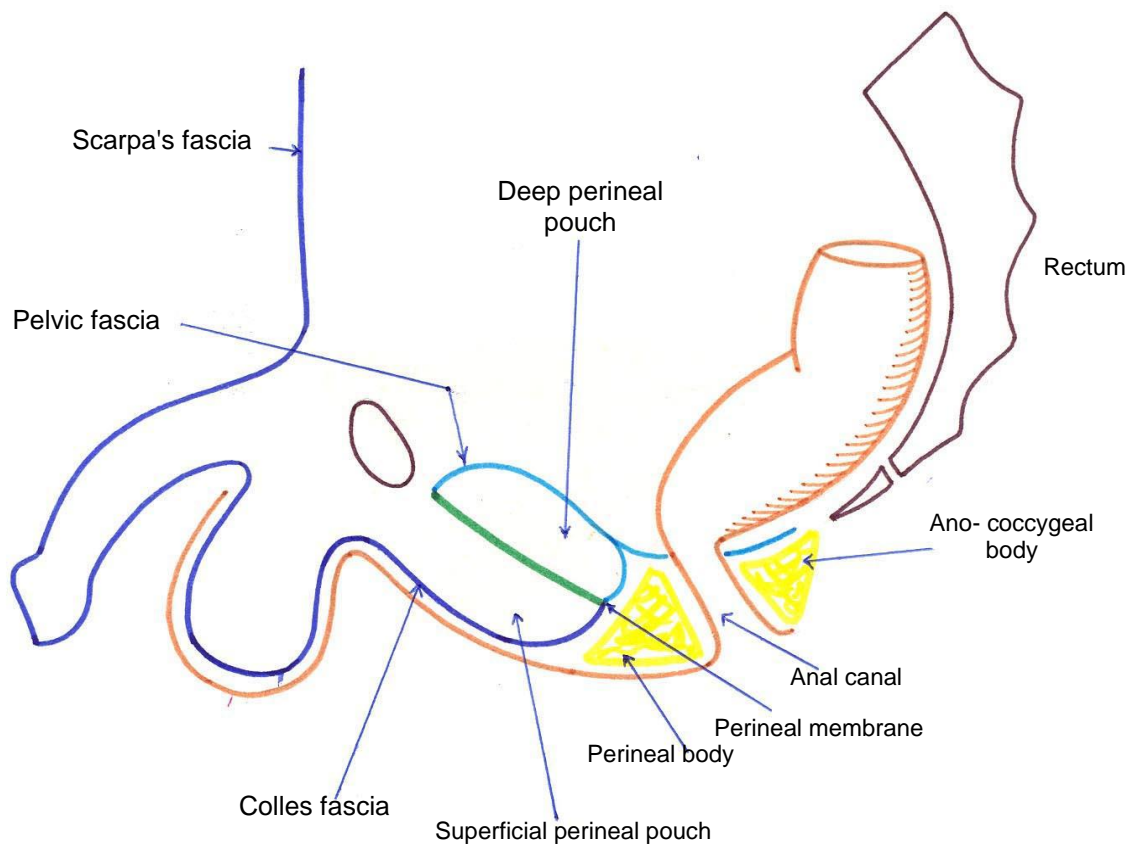
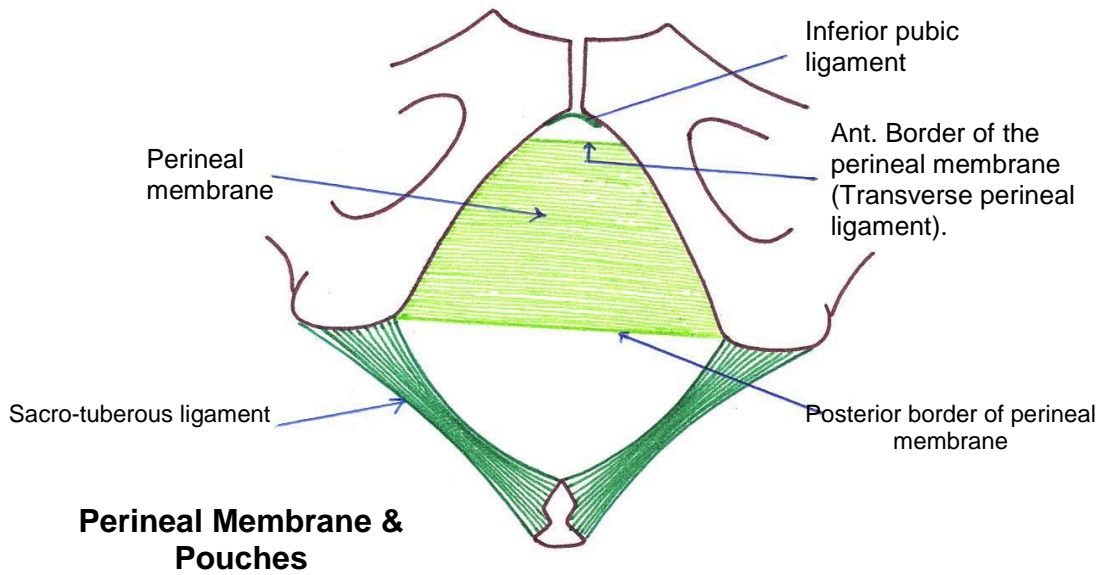
#### ❖ **Attachments :**

- *Anteriorly:* its **anterior border** is thickened to form the **transverse perineal ligament** .There is a **gap** between the transverse perineal ligament and the inferior pubic ligament of the symphysis pubis through which passes the **deep dorsal vein** of the penis to enter the pelvis and ends into the prostatic venous plexus.
- *Posteriorly :* It has a posterior border which **fuses** with *Colle's fascia* superficial to it and the inferior fascia of pelvic diaphragm deep to it thus closing the the superficial and deep perineal pouches , respectively , posteriorly.
- *Laterally:* it is attached to the pubic arches.

#### ❖ **Relations of the perineal membrane:**

- *Deep surface:* contents of the deep perineal pouch.
- *superficial surface:* contents of the superficial perineal pouch.





**Structures piercing the perineal membrane in male**

## *Perineum*

---

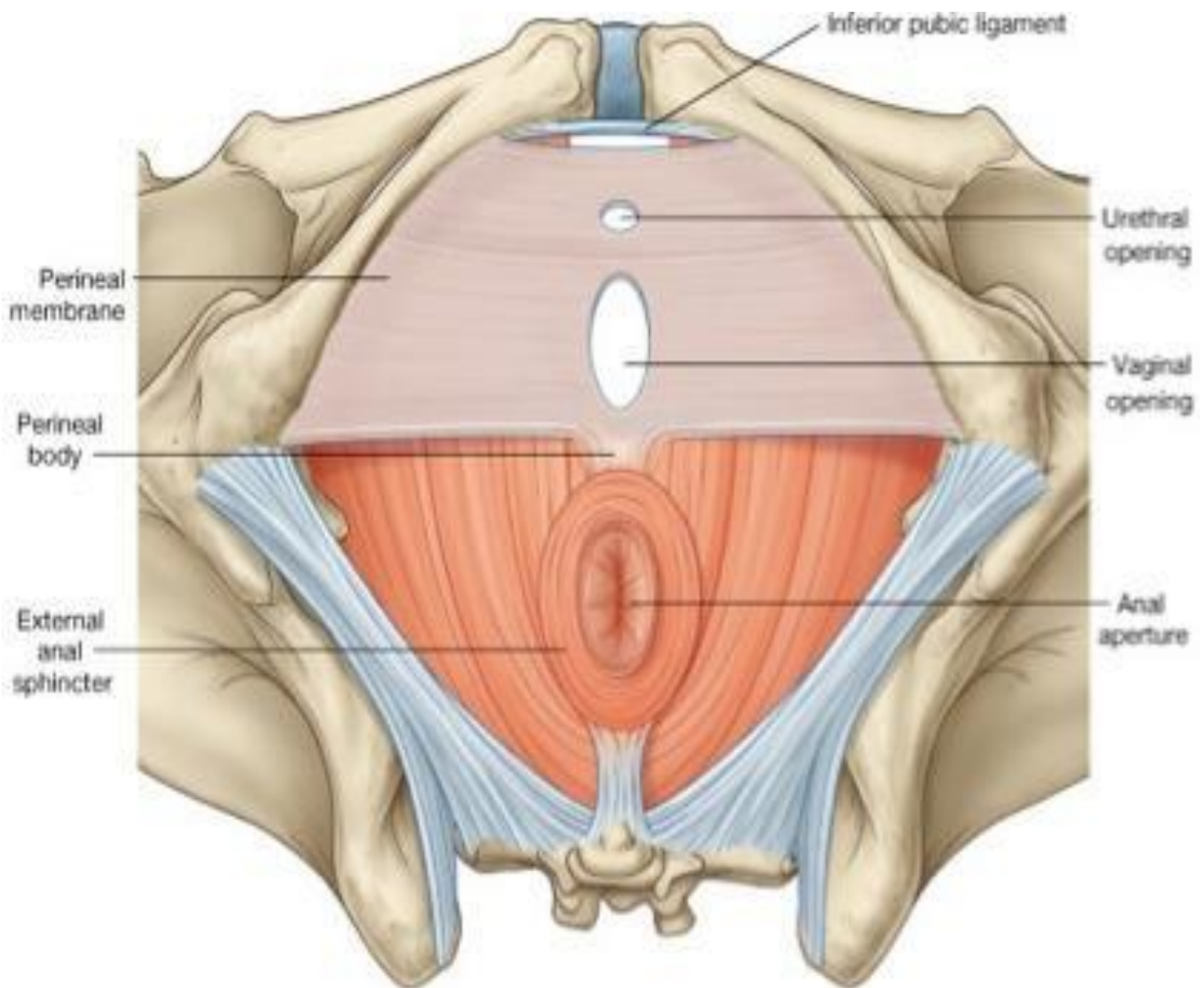
<b>In male</b>	<b>In female</b>
<p>1.Urethra</p> <p>2.Ducts of the bulbo-urethral glands (on the sides of the urethra).</p> <p>3.Branches of internal pudendal artery :</p> <ul style="list-style-type: none"><li>• Artery of the bulb of penis (beside the urethra).</li><li>• Urethral artery .</li><li>• 2 terminal branches :.Deep &amp; Dorsal artery of penis .</li></ul> <p>4. Dorsal nerve of penis</p>	<p>1.Urethra</p> <p>2.Vagina (behind the urethra).</p> <p>3.Branches of internal pudendal artery :</p> <ul style="list-style-type: none"><li>• Artery of the bulb of vestibule.</li><li>• Urethral artery .</li><li>• 2 terminal branches :.Deep &amp; Dorsal artery of clitoris .</li></ul> <p>4. Dorsal nerve of clitoris .</p>

### **❖ Structures which pierce the perineal membrane:**

**( one nerve , 2 tubes & 3 arteries )**

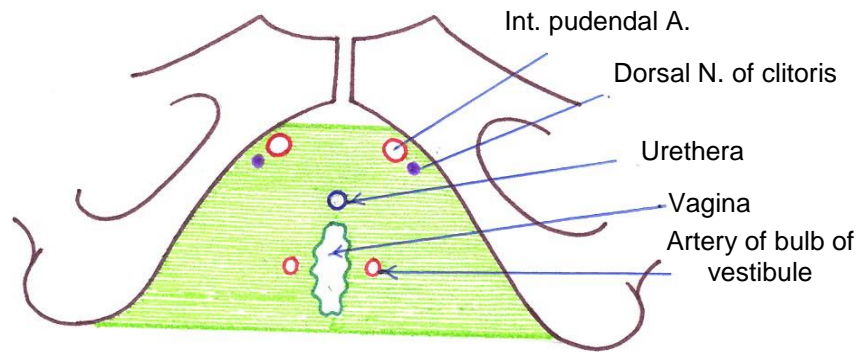
## *Perineum*

---



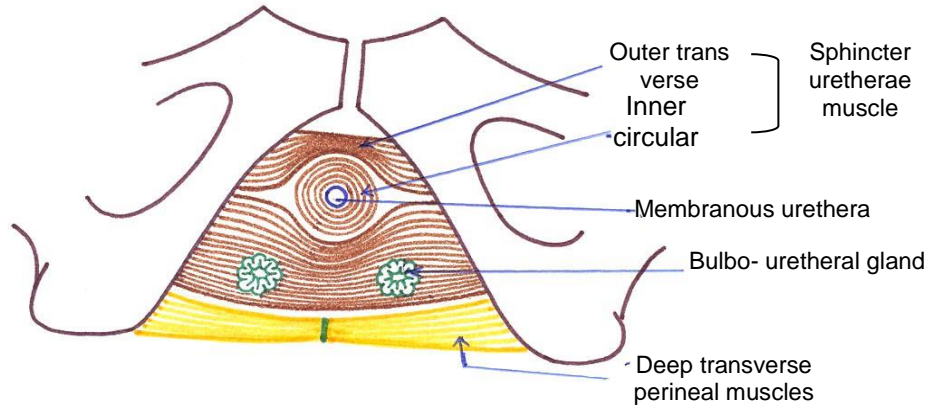
**\* PERINEAL MEMBRANE \***

*Pε*

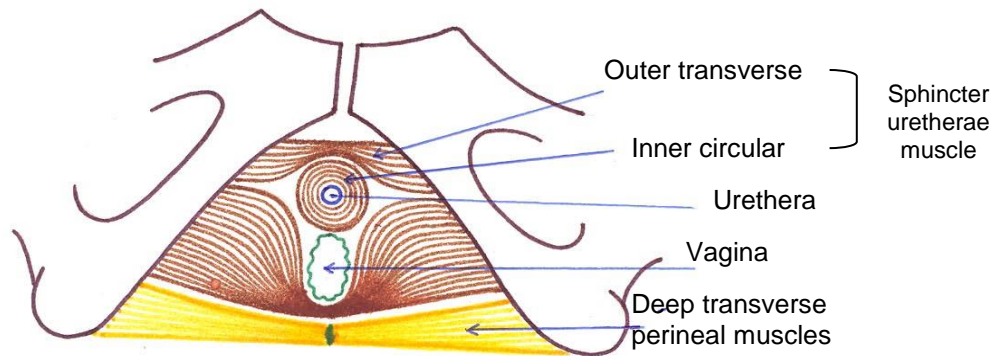


**Structures piercing perineal membrane in female**

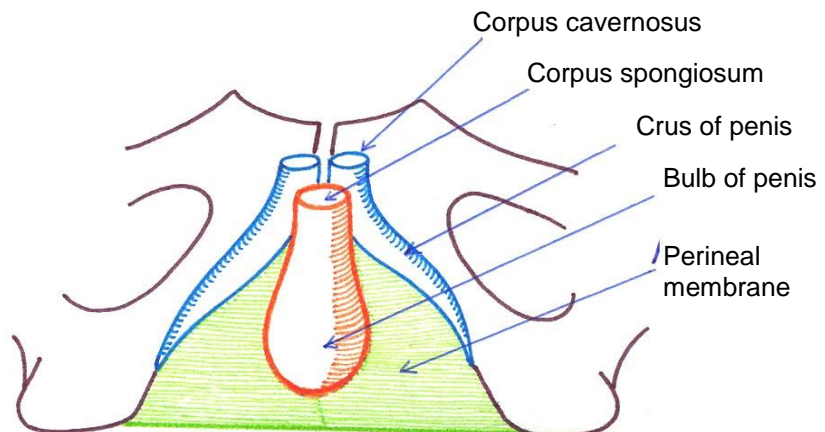
**Contents of Deep perineal pouch in male**



**Contents of Deep perineal pouch in female**



**Contents of Superficial perineal pouch in male**



## Perineal Body

- It is a *fibromuscular pyramidal* mass in the center of the perineum.
- It is a remnant of the *urorectal septum of the embryo*.
- It lies *between* the urogenital and anal triangles.
- It lies *between* the anal canal posteriorly and the bulb of the penis (*in male*) or vagina (*in female*) anteriorly.
- *In female* it lies just posterior to the posterior end of labia majora.
- It is very important in the *integrity* of the pelvic floor and should be protected during labor.

### ❖ Structures attached to the perineal body:

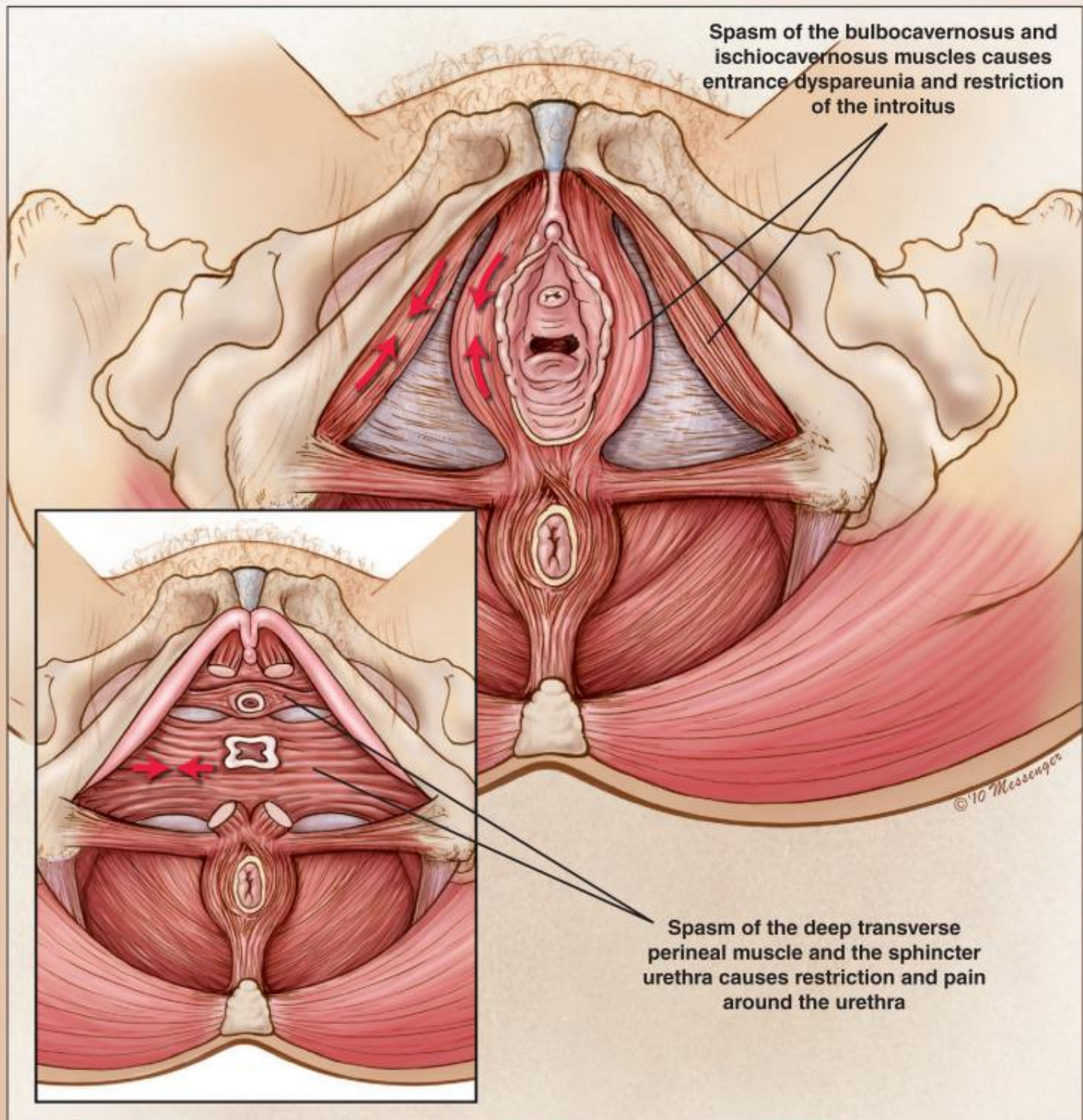
- *Anteriorly*: posterior border of perineal membrane, bulbospongiosus muscles & some fibers of external urethral sphincter.
- *Laterally*: the deep and superficial transversus perinei.
- *Posteriorly*: fibers from superficial part of the external anal sphincter.
- *Superiorly*: Denonvilliere fascia and fibers from levator ani.
- *Inferiorly covered by* skin & sc fat.

### ❖ Applied anatomy :

#### 1- Episiotomy

- During child birth a tear may occur in the posterior wall of vagina, perineal body and may extend to the anal canal.
- This **complete perineal tear** may cause weakness of the pelvic floor, uterine prolapse or injury to the external anal sphincter.

## Perineum



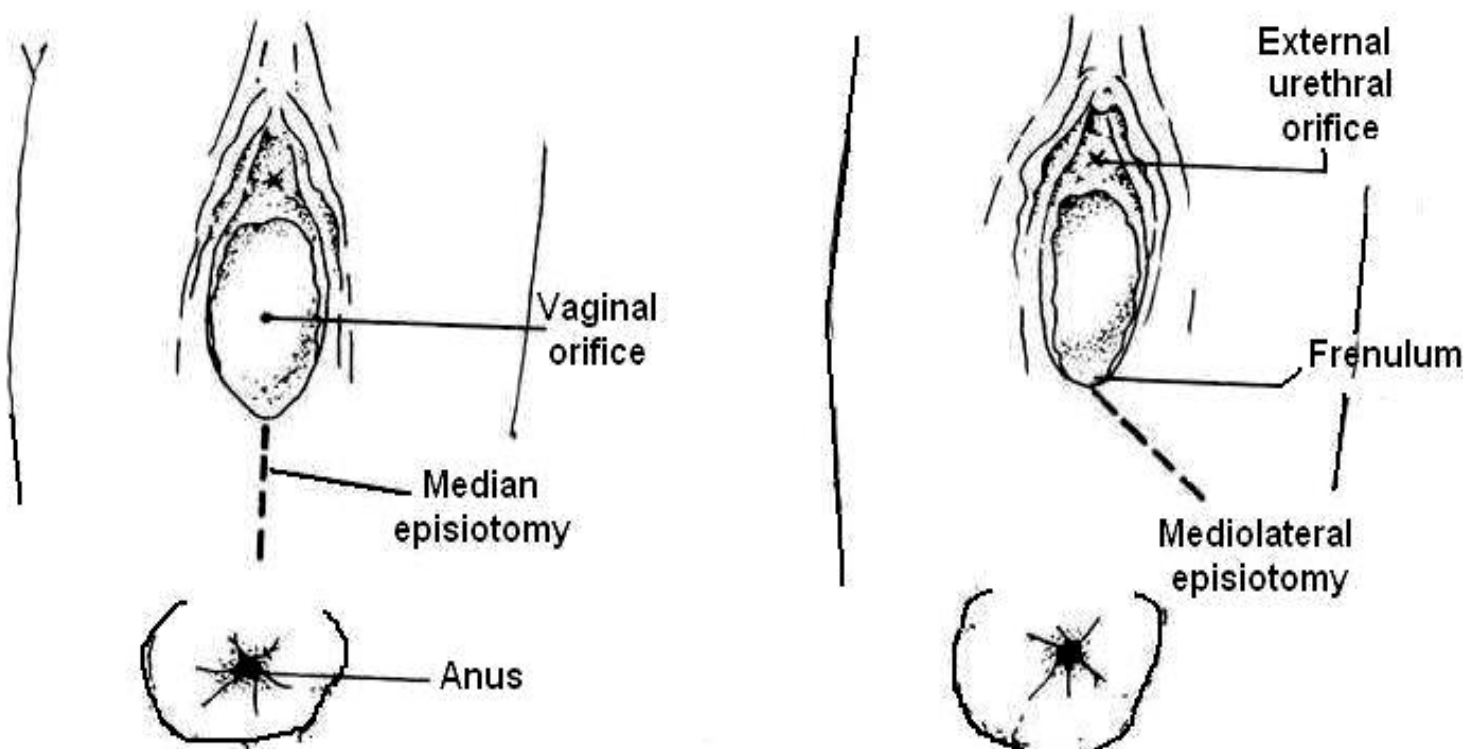
**\*Muscles attached to the perineal body in female\***

## Perineum

---

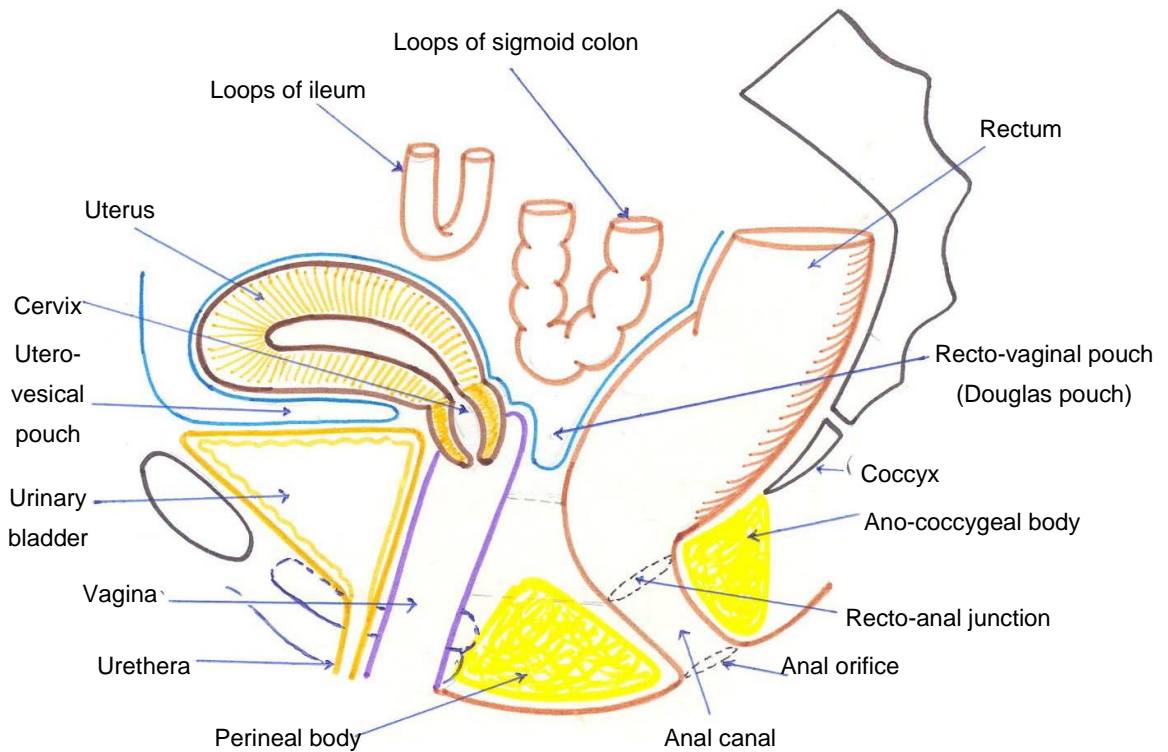
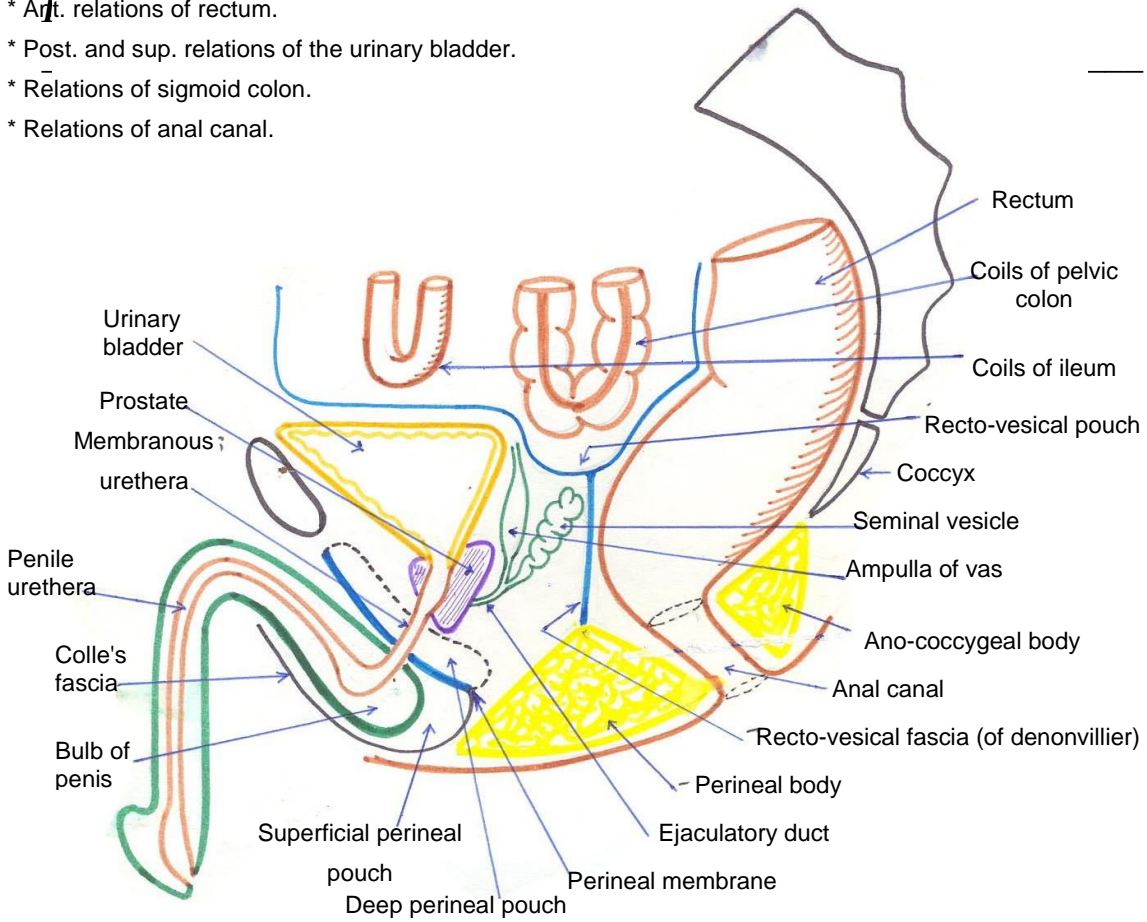
- **Instead** an episiotomy is done which is a surgical incision through the perineal skin ,perineal muscles and may be the levator ani.
  - The incision is easier to suture and heal better than the tear.
  - Two types are commonly used ; median and mediolateral. The mediolateral incision is preferred to avoid injury of the perineal body.
- 2- Tearing or stretching of perineal body due to repeated childbirth leads to prolapse of the vagina and uterus.

## Episiotomy



**Sagittal section in Male Pelvis:**

- \* Ant. relations of rectum.
- \* Post. and sup. relations of the urinary bladder.
- \* Relations of sigmoid colon.
- \* Relations of anal canal.



**Sagittal section in Female Pelvis:**

- \* Ant. relations of rectum.
- \* Post. and sup. relations of the urinary bladder.
- \* Relations of sigmoid colon.
- \* Relations of anal canal.



## \* DEEP PERINEAL POUCH \*

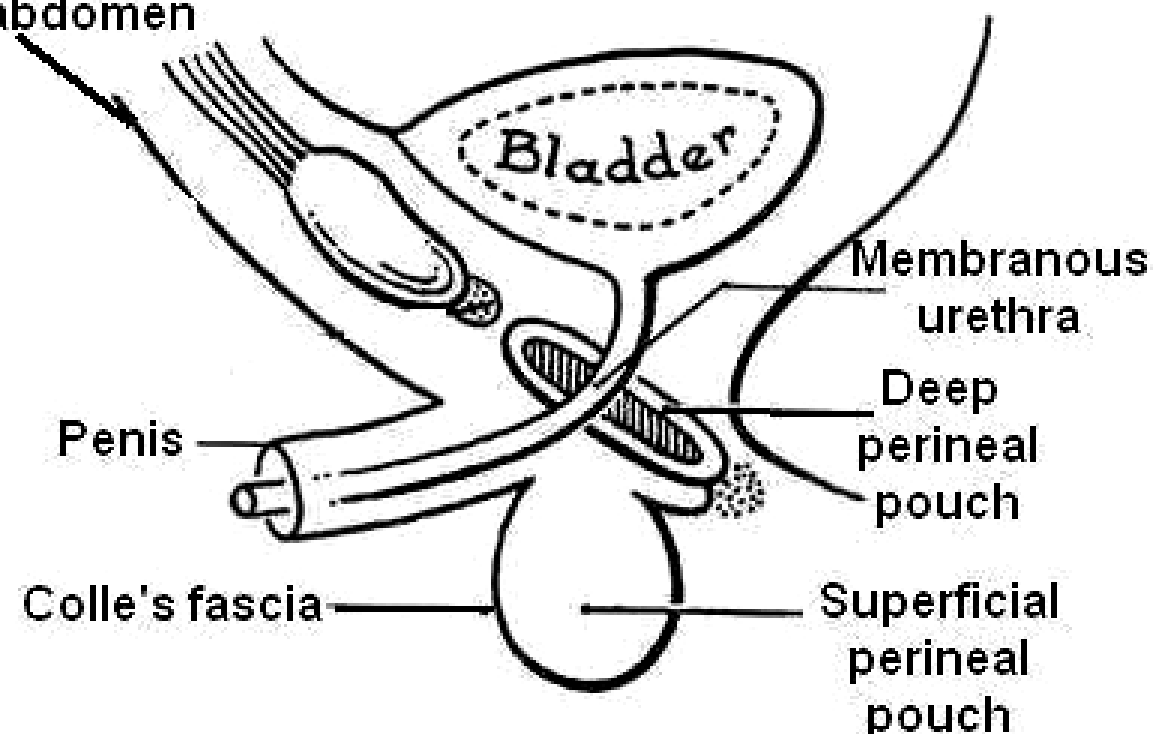
### ❖ Site :

- It is a closed space which lies between the inferior fascia of pelvic diaphragm above and the perineal membrane below .

### ❖ Boundaries:

1. **Roof** : inferior fascia of pelvic diaphragm .
2. **Floor** : perineal membrane .
3. **Anteriorly**: the pouch is closed as the inferior fascia of pelvic diaphragm fuses with the anterior border of the perineal membrane.
4. **Posteriorly**: the pouch is closed as the inferior fascia of pelvic diaphragm fuses with the posterior border of perineal membrane.
5. **On either side**: the pouch is closed as the perineal membrane (the floor) and the inferior fascia of pelvic diaphragm (the roof) are attached to the pubic arches.

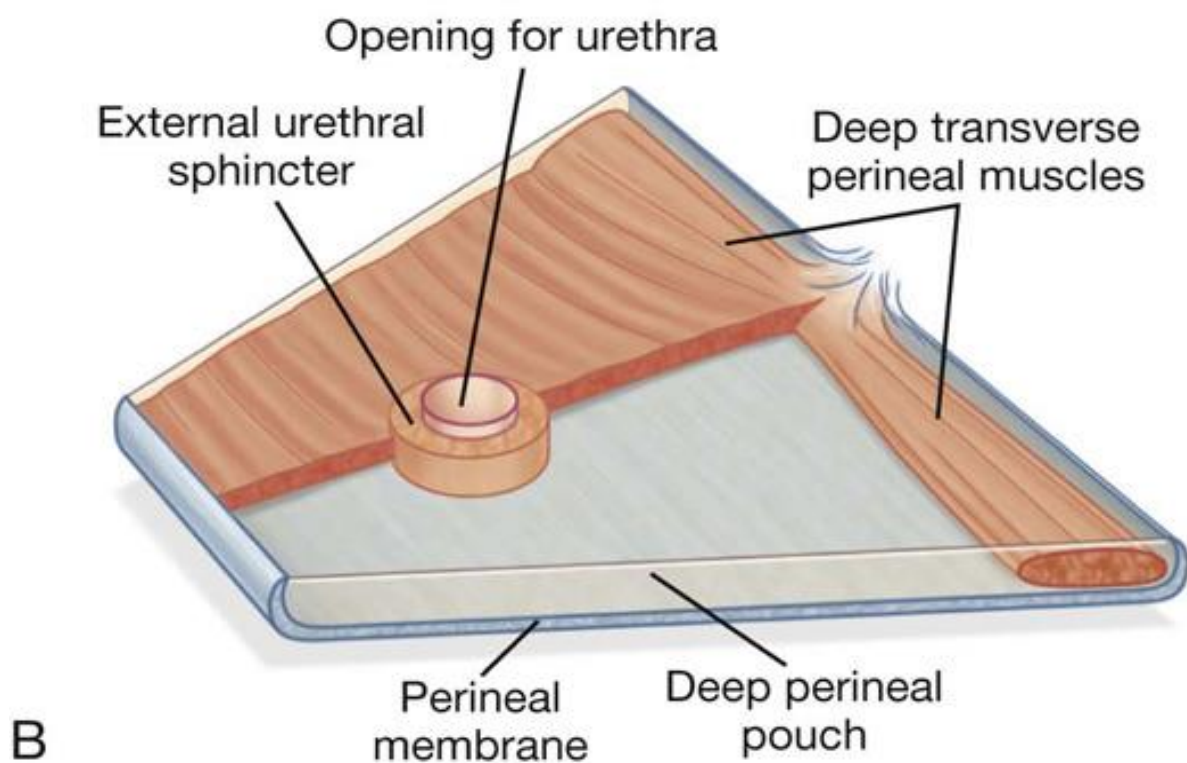
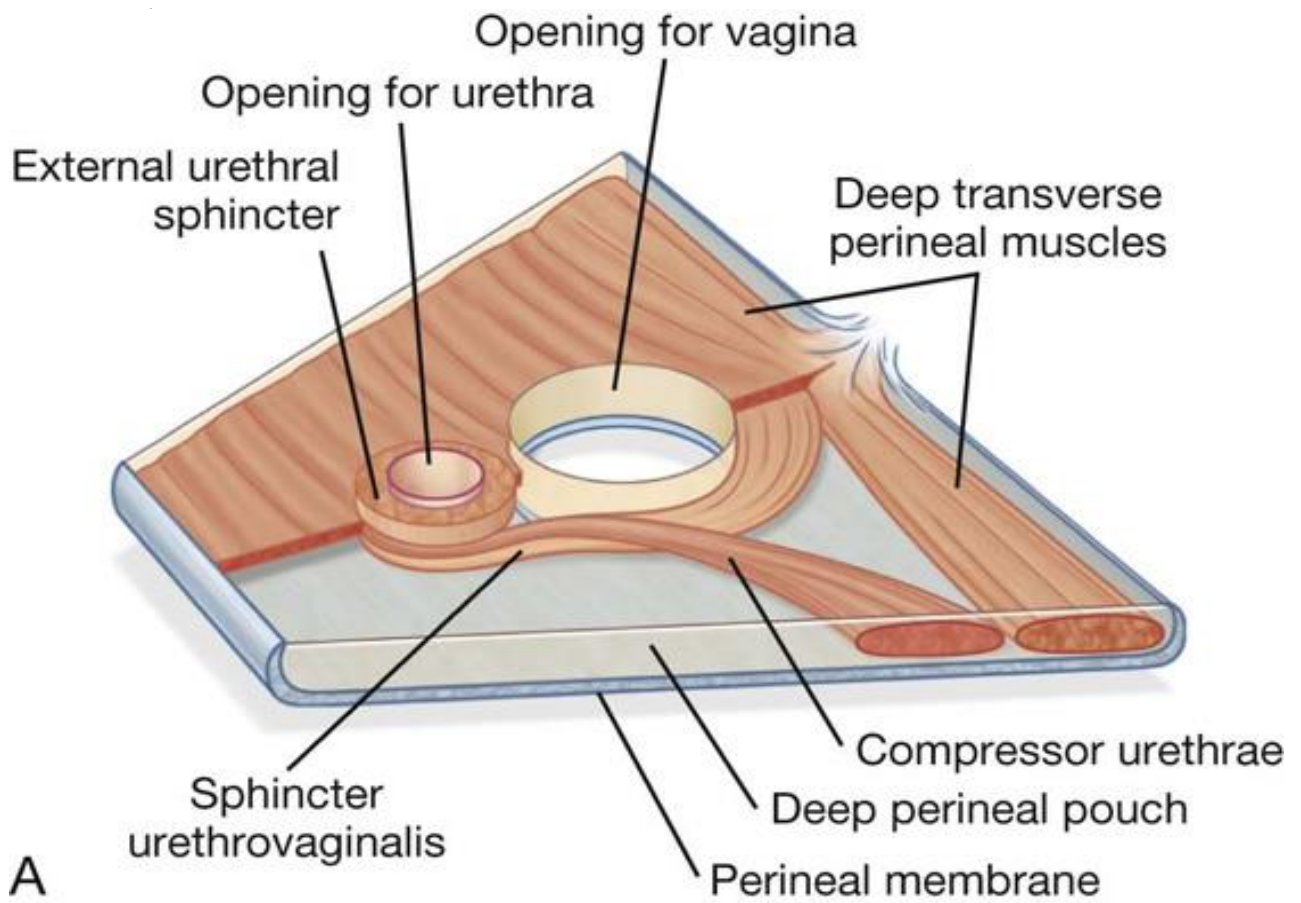
### Deep membranous layer of superficial fascia of abdomen



❖ **Contents of the deep perineal pouch**

<i>In male</i>	<i>In female</i>
<p>1.Membranous urethra</p> <p>2.Bulbo-urethral glands (<i>Cowper's</i>) on the sides of urethra..</p> <p>3.Deep perineal muscles</p> <p style="padding-left: 40px;">a)Deep transversus perinei</p> <p style="padding-left: 40px;">b)Sphincter urethrae muscle.</p> <p>4.Internal pudendal artery &amp; its branches :</p> <ul style="list-style-type: none"> <li>• 2 terminal branches (deep and dorsal arteries of the penis)</li> <li>• Urethral artery .</li> <li>• Artery of the bulb of penis.</li> </ul> <p>7.Dorsal nerve of penis.</p> <p>8. Some of branches of perineal nerve to supply the muscles in deep perineal pouch.</p>	<p>1.Part of urethra</p> <p>2.Vagina (behind the urethra)</p> <p>3.Deep perineal muscles</p> <p style="padding-left: 40px;">a)Deep transversus perinei</p> <p style="padding-left: 40px;">b)Sphincter urethrae muscle.</p> <p>4.Internal pudendal artery &amp; its branches :</p> <ul style="list-style-type: none"> <li>• 2 terminal branches (deep and dorsal arteries of the clitoris)</li> <li>• Urethral artery .</li> <li>• Artery of the bulb of vestibule.</li> </ul> <p>. 7.Dorsal nerve of clitoris.</p> <p>8. Some of branches of perineal nerve to supply the muscles in deep perineal pouch. .</p>

( these structures are classified into 2 tube , muscles & their nerve supply , and neurovascular bundle passing to the penis )

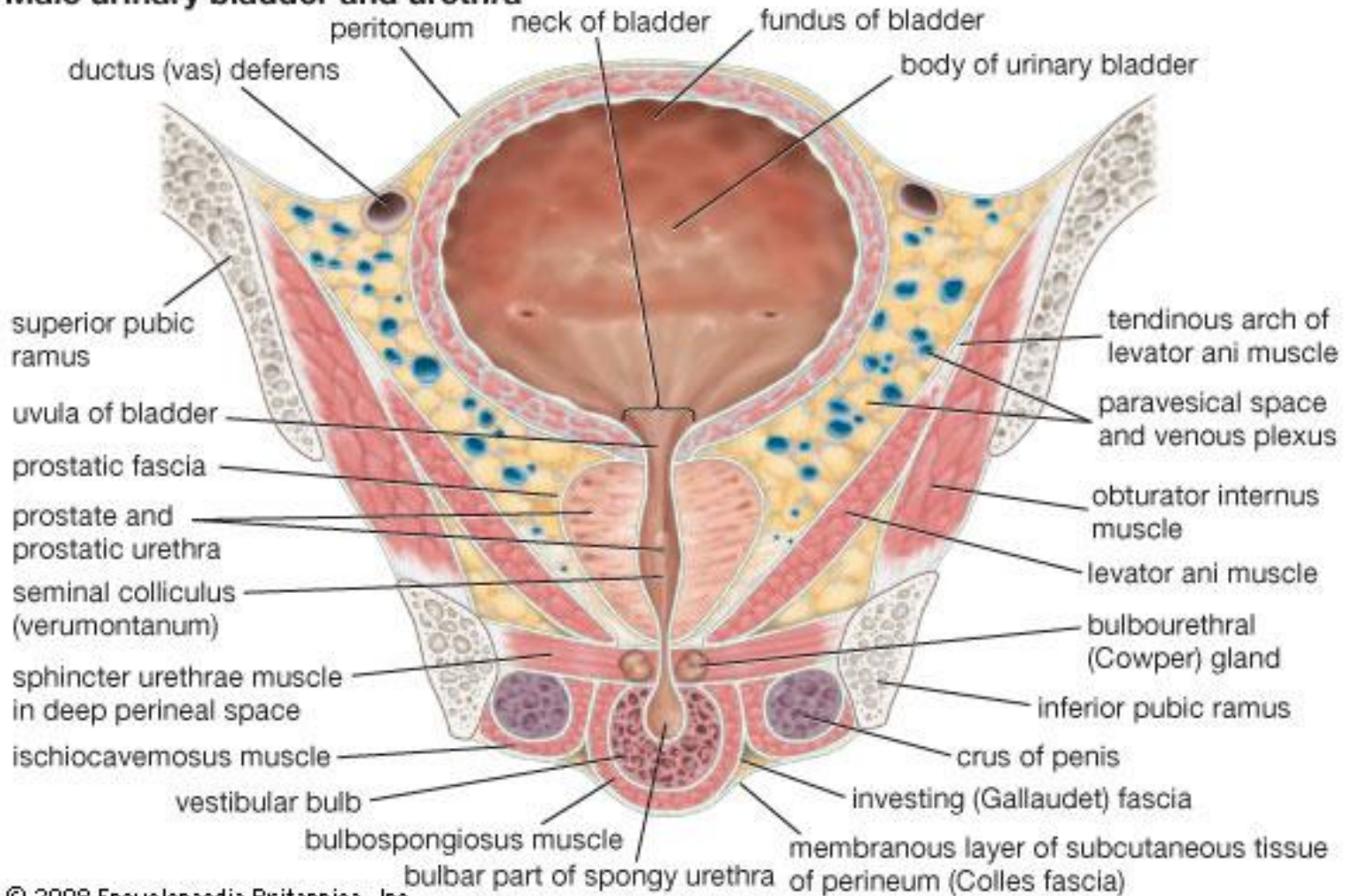


**\* Muscles in the deep perineal pouch \***

## Perineum

---

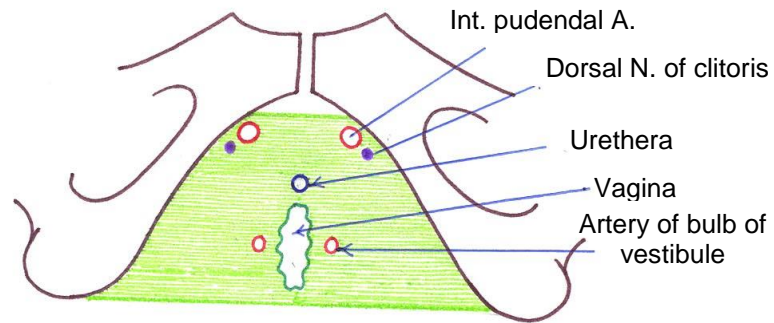
### Male urinary bladder and urethra



© 2008 Encyclopaedia Britannica, Inc.

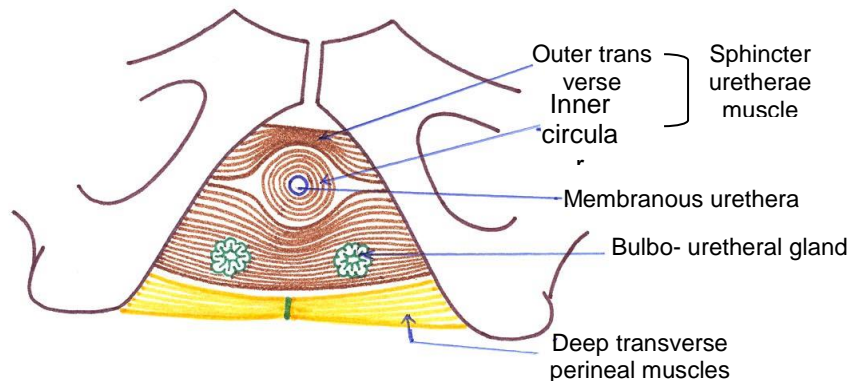
**\* Coronal section in superficial & deep perineal pouches in male \***

# Perineum

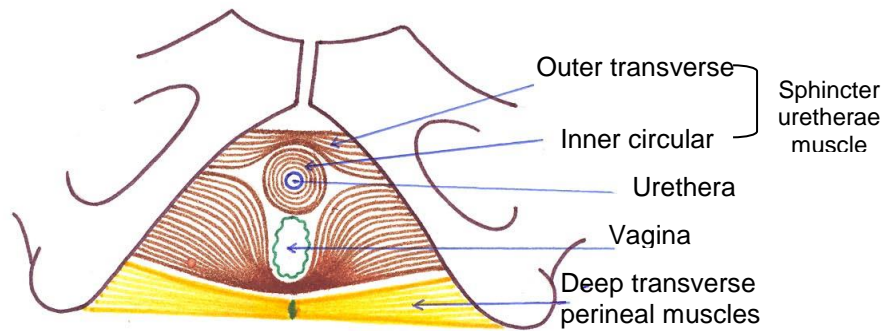


**Structures piercing perineal membrane in female**

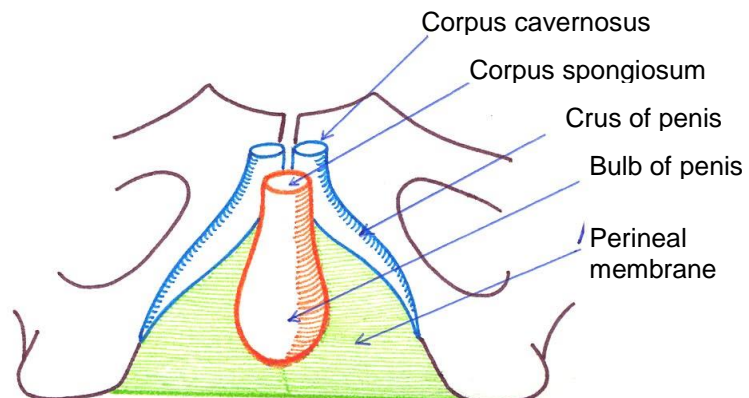
**Contents of Deep perineal pouch in male**



**Contents of Deep perineal pouch in female**



**Contents of Superficial perineal pouch in male**



❖ **Deep perineal muscles:**

**1. Sphincter urethrae muscle (external sphincter of the urethra):**

- It consists of voluntary muscle fibers surrounding the membranous urethra in male and the upper part of the urethra and vagina in female.
- It consists of 2 parts:
  1. Inner circular fibers: surrounds the urethra
  2. Outer transverse fibers: arise from the pubic arch and diverge as they run medially.

**2. Deep transversus perinei muscles:** Arise from the ischial ramus and run medially along the posterior border of perineal membrane to end in the perineal body.

- ❖ **Nerve supply:** All the deep perineal muscles are supplied by the perineal branch of pudendal nerve.

## **SUPERFICIAL PERINEAL POUCH**

❖ **Site:**

- It is the space which lies between the perineal membrane above and the membranous layer of the superficial fascia of the perineum (*Colle's fascia*) below.

❖ **Boundaries:**

- **Roof:** perineal membrane .
- **Floor:** *Colle's fascia*.
- **Anteriorly:** the pouch is open as *Colle's fascia* is continuous above with the membranous layer of superficial fascia of the anterior abdominal wall (*Scarpa's fascia*).

## Perineum

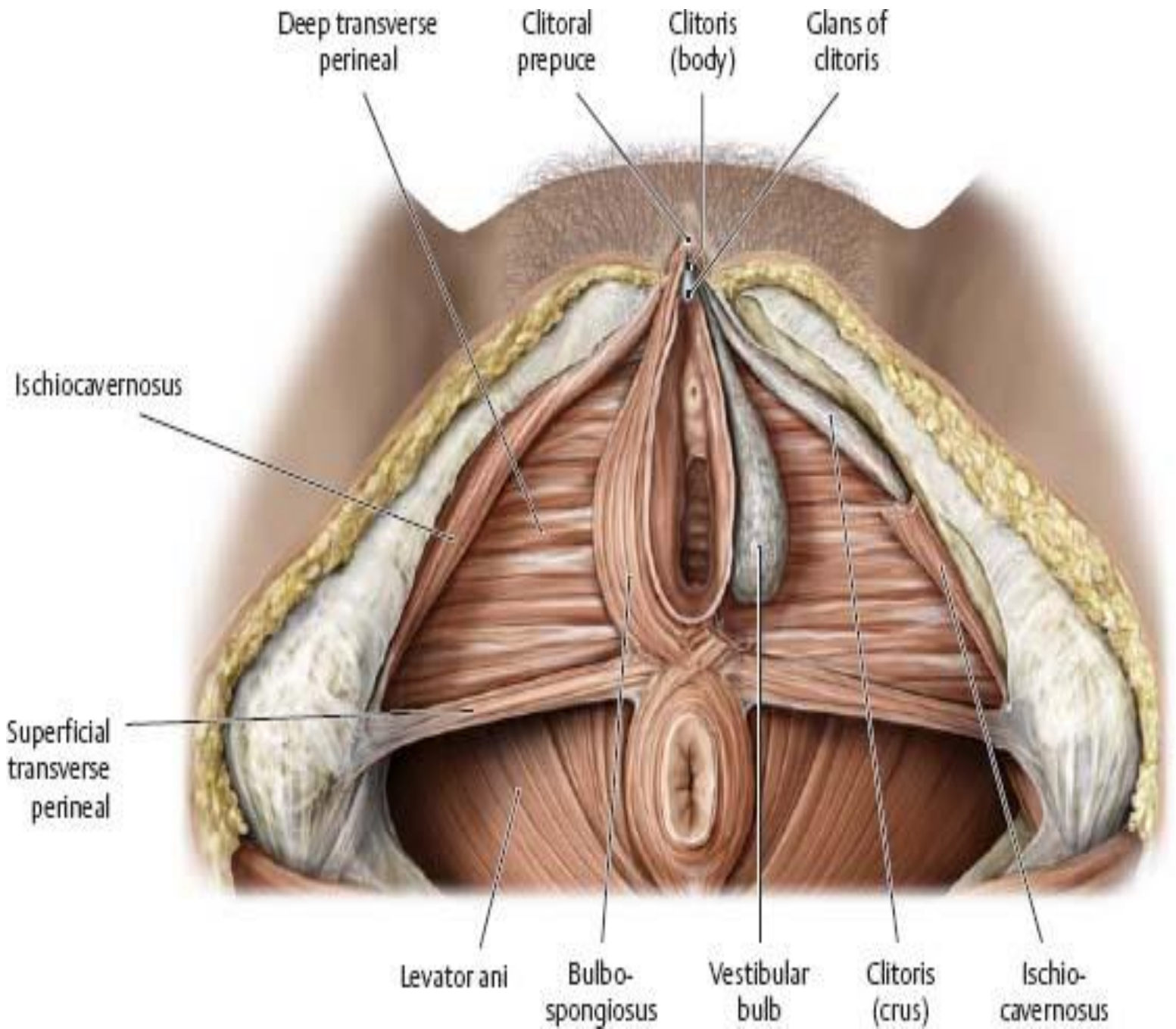
- **Posteriorly:** it is closed as *Colle's fascia* (floor) fuses with posterior border of the perineal membrane (roof).
- **On either side:** it is closed as both (the roof and the floor) are attached to the pubic arch.

### ❖ Contents of the superficial perineal pouch:

In male	In female
<p>1.Root of the penis:</p> <ul style="list-style-type: none"> <li>a. Bulb of penis</li> <li>b. Two crura of penis</li> </ul> <p>2.Superficial perineal muscles:</p> <ul style="list-style-type: none"> <li>a. Bulbospongiosus</li> <li>b. Ischiocavernosus</li> <li>c. Superficial transversus perinei</li> </ul> <p>3.Branches of internal pudendal artery:</p> <ul style="list-style-type: none"> <li>• Two terminal branches ( Deep &amp; Dorsal artery of penis)</li> <li>• Artery of bulb of penis .</li> <li>• Urethral artery .</li> <li>• Perineal artery and its two branches ( Posterior scrotal branch &amp; Transverse perineal branch )</li> </ul> <p>4.Branches of pudendal nerve :</p> <ul style="list-style-type: none"> <li>• perineal nerves (Posterior scrotal &amp; muscular)</li> <li>• Dorsal nerve of penis.</li> </ul>	<p>1.Root of clitoris:</p> <ul style="list-style-type: none"> <li>a.Bulb of vestibule ( clitoris )</li> <li>b.Two crura of clitoris</li> </ul> <p>2.Superficial perineal muscles:</p> <ul style="list-style-type: none"> <li>a. Bulbospongiosus</li> <li>b. Ischiocavernosus</li> <li>c. Superficial transversus perinei</li> </ul> <p>3.Branches of internal pudendal artery:</p> <ul style="list-style-type: none"> <li>• Two terminal branches ( Deep &amp; Dorsal artery of clitoris)</li> <li>• Artery of bulb of vestibule .</li> <li>• Urethral artery .</li> <li>• Perineal artery and its two branches ( Posterior labial branch &amp; Transverse perineal branch )</li> </ul> <p>4.Branches of pudendal nerve :</p> <ul style="list-style-type: none"> <li>• perineal nerves (Posterior labial &amp; muscular)</li> <li>• Dorsal nerve of clitoris .</li> </ul>

*Perineum*

5.Deep dorsal vein of penis .	5.Greater vestibular glands <i>(Bartholin's glands)</i>
-------------------------------	--

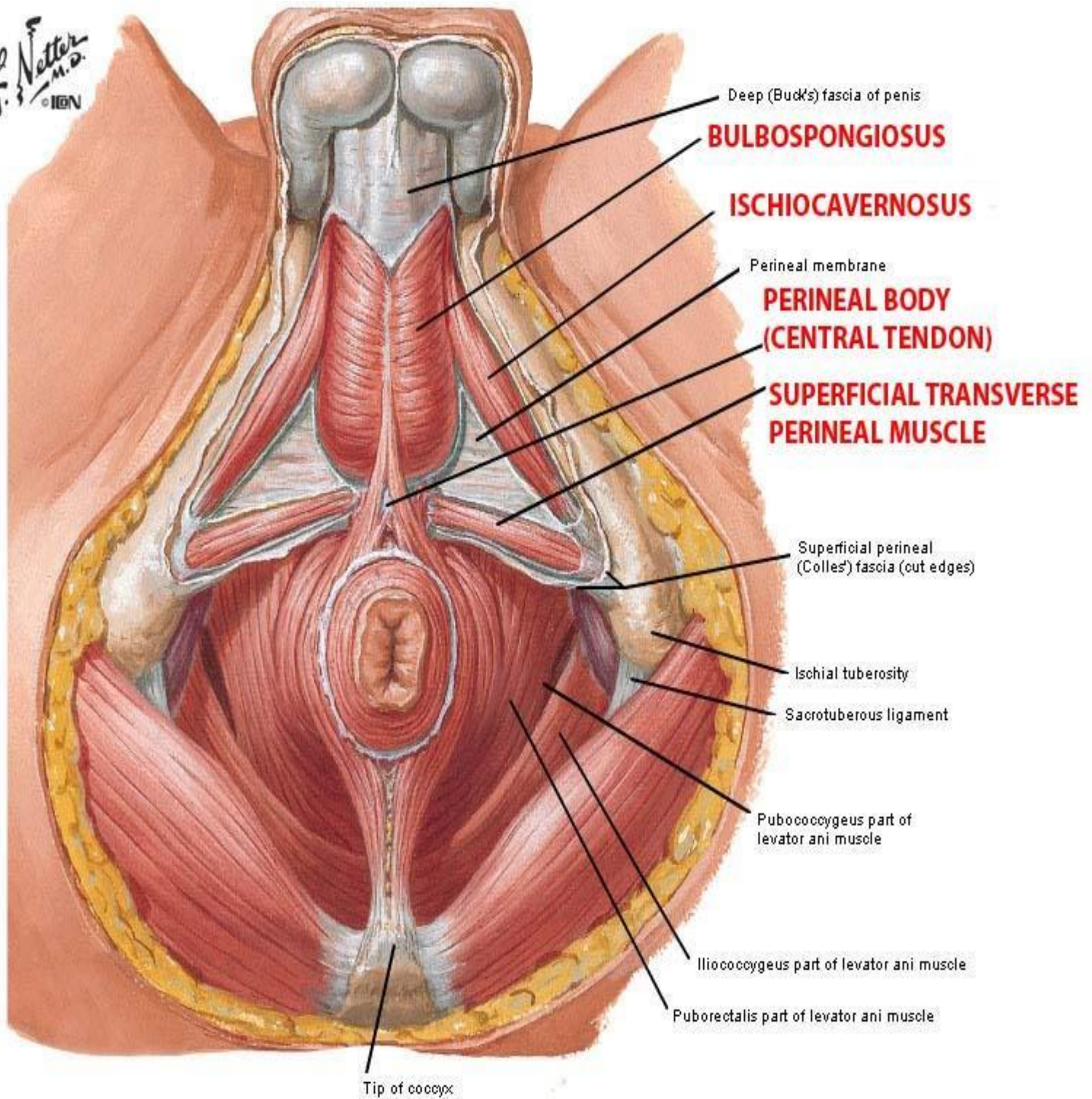


**\* Superficial & deep perineal pouches in female \***  
**( perineal membrane is removed )**



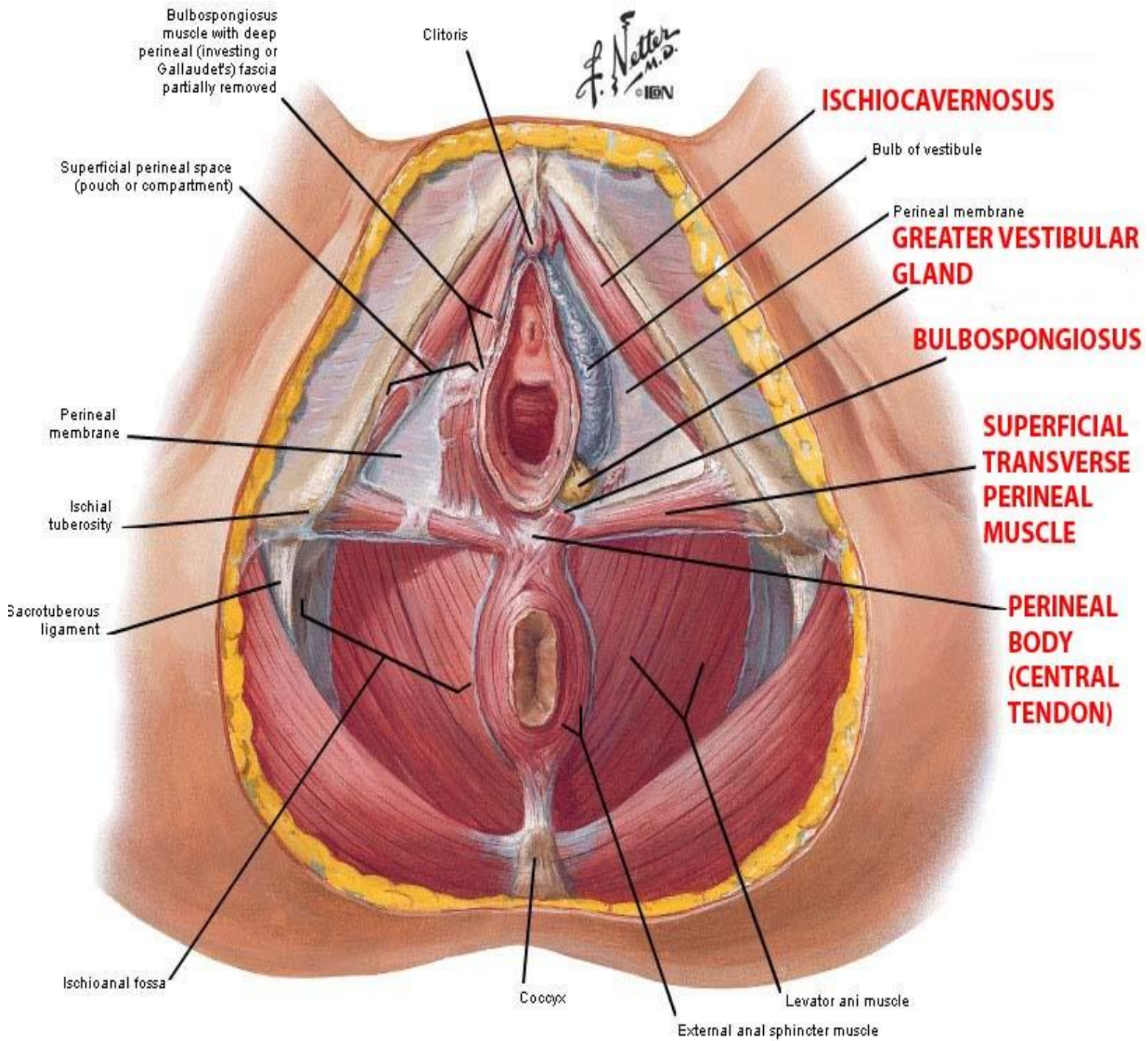
# Perineum

F. Netter M.D.  
© IGV



**\* Superficial perineal pouches in male \***

# Perineum



**\* Superficial perineal pouches in female \***

❖ **Superficial perineal muscles:** 3 pairs of muscles

**1. Two bulbospongiosus muscles:**

They arise from the perineal body and surround the bulb of the penis or clitoris. The muscles of both sides meet each other in a median raphe. They contract to evacuate the last drops of urine or semen.

**2. Two ischiocavernosus muscles:**

They arise from the ischial ramus and are inserted in the crus of the penis (in male) or clitoris (in female). They compress the crus of penis to maintain erection.

**3. Two superficial transversus perinei muscles:**

They arise from the inner surface of the ischial ramus and are inserted in the perineal body.

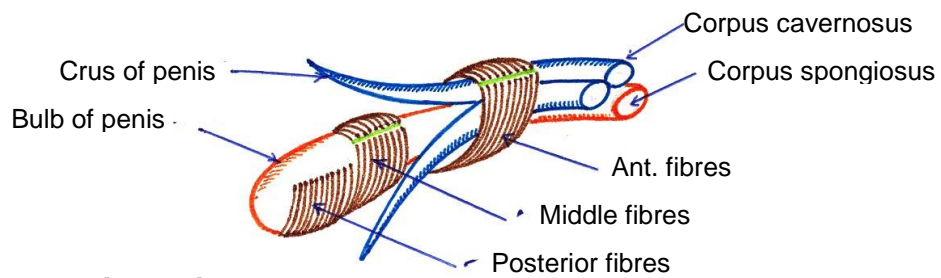
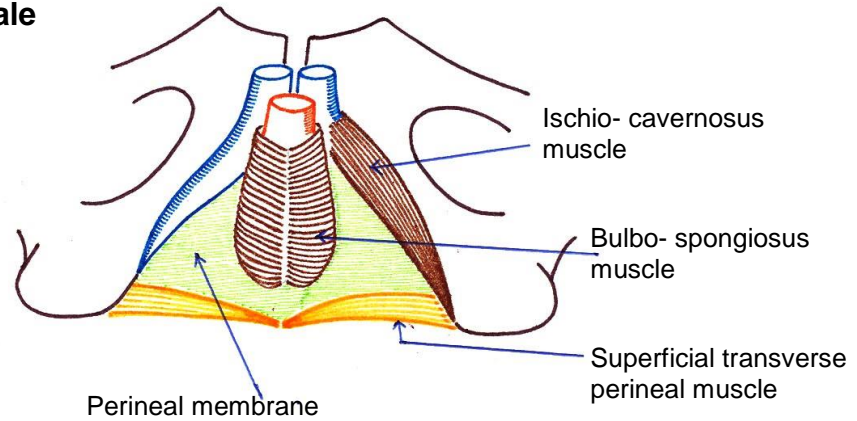
❖ **Nerve supply:** all these muscles are supplied by the perineal branch of pudendal nerve.

❖ **Applied anatomy :**

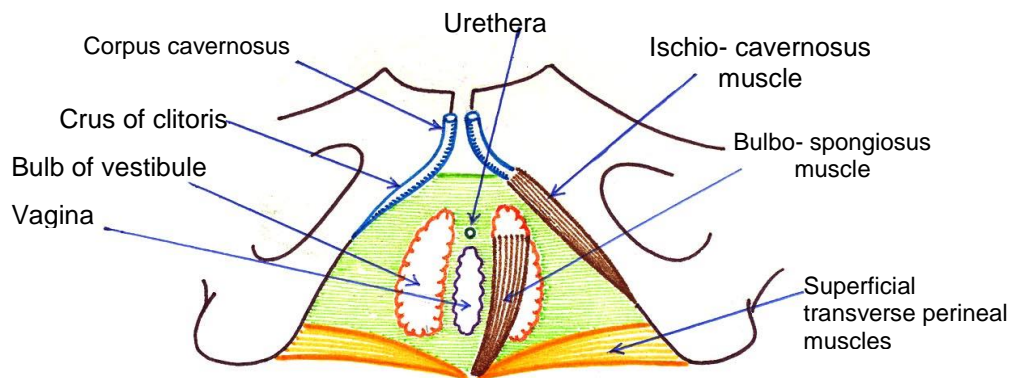
Injury of the bulbar part of male urethra leads to extravasation of urine into the superficial perineal pouch, the urine then spreads into the scrotum and penis. It can ascend in front of the symphysis pubis to reach the anterior abdominal wall between Scarpa's fascia & muscles of anterior abdominal wall and descend to the upper part of the front of thigh down to the line of fusion between the membranous layer of the superficial fascia and fascia lata.

# Perineum

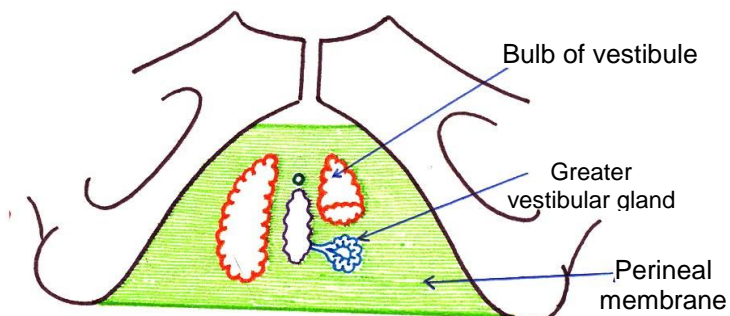
## Muscles of superficial perineal pouch in male



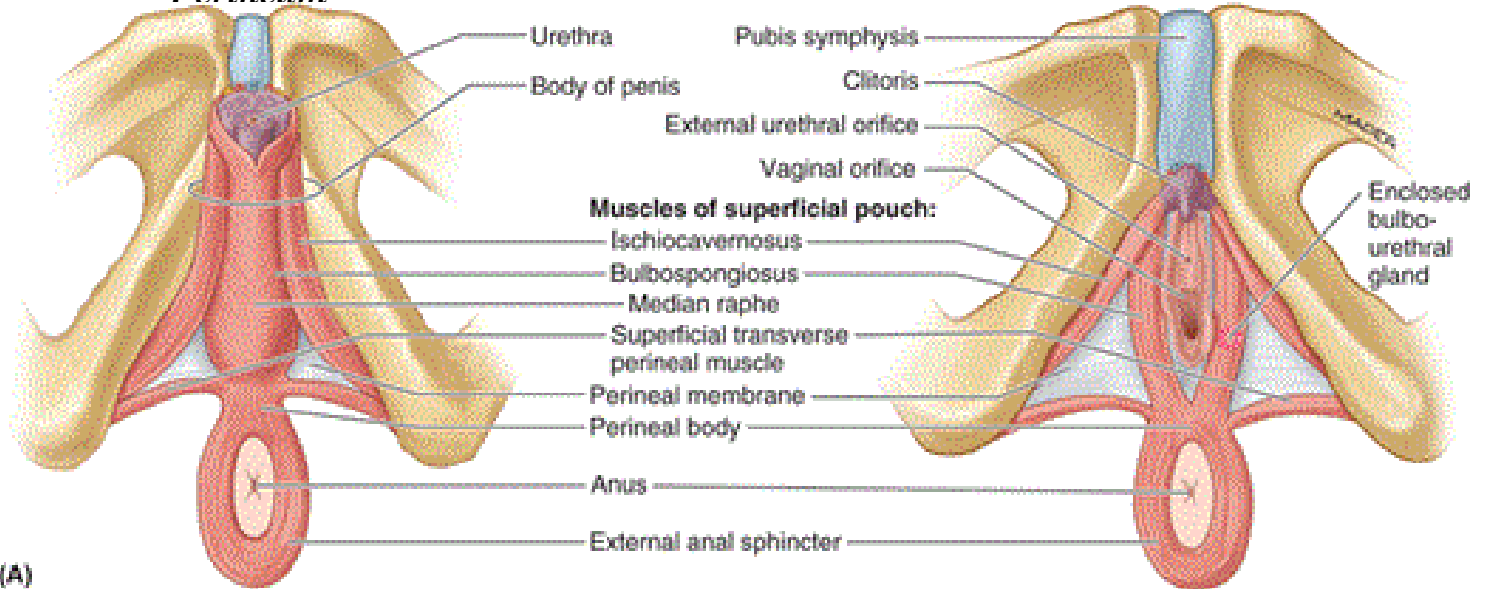
## Bulbo- spongiosus in Male



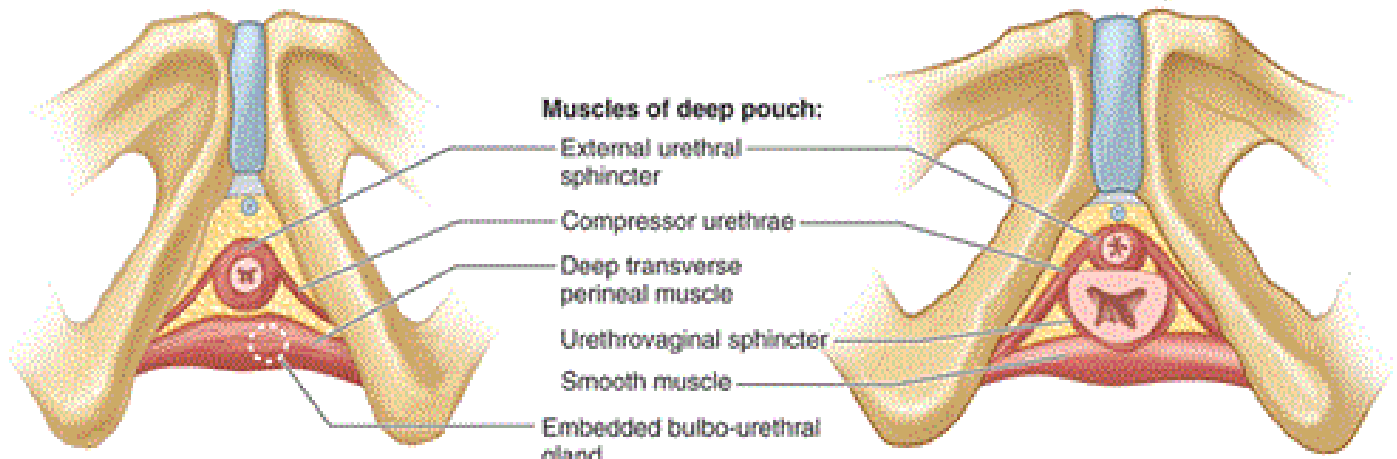
## Contents & Muscles of superficial perineal



**Perineum**



(A)

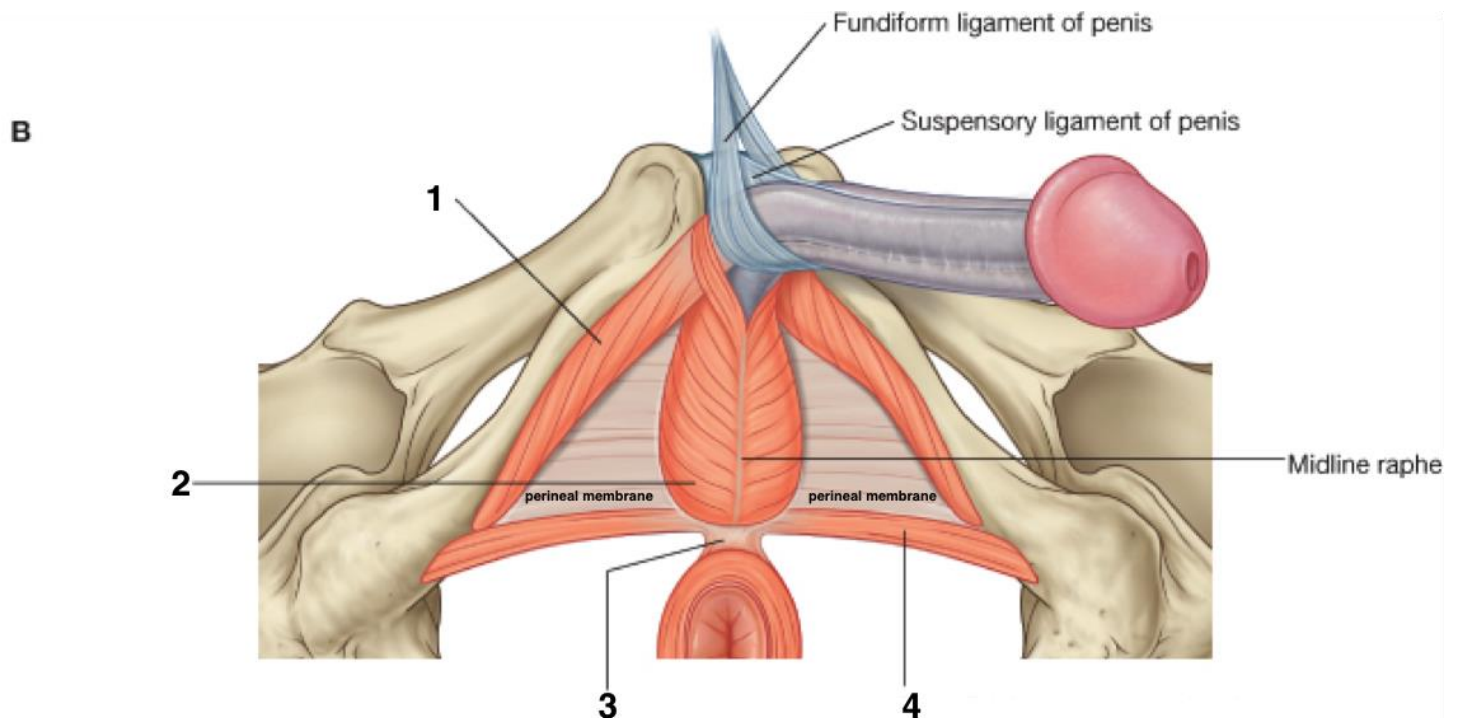


(B)

Male

Inferior views

Female

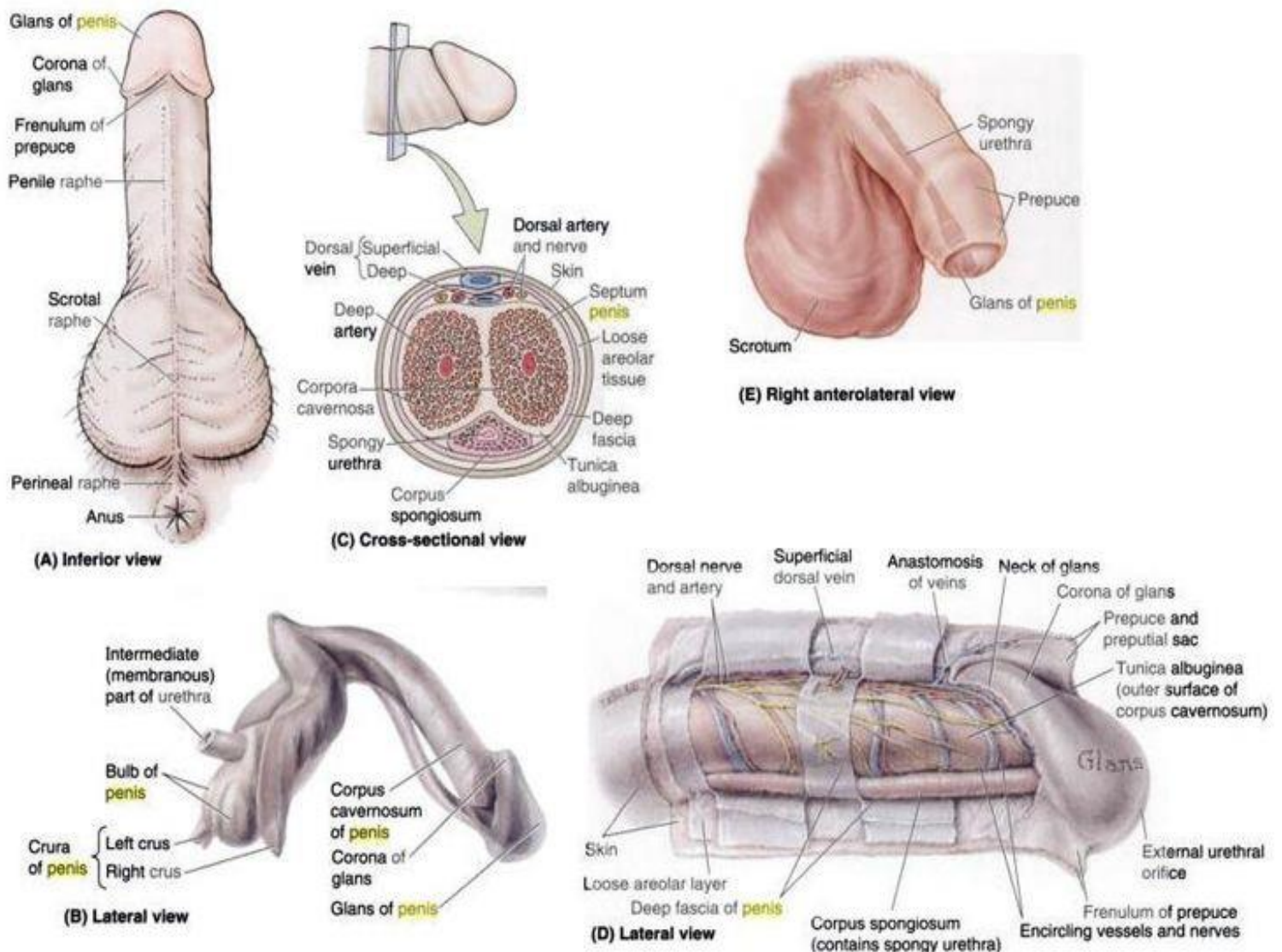


B

# Perineum

## \*EXTERNAL GENITALIA IN MALE\*

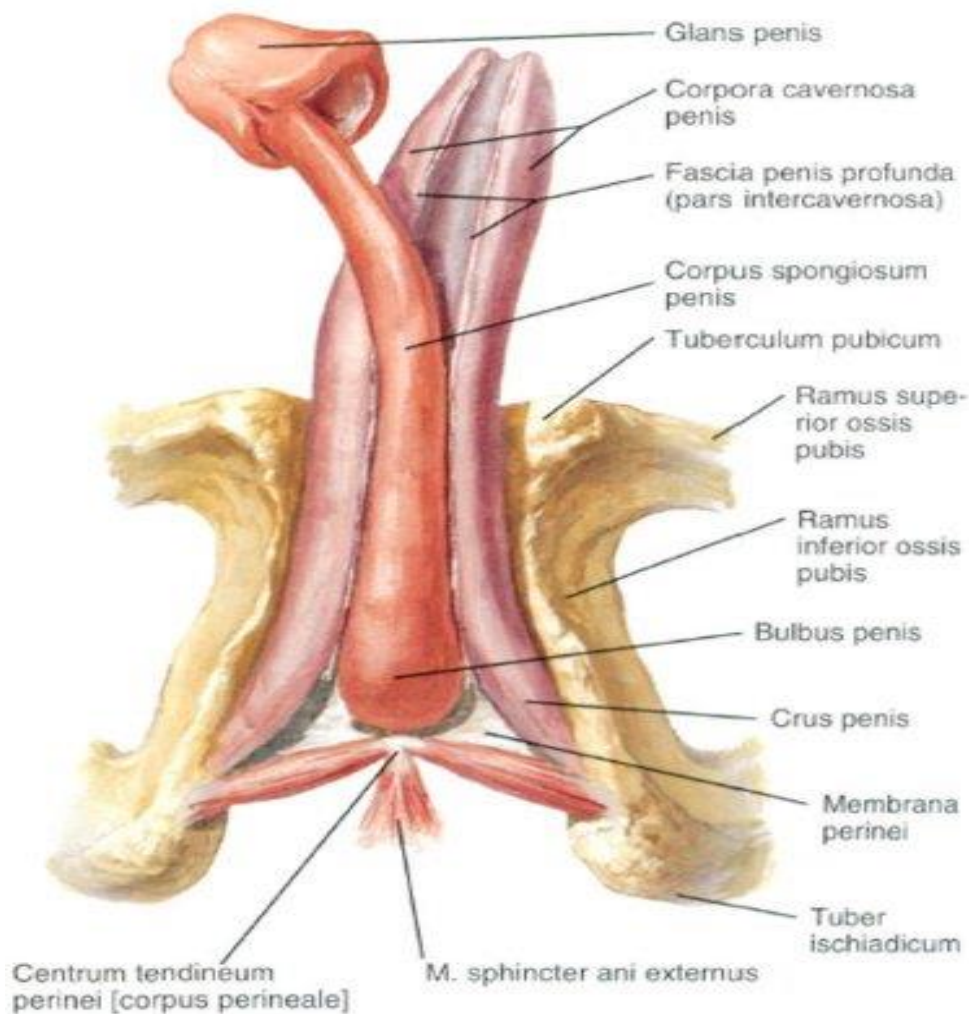
1. **Scrotum:** discussed before
2. **Penis:** consists of *Root*, *body* and *glans penis*.



**1. Root of the penis:** is the posterior attached end of penis & lies in the superficial perineal pouch and consists of 3 structures:

## Perineum

- **Two crura:** are attached to the pubic arches. They extend anterior in the the body of the penis as the 2 corpora cavernosa . Each crus is covered by an ischiocavernosus muscle
- **Bulb of the penis:** Is attached to the perineal membrane and is covered by the bulbospongiosus muscle. It extends anterior in the the body of the penis as the corpus spongiosum . The bulb of the penis is pierced by the spongy urethra , the ducts of the bulbo-urethral glands which open in the spongy urethra and artery to the bulb .



## Parts of penis

## *Perineum*

---

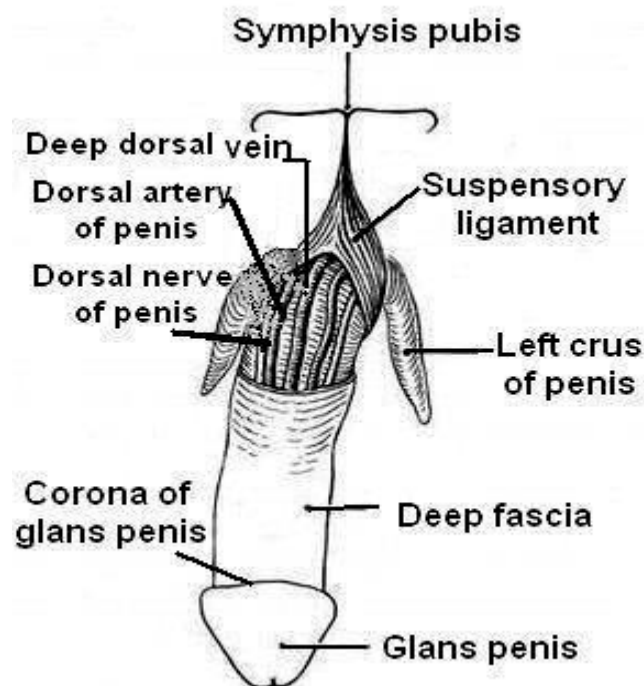
**2. Body of the penis:** is the anterior free part and consists of 3 elongated erectile tissue:

- Two corpora cavernosa: placed side by side on the dorsal aspect.
- One corpus spongiosum: placed on the ventral aspect of the 2 corpora cavernosa. It contains the spongy urethra.

**3. Glans penis:** is the distal enlarged end of corpus spongiosum. It is covered by thin skin called the *prepuce* which is removed in circumcision. The inner layer of the prepuce is connected to the lower margin of the external urethral meatus by a median fold called the *frenulum*.

### ❖ **Ligaments of the penis:**

1. *Fundiform ligament (sling like):* arises from the inferior part of linea alba and splits into two parts which pass on each side of the penis.



**Ligaments and blood vessels of penis**



2. **The suspensory ligament of the penis:** is a fibro-elastic structure which spreads out from the anterior surface of the symphysis pubis and fuses with the deep fascia on the dorsum and sides of the penis.

### ❖ **Arterial supply of the penis:** 3 pairs of arteries.

All arteries supplying the penis are branches from the internal pudendal artery.

1. **Two deep arteries:** each runs inside the corpus cavernosum supplying it. Each deep artery breaks into small tortuous *helicine (helix: coil)* arteries which supply blood during erection.

2. **Two arteries of the bulb:** each runs inside the bulb of the penis and then in the corpus spongiosum alongside the urethra .

3. **Two dorsal arteries:** each runs lateral to the deep dorsal vein of the penis and supplies the skin and fascia of the penis.

### ❖ **Venous drainage:**

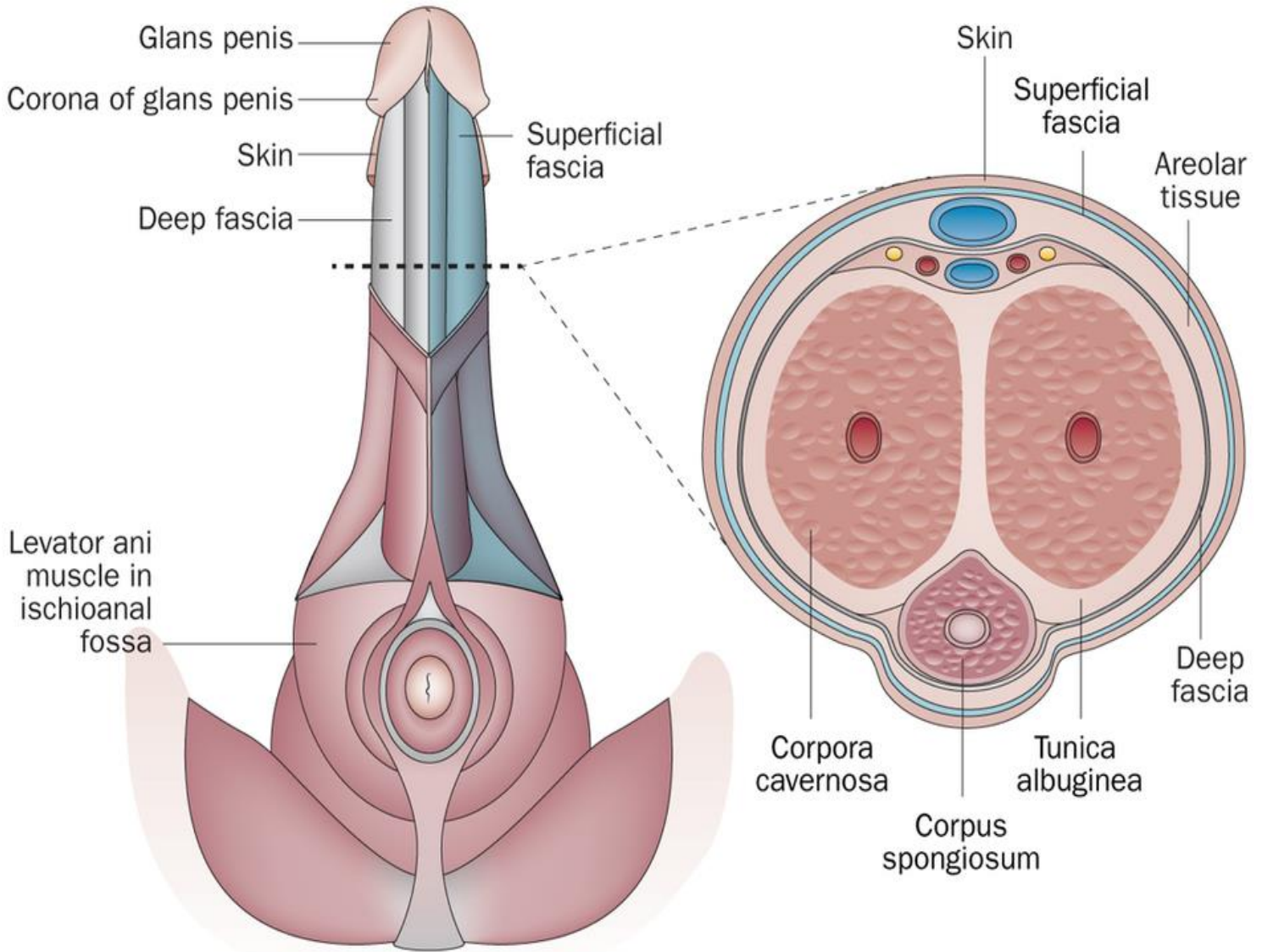
1. **Superficial dorsal vein:** runs superficial to the fascia of the penis in the median plane in the dorsum of the penis. It drains into the great saphenous vein.

2. **Deep dorsal vein:** it runs deep to the fascia of the penis in the median plane on the dorsal surface of the penis. It drains deeply into the prostatic venous plexus through the gap between the transverse perineal ligament and the inferior pubic ligament.

### ❖ **Nerves of the penis:**

- **Right and left dorsal nerves of the penis:** arise from the pudendal nerve. Each nerve runs lateral to the dorsal artery of the penis.

# Perineum



Nature Reviews | **Urology**

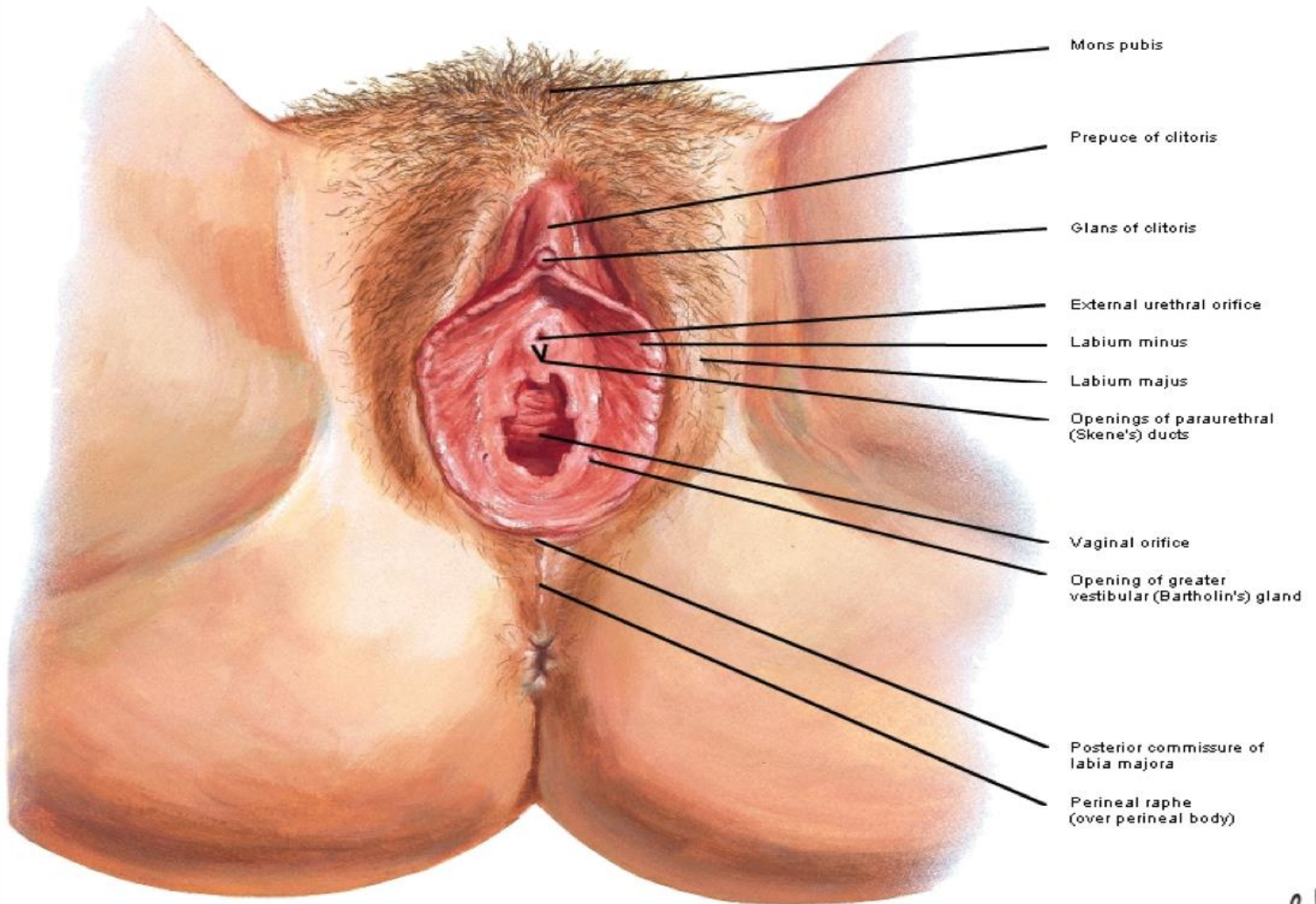
**Transverse section of the penis**

**\*EXTERNAL GENITALIA IN FEMALE\***

**(VULVA)**

1. **Mons pubis:** an elevated region over the symphysis pubis which contains a large amount of subcutaneous fat.
2. **Two labia majora:** are two rounded skin folds which form the lateral boundaries of the vulva.
3. **Two labia minora:** are small folds of skin medial to the labia majora. The space between the 2 labia minora is called the *vestibule* . Deep to labia minora, there is the bulb of vestibule. *Anteriorly* each splits as it approaches the clitoris. The smaller , posterior pair fuse and are attached to the inferior surface of the clitoris as *the fernulum* of the clitoris. The anterior pair unite to form a hood over the tip of the clitoris , *the prepuce of the clitoris*. *Posteriorly* they are connected by a thin tissue called the *fourchette*.
4. **Clitoris:** it is a miniature of penis in male.
5. **Vestibule:** is the space between the two labia minora. It contains the openings of:
  - *Female urethra* (external urethral meatus) behind the clitoris.
  - *Vaginal orifice:* it opens behind the urethra and is protected in the virgin by a membrane called *hymen* which is usually perforated at its center.
  - *Greater vestibular (Bartholin's) glands:* each gland lies on each side of the opening of vagina in the superficial perineal pouch. Their ducts open in the vestibule.

## Perineum and External Genitalia of Female Vulva or Pudendum



### External genitalia of female

## Perineum

---

